

# We are IntechOpen, the world's leading publisher of Open Access books Built by scientists, for scientists

5,500

Open access books available

135,000

International authors and editors

165M

Downloads

Our authors are among the

154

Countries delivered to

TOP 1%

most cited scientists

12.2%

Contributors from top 500 universities



WEB OF SCIENCE™

Selection of our books indexed in the Book Citation Index  
in Web of Science™ Core Collection (BKCI)

Interested in publishing with us?  
Contact [book.department@intechopen.com](mailto:book.department@intechopen.com)

Numbers displayed above are based on latest data collected.  
For more information visit [www.intechopen.com](http://www.intechopen.com)



# A Removable Class III Traction Appliance for Early Class III Treatment

*Kristin N. Moore, David R. Musich, Donald Taylor,  
Budi Kusnoto and Carla A. Evans*

## Abstract

Maxillary, mandibular, and dental effects resulting from the use of a removable intraoral Class III traction appliance as well as the protraction facemask in treatment of Class III malocclusion were assessed. This is a retrospective study comparing measurements from pre-treatment and post-treatment lateral cephalometric radiographs of two groups. Group 1 consisted of 25 patients treated with rapid palatal expansion followed by a removable intraoral Class III traction appliance. Group 2 consisted of 25 patients treated with rapid palatal expansion followed by a protraction facemask. The subjects were Caucasian, both male and female, with an age range of 3 to 12 years. The only significant differences were in length of treatment time and the skeletal change of angle SNA. The mean treatment times were 6.96 months and 10.96 months in the removable Class III traction appliance and protraction facemask groups, respectively. The mean increase in SNA was 0.46 degrees in the removable Class III traction appliance group and 1.81 degrees in the protraction facemask group. A removable Class III traction appliance provides orthodontists with another useful Class III treatment modality.

**Keywords:** Class III malocclusion, Class III treatment, protraction facemask, traction, orthodontics

## 1. Introduction

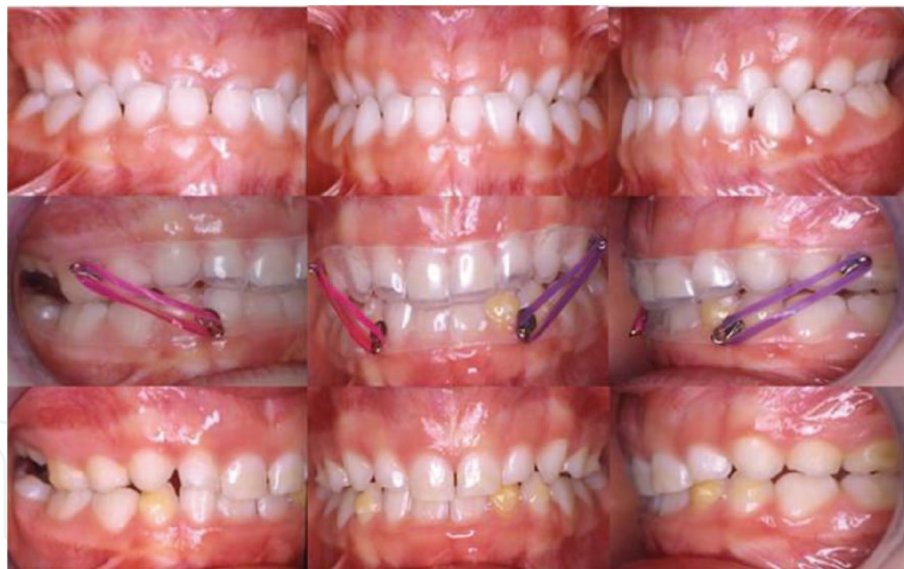Class III malocclusion can result from mandibular prognathism, maxillary skeletal retrusion or a combination of both [1]. Many treatment philosophies and appliances have been used to treat this problem, such as protraction facemask, chin cup, and Frankel's FR-III appliance and orthognathic surgery. Miniplates and temporary anchorage devices are also being used in order to minimize the negative side effects that can occur with treatment. In Class III malocclusion, an accurate diagnosis and timing of treatment are considerations in order to achieve optimal results.

The orthopedic facemask was developed in the 1960's by Delaire [2] and has been shown to be effective in treatment of Class III malocclusion in early mixed or late mixed dentition. It can assist in correction of maxillary skeletal retrusion, maxillary dentoalveolar retrusion, mandibular prognathism, and decreased lower facial height. It can produce the following effects: correction of a centric occlusion to centric relation (CO-CR) discrepancy, forward movement of the maxilla, forward movement of the maxillary dentition, lingual tipping of the lower incisors, and the downward

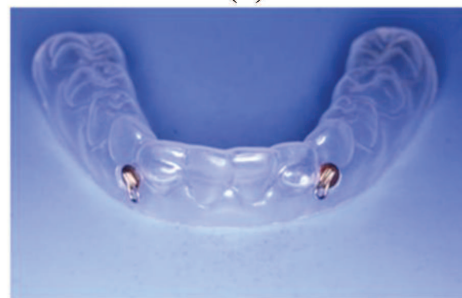and backward movement of the mandible [3]. The protraction facemask applies an anterior force on the circummaxillary sutures and stimulates bone apposition in suture areas [4]. Generally the facemask is prescribed to be worn by the patient for 12 to 16 hours per day with forces ranging between 180 g and 500 g [4, 5]. It has been suggested that the facemask be worn until the patient achieves approximately 4-5 mm of positive overjet [3]. It is often used in combination with a rapid palatal expander.

Macdonald et al. [6] found that facemask treatment increased the convexity of the facial profile due to the forward displacement and downward and backward rotation of the maxilla as well as an opening rotation of the mandible. The maxillary incisors moved forward as the mandibular incisors retruded. Ngan et al. [7] found that the maxilla moved forward an average of 2.1 mm and the molar relationship corrected to Class I or even Class II relationship. In addition, the lower face height increased and the overbite decreased by an average of 1.5 mm. Nartallo-Turley and Turley [8] found an increase in SNA, maxillary depth, and ANB as well as forward movement of A-point and ANS. The maxilla moved forward and rotated counter-clockwise and the mandible rotated clockwise as the SNB and facial depth decreased.

Intraoral devices for treatment of Class III malocclusions [9, 10] have been described. A removable Class III traction appliance using elastics to produce the desired vector of force (**Figures 1a** and **1b**) was developed in the 1980's to overcome issues of patient compliance with the protraction facemask. It can be used in conjunction with rapid palatal expansion or fixed appliances in Class III treatment. This removable appliance can be used at any age and aids in disclusion of the dentition as well as directional traction as it addresses maxillary skeletal retrusion,



(a)



(b)

**Figure 1.**

*(a) Anterior crossbite correction using the removable traction appliance followed by a retention phase using the same appliance. Retention ridges can be seen in the bottom row. (b) Location of hooks on the lower removable traction appliance.*

maxillary dentoalveolar retrusion, and functional shifts associated with mandibular prognathism [11]. Similar to protraction facemask, it is said to have the following effects: correction of a CO-CR discrepancy, forward and downward displacement of the maxilla, forward movement of the maxillary dentition, lingual tipping of the lower incisors, and the downward and backward movement of the mandible. The appliance is worn by the patient full time (20–22 hours per day) sometimes in conjunction with a rapid palatal expander and/or partial or full braces treatment until 3–4 mm of positive overjet is achieved [10].

The main advantages for the removable Class III traction device are the capacity to have light, continuous, full-time forces acting to disarticulate the occlusion and allow correction of the posterior and anterior crossbites with minimal occlusal interference. 4–8 ounce elastics are recommended for younger patients and heavier forces are recommended for older patients. 10–12 ounce elastics are sometimes recommended at night based on individual patient needs. If needed, a removable appliance could be used in conjunction with a facemask at night. Another advantage of the removable appliance is that it is easy to gain optimal compliance in patients and is tolerated well by the patient.

Some disadvantages have been reported with the removable orthodontic traction device. In the mixed dentition, strong retention from the composite ridges can accelerate exfoliation of the primary canines, compromising the anchor teeth and causing some discomfort to the patient. For this reason, it is recommended that the retentive ridges be used on teeth with the best root structure. The appliance can also experience significant wear if patients have a nocturnal bruxism habit. However, replacement of the appliance is simple and inexpensive.

This study was designed to determine whether treatment of Class III malocclusion with a removable Class III traction appliance has outcomes similar to a protraction facemask. Specifically, the objectives were to compare maxillary, mandibular, and dental effects resulting from use of both appliances.

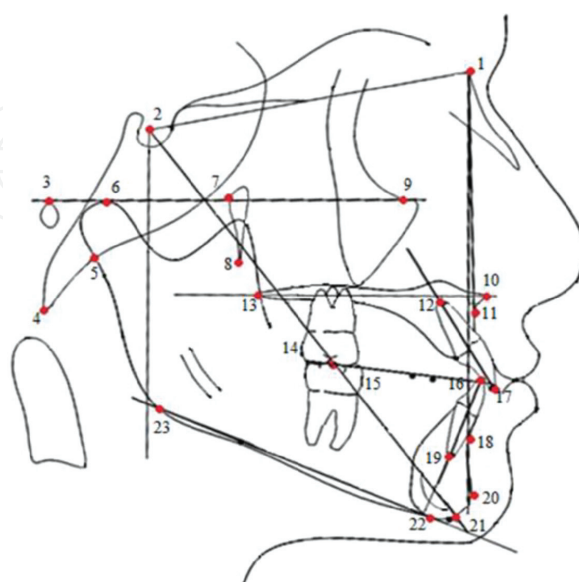
## **2. Comparison of removable traction appliance and protraction facemask**

### **2.1 Methods**

The removable orthodontic traction device described in this chapter (**Figures 1a** and **1b**) is relatively inexpensive and easy to fabricate. The first step in making this appliance is the application of retentive ridges to several of the patient's mandibular teeth especially in the anterior region. This is done by etching the tooth and then applying a composite resin to the surface of the tooth in a ridge shape, about 75% of the mesial-distal tooth width and 2–3 mm in height. Next, an impression is taken of the arch and a stone model is fabricated. Separating medium is applied to the cast and allowed to dry. A vacuum formed type retainer using C+ plastic from DENTSPLY Raintree Essix (DENTSPLY Raintree Essix, Sarasota, Florida, USA) is fabricated on the model. Durasoft® or Biocryl® from Great Lakes Orthodontics (Great Lakes Orthodontics, Ltd., Tonawanda, New York, USA) can also be used. If a hygienic fixed expander is in place, a similar removable appliance can be made for attachment of elastics to the maxillary arch. After trimming, Caplin hooks (DENTSPLY GAC International, Bohemia, NY, USA) are added to the retainers in the upper molar and lower canine regions by heating each hook with a torch and pressing it into the appropriate area on the appliance, ensuring it does not melt completely through the plastic (**Figure 1b**). After ensuring the hooks are secure, the appliance is inserted into the patient's mouth and traction is initiated using Class III elastics. The patient is instructed to wear the appliance full time. Monthly visits are recommended to monitor for progress [10].

In this retrospective study, Group 1 consisted of 25 Caucasian patients from a private orthodontic practice who had been treated with rapid palatal expansion (hygienic Hyrax™ expander) followed by the removable intraoral Class III traction appliance and 180 g force from Class III elastics. Group 2 consisted of 25 Caucasian patients treated with a rapid palatal expansion (hygienic Hyrax™ expander) followed by a protraction facemask (AD Protraction Facemask; Ormco, Orange, CA, USA) with 350-400 g traction, taken from a different private orthodontic practice. Patient data from both offices were collected, de-identified, and assigned case numbers by the private practice orthodontists. Patients from both groups were treated until positive overjet was achieved. The inclusion criteria for both groups were an initial diagnosis of a dental and skeletal Class III malocclusion based on an ANB angle less than 0 degrees, Wits appraisal less than 0, and at least 25% Class III molar relationship in permanent or primary molars. If any functional shifts were present, they were not recorded and thus not taken into consideration. Patients were excluded if any of the following were present: dentofacial deformities (i.e. cleft lip and palate), missing teeth, periodontal disease, or prior treatment elsewhere.

The patients' pre-treatment (T1) and post-treatment (T2) lateral cephalometric radiographs were collected, scanned and digitized. The radiographs were uploaded and traced using Dolphin software (Dolphin, Chatsworth, CA, USA). Skeletal and dental measurements were collected. The landmarks seen in **Figure 2** were used in the cephalometric analysis. The following cephalometric measurements were used: SNA, SNB, ANB, Wits appraisal, Y axis, angle of convexity, mandibular plane angle, facial angle, cant of occlusal plane, upper incisor to SN, lower incisor to mandibular plane, interincisal angle, upper incisor to NA, lower incisor to NB, overbite, overjet, millimeter measurement from sella perpendicular to palatal plane to maxillary molar, millimeter measurement from sella perpendicular to palatal plane to maxillary incisor, millimeter measurement from sella perpendicular to palatal plane to mandibular molar, millimeter measurement from sella perpendicular to palatal plane to mandibular incisor, millimeter measurement from sella to A point, millimeter measurement from PTM to ANS.



**Figure 2.**

*Landmarks: 1-Nasion (N); 2-Sella (S); 3-Porion (Po); 4-Basion (Ba); 5-Articulare (Ar); 6-Condylion (Co); 7-PT point; 8-Pterygomaxillare (PTM); 9-Orbitale (or); 10-anterior nasal spine (ANS); 11-Subspinale (a); 12-upper central incisor root tip; 13-posterior nasal spine (PNS); 14-upper first molar occlusal; 15-lower first molar occlusal; 16-lower central incisor crown; 17-upper central incisor crown; 18-Supramentale (B); 19-lower central incisor root; 20-Pogonion (Pog); 21-Gnathion (Gn); 22-Menton (me); 23-Gonion (go).*

A statistical power analysis determined that a sample of 20–25 subjects would yield a power of 0.8 which would provide statistically significant results. Intra-reliability and inter-reliability tests all had a correlation of 0.8 or above and those values were considered to be reliable. An independent *t*-test was used to compare sample descriptives, and to compare T1 values. An independent *t*-test for parametric data and a Mann–Whitney test for non-parametric data was utilized to evaluate mean differences between groups. Also, as another indicator of similarity of samples, cervical vertebral maturation (CVM) stage for T1 and T2 for both groups, means and standard deviations were calculated according to the method of Baccetti et al. [12].

## 2.2 Results

### 2.2.1 Sample descriptives

Means and standard deviations were calculated for both T1 and T2 chronological ages for both groups (**Table 1**). The mean age for Group 1 at T1 was 8 years, 8 months and at T2 was 10 years, 6 months. The mean age for Group 2 at T1 was 8 years, 9 months and at T2 was 11 years, 1 month. An independent *t*-test showed that no significant differences existed among the T1 and T2 chronological ages between groups ( $p > 0.05$ ). To examine cervical vertebral maturation (CVM) stages for T1 and T2 for both groups, means and standard deviations were calculated. The mean CVM for group 1 at T1 was 2.1 and at T2, 2.8. The mean CVM for group 2 at T1 was 2.4 and at T2, 3.1. An independent *t*-test showed that no significant differences occurred at T1 and T2 between groups. For length of treatment of both groups, an independent *t*-test was used and showed that significant differences existed between groups ( $p < 0.05$ ).

### 2.2.2 Comparison of T1 values and T2 values between groups

Independent *t*-tests were used to evaluate if any differences existed among the T1 values and the T2 values between groups. It was found that no significant differences existed among the T1 values between groups ( $p > 0.05$ ).

### 2.2.3 Comparison of T2-T1 differences between groups

Differences between T2 and T1 were calculated for each variable within each group (**Tables 2 and 3**). An independent *t*-test was used to evaluate if any

Group	Traction	Protaction facemask
Total number of patients	25	25
Number of males	13	13
Number of females	12	12
Average age (years)	8.74	8.87
Age range (years)	3.11–12.1 (SD 2.08)	6.9–12.1 (SD 1.47)
Average CVM	2	2
CVM range	2–3	2–5
Average treatment time (months)	6.96*	10.96*
Range of treatment time (months)	2–20	4–18

\*Indicates  $p < 0.001$ .

**Table 1.**  
*Sample characteristics.*

significant differences existed among the changes from T1 to T2 between groups for parametric data. A Mann–Whitney test was used for non-parametric data (group 2 for sella to A point and millimeter measurement of Ptm to ANS). SNA showed that significant differences existed between groups ( $p < 0.05$ ). All other values showed no significant differences between group 1 and group 2 ( $p > 0.05$ ).

### 2.3 Discussion

Both groups started and ended treatment at similar chronologic ages. Since chronologic age is only a rough indicator of maturity, cervical vertebral maturation stage was examined for both groups. Peak mandibular growth or the pubertal growth spurt has been found to occur between stages 3 and 4 with active growth having been completed at stage 6 [12]. Baccetti et al. [12] suggested that Class III treatment with rapid maxillary expansion and protraction facemask therapy should be started during stages 1 and 2 in order to produce the most effective results on the

Angular measurements (degrees)	Group	Mean	Standard deviation	t	df	Significance (2-tailed)																																																																																																																				
Facial angle	1	0.41	2.49	0.23	48	0.82																																																																																																																				
	2	0.24	2.62				Angle of convexity	1	-0.28	2.41	-1.66	32.74	0.11	2	1.73	5.55	SNA	1	0.46	1.71	-2.61	48	0.01*	2	1.81	1.96	SNB	1	0.15	1.48	-1.71	48	0.09	2	0.92	1.71	ANB	1	0.30	1.35	-1.04	36.71	0.31	2	0.90	2.53	FMA	1	0.02	3.23	-0.03	48	0.97	2	0.05	2.92	Y axis	1	0.36	2.50	-0.11	48	0.91	2	0.44	2.42	Cant of occlusal plane	1	-1.24	4.00	1.16	48	0.25	2	-2.47	3.52	Interincisal angle	1	-2.70	7.08	0.15	42.80	0.88	2	-3.07	10.19	U1-SN	1	4.25	6.04	-0.67	48	0.51	2	5.58	7.82	U1-NA	1	3.81	5.97	0.02	43.51	0.98	2	3.76	8.33	L1-MP	1	-1.40	5.28	0.28	48	0.78	2	-1.82	5.55	L1-NB	1	-1.41	4.88	0.13	48
Angle of convexity	1	-0.28	2.41	-1.66	32.74	0.11																																																																																																																				
	2	1.73	5.55				SNA	1	0.46	1.71	-2.61	48	0.01*	2	1.81	1.96	SNB	1	0.15	1.48	-1.71	48	0.09	2	0.92	1.71	ANB	1	0.30	1.35	-1.04	36.71	0.31	2	0.90	2.53	FMA	1	0.02	3.23	-0.03	48	0.97	2	0.05	2.92	Y axis	1	0.36	2.50	-0.11	48	0.91	2	0.44	2.42	Cant of occlusal plane	1	-1.24	4.00	1.16	48	0.25	2	-2.47	3.52	Interincisal angle	1	-2.70	7.08	0.15	42.80	0.88	2	-3.07	10.19	U1-SN	1	4.25	6.04	-0.67	48	0.51	2	5.58	7.82	U1-NA	1	3.81	5.97	0.02	43.51	0.98	2	3.76	8.33	L1-MP	1	-1.40	5.28	0.28	48	0.78	2	-1.82	5.55	L1-NB	1	-1.41	4.88	0.13	48	0.90	2	-1.59	5.13						
SNA	1	0.46	1.71	-2.61	48	0.01*																																																																																																																				
	2	1.81	1.96				SNB	1	0.15	1.48	-1.71	48	0.09	2	0.92	1.71	ANB	1	0.30	1.35	-1.04	36.71	0.31	2	0.90	2.53	FMA	1	0.02	3.23	-0.03	48	0.97	2	0.05	2.92	Y axis	1	0.36	2.50	-0.11	48	0.91	2	0.44	2.42	Cant of occlusal plane	1	-1.24	4.00	1.16	48	0.25	2	-2.47	3.52	Interincisal angle	1	-2.70	7.08	0.15	42.80	0.88	2	-3.07	10.19	U1-SN	1	4.25	6.04	-0.67	48	0.51	2	5.58	7.82	U1-NA	1	3.81	5.97	0.02	43.51	0.98	2	3.76	8.33	L1-MP	1	-1.40	5.28	0.28	48	0.78	2	-1.82	5.55	L1-NB	1	-1.41	4.88	0.13	48	0.90	2	-1.59	5.13																
SNB	1	0.15	1.48	-1.71	48	0.09																																																																																																																				
	2	0.92	1.71				ANB	1	0.30	1.35	-1.04	36.71	0.31	2	0.90	2.53	FMA	1	0.02	3.23	-0.03	48	0.97	2	0.05	2.92	Y axis	1	0.36	2.50	-0.11	48	0.91	2	0.44	2.42	Cant of occlusal plane	1	-1.24	4.00	1.16	48	0.25	2	-2.47	3.52	Interincisal angle	1	-2.70	7.08	0.15	42.80	0.88	2	-3.07	10.19	U1-SN	1	4.25	6.04	-0.67	48	0.51	2	5.58	7.82	U1-NA	1	3.81	5.97	0.02	43.51	0.98	2	3.76	8.33	L1-MP	1	-1.40	5.28	0.28	48	0.78	2	-1.82	5.55	L1-NB	1	-1.41	4.88	0.13	48	0.90	2	-1.59	5.13																										
ANB	1	0.30	1.35	-1.04	36.71	0.31																																																																																																																				
	2	0.90	2.53				FMA	1	0.02	3.23	-0.03	48	0.97	2	0.05	2.92	Y axis	1	0.36	2.50	-0.11	48	0.91	2	0.44	2.42	Cant of occlusal plane	1	-1.24	4.00	1.16	48	0.25	2	-2.47	3.52	Interincisal angle	1	-2.70	7.08	0.15	42.80	0.88	2	-3.07	10.19	U1-SN	1	4.25	6.04	-0.67	48	0.51	2	5.58	7.82	U1-NA	1	3.81	5.97	0.02	43.51	0.98	2	3.76	8.33	L1-MP	1	-1.40	5.28	0.28	48	0.78	2	-1.82	5.55	L1-NB	1	-1.41	4.88	0.13	48	0.90	2	-1.59	5.13																																				
FMA	1	0.02	3.23	-0.03	48	0.97																																																																																																																				
	2	0.05	2.92				Y axis	1	0.36	2.50	-0.11	48	0.91	2	0.44	2.42	Cant of occlusal plane	1	-1.24	4.00	1.16	48	0.25	2	-2.47	3.52	Interincisal angle	1	-2.70	7.08	0.15	42.80	0.88	2	-3.07	10.19	U1-SN	1	4.25	6.04	-0.67	48	0.51	2	5.58	7.82	U1-NA	1	3.81	5.97	0.02	43.51	0.98	2	3.76	8.33	L1-MP	1	-1.40	5.28	0.28	48	0.78	2	-1.82	5.55	L1-NB	1	-1.41	4.88	0.13	48	0.90	2	-1.59	5.13																																														
Y axis	1	0.36	2.50	-0.11	48	0.91																																																																																																																				
	2	0.44	2.42				Cant of occlusal plane	1	-1.24	4.00	1.16	48	0.25	2	-2.47	3.52	Interincisal angle	1	-2.70	7.08	0.15	42.80	0.88	2	-3.07	10.19	U1-SN	1	4.25	6.04	-0.67	48	0.51	2	5.58	7.82	U1-NA	1	3.81	5.97	0.02	43.51	0.98	2	3.76	8.33	L1-MP	1	-1.40	5.28	0.28	48	0.78	2	-1.82	5.55	L1-NB	1	-1.41	4.88	0.13	48	0.90	2	-1.59	5.13																																																								
Cant of occlusal plane	1	-1.24	4.00	1.16	48	0.25																																																																																																																				
	2	-2.47	3.52				Interincisal angle	1	-2.70	7.08	0.15	42.80	0.88	2	-3.07	10.19	U1-SN	1	4.25	6.04	-0.67	48	0.51	2	5.58	7.82	U1-NA	1	3.81	5.97	0.02	43.51	0.98	2	3.76	8.33	L1-MP	1	-1.40	5.28	0.28	48	0.78	2	-1.82	5.55	L1-NB	1	-1.41	4.88	0.13	48	0.90	2	-1.59	5.13																																																																		
Interincisal angle	1	-2.70	7.08	0.15	42.80	0.88																																																																																																																				
	2	-3.07	10.19				U1-SN	1	4.25	6.04	-0.67	48	0.51	2	5.58	7.82	U1-NA	1	3.81	5.97	0.02	43.51	0.98	2	3.76	8.33	L1-MP	1	-1.40	5.28	0.28	48	0.78	2	-1.82	5.55	L1-NB	1	-1.41	4.88	0.13	48	0.90	2	-1.59	5.13																																																																												
U1-SN	1	4.25	6.04	-0.67	48	0.51																																																																																																																				
	2	5.58	7.82				U1-NA	1	3.81	5.97	0.02	43.51	0.98	2	3.76	8.33	L1-MP	1	-1.40	5.28	0.28	48	0.78	2	-1.82	5.55	L1-NB	1	-1.41	4.88	0.13	48	0.90	2	-1.59	5.13																																																																																						
U1-NA	1	3.81	5.97	0.02	43.51	0.98																																																																																																																				
	2	3.76	8.33				L1-MP	1	-1.40	5.28	0.28	48	0.78	2	-1.82	5.55	L1-NB	1	-1.41	4.88	0.13	48	0.90	2	-1.59	5.13																																																																																																
L1-MP	1	-1.40	5.28	0.28	48	0.78																																																																																																																				
	2	-1.82	5.55				L1-NB	1	-1.41	4.88	0.13	48	0.90	2	-1.59	5.13																																																																																																										
L1-NB	1	-1.41	4.88	0.13	48	0.90																																																																																																																				
	2	-1.59	5.13																																																																																																																							

\*Indicates  $p < 0.05$ .

**Table 2.**  
Comparison of T2-T1 angular differences between groups (N = 25).

Linear measurements (mm)	Group	Mean	Standard deviation	t	df	Significance (2-tailed)
Wits appraisal	1	1.28	4.38	-0.25	48	0.80
	2	1.56	3.41			
U1-NA	1	1.09	2.03	-0.45	48	0.66
	2	1.37	2.38			
L1-NB	1	-0.32	1.30	0.08	48	0.93
	2	-0.35	1.44			
Overbite	1	1.19	2.47	0.71	48	0.48
	2	0.78	1.49			
Overjet	1	1.88	2.80	-1.19	48	0.24
	2	2.73	2.19			
Distance from sella ⊥ to maxillary molar occlusal	1	2.32	3.26	-1.70	48	0.10
	2	3.90	3.32			
Distance from sella ⊥ to maxillary incisor	1	3.52	4.26	-0.39	48	0.70
	2	3.95	3.52			
Distance from sella ⊥ to mandibular molar occlusal	1	2.41	2.45	-1.89	48	0.06
	2	3.72	2.45			
Distance from sella ⊥ to mandibular incisor	1	1.19	2.64	-1.08	40.67	0.29
	2	1.87	1.68			

*p* < 0.05.

**Table 3.**  
 Comparison of T2-T1 linear differences between groups (N = 25).

maxilla. Both groups had a mean initial CVM of stage 2 which correlates to pre-pubertal growth peak. No significant differences in CVM stage existed at T1 and T2 between groups suggesting that both groups were similar with regards to skeletal maturation before and after treatment.

The significant difference in treatment times may have affected the outcomes between groups. The protraction facemask was used for a greater period of time on average than the removable Class III traction appliance and has a direct effect on the maxilla. Thus, with a greater treatment time one could expect more change at SNA, which may have contributed to the significantly increased SNA in the protraction facemask treated group when compared with the removable Class III traction appliance treated group. The outcomes of the protraction facemask treated group were consistent with studies conducted by Nartallo-Turley and Turley [8], Ngan et al. [7], and Macdonald et al. [6].

No significant differences were found between groups comparing Wits appraisal, ANB, FMA, Y-axis, cant of the occlusal plane, Sella to A point, PTM to ANS, and angle of convexity. This may suggest that both appliances produced similar results in the maxilla and rotation of the mandible. It was also found that both groups exhibited proclination of the upper incisors, mesial movement of the upper and lower dentition, uprighting of the lower incisors, increase in interincisal angle, increase in overjet and increase in overbite similar to the studies by Nartallo-Turley and Turley [8], Ngan et al. [7], and Macdonald et al. [6].

The strength of this study is that it evaluated the effects of using a removable Class III traction appliance. Since the results showed that no statistical differences existed for dental and all but one of the skeletal variables between groups, the removable Class III traction appliance could be used as another minimally



invasive Class III treatment modality for patients. Further studies of removable Class III traction appliances should implement a randomized patient assignment prospectively as well as obtain long-term results in order to evaluate their overall effectiveness.

Conventional protraction facemask therapy has been found in multiple studies to be effective; however, compliance is a major limitation. Patients often view the protraction facemask as awkward at best and complain about it being difficult to wear and interfering with sleep. Cole [13] evaluated patient compliance using headgear to treat Class II malocclusion; patients were fitted with a commercially available timing headgear that measured the amount of headgear wear. Compliance levels varied from 5.6% to 107.7% with a mean of 74.4%. It was found that most patients reported more headgear wear than what actually took place. Poor patient compliance with headgear or facemask can contribute to poor outcomes in treatment.

Since the removable orthodontic traction device is an intraoral appliance, it is possible for patients to adapt to wearing the appliance full time. Patients may not view this removable intraoral appliance with the same annoyance as they do the protraction facemask. If any minimally invasive treatment modalities can be used with predictability, it has great benefit as significant risk and cost is reduced in the care of the patient.

Based on the outcomes of this study comparing a removable Class III traction appliance and protraction facemask for the treatment of Class III malocclusion, it seems that both appliances are effective treatment modalities. Each appliance has its advantages and disadvantages and each treatment modality should be selected on a patient-by-patient basis.

### **3. Conclusion**

A removable intraoral Class III traction appliance provides orthodontists with a useful noninvasive treatment alternative to protraction facemask in young patients presenting with Class III malocclusions. Both treatments resolved the Class III dental relationships; only slight differences in outcomes were found between the protraction facemask and removable Class III traction appliance, namely, time in treatment and change in angle SNA were both slightly larger in the protraction facemask patients. It is common for orthodontists to treat using a protraction facemask, but if similar results can be achieved by using a removable Class III removable traction appliance, then it may be advantageous to consider this appliance as an option for some Class III patients.

### **Conflict of interest**

The authors declare no conflict of interest.

### **Abbreviations**

CO	centric occlusion
CR	centric relation
CVM	cervical vertebral maturation
mm	millimeter
T1	pre-treatment
T2	post-treatment

IntechOpen

## Author details

Kristin N. Moore<sup>1</sup>, David R. Musich<sup>2</sup>, Donald Taylor<sup>3</sup>, Budi Kusnoto<sup>4</sup>  
and Carla A. Evans<sup>5\*</sup>

1 Lake Zurich, IL, USA

2 Schaumburg, IL, USA

3 Montreal, QC, Canada

4 University of Illinois at Chicago, Chicago, IL, USA

5 Boston University, Boston, MA, USA

\*Address all correspondence to: [caevans@bu.edu](mailto:caevans@bu.edu)

## IntechOpen

© 2021 The Author(s). Licensee IntechOpen. This chapter is distributed under the terms of the Creative Commons Attribution License (<http://creativecommons.org/licenses/by/3.0>), which permits unrestricted use, distribution, and reproduction in any medium, provided the original work is properly cited. 

## References

- [1] Guyer EC, Ellis EE, McNamara JA, Behrents RG. Components of class III malocclusion in juveniles and adolescents. *Angle Orthod* 1986;56:7-30.
- [2] Delaire J. L'emploi physiologique des tractions extra-orales postero-antérieures sur masque orthopedique dans le traitement des classes III. *Orthod Fr* 1988;59:577-589.
- [3] McNamara JA. Treatment of patients in the mixed dentition. In: *Orthodontics: Current Principles and Techniques*, ed. TM Graber, RL Vanarsdall, KWL Vig, Elsevier Mosby, St. Louis, 2005, pp. 543-577.
- [4] Şar Ç, Arman-Özçipici A, Uçkan S, Yazici AC. Comparative evaluation of maxillary protraction with or without skeletal anchorage. *Am J Orthod Dentofacial Orthop* 2011;139:636-649.
- [5] Yepes E, Quintero P, Rueda ZV, Pedvoza A. Optimal force for maxillary protraction facemask therapy in the early treatment of class III malocclusion. *Eur J Orthod* 2014;36:586-594.
- [6] Macdonald KE, Kapust AJ, Turley PK. Cephalometric changes after the correction of class III malocclusion with maxillary/facemask therapy. *Am J Orthod Dentofacial Orthop* 1999;116:13-24.
- [7] Ngan, P., Yiu, C., Hu, A., Hägg, U., Wei, S.H., and Gunel, E. Cephalometric and occlusal changes following maxillary expansion and protraction. *Eur. J. Orthod.* 20:237-254, 1998.
- [8] Nartallo-Turley PE, Turley PK. Cephalometric effects of combined palatal expansion and facemask therapy on class III malocclusion. *Angle Orthod* 1998;68:217-224.
- [9] Vanlaecken R, Williams MO, Razmus T, Gunels E, Martin C, Ngan P. Class III correction using an inter-arch spring-loaded module. *Prog Orthod* 2014;15:32.
- [10] Musich DR, Busch MJ. Clinical management of the class III growing patient. *Int Orthod Kieferorthop* 2008;40:13-26.
- [11] White LW. *Orthodontic Pearls: A Clinician's Guide*. Self-Published, 2011, p. 115.
- [12] Baccetti T, Franchi L, McNamara JA. The cervical vertebral maturation (CVM) method for the assessment of optimal treatment timing in dentofacial orthopedics. *Semin Orthod* 2005;11:119-129.
- [13] Cole W. Accuracy of patient reporting as an indication of headgear compliance. *Am J Orthod Dentofacial Orthop* 2002;121:419-423.