

We are IntechOpen, the world's leading publisher of Open Access books Built by scientists, for scientists

5,500

Open access books available

135,000

International authors and editors

165M

Downloads

Our authors are among the

154

Countries delivered to

TOP 1%

most cited scientists

12.2%

Contributors from top 500 universities



WEB OF SCIENCE™

Selection of our books indexed in the Book Citation Index
in Web of Science™ Core Collection (BKCI)

Interested in publishing with us?
Contact book.department@intechopen.com

Numbers displayed above are based on latest data collected.
For more information visit www.intechopen.com



Complications of Minimally Invasive Left Ventricular Assistance Device Implantation

Mleyhi Sobhi, Miri Rim and Denguir Raouf

Abstract

Indication of Ventricular assistance is advanced cardiac failure with maximal medical and surgical treatment has been used. The ventricular assistance has two main purposes: first, to maintain circulation by discharging the ventricle (s) until recovery, or to ensure patient survival by replacing cardiac function permanently or transitionally for patients waiting for heart Transplantation. The encouraging results of the partial or total artificial heart and the miniaturization of these devices allow their use in permanent implantation for patients with heart failure that is not eligible for heart transplantation. In left mono-ventricular assistance, blood is taken from the apex of the left ventricle (LV) and reinjected in the ascending aorta. The classic surgical approach is a total median sternotomy. Other minimally invasive approaches for the implantation or explanation of left ventricular assist devices have been published and have shown encouraging results. These alternatives currently play an important role in certain indications and in patients with heavy medical history. Nevertheless, the complications of the ventricular assistance even by minimally invasive approaches might be serious and represent a turning point in the life of the patients. In this chapter, we describe the implantation technique of left ventricular assistance device (LVAD) and we discuss its advantages and disadvantages including possible complications.

Keywords: minimally invasive, surgery, LVAD, implantation, complications

1. Introduction

End-stage heart failure has an increasing incidence and prevalence worldwide. In Germany, 1 to 2% of the population suffers from chronic heart failure, with approximately 80,000 new cases per year. Cardiac transplantation has been the therapy of choice for patients with drug-resistant heart failure, but the decreasing number of donor organs leads to a significant prolongation of the waiting time for cardiac transplantation, resulting in an increased mortality of these patients [1, 2]. Indication of ventricular assistance device is for patients with advanced heart failure in whom maximum medical and surgical treatment has been exhausted. The purpose of ventricular assistance is twofold: first, to maintain circulation by discharging the ventricle (s) until recovery, and second, to ensure the survival of the patient by replacing the cardiac function, permanently or while waiting for a heart transplantation [3, 4].

The encouraging results of the partial or total artificial heart and the miniaturization of these devices make it possible to consider their use in permanent implantation for patients with heart failure who are not eligible for heart transplantation.

In left mono-ventricular assistance, the blood is taken through a cannula placed at the apex of the left ventricle (LV) and re-injected to the patient by a vascular prosthesis anastomosed to the ascending aorta. The classic surgical approach is a total midline sternotomy. Alternative minimally invasive approaches for implantation or explantation of left ventricular assist devices have been published and have shown encouraging results [5]. These alternatives currently play an important role in certain precise indications and in the most complex patients. Nevertheless, the complications after the implantation of mechanical assistance, even by a minimally invasive route, are still serious and can be lethal.

The impact of heart failure on individuals and society in general continues to grow. Heart transplantation remains the gold standard for treating patients with end-stage heart failure. The development of artificial hearts, partial and total, was mainly inspired by the disproportion between the number of available grafts and the number of candidates for heart transplantation. The significant technological advances made since Kolff's first work in 1957 allow these patients to return to their homes while awaiting the transplant. The encouraging results of the artificial heart and the miniaturization of these devices now make it possible to consider their use in permanent implantation for patients with heart failure who are not eligible for transplantation [6].

The objectives can be divided into two categories:

- Support and optimization of hemodynamic constants while waiting for the replacement of an irreversibly damaged heart (bridge-to-transplantation). This attitude improves pulmonary hypertension and prevents multiorgan failure [7].
- Definitive implantation of a mechanical heart because the patient has a 1-year mortality greater than 50% but is not a candidate for a heart transplantation (destination therapy); survival then depends on the technical reliability of the system and on intercurrent complications. It is currently 60–86% at 1 year, more than double that of maximum medical treatment [8–11].

Implanted early enough in the course of the disease, ventricular assistance helps restore renal and hepatic functions, reduce pulmonary hypertension, mobilize excess interstitial fluid and prevent the onset of a multiorgan failure. Criteria for LVAD implantation are the persistence of the following settings despite maximum medical treatment:

- Cardiac index $< 2.0 \text{ L/min/m}^2$
- Mean arterial pressure (MAP) $< 60 \text{ mmHg}$, systolic arterial pressure $< 80 \text{ mmHg}$.
- Central venous pressure CVP and/or mean arterial pressure $> 20 \text{ mmHg}$,
- systemic arterial resistance $> 2,000 \text{ dynes/s/cm}^5$.
- Left ventricular ejection fraction < 0.25
- Venous saturation of oxygen $< 55\%$

- diuresis <20 mL/hour.
- Persistent metabolic acidosis.

Assistance is contraindicated in active systemic infection, irreversible neurological impairment, and end-stage renal or hepatic failure. Severe peripheral vascular disease and haematological disorders are relative contraindications [12]. The aortic valve must be continent, otherwise the flow of assistance will flow back into the LV and dilate it. Severe pulmonary hypertension or right heart failure are a contraindication to left monoventricular assistance; in this case, biventricular assistance must be performed (20% of cases).

Of course, ventricular assistance is an expensive therapy. Long-term implanted pumps (destination therapy) represent an expense of around € 220,000 [13]. Ventricular assist systems can be classified in three generations [3, 14]:

- 1st generation: extracorporeal pulsatile devices, often pneumatic, driven by an external console (Thoratec PVAD™, Abiomed BVS 5000™); they are bulky and contain many moving parts, including valves.
- 2nd generation: implantable pulsatile systems, most often electric (HeartMate XVE™, LionHeart™, Thoratec IVAD™).
- 3rd generation: implantable axial flow systems, designed for long periods (HeartMate II™, Jarvik 2000™, BerlinHeart™); the only moving part is the rotor, valves are unnecessary; the latest models operate by magnetic levitation which eliminates the axes of the rotor, sources of wear.

HEARTMATE LVAD device is a mechanical, continuous flow, electrical, intracorporeal, monoventricular left circulatory device. This system is indicated when the patient's body surface area is ≥ 1.2 m² in the following situations:

- Indication in an acute situation: acute mono or biventricular failure in patients with heart failure, not controlled by optimal treatment, in the absence of a conventional therapeutic alternative (drug and / or intervention and/or surgery).
- Elective indication: advanced chronic heart failure with mono or biventricular failure, when life is threatened despite optimal treatment, and at the end of a multidisciplinary consultation.

The contraindications to HEARTMATE mechanical device are:

- severe pulmonary dysfunction and fixed pulmonary arterial hypertension.
- Severe hepatic insufficiency (cirrhosis, portal hypertension, ...).
- Major disorders of blood crass and uncontrolled bleeding.
- Uncontrolled systemic septic and inflammatory syndrome.
- Documented irreversible central nervous system damage, recent stroke and cachexia.

- Systemic diseases with involvement of several organs.
- Psychiatric disorders jeopardizing adherence to treatment and lack of cooperation.
- A condition with a bad prognosis when life expectancy is less than 2 years.
- An untreated septal rupture.
- A body surface area $< 1.2 \text{ m}^2$.

“HeartMate” is one of the continuous flow systems which are driven by an axial turbine (HeartMate™ II, BerlinHeart™, Jarvik 2000™, DeBakey MicroMed™) or a centrifugal pump (HeartMate™ III). They are implanted by sternotomy or thoracotomy. The blood is taken from the apex of the LV and returned to the ascending or descending aorta through a tubular prosthesis. The assured flow rate is 3 to 10 L/min. These simpler and quieter continuous flow systems are less prone to embolism and infections than pulsatile systems [14, 15]. In addition, they let the heart continue to eject which promotes its recovery.

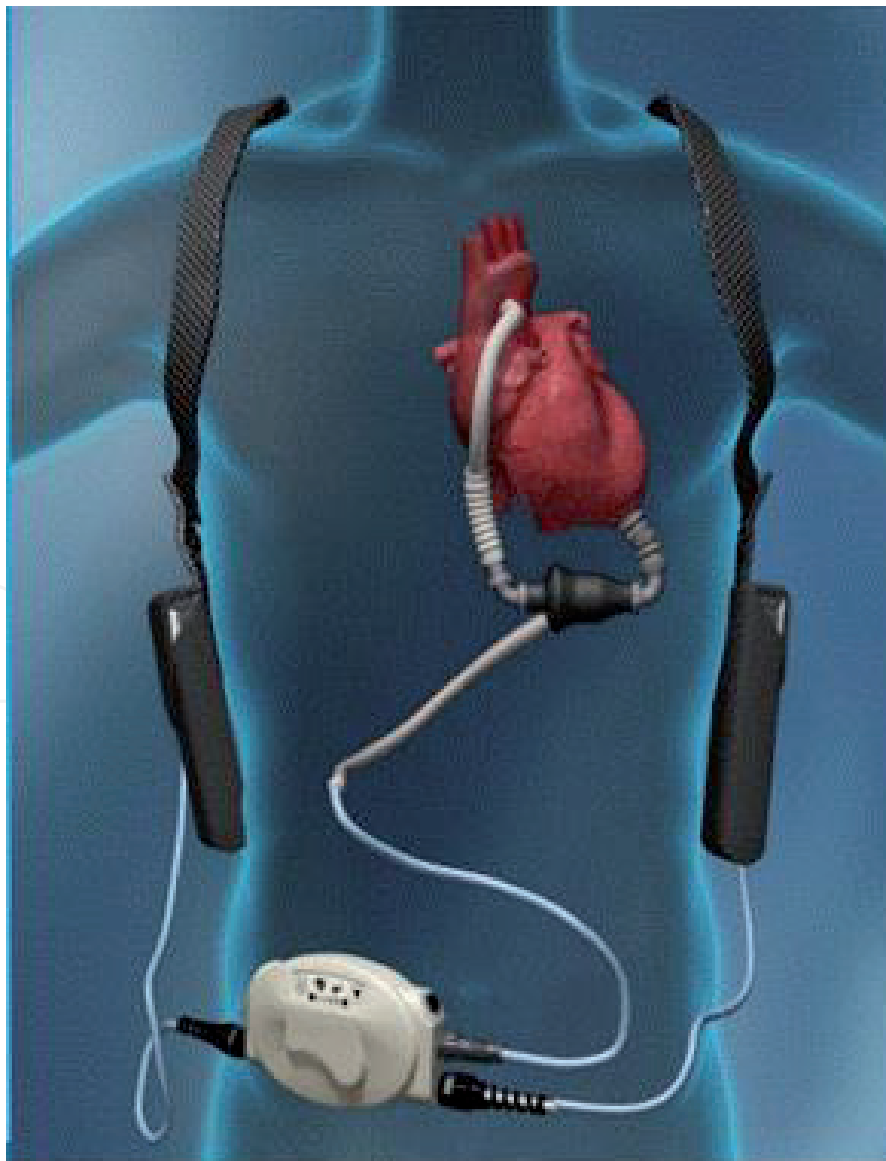

Figure 1.
LVAD device.

Their size is small, and they can be implanted in short patients. The arterial curve is practically flat, the systolic and diastolic blood pressure are the same as the Mean arterial pressure. The functionality of the LV results in hooks added to this curve; these are all the more important as the LV performs better or the pump output decreases.

The smaller design of the pump and its intrapericardial location has allowed the development of less invasive alternatives and implantation techniques. The technique of left ventricular assistance by minimally invasive approach has been described in several publications [5, 16–19]. It consists of an upper J-shaped mini-sternotomy or an anterior thoracotomy in the 2nd right intercostal space for access to the ascending aorta (site of anastomosis of the ejection voice) as well as to the right atrium (if atriocaval cannulation) and a left subcostal approach or a left anterolateral thoracotomy of 8 to 10 Cm for access to the apex of the heart and implantation of the device (**Figure 1** and **2**).

According to Anson et al. [18], the use of small incisions allows exposure of the exact areas required for cannulation without the need for cardiac manipulation which is often poorly tolerated in these severe patients, and therefore implantation without cardiopulmonary bypass (CPB) becomes possible. In the study of Bantayehu Sileshi et al. [17] including 51 HeartWare implantations for patients waiting for heart transplantation, eighteen of them were with minimally invasive approach without CPB. The choice of the surgical technique was made by a multidisciplinary committee, taking into consideration the contraindications, in particular the respiratory one, for thoracotomy. Univariate analysis revealed a statistically significant reduction in the duration of treatment with inotropic drugs ($p = 0.04$), and reduced intraoperative

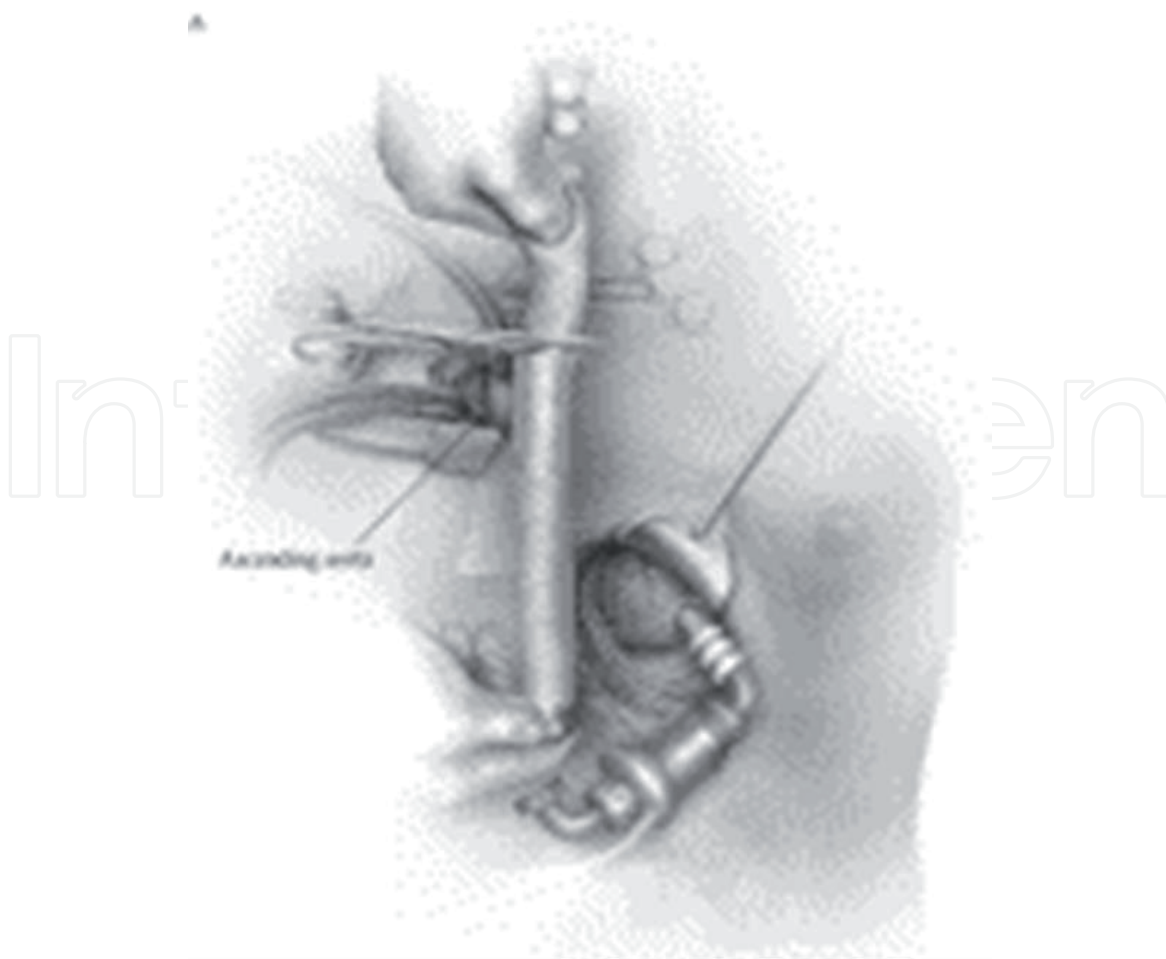


Figure 2.
Minimally invasive LVAD implantation approach.

blood transfusion ($p = 0.08$) in minimally invasive implantations. Conversely, there was no difference regarding the duration of intensive care stay ($p = 0.5$), the total intra-hospital stay ($p = 0.76$) and the total time of mechanical ventilation ($p = 0.32$). There were four in-hospital deaths and three stroke complications all were operated on by sternotomy under CPB. Authors showed also an increasing risk of infection, bleeding and redo-sternotomy complications at the time of heart transplantation [20].

Less invasive surgical approaches have been developed with the hope of reducing CPB time and operative trauma, minimizing perioperative blood loss, protecting cardiac structures from multiple re-entries, and preserving the heart geometry [21].

Haberl and al. recently described their clinical experience in minimally invasive implantation for HeartWare and HeartMate II [22]. Of the 27 patients in their study, 5 (19%) were performed without CPB. They had a reported in-hospital mortality of 14.8%, and an average hospital stay of 30 days. They concluded that minimally invasive LVAD implantation is feasible and safe. Moreover, Anelechi C [5] thinks that this technique is inadequate for patients who have previously had cardiac surgery without giving any arguments.

Minimally invasive approach was also recommended for the device remove or changing [23–27]. For example, the team of Igor D. Gregoric [23] showed the superiority of the subcostal route alone to change HeartMate XVE by HeartMate II compared to sternotomy with left subcostal approach in terms of transfusion, operative duration and postoperative stay. The same results were found in the study of John m. Stulak and his colleagues [26].

2. Complications

The complications related to the different assistance systems are numerous [11, 28, 29]:

- Infections in 32 to 45% of cases.
- Bleeding in 27% of cases.
- Arrhythmias in 24% of cases.
- Thromboembolism and stroke (10–39% depending on the device type)
- Renal failure in 20% of cases.
- Systemic inflammation and lack of cellular immunity.
- Hemolysis: depending on the pump models.

infectious complications are the most serious with 41% of deaths linked to sepsis [30]. Continuous-flow turbine systems have a clearly lower complication rate (infections, thromboses, mechanical problems) than pulsatile systems [31].

There are basically three disadvantages of continuous flow systems:

- malfunction causes the equivalent of acute aortic insufficiency because there is no valve in the system.
- As they generate negative pressure in the LV, the ventricle can collapse with a sudden drop in preload and a risk of air embolism by aspiration of air at the sutures;

- The continuous flow causes stasis in the aortic valve if it no longer opens; this can give rise to thrombi, with the risk of systemic embolization.

Thrombosis of the ventricular assist device (VAD) is associated with significant morbidity and mortality, usually requiring device replacement. Since 2011, there has been a sharp increase in the incidence of VAD thrombosis, from 2.2% before 2011 to 8.4% in 2013 [32]. The exact reason for this increase is unknown and numerous studies aim to identify it [33]. Diagnostic markers, including increased plasma lactate dehydrogenase (LDH), free plasma hemoglobin, or abnormal responses to programmed increases in pump speed (ramp test) [34] should allow early and more accurate diagnosis. [35].

The formation of thrombi in the aortic root in patients implanted with HeartMate II has been previously reported in the literature [36, 37]. The flow in the root of the aorta in patients with continuous flow LVAD has been shown experimentally to be relatively stagnant, especially when the aortic valve does not open [38] and such stasis often involves the non-coronary sinus and can be an important risk factor for thrombosis. Sachin Shah and colleagues [39] report a case of occlusion of the left common coronary trunk by aortic root thrombus in a patient with HeartMate II.

The optimal strategy for the prevention of this complication is not yet well defined; however, special attention to anticoagulation and antiplatelet therapy in the postoperative period, as well as adjusting the pump speed to allow intermittent opening of the aortic valve may be important considerations. For those who develop an aortic root thrombus, but remain asymptomatic, intensification of anticoagulation and antiplatelet therapy alone may sometimes be sufficient [39].

3. Conclusion

In conclusion, with the limited number of organ donors, long-term ventricular support systems are slowly becoming an alternative to heart transplantation. Significant technical advances have allowed the development of small, space-saving ventricular assist devices with fewer complications.


Minimally invasive alternative approaches for implantation or explantation of left ventricular assist devices have become valid and reproducible. Nevertheless, complications, in particular thromboembolic still serious. Only multidisciplinary work associating surgeon, cardiologist and anesthetist with perfect knowledge of the management of these patients and these machines can prevent complications and death.

Author details

Mleyhi Sobhi*, Miri Rim and Denguir Raouf
Cardiovascular Surgery Department, Faculty of Medicine of Tunis, La Rabta
Hospital, University of Tunis el Manar, Tunisia

*Address all correspondence to: mleyhisobhi@yahoo.com

IntechOpen

© 2021 The Author(s). Licensee IntechOpen. This chapter is distributed under the terms of the Creative Commons Attribution License (<http://creativecommons.org/licenses/by/3.0>), which permits unrestricted use, distribution, and reproduction in any medium, provided the original work is properly cited. 

References

- [1] Haeck ML, Beeres SL, Höke U, Palmén M, Couperus LE, Delgado V, Logeman EA, Maas JJ, Klautz RJ, Schalijs MJ, Verwey HF. Left ventricular assist device for end-stage heart failure: results of the first LVAD destination program in the Netherlands. *Neth Heart J*. 2015 Feb;23(2):102-108. doi: 10.1007/s12471-014-0602-4.
- [2] Christiansen S, Klocke A, Autschbach R. Past, present, and future of long-term mechanical cardiac support in adults. *J Card Surg*. 2008 Nov-Dec;23(6):664-676. doi: 10.1111/j.1540-8191.2008.00696.x.
- [3] TERRACCIANO CM, MILLER LW, YACOB MH. Contemporary use of ventricular assist devices. *Annu Rev Med* 2010; 61:255-270.
- [4] VEGAS A. Assisting the failing heart. *Anesthesiology Clin* 2008; 26:539-564.
- [5] Anelechi C Anyanwu. Nonsternotomy Approaches to Left Ventricular Assist Device placement: Combined Left Subcostal–Right Minithoracotomy Technique. *Operative Techniques in Thoracic and Cardiovascular Surgery*. Nov 2014; vol 19(3): 254-275.
- [6] E. Flecher, T. Joudinaud, J.-M. Grinda. Histoire de l'assistance circulatoire mécanique et du cœur artificiel. *Annales de chirurgie* oct 2006; Vol 131(8): 473-478.
- [7] CHRISTIANSEN S, KLOCKE A, AUTSCHBACH R. Past, present, and future of long term mechanical cardiac support in adults. *J Card Surg* 2008; 23:664-676.
- [8] BADIWALA MV, RAO V. Left ventricular device as destination therapy: are we there yet? *Curr Opin Cardiol* 2009; 24:184-189.
- [9] BIRKS EJ, GEORGE RS, HEDGER M, et al. Reversal of heart failure with a continuous-flow left ventricular assistance device and pharmacological therapy. *Circulation* 2011; 123:381-390.
- [10] LONG JW, KFOURY AG, SLAUGHTER MS, et al. Long term destination therapy with the HeartMate XVE left ventricular assist device: improved outcomes since the REMATCH study. *Congest Heart Fail* 2005; 11:133-138.
- [11] ROSE EA, GELIJNS AC, MOSKOWITZ AJ, et al. REMATCH study group. Long-term mechanical left ventricular assistance for end-stage heart failure. *N Engl J Med* 2001; 345:1435-1443.
- [12] EL-MAGHARBEL I. Ventricular assist devices and anesthesia. *Semin Cardiothor Vasc Anesth* 2005; 9:241-249.
- [13] MOHACSI P, STALDER M, MARTINELLI M, et al. Transplantation cardiaque et assistance circulatoire mécanique. Situation actuelle et perspectives. 2ème partie. *Forum Med Suisse* 2011; 11:98-102.
- [14] THUNBERG CA, GAITAN BD, ARABIA FA, et al. Ventricular assist devices today and tomorrow. *J Cardiothorac Vasc Anesth* 2010; 24:656-680.
- [15] FRAZIER OH, GEMMATO C, MYERS TJ, et al. Initial clinical experience with the HeartMate II axial-flow left ventricular assist device. *Tex Heart Inst J* 2007; 34:275-281.
- [16] Chad EW, Julien SB, Jason K, et al. Minimally invasive thoracic left ventricular assist device implantation: Case series demonstrating an integrate multidisciplinary strategy. *Journal of*

cardiothoracic and vascular anesthesia, avril 2015 vol 29(2):271-274.

[17] Bantayehu S, Nicholas AH, Mary ED et al. In-hospital outcomes of minimally invasive off-pump left thoracotomy approach using a centrifugal continuous-flow left ventricular assist device. *J Heart Lung Transplant* 2015;34:107-112.

[18] Anson C, Yoan L, Annemarie K, et al. Off-pump implantation of the HeartWare HVAD left ventricular assist device through minimally invasive incisions. *Ann Thorac Surg* 2011; 91:1294-1296.

[19] Schmitto JD, Molitoris U, Haverich A, et al. Implantation of a centrifugal pump as a left ventricular assist device through a novel, minimized approach: upper hemisternotomy combined with antero-lateral thoracotomy. *J Thorac Cardiovasc Surg* 2012;143:511-513.

[20] Unsworth B, Casula RP, Kyriacou AA, et al. The right ventricular annular velocity reduction caused by coronary artery bypass graft surgery occurs at the moment of pericardial incision. *Am Heart J* 2010;159:314-322.

[21] Schmitto JD, Mokashi SA, Cohn LH. Minimally-invasive valve surgery. *J Am Coll Cardiol* 2010;56:455-462.

[22] Haberl T, Riebandt J, Mahr S, Laufer G, Rajek A, Schima H, Zimpfer D. Viennese approach to minimize the invasiveness of ventricular assist device implantation†. *Eur J Cardiothorac Surg*. 2014 Dec;46(6):991-996; discussion 996. doi: 10.1093/ejcts/ezu051.

[23] Igor D, Brian A, Leon J, et al. Clinical Experience With Sternotomy Versus Subcostal Approach for Exchange of the HeartMate XVE to the HeartMate II Ventricular Assist Device. *Ann Thorac Surg* 2008;85:1646-1650.

[24] Sajjad M, Butt T, Oezalp F, et al. An alternative approach to explantation and exchange of the HeartWare left ventricular assist device *European Journal of Cardio-Thoracic Surgery* 43 (2013) :1247-1250.

[25] Diana GS, Prashant NM, Bartlomiej Z, et al. Minimally invasive access for off-pump HeartWare left ventricular assist device explantation. *Interactive cardiovascular and thoracic surgery* 17 (2013):581-582.

[26] John MS, Jennifer C, Jonathon WH, et al. Device exchange after primary left ventricular assist device implantation: indications and outcomes. *Ann Thorac Surg* 2013;95:1262-1268.

[27] Rojas SV, Avsar M, Khalpey Z, et al. Minimally invasive pff_pump left ventricular assist device exchange: anterolateral thoracotomy. *Artif Organs* 2014;38(7):539-542.

[28] DENG MC, EDWARDS LB, HERTZ MI, et al. Mechanical circulatory support data base of the international society for heart and lung transplantation: second annual report 2004. *J Heart Lung Transplant* 2004; 23:1027-1034.

[29] STONE ME. Current status of mechanical circulatory assistance. *Semin Cardiothor Vasc Anesth* 2007; 11:185-204.

[30] CHRISTIANSEN S, KLOCKE A, AUTSCHBACH R. Past, present, and future of long term mechanical cardiac support in adults. *J Card Surg* 2008; 23:664-676.

[31] MITTER N, SHEINBERG R. Update on ventricular assist devices. *Curr Opin Anaesthesiol* 2009; 23:57-66.

[32] Starling RC, Moazami N, Silvestry SC, et al. Unexpected abrupt increase in left ventricular assist device

thrombosis. *N Engl J Med*, 2014; 370:33-40.

[33] Edo Y. Birati MD, J. Eduardo Rame MD. Diagnosis and Management of LVAD Thrombosis. *Curr Treat Options Cardio Med*, February 2015, 17:2.

[34] Uriel N, Morrison KA, Garan AR, et al. Development of a novel echocardiography ramp test for speed optimization and diagnosis of device thrombosis in continuous-flow left ventricular assist devices: the Columbia Ramp Study. *J Am Coll Cardiol*, 2012; 60:1764-1765.

[35] Uriel N, Han J, Morrison KA, et al. Device thrombosis in HeartMate II continuous-flow left ventricular assist devices: a multifactorial phenomenon. *J Heart Lung Transplant*, 2014;33: 51-59.

[36] Freed BH, Jeevanandam V, Jolly N. Aortic root and valve thrombosis after implantation of a left ventricular assist device. *J Invasive Cardiol*, 2011; 23:63-65.

[37] Demirozu Z, Frazier O. Aortic valve noncoronary cusp thrombosis after implantation of a nonpulsatile, continuous-flow pump. *Tex Heart Inst J*, 2012, 39 (5):618-620.

[38] Kar B, Delgado R, Frazier O, et al. The effect of LVAD aortic outflow-graft placement on hemodynamics and flow. Implantation technique and computer flow modeling. *Tex Heart Inst J*, 2005;32: 294-298.

[39] Sachin S, Mehra M, Couper G, Desa A. Continuous flow left ventricular assist device related aortic root thrombosis complicated by left main coronary artery occlusion. *The Journal of Heart and Lung Transplantation*, 2014; 33 (1):119-120.