

# We are IntechOpen, the world's leading publisher of Open Access books Built by scientists, for scientists

5,500

Open access books available

136,000

International authors and editors

170M

Downloads

Our authors are among the

154

Countries delivered to

TOP 1%

most cited scientists

12.2%

Contributors from top 500 universities



WEB OF SCIENCE™

Selection of our books indexed in the Book Citation Index  
in Web of Science™ Core Collection (BKCI)

Interested in publishing with us?  
Contact [book.department@intechopen.com](mailto:book.department@intechopen.com)

Numbers displayed above are based on latest data collected.  
For more information visit [www.intechopen.com](http://www.intechopen.com)



# Vascular Aphasia

*Dragoș Cătălin Jianu, Silvana Nina Jianu, Ligia Petrica,  
Traian Flavius Dan and Georgiana Munteanu*

## Abstract

Aphasia represents an acquired central disorder of language that impairs a person's ability to understand and/or produce spoken and written language, caused by lesions situated usually in the dominant (left) cerebral hemisphere, in right-handed persons. Aphasia has a prevalence of 25–30% in acute ischemic stroke (vascular aphasia). It is considered as an important stroke severity marker, being associated with a higher risk of mortality, poor functional prognosis, and augmented risk of vascular dementia. The assessment of aphasias in clinical practice is based on classical analysis of oral production and comprehension. The language disturbances are frequently combined into aphasic syndromes which are components of different vascular syndromes that may evolve/involve rapidly at the acute stage of ischemic stroke. The main determinant of the type of vascular aphasia is the infarct location (especially left middle cerebral artery territory). Recent studies at the hyperacute stage of ischemic stroke have observed features of aphasia, have reanalyzed its neuroanatomy using new imaging techniques, and have shown that aphasias have a parallel course to that of cortico-subcortical hypoperfusion. Thus, the reversal of hypoperfusion, following recanalization (spontaneous or secondary to thrombolysis or thrombectomy), is associated with resolution of aphasia. Speech therapy is needed as soon as permitted by clinical condition.

**Keywords:** language, speech, aphasia, vascular aphasia, hyperacute stage of ischemic stroke, language therapy

## 1. Introduction

Aphasia is one of the most common and also frustrating disabilities secondary to stroke; over 25% of the patients who suffer an acute ischemic stroke are dealing with this complex syndrome in their evolution. It is also considered an important stroke severity marker, being associated with a higher risk of mortality, poor functional prognosis, and augmented risk of vascular dementia. This syndrome is a real challenge not only for the patients or their relatives but also for the specialists (neurologists, speech therapists, psychologists, and physiotherapists) involved in the diagnosis and treatment of those patients.

The assessment of aphasias in clinical practice is based on classical analysis of oral production and comprehension. The language disturbances are frequently combined into aphasic syndromes (nonfluent/fluent aphasias), which are constituents of different vascular syndromes, being accompanied by motor deficit of

the right limbs or visual deficit (hemianopia). The main determinant of the type of vascular aphasia is the infarct location (especially left middle cerebral artery territory). Recent studies at the hyperacute stage of ischemic stroke have observed features of aphasia, have reanalyzed its neuroanatomy using new imaging techniques, and have shown that aphasias have a parallel course to that of cortico-subcortical hypoperfusion. Thus, the reversal of hypoperfusion, following recanalization (spontaneous or secondary to thrombolysis or thrombectomy), is associated with resolution of aphasia. Speech therapy is needed as soon as permitted by clinical condition. Unfortunately, pharmacotherapy remains to be evaluated. Other studies examined the potential interest of new treatment, such as transcranial magnetic stimulation.

This chapter is meant to clarify different aspects regarding the definition, classification, diagnosis criteria, and therapeutically strategies for the most common vascular aphasic syndromes due to ischemic stroke.

## 2. Language and speech

In the field of neurolinguistics, there are two words, often misused as synonyms: “language” and “speech,” although each one of these terms describes different functions regarding distinct processes and involving distinct neural networks [1].

*Language* is a noninstinctive, culturally driven system of voluntarily produced symbols, involving receptive and expressive skills enabling understanding and expression of information or emotion. It represents a complex interaction between sensory-motor abilities and symbolic combinations, so that people can communicate [1].

The language system consists of five domains [1]:

1. *Phonology*: The systematic organization of different sounds in spoken languages and linguistic rules of their pronunciation and perception. It is different from phonetics. While phonology reveals the modality sounds come together within a certain language to encode meaning (to form words), phonetics describes the physical production, acoustic transmission, and perception of the sounds of speech.
2. *Morphology*: The study of the internal structure of words, how they are formed, and their relationship to other words in the same language. Morphemes represent the minimal units of words that have meaning and, in the same time, cannot be subdivided further (free morphemes can appear alone: example: “good,” but bound morphemes: example: “ly” must be added to a free morpheme to produce a word).
3. *Semantics*: The systematic meaning of words represents the study of relations between words and what they denote; it means the signification of words reflecting content and utterance intent.
4. *Syntax*: The set of linguistic principles that define the way in which words order (“arrange together”) to convey a complete thought, and to form correct sentences or phrases in a given language: example: the sequence in which the subject (S), verb (V), and object (O) combine in sentences: usually in the sequence SVO or SOV.

5. *Pragmatics*: The rules for maintaining a conversation in terms of responsiveness and relevance. It defines the way people produce and comprehend intended meanings through language, in actual situations. Unlike semantics, which defines meaning that is conventional (grammar and lexicon) in a given language, pragmatics explains how the speaker and listener are capable to overcome apparent ambiguity in a peculiar context.

Speech results from the extremely coordinated rapid motor functions, thereby requiring the combination of phonation (voicing), resonance (nasality), articulation, fluency, and prosody. It is responsible for the actual act of vocal expression of language. The most important neural structures involved in the regulation of speech are represented by the cortical systems, the basal ganglia, the cerebellum, and the corticobulbar tracts, via the nuclei of the trigeminal, facial, glossopharyngeal, vagal, accessory (spinal), hypoglossal, and phrenic nerves. All these structures maintain the control and coordination between all the muscles involved in speaking: oral, lingual, palatal, pharyngeal, laryngeal, and respiratory muscles [1].

### 3. Definition of aphasia

Aphasia represents an acquired central disorder of language that impairs a person's ability to understand or/and produce spoken language, often associated with impairment in reading (alexia) and writing (agraphia). Aphasia may supplementary affect the person's ability to use musical notation, mathematical operations, etc.; in consequence, the aphasic may present difficulties to generate and use symbol systems. Aphasia is different from a peripheral (sensory-motor) disorder of language that may mimic aphasia (such as weakness of the muscles of articulation). In the same time, it is an acquired phenomenon that appears after the language has already been learned [1–4].

### 4. Language localization

Nowadays, in the era of functional neuroimaging, using a variety of complex techniques, organization of the language network has been partially understood. The outward production of language is the effect of neural activation in huge network including different regions in the cortex, basal ganglia, cerebellum, and brainstem. An overlap in that network or with other networks of specialization determines the huge clinical spectrum following an acquired injury. One lesion in an area can produce numerous signs, and injuries concerning distinct areas can result in similar deficits [1].

Functional neuroimaging studies mentioned that the “language network” is strikingly similar across different language tasks and across different healthy people: *the dorsal frontoparietal pathway*—for articulatory and syntactic processes and *the ventral temporal pathway*—for mapping sounds to lexical representations and meanings of words [1].

Aphasia is caused by a localized brain damage. Using a combination of different neuroimaging techniques, it has been suggested that *core language functions are perisylvian left—lateralized regions* in the majority of patients (95% right-handers and 75% left-handers, respectively) [1]. These regions include (a) *anterior areas* and (b) *posterior areas* [1–5]:

Anterior areas	Posterior areas
<ul style="list-style-type: none"> <li>• The Broca's area: the posterior part of the third frontal gyrus-F3 (Brodmann areas: BA 44 and 45)</li> <li>• The Rolandic operculum (lower part of the motor area: Fa)</li> <li>• The insular cortex and the subjacent white matter</li> <li>• The left premotor and prefrontal regions (situated anterior and superior of Broca's area)</li> <li>• The supplementary motor area</li> </ul>	<ul style="list-style-type: none"> <li>• The Wernicke's area: the posterior part of the first two temporal gyri-T1/T2 (BA 22)</li> <li>• The inferior parietal lobes: the angular gyrus (BA 39), and the supramarginal gyrus (BA 40)</li> <li>• The anterior part of the temporal lobe</li> </ul>

Recent studies [2], using MRI, noted the following correlations between different linguistic disturbances and cerebral lesions due to ischemic strokes:

<ul style="list-style-type: none"> <li>• Reduction in fluency of spontaneous speech</li> <li>• Impaired repetition</li> <li>• Oral comprehension</li> <li>• Anomia (naming deficits)</li> </ul>	<ul style="list-style-type: none"> <li>• Inferior frontal gyrus</li> <li>• Putamen</li> <li>• Anterior subcortical lesions</li> <li>• Insular and external and posterior internal lesions</li> <li>• The posterior part of the superior and middle temporal gyri</li> <li>• The external capsule</li> <li>• The insula and the inferior frontal gyrus</li> <li>• Insula and external capsule</li> <li>• Posterior subcortical</li> <li>• Head of caudate nucleus</li> <li>• Medial temporal, middle and inferior frontal gyri, and genu of internal capsule</li> </ul>
---	--

## 5. The evaluation of language disturbances

The assessment of aphasias in clinical practice is based on the analysis of six different language domains, which are represented by oral production (expressive language), comprehension (language understanding), repetition, naming, reading, and writing (**Figure 1**) [1–6].

### 5.1 Assessment of oral production (expressive language/spontaneous speech)

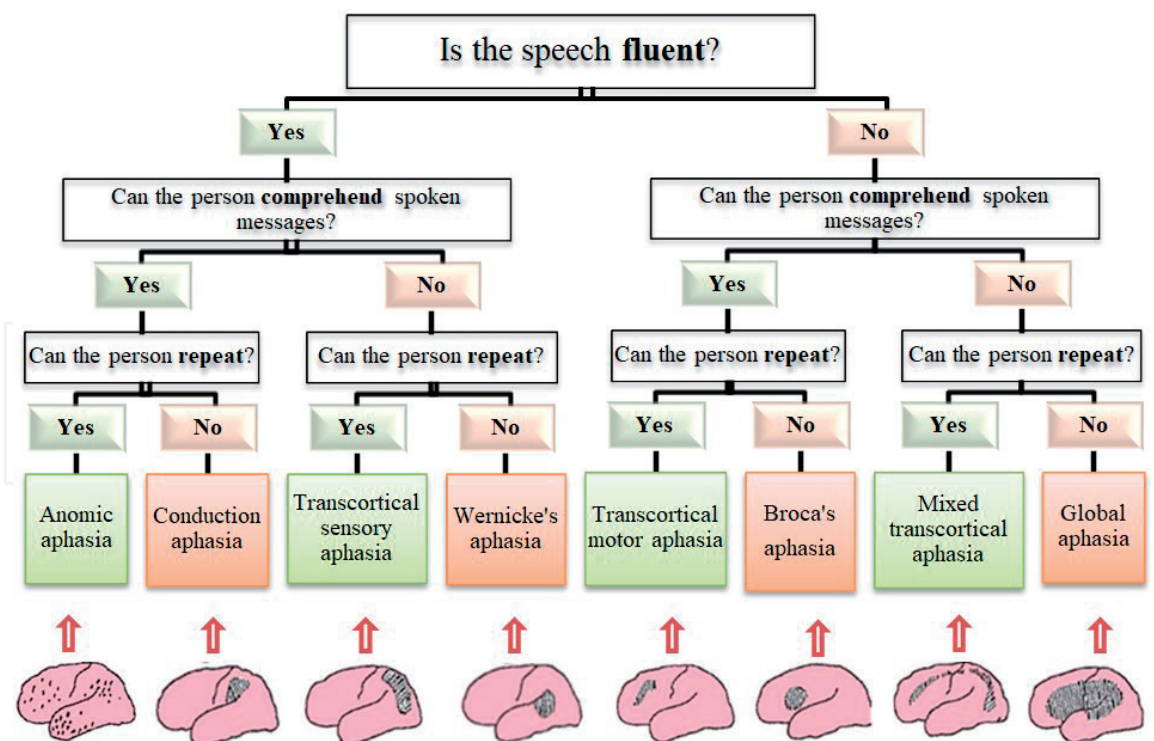
It refers to modifications of fluency, prosody and volume, and presence of deviations at various linguistic levels [1–7].

Fluency is represented by the flow of speech (number of words per minute: wpm) and effort (smoothness).

The main deviations at different linguistic levels of oral production are as follows:

- a. *Sound/articulation level* (incorrect articulation of a sound): dysarthria
- b. *Phonemic level* (addition, omission, substitution, or inversion of a phoneme): phonological paraphasias
- c. *Verbal level* (word-selection/lexicon): word-finding difficulties (anomia), are the core symptom of aphasias, usually associated with verbal (semantic) paraphasias, perseveration, circumlocutions, or, even, neologisms





**Figure 1.**  
 The assessment of aphasia in clinical practice is based on the classical analysis of oral production (fluency), comprehension, and repetition.

d. *Syntactic level* (grammar): agrammatism characterized by a severe diminution in the use of grammatical elements in language (in Broca's aphasia), and paragrammatism with an overuse of wrongly selected grammatical elements (in Wernicke's aphasia)

Other deviations are represented by oral production restricted to a few stereotyped utterances (e.g., "tan tan"), jargon aphasia (associating frequently multiple phonemic and verbal deviations leading to neologisms), echolalia, and the "conduit d'approche" (i.e., numerous attempts to correct phonemic deformations by successive approximations).

There are two types of aphasia: nonfluent (Broca's aphasia, transcortical motor aphasia, and global aphasia) and fluent (Wernicke's aphasia, transcortical sensory aphasia, and conduction aphasia). On the one hand, a nonfluent spontaneous speech presents less than 50 wpm, augmented effort, dysprosodia, sometimes hypophonia, dysarthria, few paraphasias (especially phonological paraphasias), substantive words in excess, and short sentences. On the other hand, a fluent speech presents a normal of words per minute (100–200 wpm), with a normal effort, normal prosody and volume, no deviation at sound level (correct articulation of a sound), many paraphasias (including verbal paraphasias), relatively lack of substantive words, and normal sentences (including 5–8 wps) [1–7].

## 5.2 Assessment of oral comprehension

It analyses comprehension at the linguistic levels of word and syntax [1–7]. Oral comprehension is formally examined by (a) asking the aphasic to point an object, a body part, etc. and (b) presenting different verbal commands with augmenting complexity. Impaired oral comprehension is usually underdiagnosed in clinical practice. We should think at this language disturbance when a patient does not behave according to the examiner's tasks, especially during object pointing on verbal command and

tasks using sentences of progressive complexity. The shortened Token Test is the test usually used to exam if the comprehension is impaired (adjusted score <29) and to differentiate Broca from global aphasia (adjusted score <17) [2, 6].

### **5.3 Assessment of repetition**

When testing repetition, it is essential to use different types of items (short-long verbal information and meaningful-meaningless utterances) [1–7].

Aphasias with impaired repetition ability (perisylvian aphasias) differ from this point of view from transcortical (extrasyllvian) aphasias, with normal repetition (even if oral comprehension is severely impaired in transcortical sensory aphasia).

### **5.4 Naming**

While testing naming, different types should be included: objects, body parts, actions, and colors (“What is this?”) [5–7]. If we want to assess the understanding ability of the patient, we have to exam pointing (“Show me, please, where the...is!”), which is the opposite of naming [5, 6].

### **5.5 Reading (lexia)**

While testing reading, we should focus on two aspects: (a) the mechanisms of reading (the conversion of visual signs-graphemes into phonemes) and (b) reading comprehension (using written commands, etc.) [5–7].

### **5.6 Writing (graphia)**

We should exam spontaneous writing, writing by dictation, and copying at different levels of the writing language: letters, syllables, words, sentences, and texts [5–7].

The different language disturbances observed are frequently combined into aphasic syndromes (nonfluent/fluent aphasias) [1, 2, 5, 7].

An experimented examiner can diagnose the aphasic syndrome based on analysis of six language domains (oral production, etc.).

However, clinical examination can produce two kinds of errors: (a) underestimation of oral comprehension deficit and (b) misdiagnose of verbal stereotypies with jargon aphasia.

These errors are not found in the case of assessment of aphasias using an aphasia battery test:

- Boston Diagnostic Aphasia Examination (BDAE) [8]
- Western Aphasia Battery (WAB) [9]
- Montreal-Toulouse Language Assessment Battery [10]
- Minnesota Test for Differential Diagnosis of Aphasia [6]
- Multilingual Aphasia Examination [6]
- Bilingual Aphasia Test [6]

Each test provides well-defined cut-off scores, so the description of the aphasic syndrome is more precise than that obtained on clinical grounds [2].

Bilingual Aphasia Test (BAT) [6] was realized to exam each of the languages of a bilingual or polyglot aphasic in an equivalent way. The test is available in dozens of different pairs of languages. Thus, the various versions of the BAT are linguistically equivalent tests [6].

## 6. Types of aphasic syndromes

The main determinants of the type of aphasia are *the site and size of the lesion* [2]. In the same time, *age* (with a higher frequency of nonfluent aphasias in young patients) and *sex* (with a higher frequency of nonfluent aphasias in men) are two other determinants. This aspect has been observed only in aphasics with ischemic stroke, but not in those with hemorrhagic stroke or tumors [2, 11].

Types of aphasic syndromes (nonfluent/fluent aphasias) [1, 2, 8] are:

1. Broca's aphasia
2. Wernicke's aphasia
3. Conduction aphasia
4. Transcortical aphasias:
  - a. Transcortical motor aphasia
  - b. Transcortical sensory aphasia
  - c. Mixed transcortical aphasia
5. Global aphasias
6. Anomic plus aphasias

The global aphasia (24–38%) and anomic plus aphasia (20%) are more frequent in acute ischemic stroke; Broca (10–15%), Wernicke (15%), and transcortical motor aphasias (15–20%) present an intermediate frequency, and other aphasias are rare [1, 2, 5].

About 10% of aphasias remain unclassifiable, especially in patients with a previous ischemic stroke (atypical aphasias: mixed aphasias, thalamic aphasias, and capsulo-striatal aphasias) [2, 12–14].

### 6.1 Broca's aphasia

#### 6.1.1 Clinical aspects

##### A. Assessment of oral production (spontaneous speech)

##### 1. Fluency

When there is no aphasic mutism or when mutism has regressed, the patient presents a nonfluent, arduous verbal output, characterized by difficulties to initiate spontaneous speech, effortful with hesitations and slow output (10–15 words/minute), and interrupted by word-finding pauses. Sometimes, he presents dysprosody (oral expression is monotonously, melodic modulation being absent) [1–5, 15–18].



## 2. Presence of deviations at various levels

- a. Sound/articulatory level (incorrect articulation of a sound)—dysarthria.
- b. Phonemic level (omission, substitution, addition, or inversion of a phoneme)—phonemic paraphasias.
- c. Verbal level (naming): semantic (verbal) paraphasias; word-finding difficulty (anomia), especially in spontaneous speech; deficits in action naming are more severe than deficits in object naming.
- d. Syntactic level: agrammatism, usually more apparent after the acute phase: omission of functional/grammatical words (prepositions, conjunctions, articles, auxiliary verbs/e.g. “the,” “an,” and inflections), while conceptual words (nouns, verbs, and adverbs) are used in a greater proportion—“telegraphic speech.” Sometimes, the oral production can be restricted to a few stereotyped utterances (e.g., “tan tan”) [4, 5, 17, 19].

### B. Assessment of repetition

*Poor repetition*—The patient will find difficult to repeat operational words and flexional endings, resulting phonemic and verbal paraphasias (e.g., “The boy eats an apple”/“Boy-eat-apple”). Repetition and naming are impaired, although this is less marked than spontaneous speech.

*Automatic speech*—Enumerating the days of the week, the months of the year, numbering from 1 to 10, repeating a poem, and so on, can ameliorate the verbal output [17, 20, 21].

### C. Assessment of oral comprehension

Usually, good oral comprehension, at least for commands, is needed to permit clinical exam. In some cases, syntactic comprehension can be affected as requested to understand complex sentences and multiple instructions [2]:

- a. The patient is unable to distinguish between different operational words like “on” or “in.”
- b. Comprehension of passive reversible sentences can be affected [18, 22].

Example:

(Q): “The girl was kissed by the boy. Who kissed whom?”

(A): Girl kiss boy.”

### D. Assessment of reading and writing

Reading (frontal alexia-literal alexia) and writing (frontal agraphia) are also impaired [20].

In conclusion, three characteristics represent the core of Broca’s aphasia: dysarthria, agrammatism, and preserved comprehension [1–5].

#### 6.1.2 Associated signs and symptoms

1. Contralateral hemiparesis—lesions that cause Broca’s aphasia also interrupt adjacent cortical motor fibers and deep fiber tracts.

2. Facial weakness.

3. Buccofacial apraxia/apraxia of speech, which represents a disturbance in motor programming of speech articulation. The patient is aware of his deficit, so he tries unsuccessfully to correct his disturbance by trial and error. Instead, he presents difficulty in initiating utterances, groping articulatory movements, and articulatory inconsistency on repeated attempts of the same utterance.

4. The patient with Broca's aphasia is aware of his oral expression disorders; consequently, he can develop depression [1–3].

### 6.1.3 *Anatomo-clinical correlations*

Lesions or dysfunctions usually involves on the left side in right-handed individuals (**Figure 2**):

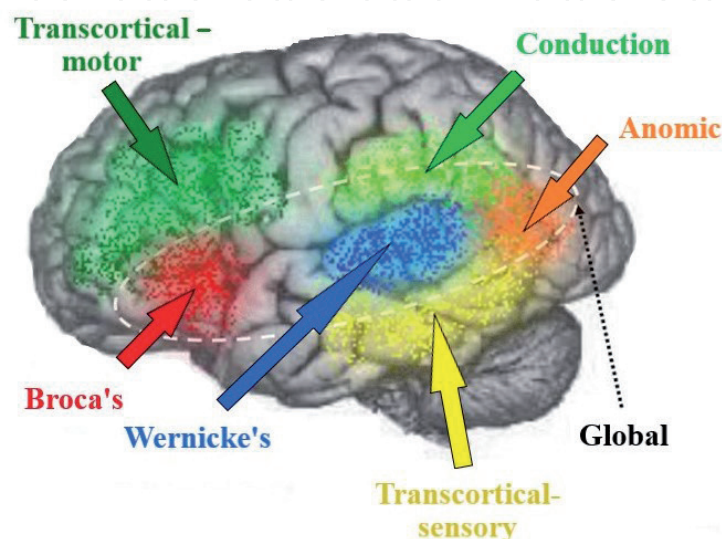
a. Broca's area: the posterior part of the third frontal gyrus-Brodmann areas 44 and 45.

Lesions in this area determine transitory apraxia of speech. Larger lesions, involving Broca's area and its subjacent white matter, produce transitory mutism, which is replaced by a rapidly improving syndrome with prominent arthric deformations and deficits in action naming that are more severe than deficits in object naming.

b. Rolandic operculum: lower part of motor area: Fa.

c. Lesions can extend or separately affect insular cortex, and subjacent white matter, centrum semiovale, capsulostriatum (caudate nucleus head and putamen), and periventricular areas. Infarctions involving together these structures and Broca's area can produce the complete syndrome of Broca's aphasia.

Broca's aphasia is produced by infarcts/severe hypoperfusion (MRI of the brain) of the superior division of the left MCA [1, 2, 5, 23–25].



**Figure 2.**  
*Different types of aphasias: anatomo-clinical correlations.*

## 6.2 Wernicke's aphasia

### 6.2.1 Clinical aspects

#### A. Assessment of oral production (spontaneous speech)

##### 1. Fluency

The verbal output is fluent, with easy initialization of speech, plentiful output (100–200 words/minute), the phrase length is normal (~5–8 words/phrase), with normal prosody. There is no quantitative reduction of spontaneous speech. In some cases, the oral production may be augmented (logorrhea), concerning patients with jargon aphasia and anosognosia (differential diagnosis with acute delirium) [1, 2, 5, 26–28].

##### 2. Presence of deviations at various levels:

a. Sound/articulation level: good articulation of sounds, well-articulated speech

b. Phonemic level: verbal paraphasias (semantically related word substitutions), phonemic paraphasias (phonologically related word or nonword substitutions), and jargon aphasia (associating frequently multiple paraphasias leading to neologisms)

c. Verbal level (naming): word-finding difficulty anomia (naming is severely affected), frequently associated circumlocutions, perseveration, and occasional neologisms

d. Syntactic level: paragrammatism: nouns replaced by pronouns (“that” and “those”) or by unspecific words (“thing” and “something”) [1, 2, 5, 26–28]

#### B. Assessment of repetition

Repetition is severely impaired [1, 2, 5, 26–28].

#### C. Assessment of oral comprehension

Oral comprehension is severely impaired, due to disturbances in language sounds perception (repetition is impossible); incapacity of accessing the meaning of the word (repetition is normal); decrease in verbal memory (repetition may be disturbed depending on the length of the verbal output of the speaker); perturbation in comprehension of the lexicosemantic relations of the phrase or utterance [1, 2, 5, 26–28].

Sometimes, comprehension is more difficult for isolated words; on the other hand, verbal reception of some lexicosemantic categories may be partially or totally preserved. Syntactic comprehension is significantly affected [1, 2, 5, 26–28].

#### D. Assessment of reading and writing

Reading is frequently impaired (alexia).

Writing (agraphia): spontaneous and dictated writing are fully of paraphasia and paragrammatism; copying a text is easier than writing after hearing one [1, 2, 5, 26–28].

### 6.2.2 Associated signs and symptoms

1. Homonymous hemianopia—frequently associated.
2. Complete/dissociated Gerstmann syndrome (agraphia, acalculia, finger agnosia, and inability to distinguish between the right and left sides of one's body).
3. Limb apraxia.
4. Anosognosia—it can be observed at the initial stage and decreases gradually; high excitation: logorrhea and exaggeration of mimico-gestural language. The patient with Wernicke's aphasia, in contrast to a Broca's aphasic, is unaware of his disorders and seems unconcerned [1, 2, 5, 26–28].

### 6.2.3 Anatomico-clinical correlations

- a. Wernicke's area: posterior part of the first two temporal gyri-T1/T2 (BA 22) (**Figure 2**).
- b. Inferior parietal lobes: angular gyrus (BA 39) and supramarginal gyrus (BA 40).
- c. Lesions can extend to the insular-external capsule region and anterior part of temporal gyri (BA22). Besides the cortical destructions from these areas, subjacent white matter can be also affected.

Wernicke's aphasia is the result of an infarct/severe hypoperfusion (MRI of the brain) of the inferior division of the left MCA (supplies the posterior part of the temporal lobe and inferior parietal lobule), usually an embolic occlusion/atherothrombotic [1, 2, 5, 23–25].

Wernicke's aphasia is more current in elderly women, due to a higher frequency of infarct in the inferior-posterior territory of the MCA in these patients [1, 2, 5].

## 6.3 Conduction aphasia

### 6.3.1 Clinical aspects

#### A. Assessment of oral production (spontaneous speech)

1. Fluency: verbal output (spontaneous speech) is fluent, although some hesitations and self-correction attempts to interrupt the flow are noted [1, 2, 5, 29–32].
2. Presence of deviations at various levels
  - a. Sound/articulation level: normal articulation (speech well-articulated).
  - b. Phonemic level: phonemic paraphasias are typical for conduction aphasia. The production of phonemic paraphasias across verbal tasks represents the cardinal feature of conduction aphasia.
    - Semantic/verbal paraphasias or neologisms are less frequent in conduction aphasia than in other fluent types of aphasia.

c. Verbal level (naming): anomia—naming may be mildly impaired.

d. Syntactic level: the grammar is preserved. Sentences are short and have simple syntax [1, 2, 5, 29–32].

### B. Assessment of repetition

Repetition is impaired, contrasting with the sparing of the oral comprehension. Repetition of monosyllabic or bisyllabic words can be normal, but repetition of polysyllabic words and of sentences is always incorrect. The patient often paraphrases the sentence rather than repeating it.

Repetitive self-corrections, word-finding difficulties, and paraphrasing are attempts to correct phonemic deformations by successive approximations, named “conduit d’approche” [2, 29–32].

### C. Assessment of oral comprehension

It involves sparing of oral comprehension. The patient understands simple, active sentences, but guesses at comprehension of passive sentences [1, 2, 5, 29–32].

### D. Assessment of reading and writing

It involves usually good reading comprehension, but paraphasic oral reading. More precisely, the patient has difficulties in spelling and reading unfamiliar words, but correctly reads and spells words.

In conclusion, conduction aphasia presents three major characteristics: a relatively fluent, though phonologically paraphasic speech; poor repetition; and relatively spared comprehension [1, 2, 5, 29–32].

## 6.3.2 Associated signs and symptoms

1. Oral and limb apraxia; ideomotor apraxia

2. Right sensory impairment [1, 2, 5]

## 6.3.3 Anatomo-clinical correlations

The lesions affect the inferior parietal lobes, especially the supramarginal gyrus or/and the external capsule; they classically disrupt the arcuate fasciculus (a large bundle of fibers), although its role remains debated for the repetition impairments: probably disconnection between the superior temporal cortex and the inferior frontal gyri, respectively (**Figure 2**).

Other explanations for the repetition impairments have been noted, such as short-term memory syndrome (the repetition impairment due to limited working memory)—so, the associated lesions are situated in areas critical for working memory: inferior parietal lobule (supramarginal and angular gyri), inferior frontal cortex, posterior temporal lobe, and/or their white matter connections (the external capsule).

Conduction aphasia is the result of an embolic infarct of the inferior division (posterior temporal or parietal) of the left MCA [1, 2, 5, 23–25].

It is rarely observed at the acute stage of stroke and more frequently affects younger patients.



## 6.4 Transcortical aphasia

Transcortical aphasia is the less common type of aphasia. They are characterized by preservation of word repetition, even of those words without meaning. Repetition of words is mediated by the perisylvian cerebral region (fronto-temporo-parietal region). Generally, in this type of aphasia, Broca's area, Wernicke's area, and the arcuate fasciculus are intact. In transcortical aphasia exists a disconnection between motor and/or sensory areas of language from hemispheric cortex, a process that occurs from lesions of border areas: (a) from ACA and MCA (transcortical motor aphasia) and (b) from MCA and PCA (transcortical sensory aphasia) [1, 2, 23–25].

### 6.4.1 Transcortical motor aphasia

#### 6.4.1.1 Clinical aspects

It is characterized by poor spontaneous speech (nonfluent, reduced oral output with possible initial mutism, loss of initiation, hypophonia, perseveration, and reduced phrase length). Minor dysarthria is noted in opposition with severe arthric deformation noted in Broca's aphasia. Sometimes, simplification of grammatical form is noted. Echolalia and perseveration are usually observed. Naming is frequently preserved.

Repetition and oral comprehension are typically spared [1, 2, 5, 33–36].

#### 6.4.1.1.1 Anatomico-clinical correlations

1. Cortical frontal lesions of border areas (watershed area) between the left anterior cerebral artery (ACA) and middle cerebral artery (MCA); less frequently left premotor and prefrontal regions, situated anterior and superior of Broca's area (dorsolateral region-sparing Broca area), and supplementary motor area (supero-medial area of the frontal lobe) (**Figure 2**)
2. Subcortical frontal lesions: thalamus, centrum semiovale with variable extension into the striatum (hypophonia is noted) [1, 2, 5, 23–25]

### 6.4.2 Transcortical sensory aphasia

#### 6.4.2.1 Clinical aspects

Spontaneous speech (oral output) is fluent, with verbal paraphasias, word-finding difficulty (especially by naming infrequent objects and animals), and circumlocutory speech (use of generic words such as "bird" for a hen and "furniture" for a showcase).

Comprehension is severely impaired at the word level, especially for unusual nouns. This contrasts with repetition sparing (this is the key feature that distinguishes it from Wernicke's aphasia). The patient is incapable to describe accurately a name that is correctly repeated. The comprehension deficit is usually associated with semantic impairment [1, 2, 5, 33–36].

#### 6.4.2.2 Anatomico-clinical correlations

1. Cortical lesions of border areas from MCA and posterior cerebral artery (PCA) territories: temporo-parieto-occipital junction region and inferotemporal region (second and third temporal gyri) (**Figure 2**)

## 2. Subcortical lesions: anterolateral thalamus

Alzheimer's disease, semantic variant of primary progressive aphasia (PPA) or Creutzfeldt-Jakob disease can produce a similar syndrome [1, 2, 5, 23–25].

### 6.4.3 Mixed transcortical aphasia (isolation aphasia)

#### 6.4.3.1 Clinical aspects

Nonfluent reduced spontaneous speech (verbal output), palilalia, or even transitory mutism, combined with impaired comprehension, impaired reading (alexia), and impaired writing (agraphia), relatively spared repetition. It combines signs of both transcortical motor and sensory aphasia. It looks like a global aphasia with relatively normal repetition [1, 2, 5, 33–36].

##### 6.4.3.1.1 Anatomico-clinical correlations

1. Cortical lesions isolating the spared perisylvian language areas (watershed territory between the left ACA and MCA in addition to the watershed territory between the left MCA and PCA) (**Figure 2**)
2. Subcortical lesions: large thalamic hemorrhage interrupting the temporal isthmus; infarcts in the left thalamus, putamen, and periventricular white matter [1, 2, 5, 23–25]

## 6.5 Global aphasia

### 6.5.1 Clinical aspects

It is the most severe form of aphasia, which associates with the following:

- a. Major disorders of oral production, represented by aphasic mutism (oral output lost), or by a spontaneous speech restricted to some stereotyped utterances (with dysarthria). Repetition is severely affected (it does not improve oral output, differing from mixed transcortical aphasia).
- b. Major disorders of the oral and written comprehension. Global aphasia differs from Broca's aphasia by the severity of oral comprehension impairment [1, 2, 5, 37].

#### 6.5.1.1 Associated signs and symptoms

Right hemiparesis/hemiplegia, right hemi-hypoesthesia, right homonym hemianopia, limbs apraxia, and facio-buccolingual apraxia [1, 2, 5, 37].

#### 6.5.1.2 Anatomico-clinical correlations

1. Extended lesions (including left perisylvian anterior and posterior language areas), which are the result of a left MCA/C1 occlusion (with a total left MCA infarct), produce global aphasia with hemiplegia, hemisensory deficits, and hemianopia (**Figure 2**) [2].

2. Broca's and Wernicke's areas may be simultaneously hypoperfused in the acute period. Thus, global aphasia can be the initial aphasic syndrome.

Early involution into Broca's aphasia (with early recovery of comprehension) may result from reperfusion of Wernicke's area. In this case, the patient presents only left frontal lobe, left basal ganglia, and left insula ischemic lesions (diffusion-weighted image shows infarct in superior division of left MCA territory, which includes Broca's area), sparing in the same time the left temporoparietal region (global aphasia with hemiplegia and early improvement of comprehension).

Later recovery of comprehension may appear from the reorganization of the language network:

3. Frontal and temporoparietal lesions (two lesions) produce global aphasia without hemiplegia. When sensory-motor deficit is missing, we should search for mixed transcortical aphasia.
4. Subcortical infarct extended into basal ganglia [1, 2, 5, 23–25, 38].

## 6.6 Anomic aphasia

### 6.6.1 Clinical aspects

Typical anomic aphasia is a fluent aphasia with word-finding difficulty anomia (noted in spontaneous speech and naming), usually associated with circumlocutions. Comprehension and repetition are spared.

Anomic plus aphasia presents additional minimal deficit of language (mild arthric deformation or mild impairment of oral comprehension or repetition). It is the mildest aphasic syndrome [1, 2, 5, 39].

### 6.6.2 Anatomico-clinical correlations

Acute anomic aphasia may be noted after stroke in many locations. It also represents a stage of all aphasic syndromes when they improve (**Figure 2**) [1, 2, 5, 23–25].

## 6.7 Peculiar aphasic syndromes

### 6.7.1 Crossed aphasias

This is a very rare condition (1% of all acute ischemic stroke aphasias) [39], defined by an aphasic syndrome in a right-handed patient (free from developmental disorders and previous brain lesions, fully lateralized, which is demonstrated using a questionnaire like Edinburgh Inventory) [40], caused by a right hemisphere lesion (nondominant hemisphere).

The anatomical determinants are similar to those observed in left hemisphere lesion, although a higher proportion of deviant cases are observed, particularly with mild aphasia contrasting with the large lesion. This fact is usually reported as evidence for bilateral representation of the language [2].

In the past, crossed aphasia was considered to be nonfluent, although today is reported that all aphasic syndromes can be registered (some cases of crossed Wernicke's aphasia in right-handed patients with lesions in the homologous area of the right cerebral hemisphere are noted [2].

### 6.7.2 Subcortical aphasias

Pure left striatocapsular infarcts (left deep MCA infarcts) can produce different types of aphasias (mainly nonfluent, especially motor transcortical aphasia and Broca's aphasia). Frequently, hypophonia (poor speech volume) can be noted.

Fluent and nonfluent aphasias have been reported in thalamic lesions. Usually, a thalamic aphasia presents a significant impairment of spontaneous speech, with verbal paraphasias, but with oral comprehension and repetition relatively spared [1, 2, 5, 28]. Patients with subcortical aphasias are older, because the main mechanism of ischemic stroke is small vascular disease.

There are two distinct mechanisms concerning subcortical vascular aphasias: (a) a possible sustained cortical hypoperfusion and infarction not visible on structural imaging studies and (b) a possible thalamic disconnection, due to striatocapsular infarcts [28].

## 7. Etiology of aphasias

Any type of lesion (localized/diffuse, acute/chronic, intermittent, progressive, or permanent) restricted to any of all mentioned language network from the dominant hemisphere in right-handed subjects (and rarely, in the nondominant hemisphere in right-handed subjects—"crossed aphasia") can cause aphasia [1, 2].

The most common causes of aphasia are the vascular pathology (ischemic and hemorrhagic stroke, aneurysm, cerebral veins, and dural sinus thrombosis), which produces vascular aphasias, traumatic brain injury, brain tumors, neuroinfections (especially Herpes simplex encephalitis), stroke mimics (aura migraine, epilepsy - ictal EEG sustaining the diagnosis of an epileptic seizure, and MRI-DWI), multiple sclerosis (rarely), and neurodegenerative diseases such as Alzheimer disease and primary progressive aphasia.

### 7.1 Vascular aphasias

Aphasia has a prevalence of 25–30% in acute ischemic stroke; it is a marker of stroke severity and of poststroke outcome, being associated with a higher risk of mortality, poor functional prognosis (can have a dramatic impact on person's ability to communicate), and increased risk of poststroke dementia [1, 2, 7–11, 41–43].

Vascular aphasias have not typically corresponded to linguistic domains network due to the fact that ischemic injuries specifically imply arterial territories, rather than being limited to the language network. Thus, the arterial syndromes include different concomitant neurological signs (hemiparesis, hemianopia, etc.) that are reported together with aphasia because they all represent functions that depend on arterial supply of a peculiar brain region (vessel which can be occluded, producing an ischemic stroke) [1, 22, 44].

The main determinant of the type of vascular aphasia is the infarct location [1, 2]. Recent studies concerning the hyperacute stage of ischemic stroke have demonstrated that aphasic symptoms have a similar evolution to that of cortical hypoperfusion; thus, improvement in cortical perfusion (following spontaneous or therapeutic recanalization) generates recovery of aphasia [1, 2, 5, 28]. Recanalization of an occluded M1 branch of MCA through development of collateral blood flow or through treatment in a patient with aphasia and a striatocapsular infarct can reverse the aphasia (the patient may present the late vascular syndrome due to the infarct rather than the initial vascular syndrome due to the hypoperfused area [1, 2, 5, 28].

## **8. Outcome**

Using different functional imaging techniques (perfusion computer tomography, diffusion- and perfusion-weighted magnetic resonance imaging, and positron emission tomography), recent studies have indicated characteristics of aphasia (in hyperacute stage), suggested prognosis (in the era of thrombolysis), and observed even the potential new treatments [such as transcranial magnetic stimulation (TMS)] [2].

### **8.1 Perfusion computer tomography**

Measuring cerebral blood flow and volume enables the definition of maps of penumbra (diminution of cerebral blood flow and normal/increase of cerebral blood volume) and infarct (diminution of cerebral blood flow and volume) in the hyperacute stage of ischemic stroke. It has been demonstrated that penumbra dynamics is the major determinant for aphasia evolution. Saving a cerebral area implicated in a specific language function (naming, etc.) clinically improved this modality [2].

### **8.2 Diffusion- and perfusion-weighted magnetic resonance imaging: the DWI/PWI mismatch region in acute stroke**

Functional MRI studies demonstrated that cerebral tissue at risk of infarction (as indicated by the mismatch of PWI and DWI) can survive if recanalization occurs quickly. This represents the major site explaining postischemic recovery, as proved by language task-specific activation adjacent to the infarct lesion within the region certified by the imaging mismatch.

### **8.3 The networks for residual language function and recovery after stroke**

Different studies using positron emission tomography reported that spontaneous recovery of vascular aphasias still occurs with the persistence of the lesion and it takes place by a few distinct mechanisms. The activation appears in some spared left hemisphere language areas, new left hemisphere areas not commonly involved in language processing (pars orbitalis of the inferior frontal gyrus, anterior insula, and middle frontal gyrus), and right hemisphere areas homotopic to control subjects language network. Interestingly, compensation by the right hemisphere respected the aphasia subtype network, the right F3 being recruited when the left F3 was affected [1, 2].

### **8.4 Prognosis**

Usually, vascular aphasias become less severe in the first 3 months after stroke. The spontaneous recovery depends on the severity of the initial aphasia (which has been related to the lesion location and size), but also on general stroke severity, etiology (ischemic and hemorrhagic), time from onset, age, gender, handedness, treatment, motivation and personality, associated disorders, etc. [1, 2, 5].

Nonfluent aphasia can rarely evolve into fluent aphasia, whereas a fluent aphasia never evolves into a nonfluent aphasia [45].

- a. Global aphasia may regress to Broca's aphasia (or less frequently to Wernicke's aphasia). Prognosis for global aphasia persisting at 1 month is poor, because only one-third of aphasics communicate satisfactorily at 2 years [2, 13, 46].



- b. Broca's aphasia may transform to anomic-plus aphasia. The prognostic for Broca's aphasia is relatively poor, because only 40% of patients regain ability to communicate satisfactorily [2].
- c. Transcortical-motor aphasia may transform to anomic-plus aphasia. The prognosis of transcortical-motor aphasia is relatively good, depending on the severity of spontaneous speech diminution and associated executive and memory impairment.
- d. Wernicke's aphasia may transform to conduction aphasia. The prognosis is relatively good, as nearly 60% of patients regain ability to communicate satisfactorily (those involving in conduction aphasics) [2].
- e. Conduction aphasia has a relatively good prognosis, because 70% of patients regain ability to communicate [2].
- f. Transcortical sensory aphasia has a relatively good prognosis, because 60% of patients regain ability to communicate satisfactorily in everyday activities [2].
- g. Anomic aphasia has a good prognosis (they have a good ability to communicate) [2, 13, 46].

The outcome of aphasia at 1 year after stroke can be predicted in the first week [45] by stroke subtype, the phonology score (the strongest predictor), age, educational level, and the Barthel Index score. Severe comprehension impairment is reported as a negative factor for stroke recovery, as the aphasic could not understand the rehabilitation tasks. In 2009, Parkinson et al. [47] observed improvement in object and action naming in chronic vascular aphasics. They noted that better recovery was associated with larger lesion in the anterior regions of the brain and absence of lesion in the subcortical regions.

## 9. Treatment

### 9.1 Speech therapy

Vascular aphasics may present some spontaneous language amelioration (spontaneous recovery), but speech therapy can significantly contribute to a better aphasia rehabilitation.

A very good language assessment is the key point for any program of speech therapy (the role of a dedicated and competent neurologist is very important) [48].

Speech therapy should not be used in the hyperacute stage of stroke. In this stage, we should focus on reperfusion (i.v. thrombolysis/thrombectomy) of the affected arterial territory. Speech and language therapy should be typically started as soon as the clinical condition becomes favorable, which is nowadays generally possible in acute stroke units (in the acute/subacute stage of stroke) [2].

The speech therapy has five objectives:

- a. *To keep the aphasic verbally active*: the specialists, including the neurologists, speech therapists, psychologists, nurses, and the family have to communicate with the patient using verbal and written language, not only gesture.

- b. *To relearn language*: even if the patient is old or present a large infarct, it is generally accepted that he can still relearn some language, from the simpler to the more complex (including the vocabulary or the grammar).
- c. *To provide strategies to improve language*: different language abilities can ameliorate if only selective strategies are used (depending on the peculiar type of aphasia; for example, the melodic intonation therapy is efficient only in Broca's aphasias, not in Wernicke's aphasia).
- d. *To teach the family to improve communication*: to avoid especially verbal interference, to keep the conversational subject, to use plenty of redundant information, to speak slow, to use prosody, and to be aware that the aphasic's communication ability certainly fluctuates due to variations in attention, etc.
- e. *To offer psychological support*: due to his/her communication difficulties, the aphasic needs somebody (the therapist) capable of understanding and supporting him [49].

Bhagal et al. [50] reviewed 10 studies and noted that intense speech therapy over a short period (approximately 9 hours of therapy per week during 12 weeks) ameliorate outcome. Conversely, lower intensity (2 hours a week) over a longer period (more than 20 weeks) did not improve evolution compared with informal support. In conclusion, speech therapy intensity should be of at least of 1 hour per day in the first 3 months after stroke onset [2].

Due to the specific level of the language which is affected, the speech therapy strategy to be used will be different (auditory analysis, word identification, etc.). For example, in global aphasia, the main goals of therapy are represented by helping the patient to use remaining abilities, to restore language abilities, to learn other methods (nonverbal) of communicating, etc. [48].

## 9.2 Pharmacotherapy

Nowadays, treatment of reperfusion (designed to restore cortical perfusion (i.v. thrombolysis/thrombectomy)) during the first 4–5 h (thrombolysis), and 6–12 h (thrombectomy) from the clinical onset, represents the main prevention approach.

Preliminary positive results were found using piracetam in nonfluent aphasias [51], but it has not been proven to be effective in long-term use [52]. Despite positive preliminary reports, bromocriptine did not improve nonfluent aphasias in a randomized, double-blind, placebo-controlled clinical trial [53]. Preliminary positive results were also noted using cholinergic agents (donepezil) in fluent aphasias [2, 54]. Efficacy of pharmacological treatments in the chronic phase needs to be demonstrated.

## 9.3 Transcranial magnetic stimulation (TMS)

Functional imaging studies of language in nonfluent aphasics usually report a possible overactivation in right hemisphere language homologues [55].

Evidence exists that left hemisphere functional recovery is clinically more relevant than right hemisphere activation as a compensatory mechanism after stroke. Thus, right hemisphere activation might be a negative factor for aphasia recovery after stroke [55]. Use of TMS could provide right hemisphere inhibition and, therefore, ameliorate regression of language deficits. Preliminary reports suggested that

TMS can improve naming in nonfluent vascular aphasics [55]. This assertion needs to be confirmed by randomized controlled trials.

As a general rule, pharmacological treatment or TMS would be better delivered just before speech and language therapy [2].

## 10. Conclusions

Vascular aphasia is a term that covers complex syndromes, and it is considered not only a stroke severity marker outcome (it is associated with a higher risk of mortality) but also a poststroke poor functional outcome (can have a dramatic impact on person's ability to communicate and increased risk of developing post-stroke dementia). Taking into consideration the unpredictable evolution of all mentioned aphasic syndromes and the lack of treatment strategies, next researches should focus on combined methods of improving patients' language after acute and even chronic stage of stroke (such as transcranial magnetic stimulation and speech therapy applied in consecutive, consequent, and sustained sessions).

## Author details

Dragoş Cătălin Jianu<sup>1,2\*</sup>, Silvana Nina Jianu<sup>3</sup>, Ligia Petrica<sup>4</sup>, Traian Flavius Dan<sup>1,2</sup> and Georgiana Munteanu<sup>2</sup>

1 Department of Neurology, “Victor Babes” University of Medicine and Pharmacy, Timisoara, Romania

2 Head of the First Department of Neurology, “Pius Brânzeu” County Emergency Clinical Hospital, Timisoara, Romania

3 Department of Ophthalmology, Military Emergency Hospital, Timisoara, Romania

4 Department of Nephrology, “Victor Babes” University of Medicine and Pharmacy, Timisoara, Romania

\*Address all correspondence to: dcjianu@yahoo.com

## IntechOpen

© 2020 The Author(s). Licensee IntechOpen. This chapter is distributed under the terms of the Creative Commons Attribution License (<http://creativecommons.org/licenses/by/3.0>), which permits unrestricted use, distribution, and reproduction in any medium, provided the original work is properly cited. 

## References

- [1] Abou Zeki D, Hillis A. Chapter 12. Acquired disorders of language and speech. In: Masud H, Schott JM, editors. *Oxford Textbook of Cognitive Neurology and Dementia*. UK: Oxford University Press; 2016. pp. 123-133
- [2] Croquelois A, Godefroy O. Chapter 7. Vascular aphasia. In: Godefroy O, editor. *The Behavioral and Cognitive Neurology of Stroke*. 2nd ed. UK: Cambridge University Press; 2013. pp. 65-75
- [3] Alajouanine T. *L'aphasie et le langage pathologique*. Paris : J.B. Baillière et fils éditeurs; 1968. p. 19
- [4] Benson FD, Geschwind N. Chapter 5. Aphasia and related disorders, a clinical approach. In: *Principles of Behavioral Neurology*. 1989
- [5] Jianu DC. *Elemente de afaziologie (Romanian)*. Timisoara, Romania: Mirton; 2001
- [6] Ardila A. Chapter 10. Assessment of aphasia. In: *Aphasia Handbook 2*. Miami, Florida, USA: Florida International University; 2014. pp. 171-188
- [7] De Renzi E, Faglioni P. Normative data and screening power of a shortened version of the token test. *Cortex*. 1978;**7**:41-49
- [8] Goodglass H, Kaplan E, editors. *The Assessment of Aphasia and Related Disorders*. 2nd ed. Philadelphia, PA: Lea and Febiger; 1983
- [9] Kertesz A. *The Western Aphasia Battery*. New York: Grune & Stratton; 1982
- [10] Nespoulous JL, Lecours AR, Lafond D, editors. *Protocole Montreal—Toulouse de l'examen de l'aphasie: Module Standard Initial (Version Beta)*. Montreal: L'Ortho Edition; 1986
- [11] Kertesz A, Sheppard A. The epidemiology of aphasic and cognitive impairment in stroke: Age, sex, aphasia type and laterality differences. *Brain*. 1981;**104**:117-128
- [12] Nadeau SE, Crosson B. Subcortical aphasia. *Brain and Language*. 1997;**58**:355-402
- [13] Verstichel P. Thalamic aphasia. *Revue Neurologique (Paris)*. 2003;**122**:947-957
- [14] Lhermitte F, Derouesné J. L'aphasie amnésique. *Revue Neurologique*. 1976;**132**:669-685
- [15] Kearns KP. Chapter 8. Broca's aphasia. In: La Pointe LL, editor. *Aphasia and Related Neurogenic Language Disorders*. 3rd ed. New York, Stuttgart: Thieme; 2005. pp. 117-141
- [16] Alexander MP, Naeser MA. Broca's area aphasics. *Brain and Language*. 1992;**43**(3):215-227
- [17] Haartmann HJ, Kolk HHJ. The production of grammatical morphology in Broca's and Wernicke's aphasics. *Cortex*. 1992;**28**:97-112
- [18] Jianu DC, Bednar M, Zolog A. Diagnosticul diferențial între tulburările fonetice și fonologice la afazici (Romanian). *Neurologie, Psihiatrie, Psihologie, Psihoterapie*. (Revista Societății de Neurologie și Psihiatrie pentru Copii și adolescenți din România), Bucuresti, Romania. 1999;**2**:55-58
- [19] Jianu DC. *Managementul afazicilor romani consecutiv infarctelor cerebrale (Romanian)*. Timisoara, Romania: Mirton; 2011
- [20] Damasio AR. Aphasia. *New England Journal of Medicine*. 1992;**326**:531-539



- [21] Kertesz A. Clinical forms of aphasia. *Acta Neurochirurgica. Supplementum* (Wien). 1993;56:52-58
- [22] Kory Calomfirescu S, Kory Mercea M. Afazia în accidentele vasculare cerebrale (Romanian). Cluj-Napoca, Romania: Casa Cărții de Știință; 1996
- [23] Thompson CK. Chapter 2. Functional neuroimaging. In: La Pointe LL, editor. *Aphasia and Related Neurogenic Language Disorders*. 3rd ed. New York-Stuttgart: Thieme; 2005. pp. 19-38
- [24] Hanna D. Chapter I. Neuroimaging contributions to the understanding of aphasia. In: Boller F, editor. *Handbook of Neuropsychology*. Vol. 2. Amsterdam, Netherlands: Elsevier Science Publishers, B.V.; 1989
- [25] Poeck K, de Bleser R, von Keyserlink DG. Computed tomography localization of standard aphasic syndromes. In: Rose FC, editor. *Advances in Neurology*. Vol. 42: Progress in Aphasiology. New York: Raven Press; 1984. pp. 71-89
- [26] Caspari I. Chapter 9. Wernicke's aphasia. In: La Pointe LL, editor. *Aphasia and Related Neurogenic Language Disorders*. 3rd ed. New York-Stuttgart: Thieme; 2005. pp. 142-154
- [27] Gainotti G, Ibba A, Caltagirone C. Perturbations acoustiques et sémantiques de la compréhension dans l'aphasie. *Revue Neurologique* (Paris). 1975;131(9):645-659
- [28] Jianu DC, Petrica M, Matcău L, Zolog A. Observații anatomo-clinice asupra unor cazuri de afazie fluentă Wernicke (Romanian). *Neurologia Medico-Chirurgica*. 2001;6(1):69-79
- [29] Simmons-Mackie N. Chapter 10. Conduction aphasia. In: La Pointe LL, editor. *Aphasia and Related Neurogenic Language Disorders*. 3rd ed. New York-Stuttgart: Thieme; 2005. pp. 155-168
- [30] Benson FD, Sheremata WA, Bouchard R, et al. Conduction aphasia, a clinico-pathological study. *Archives of Neurology*. 1973;38:339-346
- [31] Geschwind N. Disconnection syndromes in animals and man: Part 1. *Brain*. 1965;88:237-294
- [32] Jianu DC. Observații asupra unui caz de afazie de conducție (Romanian). *Neurologia Medico-Chirurgica*. 1996;1(1):35-38
- [33] Cimino-Knight A, Hollingsworth AL, Gonzalez Rothi LJ. Chapter 11. The transcortical aphasias. In: La Pointe LL, editor. *Aphasia and Related Neurogenic Language Disorders*. 3rd ed. New York-Stuttgart: Thieme; 2005. pp. 169-185
- [34] Jianu DC. Observații asupra unui caz de afazie paroxistică prin interesarea ariei motorii suplimentare Penfield, în cursul evoluției unui meningiom de sinus longitudinal superior (Romanian). *Neurologia Medico-Chirurgica*. 1998;5(2):51-53
- [35] Jianu DC, Petrica M, Deme S, Scutelnicu D, Matcău L, Zolog A, et al. Considerații anatomo-clinice asupra unor cazuri de afazie transcorticală motorie, senzorială și mixtă (Romanian). *Neurologia Medico-Chirurgica*. 2000;5(1):45-54
- [36] Grossi D et al. Mixed transcortical aphasia: Clinical features and neuroanatomical correlates. *European Neurology*. 1991;31:204-211
- [37] Collins M. Chapter 12. Global aphasia. In: La Pointe LL, editor. *Aphasia and Related Neurogenic Language Disorders*. 3rd ed. New York-Stuttgart: Thieme; 2005. pp. 186-198
- [38] Hanlon RE, Lux WE, Dromerick AW. Global aphasia without hemiparesis: Language profiles and lesion distribution. *Journal*



of Neurology, Neurosurgery,  
and Psychiatry (England).  
1999;**66**(3):365-369

[39] Godefroy O, Dubois C, Debachy B,  
Leclerc M, Kreisler A. Vascular aphasia:  
Main characteristics of patients  
hospitalized in acute stroke units.  
*Stroke*. 2002;**33**:702-705

[40] Oldfield RC. The assessment and  
analysis of handedness: The Edinburgh  
inventory. *Neuropsychologia*.  
1971;**9**:97-113

[41] LaPointe LL. *Aphasia and Related  
Neurogenic Language Disorders*. 3rd  
ed. Tallahassee, Florida: Department of  
Communication Disorders, Florida State  
University; 2005

[42] Kreisler A, Godefroy O, Delmaire C,  
et al. The anatomy of aphasia revisited.  
*Neurology*. 2000;**54**(5):1117-1123

[43] Coppens P. Why are Wernicke's  
aphasia patients older than Broca's?  
A critical view of the hypotheses.  
*Aphasiology*. 1991;**5**:279-290

[44] Lecours AR, Lhermitte F, Bryans B.  
*Aphasiology*. London: Baillière-Tindall;  
1983

[45] El Hachioui H, Lingsma HF,  
van de Sandt-Koenderman MWME,  
Dippel DWJ, Koudstall PJ,  
Visch-Brink EG. Long term prognosis  
of aphasia after stroke. *Journal  
of Neurology, Neurosurgery, and  
Psychiatry*. 2013;**84**:310-315

[46] Jianu DC, Jianu SN, Dan TF,  
Munteanu G. Extra and transcranial  
color-coded sonography findings in  
aphasics with internal carotid artery,  
and/or left middle cerebral artery  
stenosis or occlusion. *European Journal  
of Neurology*. 2018;**25**(Suppl 1):35-36

[47] Parkinson BR, Raymer A,  
Chang YL, Fitzgerald DB, Crosson B.  
Lesion characteristics related to

treatment improvement in object  
and action naming for patients with  
chronic aphasia. *Brain and Language*.  
2009;**40**:23-23

[48] Ardila A. Chapter 12. Aphasia  
rehabilitation. In: *Aphasia Handbook 2*.  
Miami, Florida, USA: Florida  
International University; 2014.  
pp. 198-208

[49] Ardila A. Chapter 11. Recovery  
and prognosis in aphasia. In: *Aphasia  
Handbook 2*. Miami, Florida, USA:  
Florida International University; 2014.  
pp. 189-197

[50] Bhogal SK, Teasell R, Speechley M.  
Intensity of aphasia therapy, impact on  
recovery. *Stroke*. 2003;**34**:987-993

[51] Greener J, Enderby P, Whurr R.  
Speech and language therapy for aphasia  
following stroke. *Cochrane Database of  
Systematic Reviews*. 2001;**2**:CD000125

[52] Güngör L, Terzi M, Onar MK. Does  
long term use of piracetam improve  
speech disturbances due to ischemic  
cerebrovascular diseases? *Brain and  
Language, Elsevier*. 2011;**117**:23-27

[53] Ashtary F, Janghorhani M,  
Chitsaz A, Reisi M, Bahrami A. A  
randomized, double-blind trial of  
bromocriptine efficacy in nonfluent  
aphasia after stroke. *Neurology*.  
2006;**27**:97-98

[54] Berthier ML. Poststroke aphasia:  
Epidemiology, pathophysiology  
and treatment. *Drugs & Aging*.  
2005;**22**:163-182

[55] Naeser MA, Martin PI, Ho M, et al.  
Transcranial magnetic stimulation  
and aphasia rehabilitation. *Archives of  
Physical Medicine and Rehabilitation*.  
2012;**93**:S26-S34