

We are IntechOpen, the world's leading publisher of Open Access books Built by scientists, for scientists

4,500

Open access books available

119,000

International authors and editors

135M

Downloads

Our authors are among the

154

Countries delivered to

TOP 1%

most cited scientists

12.2%

Contributors from top 500 universities



WEB OF SCIENCE™

Selection of our books indexed in the Book Citation Index
in Web of Science™ Core Collection (BKCI)

Interested in publishing with us?
Contact book.department@intechopen.com

Numbers displayed above are based on latest data collected.
For more information visit www.intechopen.com



Plasticity of the Visual Pathway and Neuroimaging

M. Gallegos-Duarte, S. Moguel-Ancheita,
J.D. Mendiola- Santibañez, V. Morales-Tlalpan and
C. Saldaña

Additional information is available at the end of the chapter

<http://dx.doi.org/10.5772/53013>

1. Introduction

Once the formation of cerebral and ocular structures has been completed, the simple light stimulus is enough to activate the necessary neural circuits that integrate the visual tract. It has been estimated that 50% of the cerebral cortex participates in the integration of the human binocular visual system. This system is practically distributed throughout the brain. Therefore, its study has captured the interest of various scientific fields.

The neuronal plasticity of the visual system is the theme of several current works [1, 2, 3]. Nevertheless, very little is known about the adaptive changes and about neuronal plasticity in children who have congenital strabismus (CS), main subject of the current chapter.

The vision is a brain function highly specialized and complex [4]. The structures that perform it are developed by means of division processes, migration, functional integration and regionalization during the corticogenesis [5]. An incorrect development or a bad functioning of the molecular, cellular or physiological mechanisms can induce an altered vision as in the case of strabismus.

The visual process is the result of the elaboration of images generated in the cortical network. This process comprises from the moment the light stimulus reaches the retina until the evocation of visual memories imbued with an affective component generated by the thalamus.

In a simple way, we will say that the visual system is integrated by the visual via and cortical integrator, but in this chapter we will specifically refer to the last one [6, 7]. The visual via takes the information in one direction in an antero-posterior direction. It extends from the eyes as sensorial receptors, arrives to the optical nerves, whose monocular

information influences the chiasma, where the nasal sector of the monocular information will perform a crossing of fibers, remaining the temporal fibers without crossing, from this point, the information shared by both eyes continues through the optic bands to the primary visual cortex or striate cortex to systematize the information and generate hyper-complex images [4, 8]. All the steps described, up to now, are considered to form part of the first afferent visual system.

Once the images that have been previously decoded by the striate cortex, in accordance with its temporal frequency space, perceptual-visual process initiates [1, 9]; for that, the visual information must be included in the intern dialog of the brain by means of the cortical network for the purpose of giving it a sense. For that, the information coming from the striate cortex travels through the anterior portions of the brain to be processed in multiple neuronal centers and circuits that shape the cortical integrator [4, 8].

Although the striate cortex is in charge of capturing a great amount of visual elements, it lacks an adequate working memory, for that situation, it results impossible to process the logic of the hyper complex images and give them a ludic sense, to identify and give sense to the environment, it is necessary to resend the information to the working memory sited in the thalamic cortex that adjoins the temporal lobes [4, 8].

Part of the information coming from the grooved area is directed towards the temporal lobes to give a logic sense to answer the question “what am I seeing?” The temporal cortex shares its proximity with the thalamus and auditory areas, because besides de affective sense (like, dislike, danger, repulsion, attraction, etc.) the temporal area processes the visual information to give it directionality [10, 11].

The temporal lobes cooperate with their counterpart of Magno-cellular elements that conform the occipital-parietal via, this last one is the one in charge of assertively answering the question “where is what I am seeing?” the four pathways: left and right occipital temporal as well as the left and right occipital-parietal, give a meaning to the visual information coming from the striate cortex [2, 9].

These associative areas conduct the information that must transform in complex pre-logic elements such as the early recognition of facial expressions or manual attitudes of others (threaten, friendship, indifference), for example, and they are the base for the realization of some specific visual-motor functions such as reading-writing. Once the limbic system adjacent to the temporal lobes, gives affective sense, motivation, and nuance to the visual information, all the observed can be evaluated in relation with other experiences kept in the memory [4, 8, 12].

The cortical integrator works in parallel in an interactive form, as if it were a close cybernetic negative feedback system; its most elaborated product is the binocular vision. It is to be expected that the correct operation and integration of the neuronal visual network depend on an adequate connectivity among the parts that conform the cortical network. In this context, the visual perception is the result of the process of the information that is generated in the neuronal circuits [1, 13, 14].

From this point, all the information is distributed through the cortical network [1, 9] and this is important to consider before analyzing the studies of neuroimaging, by means of a neuro-metric study [15], electroencephalography [16, 17], or visual perceptual study [18].

Although the CE does not initially affect the superior functions such as judgment or intel-lect, frequently patients who have this disease may get confused with letters, they require more time to learn to read, are easily distracted, and in general, the development of their activities take more time respecting the individuals with a normal vision. In fact, the chil-dren with strabismus present different grades of visual perceptual deficit, which we believe is related with the alterations in the pathway of neuronal interconnection sited in the striate cortex and the cortico-cortical and interhemispheric zones that participate in the processing of the image [6, 15, 17, 19] as it will be forwardly described in the perceptual-visual analysis (Table 1).

Visual perceptual ability	Before the treatment	After the treatment
Fusion Amplitude	-0.4/-0.7	+3 /-1
Stereopsis	0%	0%
Fixation disparity	H: -1.1 V: -0.4	H:-1.1 V: -0.7
Perception Speed	43%	50%
Main elements	88%	95%
Visual memory	87%	93%
Saccadic Movements	72 %	75 %
Shapes and Sizes	42%	80%
Following movements	95%	97%
Peripheral vision	42%	50%
Spatial vision	82%	85%

Table 1. Percentages before and three months after surgery for correction of congenital strabismus H: horizontal, V: vertical.

The Computerized Visual Perceptual Analysis (CVPA) is used to meet the efficiency of visu-al perceptual system. The CVPA basically estimates the efficiency of the integrator in the posterior portions of the brain, that is, the development of the occipito-temporal and occipi-to-parietal pathway.

The SPECT (Single Photon Emission Computed Tomography) estimates the metabolic demand of one determined cerebral region, when measuring the energetic demand of the neuronal groups [20, 21]. In these type of studies it is used as a reporter the analog consume of glucose radioactively marked with Technetium-99, which proportionally increments or diminishes based on the functional demand [22], (Figure 1).

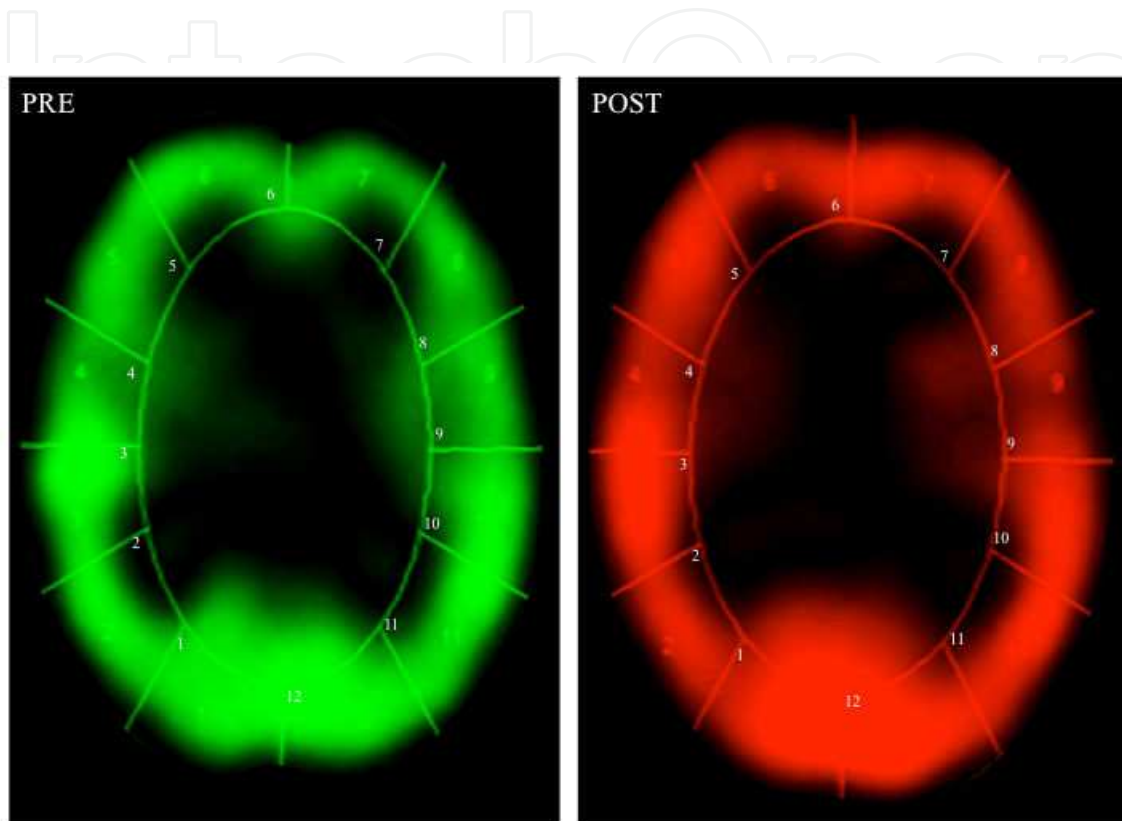


Figure 1. Pictures of the brain SPECT of a girl of 6 years of age. Green shows the status prior to treatment, color red shows the status 4 months after treatment with botulinum toxin. The right hemisphere (left side of the pictures) include zones 1 to 6, from bottom to up and the left hemisphere (right side of the picture) comprises de zones 7 to 12 from bottom to up.

This allows us to get to know the states of normal function, hyperfunction and hypofunction related to the different neuronal groups that work in the specific zones of the brain cortex [20, 21]. In pathologic conditions it is a very useful tool because it indicates us with high precision the normal and affected zones (Figure 2).

The information obtained by means of SPECT has allowed a better understanding of several events referring to the brain behavior and we have used it to determine the behavior and the functional specialization of the visual cortex. The findings that we have found with this methodology have been relevant for the neurology research and specifically to better understand the sickness, and has been helpful to know more about the origin, prognostic, plasticity and improve the life quality in the patients; the neuro adaptive changes that we have found by means of the brain SPECT [23, 24] are next detailed.

The neuronal network generates electric impulses, and this electric activity can be registered by means of the use of the Digitalized Brain Mapping (DBM), (Figure 3), as well as the analysis of the coherence of electroencephalography [25]. These methods provide an objective and noninvasive index of the functional relations that exist between the areas of the brain surface.

IntechOpen

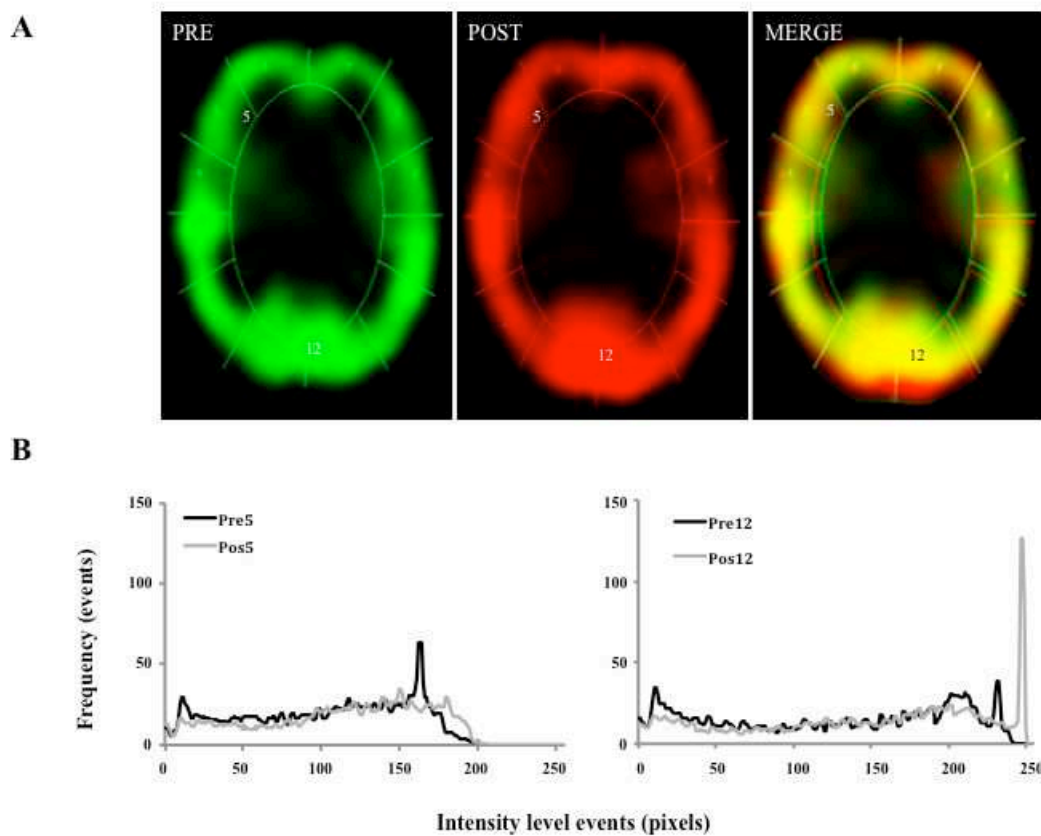


Figure 2. Above, to the right, the picture shows the combination of both studies (MERGE): yellow are those areas that did not suffer many changes, red highlights areas that showed an important metabolic increase (zones 1 and 12), and in shades of green (zones 5 and 9) are those areas that modulated their metabolic activity. At the bottom of the figure, the graphs show uptake of Technetium-99. The black line shows the previous state to the eye alignment by the use of botulinum toxin (Pre), the gray shows the reception levels of the glucose analog 3 months after the treatment (Post). The increase of the uptake after the treatment indicates a greater metabolic activity in V1 and V2. Reception of Technetium 99, the axis "X" shows the intensity level while the axis "Y" indicates the number of times that such intensity is registered

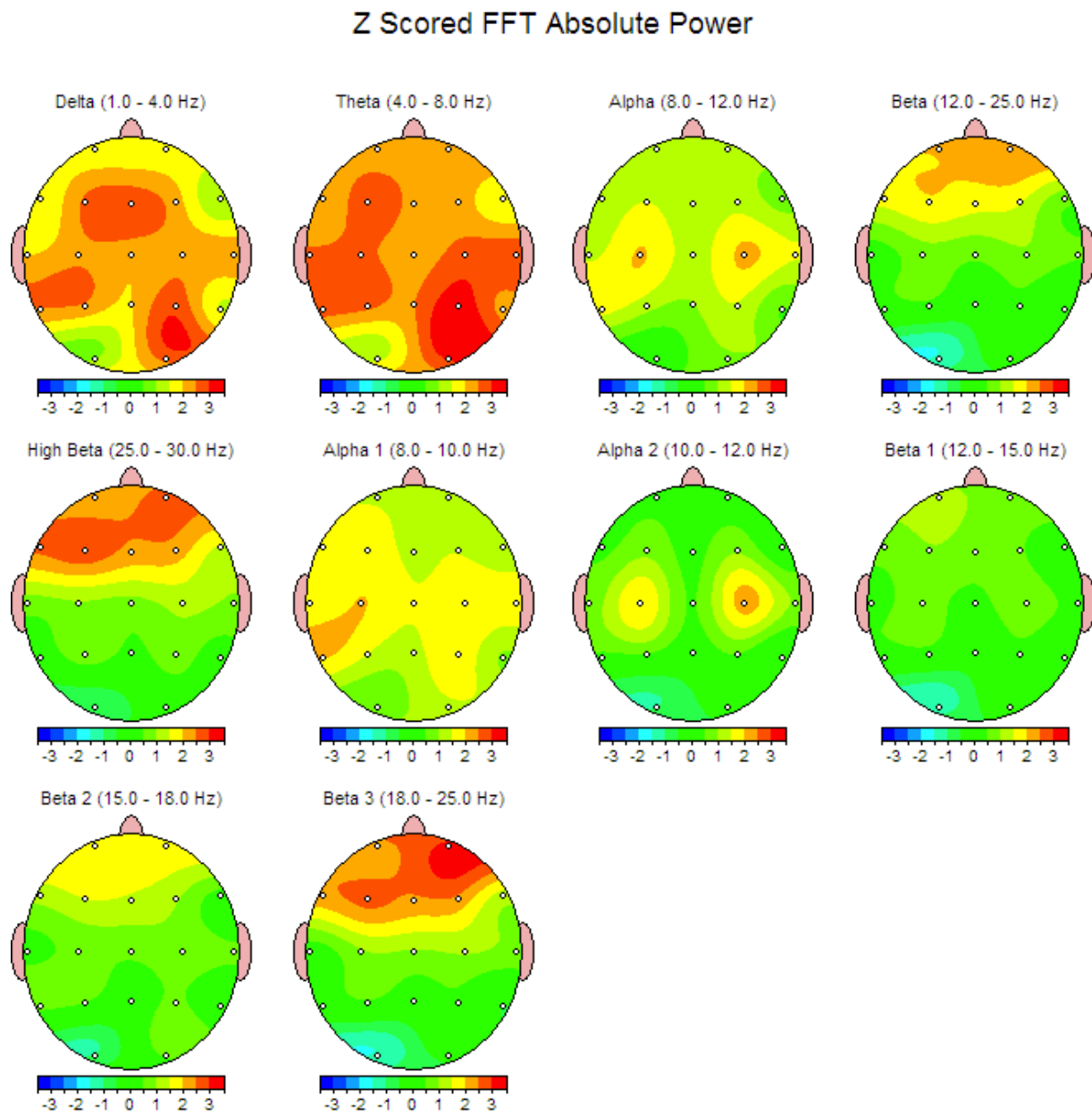


Figure 3. The Brain Mapping shows an increase in the absolute power and hypersimetry in the posterior regions of the brain after the surgery treatment of an 11 years old boy with congenital strabismus. Previous to the treatment he presented slow activity and asymmetry of the background activity in occipital regions.

In a previous study, we reported the results for 193 DBM obtained from children with congenital strabismus [26]. We found that 57% of the patient's studies without treatment presented alterations in the electric behavior that went from mild, such as intertemporal hypo coherence, up to important such as paroxysms and epilepsy, but 6 months after the surgery only 29% of the patients presented alterations in the electric activity (Figure 4). This motivated to perform a more meticulous analysis of the changes of the electric behavior that happen after the surgery by means of Neurometry [15].

Using digitized brain mapping, the authors have discovered morphometric and neurofunctional alterations in the cerebral cortex of patients with essential strabismus, such as intertemporal hypocoherence, cortico-subcortical dysfunction, slowing-down and asymmetry in the frequency, among others (Figures 3 and 4).

IntechOpen

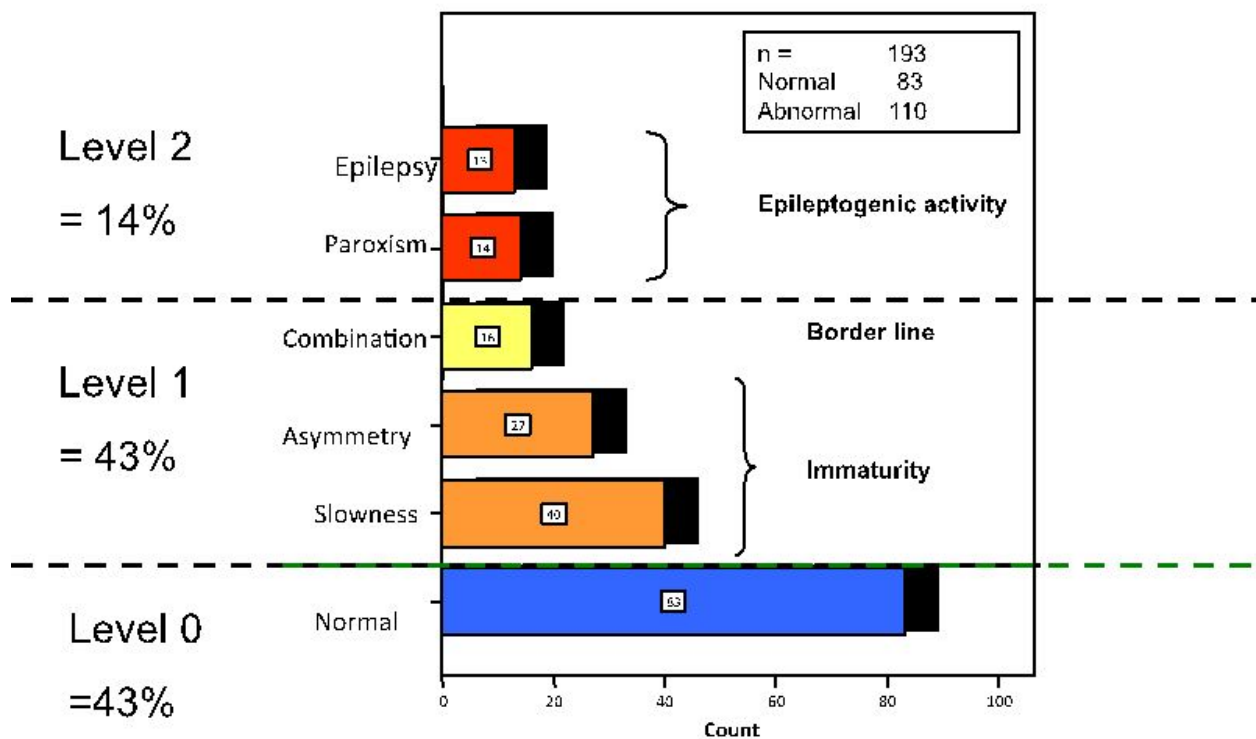
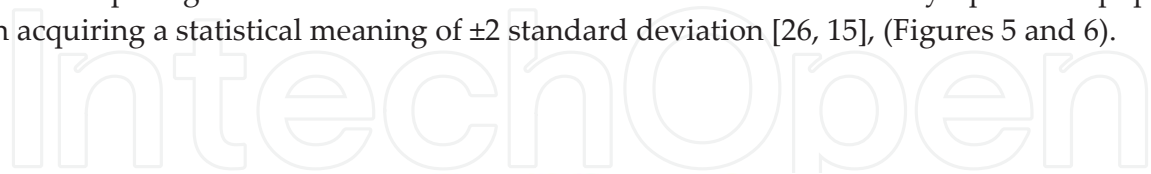

Figure 4. Summary of the reports of the Digitalized Brain Mapping obtained from 193 children with congenital strabismus. The dotted lines separate the sample in 4 levels: 43% were located with a normal electric behavior, 43% in level 1 with low electroencephalographic alterations and 14% presented important alterations

Neurometry allows us to get to know the coherence, which is determined by the activity of the short and large interconnection fibers, intra and interhemispheric, and expresses the synchrony among neuronal groups [15, 27] (Figures 6 and 7). So, meanwhile the hypo coherence expresses the lack of capacity of connection of neuronal groups, the hyper coherence indicates that two or more areas are over connected and work in excessive form. Besides, it allows comparing the obtained results with normative values of the asymptomatic population acquiring a statistical meaning of ± 2 standard deviation [26, 15], (Figures 5 and 6).



Z Scored FFT Coherence

Intrahemispheric: LEFT

	DELTA	THETA	ALPHA	BETA
FP1 F3	-0.17	0.78	1.02	1.15
FP1 C3	-1.54	-0.54	-1.78	0.53
FP1 P3	-2.19	-1.58	-1.12	-0.68
FP1 O1	0.42	1.04	1.13	-0.38
FP1 F7	-2.78	-1.79	-0.97	-0.92
FP1 T3	-0.91	-0.19	-0.98	0.18
FP1 T5	-0.11	0.62	0.64	-1.33
F3 C3	-2.29	-1.31	-2.89	-0.52
F3 P3	-2.45	-1.38	-2.25	-1.04
F3 O1	-0.53	-0.66	1.01	-1.40
F3 F7	-1.72	-0.77	-0.78	-0.84
F3 T3	-0.66	0.00	-1.00	-0.13
F3 T5	-1.07	-1.24	-0.13	-1.58
C3 P3	-2.20	-0.89	-1.33	-0.95
C3 O1	-1.65	-2.09	-1.73	-1.65
C3 F7	-1.46	0.03	-0.55	-0.05
C3 T3	-0.13	0.70	0.23	0.28
C3 T5	-2.16	-2.35	-1.49	-1.57
P3 O1	-1.67	-1.98	-0.05	-1.37
P3 F7	-2.09	-0.37	-0.87	-0.40
P3 T3	0.22	1.04	0.50	0.95
P3 T5	-2.02	-1.66	-0.25	-1.35
O1 F7	0.73	0.75	0.68	-2.07
O1 T3	-0.11	-0.56	-0.44	0.30
O1 T5	-1.29	0.07	0.10	0.12
F7 T3	-0.94	0.49	0.26	-0.91
F7 T5	-0.32	-0.72	-0.28	-0.22
T3 T5	-1.14	-0.93	0.09	0.27

Intrahemispheric: RIGHT

	DELTA	THETA	ALPHA	BETA
FP2 F4	-1.03	-1.05	-0.19	0.28
FP2 C4	-2.95	-1.84	-2.84	-0.41
FP2 P4	-2.17	-1.88	-1.31	-1.13
FP2 O2	-0.08	0.31	0.84	-0.60
FP2 F8	-1.99	-2.11	-1.76	-1.48
FP2 T4	-1.39	-1.02	-1.94	-0.26
FP2 T6	-0.85	0.15	0.51	-0.87
F4 C4	-2.85	-1.42	-2.78	-0.53
F4 P4	-2.43	-1.65	-1.84	-1.00
F4 O2	-1.35	-1.12	0.12	-1.49
F4 F8	-1.12	-1.45	-0.83	-0.92
F4 T4	-1.09	-1.07	-1.35	-0.15
F4 T6	-1.27	-1.31	-0.64	-1.30
C4 P4	-2.05	-2.03	-1.27	-1.09
C4 O2	-0.66	-1.37	-1.05	-1.23
C4 F8	-1.51	-1.45	-1.07	-0.68
C4 T4	-0.67	-1.31	-0.07	0.15
C4 T6	-2.31	-2.85	-1.54	-1.85
P4 O2	0.15	-0.04	0.66	0.36
P4 F8	-1.41	-1.42	-1.31	-0.50
P4 T4	0.31	-0.24	0.61	0.62
P4 T6	-1.33	-1.74	0.04	-1.14
O2 F8	-0.11	0.67	-0.19	-1.21
O2 T4	0.44	-0.80	0.40	0.52
O2 T6	-0.58	-0.25	0.74	-0.08
F8 T4	-0.63	0.09	-0.32	0.06
F8 T6	-0.92	-0.68	-1.39	-0.69
T4 T6	-1.23	-1.82	0.13	0.02

Interhemispheric: HOMOLOGOUS PAIRS

	DELTA	THETA	ALPHA	BETA
FP1 FP2	-4.09	-2.77	-1.51	-0.60
C3 C4	-1.47	-1.30	-1.96	-0.92
O1 O2	-0.25	1.51	2.09	2.74
T3 T4	-1.45	0.57	2.26	-0.61

	DELTA	THETA	ALPHA	BETA
F3 F4	-3.54	-3.02	-1.56	-0.80
P3 P4	-0.62	-1.31	-0.15	-1.12
F7 F8	-2.40	-2.47	-2.23	-0.83
T5 T6	0.15	-0.49	0.04	-1.06

Figure 5. Neurometric report before the treatment of the intrahemispheric (up) and interhemispheric (down) coherence analysis of a 7 years old boy with congenital strabismus. The excessive hypocoherece is marked in blue color, the excessive hypercoherence is marked in red. In abbreviation is marked by pairs the zones of interest analyzed (O1= left occipital, T4 = right temporal, as an example).

The Neurometry analysis has enabled us to determine that the following functional relations are altered: occipito-temporal, occipito-parietal and, especially, inter-temporal; the latter includes intra- and inter-hemispheric relations [10, 15, 28]. Similarly, we have employed the brain SPECT technique to define those areas with functional deficits [29, 30].

In a study performed by neurometric analysis we found previous to the surgery treatment of congenital strabismus that 15 of the 16 patients showed everlasting hypocoherece [28]; but after the surgery we found an improvement in this parameter. (Figure 6).

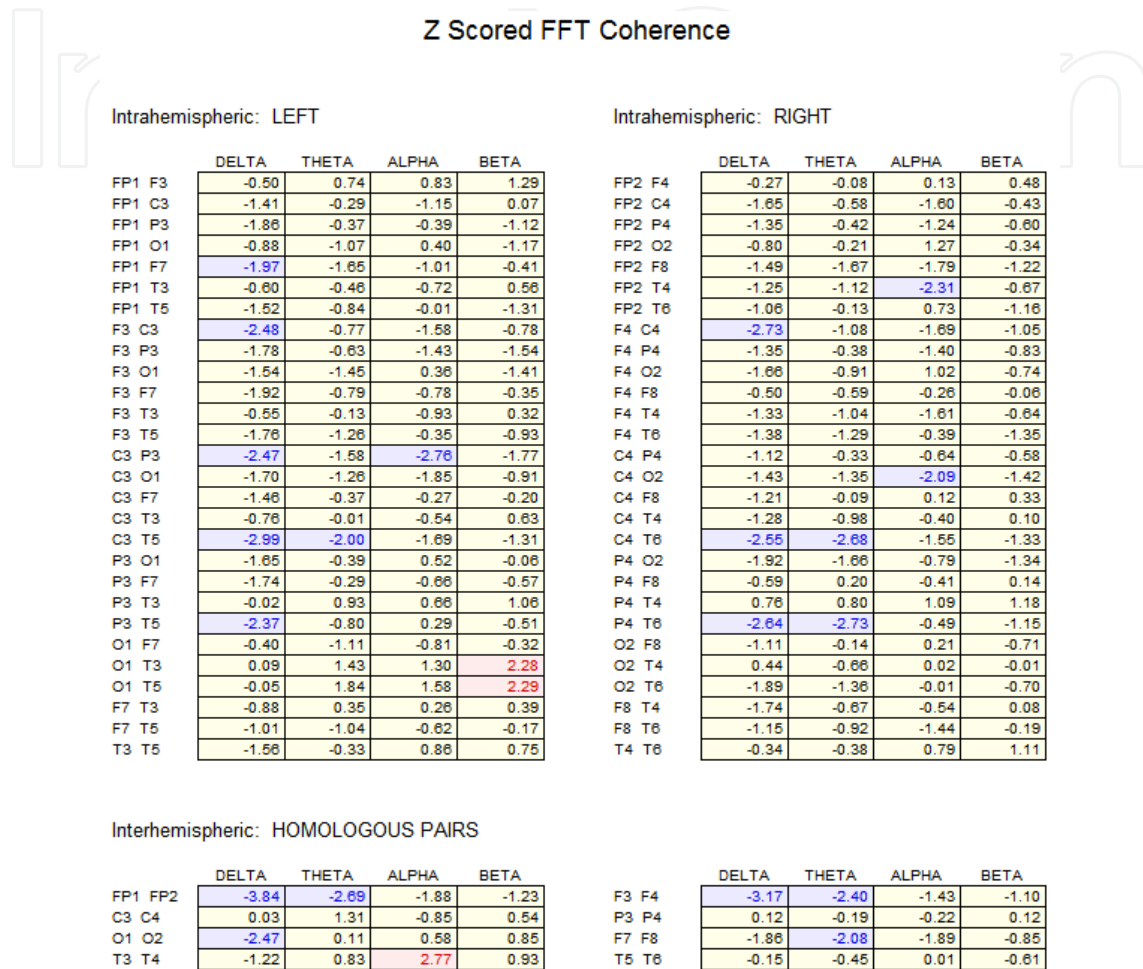


Figure 6. Neurometric report of the same boy as in figure 9 but 6 months after the surgical treatment. A diminish of the hypocoherece for Delta in frontal regions, an increase of the intertemporal coherences for Alfa and the modulation of the occipito-occipital coherence are observed.

2. Statement of problem

The CS is a neurological disease that manifests as a pathological deviation of the eyes [6, 31]. It represents the maximum perturbation of the binocular visual system and affects 3% of human beings [32, 33]. Due to the sensorial and motor alterations that characterize this disease may be systemized in an accurate manner, and results very simple to correlate the clinic with the neuroimage studies [26].

Given its anatomic and functional repercussions together with its esthetic and social impact, the predominance of CS in humans is patent [34]. In Mexico, where the majority of the population has a mixture of Spanish and Native American origins, this condition is one of the most frequent congenital disabilities [35].

However, one thing is to study the visual tract in healthy subjects and other very different matter is the study of the cerebral cortex of individuals with functional and/or structural asymmetries in their visual system, as happens in patients with essential strabismus. In particular, among our main concerns are the results of surgical and pharmacological manipulations of the extra ocular muscles, which will be addressed in this chapter.

In this manner, strabismus taken as a model of study offers researchers a unique opportunity to gain more insight into the mechanisms the brain uses to compensate the disequilibrium in the cortical network. This network, given the nature of the disease, instead of working in parallel presents peculiarities that should be considered in the study of brain plasticity.

The analysis of the cortical alterations inherent to strabismus has been possible due to neuroimaging techniques. As a result, it has been possible to ascertain, for example, that the fine morphometry in the brain of strabismic children is different from that in healthy children. This is particularly patent in the posterior portions of the brain.

3. Method used

To inquire about the changes that occur in the binocular visual system are analyzed the adaptive changes and brain plasticity before and after the ocular alignment, using the neuroimaging studies [36, 37]: SPECT, CVPA, DBM and Neurometry.

To identify these changes, the authors have carried out studies to determine the "before" and "after" in the treatment of strabismus by combining various neuroimaging approaches. As a result, have been identified positive and objective signs of brain plasticity.

To clinically study the perceptual system of the cortical network we use besides the visual acuteness, the CVPA, which examines the 10 basic visual abilities that are detailed in the table 1; these abilities are a reference of the functionality of the visual perceptual system [38].

To get to know the adaptive changes in the perceptual area, we carried out the CVPA on 22 children from 6 to 7 years old before and after the strabismus surgery. These children didn't received any additional treatment besides the surgery treatment (Table 1).

We have obtained SPECT images previous to the surgery or pharmacological treatment and 4 months after the treatment (Figures 7 and 8). The images were compared to determine the modified area and with that we could localize specifically the metabolic modifications in the several neuronal groups and, afterwards associate them to the neuronal function changes in the patients [36].

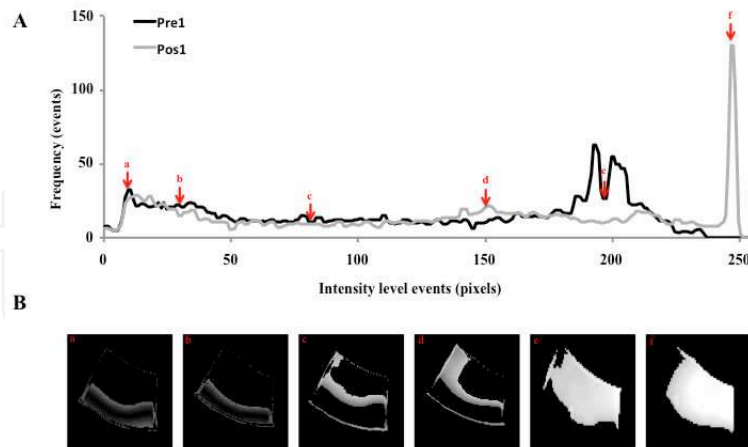


Figure 7. Zone 1 analysis of the SPECT (right occipital) of a 5 years old girl with congenital strabismus. The graphics and photos show the uptake of Technetium-99, the axis "X" shows the intensity level while the "Y" axis indicates the number of times that such intensity is registered. The black line shows the state previous to the strabismus treatment of the first case, and the gray line shows the state after the treatment. This metabolic modulation obeys the neuroadaptive change and the brain plasticity. The pictures show the different zones of interest that that were analyzed (marked in red arrows, has shown in the upper graphic)

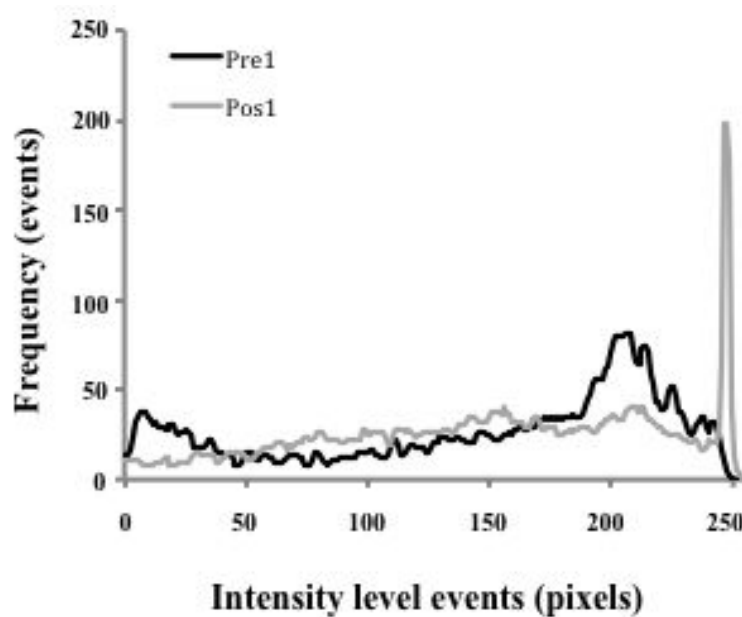


Figure 8. Behavior of the Technetium 99 before and after the treatment with botulinum toxin in a patient of 7 years old with congenital strabismus. The "X" axis shows the intensity level and the "Y" axis shows the number of times that such intensity is registered, the black line shows the previous behavior and the gray line shows the behavior after the treatment. Before the treatment, the zone 1 shows the increase of the density from 183 to 250, after the treatment an important increase is observed in 284, possibly related to the inter-hemispheric connectivity because the patient could obtain a binocular vision

To quantify the neurological adaptive changes related to the CS treatment, it was analyzed and graphed the capturing of the Technetium-99 for the purpose of establishing the grade of hyper and hypo function of the 12 zones of interest. In this communication it is showed the values before and after treatment in the gray scale (Figures 2, 7 and 8).

4. Results

In this study, after the surgery, it was demonstrated a certain recovery in CVPA, some of these changes as is the case of the saccadic movements and the disparity of the fixation were discrete, nevertheless other parameters such as perception of forms and sizes, the magnitude of the fusion or the peripheral vision showed important changes. Up to here, the changes clinically detected by CVPA indicate that there were favorable adaptive changes (Table 1).

From a metabolic point of view, the alterations previous to the strabismus treatment include the presence of hypometabolic regions; these regions show a substantial improvement after the pharmacological treatment with the botulinum toxin (Figures 1, 2, 7 and 8).

The pictures of the brain cortex showed a representative example of the change observed in several patients, in those pictures it is showed the metabolic change in special form, in the same individual before and after the correction of strabismus [4, 36, 37]. The image was divided in 12 sections to locate the prompt changes and to make the analysis easy (Figures 1 and 2).

From a bioelectric perspective, one of the most significant neuro-adaptive changes we have found after the strabismus treatment is an improvement in inter-temporal and inter-parietal coherences (Figure 9 and 10). On the other hand, we have shown the presence of hyper-symmetry and higher efficacy in the cortical input of the primary visual cortex using the Neuro-metry technique (Figure 11). These findings are in accordance with brain SPECT results (Figures 2 and 8).

When comparing the previous and posterior neurometries to the surgery treatment of 9 patients of strabismus, we found significant changes: improvement in the intertemporal coherences, an occipito-occipital hypersimetry (Figure 11), as well as a diminish in the occipital hyper-coherence, these data suggest that the surgery modifies substantially the connectivity cortico-cotical interhemispheric, as well as an increase in the activity of the striate cortex.

The findings found are congruent with the observed in the brain SPEC, in the sense that after the orientation of the visual axes, it was evident an exponential increase of the metabolism in the cortical areas V1 and V2 responsible of the elaboration of the hyper complex images with the depth sense, and these favorable adaptive changes indicate the presence of neuroplasticity in the binocular visual system in a punctual manner.

Right occipito-parietal coherence

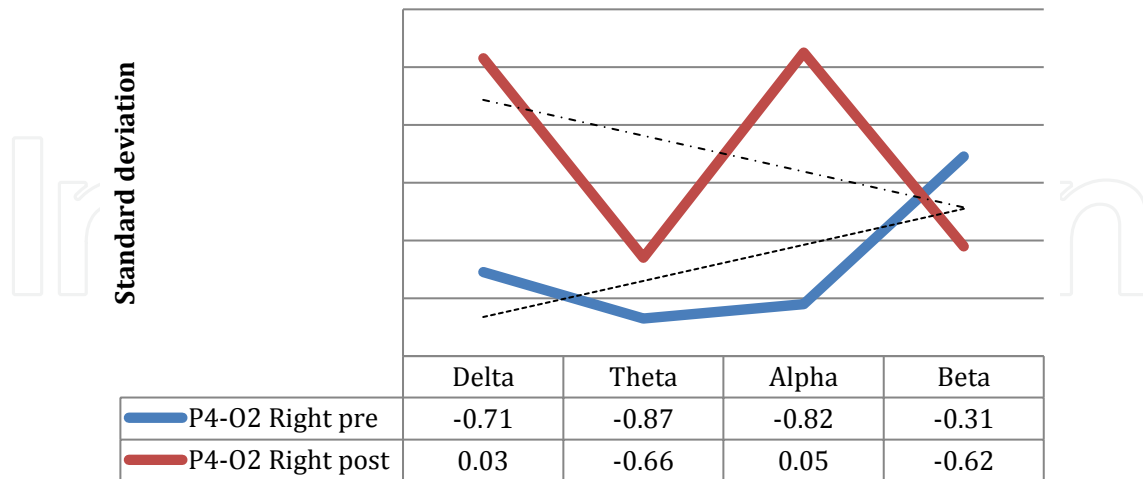


Figure 9. Posterior neuroelectric changes to the surgical correction of strabismus in a 5 years old child. A marked hypo-coherence in the occipito-parietal via before the treatment is represented with the blue line while the red line shows an improvement for Alfa and Delta after de surgery.

Left fronto-central coherence

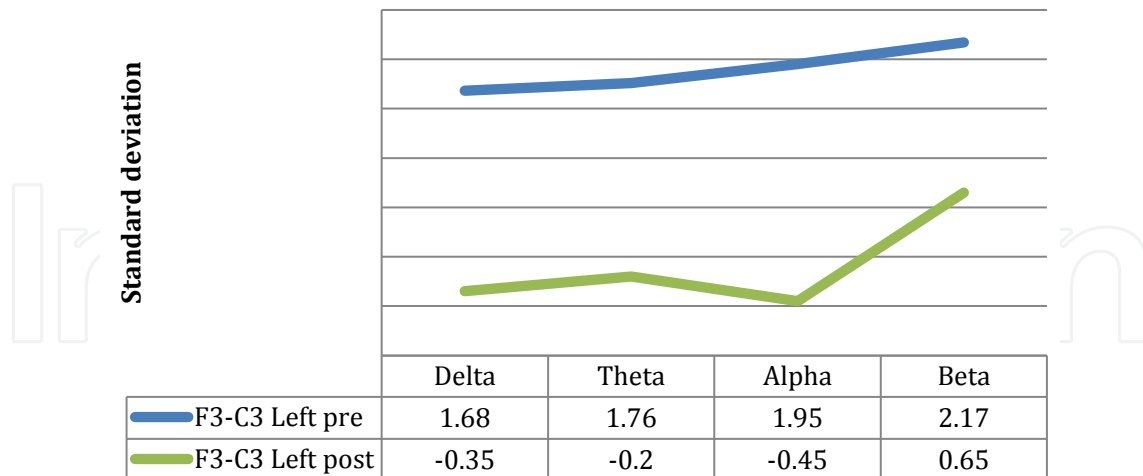


Figure 10. Neurometric analysis of a 5 years old child with congenital strabismus. The blue line showed the previous state of hypercoherence and the green line shows the normofuntion 3 months after the treatment.

Occipito-occipital symmetry

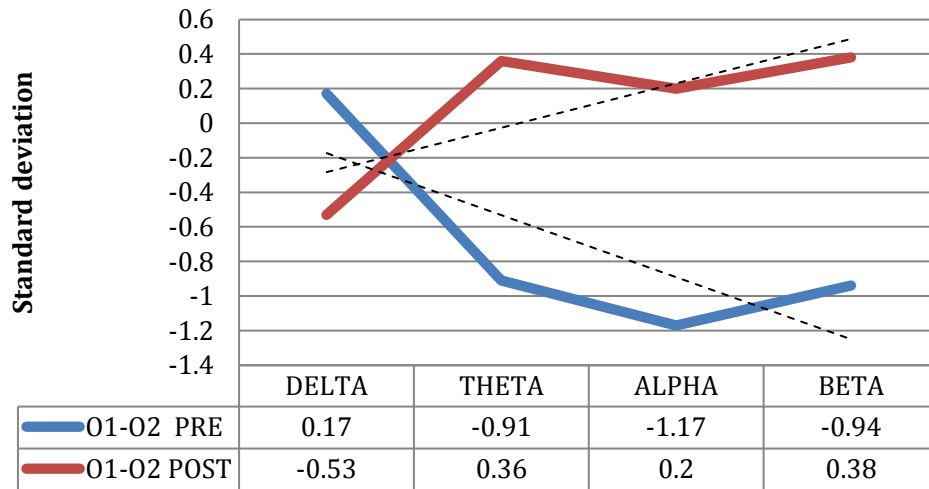


Figure 11. Neurometric analysis of a 5 years old boy with congenital strabismus before and 3 months after the strabismus surgery- the blue line shows important occipito-occipital asymmetry before the surgery. The red line shows occipital hypersymmetry after the surgery; this hypersymmetry is a finding frequently found after the surgical correction of congenital strabismus and indicates an increase in the function of the striate cortex.

5. Discussion

It is highlighted the fact that the human brain has plasticity or capacity to minimize the effects of the injuries through the structural and functional changes [39, 40], and in the best way to evaluate the plasticity, is by means of the clinic situation analysis with respect the previous and posteriors state to the treatment, or more simple, determining a “before” and “after” in the most objective possible mode, and what a better way to do it than by means of a neuro image [36, 37, 41].

To know with more acuteness what happens with the brain plasticity, we have used different functional neuro-image methods such as brain SPECT, the DBM and the Neurometry as we will next see [29, 30, 42].

Although the data obtained through the SPECT are a reflex of the cortical metabolic activity, they don’t measure neither the activity nor the electric connectivity, for such motive it is important to study them by means of other techniques additional to this activity. The combination of both techniques of complementary form allows us to establish with exactness if this events area correlated.

The authors decided to use a combination of three different neuroimaging methods before and after the treatment of strabismus to determine some neuroadaptive changes in patients with strabismus and have encountered significant neuro-adaptive changes, which we want to share with the reader. In this chapter, we want to share our neuroimaging

findings with the international scientific community, as well as our conclusions with regard to this subject.

The idea arose due to evidence that after the correction of the strabismus, the parents reported an improvement in the performance of homework such as reading, playing or writing, without any other different treatment than the surgery or the application of botulinum toxin.

Based on these studies, we have identified metabolic and neurofunctional changes present after the strabismus treatment. This information has shed some light in those neuro-adaptive changes prompted in the cortical integrator as a consequence of the manipulation of the extra-ocular muscles. This evidence has been obtained from neuroimaging techniques.

Regarding this long waited improvement related to strabismus, it is curious that in 1887, George Thomas Stevens had proposed the rehabilitation of an epileptic event and chorea by means of the optical and surgical correction of strabismus. The unusual idea of Stevens to treat in this mode an epileptic event more than one hundred years ago motivated, and not without reason, a scrupulous following for two and a half years to establish a commission of distinguished neurologists pertaining to the incipient neurological society of York. This commission in the middle of a controversial resolution dictated as unjustifiable the offer of the treatment of that doctor [16, 43].

More than once century later, while watching our results, we found three interesting facts related with that controversial proposal of Stevens: a) first of all ,the epilepsy is presented in a relative higher proportion that the general population in children with congenital strabismus, in the same way that some neurological diseases that manifest epilepsy have besides strabismus [15], b) after the ocular alignment the metabolic and neuroelectrical cortical activity changes positively, c) and finally, the fact that some strabismus manifestations such as the variability or inestability in the deviation angle worsen when a patient with strabismus and epilepsy does not take its medicines but improve when they are under control.

Maybe, Stevens was not so wild as it seem to be on that time; of course that keeping the due distances with what was expected to obtain. We do not suggest that by treating strabismus, the epilepsy is corrected or improved, but now we know that the cortical network can make important adjustments with the purpose to adapt to the new state.

It is now known that patients with congenital strabismus have a greater incidence of presenting depression, suicide, epilepsy, and attention deficit than the general population [4, 6, 15-17]. All indicates that the cortical network is implicated in the origin of strabismus and that the correction of this disease can improve in some way the efficiency of the cortical network.

6. Conclusions

The brain plasticity obeys the brain capacity to diminish the effects of the neuronal damage, being of genetic origin or produced by an injury [44], In spite that the cortical integrator has

a specialization level and maximum sophistication, it remains in an invariable state; on the contrary, the studies here shown mark that the plasticity of the visual system to compensate the binocular privation continually present.

The functional observed changes indicate that the simple fact of relocating the eyes in a way that the corresponding areas of the retina are stimulated, allows the cortical network to be in charge of the visual perception.

Effectively, the reactivation of areas relatively silent previous to the correction of the disease indicate that exists a residual capacity of the binocular system to reorganize, improve its connectivity, and the neuroconduction not only through the short and long intra and inter hemispherical interconnection via, but also through zones that comprise great cellular groups and that are capable of reactivating in a relative short time.

The combined use of SPECT, CVPA, DBM and Neurometry allow to best understand the concepts of regional plasticity, distinguishing that at least in the treatment of the strabismus, the occipital symmetry is increased, the metabolism is increased in V1 and V2, diminishes the intertemporal hypochoerence, improves the occipito-temporal coherence and eventually diminished the paroxysms. Clinically diminishes the angular variability, improves the perceptual parameters and in some way we believe that this helps us to contribute to a better visual performance.

As we can see it, the cortical plasticity does not refer simply to repair the damage, but it is a complex strategy of the cortical integrator guided to optimize the resources of the entire network, increasing the efficiency of all the visual system.

Based on all mentioned, we believe that the strabismus instead of being a merely cosmetic problem represents a neurological alteration, and when the treatment is applied involves neuroadaptative changes very favorable for the patient.

Nomenclatures

DBM Digitized brain mapping

SPECT Single Photon Emission Computed Tomography

CVPA Computerized Visual Perceptual Analysis

MERGE combining images computer system

Acknowledgements

The authors wish to thank the Mario Moreno Reyes foundation for the financial support. Jorge D. Mendiola-Santibañez thanks to CONACyT for the financial support, and Carlos Saldaña to PROMEP.

Author details

M. Gallegos-Duarte^{1*}, S. Moguel-Ancheita², J.D. Mendiola- Santibañez³,
V. Morales-Tlalpan⁴ and C. Saldaña¹

*Address all correspondence to: martin_oso@hotmail.com

1 Laboratory of Biophysics of Membranes and Nanotechnology, Department of Biomedical Research, Faculty of Medicine, Universidad Autónoma de Querétaro, Mexico

2 National Medical Center "20 de Noviembre" ISSSTE, Col. del Valle, México

3 Engineering Faculty, Universidad Autónoma de Querétaro, Querétaro, Qro, México

4 Regional Hospital of high specialty of the Bajío, San Carlos La Roncha. León, Guanajuato, México

References

- [1] Kusunoki M, Goldberg M.E. The time course of perisaccadic receptive fields shifts in the lateral intraparietal area of the monkey. *J Neurophysiol* 2002; 89:1519-1527.
- [2] Ross J, Morrone M.C,Goldberg M.E,Burr D.C.Changes in visual perception at the time of saccades. *Trens Neurosci* 2001; 24: 113-121.
- [3] McCoy PA, Huang HS, Philpot BD. Advances in understanding visual cortex plasticity. *Curr Opin Neurobiol* 2009;19(3):298-304.
- [4] Moguel-Ancheita S, Orozco-Gómez LP. Disfuncionalidad neuronal y psicomotora como retraso en el tratamiento de la ambliopía. *Cir Ciruj* 2007; 75:481-489.
- [5] Bystron I, Blakemore C, Rakic P. Development of the human cerebral cortex: Boulder Committee revisited. *Neuroscience*. 2008;9: 110-122.
- [6] Gallegos-Duarte M, Mendiola-Santibañez J, Saldaña C. Alteraciones de la sustancia blanca en el estrabismo congénito esencial. Estudio neurofuncional y morfométrico. *Acta Estrabológica* 2012; 51 (1): 13-40.
- [7] Nishitani N, Uutela K, Shibasaki H, Hari R. Cortical visuomotor integration during eye pursuit and eye–finger pursuit. *J. Neurosci* 1999; 19 (7): 2647–2657.
- [8] Wurtz R, Kandel ER. Vías visuales centrales. En: Kandel ER, Schwartz JH, Jessell TM, editores. *Principios de neurociencia*. 4ta ed. España: McGraw Hill;2000. pp. 524-545.
- [9] Merriam E.P, Genovese C.R, Colby C.L. Spatial updating in human parietal cortex. *Neuron* 2003; 39: 361-373.

- [10] Farivar R. Dorsal-ventral integration in object recognition. *Brain Res Rev* 2009; 61 (2): 144-53.
- [11] Bachevalier J, Mishkin M. Visual recognition impairment follows ventromedial but not dorsolateral prefrontal lesions in monkeys. *Behav Brain Res* 1986; 20: 249-261.
- [12] Alvarez P, Squire LR. Memory consolidation and the medial temporal lobe: A simple network model. *Neurobiology* 1994; (91): 7041-7045.
- [13] Hall NJ, Colby CL. Remapping for visual stability. *Philos Trans R Soc Lond B Biol Sci.* 2011; 366 (1564):528-39. Review.
- [14] El proceso Cognitivo Cap 2: Publicaciones de la facultad de Medicina de la UNAM. On line: <http://www.facmed.unam.mx/publicaciones/otraspub/gea-concurso/Cap2.PDF> (accessed 22 mars 2008).
- [15] Gallegos-Duarte M, Mendiola-Santibáñez JD, Ortiz-Retana J J; Rubín de Celis B, Vidal-Pineda R, Sigala-Zamora A. Desviación disociada. Un estrabismo de origen cortical. *Cir Ciruj* 2007; 75 (4): 237-243.
- [16] Gallegos-Duarte M, Moguel-Ancheita S. Participación y neuromodulación de la corteza en un caso de estrabismo disociado y epilepsia. *Arch Chil Oftalmol.* 2006; 63 (2): 199-209.
- [17] Gallegos-Duarte M, Moguel-Ancheita S, Rubin de Celis B. Alteraciones en el mapeo cerebral en la endotropia congénita variable. *Rev Mex Oftalmol* 2004; 78 (3): 122-126
- [18] Visual perceptual learning. Lu ZL, Hua T, Huang CB, Zhou Y, Doshier BA. *Neurobiol Learn Mem.* 2011; 95 (2):145-51. Review.
- [19] Mendiola-Santibáñez JD, Gallegos-Duarte M. Segmentation of the brain and White matter on MRI using morphological connected transformation for the strabismus study. In: *Brain Imaging*. INTECH Open Access Publishers. p 171-194.
- [20] Mullan BP, Oconnor MK, Hung JC, Single photon emission computed tomography brain imaging. *Neurosurg Clin N Am* 1996; 7(4): 617-651.
- [21] Mizoguchi S, Suzuky Y, Kiyosawa M, Mochizuki M, Kacasaki T, Is K, et al. Detection of visual activation of lateral geniculate nucleus by positron emission tomography. *Graef Arch Clin Exp Ophthalmol* 2003; 241 (1): 8-12.
- [22] Ochoa-Madrigal MG, Ortega-Soto H, Valencia-Granados FJ, Cortés-Marmolejo F, Gutiérrez-Trejo MA, Galicia-Tapia et al. Perfusión sanguínea cerebral mediante SPECT en niños con trastorno con déficit de atención con hiperactividad. *Neurocir Psiquiat* 2004; 37 (4): 145-155.
- [23] Moguel-Ancheita S. Aplicaciones de Toxina botulínica en Estrabismo. *Rev Mex Oftalmol* 1997; 71(5):194-200.
- [24] Moguel-Ancheita S. Tratamiento del Estrabismo con toxina botulínica. *Rev Mex Pediatr* 2000; 67(4):166-171.

- [25] Urretstarazu E, Iriarte J. Análisis matemáticos en el estudio de señales electroencefalográficas. *Rev Neurol* 2005; 41 (7): 223-434. [35].- Hoyt CS, Good W V. Infantile strabismus: What is it? Where is it? *Br J Ophthalmol* 1994; 78: 325-6.
- [26] Gallegos-Duarte M, Rubio-Chevannier HF, Mendiola-Santibáñez J; Brain Mapping Alterations in Strabismus. *Brain Research Journal* 2007; 1 (4): 287-337.
- [27] Calderón-González PL, Parra-Rodríguez M A, Libre-Rodríguez JJ, Gutiérrez J.V. Análisis espectral de la coherencia cerebral en la enfermedad de Alzheimer. *Rev Neurol* 2004; 38 (5): 422-427.
- [28] Gallegos-Duarte M. Neuroelectric alterations in strabismus. *Cir Ciruj* 2010; 78 (3): 215-220.
- [29] Zeki S, Watson JDG, Lueck CJ, Fristch KJ, Kennard C, Frackowiak RSJ. A direct demonstration of functional specialization in human visual cortex. *J Neurosci* 1991; 11(3): 641-649.
- [30] Marg E. Imaging visual function of the human brain. *Am J Optom & Physiol Optics* 1988; 65(10): 828-851.
- [31] Gallegos-Duarte, M; Estigma y origen de la endotropia congénita. *Rev Mex Oftalmol* 2005; 79 (1): 10-16.
- [32] Engle EC Genetic basis of congenital strabismus. *Arch Ophtalmol* 2007; 125: 189-195.
- [33] A study of heredity as a risk factor in strabismus. Ziakas NG, Woodruff G, Smith LK, Thompson JR. *Eye* 2002; 16. 519-521.
- [34] Michaelides M, Moore AT. The genetics of strabismus. *J Med Genet* 2004; 41: 641-646.
- [35] Hoyt CS, Good WV.: Infantile strabismus: What is it? Where is it? *Br J Ophthalmol* 1994; 78:325-6.
- [36] Moguel-Ancheita S, Orozco-Gómez LP, Gallego-Duarte M, Alvarado I, Montes C. Cambios metabólicos en la corteza cerebral relacionados con el tratamiento de estrabismo. Resultados preliminares con SPECT. *Cir Ciruj* 2004; 72: 165-17.
- [37] Gallegos-Duarte M 2004: Adaptative neurological modifications after medical and surgical treatment of strabismic syndrome with variability in the angle of presentation, may 10, 2004, Spring meeting. French Association of Ophthalmology. Palais du Congrès, Paris, France.
- [38] Kavale K. Meta-analysis of the relationship between visual perceptual skills and Reading achievement. *J Learn Disabil* 1982; (15):1 42-51.
- [39] Aguilar-Rebolledo F. ¿Es posible la restauración cerebral? Mecanismos biológicos de la plasticidad neuronal. *Plas Rest Neurol* 2003; 2 (2): 143-152.
- [40] Lobato RD. Historical vignette of Cajal's work "Degeneration and regeneration of the nervous system" with a reflection of the author. *Neurocirugía* 2008; 19:456-468.

- [41] Pascual-Castroviejo. Plasticidad cerebral. *Rev Neurol (Barc)* 1996; 24 (135): 1361-1366.
- [42] Milner AD, Goodale MA. The visual brain in action. *Psyche* 1998; 4(12):1-11.
- [43] Keane JR. Strabismus surgery for neurological illness. The Stevens commission 1887-1889. *Arch Neurol* 1989; 46 (3) : 323-4.
- [44] Bergado-Rosado JA, Almaguer-Melian W. Mecanismos celulares de la neuroplasticidad. *Rev Neurol* 2002; 31 (11): 1074-1095.

IntechOpen