

We are IntechOpen, the world's leading publisher of Open Access books Built by scientists, for scientists

5,500

Open access books available

135,000

International authors and editors

165M

Downloads

Our authors are among the

154

Countries delivered to

TOP 1%

most cited scientists

12.2%

Contributors from top 500 universities



WEB OF SCIENCE™

Selection of our books indexed in the Book Citation Index
in Web of Science™ Core Collection (BKCI)

Interested in publishing with us?
Contact book.department@intechopen.com

Numbers displayed above are based on latest data collected.
For more information visit www.intechopen.com



Lung Cancer – CT Vs Bronchoscopy

António Saraiva and Christopher Oliveira
*Escola Superior de Tecnologia da Saúde de Coimbra (ESTeSC), Coimbra
Portugal*

1. Introduction

During the recent years was possible to witness significant changes in the incidence and types of lung pathology seen by clinicians. It is important to mention that lung pathologies are some of the most common medical conditions worldwide.

Lung cancer was a rare disease in the early 1900s, but has since become far more prevalent and this lung pathology remains one of the greatest medical challenges with nearly 1.5 million cases worldwide each year and is the most common cause of cancer death in the world (Harewood GC et al., 2002) and (Spiro SG et al., 2010). It is typically a disease of elderly patients, with a peak incidence at around 70-80 years of age (Chen YM et al., 2009).

The incidence and mortality of lung cancer have increased sharply during this century, making it a common cause of death and the most frequent fatal cancer in men and women (Beckett WS, 1993). Clearly, lung cancer is an important and widespread disease that constitutes a major public health problem (Witschi H, 2001).

From all malignant tumors, except for non-melanoma skin cancer, lung cancer is the second most common type among men and the most frequent among women. The most concerning characteristics of this kind of cancer is that it has caused more deaths than the sum of the deaths caused by prostate, breast and rectal cancer in developed countries (Silva AC et al., 2011).

Smoking is estimated to be the cause of 85% of lung cancer deaths (Agarwal A et al., 2003). It is important to remind that the consumption of tobacco is not the only cause of this malignant tumor. Other factors are associated, affecting the incidence of this disease: exposure to arsenic, chromium, nickel and asbestos, cicatricial lesions of tuberculosis, and familiar history of lung cancer (Beckett WS, 1993) and (Figueiredo L et al., 1999).

Studies in molecular biology have elucidated the role that genetic factors play in modifying an individual's risk for lung cancer. Although chemopreventive agents may be developed to prevent lung cancer, prevention of smoking initiation and promotion of smoking cessation are currently the best weapons to fight lung cancer (Bilello Ks et al., 2002).

This malignant pathology, like most other solid tumors, is usually recognized late in its natural history. The five-year mortality from the time of presentation remains at approximately 85 to 90% and more than 90% of the patients with lung cancer will be symptomatic at presentation (Beckles MA et al., 2003).

Most patients with lung cancer present to the clinician in a fairly advanced stage and at best only 25-30% of patients can be offered curative resection (Kamath AV et al., 2006). A minority present with symptoms related to the primary tumor, and most patients present with either nonspecific systemic symptoms, including anorexia, weight loss and fatigue, or specific symptoms indicating metastatic disease (Beckles MA et al., 2003).

One of the causes of the low survival rate from lung cancer is related to difficulty of its precocious diagnosis due to the absence of symptoms and to the poor diagnosis at more advanced stages of the disease (Jamnik S et al., 2002). Prognosis is related to the type of presenting symptoms (Beckles MA et al., 2003).

Patients with lung cancer have a five-year survival rate varying from 13% to 21% in developed countries and varying from 7% to 10% in emerging countries (Silva AC et al., 2011).

However, when lung cancer is found at the early stage I or II, five-year survival rates can be as high as 60-70% (Beadsmoore CJ & Screatton NJ, 2003). The best survival rates are found in the subgroup of patients with lung cancer with surgically resectable tumors. Clinicians, therefore, are vitally interested in recognizing lung cancer early and determining surgical resectability accurately (Colice GI, 1994).

Symptoms, signs and abnormalities in laboratory tests relating to the lung cancer can be classified as follows: those related to the primary lesion, those related to intrathoracic spread, those related to distant metastasis, and those related to paraneoplastic syndromes (Beckles MA et al., 2003).

Lung cancer is routinely classified as Small Cell Lung Cancer (SCLC) or Non Small Cell Lung Cancer (NSCLC) on the basis of distinctive pathological and molecular features but also for appropriate therapeutic management (Scagliotti GV et al., 2009). The distinction between SCLC and NSCLC came into prominence when it was realized that SCLC was characterized by widespread metastatic spread at diagnosis and often displayed partial or complete response to conventional cytotoxic therapies (Gazdar AF, 2010).

The NSCLC category encompasses several subtypes having different morphological features generally treated according to similar strategies, so that a clear cut distinction among these types was not considered mandatory and accounts for 80% to 85% of lung carcinoma and determining the prognosis for an individual patient with NSCLC is difficult, in part because of the marked clinical heterogeneity of patients with the disease. Patients with early stage NSCLC have relatively high long-term survival rates after surgical resection, but a substantial majority of patients, approximately 80%, present in advanced stages (Scagliotti GV et al., 2009) and (Wang T et al., 2010).

SCLC is associated with poor diagnosis, with an average two-year survival rate of less than 10%. Patients are usually symptomatic at diagnosis, 30% to 40% report dyspnea and chest pain. Only 4% to 5% of SCLC cases are detected as solitary pulmonary nodule. Therefore, SCLC differs markedly from NSCLC in biologic behavior and clinical behavior. SCLC it is associated with rapid growth, and almost two-thirds of patients have metastatic disease at presentation. The response to the initial phase of the treatment is usually good, with almost 80% of the patients showing a major response (Argiris A & Murren JR, 2001) and (Oliveira C & Saraiva A, 2010).

The main histological types of this malignant disease include: adenocarcinoma, squamous cell carcinoma, SCLC and large-cell carcinoma. Adenocarcinoma accounts for 25 to 30% of NSCLC and is the most common histological type. It is typically classified as acinar, papillary, solid, and bronchioloalveolar varieties (Beckles MA et al., 2003) and (Patz EF Jr, 2000). The incidence of adenocarcinoma has increased in recent decades, while the incidence of squamous cell carcinoma has reached a plateau or has decreased (Chen YM et al., 2009).

A variety of techniques are available as methods of achieving a definitive diagnosis. The diagnostic evaluation of this disease has two main objectives: the definition of the pathological type of the tumor and staging of the disease (Westeel V, 2003). A diagnosis should be obtained by whatever method is easiest in patients who are presumed to have SCLC or who have very clear evidence of advanced NSCLC (*e.g.*, a large pleural effusion or metastatic disease). The most appropriate test is usually determined by the type of lung cancer (SCLC or NSCLC), the size and location of the tumor, and the presumed stage of the cancer (Brundage MD et al., 2002).

The available tools for diagnosing and staging lung cancer patients can be broadly categorized into non-invasive, minimally invasive and invasive (surgical) modalities (Hicks RJ et al., 2007).

Current imaging for lung cancer makes use of chest radiographs, Computed Tomography (CT), Magnetic Resonance Imaging (MRI), and nuclear medicine. Most studies are designed to detect anatomic abnormalities, leading to some problems in sensitivity and especially specificity. In the future, imaging may be directed more at tumor biology, and perhaps then will have a greater impact on this devastating disease (Patz EF Jr, 2000).

Although histology diagnosis is the most accurate detection method in the medical environment, it is an aggressive invasive procedure that involves risks, discomfort and trauma, which restrict it to be used in the clinical practice (Xiuhua G et al., 2011).

A person who is at high-risk for lung cancer and asymptomatic, and who is interested in potentially being screened should be fully apprised of the implications of screening and of the treatment that may result. It is fulcral to mention that the value of screening for early disease is not yet established and trials to see if mortality can be improved as a result are in progress (Henschke CI et al., 2007) and (Spiro SG et al., 2010).

It is important to refer that most symptomatic lung cancer is discovered at advanced stages, with the goal of long-term survival entirely dependent on effective treatment of stage III and IV lung cancer (Wang T et al., 2010).

More accurate staging at the time of initial presentation could improve design of clinical trials and avoid inappropriate surgical decisions in individual patients (Roberts JR et al., 1999). The TNM classification system for the staging of lung cancer has led to important advances in the determination of prognosis and treatment of patients with this disease (McLoud TC, 2006). TNM-staging has important influence on prognosis and therapy (Serke M & Schönfeld N, 2007).

This system takes into account the degree of spread of the primary tumor (represented by T); the extent of regional lymph node involvement (represented by N); and the presence or absence of distant metastases (represented by M). The TNM system is used for all lung

carcinomas except SCLCs, which are staged separately. SCLC is staged as limited or extensive disease. Limited disease is localized enough to be included in a radiation port, while extensive disease includes distant metastases.

Staging of extrathoracic disease is very important in providing optimal care for the patient with lung cancer (Shaffer K, 1997). The majority of the patients will have locally advanced or metastatic disease at the time of diagnosis (Stinchcombe TE et al., 2009).

It is fulcral to mention that survival is inversely proportional to the stage, with early detection and diagnosis being the key to achieving surgical cure (Hollings N & Shaw P, 2002).

An early diagnosis is the determining factor in the therapeutic selection. Surgery, Chemotherapy and Radiotherapy are the most frequently utilized types of treatment. It is important to refer that in SCLC surgery has a restricted use in management of this type of lung cancer, as only a few patients with limited disease may be eligible; chemotherapy is the primary form of treatment for both stages, and radiation is included for patients staged with limited disease (Argiris A & Murren JR, 2001).

Surgery has a pivotal role in the treatment of bronchogenic carcinoma. Indeed, resection is the standard treatment of early stages (I and II) non-small cell lung cancer, remains optional for a portion of patients with a locally advanced disease (IIIA and IIIB) and in anecdotal carefully selected patients with an oligometastatic disease (IV) (Thomas PA, 2009). In many situations a combination of two or even three treatment modalities is necessary.

In this chapter the authors will emphasize the role of Bronchoscopy and Computed Tomography in the diagnosis of Lung Cancer.

2. Bronchoscopy

Bronchoscopy is an essential tool in respiratory medicine, which allows visualization and sampling from the main airways and it is a central technique in diagnosing lung cancer, but also in different therapeutic approaches (Herth FJ et al., 2006).

This exam is currently the most commonly employed invasive procedure in the practice of pulmonary medicine. Both the rigid and flexible bronchoscopes are used to diagnose and to treat various pulmonary disorders (Udaya B & Prakash S, 1999).

It is important to emphasize that the most common indication for bronchoscopy is for tissue sampling and determining the extent of lung cancer and it is, also, utilized extensively in the initial evaluation of patients suspected of having this pulmonary malignant pathology (Simon M et al., 2010) and (Aristizabal JF et al., 1998). The indications for the bronchoscopic exam are extensive. The main diagnostic indications include pulmonary involvement by neoplasms, infections, diffuse lung diseases, and airway problems (Table 1) (Plekker D et al., 2010), (Shah PL, 2008) and (Udaya B & Prakash S, 1999).

The principal advantages of flexible bronchoscopy include a more extensive view of the tracheobronchial tree, ease of performance, and no requirement for general anesthesia (Suleman A et al., 2008).

Advancements in computer technology and engineering have allowed for the emergence of newer modalities to evaluate endobronchial, parenchymal, and mediastinal pathology (El-

Indications for Bronchoscopy

Diagnostic

Investigation of symptoms - Haemoptysis, Persistent cough, Recurrent Infection

Investigation of abnormal chest imaging - Lung masses, Diffuse infiltrates, Atelectasis or Pleural effusions

Diagnostic sampling of pathological processes - Endobronchial forceps biopsy, Transbronchial lung biopsy, Endobronchial brush, Bronchoalveolar lavage, Transbronchial needle aspiration

Staging of lung cancer - Mediastinal tissue diagnosis and staging

Infection - Identification of organisms (*e.g.* suspected tuberculosis), Evaluate airways if recurrent or persistent infection

Interstitial Lung Disease - Bronchoalveolar lavage for differential cell count and histology

Therapeutic

Foreign body removal, Management of massive haemoptysis, Endobronchial laser ablation, Electrocautery, Cryotherapy, Brachytherapy, Photodynamic therapy, Dilation of airway, Stent placement, Bronchoscopic lung volume reduction, Thermoplasty, Radiofrequency ablation

Research

Endobronchial biopsies in research of airway diseases, Bronchoalveolar lavage in research of diffuse lung diseases

Table 1. Indications for Bronchoscopy

Bayoumi E et al., 2008). Bronchoscopy has an important role in the evaluation of suspected lung cancer, interstitial lung disease, persistent infection and the assessment of new pulmonary infiltrates in immunocompromised patients. Recent developments have ranged from the improvement in image quality to integration of ultrasound (Shah PL, 2008).

Laser therapy, electrocautery, cryotherapy and stenting are well-described techniques for the palliation of symptoms due to airway involvement in patients with advanced stages (Simon M et al., 2010).

The decision about whether to perform a diagnostic bronchoscopy for a lesion that is suspicious for lung cancer depends largely on the location of the lesion (central Vs peripheral) (Rivera MP et al., 2003).

The bronchoscopic procedure requires specific training and experience in both flexible and rigid bronchoscopy. The recent advances in minimally invasive procedures has ultimately included a new array of therapeutic bronchoscopy for diseases which would otherwise not be treated, or offered only surgery, ended up adding a new variety of procedures that demand constant updates for the specialist to keep up with this rapidly evolving technology (Herth FJ et al., 2006).

Various diagnostic accessories can be inserted through the working channel of the flexible bronchoscope. These accessories include biopsy forceps, needles, and brushes, and they

have greatly aided in the diagnosis and staging of lung cancers. Their combined effect has greatly improved the ability to obtain pulmonary biopsies, especially of ever smaller lesions (Herth FJ et al., 2006) and (Udaya B & Prakash S, 1999).

Bronchoscopy with Transbronchial Needle Aspiration (TBNA) for cytologic or histologic examination of mediastinal lymph node has been shown to be a safe procedure (Rivera MP et al., 2003).

Flexible bronchoscopy is an extremely safe procedure provided some basic precautions are taken. A recent retrospective analysis of 23,682 patients over a period of 11 years showed a mortality rate of 0.013% with a complication rate of 0.739% (Jin F et al., 2008).

Complications may result from topical anesthesia, agents used for sedation or the procedure itself. Potentially life-threatening complications include respiratory depression, airway obstruction, arrhythmias, haemorrhage, infection and pneumothorax. Patient preparation for elective bronchoscopy includes fasting prior to procedure, informed consent, careful sedation in some cases, and topical anesthesia. Some of the contraindications include totally uncooperative patients, hemodynamically unstable patients, any severe acute illness and those who refuse to undergo the procedure (Plekker D et al., 2010) and (Suleman A et al., 2008).

Diagnostic yield depends on the location, size, character of the border of the lesion, and the ability to perform all sampling methods (Chechani V, 1996). The success rate of bronchoscopy in obtaining diagnostic pathologic material is significantly higher when a third- to fifth-order bronchus can be traced to the pulmonary nodule on a chest CT (positive CT bronchus sign) (Aristizabal JF et al., 1998).

The role of flexible bronchoscopy in lung cancer includes the following: inspection of airways to detect ipsilateral and contralateral endobronchial disease and their biopsy; transbronchial biopsy of the pulmonary nodule or mass; detection of mediastinal and/or hilar adenopathy; and possible transbronchial needle aspiration of the hilar or mediastinal nodes (Aristizabal JF et al., 1998). Bronchoscopy is also important in staging and it is required a careful inspection of the upper airways, superior vocal cords, trachea, carina and bronchi.

The endoscopic signs of lung carcinoma are variable, extending from a simple loss of brightness in a small area of the bronchial mucosa to a typical vegetative mass. Classically, three types of typical lesions or direct signs of tumor are taken into consideration: mass, infiltration and obstruction. However many other endoscopic changes or indirect signs (edema or local vascular fragility, localized inflammation or congestion, stenosis, bronchial stiffness and extrinsic compression) may correspond to a lung cancer so that, especially in patients at risk, these lesions should be investigated by aspiration and/or brushing and/or biopsy (Baughman RP et al., 1999) and (Cook RM et al., 1995).

Central lesions can present as an exophytic endobronchial mass, submucosal spread or a peribronchial tumor causing extrinsic compression. Most studies defined peripheral lesion as lesions that are not visible in the main or lobar airways (Rivera MP et al., 2003).

In central tumors endoscopically visible, studies referred a diagnostic yield of 91% to 94% in central lesions and 83% in peripheral lesions (Shure D, 1996).

The sensitivity of bronchoscopy for peripheral lesions is most affected by the size of the lesion. The False-Negative rate can be estimated to be fairly high in the case of peripheral lesions, especially smaller ones, because of the relatively low sensitivity in this setting (Rivera MP et al., 2003).

A negative initial bronchoscopy in a suspected lung cancer patient implies a greater potential for excessive delays in diagnosis and treatment in spite of a greater chance of curative treatment. Most of the delay occurs in the interval from the outpatient appointment to decision-to-treat. Patients with negative bronchoscopy require a more concerted effort to achieve a timely diagnosis and treatment (Devbhandari MP et al., 2008).

Bronchoscopy has, also, an important role in the diagnosis of benign conditions, but the chance of finding a benign condition in a patient who is clinically suspected of having lung cancer is only 1% (Rolston KVI et al., 1997).

The role of both old and new diagnostic bronchoscopy will continue to evolve as further improvements are made in bronchoscopes, accessory equipment, and imaging technologies (Herth FJ et al., 2010).

It is important to refer that special emphasis has been placed on their role in the early detection and staging of lung cancer. Some technology requires further study to delineate its role in the disease, whereas other modalities are emerging as the new gold standard in evaluation of lung cancer (El-Bayoumi E et al., 2008).

3. Computed tomography

Radiological studies play a fundamental role in every aspect of clinical medicine. Imaging offers invaluable information in establishing a diagnosis, guiding interventional procedures and directing patient management. Thus, imaging techniques play a crucial role in the diagnosis, staging and follow-up of patients with lung cancer. (Hansell DM et al., 2010) and (Wynants J et al., 2007).

Computer aided diagnosis of lung CT image has been a remarkable and revolutionary step, in the early and premature detection of lung abnormalities. CT was introduced into clinical practice in the 1970s as an exciting new method for imaging the thorax. Since then, clinicians have come to rely heavily on CT for evaluating potentially malignant chest lesions and the intrathoracic spread of lung cancer (Colice GL, 1994).

CT scanners can image the entire central airways in only half a second, allowing for dynamic cine imaging of the trachea and bronchi during respiratory manoeuvres (Hansell DM et al., 2010).

High Resolution CT techniques developed in the last decade have become invaluable tools for the detection of subtle diffuse lung disease patterns and for their characterization into multiple possible diseases and they provide detailed information regarding the lung parenchyma and can delineate structures down to the level of the secondary pulmonary lobule. It is particularly useful for image-based diagnosis, since alteration of the lung anatomy, caused by a disease, can be clearly seen in a thin-slice CT image (Tatjana Z & Busayarat S, 2011).

CT is still the basis of imaging studies in the preoperative staging and post-therapeutic evaluation of lung cancer and is currently the best imaging modality for diagnosing lung

diseases. The most recent developments in multidetector technology have dramatically improved the temporal and spatial resolution of CT (Lauren F et al., 2006) and (Tatjana Z & Busayarat S, 2011).

A chest CT is obtained in most of the patients with a pulmonary nodule or mass. A large body of imaging literature suggests that CT is a sensitive method to evaluate the proximal bronchi for neoplasm. It is also suggested that CT is helpful in predicting the yield of bronchoscopy in obtaining pathologic diagnosis of a pulmonary nodule or mass. In addition to demonstrating the location of the nodule (lobe, peripheral vs. central location), CT can also demonstrate if a third or fourth-order bronchus leads to or is contained within the pulmonary nodule or mass (Aristizabal JF et al., 1998).

CT plays a relevant role in the determination of presence and extent of lung cancer, demonstrating the size and site of the tumor. However, this exam presents some limitations such as high cost, utilization of ionizing radiation, contrast agent nephrotoxicity, besides the necessity of further procedures to confirm the diagnosis (Oliveira C & Saraiva A., 2010).

The findings of CT scans of the chest and clinical presentation usually allow a presumptive differentiation between SCLC and NSCLC. CT may also predict the yield of bronchoscopy in making a tissue diagnosis of pulmonary nodule or mass, if the predictive value of bronchoscopy is low, an alternate method of diagnosis may be chosen. CT can identify specific features in lung nodules that are diagnostic (e.g. arteriovenous fistulae, rounded atelectasis, fungus balls, mucoid impaction and infarcts) (Aristizabal JF et al., 1998), (Hollings N & Shaw P, 2002) and (Rivera MP et al., 2003).

This imaging modality also assists the implementation of complementary techniques including transthoracic needle aspiration biopsy, mediastinoscopy or video-assisted thoracic surgery (Landreneau RJ et al., 1996).

The CT indispensability in the study of lung cancer is associated with the obligatoriness of endoscopy of the respiratory tract with flexible endoscope (Cordeiro AJA Robalo, 1995).

Computed Tomography can detect tumors as small as 0.5 cm compared to a chest radiography which detects tumors at 3 cm. Yet, it is important to note that smaller tumor size does not necessarily equate to an early stage cancer as each tumor has its own growth pattern and disease development (Read et al., 2006).

It is important to note that pulmonary nodules of lung cancer in CT images share similarity with benign cases to some extent (such as tuberculosis, inflammatory pseudotumor, hamartoma, and aspergillosis) which makes it difficult to distinguish (Jee WC et al., 2008).

The majority of patients who present with lung cancer undergo CT scanning of the chest and liver (adrenal glands should be routinely included if lung cancer is suspected) and it is useful in helping to distinguish vascular structures from lymph nodes as well as in delineating mediastinal invasion by centrally located tumors (Al Jahdali H, 2008). Prediction of lymph node metastasis using combination of gene signatures and chest CT is superior to the CT-only diagnosis (Chang JW et al., 2008).

Morphologic imaging techniques such as CT cannot always differentiate reliably between benign and malignant lesions, as enlarged nodes may also be inflammatory whereas

normal-sized lymph nodes may contain malignancy. Thoracic CT is the most commonly used noninvasive staging method of the mediastinum (Harewood GC et al., 2002). CT scanning reliably depicts mediastinal invasion, provided that the tumor surrounds the major mediastinal vessels or bronchi. So it is fulcral to mention that CT of the chest is an important imaging modality that helps in detailed imaging of the primary tumor and its anatomic relationship to other structures, and it provides information with respect to the size of mediastinal lymph nodes and the status of the pleural space.

Currently available results on CT screening for lung cancer show that the work-up on baseline screening can be confined to less than 15% of the individuals and to less than 6% on annual repeat screening, almost all cases are detected by screening with very few diagnoses made between screening on the prompting of symptoms, and over 80% of all the diagnoses are of Stage I (Henschke CI et al., 2005).

Although the introduction of low-dose spiral CT is considered to be one of the most promising clinical research developments, CT screening is used for detecting small peripheral lesions. CT screening is a far more sensitive method than conventional radiography for identifying small, potentially early-stage, lung cancers (Hansell DM et al., 2010) and (Yasufuku K, 2010).

CT scanning of the chest is useful in providing anatomic detail that better identifies the location of the tumor, its proximity to local structures, and whether or not lymph nodes in the mediastinum are enlarged (Silvestri GA et al., 2007). CT enables us to see the lung anatomy in great detail and has been used to accurately diagnose lung diseases and is a remarkable technique for visualizing structures within the thorax (Colice GL, 1994) and (Xu Y et al., 2006).

In the decades, CT has been the main diagnosis tool of lung cancer for its convenience and safety, and widely used in clinical practice. However, it is difficult to distinguish between benign and malignant cases in the CT images of pulmonary nodules, especially for the doctors who were lack of experience. This imaging modality is useful in predicting the likelihood of achieving positive histocytology at Flexible Bronchoscopy. The overall CT prediction is superior to any of the individual CT features taken alone (Bungay HK et al., 2000) and (Xiuhua G et al., 2011).

4. CT Vs bronchoscopy in the diagnosis of lung cancer

4.1 Purpose

The main objective of this study was to analyze the role of Bronchoscopy and CT in the diagnosis of lung cancer by evaluating the effectiveness of these techniques in the presence of this malignant pathology.

It is important to emphasize that the possibility to evaluate two important diagnostic methods in the presence of Lung Cancer is the main factor that justifies this study.

4.2 Methods

This retrospective study was conducted with the approval of the institutional review board of the Hospital Distrital da Figueira da Foz.

This investigation was done in the Department of Pneumology of the Hospital Distrital da Figueira da Foz, between January and July 2009.

To carry out this study, the medical records of 70 patients were analyzed (42 patients were men and 28 patients were women; the mean age was 66 years).

These patients were referred to the Department of Pneumology of the Hospital Distrital da Figueira da Foz (along a four-year period - January 2003 to January 2007) and submitted to Bronchoscopy and Computed Tomography for suspicion of Lung Cancer, confirmed or not by the study of the pathology.

It is fulcral to refer that bronchoscopy and CT exams were considered as either negative or positive according to the information included in the respective reports. Bronchoscopy exams and the subsequent reports were performed by a Pneumologist. A Radiologist performed the chest CT exams and prepared the respective reports.

In this investigation agreements between the results of the exam and the presence or absence of lung cancer were analyzed by calculating Cohen Kappa statistics. Agreements were assessed for both exams in study (Bronchoscopy and Computed Tomography).

4.3 Results and discussion

It is important to mention that among the 70 patients submitted to bronchoscopy and CT, 37 were diagnosed with lung cancer.

The statistical analysis permitted to observe that the relation between the bronchoscopy results and the presence or absence of lung cancer was statistically significant ($p < 0.05$). Also the Kappa Value 0.656 demonstrated a good rate of agreement between the results.

It is primordial to refer that the authors observed that in the 37 positive bronchoscopic studies, 83.8% corresponded to the presence of cancer, and 16.2% to a negative diagnosis of this lung pathology. As regards the 33 negative bronchoscopic exams, 81.8% corresponded to the absence of lung cancer, and 18.2% to the presence of this malignant pathology (Table 2).

The relation between CT results and the presence or absence of lung cancer was considered statistically significant ($p < 0.05$), after the statistical analysis. The kappa value was 0.451, corresponding to a weak agreement between the results.

Among the 42 CT studies interpreted as positive, 71.4% corresponded to the presence of this malignant pathology, and 28.6% corresponded to the absence of this pathology. In the 28 CT studies read as negative, 75% corresponded to a negative diagnosis of lung cancer, and 25% demonstrated the presence of this disease (Table 3).

In Table 4 is possible to observe the sensitivity, specificity, accuracy, false-positive and false-negative of bronchoscopy and CT scans. In this study, Bronchoscopy sensitivity was 83.8%, specificity 81.8%, and accuracy 82.8%. False-positive results corresponded to 18.2%, and false-negative results to 16.2%.

The CT sensitivity was 81.1%, specificity 63.6%, and accuracy 72.8%. False-positive results corresponded to 36.4% and false-negative results to 18.9%.

			Presence or Absence of Lung Cancer		TOTAL
			PRESENT	ABSENT	
Bronchoscopy	POSITIVE	N	31	6	37
		% Bronchoscopy	83.8%	16.2%	100.0%
		% Total	44.3%	8.6%	52.9%
	NEGATIVE	N	6	27	33
		% Bronchoscopy	18.2%	81.8%	100.0%
		% Total	8.6%	38.6%	47.1%
TOTAL	N	37	33	70	
	% Bronchoscopy	52.9%	47.1%	100.0%	
	% Total	52.9%	47.1%	100.0%	

Table 2. Relation between the results of Bronchoscopy and the Presence or Absence of Lung Cancer ($\chi^2 = 30.125$; $gl = 1$; $p = 0$; Kappa value = 0.656)

			Presence or Absence of Lung Cancer		TOTAL
			PRESENT	ABSENT	
CT	POSITIVE	N	30	12	42
		% CT	71.4%	28.6%	100.0%
		% TOTAL	42.9%	17.1%	60.0%
	NEGATIVE	N	7	21	28
		% CT	25.0%	75.0%	100.0%
		% TOTAL	10.0%	30.0%	40.0%
TOTAL	N	37	33	70	
	% CT	52.9%	47.1%	100.0%	
	% TOTAL	52.9%	47.1%	100.0%	

Table 3. Relation between the results of CT exams and the Presence or Absence of Lung Cancer ($\chi^2 = 14.533$; $gl=1$; $p=0$; Kappa value =0,451)

	SENSITIVITY	SPECIFICITY	ACCURACY	FALSE-POSITIVE	FALSE-NEGATIVE
Bronchoscopy	83.8%	81.8%	82.8%	18.2%	16.2%
CT	81.1%	63.6%	72.8%	36.4%	18.9%

Table 4. Sensitivity, Specificity, Accuracy, False-Positive and False-Negative of Bronchoscopy and CT Exams

The results of Bronchoscopy confirmed the fact that this is an important test in the diagnosis of lung cancer, by its diagnostical dependence in the pathological examination of tissue or cells obtained by various techniques of biopsy. Several studies have demonstrated that more

than 70% of lung carcinomas are visible to bronchoscopy and combining bronchial biopsy, bronchial brushing, and bronchial washing results in an excellent diagnostic yield (Govert JA et al., 1998) and (Herth FJF, 2011).

The false-negative results of bronchoscopy found in the current study (16.2%) are due to the presence of peripheral lesions, particularly the smaller ones, because of the poor role played by bronchoscopy in these cases. Some published studies indicate that the sensitivity of bronchoscopy is poor for peripheral lesions that are < 2 cm in diameter (Chechani V, 1996), (Popovich J Jr et al., 1982) and (Schreiber G et al., 2003).

In the present investigation the authors obtained a sensitivity of 81.1% for CT, corroborating reports in the literature demonstrating that as lung cancer is detected by radiological methods, $\frac{3}{4}$ of the natural history of the pathology were already completed (Scagliotti G, 2001).

Radiology has traditionally played a crucial role in the evaluation and follow-up of patients with lung cancer. That role has changed with time, particularly with advances in surgical treatment and the introduction of new, less invasive techniques, such as video-assisted thoracoscopy and different imaging modalities have been used in the diagnosis and staging of lung cancer; reports refer that CT plays an important role in the diagnosis of lung cancer, however has been limited by uncertain detection rate for early stage of NSCLC, particularly central tumors (Jiang F et al., 2009) and (Shaffer K, 1997). CT scanning is required for a better delineation of the abnormality detected on plain radiographs.

Some studies in the literature mention that imaging plays an essential role in diagnosing, staging, and following patients with lung cancer (Patz EF Jr, 1999) and (Sarin PS et al., 1996).

The specificity of CT in this investigation is a result of the number of false-positive results (36.4%) and this situation is due to the fact that radiological findings suggestive of lung cancer (that lead to the rate of a CT study as positive) such as parenchymal mass with speculated margins, thickwalled cavities, microlobulations, cavitary nodules and chest wall invasion may be observed in other diseases such as infections, pulmonary inflammatory processes, infarction and lung abscesses (George CJ et al., 2004), (Madhusudhan KS et al., 2007) and (Runciman DM et al., 1993).

Several studies indicate that the high proportion of false-positive CT findings may reach 70% and thus, histological confirmation is essential for diagnosis (Makris D et al., 2007) and (Swensen SJ et al., 2005).

5. Conclusion

Lung cancer is a common pathology that has a poor prognosis and survival is inversely proportional to the stage, with early detection and diagnosis being the key to achieving surgical cure.

Despite medical advances lung cancer remains the leading cause of cancer deaths (Serke M & Schönfeld N, 2007).

The diagnosis of lung cancer is essentially achieved by CT and bronchoscopic techniques. During these years numerous improvements of these diagnostic tools have been made

available, which aspire to reduce the time to diagnosis and to simplify the initial staging approach.

The modality selected to diagnose a suspected lung cancer is based on the size and location of the primary tumor in the lung, the presence of potential metastatic spread, and the anticipated treatment plan (Schreiber G et al., 2003).

The main goals in selecting a specific diagnostic modality are to maximize the yield of the selected procedure for both diagnosis and staging and to avoid unnecessary invasive tests. The selection of the most appropriate test is done in a multidisciplinary way with contribution from a pulmonologist, radiologist and thoracic surgeon (Rivera MP et al., 2003).

The radiological diagnosis has become a key element in the evaluation and management of the patients with lung cancer and, in some instances, accurate staging and determination of appropriate treatment can be done noninvasively, with only imaging modalities, although in numerous situations surgical staging is also necessary.

Flexible Bronchoscopy with its attendant procedures is a valuable diagnostic tool in the workup of a patient who is suspected of having lung cancer. In the last decade, major advances have been made in interventional bronchoscopy.

Bronchoscopy results in this study corroborated the relevance of this method in the diagnosis of this malignant pathology, considering its dependence on the anatomopathological study of tissue or cells obtained through different biopsy techniques.

CT is today one of the cornerstones of imaging techniques and with the improved technical quality of CT scans, more small lesions are now detectable in the lungs.

The specificity of CT is limited and a histologic diagnosis or follow-up evaluation is, usually, necessary. The potential benefits of introducing CT screening for lung cancer detection may be its ability to detect more early stage tumors and decrease the numbers of later stage disease. And CT can best be thought of as a imaging tool that can provide a roadmap for more accurate surgical staging.

It is important to emphasize that in the detection and diagnosis of lung cancer should be carried out complementary exams that include CT and Bronchoscopy.

6. Definitions

False positive - is the proportion of absent events that yield positive test outcomes, i.e., the conditional probability of a positive test result given an absent event.

False - Negative - is the proportion of events that are being tested for which yield negative test outcomes with the test, i.e., the conditional probability of a negative test result given that the event being looked for has taken place.

Sensitivity - measures the proportion of actual positives which are correctly identified as such (e.g. the percentage of sick people who are correctly identified as having the condition).

Specificity - measures the proportion of negatives which are correctly identified (e.g. the percentage of healthy people who are correctly identified as not having the condition).

Positive predictive value - is the proportion of subjects with positive test results who are correctly diagnosed. It is a critical measure of the performance of a diagnostic method, as it reflects the probability that a positive test reflects the underlying condition being tested for.

Negative predictive value - is a summary statistic used to describe the performance of a diagnostic testing procedure. It is defined as the proportion of subjects with a negative test result who are correctly diagnosed. A high NPV means that when the test yields a negative result, it is uncommon that the result should have been positive

7. References

- Agarwal, A., Ghotekar, L. H., Garbyal, R. S., Mital, V. P. & Chokhani, R. (2003). Evaluation of pulmonary malignancies in Kathmandu Valley and role of bronchoscopic techniques in diagnosis of such cases, *JIACM* 4:127-33.
- Al Jahdali, H. (2008). Evaluation of the patient with lung cancer, *Ann Thorac Med* 3:74-8
- Argiris, A. & Murren, J. R. (2001). Staging and clinical prognostic factors for small-cell lung cancer, *Cancer J* 7(5):437-47
- Aristizabal, J. F., Young, K. R. & Nath, H. (1998). Can Chest CT decrease the use of evaluation of suspected bronchogenic preoperative bronchoscopy in the carcinoma?, *Chest* 113:1244-1249
- Baughman, R. P. & Pina, E. M. (1999). Role of bronchoscopy in lung cancer research, *Clin Chest Med* 20(1):191-9
- Beadsmoore, C. J. & Screaton, N. J. (2003). Classification, staging and prognosis of lung cancer, *Eur J Radiol* 45(1):8-17
- Beckles, M.A., Spiro, S.G., Colice, G.L & Rudd, R. M. (2003). Initial evaluation of the patient with lung cancer: symptoms, signs, laboratory tests and paraneoplastic syndromes, *Chest* 123(1 Suppl):97S- 104S.
- Bekett, W.S. (1993). Epidemiology and etiology of lung cancer, *Clin Chest Med* 14:1-15
- Bilello, K.S., Murin, S. & Matthay, R.A. (2002). Epidemiology, etiology and prevention of lung cancer, *Clin Chest Med* 23(1):1-25
- Brundage, M. D., Davies, D. & Mackillop, W. J. (2002). Prognostic Factors in Non-small Cell Lung Cancer* - A Decade of Progress, *Chest* 122:1037-1057
- Bungay, H. K., Pal, C. R., Davies, C. W., Davies, C. W., Davies, R. J. & Gleeson, F. V. (2000). An evaluation of computed tomography as an aid to diagnosis in patients undergoing bronchoscopy for suspected bronchial carcinoma, *Clin Radiol* 55(7):554-60
- Chang, J. W., Yi, C. A., Son, D. S., Choi, N., Lee, J., Kim, H. K., Choi, Y. S., Lee, K. S. & Kim, J. (2008). Prediction of lymph node metastasis using the combined criteria of helical CT and mRNA expression profiling for non-small cell lung cancer, *Lung Cancer* 60(2):264-70
- Chechani, V. (1996). Bronchoscopic diagnosis of solitary pulmonary nodules and lung masses in the absence of endobronchial abnormality, *Chest* 109(3):620-5
- Chen, Y. M., Shih, J. F., Tsaim, C. M., Lee, Y. C., Perng, R. P. & Whang-Peng, J. (2009). Revisiting Squamous Cell Carcinoma of the Lungs - A Disease Given Less Attention, *J Chinese Oncol Soc* 25(6):393-402

- Colice, G. L. (1994). Chest CT for known or suspected lung cancer, *Chest* 106(5):1538-50
- Cook, R. M. & Miller, Y. E. (1995). Flexible fiberoptic bronchoscopy in the diagnosis and staging of lung cancer, in Johnson EB, Johnson HD, editors. Lung cancer. New York, NY: Wiley-Lyss, p. 123- 44.
- Cordeiro, A. J. A. Robalo (1995). Pneumologia fundamental. Lisboa: Fundação Calouste Gulbenkian, p. 349-73.
- Devbhandari, M. P., Quennell, P., Krysiak, P., Shah, R. & Jones, M. T. (2008). Implications of a negative bronchoscopy on waiting times to treatment for lung cancer patients: results of a prospective tracking study, *Eur J Cardiothorac Surg* 34(3):479-83
- El-Bayoumi, E. & Silvestri, G. A. (2008). Bronchoscopy for the diagnosis and staging of lung cancer, *Semin Respir Crit Care Med* 29:261-70.
- Figueiredo, L. & Bento, M. T. (1999). Neoplasia do pulmão, in Pisco JM & Sousa LA. Noções fundamentais de imagiologia. Lisboa: Lidel-Edições Técnicas, p. 195-209.
- Gazdar, A. F. (2010). Should we continue to use the term non-small-cell lung cancer, *Ann Oncol* 21 Suppl 7:vii225-9
- George, C. J., Tazelaar, H. D., Swensen, S. J. & Ryu, J. H. (2004). Clinoradiological features of pulmonary infarctions mimicking lung cancer, *Mayo Clin Proc* 79(7):895-8.
- Govert, J. A., Dodd, L. G., Kussin, P. S. & Samuleson, W. M. (1999). A prospective comparison of fiberoptic transbronchial needle aspiration and bronchial biopsy for bronchoscopically visible lung carcinoma, *Cancer* 87(3):129-34
- Hansell, D. M., Boiselle, P. M., Goldin, J., Kauczor, H. U., Lynch, D. A., Mayo, J. R. & Patz, E. F. Jr. (2010). Thoracic Imaging, *Respirology* 15:393-400
- Harewood, G. C., Wiersema, M. J., Edell, E. S. & Liebow, M. (2002). Cost-Minimization Analysis of Alternative Diagnostic Approaches in a Modeled Patient with Non-Small Cell Lung Cancer and Subcarinal Lymphadenopathy, *Mayo Clin Proc* 77:155-164
- Henschke, C. I., Yankelevitz, D. F. & Altorki, N. K. (2007). The role of CT screening for lung cancer, *Thorac Surg Clin* 17(2):137-42
- Henschke, C. I. & I-ELCAP Investigators. (2005). CT screening for lung cancer: update 2005, *Surg Oncol Clin N Am* 14(4):761-76
- Herth, F. J. F. (2011). Bronchoscopic techniques in diagnosis and staging of lung cancer, *Breath* 7(4):325-337
- Herth, F. J. & Eberhardt, R. (2010). Flexible bronchoscopy and its role in the staging of non-small cell lung cancer, *Clin Chest Med* 31(1):87-100.
- Herth, F. J., Eberhardt, R. & Ernst, A. (2006). The future of bronchoscopy in diagnosing, staging and treatment of lung cancer, *Respiration* 73:399- 409.
- Hicks, R. J., Lau, E., Alam, N. Z. & Chen, R. Y. (2007). Imaging in the diagnosis and treatment of non-small cell lung cancer, *Respirology* 12(2):165-72
- Hollings, N. & Shaw, P. (2002). Diagnostic imaging of lung cancer, *Eur Respir J* 19:722-742
- Jamnik, S., Santoro, I. L. & Uehara, C. (2002). Comparative study of prognostic factors among longer and shorter survival patients with bronchogenic carcinoma, *J. Pneumologia* 28(5): 245 - 249.

- Jiang, F., Todd, N. W., Liu, Z., Katz, R. L. & Stass, S. A. (2009). Combined genetic analysis of sputum and computed tomography for noninvasive diagnosis of non-small-cell lung cancer, *Lung Cancer* 66(1):58-63
- Jin, F., Um, D., Chu, D., Fu, E., Xie, Y. & Liu T. (2008). Severe complications of bronchoscopy, *Respiration* 76(4):429-33
- Kamath, A. V. & Chhajer, P. N. (2006). Role of bronchoscopy in early diagnosis of lung cancer, *Indian J Chest Dis Allied Sci* 48(4):265-9
- Landreneau, R. J., Hazelrigg, S. R., et al. (1996). Video-Assisted Thoracic Surgery, In Aisner J, Arriagada R, et al, editors. *Comprehensive Textbook of Thoracic Oncology*. Baltimore : Williams & Wilkins, p. 965-979
- Laurent, F., Montaudon, M. & Corneloup, O. (2006). CT and MRI of lung cancer, *Respiration* 73:133-142.
- Madhusudhan, K. S., Gamanagatti. S., Seith, A. & Hari, S. (2007). Pulmonary infections mimicking cancer: report of four cases, *Singapore Med J* 48:e327- 31.
- Makris, D., Scherpereel, A., Leroy, S., Bouchindhomme, B., Faivre, J. B., Remy, J., Ramon, P. & Marquette, C. H. (2007). Electromagnetic navigation diagnostic bronchoscopy for small peripheral lung lesions, *Eur Resp J* 29:1187-1192
- McLoud, T. C. (2006). "A System for the Clinical Staging of Lung Cancer" – A Commentary, *AJR* 187:269-270
- Oliveira, C. & Saraiva, A. (2010). Comparative study between computed tomography and bronchoscopy in the diagnosis of lung cancer, *Radiol Bras* 43(4):229-235
- Patz, E. F. Jr. (2000). Imaging Bronchogenic Carcinoma, *Chest* 117:90S-95S
- Patz, E. F. Jr. (1999). Imaging lung cancer, *Semin Oncol* 26(5 Suppl 15):21-6
- Plekker, D., Koegelenberg, C. F. N. & Bolliger, C. T. (2010). Different techniques of bronchoscopy, *Eur Respir Mon* 48:1-17
- Popovich, J. Jr., Kvale, P. A., Eichenhorn, M. S., Radke, J. R., Ohorodnik, J. M. & Fine, G. (1982). Diagnostic accuracy of multiple biopsies from flexible fiberoptic bronchoscopy. A comparison of central versus peripheral carcinoma, *Am Rev Respir Dis* 125(5):521-3
- Read, C., Janes, S., George, J. & Spiro, S. (2006). Early Lung Cancer: screening and detection, *Prim Care Respir J* 15 (6), 332-336.
- Rivera, M. P., Detterbeck, F., Mehta, A. C. & American College of Chest Physicians. (2003). Diagnosis of lung cancer: the guidelines, *Chest* 123(1 Suppl 1):129S-36S.
- Roberts, J. R., Blum, M. G., Arildsen, R., Drinkwater, D. C. Jr., Christian, K. R., Powers, T. A. & Merrill, W. H. (1999). Prospective comparison of radiologic, thoracoscopic, and pathologic staging in patients with early non-small cell lung cancer, *Ann Thorac Surg* 68(4):1154-8
- Runciman, D. M., Shepherd, M. C. & Gaze, M. N. (1993). Lung abscesses mimicking multiple pulmonary metastases, *Clin Oncol (R Coll Radiol)* 5(5):317-8
- Sarinas, P. S., Chitkara, R. K., Rizk, N. W., Segall, G. M. & Stark, P. (1996). Imaging in lung cancer, *Curr Opin Pulm Med* 2(4):263-70
- Scagliotti, G. V., Ceppi, P., Novello, S. & Papotti, M. (2009). Chemotherapy Treatment Decisions in Advanced Non-small Cell Lung Cancer Based on Histology, *Am Soc Clin Oncol* 27:431-435

- Scagliotti, G. (2001). Symptoms, signs and staging of lung cancer, *Eur Respir Mon* 17:86–119.
- Schreiber, G. & McCrory, D. C. (2003). Performance Characteristics of Different Modalities for Diagnosis of Suspected Lung Cancer: Summary of Published Evidence, *Chest* 123:115S-128S
- Serke, M. & Schönfeld, N. (2007). Diagnosis and staging of lung cancer, *Dtsch Med Wochenschr* 132(21):1165-9
- Shaffer, K. (1997). Radiologic Evaluation in Lung Cancer: Diagnosis and Staging, *Chest* 112:235S-238S
- Shah, P. L. (2008). Flexible bronchoscopy, *Medicine* 36(39):151-154
- Shure, D. (1996). Tissue Procurement: Bronchoscopic Techniques for Lung Cancer, in: Pass HI, Mitchell JB, Johnson DH, editors, *Lung Cancer, Principles and Practice*. New York: Lippincott Williams and Wilkins, p. 471-477
- Silva, A. C, Paiva, A. C., Nunes, R. A. & Gattass, M. (2011). Informatics and Computerized Tomography Aiding Detection and Diagnosis of Solitary Lung Cancer. in, Homma N, editor. *Theory and Applications of CT Imaging and analysis*. Rijeka: In-Tech, p. 15 – 36
- Silvestri, G. A., Gould, M. K., Margolis, M. L., Tanoue, L. T., McCrory, D., Toloza, E. & Detterbeck F (2007). Noninvasive Staging of Non-small Cell Lung Cancer*: ACCP Evidenced-Based Clinical Practice Guidelines (2nd Edition), *Chest* 132:178S-201S
- Simon, M. & Simon, I. (2010). Update in bronchoscopic techniques, *Pneumologia* 59:53–6.
- Spiro, S. G., Tanner, N. T., Silvestri, G. A., Janes, S. M., Lim, E., Vansteenkiste, J. F. & Pirker, R. (2010). Lung cancer: progress in diagnosis, staging and therapy, *Respirology* 15(1):44-50
- Stinchcombe, T. E. & Socinski, M. A. (2009). Current treatments for advanced stage non-small cell lung cancer, *Proc Am Thorac Soc* 6:233–41.
- Suleman, A., Ikramullah, Q., Ahmed, F. & Khan, M. Y. (2008). Indications and Complications of Bronchoscopy. An experience of 100 cases in a tertiary care hospital, *JMPI* 22(3):210-214
- Swensen, S. J., Jett, J. R., Hartman, T. E., Midthun, D. E., Mandrekar, S. J., Hillman, S. L., Skyes, A. M., Aughenbaugh, G. L., Tatjana, Z. & Busayarat, S. (2011). Computer-aided Analyses and Interpretation of HRCT Images of the Lung, in Homma N, editor, *Theory and Applications of CT Imaging and analysis*. Rijeka: In-Tech, p. 37-62
- Thomas, P.A. (2009). Standards of surgery in lung cancer., *Rev Prat* 59(7):934-8
- Udaya, B. & Prakash, S. (1999). Advances in Bronchoscopic Procedures, *Chest* 116:1403-1408
- Yasufuku, K. (2010). Early diagnosis of lung cancer, *Clin Chest Med* 31(1):39-47
- Xiuhua, G., Tao, S., Huan, W. & Zhigang L. (2011). Prediction Models for Malignant Pulmonary Nodules Based-on Texture Features of CT Image, in Homma N, editor. *Theory and Applications of CT Imaging and Analysis*. Rijeka:In-Tech; 2011.p. 63-76
- Xu, Y., Van Beek, E. J., Hwanio, Y., Guo, J., McLennan, G. & Hoffman, E. A. (2006). Computer-aided classification of interstitial lung diseases via MDCT: 3D adaptive multiple feature method (3D AMFM), *Acad Radiol* 13(8):969-78
- Wang, T., Nelson, R. A., Bogardus, A. & Grannis, F. W. Jr. (2010). Five-year lung cancer survival: which advanced stage nonsmall cell lung cancer patients attain long-term survival, *Cancer* 116(6):1518-25

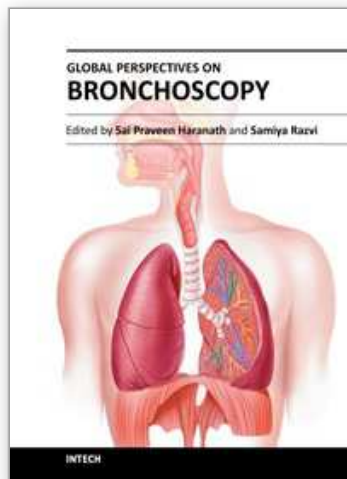
Westeel, V. (2003). Diagnosis of lung cancer, *Rev Prat* 53:727-34.

Witschi, H. (2001). A Short Story of Lung Cancer, *Toxicol Sci* 64(1):4-6

Wynants, J., Stroobants, S., Dooms, C. & Vansteenkiste, J. (2007). Staging of lung cancer, *Radiol Clin North Am* 45:609-25

IntechOpen

IntechOpen



Global Perspectives on Bronchoscopy

Edited by Dr. Sai P. Haranath

ISBN 978-953-51-0642-5

Hard cover, 240 pages

Publisher InTech

Published online 13, June, 2012

Published in print edition June, 2012

Bronchoscopy has become an essential part of modern medicine. Recent advances in technology have allowed integration of ultrasound with this tool. The use of lasers along with bronchoscopes has increased the therapeutic utility of this device. Globally an increasing number of pulmonary specialists, anaesthesiologists and thoracic surgeons are using the bronchoscope to expedite diagnosis and treatment. The current volume on bronchoscopy adds to the vast body of knowledge on this topic. The democratic online access to this body of knowledge will greatly increase the ease with which both trainees and expert bronchoscopists can learn more. The contributions from around the world cover the breadth of this field and includes cutting edge uses as well as a section on pediatric bronchoscopy. The book has been an effort by excellent authors and editors and will surely be a often reviewed addition to your digital bookshelf. In summary, this book is a great testament to the power of collaboration and is a superb resource for doctors in training, ancillary team members as well as practicing healthcare providers who have to perform or arrange for bronchoscopy or the associated procedures.

How to reference

In order to correctly reference this scholarly work, feel free to copy and paste the following:

António Saraiva and Christopher Oliveira (2012). Lung Cancer - CT Vs Bronchoscopy, Global Perspectives on Bronchoscopy, Dr. Sai P. Haranath (Ed.), ISBN: 978-953-51-0642-5, InTech, Available from:
<http://www.intechopen.com/books/global-perspectives-on-bronchoscopy/lung-pathology-ct-vs-bronchoscopy>

INTECH
open science | open minds

InTech Europe

University Campus STeP Ri
Slavka Krautzeka 83/A
51000 Rijeka, Croatia
Phone: +385 (51) 770 447
Fax: +385 (51) 686 166
www.intechopen.com

InTech China

Unit 405, Office Block, Hotel Equatorial Shanghai
No.65, Yan An Road (West), Shanghai, 200040, China
中国上海市延安西路65号上海国际贵都大饭店办公楼405单元
Phone: +86-21-62489820
Fax: +86-21-62489821

© 2012 The Author(s). Licensee IntechOpen. This is an open access article distributed under the terms of the [Creative Commons Attribution 3.0 License](#), which permits unrestricted use, distribution, and reproduction in any medium, provided the original work is properly cited.

IntechOpen

IntechOpen