

We are IntechOpen, the world's leading publisher of Open Access books Built by scientists, for scientists

5,800

Open access books available

142,000

International authors and editors

180M

Downloads

Our authors are among the

154

Countries delivered to

TOP 1%

most cited scientists

12.2%

Contributors from top 500 universities



WEB OF SCIENCE™

Selection of our books indexed in the Book Citation Index
in Web of Science™ Core Collection (BKCI)

Interested in publishing with us?
Contact book.department@intechopen.com

Numbers displayed above are based on latest data collected.
For more information visit www.intechopen.com



A Review of Tonsillectomy Techniques and Technologies

S. K. Aremu

*Federal Medical Centre, Azare, Bauchi State,
Nigeria*

1. Introduction

1.1 Anatomy

The circular band of lymphoid tissue within the pharynx consisting of the adenoids, the palatine tonsils (Figure 1), and lingual tonsils is known as Waldeyer's ring. The palatine tonsils are lymphoid tissue with prominent germinal centers and the palatine tonsils, in contrast to the lingual tonsils and adenoids, have a distinct capsule¹which separates the tonsils from the lateral pharyngeal walls. The tonsil lies within a bed of three muscles that make up the tonsillar fossa. Forming the anterior pillar is the palatoglossus muscle and the posterior pillar is the palatopharyngeus muscle, while the superior constrictor muscle makes up the bed of the fossa. Medially, the tonsil crypts lay exposed to the oropharynx with specialize stratified squamous epithelium.

The tonsils are well vascularized with the majority of the blood supply arising from the tonsillar branch of the facial artery.¹The nerve supply of the tonsils arise from the ninth cranial nerve and descending branches from the lesser palatine nerves and the tympanic branch of CN IX is thought to account for the referred ear pain found in some cases of tonsillitis. The tonsils have no afferent lymphatic vessels. Their efferent lymph drainage is through the upper cervical nodes, especially to the jugulodigastric group. Tonsils and adenoids are immunologically most active between the ages of 4 and 10 years, and tend to involutes after puberty.²

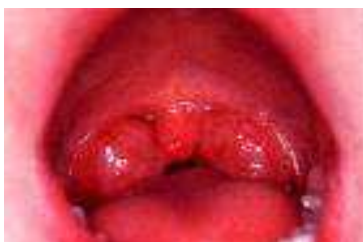

Fig. 1. Orophaynx with Palatine Tonsils.

1.2 Indications for tonsillectomy

1.2.1 Absolute³

1. Obstructive sleep apnea
2. Cardiopulmonary complications secondary to airway obstruction (e.g., cor pulmonale, alveolar hypoventilation)
3. Suspected malignancy (asymmetric Tonsillar Hypertrophy) ⁴
4. Hemorrhagic tonsillitis
5. Tonsillitis causing febrile seizures

1.2.2 Relative³

1. Recurrent acute tonsillitis meeting one or more of the following criteria:
 - Seven episodes in 1 year
 - Five episodes/year for 2 consecutive years
 - Three episodes/year for 3 consecutive years
 - Two weeks of missed school or work in 1 year
2. Chronic tonsillitis refractory to antimicrobial therapy
3. Tonsillolithiasis with associated halitosis and pain, unresponsive to conservative measures
 - Peritonsillar abscess
 - Dysphagia due to tonsillar hypertrophy.

The indications for tonsillectomy have dramatically changed and are today more clearly defined. Geographical variations in the incidence of tonsillectomy are recognized and, although most of this variation may only reflect varying attitudes between physicians, there is little doubt that geographical variations in pathology are partly responsible⁵. In adults, the most common indication is recurrent acute tonsillitis⁵. However the most common indication in children is obstructive sleep apnea. Patients with a prior history of recurrent tonsillitis and prior peritonsillar abscess may be more likely to develop another peritonsillar abscess and are candidates for tonsillectomy.

2. History

Tonsillectomy has been performed by otolaryngologists, general surgeons, family practitioners and general practitioners. However, in the past 30 years the recognition for the need of standardization of surgical technique resulted in a shift in practice patterns so that it is almost exclusively performed by the otolaryngologists.

The first known removal of tonsils dates back to the first century AD, when Cornelius Celsus in Rome used his own finger to perform it⁶. The earliest description of the procedure was by Paul of Aegina in 625. The early instruments that were used for tonsillectomy were actually first developed for removal of the uvula. Phillip Syng invented what would become the forerunner for the modern tonsillotome. Not until the mid 18th century did Caque of Rheims perform tonsillectomies on a regular basis. Since then several different techniques have been used for tonsillectomy.

However, the difficulties encountered by surgeons, especially in controlling the peri-operative bleeding, were a major drawback. It was only 1909, when Cohen adopted suture ligation of bleeding vessels to control the hemorrhage, that tonsillectomy became a common practice in hospitals⁷.

Sixty years later Haase and Noguera⁸, introduced the use of diathermy and the concept of electro-dissection was first described by Goycolea⁶ in 1982 using monopolar diathermy.¹⁰ years later Pang⁹ reported the first electro-dissection tonsillectomy using the bipolar forceps technique.

3. Preoperative evaluation

Adequate history and physical examination are essential in the preoperative diagnosis and evaluation of the patient being worked up for tonsillectomy. History alone is the most common method for diagnosing obstructive sleep apnea.¹⁰ When the diagnosis is at all in question, the child is younger than 2 years, or there is concern about the severity of the sleep apnea, a polysomnogram should be recommended.¹¹ Preoperative electrocardiogram and chest x-ray are not necessary unless there is a history of heart disease.¹² Other preoperative evaluation needs to be decided based on the medical conditions of each individual patient. For example, a child with von Willebrand disease should have the input of a hematologist regarding the use of desmopressin to minimize the risk of bleeding during the intra-operative and post-operative periods.

4. General technique

4.1 Exposure

For a successful surgery, adequate exposure, of the oro-pharynx must be achieved. Also knowledge of the relevant anatomy and tissue tension is important. With the aid of a mouth gag, e.g, Boyle -Davis (Figure 2), the oropharynx is exposed. Dentition may be protected by a plastic or rubber athletic mouth guard and careful mouth gag placement. Care is taken not to allow the lateral flanges of the tongue blade of the gag to scratch dental enamel. Protection of the mucosa from electrical and thermal conductivity is achieved by interposing a gloved finger between the instrument metal and the patient.¹³



Fig. 2. Open-sided mouth gag (Davis Mouth Gag).

4.2 Surgical procedure

The method anesthesia induction and patients' positioning is similar for most patients undergoing tonsillectomy, regardless of which technique is used to remove the tonsils. The patient is placed in the supine position and orally intubated. The endotracheal tube is taped to the patient's chin in the midline. Alternatively, some practitioners prefer to use a laryngeal mask airway.^{14,15} The bed is turned 90°-180° so that the surgeon can sit or stand at the head of the bed. The patient is positioned at the edge of the bed, and a small shoulder roll is placed. Either a Crowe-Davis, McIvor, or Dingman mouth gag is inserted and expanded to keep the mouth open for the duration of the procedure. Tissue tension during complete tonsillectomy is achieved by strong medial traction of Allis clamps and torsion of the tonsils medially (Figure 3).

The tonsils are then removed using 1 of the techniques described later.

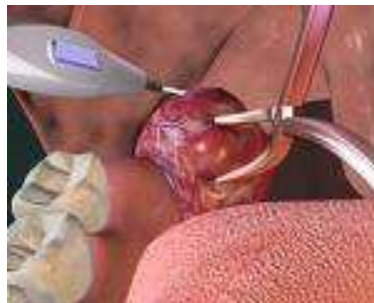

Fig. 3. Medial Traction on the Tonsil.

5. Patients and methods

50 patients (30 males, 20 females) were studied. 28(56%) had adenotonsillectomy, while 22(44%) had only tonsillectomy alone. The data was obtained by the author from three centres: University of Ilorin teaching hospital, Kwara state, IBB specialized hospital Minna, Niger state and Federal medical centre, Azare, Bauchi state.

35(70%) of the surgeries were performed using cold surgical dissection technique, while 15(30%) were done using bipolar electrocautry. All the surgeries were performed by one of two experienced surgeons. All the children were kept overnight; some were discharged the following day after they can tolerate liquid diet. Routine antibiotics and analgesics were given to all the patients.

For the 28 patients who had adenotonsillectomy, the mean operating time for the 8 bipolar electrocautries was 42.0 minutes and 47.2 minutes for the 20 cold dissection patients.

For the 22 patients who had tonsillectomy alone, the mean operating time was 31.4 minutes for the 7 bipolar electrocautries, while 34.2 minutes for the 15 cold dissections.

Complication of hemorrhage were seen in 3(6.0%) of all the patients, 2(66.7) were in cold dissection group and 1(33.3%) in bipolar electrocautry group.

6. Techniques and technologies

The techniques of Tonsillectomy can be broadly divided into 2 major categories: extracapsular (total tonsillectomy, subcapsular) and intracapsular (partial tonsillectomy). Intracapsular is also known as “subtotal,” and this procedure is referred to as tonsillotomy in some literatures. Extracapsular tonsillectomy involves dissecting lateral to the tonsil in the plane between the tonsillar capsule and the pharyngeal musculature, and the tonsil is generally removed as a single unit. Partial tonsillectomy, or tonsillotomy, involves removal of most of the tonsil, while preserving a rim of lymphoid tissue and tonsillar capsule in the most recent iteration of this older technique.¹⁶ Preservation of this margin of tissue, this “biologic dressing,” may promote an easier recovery, with lower hemorrhage rates and better recovery of diet and activity reported in comparison with traditional monopolar tonsillectomy techniques.^{17,18} The most common extracapsular techniques use a “cold” knife (sharp dissection), monopolar electrocautery, bipolar cautery (or bipolar scissors), or harmonic scalpel. Intracapsular techniques may use the microdebrider, bipolar radiofrequency ablation (which can also be used to remove the entire tonsil), and carbon dioxide laser. Either extracapsular or intracapsular tonsillectomy can be performed for the pediatric patient with obstructive sleep apnea, but only extracapsular techniques should be used for patients undergoing tonsillectomy as a result of tonsillitis or peritonsillar abscess. In addition, tonsils can be ablated using a laser or monopolar radiofrequency (somnoplasty) in a cooperative adult in a clinic setting.

7. “Cold” knife

A frequently used method for total tonsillectomy is the “cold” or sharp dissection technique. In this technique, the tonsil and capsule are dissected from surrounding tissue using scissors, knife, or tonsil dissector (Figure 4) and the inferior pole is amputated with a tonsil snare.



Fig. 4. Tonsil Dissector.

8. Harmonic scalpel

The harmonic scalpel (Figure 5) can be used to perform an extracapsular tonsillectomy (Ethicon Endo-Surgery Inc, Cincinnati, OH). It uses ultrasonic energy to vibrate its blade at 55,000 cycles per second. The vibration transfers energy to the tissue, providing simultaneous cutting and coagulation, so, typically, no additional instrument is needed for haemostasis. The components of the device include a generator, a hand piece, and a disposable blade. A high-frequency power supply provides energy to the hand piece. The blade oscillations dissect tissues by creating intra-cellular cavities as pressure waves are conducted through the tissues. The expansion and contraction of these cavities results in the lysis of cellular connections, resulting in tissue dissection.

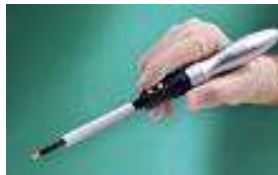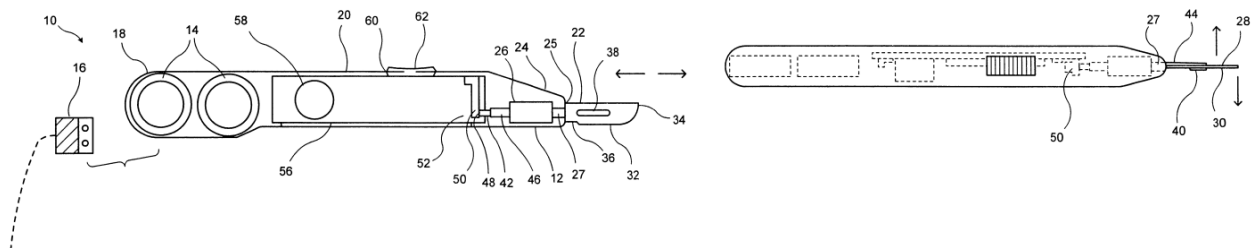


Fig. 5. Harmonic/ultrasonic scalpel.

9. Bipolar radiofrequency ablation

Bipolar radiofrequency ablation can be used to perform an extracapsular or intracapsular tonsillectomy; however, it is most commonly used to perform a partial tonsillectomy (Figure 6). The equipment includes a radiofrequency generator, foot control, saline irrigation regulator, and the coblation wand (PlasmaCare Corp, Sunnyvale, CA). During a bipolar radiofrequency ablation tonsillectomy, conductive saline solution is converted into an ionized plasma layer, resulting in molecular dissociation with minimal thermal energy transfer. Haemostasis can usually be performed with the coblation wand alone.



Fig. 6. Bipolar Probe.

10. Microdebrider tonsillectomy

This is another method for intracapsular tonsillectomy. The microdebrider is a powered rotary shaving device with continuous suction, made up of a tube, and connected to a hand piece, which, in turn, is connected to a motor with foot control and a suction device. A partial tonsillectomy is completed with the removal of approximately 90% to 95% of the tonsil, while preserving the tonsillar capsule.

11. Advantages and disadvantages of the techniques

There is great debate about the relative merits of the various tonsillectomy techniques published in many studies, with many more ongoing that compare the techniques. The existing literature consistently reports that the intracapsular (partial) techniques result in less postoperative pain, however, the degree of lessened pain continues to be much debated.^{19,20,21} In addition; there is a small risk of tonsil regrowth and the necessity for an additional procedure with the intracapsular techniques. Of the extracapsular techniques, “cold” tonsillectomy results in less postoperative pain compared with an electrocautery or “hot” tonsillectomy; however, the latter procedure is typically faster and has less intraoperative blood loss.^{22,23,24} Although not extensively researched thus far, a total tonsillectomy with the coblation unit may have slight advantages over electrocautery tonsillectomy.²⁵ The studies on outcomes of surgeries completed with the harmonic scalpel do not show any definitive advantage to the scalpel.^{26,27} It is not clear which technique, if there is one, results in the lowest rate of postoperative hemorrhage.^{28,29}

Most of the data available to date suggest that there is no difference in the bleeding rates between extracapsular and intracapsular tonsillectomy.³⁰ The equipment involved with various techniques varies in price, although the largest cost factor in any tonsillectomy is the operating time.

12. Postoperative care

A majority of children can safely be discharged home on the same day of surgery, regardless of the surgical technique used.^{10,30} Children younger than 2 years or who live far from a hospital should be kept overnight for observation. Pain medication should be recommended, and most physicians prescribe either acetaminophen or acetaminophen with codeine postoperatively.³¹ Some physicians recommend a soft diet postoperatively, others recommend “diet as tolerated.”¹⁰ In our centres we commence the child on firstly on cold ice cream and subsequently on liquid diet.

Studies have not shown any difference in recovery between children who have a restricted versus those who have non-restricted diets postoperatively.^{32,33}

13. Long-term follow-up

Typically, the patient will be seen in the office in 2 weeks, then 1 month of the tonsillectomy to confirm adequate healing, although it is also acceptable to follow-up with a phone call only.^{10,34}

14. Conclusions

Appreciation of the indications and the use of new tonsillectomy techniques and technologies, as well as an awareness of the economic ramifications of their adoption, will ultimately provide the best care for tonsillectomy patients.

15. References

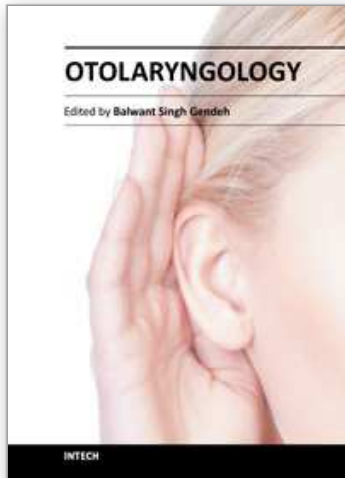
- [1] Casselbrant ML: What is wrong in chronic adenoiditis/tonsillitis anatomical considerations? *Int J Pediatr Otorhinolaryngol* 49:S133-135,1999.
- [2] Richtsmeier WJ, Shikhani AH. The physiology and immunology of the pharyngeal lymphoid tissue. *Otolaryngol Clin North Am* 20(2):219-28, May 1987.
- [3] Paradise JL: Tonsillectomy and adenoidectomy. In Bluestone CD, Stool SE, Alper CM, et al (eds): *Pediatric Otolaryngology* 4th ed. Philadelphia, W.B Saunders:1210-1222, 2002.
- [4] Hoddeson EK, Gourin CG: Adult Tonsillectomy: Current Indications and Outcomes *Otolaryngol Head Neck Surg* 140(1):19-22, Jan 2009.
- [5] B.C. Okafo. Tonsillectomy: An Appraisal of Indications in Developing Countries. *Laryngoscope* 96(5 & 6):517-522, July 1983.
- [6] J. McAuliffe-Curtain, The history of tonsil and adenoid surgery. *Otolaryngol. Clin. North Am.* 20:415-419, 1987.
- [7] H. Feldman, Two hundred year history of tonsillectomy. Images from the history of otorhinolaryngology, highlighted by instruments from the collection of the German Medical History Museum in Ingolstadt. *Laryngorhinootologie* 76:751-760, 1997.
- [8] F.R. Haase and J.T. Noguera, Hemostasis in tonsillectomy. *Arch. Otolaryngol.* 75:125, 1962.
- [9] Y.T. Pang, H. El-Hakim and M.P. Rothera, Bipolar diathermy tonsillectomy. *Clin. Otolaryngol.* 19:355-357, 1992.
- [10] Kay DJ, Mehta V, Goldsmith AJ: Perioperative adeno-tonsillectomy management in children: Current practices. *Laryngoscope* 113:592-597, 2003.
- [11] Messner AH: Evaluation of obstructive sleep apnea by polysomnography prior to pediatric adenotonsillectomy. *Arch Otolaryngol Head Neck Surg* 125:353-356, 1999.
- [12] James AL, Runciman M, Burton MJ, et al: Investigation of cardiac function in children with suspected obstructive sleep apnea. *J Otolaryngol* 32:151-154, 2003.
- [13] Shah UK: Letter to editor, "A simple suggestion to reduce perioral burns during adenotonsillectomy," in: Naura MJ et al. Perioral burns after adenotonsillectomy. *Arch Otolaryngol Head Neck Surg* 134:673, 2008.
- [14] Hatcher IS, Stack CG: Postal survey of the anaesthetic techniques used for paediatric tonsillectomy surgery. *Paediatr Anaesth* 9:311-315, 1999.

- [15] Hern JD, Jayaraj SM, Sidhu VS, et al: The laryngeal mask airway in tonsillectomy: The surgeon's perspective. *Clin Otolaryngol* 24:122-125, 1999.
- [16] Koltai PJ, Solares CA, Mascha EJ, et al: Intracapsular partial tonsillectomy for tonsil hypertrophy in children. *Laryngoscope* 112:17-19, 2002.
- [17] Solares CA, Koempel JA, Hirose K, et al: Safety and efficacy of powered intracapsular tonsillectomy in children: A multi-center retrospective case series. *Int J Pediatr Otorhinolaryngol* 69:21-26, 2005.
- [18] Schmidt R, Herzog A, Cook S, et al: Complications of tonsillectomy: A comparison of techniques. *Arch Otolaryngol Head Neck Surg* 133:925-928, 2007.
- [19] Chan KH, Friedman NR, Allen GC, et al: Randomized, controlled, multisite study of intracapsular tonsillectomy using low-temperature plasma excision. *Arch Otolaryngol Head Neck Surg* 130:1303-1307, 2004.
- [20] Chang K: Randomized controlled trial of Coblation versus electrocautery tonsillectomy. *Otolaryngol Head Neck Surg* 132:273-280, 2005.
- [21] Hall MDJ, Littlefield CPD, Birkmire-Peters DP, et al: Radiofrequency ablation versus electrocautery in tonsillectomy. *Otolaryngol Head Neck Surg* 130:300-305, 2004.
- [22] Leinbach RF, Markwell SJ, Colliver JA, et al: Hot versus cold tonsillectomy: A systematic review of the literature. *Otolaryngol Head Neck Surg* 129:360-364, 2003.
- [23] Hanasono MM, Lalakea ML, Mikulec AA, et al: Perioperative steroids in tonsillectomy using electrocautery and sharp dissection techniques. *Arch Otolaryngol Head Neck Surg* 130:917-921, 2004.
- [24] Perkins J, Dahiya R: Microdissection needle tonsillectomy and postoperative pain: A pilot study. *Arch Otolaryngol Head Neck Surg* 129:1285-1288, 2003.
- [25] Stoker KE, Don DM, Kang DR, et al: Pediatric total tonsillectomy using coblation compared to conventional electrosurgery: a prospective, controlled single-blind study. *Otolaryngol Head Neck Surg* 130:666-675, 2004.
- [26] Shinhar S, Scotch BM, Belenky W, et al: Harmonic scalpel tonsillectomy versus hot electrocautery and cold dissection: An objective comparison. *Ear Nose Throat J* 83:712-715, 2004.
- [27] Willging JP, Wiatrak B: Harmonic scalpel tonsillectomy in children: A randomized prospective study. *Otolaryngol Head Neck Surg* 128: 318-325, 2003.
- [28] O'Leary S, Vorrath J: Postoperative bleeding after diathermy hage: Cold versus hot dissection. *Otolaryngol Head Neck Surg* 131:833-836, 2004.
- [29] Lee MS, Montague ML, Hussain SS: Post-tonsillectomy hemorrhage: Cold versus hot dissection. *Otolaryngol Head Neck Surg* 131:833-836, 2004.
- [30] Mills N, Anderson BJ, Barber C, et al: Day stay pediatric tonsillectomy – A safe procedure. *Int J Pediatr Otorhinolaryngol* 68:1367-1373, 2004.
- [31] Moir MS, Bair E, Shinnick P, et al: Acetaminophen versus acetaminophen with codeine after pediatric tonsillectomy. *Laryngoscope* 110: 1824-1827, 2000.
- [32] Brodsky L, Radomski K, Gendler J: The effect of post-operative instruction on recovery after tonsillectomy and adenoidectomy. *Int J Pediatr Otorhinolaryngol* 25:133-140, 1993

- [33] Hall MD, Brodsky L: The effect of post-operative diet on recovery in the first twelve hours after tonsillectomy and adenoidectomy. *Int J Pediatric Otorhinolaryngol* 31:215-220, 1995.
- [34] RosbeKW, JonesD, JalisiS, et al: Efficacy of postoperative follow-up telephone calls for patients who underwent adenotonsillectomy. *Arch Otolaryngol Head Neck Surg* 126:718-721, 2000.

IntechOpen

IntechOpen



Otolaryngology

Edited by Prof. Balwant Singh Gendeh

ISBN 978-953-51-0624-1

Hard cover, 198 pages

Publisher InTech

Published online 23, May, 2012

Published in print edition May, 2012

This book emphasizes on different aspects of otolaryngology - the medical sciences of diagnosis and treatment of ENT disorders. "Otolaryngology" is divided into various clinical sub-specialities, namely otology, rhinology, laryngology, and head and neck. This book incorporates new developments, as well as future perspectives in otolaryngology. I would like to dedicate this book to those of you who will pick up the torch and by continued research, close clinical observation and the highest quality of clinical care, as well as by publication and selfless teaching, further advance knowledge in otolaryngology from this point forward. It is intended to be a guide to other books to follow. Otolaryngologists, researches, specialists, trainees, and general practitioners with interest in otolaryngology will find this book interesting and useful.

How to reference

In order to correctly reference this scholarly work, feel free to copy and paste the following:

S. K. Aremu (2012). A Review of Tonsillectomy Techniques and Technologies, Otolaryngology, Prof. Balwant Singh Gendeh (Ed.), ISBN: 978-953-51-0624-1, InTech, Available from:

<http://www.intechopen.com/books/otolaryngology/a-review-of-tonsillectomy-techniques-and-technologies>

INTECH
open science | open minds

InTech Europe

University Campus STeP Ri
Slavka Krautzeka 83/A
51000 Rijeka, Croatia
Phone: +385 (51) 770 447
Fax: +385 (51) 686 166
www.intechopen.com

InTech China

Unit 405, Office Block, Hotel Equatorial Shanghai
No.65, Yan An Road (West), Shanghai, 200040, China
中国上海市延安西路65号上海国际贵都大饭店办公楼405单元
Phone: +86-21-62489820
Fax: +86-21-62489821

© 2012 The Author(s). Licensee IntechOpen. This is an open access article distributed under the terms of the [Creative Commons Attribution 3.0 License](#), which permits unrestricted use, distribution, and reproduction in any medium, provided the original work is properly cited.

IntechOpen

IntechOpen