

We are IntechOpen, the world's leading publisher of Open Access books Built by scientists, for scientists

5,300

Open access books available

132,000

International authors and editors

160M

Downloads

Our authors are among the

154

Countries delivered to

TOP 1%

most cited scientists

12.2%

Contributors from top 500 universities



WEB OF SCIENCE™

Selection of our books indexed in the Book Citation Index
in Web of Science™ Core Collection (BKCI)

Interested in publishing with us?
Contact book.department@intechopen.com

Numbers displayed above are based on latest data collected.
For more information visit www.intechopen.com



Acetabular Augmentation by Residual Hip Dysplasia

Borut Pompe and Vane Antolič

*Department of Orthopaedic Surgery, University Medical Centre Ljubljana,
Slovenia*

1. Introduction

Residual hip dysplasia is one of the most common causes of secondary osteoarthritis of the hip joint. It is suggested that excessive hip joint contact stress due to small weight-bearing area is an important precipitating factor for the development of hip arthrosis (Hadley et al., 1990; Hipp et al., 1999; Maxian et al., 1995). Dysplasia of the hip refers to mechanical deformations and deviations in the size and shape or mutual proportions between the upper part of the femur and acetabulum (Durnin et al., 1991). The dysplastic hips are diagnosed according to anatomical changes in the hip that are visible in the radiographs (Durnin et al., 1991; Legal 1987; Pauwels, 1976). Usually, the center-edge angle of Wiberg (ϑ_{CE}) is used as the main radiographic parameter for the assessment of the hip dysplasia (Legal 1987; Pauwels, 1976). The range of ϑ_{CE} from 20–25° is considered as the lower limit for normal hips, while the value of ϑ_{CE} below 20° is pathognomonic for the hip dysplasia (Legal 1987). The size of the angle ϑ_{CE} correlates with the size of the weight bearing area and may therefore serve as an indirect measure of the hip joint contact stress (Brinckmann et al., 1981; Hipp, 1999; Iglic et al., 1993; Kummer 1988; Malvitz & Weinstein, 1994). However, it was suggested that besides ϑ_{CE} other geometrical parameters such as the radius of the femoral head (Brinckmann et al., 1981; Legal 1987) or the pelvic shape (Iglic et al., 1993, 2001; Kersnic et al., 1997) should be taken into account in assessment of the contact stress distribution. Therefore, the direct calculation of the contact stress in the hip joint has been introduced in the assessment of the biomechanical status of the hip (Brinckmann et al., 1981; Kummer, 1991; Legal 1987; Vengust, 2001) (Fig.1).

Dysplastic hips in adults are treated by redirection (Ganz et al. 1988; Salter et al. 1984; Steel, 1973; Sutherland & Greenfield 1977) and periarticular osteotomies of the acetabulum (Pemberton, 1965), as well as by Chiari osteotomy (Chiari, 1953) and by extraarticular augmentation of the acetabular roof (Staheli, 1981), consisting of interposition of the joint capsule between the femoral head and the reconstructed acetabular roof. The aim of these procedures is to relieve pain and to postpone the development of hip arthrosis.

The slotted acetabular augmentation (SAA), described by Staheli, is designed to treat mildly or severely dysplastic hips (Staheli, 1981). SAA seems to be a safer technique than complex redirection and periarticular acetabular osteotomies (Staheli, 1991). In SAA, the acetabular roof is extended laterally, posteriorly and anteriorly by the grafts harvested from the ilium

and placed into the slot above the acetabulum in the radial and tangential directions. Grafts are held in place by an elongated reflected tendon of the rectus femoris muscle. No pin fixation is required. After the operation, patients are immobilised in a single hip spica cast for six weeks (Staheli, 1981). SAA is a well-established technique for the treatment of children and adolescents with hip dysplasia. It has not been widely accepted for treating hip dysplasia in adults although good outcomes have been reported with other augmentation techniques in adults.

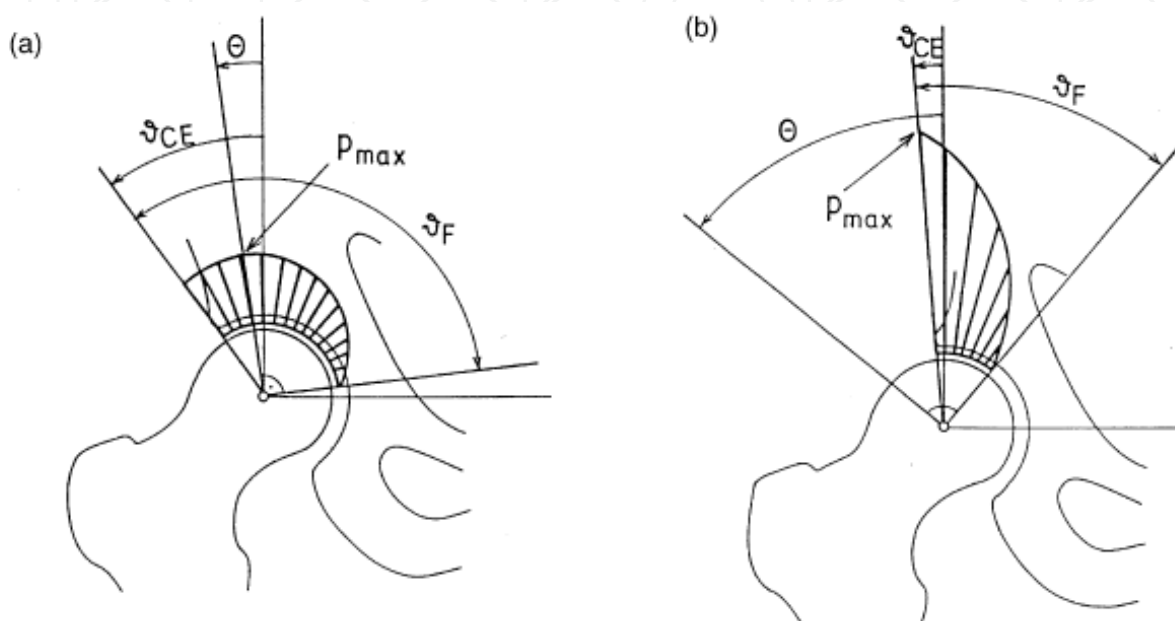


Fig. 1. Schematic presentation of the contact stress distribution in the normal (a) and dysplastic hip joint (b). The center-edge angle (ϑ_{CE}), the coordinate of the pole of stress distribution (θ), the functional angle of the weight bearing area (ϑ_F) and the location of the peak contact stress (p_{max}) are shown.

The purpose of this article was to review our early results of SAA done for residual hip dysplasia in adults. Preoperative values of the centre-edge angle of Wiberg, peak stress on the weight-bearing area of the hip and clinical Harris Hip Score were compared with the values determined at the latest follow-up. The joint-space width was used as an indicator of cartilage degeneration. The level of patient satisfaction was determined.

2. Patients and methods

Between 1997 and 2005, 14 consecutive patients underwent SAA for hip dysplasia. The study included 12 patients undergoing 14 SAAs for residual hip dysplasia; two patients were lost to follow-up and were excluded from the study. All our patients were women, who had a median age of 38.5 (17–42) years at the time of operation. Two of them were operated on bilaterally. All the operated hips showed spherical congruency and had been painful for an average of 4 years before the procedure. Based on the classification system of the Commission for the study of hip dysplasia of the German Society for Orthopaedics and Thraumatology (Tönnis et al., 1985) hips are classified according to the age of the patient and the ϑ_{CE} into the following four grades: grade 1—normal hips with the ϑ_{CE} equal to or

greater than 30° ; grade 2—mildly pathological hips with the angle equal to or greater than 20° and less than 30° ; grade 3—moderately pathological hips with the ϑ_{CE} equal to or greater than 5° and less than 20° ; and grade 4—extremely pathological hips with the ϑ_{CE} of less than 5° . All hips evaluated in our study had a ϑ_{CE} of less than 30° , thereby meeting the criteria for hip dysplasia. Preoperatively, two hips were grade 2, eight hips grade 3 and four hips grade 4. None of the hip was subluxated or dislocated before the surgery. The median follow-up period was 4 (1–8) years after surgery.

2.1 Preoperative planning

Previous studies found that in dysplastic conditions where ϑ_{CE} is small or negative, hip joint contact stress is higher than in hips with a larger ϑ_{CE} ; however, stress can also be higher due to a higher or a too vertical resultant hip joint force (Iglič et al., 1993a; Ipavec et al., 1999; Genda et al., 2001). The direction and magnitude of the resultant hip joint force \mathbf{R} depends, among other factors, on the femoral and pelvic geometry (Brand, 1997; Iglič et al., 1993b). It has been suggested that a computer model could be useful for guiding clinical decision-making to determine optimal treatment (Genda et al., 2001; Hsin et al., 1996; Michaeli et al., 1997). The influence of both the ϑ_{CE} and \mathbf{R} are expressed by the contact stress distribution. Some recent studies indicate that the distribution of the contact stress is the most important biomechanical parameter for predicting successful hip development (Pompe et al., 2003).

Peak contact stress in the weight bearing area of the hip (p_{max}) was calculated using a computer program, HIPSTRESS (Iglič & Kralj-Iglič, 1999; Iglič et al., 2002). The program consists of two procedures. First, the hip joint resultant force \mathbf{R} transmitted from the acetabulum to the femur is determined by a three-dimensional biomechanical model of the human hip (Iglič et al., 2002). This model is based on solving of the static equilibrium equations for the forces and torques acting on the pelvis and the loaded leg in the one-legged stance (Iglič et al., 1993b, 2002). In the one-legged stance the activity of the hip abductor muscles is necessary to maintain the balance of the pelvis. In our model, nine effective muscles are included (Iglič et al., 1993b, 2002). It is assumed that the force of the individual muscle acts in the straight line connecting the attachment point of the muscle on the pelvis to the attachment point on the femur. The individual variations in the femoral and pelvic geometry influence the directions of the muscle forces as well as the radius vectors of the application points of the muscle forces on the pelvis and femur. Therefore the geometry of the hip should be adapted for each patient individually according to the data determined from standard anteroposterior radiographs (Daniel et al., 2001; Iglič et al., 2001, Vengust et al., 2001; Zupanc et al., 2001). The input geometrical parameters of the model for determination of \mathbf{R} are shown in the Fig. 2.

It was shown that the resultant hip joint force \mathbf{R} determined in one-legged stance lies nearly in the frontal plane of the body (Iglič et al., 1993b, 2002). Therefore in the second mathematical model for determination of the contact stress distribution (Daniel et al., 2001; Iglič et al., 2002) the force \mathbf{R} is assumed to lie in the frontal plane. The hip joint reaction force in the frontal plane can be expressed by its magnitude (R) and by its inclination in the frontal plane with respect to the vertical plane ϑ_R (Fig. 2). The angle ϑ_R is taken to be positive in the medial direction from the vertical axis and negative in the lateral direction from the vertical axis (Daniel et al., 2001; Iglič et al., 1993a).

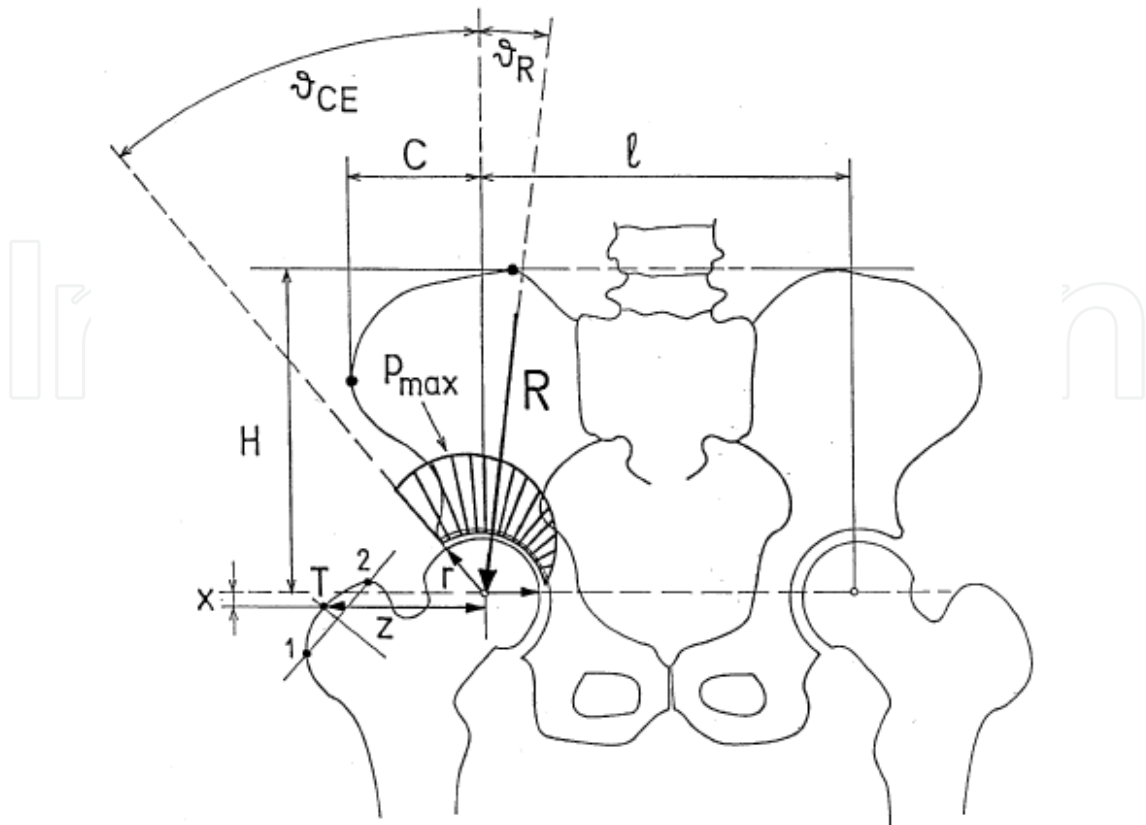


Fig. 2. The geometrical parameters used for determining the resultant hip force (R) include: interhip distance (l), pelvic height (H), pelvic width (C) and coordinates of the muscle attachment point (T), on the greater trochanter (z and x) and the centre-edge angle of Wiberg (θ_{CE})

In the second step the mathematical model for calculation of the stress distribution in the hip joint (Daniel et al., 2001; Iglič et al., 2002; Ipavec et al., 1999) is used. The model assumes the non-uniform distribution of the contact stress (Ipavec et al., 1999). Area of the hip where stress differs from zero is called the weight-bearing area. The size of the weight-bearing area and distribution of the contact stress are not fixed but depend on the load and geometry of the hip (Ipavec et al., 1999). The basic idea of the model is described below.

Besides the magnitude of the resultant hip force R and inclination of the resultant hip force θ_R the input parameters of the mathematical model for calculation of the hip joint contact stress are also the center-edge θ_{CE} and the radius of the femoral head r (Fig.2). The θ_{CE} is taken to be positive in the lateral direction from the vertical axis and negative in the medial direction from the vertical axis (Fig. 2).

Within the model of stress distribution the contact stress at any point of the weight-bearing area (p) is taken to be proportional to strain in the cartilage layer. The cartilage fills in the cleft between the femoral head and the acetabulum. It is assumed that the femoral head has spherical shape and acetabulum is the portion of the sphere, symmetric with respect to the frontal plane.

After loading there is one point where the spherical surfaces of the acetabulum and the femoral head are the closest. Due to symmetry of the articular surfaces with respect to the

frontal plane and due to position of the hip joint reaction force in the frontal plane this point lies in the frontal plane and is called the stress pole (Ipavec et al., 1999). Position of the stress pole can be determined by the spherical coordinate θ (Brinckmann et al., 1981; Ipavec et al., 1999) which is angular displacement of the pole from the vertical axis in the frontal plane. θ is positive in the lateral direction and negative in the medial direction from the vertical axis as well as ϑ_{CE} . The above assumptions lead to the cosine dependency of the contact stress distribution in the hip joint (Brinckmann et al., 1981). The lateral border of the weight-bearing area is determined by the acetabular geometry while the medial border is determined as the curve where stress vanishes.

In the case of dysplastic hips (usually with small ϑ_{CE}) the stress pole lies outside the weight bearing area, therefore the peak contact stress is located at the point of the weight bearing surface which is closest to the pole, i.e. at the lateral acetabular rim. For small ϑ_{CE} the contact stress distribution is highly nonuniform all over the weight bearing area.

The peak stress on the weight-bearing area of the hip was determined before the operation and at the latest follow-up. The Harris Hip Score was calculated preoperatively and at the latest follow-up. The joint-space width was measured in line with the centre of the femoral head. Patient satisfaction with the results of SAA was graded as very satisfied, satisfied and not satisfied. The paired Student's *t*-test was used to detect differences between preoperative and followup values. The level of significance was set at 5%.

2.2 Surgical technique

All patients were treated by the same operative technique (Staheli, 1991) performed by the second author (V.A.). The median surgical time was 120 min (90-180). The patients were operated on lying supine on a standard operating table. A Smith- Petersen approach was used to expose the hip joint. The sartorius attachment was detached. It was important to avoid lateral femoral cutaneous nerve damage. A tendon of the reflected head of the rectus femoris was divided as posteriorly as possible, and prepared for a Z-shaped elongation. A slot in the subchondral bone at the acetabular margin was made by drilling 1-cm holes into the acetabular margin. It was important to drill the holes as close to the joint capsule as possible. The holes were joined with a narrow rongeur (Fig 3).

Autologous bone grafts harvested from the ipsilateral pelvic wing were used for additional coverage of the femoral head. The grafts were rectangular in shape, approximately 1 cm wide, 2 to 5 cm long and up to 1 cm thick, with cortical bone on one side and cancellous bone on the other (Fig. 4).

In the layer above the femoral head, the grafts were placed in the acetabular slot with the cortical side down. The graft should be placed in the acetabular slot as press fit as possible. A part of the graft which is not in the acetabular slot should lie on the joint capsule and form a new acetabular roof. The size of the graft should be measured precisely by planning the operation to avoid the acetabular roof overcorrection. The next layer of grafts is perpendicular to the first layer and it lies in the tangential direction to the acetabulum (Fig. 5).

The two layers of the graft were secured by suturing the tendon back in its original position. The uppermost layer consisted of irregular bone chips which were "hammered" in place. When viewed from the side, the uppermost layer was triangular in shape, with the base on the tangential layer providing additional mechanical support to the first two layers (Fig. 6).

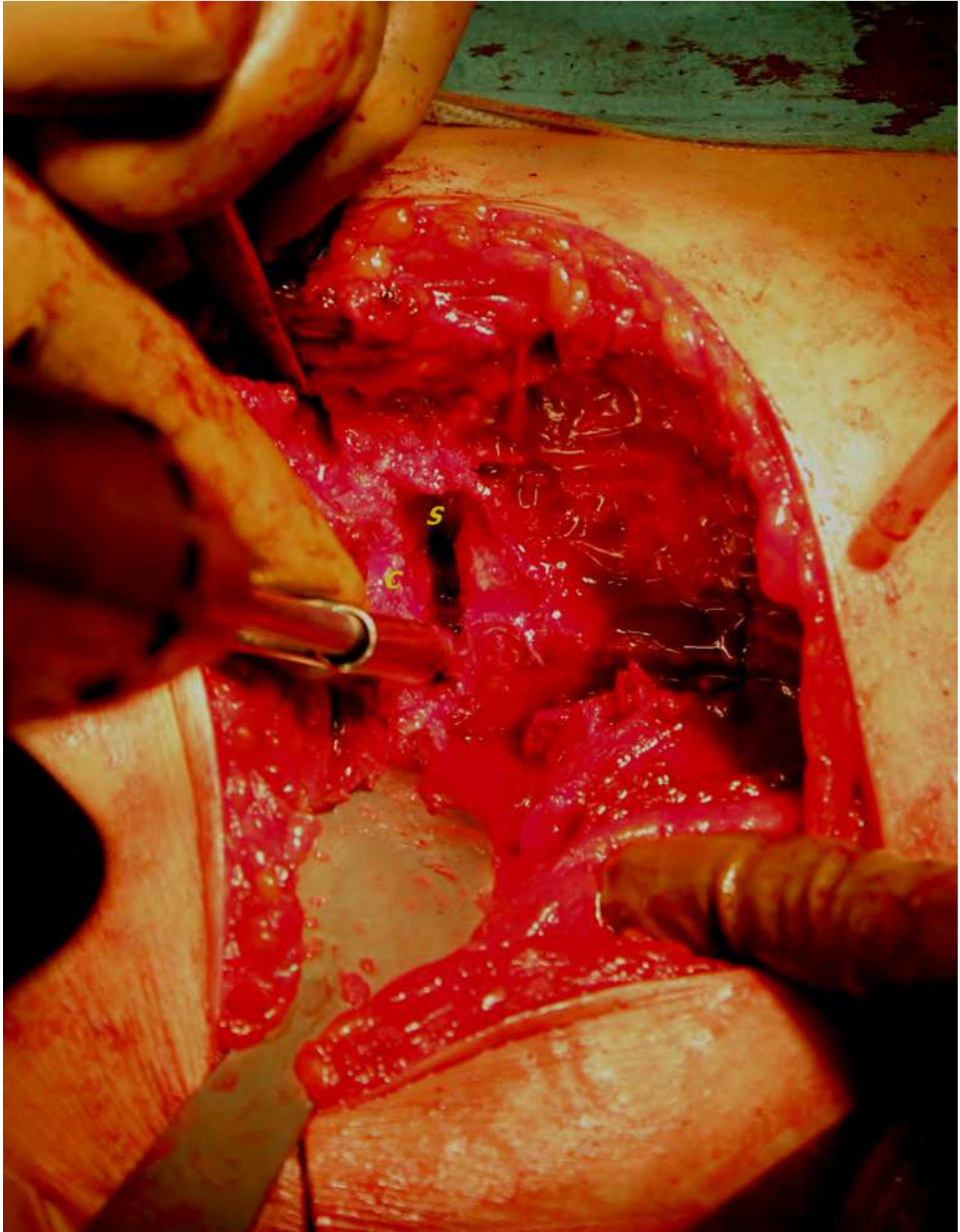


Fig. 3. Drilling the slot into acetabular margin (S) as close to the joint capsule (C) as possible

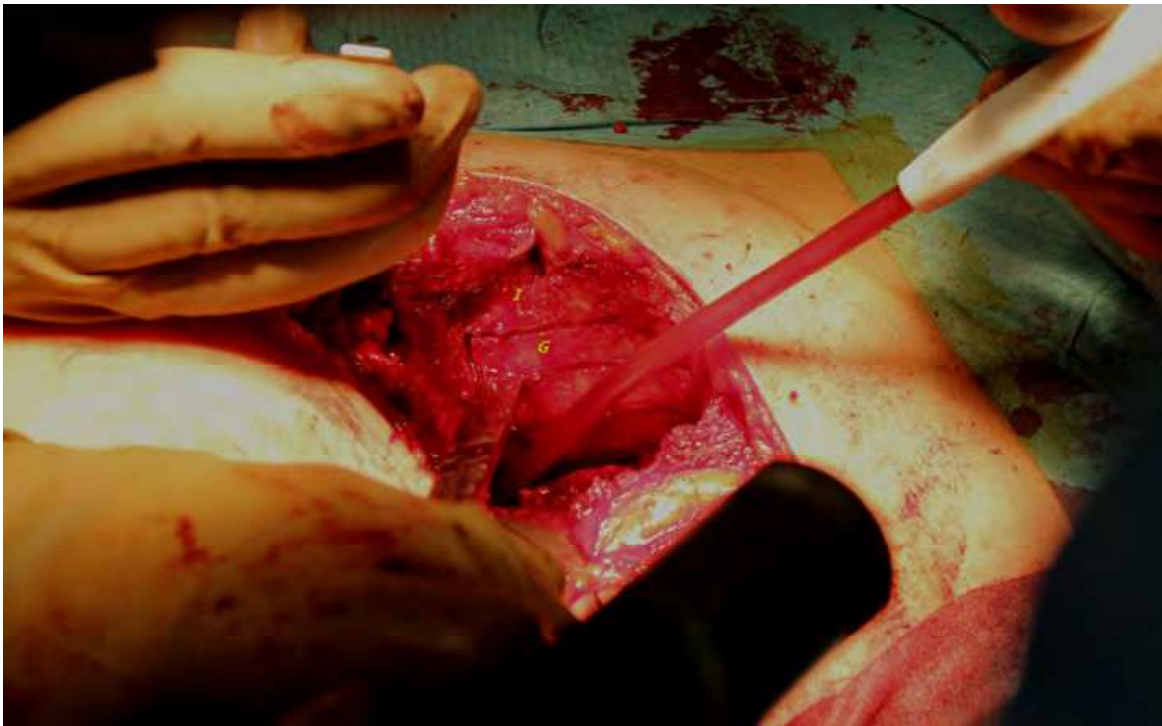


Fig. 4. The preparation of grafts (G) from the os ileum (I)

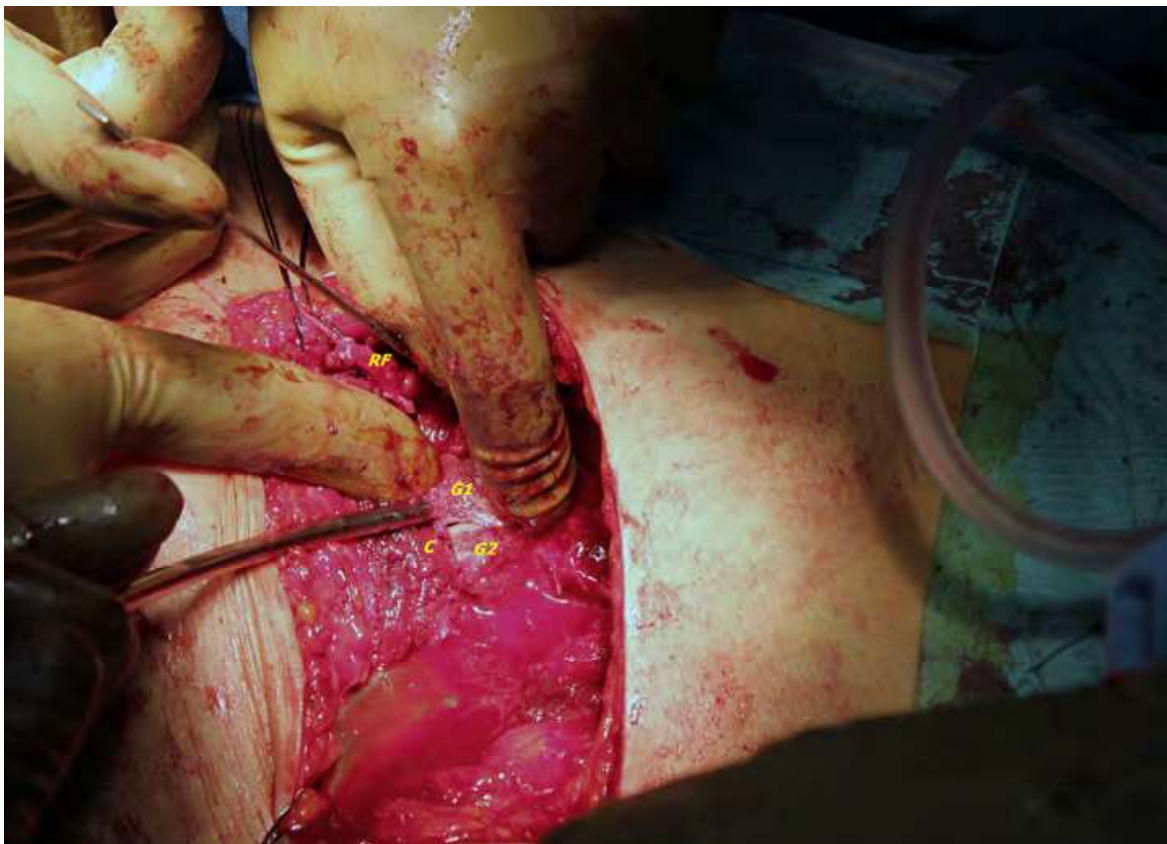

Fig. 5. Inserting the grafts into the slot. RF: Anterior part of the reflected head of the rectus femoris prepared for a Z-shaped elongation, G1: Insertio of the graft, G2: Inserted graft, C: Joint capsula

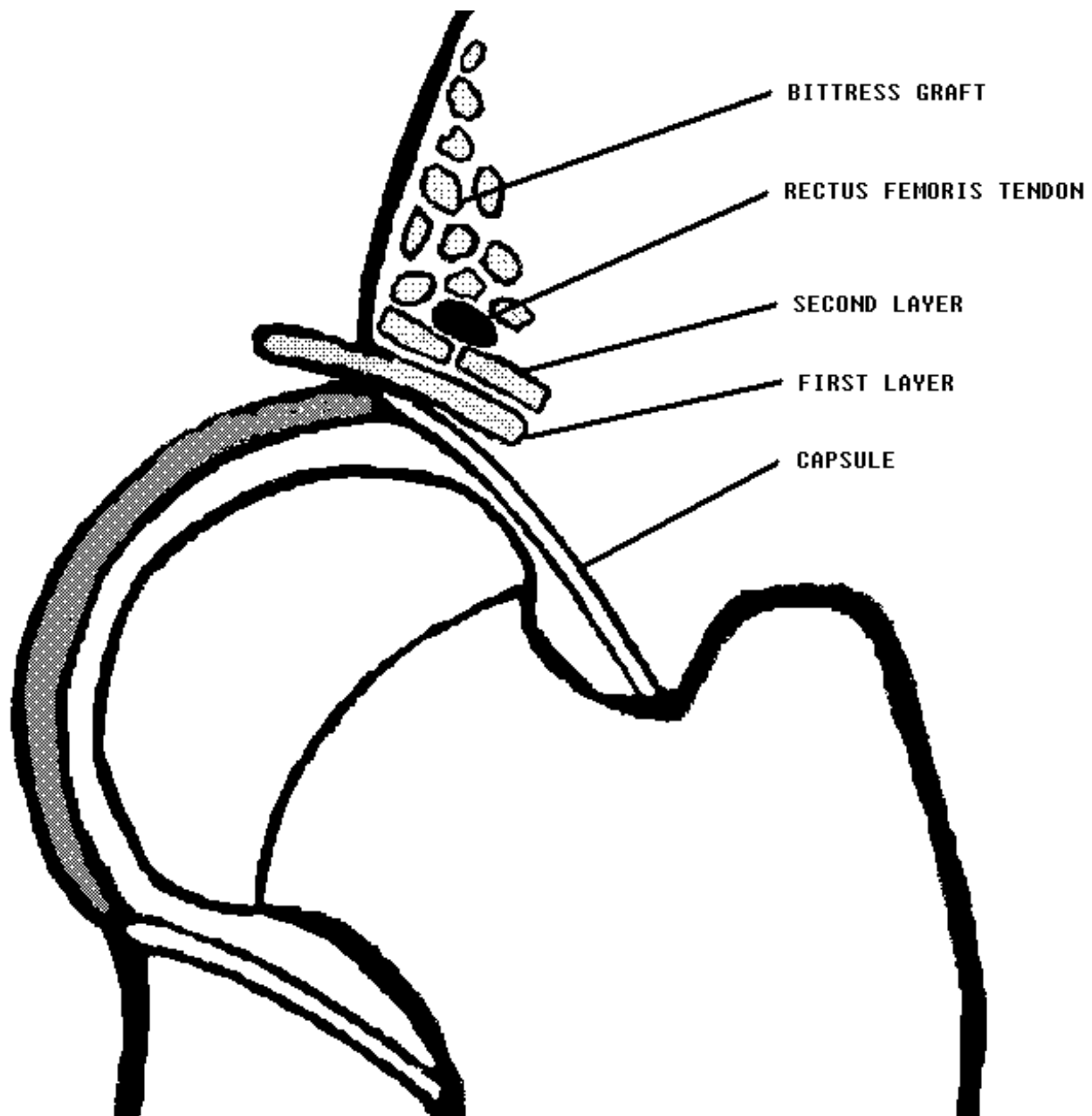


Fig. 6. The slotted acetabular augmentation operative technique.

2.3 Postoperative treatment

A single hip spica cast was applied with the hip in 15 degrees of abduction, 20 degrees of flexion and in neutral rotation position. The median hospital stay was ten days (6-17). After six weeks the cast was removed and the patients started passive and active range of motion exercises. No weight bearing was permitted for six weeks postoperatively. After removal of the cast, the patients were allowed to bear 1/5 of body weight on the affected extremity for next three months.

Radiographs were taken prior to surgery (Fig. 7) and at the latest follow-up (Fig. 8); a 10 % magnification rate was taken into account.

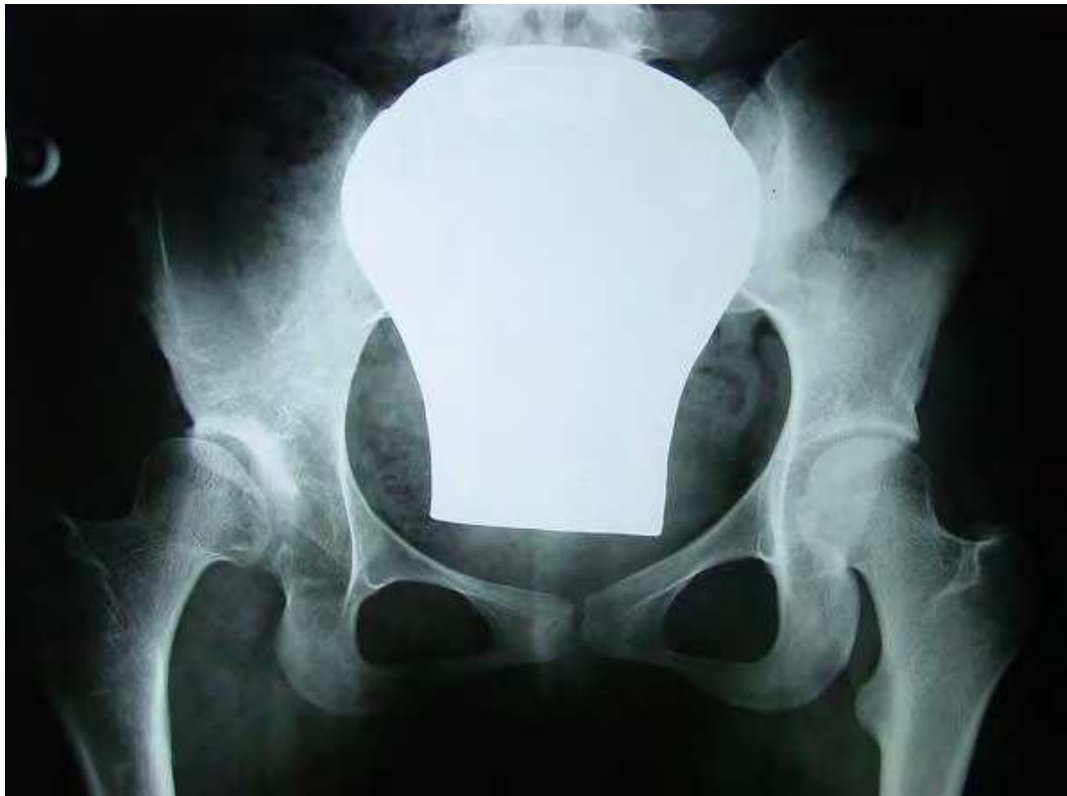

Fig. 7. Radiographs of a 19-year-old woman with the Wiberg angle of 1° on the right, taken before the operation.

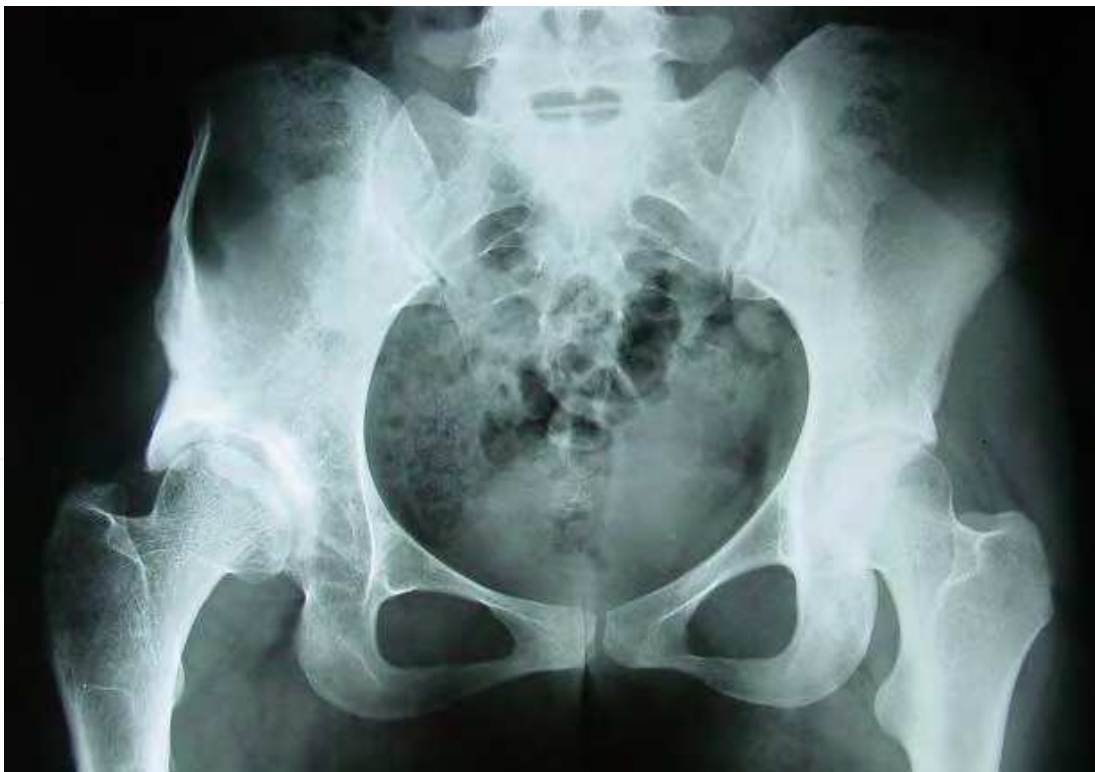

Fig. 8. Radiographs of the same woman 4 years after the slotted acetabular augmentation. The Wiberg angle increased to 42°.

3. Results

Table 1 shows the median preoperative and follow-up values and the ranges for the centre-edge angle of Wiberg, peak stress on the hip weight-bearing area and the clinical Harris Hip Score. Statistically significant differences were found between preoperative and follow-up values of the centre-edge angle, peak stress on the hip weight-bearing area and Harris Hip Score ($p < 0.001$).

	ϑ_{CE} (degrees)	P_{max} (MPa)	HHS (points)
<i>PREOPERATIVE</i>	9	14,9	60
	min. 1; max. 26	min. 6,3; max. 28,1	min. 45; max. 98
<i>AT FOLLOW-UP</i>	43	4,1	93
	min. 31; max. 55	min. 3; max. 6,1	min. 49; max. 100

Table 1. Median values and ranges before the operation and at the latest follow-up. ϑ_{CE} ; centre-edge angle of Wiberg, P_{max} ; peak stress on the weight bearing area of the hip, HHS; Harris Hip Score. The differences between preoperative and at follow-up values are highly significant ($P < 0.001$).

The median joint-space width was 5 (3-9) mm prior to surgery, and 4 (2-6) mm at the latest follow-up. The difference was not statistically significant ($p = 0.2$).

Postoperatively, all patients experienced less pain in performing activities of daily living. Complete pain relief was reported by three patients (four SAAs), and less pain in performing activities of daily living by eight patients (nine SAAs). Pain experienced postoperatively by one patient (one SAA) was due to retrotrochanteric bursitis and was relieved after an injection. Six patients (eight SAAs) were very satisfied, and six patients (six SAAs) were satisfied with the outcome. None of the patients reported dissatisfaction with the procedure.

4. Discussion

From 1987 to 1995, the Bernese periacetabular osteotomy was the preferred method for the treatment of residual congruent dysplastic hips at this Department (Kralj et al., 2005). Since 1997, SAA has been used in the treatment of adult females with residual dysplasia of the hip demonstrating spherical congruency, although the technique was originally indicated for the treatment hips with aspherical congruence in children and adolescents (Staheli 1981; Staheli & Chew, 1992). There were no male patients with residual hip dysplasia in our series.

In this study the classification system of the Commission for the study of hip dysplasia of the German Society for Orthopaedics and Traumatology was used (Tönnis et al., 1985). Their evaluation scheme is based on the grades of deviation from normal. All hips evaluated in our study had a ϑ_{CE} of less than 30° , thereby meeting the criteria for hip dysplasia. Preoperatively, two hips were grade 2, eight hips grade 3 and four hips grade 4. After the operation, all hips were grade 1. In two patients (three hips) a decreased range of motion in flexion and in abduction was found after the operation, which may be due to overcorrection of the acetabular roof with the consequential femoroacetabular impingement. This poor outcome can be attributed to an avoidable mistake. The aim of the operation is to increase the angle of Wiberg and we should avoid acetabular overcoverage exceeding 40° .

The tendon suturing over the grafts, and spica cast immobilisation seem to afford adequate immobilisation as indicated by the absence of radiographic graft displacement, and good graft incorporation and remodelling. The cast was well tolerated by the patients. Lengthy immobilisation in a spica cast appears to be a major drawback of the SAA technique compared with redirection and periarticular acetabular osteotomies, which in the majority of cases require no spica cast immobilisation. No complications related to internal osteosynthesis are to be expected in the SAA patients. Moreover, SAA requires no osteotomy, which tends to be the main source of complications in redirection and periarticular acetabular osteotomies, such as nerve palsy, pseudarthrosis, pain, intraarticular fracture and iatrogenic worsening of arthrosis, necessitating total hip replacement (Staheli, 1991).

In SAA, the capsule under the bony shelf is supposed to undergo metaplasia into the fibrocartilage (Moll, 1982). No significant changes of the joint-space width medial to the shelf, i.e. the original acetabular roof, were noted in our study, which suggests that no significant joint cartilage degeneration occurred during the follow-up period. Reduction in the median peak stress on the hip weight-bearing area was obtained in SAA and Bernese osteotomy with the use of the above described mathematical model (Daniel et al., 2001; Iglič & Kralj-Iglič, 1999; Iglič et al., 2002). The greatest influence on the peak stress is exerted by the radius of the femoral head, followed by the interhip distance, the position of the attachment point of the muscles on the greater trochanter and the pelvic height and width. Furthermore, the method has proved to be clinically relevant for evaluating the long-term clinical status of hips after osteotomies for aseptic necrosis of the femoral head (Dolinar et al., 2003) and after Bernese osteotomy (Kralj et al., 2005). This method has also been used to analyse the effect of the Salter innominate osteotomy (Vengust et al., 2001), and the Imhauser and Dunn-Fish operations for severe slipped capital femoral epiphysis (Zupanc et al., 2001).

In SAA and in Bernese osteotomy it was assumed that additional femoral head coverage was round (Iglič et al., 1993a). The postoperative values decreased to the level observed in healthy adult hips (Mavčič et al., 2002). SAA is therefore considered to be an adequate alternative to the redirection and periarticular osteotomies of the acetabulum. No reports on the SAA treatment of hip dysplasia in adults have yet been published, but good outcomes have been reported with other augmentation techniques in adults (Courtois et al., 1987; Love et al., 1980; Migaud et al., 2004). The severity of preoperative arthrosis and the congruency have been identified as the main factors impairing survivorship in these patients (Fawzy et al., 2005).

We believe that with small number of patients with residual dysplasia the simplicity and safety of the SAA technique outweigh the advantages of the relatively highrisk Bernese periacetabular osteotomy.

5. Conclusion

In our series, the procedure has proved reliable and safe. Its advantages include symptomatic pain relief, adequate acetabular roof coverage and reduced peak stress on the weight bearing area of the hip. It can be used to postpone the development of hip arthrosis in adults with acetabular dysplasia.

6. Acknowledgements

The authors thank Veronika Kralj-Iglič, Aleš Iglič, Blaž Mavčič and other creators of the computer program HIPSTRES. The computer programs HIPSTRESS can be obtained from the web page <http://physics.fe.uni-lj.si> free of charge in order to use them for scientific purposes.

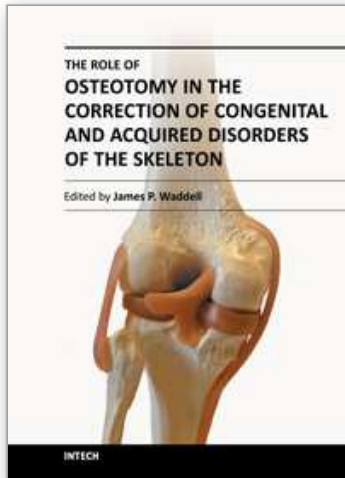
7. References

- Armand M, Lepistö J, Tallroth K. Outcome of periacetabular osteotomy: joint contact pressure calculation using standing AP radiographs, 12 patients followed for average 2 years. *Acta Orthop*, 2005; 76: 303–13
- Brinckmann P, Frobin W, Hierholzer E. Stress on the articular surface of the hip joint in healthy adults and persons with idiopathic osteoarthritis of the hip joint. *J Biomech* 1981;14:149–56
- Chiari K (1953) Beckenosteotomie zur Pfannendachplastik. *Wien Med Wochenschr* 103(38):707–714
- Courtois B, Le Saout J, Lefevre C, Kerboul B, Robin L, Miroux D, Lagdani R (1987) The shelf operation for painful acetabular dysplasia in adults. A continuous series of 230 cases. *Int Orthop* 11(1):5–11
- Daniel M, Antolič V, Iglič A, Kralj-Iglič V (2001) Determination of contact hip stress from nomograms based on mathematical model. *Med Eng Phys* 23(5):347–357
- Dolar D, Antolič V, Herman S, Iglič A, Kralj-Iglič V, Pavlovčič V (2003) Influence of contact hip stress on the outcome of surgical treatment of hips affected by avascular necrosis. *Arch Orthop Trauma Surg* 123:509–513
- Durnin CW, Ganz R, Klaue K. The acetabular rim syndrome—a clinical presentation of dysplasia of the hip. *J Bone Joint Surg* 1991;73B:423–9
- Fawzy E, Mandellos G, De Steger R, McLardy-Smith P, Benson MKD, Murray D (2005) Is there a place for shelf acetabuloplasty in the management of adult acetabular dysplasia? A survivorship study. *J Bone Joint Surg (Br)* 87(9):1197–1202
- Genda E, Iwasaki N, Li G. Normal hip joint contact pressure distribution in single-leg standing – effect of gender and anatomic parameters. *J Biomech*, 2001; 34: 895–905
- Ganz R, Klaue K, Vinh TS, Mast JW (1988) A new periacetabular osteotomy for the treatment of hip dysplasia. Technique and preliminary results. *Clin Orthop* 232:26–36

- Hadley NA, Brown TD, Weinstein SL (1990) The effect of contact pressure elevations and aseptic necrosis on the long-term clinical outcome of congenital hip dislocation. *J Orthop Res* 8(4):504–513
- Hipp JA, Sugano N, Millis MB, Murphy SB (1999) Planning acetabular redirection osteotomies based on joint contact pressures. *Clin Orthop Rel Res* 364:134–143
- Hsin J, Saluja R, Eilert RE. Evaluation of the biomechanics of the hip following a triple osteotomy of the innominate bone. *J Bone Joint Surg Am*, 1996; 78: 855–62
- Iglič A, Srakar F, Antolič V. Influence of the pelvic shape on the biomechanical status of the hip. *Clin. Biomech.* 1993b;8:233–4.
- Iglič A, Daniel M, Kralj-Iglič V, Antolič V, Jaklič A. Peak hip joint contact stress in male and female population. *J. Musculoskeletal Res.* 2001;5:17–21
- Iglič A, Kralj Iglič V, Antolič V, Srakar F, Stanič U (1993a) Effect of the periacetabular osteotomy on the stress on the human hip joint articular surface. *IEEE Trans Rehabil Eng* 1:207–212
- Iglič A, Kralj-Iglič V (1999) Computer system for determination of hip joint contact stress distribution from antero-posterior pelvic radiograph. *Radiol Oncol* 33:263–266
- Iglič A, Kralj-Iglič V, Daniel M, Maček-Lebar A (2002) Computer determination of contact stress distribution and size of weight bearing area in the human hip joint. *Comput Methods Biomech Biomed Eng* 5(2):185–192
- Ipavec M, Brand RA, Pederson DR, Mavčič B, Kralj-Iglič V, Iglič A (1999) Mathematical modelling of stress in the hip during gait. *J Biomech* 32:1229–1235
- Kersnič B, Iglič A, Kralj-Iglič V, Srakar F, Antolič V. Increased incidence of arthrosis in women could be related to femoral and pelvic shape. *Arch. Orthop. Trauma Surg.* 1997;116:345–7
- Kralj M, Mavčič B, Antolič V, Iglič A, Kralj-Iglič V (2005) The Bernese periacetabular osteotomy: clinical, radiographic and mechanical 7–15-year follow-up of 26 hips. *Acta Orthop* 76(6):833–840
- Kummer B. Biomechanischer Aspekt der Luxationshüfte. *Orthopadie* 1988;17:452–62
- Kummer B. Die klinische Relevanz biomechanischer Analysen der Hüftregion. *Z. Orthop.* 1991;129:285–94.
- Legal H. Introduction to the biomechanics of the hip. In: Tonnis D, editor. *Congenital dysplasia and dislocation of the hip*. Berlin: Springer-Verlag; 1987. p. 26–57
- Li G, Sakamoto M, Chao EYC: A comparison of different methods in predicting static pressure distribution in articulating joints. *J Biomech*, 1997; 30: 635–38
- Love BR, Stevens PM, Williams PF (1980) A long-term review of shelf arthroplasty. *J Bone Joint Surg (Br)* 62(3):321–325
- Malvitz TA, Weinstein SL. Closed reduction of congenital dysplasia of the hip. *J. Bone Joint Surg.* 1994;76A:1777–91
- Mavčič B, Pompe B, Antolič V, Daniel M, Iglič A, Kralj-Iglič V (2002) Mathematical estimation of stress distribution in normal and dysplastic human hips. *J Orthop Res* 20(5):1025–1030
- Maxian TA, Brown TD, Weinstein SL (1995) Chronic stress tolerance levels for human articular cartilage: two nonuniform contact models applied to long term follow up of CDH. *J Biomech* 28(2):159–166
- Michaeli DA, Murphy SB, Hipp JA: Comparison of predicted and measured contact pressures in normal and dysplastic hips. *Med Eng Phys*, 1997; 19: 180–86

- Migaud H, Chantelot C, Giraud F, Fontaine C, Dequennoy A (2004) Long-term survivorship of hip shelf arthroplasty and Chiari osteotomy in adults. *Clin Orthop* 418:81–86
- Moll FK Jr (1982) Capsular change following Chiari innominate osteotomy. *J Pediatr Orthop* 2(5):573–576
- Pauwels F. Biomechanics of the normal and diseased hip. Berlin: Springer-Verlag, 1976
- Pemberton PA (1965) Pericapsular osteotomy of the ilium for treatment of congenital subluxation and dislocation of the hip. *J Bone Joint Surg (Am)* 47:65–86
- Pompe B, Daniel M, Sochor M, Vengust R, Kralj-Iglič V, Iglič A. Gradient of contact stress in normal and dysplastic human hips. *Med Eng Phys*, 2003; 25: 379–85
- Salter RB, Hansson G, Thompson GH (1984) Innominate osteotomy in the management of residual congenital subluxation of the hip in young adults. *Clin Orthop* 182:53–68
- Staheli LT (1981) Tehnique: slotted acetabular augmentation. *J Pediatr Orthop* 1(3):321–327
- Staheli LT (1991) Surgical management of acetabular dysplasia. *Clin Orthop Rel Research* 264:111–121
- Staheli LT, Chew DE (1992) Slotted acetabular augmentation in children and adolescence. *J Pediatr Orthop* 12(5):569–580
- Steel HH (1973) Triple osteotomy of the innominate bone. *J Bone Joint Surg (Am)* 55(2):343–350
- Sutherland DH, Greenfield R (1977) Double innominate osteotomy. *J Bone Joint Surg (Am)* 59(8):1082–1091
- Tönnis D, et al (1985) Die operative Behandlung der Hüft dysplasie. Technik und Ergebnisse. Bücherei des Orthopäden, Enke, Stuttgart, Bd 44
- Vengust R, Daniel M, Antolič V, Zupanc O, Iglič A, Kralj-Iglič V (2001) Biomechanical evaluation of hip joint after Salter innominate osteotomy: a long-term follow-up study. *Arch Orthop Trauma Surg* 40:511–516
- Zupanc O, Antolič V, Iglič A, Jaklič A, Kralj-Iglič V, Stare J, Vengust R (2001) The assessment of contact stress in the hip joint after operative treatment for severe slipped capital femoral epiphysis. *Inter Orthop* 25:9–12

IntechOpen



The Role of Osteotomy in the Correction of Congenital and Acquired Disorders of the Skeleton

Edited by Prof. James Waddell

ISBN 978-953-51-0495-7

Hard cover, 294 pages

Publisher InTech

Published online 11, April, 2012

Published in print edition April, 2012

This book demonstrates specific osteotomy techniques from the skull to the hallux. The role of osteotomy in the correction of deformity is under appreciated in part because of the ubiquitous nature of joint replacement surgery. It should be remembered, however, that osteotomy has a role to play in the correction of deformity in the growing child, the active young adult, and patients of any age with post-traumatic deformity limiting function and enjoyment of life. In this text we bring you a number of papers defining specific problems for which osteotomy is found to be an effective and lasting solution. I hope you find it useful.

How to reference

In order to correctly reference this scholarly work, feel free to copy and paste the following:

Borut Pompe and Vane Antolič (2012). Acetabular Augmentation by Residual Hip Dysplasia, The Role of Osteotomy in the Correction of Congenital and Acquired Disorders of the Skeleton, Prof. James Waddell (Ed.), ISBN: 978-953-51-0495-7, InTech, Available from: <http://www.intechopen.com/books/the-role-of-osteotomy-in-the-correction-of-congenital-and-acquired-disorders-of-the-skeleton/acetabular-augmentation-by-residual-hip-dysplasia>

INTECH
open science | open minds

InTech Europe

University Campus STeP Ri
Slavka Krautzeka 83/A
51000 Rijeka, Croatia
Phone: +385 (51) 770 447
Fax: +385 (51) 686 166
www.intechopen.com

InTech China

Unit 405, Office Block, Hotel Equatorial Shanghai
No.65, Yan An Road (West), Shanghai, 200040, China
中国上海市延安西路65号上海国际贵都大饭店办公楼405单元
Phone: +86-21-62489820
Fax: +86-21-62489821

© 2012 The Author(s). Licensee IntechOpen. This is an open access article distributed under the terms of the [Creative Commons Attribution 3.0 License](#), which permits unrestricted use, distribution, and reproduction in any medium, provided the original work is properly cited.

IntechOpen

IntechOpen