

We are IntechOpen, the world's leading publisher of Open Access books Built by scientists, for scientists

5,600

Open access books available

138,000

International authors and editors

175M

Downloads

Our authors are among the

154

Countries delivered to

TOP 1%

most cited scientists

12.2%

Contributors from top 500 universities



WEB OF SCIENCE™

Selection of our books indexed in the Book Citation Index
in Web of Science™ Core Collection (BKCI)

Interested in publishing with us?
Contact book.department@intechopen.com

Numbers displayed above are based on latest data collected.
For more information visit www.intechopen.com



Renal Biopsy Interpretation

Sakineh Amoueian and Armin Attaranzadeh
Mashhad University of Medical Sciences

Iran

1. Introduction

The kidney is a mysterious organ that makes urine from Shiraz wine (1). It has a role in excreting waste products, regulating body fluids and balancing soluble ions.

The focus of this chapter is the gross anatomy and histology of the kidney renal biopsy techniques and differential diagnosis of the important renal disease and interpretation of these.

2. Anatomy

The kidneys are two bean shape organs within peritoneum located between 12th thoracic rib to 3rd lumbar vertebrae. A space named perirenal, with fatty tissue, surrounds each kidney (2). In the anterior, there are the pancreas, duodenal loop, ascending and descending colon, and the hepatic, splenic, and proximal superior mesenteric arteries. In the posterior, there is fat but no organs. The kidneys exhibit craniocaudal movement of 1.9 to 4.1 cm during respiration (4). Each organ weights 125 to 170 gr in males and 115 to 150 gr in females (4). Both together represent 0.04% of total body weight. Kidney weight correlates best with body surface area, whereas age, sex, and race do not influence it (5). The dimensions of the kidney are 11-12 cm (length), 5-7.5 cm (width) and 2.5-3 cm (thickness). Renal volume can increase or decrease by 15% to 40% with major fluctuations in blood pressure, intravascular volume, or interstitial expansion by edema (6). The renal artery divides into anterior and posterior arteries which in turn give off segmental arteries, which supply the apical, upper, middle, lower and posterior segmental regions of the parenchyma (7). After branching to anterior and posterior divisions at the hilus, the main renal artery gives off interlobar (between lobes and extend to corticomedullary junction), arcuate (between cortex and medulla) and interlobular arteries (extend cortex to capsule) respectively. Afferent arterioles are branched from interlobular arteries which make glomerulus and efferent arterioles after glomerulus, forms peritubular or interstitial capillaries around tubules. Efferent arterioles form vasa recta which supplies the outer and inner medulla (8). Multiple anastomoses between capillaries within the lobule create a capillary meshwork. The vasa recta and peritubular capillaries form interlobular veins and with a similar pattern as arteries leave the kidneys as renal veins (8).

On the cut surface of kidney, there is a pale outer region (cortex) and a darker inner region (medulla). The medulla is divided to 18 pyramids. Each pyramid base is located at the corticomedullary junction, and apex has 20-70 small openings representing the distal ends of

collecting ducts (9). The renal cortex forms a 1.0-cm layer beneath the renal capsule and extends down between the renal pyramids forming the columns of Bertin (10).

Renal lobe is composed of a pyramid with its surrounding cortical parenchyma (11). The renal pelvis is an extension of upper ureter. A detailed anatomy description of kidney is provided elsewhere (12).

3. Nephrons

The functional and basic unit of the kidney is the nephron which is composed of renal corpuscle (glomerulus and Bowman's capsule), and cylindrical epithelial-lined tubular component (proximal tubule, Henle's loop and distal tubule).

Tubular part of the nephron has complex spatial and topographic relationship with its microvasculature and demonstrates sequential variation in its cellular constitution depending on the function (10). The glomeruli are located in cortex. There are two main groups of nephrons: those with a short loop of Henle and those with long loop. The length depends on the glomerulus location. The superficial and midcortical nephrons have short loops (85%) and the juxtamedullary and some deep midcortical ones, have long loops (15%) (10). Henle's loop is located in the medulla and is connected proximally to proximal tubule just after glomerulus, and distally to distal tubule. These two groups of tubules are located in the cortex. The distal tubule then connects to collecting ducts ending in renal papilla. The Henle's loop and collecting ducts are arranged in radial form from papilla to cortex. The number of Nephrons depends on weight at birth and age, meaning that in low birth weight is the nephrons weight less than normal with increased risk of hypertension (13). The estimated number of nephrons is 400-800 thousands (14). Even a broader range of 227000-1825000 has been reported (15).

4. Kidney histology

4.1 Glomerulus

Malpigi first described the glomerulus and demonstrated its relation with the renal vasculature (16). Later, Bowman showed and presented glomerulus, in detail (17,18). Glomerulus is used to refer to the glomerulus tuft and Bowman's capsule. Bowman's capsule is the dilated part of the proximal tubule (19). Glomerulus is a vascular tuft lined by endothelium and is supported by a mesangium that contains cells and a matrix material and glomerular capillary loop basal lamina. The term GBM (glomerular basement membrane) is used for capillary loop components observable by light microscopy that includes cellular elements, podocyte and endothelial cells and the matrix component of basal lamina (10). Bowman's capsule (BC) is a thick connective tissue barrier between the glomerular filtrate within Bowman's space and the interstitium (20). It is approximately spherical and lined along its inner surface by parietal epithelial cells.

The vasculature unit is covered by epithelial cells which form the visceral layer of Bowman's capsule. There is another epithelial layer named parietal epithelium that is continuous with visceral layer and make a pouch space between the two layers and surrounds the glomerular vascular tuft. The glomerulus has a round figure and 200 μm diameter (21). There are some variations in size depending physiologic conditions (22). Lobularity of glomerulus is not prominent in normal kidney.

Cellularity assessment of glomerulus mesangium is obtained in sections of 2-4 μm thickness. The normal mesangial cell number is one or two cells per matrix area (10). Generally there are less than 4 cells in mesangial region of far from vascular pole.

Endothelial cells have eosinophilic cytoplasm and round to oval nucleoli which project into capillary lumen. Their surfaces have a negative charge (23). Endothelial cells completely line the inner surface of the glomerular capillary loops and have fenestrated regions and nonfenestrated regions. The fenestrations are round to oval and measure approximately 70 to 100 nm in diameter. These fenestrations are open and lack a diaphragm (10). Many molecules are produced by endothelial cells that function in the immune response and coagulation system, and also mediate vasoconstriction and vasodilatation (24).

The mesangium supports glomerulus capillary tuft which regulate glomerular filtration by contraction properties (25). These cells have a phagocytic function that clears debris from this region (26). The mesangial matrix is structurally similar to basement membrane of glomerulus. This can be seen by Periodic Acid Schiff (PAS) and silver staining.

Endothelial cells and visceral epithelial cells have a common basement membrane of 310-380 nm thickness (27). It is thicker in males than females and has variation depending physiologic conditions (28).

Visceral epithelial cells are located outside of glomerulus capillary wall, bulging to Bowman's space between the two epitheliums. They have eosinophilic cytoplasm and processes that surround glomerulus and capillaries and divide to foot processes afterwards. The processes have contraction function related to actin, myosin and α -actinin in their cytoplasm (28). The foot processes are arranged on basement membrane with a 25-60 nm distance from each other and called filtration split. These cells have a negative charge (29).

The parietal epithelium of Bowman's space is simple squamous layer. These cells have 0.1-0.3 μm height which increases around nucleus region. The epithelial cells have a basement membrane on Bowman's capsule.

Golgi observed a unit named juxtaglomerular apparatus in vascular pole of glomerulus (30). The juxtaglomerular apparatus is a complex structure composed of specialized epithelial cells, the macula densa, vascular components (including portions of the afferent and efferent arterioles), and extraglomerular cells known as lacis cells (31,32). Rennin and angiotensin II are produced in these cells (33). The macula densa consists of a plaque of specialized tubular cells, polarized to the glomerular side of the tubule and projecting into the lumens that are taller than collecting tubules cell with an apical nucleus, and short surface microvilli, but lack lateral interdigitation characteristic of other cells of the thick ascending limb (10).

4.2 Proximal tubule

This unit is about 14 mm long and is composed of a convoluted and a straight portion (21). The convoluted part forms some coils near its glomerulus in the cortex and then goes to medulla and forms straight part. In histologic section of cortex, the major part of tissue is composed of proximal convoluted tubules. In biopsy sections, collapsed lumens of these tubules are seen (34). Proximal tubule cells are cuboid or short columnar with eosinophilic cytoplasm, often granular and a round nucleus in the center.

These cells have many mitochondria located at the cell base. In apex of cells, there is a brush like border which can vary in different parts of proximal tubules.

The proximal tubules' task is reabsorption of the majority (60%) of glomerular ultrafiltrate. This includes sodium, chloride, glucose, amino acids, bicarbonate and water.

4.3 Henle's loop

Between proximal and distal tubule, there is a U-shape unit named Henle's loop. Resting on medulla, Henle's loop can be long or short depending on the glomerulus location. Their cells

are flat, 1-2 μm thick with nuclei bulged into lumen and with attenuated cytoplasm with no brush border which creates a resemblance to the endothelial lining of a capillary. Henle's loop have a role in concentration of urine. The transporting of water and chloride sodium in this loop is passive.

4.4 Distal tubule

This unit connects to ascending part of Henle's loop and is composed of thick part of the loop, distal convoluted tubule and macula densa as described in juxtaglomerular apparatus. The thick part of Henle's loop has cuboidal cells with eosinophilic cytoplasm and round nuclei, often bulging into lumen. These cells have many mitochondria with active transport of materials especially sodium chloride. In contrast to proximal tubule, these cells have less height, less eosinophilic property and no brush border.

After this part, distal convoluted tubule begins which is the terminal part of distal tubules. These cells are similar but taller than thick ascending cells and have round nuclei, without brush border and indistinct lateral cell border and less eosinophilic than proximal tubules. Their lumen is often open. Their function is reabsorption of chloride sodium.

In the end of distal convoluted tubules, a transitional segment begins which connects these tubules to the collecting duct system.

Most nephrons connect to initial collecting tubules (35). About 40% of nephrons connect to arcades which have three nephron attachments and every cortical collecting tubule, connects to 11 nephrons (9). The collecting duct system has similar cells to distal convoluting tubules and cortical collecting ducts.

4.5 Collecting duct

This unit begins near the end of distal convoluted tubules in the cortex and goes to the tip of papilla. This system has three part in cortex, outer medulla and inner medulla which are covered by different epithelial cells (36).

The cortical part has cuboidal cells with round central nucleus, distinct lateral cell border, open lumen and no brush border. There are two distinct cells in this unit: principal cells and intercalated cells, which are difficult to differentiate in light microscope, but the former has a clear cytoplasm.

Principal cells function, is potassium secretion into the cortical collecting duct.

Intercalated cells are darker than principal cells and are interspersed in lining of collecting duct. They have many mitochondria and also carbonic anhydrase II enzyme. The cortical part of collecting duct involves in acidification of urine (37). The outer medullary part of collecting duct is lined by similar cells to cortical part, only taller. This part is also involved in urine acidification. In the last part of collecting duct, named inner medullary collecting duct, there is an increase in diameter and height of epithelial cells as the duct is descending (38). It means that cuboidal cells gradually turn to columnar cells. This part plays a role in urine concentration.

4.6 Other parts of kidney tissue

The kidney artery distribution was introduced in the first pages of this chapter. Interstitium of the kidney is about 5-20% of cortex (39). This part is composed of extracellular matrix and interstitial cells, but cannot be seen in light microscopy (40). This part is increased in medulla and reaches 10-40% of medulla (41). In this region, it could be seen as gelatinous

appearance. The interstitial cells are involved in producing extracellular matrix and some endocrine substances such as those function as antihypertensive (42).

Lymphatic vessels are not prominent in light microscope view. They are originated close to interlobular arteries and make arcuate and interlobar lymphatic vessels which drain into lymph vessels located at kidney hilus. The lymphatic vessels are believed that exist only in cortex (43,44). The kidney nerves are originated from celiac plexus (45) and accompany vessels in cortex and medulla (46).

5. Renal biopsy techniques

Renal biopsy has an important role in diagnosis, prognosis, and response to therapy. The first renal biopsy was taken about one century ago in the United States. Widespread introduction of renal biopsy for clinical use, began in 1950s (47). Renal biopsy has been used to identify pathologic changes in different clinical conditions and recognize renal diseases with similar manifestations.

6. Requisition/referral form

In every medical center it should be a form designed for pathologic specimens. Over the biopsy procedure this form should be completed by the physician and sent to pathology laboratory. Minimum informations required in these forms include patient's full name, date of birth, sex, race, date of biopsy, clinical problem(s), type of insurance, address, phone number, emergency situation, fixative fluid, biopsy location and side, physician's name and phone. Specimens should be labeled with patient's name and a second identifier like father's name or date of birth.

7. Biopsy technique

Renal biopsies are taken by nephrologists or radiologist by True-cut or biopsy gun under local anesthesia. It is performed in prone position for native kidneys and in supine position for transplanted kidneys. Nowadays, biopsies can be obtained by ultrasound or computed tomography guided (47). The use of biopsy gun, guided by ultrasound has more safety and yield (48,49,50).

Each glomerulus has a 200-250 μm diameter, therefore, the needle should be selected properly. 14-gauge, 16-gauge, and 18-gauge needles have internal diameter of 900-1000, 600-700, 300-400 μm , respectively. It is better to use 16 or 14 gauge needle as the use of 18 gauge needle can result in narrower and fragmented tissue.

In renal mass biopsies, the 18-21 gauge needles can be used (51).

Biopsies from subcapsular region show nonspecific sclerosis. The optimum location for biopsy is juxtamedullary, because these glomeruli are the earliest ones involved in focal segmental glomerulosclerosis (52).

Other renal biopsy techniques include transjugular retrograde approach by catheter (53,54), laparoscopic techniques (55), and open laparatomic biopsy.

8. Risks

There is little discomfort experienced by patients in renal biopsies although it is a painful procedure. The most common complication, is microscopic hematuria (almost all patients).

Gross hematuria is occurred in 5-7% of patients (56). There are some other complications including perinephric hematuria, arteriovenous fistula(57), ileus, renal pelvic rupture and entrance into neighbor organs. Other complications are the need for transfusion (less than 1%), renal loss (less than 0.1%), and death (very rare) ((47,58,59). Ultrasound guided biopsy and automatic biopsy devices are helpful techniques, but do not decrease the complications (57,59). Overall, renal biopsy is considered a safe medical approach (47,60,61).

9. Gross inspection

The specimen should be handled and processed with great care. It should be moved by a wooden stick like toothpick and forceps use is forbidden because of crush artifact (62). After renal biopsy is obtained, it should be placed in a drop of saline and examined under microscope for its color and appearance.

The reddish pin points or hemispheres on tissue surface are the glomeruli, which are not observable in conditions such as fibrosis and hypercellular bloodless glomeruli, (63). The biopsy should not be dried after taking the tissue and should be divided as soon as possible. The cylindrical tissue should be divided and fixed in proper solutions for light microscopy, immunofluorescence study and electron microscopy. Longitudinal sectioning is not advised, because the needle diameter is changed to narrower ones.

A cutting protocol for needle biopsy in the first sample is cutting 1-2 mm of each end side and fixing in glutaraldehyde for electron microscopy, two third of the remaining tissue from cortical side for light microscopy, and one third of the tissue from cortical side for immunofluorescence study (63). If there is a second sample, similar cutting is done for electron microscopy, but one third of cortical side is taken for immunofluorescence study and two third of medullary side for light microscopy (62).

Repeated biopsies, need only light microscopy sample (52).

If the specimen is small, immunofluorescence study might be omitted and if it is very small, it is better to process entire sample for electron microscopy(63)

The renal biopsies are studied in 4-5 μm sections using different stains. The main staining material for the biopsies is Hematoxilin & Eosin Other stains commonly used in renal biopsies are: Periodic Acid Schiff, Methenamin silver, Masson trichrome, Congo red and reticulin.

10. Fixatives

For light microscopy, neutral buffered formaldehyde is used. It is suitable for immunohistochemical study and also molecular procedures (62). Bouin's fluid, mercury based fixatives such as Zenker's, and Karnowsky's fixatives have better morphology preservation properties (63), yet they need additional handling precautions, and are not suitable for immunohistochemistry and molecular studies (62).

Methacaren, a modified Carnoy fixative, provides good fixation for light microscopy as well as electron microscopy (64).In processing, the tissue is better to be wrapped in a wet thin paper like lens paper.

In emergency evaluation, the fixative and also processing is done by microwave devices.

For electron microscopy, 2-3% glutaraldehyde fluid is suitable. It should be cool and buffered and be made in the last 3 months. Immunofluorescence samples do not need any fixative and should be delivered and frozen in Michel's media for frozen sections.

11. Sectioning and staining

After histologic processing and paraffin embedding, the tissues are sectioned by microtome. These sections are prepared as thin as 3 μm or less for light microscopy. Thicker sections are needed in congo red and Immunohistochemistry staining.

The most helpful stains for light microscopy are Hematoxiline and Eosine (H&E), methenamine silver, Periodic Acid Schiff (PAS), trichrome, congo red and reticulin.

H&E highlights the cells well, while methenamine silver shows basement membrane and matrix of connective tissues. In PAS staining, there is good highlighting of cells and basement membrane. Trichrome staining is suitable for basement membrane, fibrosis, and deposit assessment. Congo red is recommended for amyloid discovering while elastin stains such as reticulin are helpful in vascular lesions.

Table 1 provides a comparison of the characteristics of tissues provided by three different stains (8).

	PAS	trichrome	silver
Basement membrane	red	Deep blue	black
Mesangial matrix	red	Deep blue	black
Interstitial collagen	-	Pale blue	-
Cell cytoplasm	-	Rust/ orange-granular	-
Immune complex deposits	-/+	Bright red-orange homogeneous	
fibrin	Weakly +	Bright red-orange fibrillar	-
amyloid	-	Light blue-orange	-
Tubular casts	red	Light blue	Gray to black
Insudative lesions	-/+	Bright red-orange homogeneous	-

Table 1.

12. Specimen adequacy

There is a question of how much tissue is necessary for diagnosis of renal disease. In diffuse glomerular diseases, such as amyloidosis and membranous glomerulopathy, one glomerulus is enough for diagnosis. In focal diseases, considering the random distribution of abnormalities, the probability of finding any glomerulopathy is represented by binomial equation (65). For example, if we have 10 glomeruli and the disease exist in 10% and 35% of them, we will have 65% and 95% positive report in the biopsy, respectively.

Fogo mentioned 25 and 10 glomeruli are needed for most accurate diagnosis in light microscopy for native and transplanted kidneys respectively (52). In one study it was found that a specimen with at least 25 glomeruli is needed for the biopsies of chronic lesions of the kidney (66).

There is semi-quantification of pathologic findings including glomeruli number, percentage of affected glomeruli, mesangial matrix volume, inflammatory cell infiltrate, percentage of fibrosis and atrophy in different patients. Also quantification techniques in renal biopsy have been reported (67,68,69,70). These quantifications help in monitoring the patients

and their response to therapy as well as comparison of different biopsies and their correlation with clinical points.

Quantification methods require a standard protocol for processing and sectioning (70).

13. Differential diagnosis of renal lesions

Renal biopsies are done to determine tissue diagnosis, exclude other diagnostic possibilities, assessing the severity and activity of the lesion (grade), and the amount of irreversible scarring (stage) (63). There are some steps in renal biopsy evaluation with each step correlating to one the part of the kidney including glomeruli, tubules, Interstitium and vascular parts and correlate them with each other. Any changes in each part of the kidney may be associated with secondary changes in others. The maximum data about renal biopsies is provided by light microscopy, immunofluorescence study and electron microscopy (71,72,73).

In the future, genomics and proteomics studies will be used for the diagnosis of renal diseases. In glomerular evaluation, pathologists should diagnose the inflammation, glomerular basement membrane changes, scarring, spikes, fibrinoid exudates, hypercellularity and deposits.

In tubular parts, the focus should be on cellular injuries, regeneration, atrophy, cast, edema, fibrosis and crystals.

Interstitium pathology includes cellular infiltrate, edema, and fibrosis, while vascular part changes are inflammation, sclerosis, hyalinosis and thrombosis.

In overall inspection of biopsy, pathologists should know about the clinical status and chronicity of the disease. In the chronic nephron loss, there is compensatory of remained normal nephrons which leads to a mixture of hypertrophied functioning glomeruli and atrophic non-functioning nephrons (10).

The pathologist also should know that many diseases which affect the kidney, have different manifestations other than kidney.

Light microscopy is often the most important tool for detecting the primary site of injury, but to differentiate between the diseases with common manifestation, electron microscopy and immunofluorescence study are helpful (10).

In this section we used Heptinstal Renal Pathology tables and their respective authors.

14. Glomerular lesions

The clinical presentations of glomerular diseases are very different including proteinuria, hematuria, casts, nephritic syndrome, acute nephritis, renal failure (acute and chronic) and rapidly progressive nephritis. Clinical data about age and urine sediment (nephritic or nephritic), narrows differential diagnoses (74).

There are some reports on the relative frequency of renal disorders in biopsies (75). The complexity and variety of glomerular diseases is a challenge for nephropathologists (10).

Renal injuries could be categorized as acute or fibrosing. Active lesions include proliferation, necrosis, crescent, edema, and active inflammation. Fibrosing lesions include glomerulosclerosis, fibrosis, crescent, tubular atrophy, interstitial fibrosis and vascular fibrosis (76).

It should be remembered in the prognosis and monitoring of renal diseases that glomerular lesion can change over time. .

There is a standard terminology for glomerular involving lesions report which is stated by Jennette and et al (10,75).

Focal: less than 50% of glomeruli

Diffuse: more than 50% of glomeruli

Segmental: part of a glomerulus

Global: all of a glomerulus

Mesangial hypercellularity: 4 or more nuclei in mesangial region

Endocapillary hypercellularity: increased cellularity internal to the GBM composed of leukocytes, endothelial cells or mesangial cells.

Extracapillary hypercellularity: increased cellularity in Bowman's space – (more than one layer of parietal or visceral epithelial cells or monocyte/machrophage)

Crescent: extracapillary hypercellularity other than the epithelial hyperplasia of collapsing variants of FSGS

Fibrinoid necrosis: lytic destruction of cells and matrix with deposition of acidophilic fibrin-rich material

Sclerosis: increased collagenous extracellular matrix that is expanding the mesangium, obliterating capillary lumens or forming adhesions to Bowman's capsule

Hyaline: glassy acidophilic extracellular material

Membranoproliferative: combined capillary wall thickening and mesangial or endocapillary hypercellularity

Lobular (hypersegmented): expansion of segments that are demarcated by intervening urinary space

Mesangiolytic: detachment of the paramesangial GBM from the mesangial matrix or lysis of mesangial matrix

Each of these terms could be categorized further according to some other parameters ((74,77,78,79,80,81 ,82,83):

Focal glomerulonephritis: is includes inflammatory lesions in less than 50% of glomeruli. the differential diagnoses are noted based on the age and are as follow:

<15 years:

- mild postinfectious glomerulonephritis
- IgA nephropathy
- thin basement membrane disease
- hereditary nephritis
- Henoch Schoenlein purpura
- mesangial proliferative glomerulonephritis

15-40 years:

- IgA nephropathy
- thin basement membrane disease
- systemic lupus erythematosus
- hereditary nephritis
- mesangial proliferative glomerulonephritis

>40 years:

- IgA nephropathy

Diffuse glomerulonephritis: affects most or all of the glomeruli and differential diagnoses according to age are:

<15 years:

- postinfectious glomerulonephritis
- membranoproliferative glomerulonephritis

15-40 years:

- postinfectious glomerulonephritis
- systemic lupus erythematosus
- rapid progressive glomerulonephritis
- fibrillary glomerulonephritis
- membranoproliferative glomerulonephritis

>40 years:

- rapid progressive glomerulonephritis
- fibrillary glomerulonephritis
- vasculitis
- postinfectious glomerulonephritis

Nephrotic syndrome: is associated with proteinuria and lipiduria and its differential diagnoses according to age include:

<15 years:

- minimal change disease
- focal segmental glomerulosclerosis
- mesangioproliferative glomerulonephritis

15-40 years:

- focal segmental glomerulosclerosis
- minimal change disease
- membranous nephropathy
- diabetic nephropathy
- preeclampsia
- post infectious glomerulonephritis

>40 years:

- focal segmental glomerulosclerosis
- membranous nephropathy
- diabetic nephropathy
- minimal change disease
- IgA nephropathy
- amyloidosis
- light chain deposition disease
- benign nephrosclerosis
- postinfectious glomerulonephritis

In each pattern, the injuries should be written and overall the proper diagnosis should be made. The optimum approach to pathologic diagnosis of a glomerular disease is based on the presence of features indicative of specific disease and the absence of the features indicative of other disorders (10).

One of the first steps in evaluation of glomeruli is the distinction between the primary and the secondary lesions. The systemic diseases including systemic lupus erythematosus, systemic vasculitis (e.g. Wegner granulomatosis), microscopic polyangitis, Henoch Schoenlein purpura, cryoglobulinemic vasculitis, diabetes mellitus, amyloidosis, monoclonal immunoglobulin deposition disease, hypertension, hepatitis B infection and etc. affect the kidney as well as the other organs.

In light microscopy evaluation, each part of glomerulus should be noted for normal and abnormal cellularity and extracellular materials.

In normal morphology of glomeruli, the diagnoses are minimal change disease and thin basement membrane nephropathy and electron microscopy and immunofluorescence would be helpful. Early stages of many glomerulopathies show normal features in light microscopy. If there are capillaries with thick walls, diseases such as membranous glomerulopathy, diabetic glomerulosclerosis, amyloidosis, immunoglobulin deposit disease, should be remembered.

Alteration of glomerular basement membrane is summarized here (82,83,84):

Where limited sclerosis of glomeruli is observed, focal segmental glomerulosclerosis, Alport's syndrome, and sclerotic phase of different glomerulopathies are differential diagnoses.

Hypercellularity may result from increase in mesangial, visceral epithelial, endothelial cells or infiltrate of leukocytes.

Mesangial hypercellularity is seen in mesangioproliferative glomerulonephritis, postinfectious glomerulonephritis, and membranoproliferative glomerulonephritis. Lobular pattern of glomeruli should remind membranoproliferative glomerulonephritis with nodular expansion, fibrillary glomerulonephritis, and immunotactoid glomerulopathy.

Diffuse sclerosis is seen in end stages of glomerular, vascular or tubulointerstitial diseases. It should be noted that many diseases may have no changes in morphology at the beginning of their evolution while other diseases such as lupus or IgA nephropathies may result in any of the changes.

On the other hand glomerulus lesions are categorized like the following (76,80)

Sclerosis:

- usual:
- collapsing:
- tip lesion of FSGS:
- secondary:

Crescent:

- according to cellular and degree of fibrous:
 - cellular:
 - fibrocellular:
 - fibrous:
- according to immune deposits:
 - immune etiology:
 - pauci immune:

Proliferation:

- mesangial with nodules
 - diabetic nephropathy
 - light chain deposition disease
 - membranoproliferative glomerulonephritis
 - amyloidosis
 - idiopathic nodular sclerosis
- mesangial without nodules
 - lupus nephritis
 - IgA nephropathy

- chronic infection related glomerulonephritis
- mesangial without deposits
 - minimal change disease
 - focal segmental glomerulosclerosis
 - early diabetic nephropathy
- mesangial and endocapillary
 - membranoproliferative glomerulonephritis
 - proliferative lupus nephritis
 - cryoglobulinemia glomerulonephritis
 - postinfectious glomerulonephritis
 - fibrillary glomerulonephritis
 - immunotactoid glomerulopathy
 - dense deposit disease

Unusual lesions:

- foamy podocytes:
- foamy macrophages intraglomerular:

It should be remembered that each specific histological pattern in light microscopy could be seen in different diseases (10,74,77,80,81,83,84):

No abnormality:

- normal glomerulus
- no light microscopic changes
 - minimal change disease
 - thin basement membrane nephropathy
- early lesion of glomerulus (near in all diseases)

Thick capillary walls only

- membranous glomerulopathy
- thrombotic microangiopathy
- preeclampsia/eclampsia
- fibrillary glomerulonephritis with capillary predominance of deposits

Thick walls with mesangial expansion without hypercellularity:

- diabetic glomerulopathy
- membranous glomerulopathy with mesangial deposits
- amyloidosis
- monoclonal Ig deposition disease
- fibrillary glomerulonephritis
- dense deposit disease

Focal segmental glomerulosclerosis:

- minimal change disease
- healing of previous glomerular injuries
- hypertension
- hereditary nephritis
- chronic phase of focal glomerulonephritis

Membranous injury:

- drug assumption like gold, penicillamin, mercury
- systemic lupus erythematosus

- chronic hepatitis B
 - underlying malignancy
- Membranoproliferative glomerulopathy:*

- membranoproliferative glomerulonephritis
- diabetic glomerulonephritis
- thrombotic microangiopathy
- fibrillary glomerulonephritis
- immunotactoid glomerulopathy
- systemic immune complex disease
 - systemic lupus erythematosus
 - infectious endocarditis
 - hepatitis C
 - complement dysregulation
 - chronic thrombotic microangiopathy
 - monoclonal immunoglobulin deposition disease

As it is emphasized before, clinical information is very important and differential diagnoses of diseases are possible based on those information.

According to serologic studies (74):

- antistreptococcal antibody: poststreptococcal glomerulonephritis
- anti nuclear antibody: lupus nephritis
- anti GBM antibody: anti GBM antibody disease
- circulating cryoglobulins: mixed cryoglobulinemia
- antineutrophil cytoplasmic antibody: Wegner's granulomatosis

According to decreased serum complement levels:

- postinfectious glomerulonephritis
- lupus nephritis
- membranoproliferative glomerulonephritis
- mixed cryoglobulinemia

According to presence of acute renal failure:

- idiopathic minimal change disease
- collapsing focal segmental glomerulosclerosis
- minimal change disease with acute interstitial nephritis of NSAIDs
- crescentic glomerulonephritis
- nephrotic syndrome secondary to monoclonal immunoglobulin deposition disease because of myeloma casts

In addition to light microscopy, immunofluorescence could be helpful in many normal morphology and also many conditions where there is thickening of membranous or expansion of mesangial. It can help to determine the location and pattern of deposits and composition of deposits.

Nowadays the routine antibodies which are used in immunofluorescent study are including IgG, IgA, IgM, kappa, lambda, c3, c4, c1q.

Some diseases may be dismissed without immunofluorescence or immunohistochemistry use, including light chain associated disease, IgA nephropathy, c1q nephropathy, anti GBM disease, humeral (c4d) transplant rejection, and fibronectin glomerulopathy.

In electron microscopy, basement membrane changes such as split, existence and pattern of deposits, fibrillary changes and also mesangial deposits can be diagnosed. Some diseases are detected only by electron microscopy studies including but not limited to fibrillary/

immunotactoid glomerulopathy, amyloidosis, cryoglobulinemia, monoclonal immunoglobulin deposition disease, collagenofibrotic glomerulopathy, fibrinogen glomerulopathy, Alport's syndrome, dense deposit disease, thin glomerular basement membrane nephropathy, lipoprotein glomerulopathy, and nail-patella syndrome. Electron microscopy can differentiate between these diseases due to specific texture of deposits (10).

15. Tubular lesions

Kidney tubules in cortex and medulla have different architecture and also different cell types. It is worth noting that cortical tubules have few interstitial tissues, compared to medullary region.

Many changes could be seen in different renal diseases. these alterations are categorized based on different point of views. Some of these are presented below.

First tubular changes introduced (10, 85):

Acute tubular cell injury

- acute tubular necrosis (often coagulation necrosis/ usually secondary to toxins or ischemia. Other changes in the cells are karyorrhexis, ballooning of cytoplasm, detachment from basement membrane, loss of brush border, thinning, luminal dilation, intraluminal different casts, especially cellular ones)
- hyaline droplet formation (small to large droplets in lysosomes of tubular epithelium because of altered permeability and absorption of proteins.)
- vacuolar change (fine and diffuse appearance)
- fatty change (cytoplasm with fine small vacuoles in base of epithelial cells in severe proteinuria or nephrotic syndrome with hyperlipidemia, Reyes` syndrome, poisoning with phosphorus or carbon tetrachloride. In non nephrotic syndrome, it is in favor of Alport's syndrome)
- foam cells
- hypokalemic nephropathy (coarse and irregular varied size vacuoles due to chronic loss of potassium like laxative abuse, rectosigmoid polyps)
- hydropic change (in conditions with assumption of sucrose, manitol, dextrane, radio opaque materials, IVIG and cyclosporine A)
- pigmented in tubular epithelium
- intranuclear inclusions (usually in immunosupressed patients infected by CMV or polyoma virus and adenovirus and lead poisoning)

Tubular casts (principal histologic feature of light chain disease, myoglobulinuria, hemoglobulinuria, oxalate nephropathy, urate nephropathy, nephrocalcinosis and drug induced tubular lesions)

- hyaline: renal failure or low urine output
- WBC: tubulointerstitial inflammation
- epithelial cell or granular: acute tubular injury
- RBC: glomerular bleeding
- large hyaline fractured: light chain casts (often accompanied by giant cells and neutrophils)
- coarse granular acidophilic or red brick: myoglobin or hemoglobin *Tubular atrophy* (simplified epithelial cells with thickening of basement membrane)

Tubulitis (infiltration of inflammatory cells indicative of active tubulointerstitial inflammation or nephritis or allograft rejection)

Tubular basement membrane changes (in tubular atrophy, hereditary nephritis, diabetic nephropathy, monoclonal immunoglobulin deposit, dense deposit disease)

16. Interstitium lesions

As it was mentioned in previous chapter, interstitium occupies small portion of kidney tissue and is slightly larger in medullary region. This part of the kidney tissue becomes affected primarily or secondarily in renal diseases. In many lesions of glomeruli, tubular or vascular, interstitium also gets involved and shows pathologic features.

Interstitium is the main site that demonstrates pathologic findings in drug allergic reactions and pyelonephritis (10).

Two main lesions are acute and chronic interstitium nephritis with the former showing reversible infiltration of inflammatory cells accompanied with edema, and the latter showing irreversible fibrosis and atrophy of other compartments.

Acute phase can heal or result in chronic phase and scarring.

The lesions of interstitium that can be observed in light microscopy are listed here (5 with modification). No pathologic changes

- normal kidney
- no changes in the portion
- early disease

Expansion and edema (due to increased permeability of vessels)

- acute tubular necrosis
- thrombosis of renal vein
- nephrotic syndrome
- acute glomerulonephritis
- thrombotic microangiopathy

Expansion with eosinophilic material

- fibrosis (chronic disease)
- sickle cell anemia
- radiation
- amyloidosis

Expansion with leukocyte infiltration

- interstitial nephritis with polymorphonuclear cells (infections, drug induced, sepsis)
- lymphoplasmacytic (chronic nephritis, vasculitis, lupus nephritis, infections, rejection, drug induced)
- eosinophils (vasculitis, drug induced, lupus nephritis)
- epithelioid cells/granuloma (tuberculosis, sarcoidosis, drug induced, malakoplakia)

Foam cells

- Alport's syndrome
- prolonged nephrotic syndrome

Hemorrhagia

- acute rejection
- vasculitis
- severe glomerulonephritis
- malignant hypertension

Expansion with neoplastic cells

- lymphoma/leukemia

- primary or secondary tumors

Crystals

- calcium carbonate
- calcium oxalate
- uric acid
- cholesterol

Fibrosis

- chronic phase of inflammation
- secondary to chronic lesions of other parts

It should be noted that in every pathologic changes in the interstitium, other parts should be examined carefully, as usually there are changes of overall kidney tissue.

17. Vascular lesions

Kidney vessels are susceptible to many damages. Many immune complexes reach the kidney through blood circulation and are filtered in glomeruli. Receiving about 20% of the cardiac output, the kidneys are constantly exposed to the damaging elements which circulate in blood.

The main injuries of vascular elements are listed here (5 with modification).

Vasculitis

- in systemic injury of vessels
- in local injuries of vessels due to toxins or infection or inflammation

Deposition of materials

- amyloidosis
- immune complexes
- arteriosclerosis

Hypertension induced injuries

- hypertrophy of media
- intimal thickening
- fibrinoid necrosis
- thrombotic microangiopathy
- fibrointimal hyperplasia

Endothelitis

- drug induced
- toxins

Thrombus

- secondary lesion to endothelitis; may cause anemia and thrombocytopenia

Emboli

- small parts of coagulated blood, fat or tumor cells usually in larger arterioles of the kidney

In summary, the importance of clinical characteristics and laboratory results in pathologic assessment of renal biopsies should be stressed. Proper diagnoses can be achieved using light microscopy, electron microscopy and immunofluorescence study of biopsies, in addition to integration of all clinical, laboratory and pathologic data. (10)

18. References

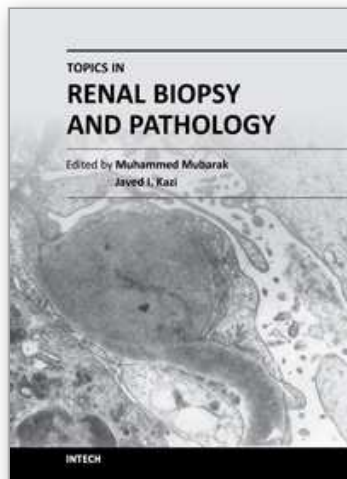
- [1] Cotran R S, Komar V, Robbins and Cotran pathologic basis of disease. 7th edit, Saunders Co, 2010; 905-69.

- [2] Stephen S. Sternberg . Histology for pathologists , second edition. Lippincott-Raven Publishers , Philadelphia, 2010;799-830
- [3.] Suramo I, Paivansalo M, Myllyla V. Cranio-caudal movements of the liver, pancreas and kidneys in respiration. *Acta Radiol Diagn (Stockh)* 1984;25:129.
- [4] Wald H. The weight of normal adult human kidneys and its variability. *Arch Pathol Lab Med* 1937;23:493-500.
- [5] Kaisiske BL, Umen AI. The influence of age, sex, race, and body habitus on kidney weight in humans. *Arch Pathol Lab Med* 1986;110: 55-60.
- [6] Hodson CJ. Physiological changes in size of the kidneys. *Clin Radiol* 1961;12:91.
- [7] Graves FT. The anatomy of the intrarenal arteries and its application to segmental resection of the kidney. *Br J Surg* 1954;42: 132-139.
- [8] Agnes B. Fogo MD , Michael Kashgarian ,Diagnostic Atlas of Renal Pathology: A Companion to Brenner and Rector's The Kidney,2005;
- [9] Oliver I. *Nephrons and kidneys: a quantitative study of development and evolutionary mammalian renal architectonics*. New York: Harper & Row; 1968.
- [10] Jennette, J. Charles; Olson, Jean L.; Schwartz, Melvin M.; Silva, Fred G. *Hepinstall's Pathology of the Kidney*, 6th Edition, Lippincott Williams & Wilkins,2007;1-72.
- [11] Hodson CJ. The lobar structure of the kidney. *Br J Urol* 1972;44: 246-261.
- [12] Clapp WM, Abrahamson DR. Development and gross anatomy of the kidney. In: Tisher CC, Brenner BM, eds. *Renal pathology*. 2nd ed. Philadelphia: JB Lippincott; 1994:3-59.
- [13] Manalich R, Reyes L, Herrera M, et al. Relationship between weight at birth and the number and size of renal glomeruli in humans: A histomorphometric study. *Kidney Int* 2000;58:770.
- [14] Neugarten J, Kasiske B, Silbiger SR, et al. Effects of sex on renal structure. *Nephron* 2002;90:139.
- [15] Hughson M, Farris AB 3rd, Douglas-Denton R, et al. Glomerular number and size in autopsy kidneys: The relationship to birth weight. *Kidney Int* 2003;63:2113.
- [16] Malpighi M. *De viscerum structura exercitatio anatomica*. Bonn, Germany;1666.
- [17] Bowman W. On the structure and use of the Malpighian bodies of the kidney, with observations on the circulation through that gland. *Philos Trans R Soc Land* 1842;132:57-80.
- [18] Fine LG. William Bowman's description of the glomerulus. *Am J Nephrol*1985;5:437-440.
- [19] Rouiller C. General anatomy and histology of the kidney. In: Rouiller C, Muller AF, eds. *The Kidney: Morphology, Biochemistry and Physiology*. New York: Lippincott, 1989:67.
- [20] Mbassa G, Elger M, Kriz W. The ultrastructural organization of the basement membrane of Bowman's capsule in the rat renal corpuscle. *Cell Tissue Res* 1988;253:151.
- [21] Dunnill MS, Halley W. Some observations on the quantitative anatomy of the kidney. *J Pathol*1973;110:113-121.
- [22] Newbold KM, Howie AI, Koram A, Adu A, MichaelJ. Assessment of glomerular size in renal biopsies including minimal change nephropa, thy and single kidneys. *J Pathol*1990;160:255-258.
- [23] Horvat R, Hovoka A, Dekan G, Poczewski H, Kerjaschki D. Endothelial cell membranes contain podocalyxin-the major sialoprotein of visceral glomerular epithelial cells. *J Cell Bioi* 1986;102: 484-491.

- [24] Savage CO. The biology of the glomerulus: endothelial cells. *Kidney Int* 1994;45:314.
- [25] Schlondorff D. The glomerular mesangial cell: an expanding role for a specialized pericyte. *FASEB J* 1987;1:272-281.
- [26] Michael AF, Keane WF, Raij L, Vernier RC, Mauer SM. The glomerular mesangium. *Kidney Int* 1980;17:141-154
- [27] Steffes MW, Barbosa J, Basgen JM, Sutherland DER, Najarian JS, Mauer SM. Quantitative glomerular morphology for the normal human kidney. *Lab Invest* 1983;49:82-86
- [28] Drenckhahn D, Franke R. Ultrastructural organization of contractile and cytoskeletal proteins in glomerular podocytes of chicken, rat and man. *Lab Invest* 1988;59:673-682.
- [29] Latta H, Johnston WH, Stanley TM. Sialoglycoproteins and filtration barriers in the glomerular capillary wall. *J Ultrastruct Res* 1975;51: 354-376.
- [30] Golgi C. Annotazioni intorno all'istologia dei reni dell'uomo e di altri mammiferi e sull'istogenesi: dei canalicoli oriniferi. *Atti R Accad Na: Lincei Rendiconti* 1889;5:337-342.
- [31] Christensen JA, Meyer DS, Bohle A. The structure of the human juxtaglomerular apparatus. A morphometric, lightmicroscopic study on serial sections. *Virchows Arch A Pathol Anat Histol* 1975;367:83.
- [32] Barajas L. Anatomy of the juxtaglomerular apparatus. *Am J Physiol* 1979;237: F333.
- [33] Cantin M, Gutkowska J, Lacasse J, et al. Ultrastructural immunocytochemical-localization of renin and angiotensin II in the juxtaglomerular cells of the ischemic kidney. *Am J Pathol* 1984;115:212-224.
- [34] Parker MV, Swann HG, Sinclair JG..The functional morphology of the kidney. *Tex Rep Bioi Med* 1962;20:"424-458.
- [35] Jamison RL, Kriz W. *Urinary concentrating mechanism: structure and function*. New York: Oxford University Press; 1982.
- [36] Madsen KM, Tisher CC. Structural-functional relationships along the distal nephron. *Am J Physiol* 1986;250:FI-F15.
- [37] Lonnerholm G. Histochemical-demonstration of carbonic anhydrase activity in the human kidney. *Acta Physiol Scand* 1973;88:455-468.
- [38] Madsen KM, Clapp WL, Verlander JW. Structure and function of the inner medullary collecting duct. *Kidney Int* 1988;34:441-454.
- [39] Kappel B, Olsen S. Cortical interstitial tissue and sclerosed glomeruli in the normal human kidney, related to age and sex. A quantitative study. *Virchows Arch [A]* 1980;387:271-277.
- [40] Bohman SO. The ultrastructure of the renal medulla and the interstitial cells. In: Cotran RS, ed. *Tubulo-interstitial nephropathies*. New York: Churchill Livingstone; 1983:1-34.
- [41] Pfaller W. Structure function correlation in rat kidney. Quantitative correlation of structure and function in the normal and injured rat kidney. *Adv Anat Embryol Cell Bioi* 1982;70:1-106.
- [42] Muirhead EE. Antihypertensive functions of the kidney. *Hypertension* 1980;2:444-464.
- [43] Bell RD, Keyl MJ, Shrader FR, Jones EW, Henry LP. Renal lymphatics: the internal distribution. *Nephron* 1968;3:454-463.

- [44] Lemley KV, Kriz W. Structure and function of the renal vasculature. In: Tisher CC, Brenner BM, eds. *Renal pathology*. 2nd ed. Philadelphia: J8 Lippincott; 1994:981-1026.
- [45] Mitchell I GAG. The nerve supply of the kidneys. *Acta Anat* 1950;10: 1-37.
- [46] Gosling JA. Observations on the distribution of intrarenal nervous tissue. *Anat Rec* 1969;163:8J-88.
- [47]. Walker P.D. The Renal Biopsy. *Arch pathol lab med* 2009; 133,181-188.
- [48] Burstein DM, Korbet SM, Schwartz MM. The use of the automatic core biopsy system percutaneous renal biopsies: a comparative study. *Am J Kidney Dis*. 1993;22:545-552.
- [49] Nicholson ML, Wheatley TJ, Doughman TM, et al. A prospective randomized trial of three different sizes of core-cutting needle for renal transplant biopsy. *Kidney Int*. 2000;58:390-395
- [50] Ori Y, Neuman H, Chagnac A, et al. Using the automated biopsy gun with real-time ultrasound for native renal biopsy. *IMAJ*. 2002;4:698-701.
- [51] Nadel L, Baumgartner B.R, Bernardino M.E. Percutaneous renal biopsies: accuracy, safety, and indications. *Urol Radiol* 1986;1:67-71.
- [52] Fogo A.B. Approach to Renal Biopsy. *Am J of Kidney Dis* 2003;42: 826-836.
- [53] Thompson BC, Kingdon E, Johnston M, et al. Transjugular kidney biopsy. *Am J Kidney Dis*. 2004;43:651-662.
- [54] Fine DM, Arepally A, Hofmann LV, Mankowitz SG, Atta MG. Diagnostic utility and safety of transjugular kidney biopsy in the obese patient. *Nephrol Dial Transplant*. 2004;19:1798-1802.
- [55] Gimenez LF, Micali S, Chen RN, Moore RG, Kavoussi LR, Scheel PJ. Laparoscopic renal biopsy. *Kidney Int*. 1998;54:525-529.
- [56] Wickre CG, Golper TA. Complications of percutaneous needle biopsy of the kidney. *Am J Nephrol* 1982;2:173.
- [57] Burstein DM, Schwartz MM, Korbet SM. Percutaneous renal biopsy with the use of real-time ultrasound. *Am J Nephrol* 1991;11:195.
- [58] Preda A, Van Dijk LC, Van Oostaijen JA, Pattynama PMT. Complication rate and diagnostic yield of 515 consecutive ultrasound-guided biopsies of renal allografts and native kidneys using a 14-gauge Biopty gun. *Eur Radiol*. 2003;13: 527-530.
- [59] Whittier WL, Korbet SM. Timing of complications in percutaneous renal biopsy. *J Am Soc Nephrol*. 2004;15:142-147.
- [60] Fraser I.R, Fairly K.F. Renal biopsy as an outpatient procedure. *Am J of Kidney Dis* 1995; 6: 876-8.
- [61] Khajehdehi P, Junaid SMA, Salinas-Madrigal L, et al. Percutaneous renal biopsy in the 1990s: safety, value, and implications for early hospital discharge. *Am J Kidney Dis* 1999;34:92-7.
- [62] Walker P.D, Cavallo T, Bonsib S.M. Practice guidelines for renal biopsy. *Modern pathol* 2004; 17: 1555-63.
- [63] Furness P.N. Renal biopsy specimens. *J Clin Pathol* 2000;53:433-438.
- [64] Shibutani M, Uneyama C. Methacarn: a fixation tool for multipurpose genetic analysis from paraffin embedded tissues. *Methods Enzymol* 2002; 356:114-125.
- [65] Corwin HL, Schwartz MM, Lewis EJ. The importance of sample size in the interpretation of the renal biopsy. *Am J Nephrol* 1988;8:85.

- [66] Wang H.J, Kjellstrand C.M, Cockfield S.M, and Solez K. On the influence of sample size on the prognostic accuracy and reproducibility of renal transplant biopsy. *Nephrol Dial Transplant* 1998; 13: 165-172.
- [67] Bohle A, Wehrmann M, Bogenschutz O, et al. The long-term prognosis of the primary glomerulonephritides: A morphological and clinical analysis of 1747 cases. *Pathol Res Pract* 1992;188:908.
- [68] Kim KH, Kim Y, Gubler MC, et al. Structural-functional relationships in Alport syndrome. *J Am Soc Nephrol* 1995;5:1659.
- [69] Mauer SM. Structural-functional correlations of diabetic nephropathy. *Kidney Int* 1994;45:612.
- [70] Pesce C. Glomerular Number and Size: Facts and Artefacts. *The anatom record* 1998; 251:66-71.
- [71] Lajoie G, Silva FG. Approach to the interpretation of renal biopsy. In: Silva FG, D'Agati VD, Nadasdy T, eds. *Renal Biopsy Interpretation. Part II. Manual of Renal Biopsy Interpretation*, 1st ed. New York: Churchill Livingstone, 1996: 63.
- [72] Chapman JR. Longitudinal analysis of chronic allograft nephropathy: Clinicopathologic correlations. *Kidney Int Suppl* 2005: S108.
- [73] Coppo R, D'Amico G. Factors predicting progression of IgA nephropathies. *J Nephrol* 2005;18:503.
- [74] Rose B.D. Differential diagnosis of glomerular disease. [Uptodate.com](http://uptodate.com)
- [75] Jennette JC, Falk RJ. Nephritic syndrome and glomerulonephritis. In: Silva FG, D'Agati VD, Nadasdy T, eds. *Renal Biopsy Interpretation*. New York: Churchill Livingstone, 1996: 71.
- [76] Fogo A.B. Approach to Renal Biopsy. *Am J of Kidney Dis* 2003;42: 826-836.
- [77] Couser W.G. Rapidly progressive glomerulonephritis: classification, pathogenetic, mechanisms, and therapy. *Am J Kidney Dis* 1998;11(6):449-464.
- [78] Lai K.N, Li P.K, Lui S.F, Au T.C, Tam J.S, Tong K.L, Lai F.M. Membranous nephropathy related to hepatitis B virus in adults. *N Engl J Med* 1991;324(21):1457-63.
- [79] Neugarten J, Baldwin D.S. Glomerulonephritis in bacterial endocarditis. *Am J Med* 1984;77(2):297-304.
- [80] Haas M. Histologic subclassification of IgA nephropathy: a clinicopathologic study of 244 cases. *Am J Kidney Dis* 1997;29(6):829-42.
- [81] Cameron J.S. Focal segmental glomerulosclerosis in adults. *Nephrol Dial Transplant* 2003;18[suppl 6]:vi45-vi51.
- [82] Jahanzad I, Amoueian S, Attaranzadeh A. Familial Lecithin cholesterol Acetyl transferase deficiency: a case report. *Archives of Iranian medical journal*. 2009. vol, No2, P179-81.
- [83] Jahanzad I, Amoueian S, Attaranzadeh A. Alport's syndrome: Ultrastructural study of 26 suspected cases. *Iranian journal of pathology*. 2008; vol 2, No 2. p178-180 .
- [84] Jennette J.C. An algorithmic approach to renal biopsy interpretation of glomerular disease. First International Renal Pathology Conference, nephropathology workshop of European Society of Pathology. *Native Kidney Pathology - Glomerular diseases* last updated at 2010-09-19 20:26:56
- [85] D'Agati VD, Jennette JC, Silva FG. Diseases of the renal tubules. In: D'Agati VD, Jennette JC, Silva FG, eds. *Non-neoplastic Kidney Disease*. Washington: American Registry of Pathology, 2005: 517



Topics in Renal Biopsy and Pathology

Edited by Dr. Muhammed Mubarak

ISBN 978-953-51-0477-3

Hard cover, 284 pages

Publisher InTech

Published online 04, April, 2012

Published in print edition April, 2012

There is no dearth of high-quality books on renal biopsy and pathology in the market. These are either single author or multi-author books, written by world authorities in their respective areas, mostly from the developed world. The vast scholarly potential of authors in the developing countries remains underutilized. Most of the books share the classical monotony of the topics or subjects covered in the book. The current book is a unique adventure in that it bears a truly international outlook and incorporates a variety of topics, which make the book a very interesting project. The authors of the present book hail not only from the developed world, but also many developing countries. The authors belong not only to US but also to Europe as well as to Pakistan and Japan. The scientific content of the book is equally varied, spanning the spectrum of technical issues of biopsy procurement, to pathological examination, to individual disease entities, renal graft pathology, pathophysiology of renal disorders, to practice guidelines.

How to reference

In order to correctly reference this scholarly work, feel free to copy and paste the following:

Sakineh Amoueian and Armin Attaranzadeh (2012). Renal Biopsy Interpretation, Topics in Renal Biopsy and Pathology, Dr. Muhammed Mubarak (Ed.), ISBN: 978-953-51-0477-3, InTech, Available from: <http://www.intechopen.com/books/topics-in-renal-biopsy-and-pathology/post-biopsy-examination-normal-kidney-histology-pathohistological-findings-and-differential-diagnose>

INTECH
open science | open minds

InTech Europe

University Campus STeP Ri
Slavka Krautzeka 83/A
51000 Rijeka, Croatia
Phone: +385 (51) 770 447
Fax: +385 (51) 686 166
www.intechopen.com

InTech China

Unit 405, Office Block, Hotel Equatorial Shanghai
No.65, Yan An Road (West), Shanghai, 200040, China
中国上海市延安西路65号上海国际贵都大饭店办公楼405单元
Phone: +86-21-62489820
Fax: +86-21-62489821

© 2012 The Author(s). Licensee IntechOpen. This is an open access article distributed under the terms of the [Creative Commons Attribution 3.0 License](#), which permits unrestricted use, distribution, and reproduction in any medium, provided the original work is properly cited.

IntechOpen

IntechOpen