

We are IntechOpen, the world's leading publisher of Open Access books Built by scientists, for scientists

5,600

Open access books available

138,000

International authors and editors

175M

Downloads

Our authors are among the

154

Countries delivered to

TOP 1%

most cited scientists

12.2%

Contributors from top 500 universities



WEB OF SCIENCE™

Selection of our books indexed in the Book Citation Index
in Web of Science™ Core Collection (BKCI)

Interested in publishing with us?
Contact book.department@intechopen.com

Numbers displayed above are based on latest data collected.
For more information visit www.intechopen.com



Electrodiagnostic Medicine Consultation in Peripheral Nerve Disorders

S. Mansoor Rayegani¹ and R. Salman Roghani²

¹Shahid Beheshti Medical University, PM&R Research Center,

²University of Social Welfare and Rehabilitation

Iran

1. Introduction

Peripheral nerve disorders including entrapment syndromes, nerve lesions and peripheral neuropathic processes are among common disorders that are dealt in routine daily practice of neuromusculoskeletal practitioners.

Surgeons, Psychiatrists, Rheumatologists, Neurologists and Therapists are involved in this practice. Different fields of practice such as diagnosis, non-surgical management, surgery and rehabilitation medicine are addressed in this era. For proper and effective management, precise and appropriate diagnosis of the disorders is mandatory. In addition to clinical examination i.e, history and physical examination, There are different tools for quantitative assessment and diagnosis of peripheral nerve disorders. Imaging studies such as sonography, MRI and CT-Scan are among such studies.

Electrodiagnostic medicine consultation (EDX) is by far the most routine and precise evaluation methods for peripheral nerve disorders [1]. In fact by EDX study, physiologic aspects of disorders is precisely evaluated.

EDX is a type of medical consultation performed by a qualified physician who has expertise in neuromuscular medicine practice and must be a physician, that can be psychiatrist "rehabilitation medicine specialist" and/or trained neurologist [2]. In this chapter basics of EDX, with planned, routine and practical electrodiagnostic medicine evaluation of peripheral nerve disorders are discussed. In addition to EDX studies that are used for physiologic study of peripheral nerve disorders, there is increased tendency to use imaging studies such as sonography for anatomic evaluation of the disorders. Sonography has very significant role as an adjuvant diagnostic method for EDX study and could not be regarded as the alternative to electrodiagnostic medicine consultation a brief discussion about application of sonography in peripheral nerve disorders is also given.

2. Electrodiagnostic medicine consultation

EDX is a specific branch of medicine practiced by a trained physician for diagnosis, treatment and prognostication of neuromuscular disorders. In many instances of peripheral nerve disorders such as entrapment syndromes the only reliable and precise tool to

diagnose and differentiate between different types of syndromes is electrodiagnostic medicine studies.(figure 1)

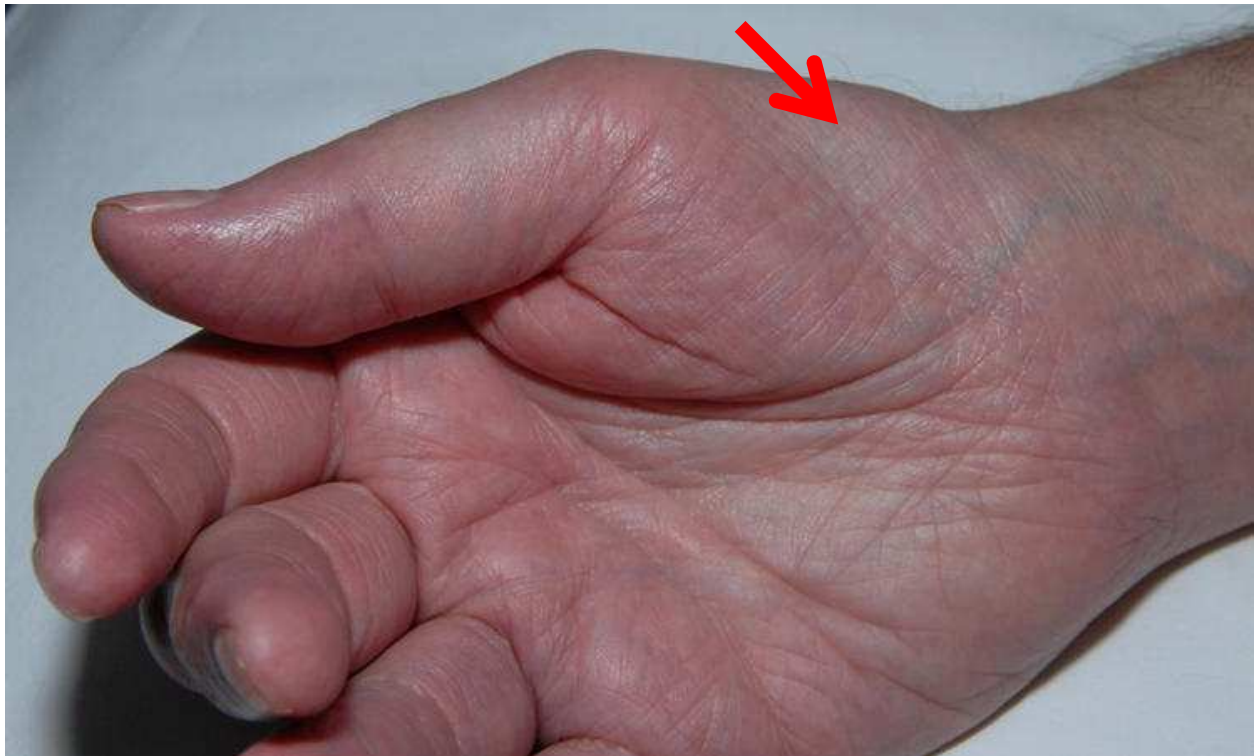

Fig. 1. Thenar atrophy in a 40 Y/O female that could be seen In both CTS and TOS. EDX is unique for differential diagnosis between these 2 entities (From the author personal archive).

There are 2 separate fields of electrodiagnostic medicine study called central and peripheral EDX. In central EDX study by stimulating peripheral sensory systems such as Auditory (cranial nerve VIII) , visual (cranial nerve II) and sensory nerves and recoding from the related cortical and spinal cord areas central nervous disorders are evaluated . These studies that are called auditory brainstem response (ABR), visual evoked potential (VEP) and somatosensory Evoked potentials (SEP) are used mainly for diagnostic evaluation of CNS disorder such as multiple sclerosis, traumatic brain injuries, myelopathic process and other related disorders [3]. There is another type of CNS EDX study called magnetic motor evoked potential "MMEP" that is used for motor stimulation of cortex and spinal cord. MEP is also used for study of deeply seated peripheral nerves such as sciatic, lumbosacral and cervical roots, lumbosacral and brachial plexus. In this study by cortical, spinal cord and/or peripheral nerve stimulation using magnetic coil, proper response is recorded from related limb muscles.

Peripheral EDX study that is used for evaluation of peripheral nervous system disorder i.e motor unit (figure 2) and sensory fibers is composed of nerve conduction studies (NCS) late responses (H-reflex, F-Wave) and needle electromyography (EMG).

The 1st and basic step in performing electrodiagnostic medicine study is pertinent and precise clinical examination including history, physical examination, lab and imaging studies . By Peripheral EDX study, disorders of motor neuron, spinal roots, lumbosacral and

brachial plexus, peripheral nerves, neuromuscular junction and muscles are diagnosed and classified according to the site of involvement, type and severity of the disorder.

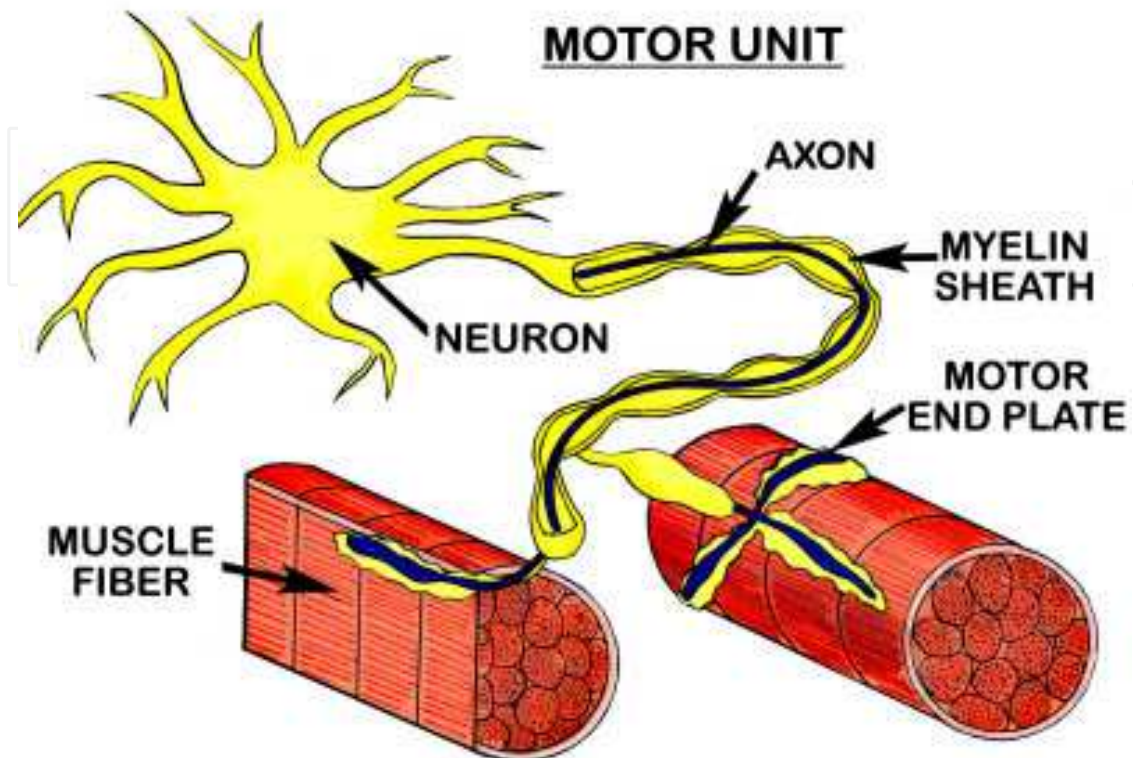


Fig. 2. Typical schematic picture of a motor unit

Taking history and performing physical examination are critical and first step in performing electrodiagnostic medicine consultation. Other items that are critical for EDX evaluation of peripheral nerve disorders include; pathophysiologic types of injuries, timing of study, localization and reinnervation processes that are discussed below [4].

3. History and physical examination

Because in many situations the Electrodiagnostic medicine consultant physician who is performing EDX study, is more familiar and has more experience regarding diagnosis of peripheral nerve disorders and other related musculoskeletal disease than the primary referring physician it is mandatory for EDX physician to take a complete pertinent history and perform physical examination to provide related differential diagnosis list.

Deep and precise knowledge of neuromuscular anatomy is needed for clinical evaluation. Distribution of symptoms and whether it is focal or general is critical for establishing the proper plan of study. Whether symptoms are constant or intermittent and changes during day or night time is another important subject to be funded out in history taking. Chronologic status of the symptoms are important for detection of consequent muscular atrophy and/or trophic skin changes.

Past medical history and family history are in many instances pertinent to the patients present symptom and should be addressed.

In addition to history, that is very important for establishing differential diagnosis, precise and detailed pertinent physical examination is very useful for providing clinical diagnosis of peripheral nerve disorders.

There is four basic and mandatory steps in physical examination of peripheral nerve disorders; Manual Muscle Testing (MMT), quantitative sensory testing including deep and superficial, heat and cold, light and pin prick sensation and two point discrimination should be assessed and is useful in some mild lesions, Deep Tendon Reflexes (DTR) should also be evaluated for detecting abnormalities in reflex arc such as roots lesion.

The fourth step in physical examination is performing provoking tests. These tests are used for putting the nerves in such a jeopardized condition to reveal the symptoms. Phalen test is one of the most sensitive and well known provoking tests that is used for clinical diagnosis of carpal tunnel syndrome.

4. Pathophysiology of peripheral nerve disorders

Nerve injuries classification is according to completeness and/or pathophysiologic bases.

In complete injuries all of the nerve components at the site of injury are disrupted in contrast to incomplete injuries in which some components of nerves are spared. This classification of complete and incomplete type of injury has very important therapeutic and clinical implications.

Segmental demyelination (ie, neurapraxia) and axonal injury with consequent Wallerian degeneration are the two basic pathophysiologic types of nerve injuries (figure 3). In many instances there is mixed type of neurapraxia and axonal injury involving different nerve fibers at the site of nerve injury.

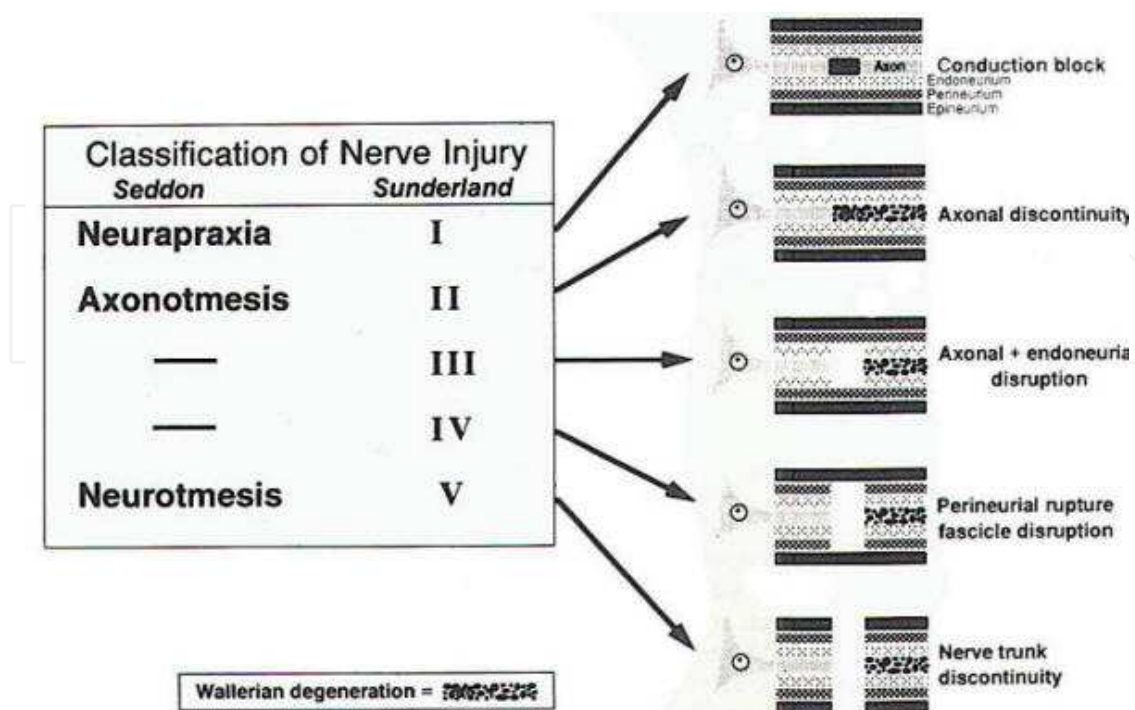


Fig. 3. Pathophysiologic types of nerve injury (from neurosurgery.tv)

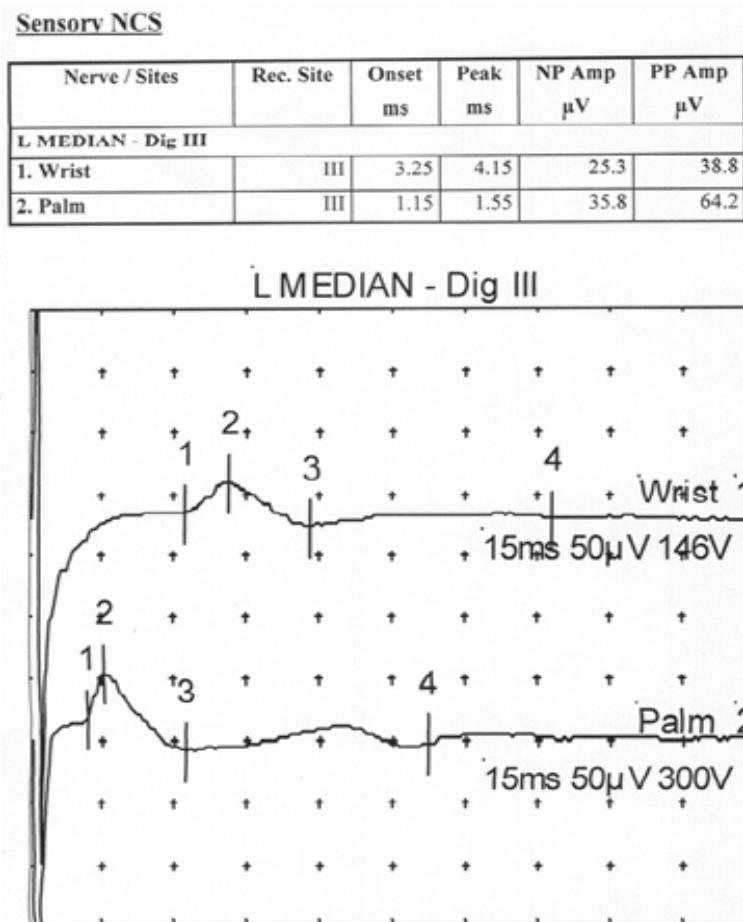


Fig. 4. Mixed type of conduction block and demyelination in a patient with carpal tunnel syndrome (From the author personal archive).

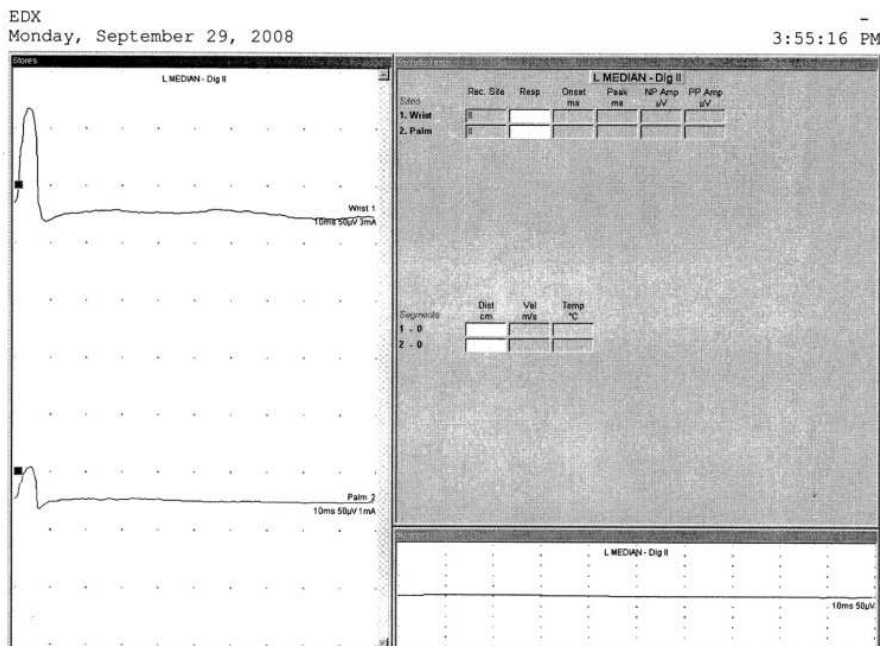


Fig. 5. complete axonal damage with absence of response in distal and proximal stimulation at the site of injury (From the author personal archive).

In neurapraxia with segmental demyelination the nerve fiber axons are intact and no axonal degeneration and nerve destruction occurs. (figure 4) In axonal injury the injured axons undergo a process known as Wallerian degeneration. Axonal function is disrupted immediately after the injury and although the disconnected distal segment initially survives and conducts the applied stimulus over the course of the next 7 days, finally this segment slowly degenerates in a centrifugal fashion and eventually becomes inexcitable.(figure 5) Axonal injuries that spare the supporting perineural connective tissue sheath are known as axonotmetic injury. The intact perineural connective tissue sheaths provide a conduit for axonal regeneration from the cell body to the target muscle, facilitating recovery. Injuries that disrupt the whole nerve, affecting both the axon and supporting connective tissue, are known as neurotmetic lesions. These injuries are less likely to recover by axonal regeneration and often require surgical repair.

Individual axons can exhibit only one of these types of pathophysiologic change, however an injured nerve is composed of thousands of axons, and a mixed pattern of segmental demyelination and axonal loss is manifested.

A precise and timed electrodiagnostic medicine consultation study is very useful and critical for determining the completeness and pathophysiologic type of all nerve injuries[5].

5. Timing of the EDX study

Timing is an important and critical issue especially regarding acute traumatic nerve injuries. Lack of understanding about influence of timing on EDX studies can result to false negative results. Different pathophysiologic type of injury such as neurapraxia, Demyelination and axonal loss can cause different presentation in EDX findings at different time course of the injury[6]. Following are the electrodiagnostic findings in a defined time course

5.1 Onset to day 7

There is no or small nerve conduction study response with proximal stimulation to the site of lesion depending on the severity of the lesion whether it is partial or complete. However in all types of nerve injuries the distal segment response is elicited. There is no or decreased voluntary motor unit action potentials in EMG study of muscles below lesion in all types of lesion including neurapraxia, demyelination or axonal loss.

5.2 Day 7 to 14

This time window is very important and critical to distinguish between neurapraxia (conduction block/demyelination) and axonal damage. In Axonal damage Wallerian degeneration is progressed toward the muscle end organ and distal stimulation to the site of lesion cause no response in motor nerves at seventh day and sensory nerve at tenth day after injury. Instead in neurapraxic lesion the responses will be elicited by distal stimulation. (figure 6)

In both complete neurapraxia and axonal loss lesions there is no voluntary EMG (MUAPS) activities in muscles distal to the lesion.

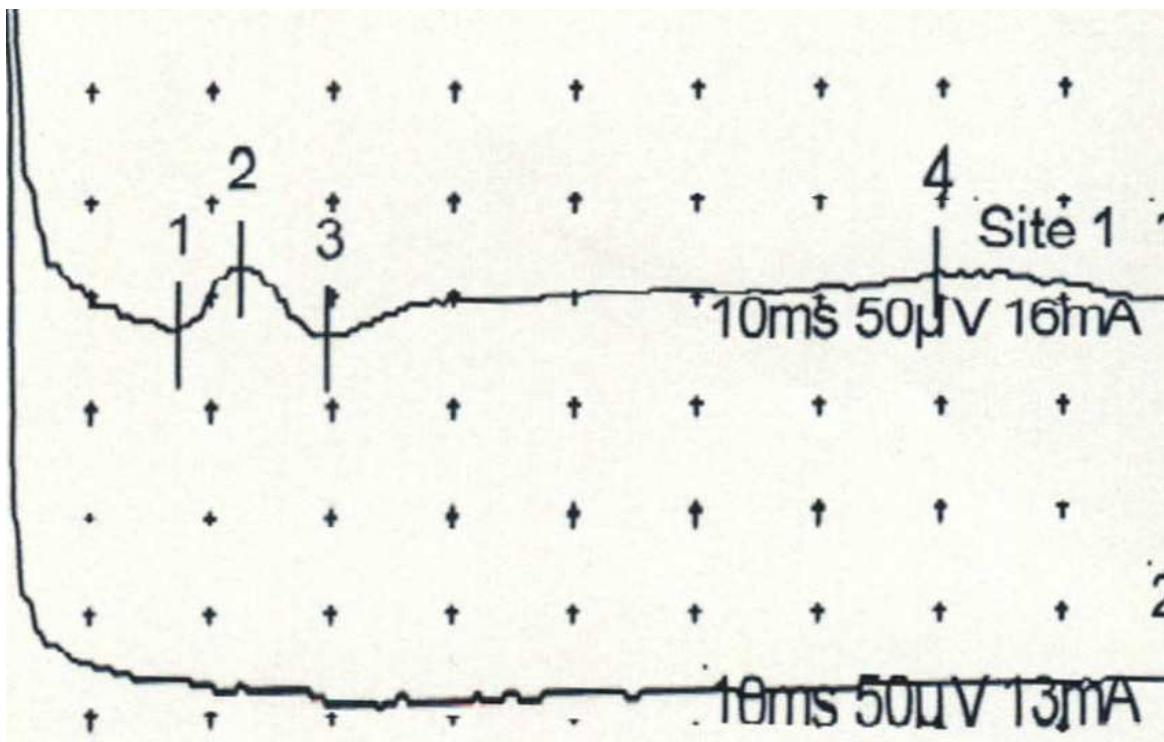


Fig. 6. Pure conduction block with lack of response by proximal stimulation(lower trace) and presence of response by distal stimulation (upper trace) (From the author personal archive).

5.3 Day 14 forward

It takes about 2 to 3 week after onset of injury to see spontaneous EMG potentials. Such as fibrillation and positives sharp waves. These potentials are pathognomonic and specific for detection of axonal loss in peripheral nerve lesions and may persists for a long time(figure7, 8)

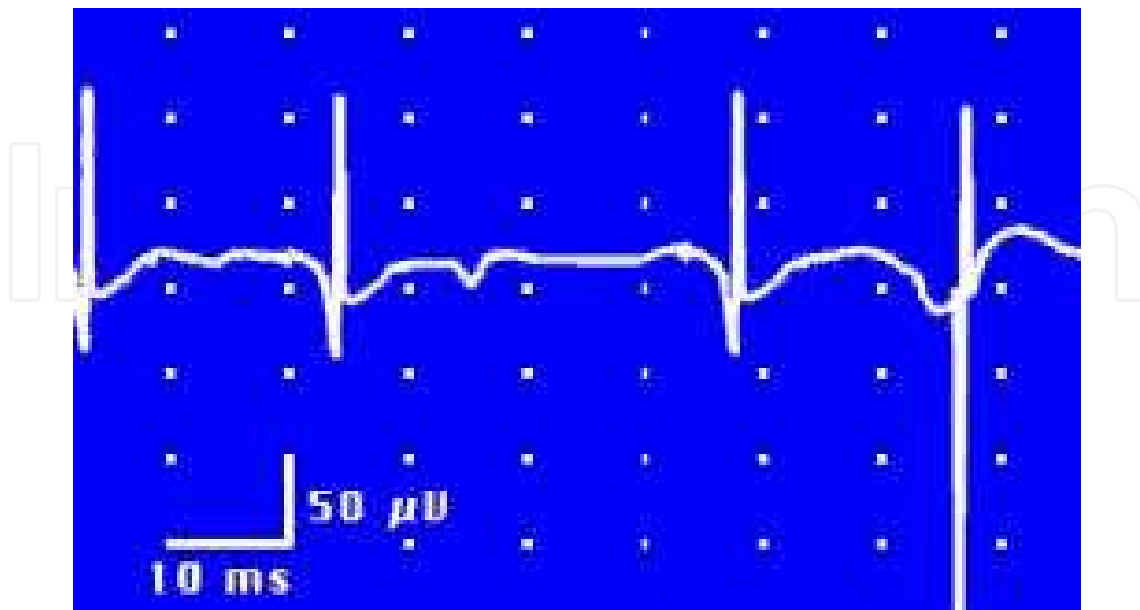


Fig. 7. Fibrillation potentials recorded from denervated muscle 20 days post axonal nerve injury.

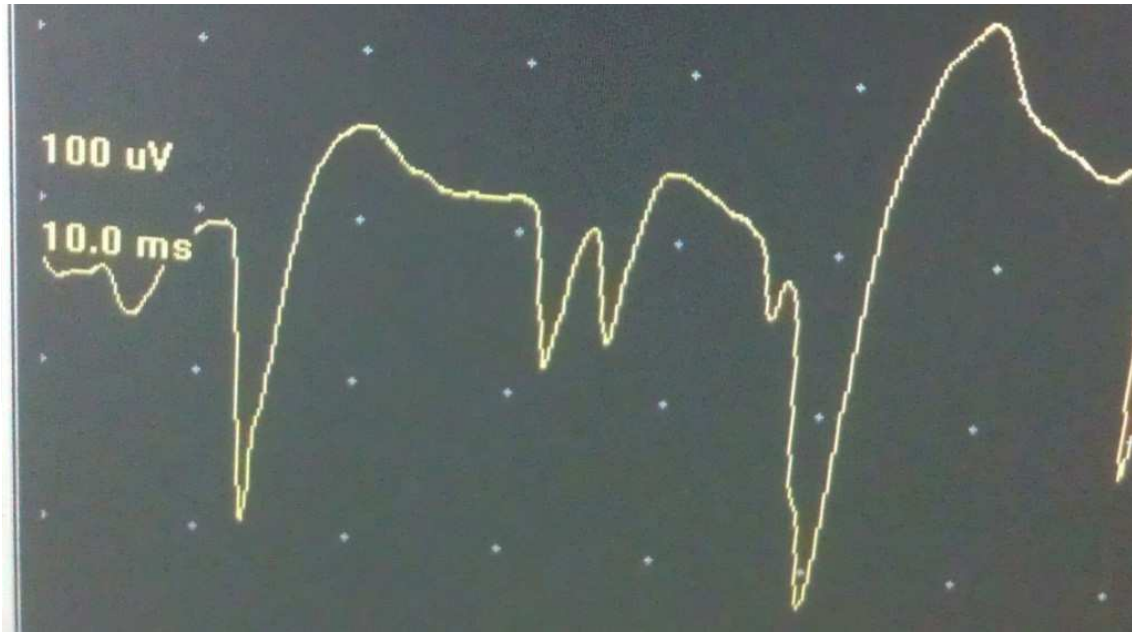


Fig. 8. Positive sharp waves (PSW) recorded from the same muscle at different needle position (The author personal archive).

In contrast to axonal loss, in pure neurapraxic and demyelination it is possible to record the response distal to the site of injury and usually there is no spontaneous activities in needle EMG of distal muscles.

6. Reinnervation process

According to the type of injury; complete or incomplete, there is two main reinnervation process, axonal regrowth and axonal sprouting. Axonal regrowth is occurred in complete axonal injuries proceeding at 1 inch per month and producing short duration and low amplitude motor unit action potentials called nascent MUAPS in needle EMG of involved muscles.

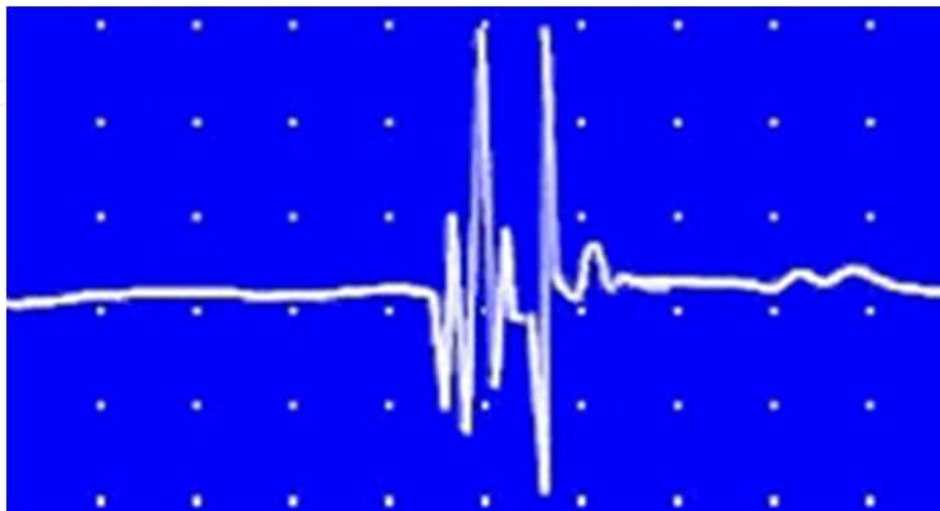


Fig. 9. Polyphasic, long duration, high amplitude MUAPS indicative for reinnervated muscle fibers by axonal sprouting in partial nerve lesion.

In Partial lesions the major process is axonal sprouting that originates from intact axons to innervate orphan muscles fiber cells and producing long duration, high amplitude motor unit action potential in volitional EMC activities (figure 9). In both processes of reinnervation, number of spontaneous activities decreased and distal responses of NCS will be recorded if the reinnervation process continued. Albeit the NCS response nerve reach to the preinjury normal range [7].

7. Localization

One of the most important and key findings in peripheral nerve disorders is localization of the injury site in nerve course. This subject is very important and critical for referring physicians especially surgeons. Both needle EMG and NCS are used for localizing the lesion site. In pure axonal loss with secondary complete Wallerian degeneration, needle EMG of muscles that are located in distal and proximal to the site of presumed injury can localize the injury site.

Knowledge of nerve branching and surface anatomy of peripheral nerve and muscular branching is crucial for the localization .

Nerve conduction studies including distal latency, NCV and amplitude of the recorded responses by proximal and distal stimulation at the presumed site of involvement is more useful in detection of neurapraxia (conduction block) and demyelination types of involvement [8].

8. Prognostication of the injury

There is some factors that are working for prognosis evaluation in peripheral nerve injuries. Pathophysiologic process, i.e axonal loss or demyelination (conduction block), time onset of lesion , severity of the lesion; complete or incomplete and the distance between lesion site and target muscles are the most important determining factors in prognostication of nerve injury [9].

Unfortunately electrodiagnostic studies cannot distinguish between complete axonotmetic and neurotmetic lesions. In contrast demyelination and conduction block processes could be easily distinguished.

Serial, periodic and careful EMG follow up examination could be helpful for distinguishing between neurotmesis and axonotmesis. Lack of suspected regeneration in target muscles in estimated time could be attributed to the neurotmetic type of lesion.

Apparently neurapraxic (conduction block) and demyelination type of lesion have better and good prognosis for recovery compared to axonotmesis and neurotmesis.

This is primary and basic role of electrodiagnostic medicine consultant physician to adequately differentiate between complete and incomplete and also axonotmetic and conduction block/ Demyelination types of injury.

Complete nerve injuries that are predominantly neurapraxic can be expected to recover favorably over the course of weeks to months. When such cases do not recover as expected, patients should undergo follow-up electrodiagnostic testing, which may show the presence of significant secondary axonal loss suggesting that the initial testing was done too early, before the electrophysiologic abnormalities had fully evolved. However, if the follow-up study shows

persistent conduction block across the injury site, then the patient should be evaluated carefully for an ongoing compressive lesion (eg, hematoma) by appropriate imaging studies.

Complete lesions with electrodiagnostic evidence of axonal loss may be axonotmetic or neurotmetic. Axonotmetic injuries are more likely to recover spontaneously. Neurotmetic injuries often require surgical repair for adequate recovery. The only way to differentiate these injury types noninvasively is to monitor the patient for signs of recovery. However, the chances of successful surgical repair begin to decline by 6 months after the injury. By 18-24 months, the denervated muscles usually are replaced by fatty connective tissue, making functional recovery impossible. In most cases, close clinical observation is warranted for 3-6 months after this type of nerve injury. If no clinical or electrophysiologic evidence of recovery is noted during this period, these patients should be referred for surgical exploration.

Indication for surgical exploration and repair include; complete nerve lesions caused by lacerations or penetrating injuries, significant nerve injuries with no clinical or electrodiagnostic evidence of recovery after 3-6 months of clinical observation are also indications for surgical exploration and intraoperative nerve conduction testing and possible surgical repair.

At the time of surgical exploration, the injured nerve may be obviously severed, in which case the injured segment should be resected and an end-to-end anastomosis (usually with an intervening nerve graft) performed. If the injured nerve segment appears to remain in continuity, intraoperative nerve conduction studies can differentiate axonotmetic from neurotmetic injury[10].

The above discussion is mainly focused on electrodiagnostic evaluation of acute traumatic peripheral nerve injuries in which EDX evaluation and assessment has a crucial role for treatment planning. There are a lot of other types of peripheral nerve disorders such as lumbosacral and cervical radiculopathy, plexopathy, entrapment syndromes and peripheral neuropathic processes in which EDX also is highly applicable and has invaluable diagnostic role. These disorders need to be discussed in detail in separate book chapter, however it is worthwhile to mention here that except for time course assessment of the study other issues including localization, prognostication and determining pathophysiologic type of disorders i.e demyelination/axonal involvement are similarly applicable to all types of disorders.

9. Nerve sonography as a complementary method to Electrodiagnostic medicine

High resolution Ultrasonography is a useful method in the evaluation of common neuromuscular disorders as an adjunct to Electrodiagnostic studies (EDX) or independently.[11, 12] Any physician, who is expert in electrodiagnostic medicine, or visits patients with common neuromuscular problems, is likely to improve the care of patients by adding anatomy details of sonography to physiologic data which gathered from EDX. It may confirm Electrodiagnostic findings or find pathologies in case of false negative EDX studies especially in tunnel syndromes[fig10]. [13] Ultrasonography also could identify target muscles more precisely[fig11]; avoid penetrating vasculature [fig12] by EMG needle especially in coagulation disorders and targeting nerves for near nerve conduction studies [fig13]. [14] Risky EMG such as diaphragmatic one could be performed safer under sono guide by real time visualization of diaphragm and lung movements with respiration, which let us accurate estimation and finding optimal needle insertion points and depth . [15]

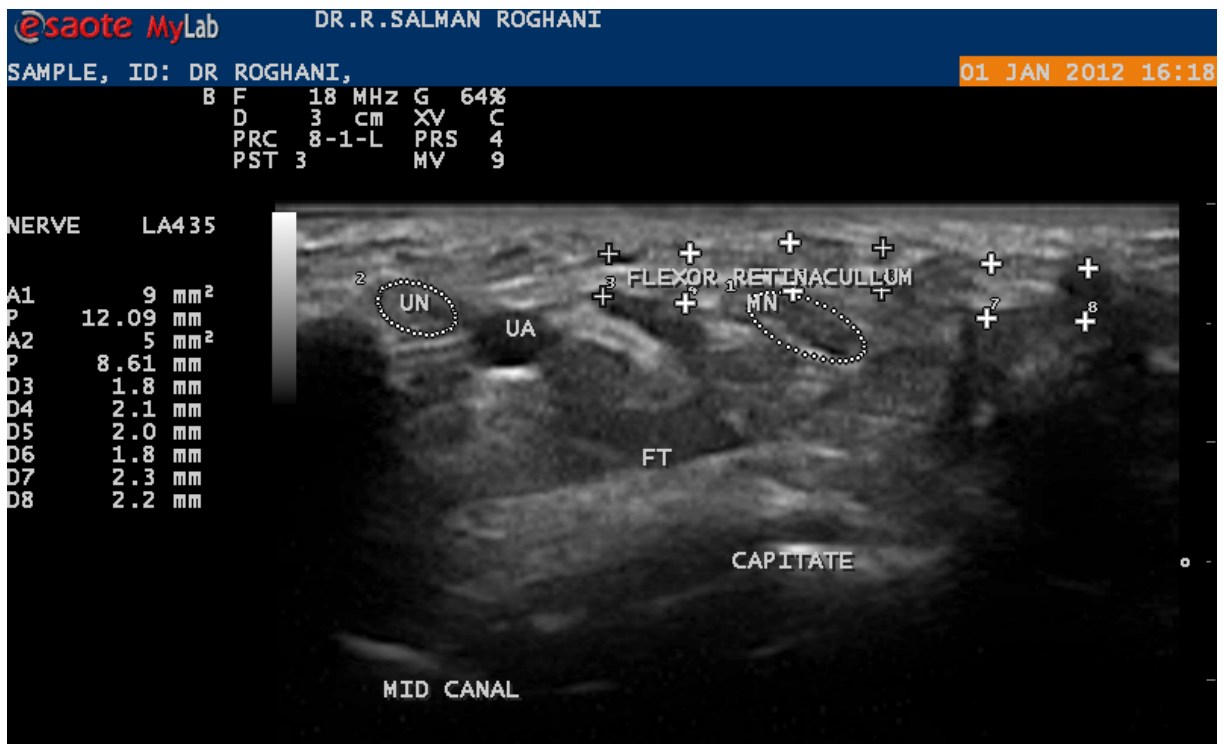


Fig. 10. Ultrasound cross sectional Image at the tunnel of carpal with a lot of anatomic information about region(The author² personal archive)

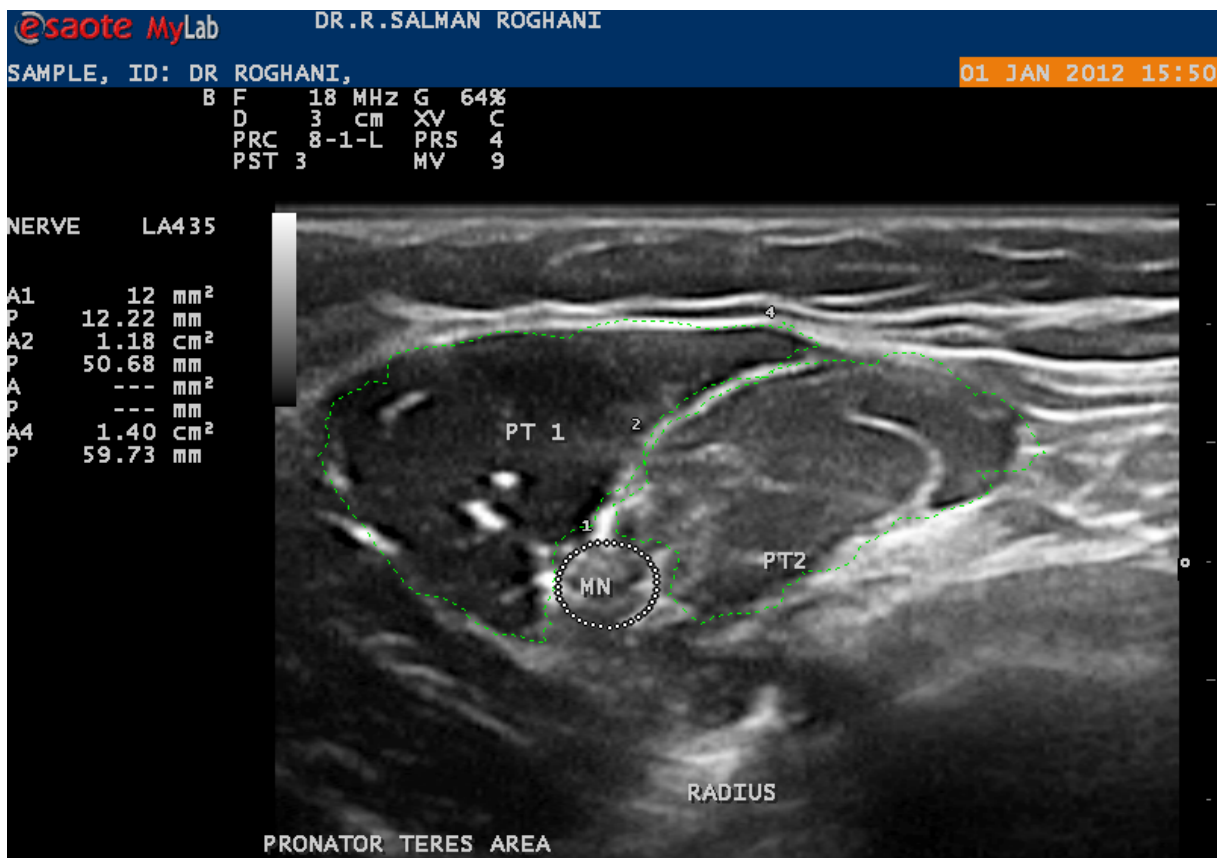


Fig. 11. Precise muscles localization (The author² personal archive)

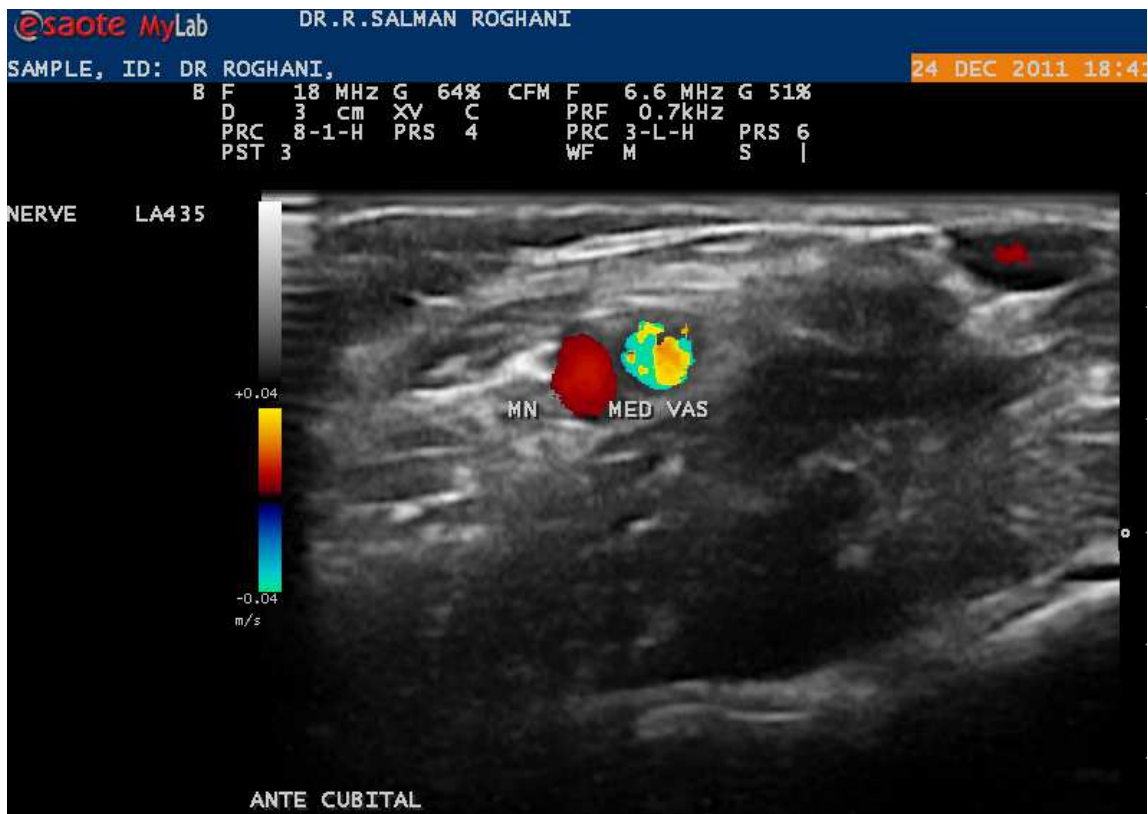

Fig. 12. Doppler Ultrasound image to avoid vasculature penetration (The author² personal archive)

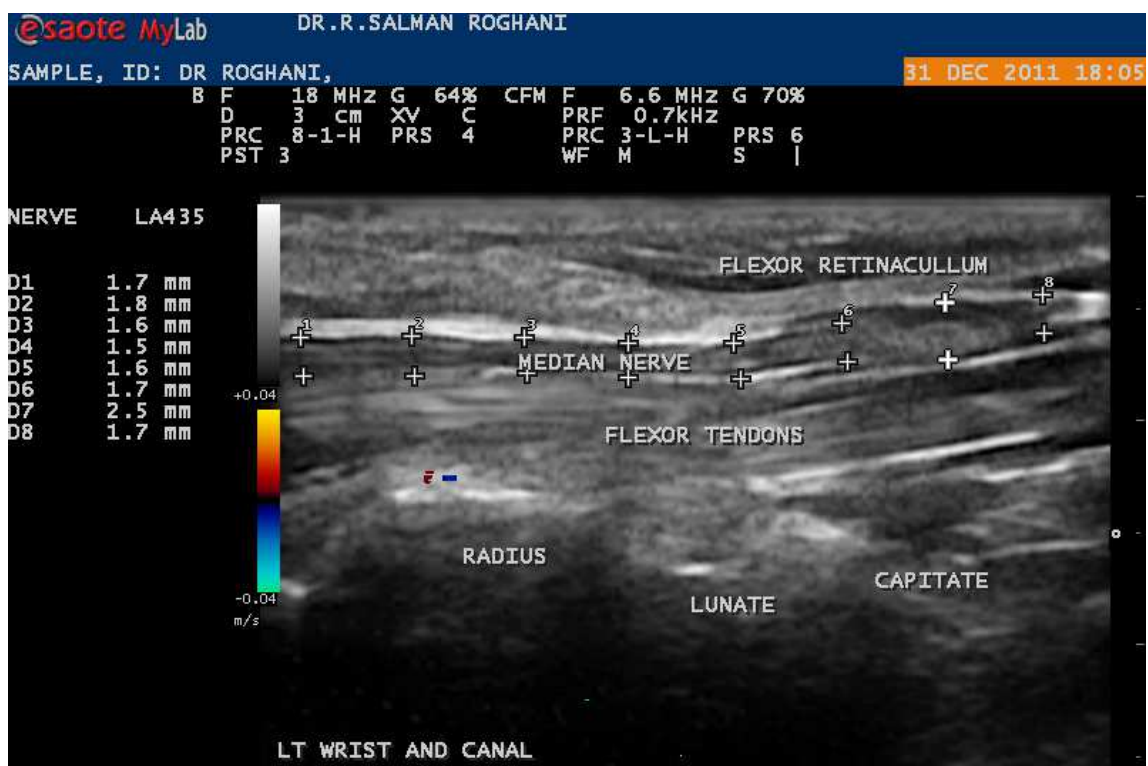


Fig. 13. longitudinal scan of median nerve at wrist which is best for near nerve stimulation or injection. (The author² personal archive)

We found that our residents learn nerve, muscle and joints anatomy more accurately with more interest using ultrasonography guide. Selection of muscles for botulinum toxin denervation and tendons for chronic tendinopathies could be done more precisely under sono guide and also injection of these tissue with more confidence. [16] Doppler mode not only could determine main vasculature and avoid them during needling or injection it also could determine inflammation of nerves in inflammatory neuropathies or tendinopathies. [17]

Real time scanning, reasonable price of instrument comparing to other imaging like CT or MRI and relatively short time of scan in a professional hand and also possibility of immediate scan after or during electromyography, make ultrasound a valuable choice in EDX lab for adding anatomic information to physiologic findings.

10. Summary

Electrodiagnostic medicine consultation is highly sensitive indicator of early nerve injury, detects dynamic and functional injury missed by other diagnostic tools such as MRI, provides information regarding chronicity of nerve injury, provides prognostic data, is highly localizing, clarifies clinical scenarios when one disorder mimics another, identifies combined multi-site injury, avoiding missed diagnoses, identifies more global neuromuscular injury with focal onset.

Electrodiagnostic studies are a supplement to, and not a replacement for the history and physical examination.

Results of EDX are often time-dependent and not “standardized” investigations and may be modified by the practitioner to answer the diagnostic question

All results are dependent on a reliable laboratory with full repertoire of techniques and qualified expert consultant Electrodiagnostician physician.

11. Acknowledgement

I wish to thank my wife through her dedication to helping me having a calm environment for editing this chapter and the book, her support in making sure I finally finished this work.

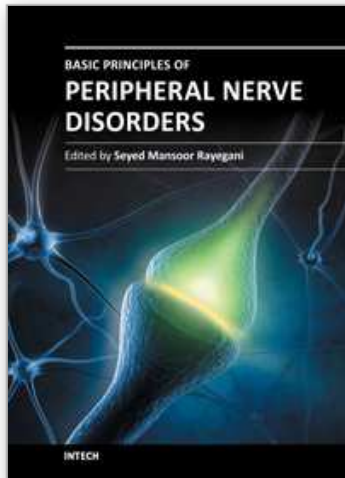
I would also like to thank my daughter, Negar who helped me for arranging the web search and also thanks my son, Hesam for his help in preparing electronic form of my personal archive.

12. References

- [1] Van Beek AL. *Hand Clin.* 1986 Nov;2(4):747-60.
- [2] Daniel Dumitru, Anthony A. Amato, Machiel Zwarts. *Electrodiagnostic Medicine.* Hanley & Belfus (2001).
- [3] *Physical Medicine and Rehabilitation: Principles and Practice*, 4th ed., vol. 1, pp. 105-139. Philadelphia: Lippincott Williams and Wilkins.
- [4] *Johnson's Practical Electromyography*, 4th Edition By William S. Pease, Henry L. Lew, Ernest W. Johnson

- [5] Stewart JD. Focal Peripheral Neuropathies. New York: Raven Press;1993
- [6] Johnson's Practical Electromyography, 4th Edition pp.259-262 By William S. Pease, Henry L. Lew, Ernest W. Johnson
- [7] Korte N, Schenk HC, Grothe C, Tipold A, Haastert-Talini K. Muscle Nerve. 2011 Jul;44(1):63-73
- [8] Kimura J: Electrodiagnosis in Diseases of Nerve and Muscle: Principles and Practices (Ed 3), Oxford University Press 2001.
- [9] Derr JJ, Micklesen PJ, Robinson LR. Am J Phys Med Rehabil. 2009 Jul;88(7):547-53.
- [10] Brown WF, Veitch J. AAEM minimonograph #42: intraoperative monitoring of peripheral and cranial nerves. Muscle Nerve. Apr 1994;17(4):371-7.
- [11] Chiou, H.J., et al., Peripheral nerve lesions: role of high-resolution US. Radiographics, 2003. 23(6): p. e15.
- [12] Koenig, R.W., et al., High-resolution ultrasonography in evaluating peripheral nerve entrapment and trauma. Neurosurg Focus, 2009. 26(2): p. E13.
- [13] Zyluk, A., P. Puchalski, and P. Nawrot, [The usefulness of ultrasonography in the diagnosis of carpal tunnel syndrome--a review]. Chir Narzadow Ruchu Ortop Pol, 2010. 75(6): p. 385-91.
- [14] Zheng, H., et al., [Evaluation of safety and anesthetic effect for ultrasound-guided cervical plexus block]. Zhonghua Yi Xue Za Zhi, 2011. 91(27): p. 1909-13.
- [15] Boon, A.J., et al., Ultrasound-guided needle EMG of the diaphragm: technique description and case report. Muscle Nerve, 2008. 38(6): p. 1623-6.
- [16] Davidson, J. and S. Jayaraman, Guided interventions in musculoskeletal ultrasound: what's the evidence? Clin Radiol, 2011. 66(2): p. 140-52.
- [17] Jacob, D., M. Cohen, and S. Bianchi, Ultrasound imaging of non-traumatic lesions of wrist and hand tendons. Eur Radiol, 2007. 17(9): p. 2237-47.

IntechOpen



Basic Principles of Peripheral Nerve Disorders

Edited by Dr. Seyed Mansoor Rayegani

ISBN 978-953-51-0407-0

Hard cover, 278 pages

Publisher InTech

Published online 28, March, 2012

Published in print edition March, 2012

Peripheral nerve disorders are comprising one of the major clinical topics in neuromusculoskeletal disorders. Sharp nerve injuries, chronic entrapment syndromes, and peripheral neuropathic processes can be classified in this common medical topic. Different aspects of these disorders including anatomy, physiology, pathophysiology, injury mechanisms, and different diagnostic and management methods need to be addressed when discussing this topic. The goal of preparing this book was to gather such pertinent chapters to cover these aspects.

How to reference

In order to correctly reference this scholarly work, feel free to copy and paste the following:

S. Mansoor Rayegani and R. Salman Roghani (2012). Electrodiagnostic Medicine Consultation in Peripheral Nerve Disorders, Basic Principles of Peripheral Nerve Disorders, Dr. Seyed Mansoor Rayegani (Ed.), ISBN: 978-953-51-0407-0, InTech, Available from: <http://www.intechopen.com/books/basic-principles-of-peripheral-nerve-disorders/electrodiagnostic-medicine-consultation-in-peripheral-nerve-disorders>

INTECH
open science | open minds

InTech Europe

University Campus STeP Ri
Slavka Krautzeka 83/A
51000 Rijeka, Croatia
Phone: +385 (51) 770 447
Fax: +385 (51) 686 166
www.intechopen.com

InTech China

Unit 405, Office Block, Hotel Equatorial Shanghai
No.65, Yan An Road (West), Shanghai, 200040, China
中国上海市延安西路65号上海国际贵都大饭店办公楼405单元
Phone: +86-21-62489820
Fax: +86-21-62489821

© 2012 The Author(s). Licensee IntechOpen. This is an open access article distributed under the terms of the [Creative Commons Attribution 3.0 License](#), which permits unrestricted use, distribution, and reproduction in any medium, provided the original work is properly cited.

IntechOpen

IntechOpen