

# We are IntechOpen, the world's leading publisher of Open Access books Built by scientists, for scientists

5,200

Open access books available

128,000

International authors and editors

150M

Downloads

Our authors are among the

154

Countries delivered to

TOP 1%

most cited scientists

12.2%

Contributors from top 500 universities



WEB OF SCIENCE™

Selection of our books indexed in the Book Citation Index  
in Web of Science™ Core Collection (BKCI)

Interested in publishing with us?  
Contact [book.department@intechopen.com](mailto:book.department@intechopen.com)

Numbers displayed above are based on latest data collected.  
For more information visit [www.intechopen.com](http://www.intechopen.com)



# Bisphosphonates and Bone

Sirmahan Cakarer, Fırat Selvi and Cengizhan Keskin  
*Istanbul University, Dentistry Faculty,  
Department of Oral and Maxillofacial Surgery  
Turkey*

## 1. Introduction

Bisphosphonates are pyrophosphate analogues which were used for over a century in industry (mainly in the textile and oil industries) as antiscaling and anticorrosive agents because of their property of inhibition of calcium carbonate precipitation. After the discovery of biological effects of bisphosphonates more than 30 years ago, they have now become indispensable in medicine for the treatment of skeletal complications of malignancy, Paget's disease, osteoporosis, multiple myeloma, hypercalcemia and fibrous dysplasia.

Bisphosphonates can be classified into two groups regarding their administration routes as orally or intravenously. The biological action mechanism of bisphosphonates on bone is maintained by their inhibitory effects on osteoclasts.

The general side effects and complications associated with bisphosphonates are esophageal or gastric irritation, atypical bone fractures, osteonecrosis of the jaws and ocular inflammation. Among these complications, Bisphosphonate-related Osteonecrosis of the Jaws (BRONJ) attracts clinical attention because of its difficult management and its pathogenesis still being unclear.

The present chapter reviews history, classification, pharmacokinetics, clinical relevance and the mechanism of action of bisphosphonates. This chapter also focuses on the common side effects associated with these drugs, including mainly the Bisphosphonate-related Osteonecrosis of the Jaws (BRONJ). The importance of the consultation in between the medical doctors and the maxillofacial surgeons who experience the complications of bisphosphonates is emphasized. The practitioners who commonly prescribe bisphosphonates, should be aware of the complications of these drugs which may strongly diminish the quality of life of the patients.

## 2. History and development of bisphosphonates

The bisphosphonates, in the past erroneously called diphosphonates, have been known to chemists since the middle of the 19th century, the first synthesis dating back to 1865 in Germany. Their use was industrial (mainly in the textile, fertilizer and oil industries) and, because of their property of inhibiting calcium carbonate precipitation, as preventors of scaling (1). Their use as 'water softeners' was based on their ability to act as sequestering

agents for calcium, and in particular their ability to inhibit calcium carbonate precipitation, as do polyphosphates (2).

In the early 1960s, it is showed that body fluids such as plasma and urine contained inhibitors of calcification. Since it had been known since the 1930s that trace amounts of polyphosphates were capable of acting as water softeners by inhibiting the crystallization of calcium salts, such as calcium carbonate, they proposed that compounds of this type might be natural regulators of calcification under physiological conditions. Fleisch and his colleagues showed that inorganic pyrophosphate, a naturally occurring polyphosphate and a known by-product of many biosynthetic reactions in the body, was present in serum and urine and could prevent calcification by binding to newly forming crystals of hydroxyapatite. It was therefore postulated that pyrophosphate (PPi) might be the agent that normally prevents calcification of soft tissues, and regulates bone mineralization. Pathological disorders, such as the formation of kidney stones, might be linked to disturbances in PPi metabolism. The concentrations of pyrophosphate would be expected to be regulated by hydrolytic enzymes. Studies of the rare inherited disorder, hypophosphatasia, in which lack of alkaline phosphatase is associated with mineralization defects, showed that PPi levels were elevated in both plasma and urine, and verified that alkaline phosphatase was the key extracellular enzyme that hydrolyzes pyrophosphate. Attempts to exploit these concepts by using pyrophosphate and polyphosphates to inhibit ectopic calcification in blood vessels, skin, and kidneys in laboratory animals were successful only when the compounds were injected. Orally administered pyrophosphate and polyphosphates were inactive, due to the hydrolysis of pyrophosphate in the gastrointestinal tract, probably by mucosal brush border phosphatases. During the search for more stable analogues of pyrophosphate that might also have the antimineralization properties of pyrophosphate but that would be resistant to hydrolysis, several different chemical classes were studied. The bisphosphonates (at that time called diphosphonates) were among those studied. Like pyrophosphate, bisphosphonates had high affinity for bone mineral and were found to prevent calcification both *in vitro* and *in vivo*, but, unlike pyrophosphate, were also able to prevent pathological calcification when given orally to rats *in vivo*. This property of being active by mouth was key to their future use in humans. Perhaps the most important step towards the future use of bisphosphonates occurred when we found that bisphosphonates also had the novel property of being able to inhibit the dissolution of hydroxyapatite crystals. This led to studies to determine whether they might also inhibit bone resorption. Many studies using a variety of experimental systems showed that they were able to inhibit osteoclast-mediated bone resorption, both in organ cultures of bone *in vitro*, and in various animal models, e.g. thyroparathyroidectomized rats treated with parathyroid hormone to stimulate bone resorption *in vivo* (3).

### 3. Chemistry of bisphosphonates

Bisphosphonates are stable analogues of naturally-occurring inorganic pyrophosphate. Stability is conferred by a carbon atom replacing the oxygen atom that connects the two phosphates. This renders the molecule resistant to biological degradation. The BPs of clinical interest all have two phosphonate groups that share a common carbon atom (P-C-P). The P-C-P group is resistant not only to chemical but also to enzymatic hydrolysis. As a result, BPs are not converted to metabolites in the body and are excreted unaltered. The two

phosphonate groups have a dual function. They are required both for binding to bone mineral and for cell-mediated antiresorptive activity. Modifications to one or both phosphonate groups can dramatically reduce the affinity of the BP for bone mineral, as well as reduce biochemical potency. The R1 and R2 side-chains attached to the carbon atom are responsible for the large range of activity observed among the BPs. R1 substituents such as hydroxyl or amino enhance chemisorption to mineral, while varying the R2 substituents results in differences in antiresorptive potency of several orders of magnitude. The increased antiresorptive potency observed with the different R2 groups is linked to the ability to affect biochemical activity, e.g., inhibition of the farnesyl pyrophosphate synthase (FPPS) enzyme (1, 4).

#### 4. Classification

There are two classes of bisphosphonate regarding the presence or absence of Nitrogen. Non-Nitrogen containing bisphosphonates are; Etidronate (Didronel), Clodronate (Bonefos, Loron) and Tiludronate. The non-nitrogenous bisphosphonates (disphosphonates) are metabolised in the cell to compounds that replace the terminal pyrophosphate moiety of ATP, forming a nonfunctional molecule that competes with adenosine triphosphate (ATP) in the cellular energy metabolism. The osteoclast initiates apoptosis and dies, leading to an overall decrease in the breakdown of bone (5,6).

On the other hand, bisphosphonates can be classified into two groups regarding their administration routes as orally or intravenously. Orally administered bisphosphonates are; risedronate, alendronate, tiludronate and etidronate. These are usually taken weekly. Intravenously administered bisphosphonates are; pamidronate and zoledronic acid. These are usually administered monthly. On the other hand, ibandronate and clodronate can be administered as orally and intravenously (7,8,9).

Alendronate has a greater bone affinity than risedronate. The recommended weekly dose of alendronate at 70 mg weekly is almost double the potency of the recommended dose of 35 mg risedronate (10).

The duration of effect of bisphosphonates extends far beyond the duration of treatment. The effect of alendronate may be evident for more than five years after discontinuation of treatment and zoledronic acid has been shown to produce a sustained reduction in bone turnover for 12 months following administration of a single dose (8).

#### 5. Pharmacology of bisphosphonates

Bisphosphonates can be given intravenously or orally. When taken orally, they must be taken after a prolonged fast (usually first thing in the morning), with water only, followed by 30-60 min with nothing else by mouth to allow for adequate absorption. Under ideal conditions, less than 1% of an orally administered dose is absorbed; taking a bisphosphonate with food or anything containing divalent cations will completely block its absorption. There is no systemic metabolism. The half-life in plasma is short. Fifty percent of the absorbed dose binds to bone surfaces, mostly avidly at sites of active remodeling. The skeletal capacity is large and the binding sites are virtually unsaturable. The 50% or so that does not bind to bone is excreted rapidly by the kidneys (11).

The renal/nonrenal clearance ratio differs significantly among bisphosphonates; the ratio is approximately 2 for clodronate and 0.3 for pamidronate. This may partly explain the higher dose of clodronate needed for a therapeutic effect. The distribution of the bisphosphonates within the skeleton is not homogeneous; the drug is targeted to sites of skeletal metabolism, where bone mineral is exposed to the surrounding fluids. The degree of skeletal uptake is dependent upon the rate of bone turnover. When the bisphosphonates are incorporated into bone, the half-life is extremely long, to over 10 years, relating to the turnover time of the active skeletal sites. After very high intravenous doses some bisphosphonates accumulate in liver, spleen, lung and kidney (9).

## 6. Mechanism of action

The mechanisms of action of the bisphosphonates in bone metabolism are complex and multifactorial. Although complex mechanisms are involved, the side chains influence the binding affinity (R1 side chain) and the antiresorptive potency (R2 side chain). They act almost exclusively on bone because of their specific affinity to bone where they are deposited in newly formed bone and close to osteoclasts. Although the time in the circulation is short, 30 to 180 minutes, once incorporated into bone they can persist for up to 10 years. Different types of bisphosphonates have differing affinities to bone with the rank order from greatest to least being zoledronate, alendronate, ibandronate, risedronate, etidronate and clodronate. Once in the bone they directly affect mononuclear activity, which is the parent cell of osteoclasts, they disrupt osteoclast mediated, bone resorption and increase apoptosis of osteoclasts. This in turn reduces bone deposition by osteoblasts. The net effect of this is to reduce bone resorption and bone turnover. Angiogenesis is reduced by depression of blood flow and a marked decrease in vascular endothelial growth factor. Epithelial keratinocytes are also inhibited. The net effect of these actions is to reduce healing capacity (10).

Treatment with bisphosphonates also results in a modest increase in bone mineral density (BMD). Non-nitrogen-containing bisphosphonates inhibit osteoclastic activity by producing toxic analogs of ATP that cause cell death. Nitrogen-containing bisphosphonates (*e.g.* alendronate, risedronate, ibandronate, and zoledronate) inhibit an enzyme called farnesyl pyrophosphate synthase, an enzyme in the 3-hydroxy-3-methylglutaryl coenzyme A reductase pathway. Inhibition of this enzyme interferes with a process called prenylation: preventing the addition of 15- and 20-carbon side chains that anchor GTP-binding proteins to the osteoclast cell membrane; this leads to reduced resorptive activity of osteoclasts and accelerated apoptosis (programmed cell death). The rank order of potency for inhibiting farnesyl pyrophosphate synthase is zoledronate \_ risedronate \_\_ ibandronate \_ alendronate, with the more potent heterocyclic bisphosphonates (zoledronate and risedronate) having a more optimal fit than the compounds with an alkyl side chain (alendronate and ibandronate).

Each bisphosphonate has a unique profile of binding affinity and antiresorptive potency that likely results in clinically meaningful differences in the speed of onset and offset of effect, the degree of reduction of bone turnover, uptake in cortical *vs.* trabecular bone and types of antifracture effect (vertebral *vs.* nonvertebral) (11).



### 6.1 Effects of bisphosphonates on bone turnover

The degree of reduction of bone turnover achieved by each bisphosphonate, as well as the duration of action appears to be associated with their mineral-binding affinity and skeletal retention. Bisphosphonates with higher mineral-binding affinity and potential retention, such as alendronate and zoledronate, are associated with greater reduction of bone turnover and have a longer duration of effect after treatment is stopped. Bisphosphonates with lower mineral-binding affinity and retention, such as risedronate and etidronate, appear to reduce bone turnover less and this effect seems to be more readily reversible when therapy stops. In patients treated for 3 years or 7 years with risedronate, bone turnover markers returned to pretreatment levels within 1 year after discontinuation of treatment (12).

## 7. Clinical use of bisphosphonates

The most impressive clinical application of bisphosphonates has undoubtedly been as inhibitors of bone resorption, often for diseases where no effective treatment existed previously, but it took many years for them to become well established. However, the first clinical uses of bisphosphonates were as inhibitors of calcification. Etidronate was the only BP to be used in this way, first in fibrodysplasia ossificans progressiva (FOP, formerly known as myositis ossificans). Etidronate showed some promise in patients who had undergone total hip replacement surgery to prevent subsequent heterotopic ossification and to improve mobility. It was also used to prevent ectopic calcification and ossification, after spinal cord injury and in topical applications in toothpastes to prevent dental calculus. There is a recent and renewed interest in devising effective treatments for calcification in renal failure and vascular disease. One of the other early clinical uses of bisphosphonates was as agents for bone imaging, "bone scanning," for which they still remain outstandingly useful for detecting bone metastases and other bone lesions. The application of pyrophosphate and simple bisphosphonates as bone scanning agents depends on their strong affinity for bone mineral, particularly at sites of increased bone turnover, and their ability to be linked to a gamma-emitting technetium isotope. Bisphosphonates have become the treatment of choice for a variety of bone diseases in which excessive osteoclast activity is an important pathological feature, including Paget's disease of bone, metastatic and osteolytic bone disease, and hypercalcaemia of malignancy, as well as osteoporosis.

Currently there are at least eleven bisphosphonates (etidronate, clodronate, tiludronate, pamidronate, alendronate, ibandronate, risedronate, and zoledronate, and also to a limited extent olpadronate, neridronate and minodronate) that have been registered for various clinical applications in various countries (2).

### 7.1 Bisphosphonates in oncology

Consensus guidance recommendations indicate that all patients with multiple myeloma and radiologically confirmed bone metastases from breast cancer should receive bisphosphonates from the time of diagnosis and continue indefinitely. Bisphosphonate treatment—specifically zoledronic acid—is also appropriate for patients with endocrine-resistant metastatic bone disease from prostate cancer. Patients with other tumours and symptomatic metastasis to bone

should be considered for treatment with zoledronic acid if bone is the dominant site of metastasis, especially if the prognosis is reasonable. Patients with renal cell cancer particularly appear to benefit from treatment. There is extensive experience with intravenous bisphosphonates in breast cancer with zoledronic acid, pamidronate and ibandronate all showing useful clinical activity. For most patients with multiple myeloma intravenous bisphosphonates have become part of routine clinical management.

Over recent years great advances have been made in the development and use of bone-targeted therapy in oncology. The use of bisphosphonates in oncology has had a profound beneficial effect on the management of metastatic bone disease and the prevention of treatment-induced bone loss. Their use should be considered in all patients with bone metastases, especially those with symptoms and without immediately life-threatening extraskkeletal disease. Guidelines for the use of the agents in preventing treatment-induced bone loss are evolving and trials investigating their potential role in the adjuvant setting to prevent metastasis are ongoing. If proven, the clinician will need to decide if the patient is at risk of bone loss, bone metastasis or both, as the dose and frequency of bisphosphonate may differ within each scenario. As a class the agents are well tolerated. Occasional serious toxicities in terms of renal impairment and osteonecrosis of the jaw can be largely avoided through adhering to the recommended dose and infusion times and good preventative dental care respectively (13).

### **7.2 Bisphosphonates in Paget's disease of bone**

Paget's disease is characterised by focal abnormalities of increased bone turnover affecting one or more sites throughout the skeleton. The axial skeleton is preferentially affected, and common sites of involvement include the pelvis (70% of cases), femur (55%), lumbar spine (53%), skull (42%), and tibia (32%). Paget's disease was the first clinical disorder in which a dose dependent inhibition of bone resorption could be demonstrated using bisphosphonates in man, and was well established by the 1980s. The medical treatment of Paget's disease is now reliant almost exclusively on the use of the bisphosphonate class of drugs. There have been gradual improvements in the ability of these drugs to keep the disease under control, starting with etidronate in the 1970s, and progressing through the use of other BPs given by mouth, such as clodronate, tiludronate, alendronate, and risedronate. These days most patients are treated with BPs given by infusion, either as pamidronate or more recently as zoledronic acid (2, 14).

### **7.3 Bisphosphonates in osteoporosis**

Osteoporosis is an emerging medical and socioeconomic threat characterised by a systemic impairment of bone mass, strength, and microarchitecture, which increases the propensity of fragility fractures. Bone mineral density (BMD) can be assessed with dual x-ray absorptiometry (DXA), and osteoporosis is defined by a T score of less than -2.5, ie, more than 2.5 standard deviations below the average of a young adult. About 40% of white postmenopausal women are affected by osteoporosis and, with an ageing population, this number is expected to steadily increase in the near future. The lifetime fracture risk of a patient with osteoporosis is as high as 40%, and fractures most commonly occur in the spine, hip, or wrist, but other bones such as the trochanter, humerus, or ribs can also be affected.

From a patient's perspective, a fracture and the subsequent loss of mobility and autonomy often represent a major drop in quality of life. Additionally, osteoporotic fractures of the hip and spine carry a 12-month excess mortality of up to 20%, because they require hospitalisation and they have subsequently enhanced risk of other complications, such as pneumonia or thromboembolic disease due to chronic immobilisation (15).

A number of bisphosphonates have been evaluated in postmenopausal osteoporosis and investigated in large clinical trials with fracture as an end-point. This has resulted in the licensing of alendronate, risedronate, ibandronate and zoledronic acid for the treatment of postmenopausal osteoporosis. Bisphosphonate therapy acts by lowering the activation frequency and so slows the deterioration in bone architecture. Bisphosphonates are effective in reducing bone turnover, with an earlier decrease in bone resorption than bone formation; there are differences in the time course and magnitude of response, depending on the type and route of administration of the bisphosphonate. There is an increase in BMD that results from filling in of the remodeling space and increasing mineralization of bone tissue. In consequence, there is a reduction in fracture risk in postmenopausal women with osteoporosis. The licensed bisphosphonates exhibit some differences in potency and speed of onset and offset of action. These differences mean that different agents may be more advantageous in different situations. Uncertainties remain around the optimum duration of treatment and treatment holidays, how best to use bisphosphonates with anabolic treatments, and the benefits of treatment in patients who do not have a BMD T-score below  $-2.5$ . (16).

#### **7.4 Bisphosphonates in orthopedic interventions**

The rationale for the potential use of bisphosphonates in orthopedics is similar to that of other uses to limit bone resorption. Recent years have seen a great many studies, both pre-clinical and clinical, exploring the potential application of the BPs to the problems of bone catabolism encountered in orthopedics. To date, the most promising roles for the BPs have been found in prevention of bone collapse following osteonecrosis and in enhancing implant fixation. Combination therapies that have both bone anti-resorptive and anabolic agents also show great promise for orthopedic applications. However, further large scale clinical trials are required to confirm whether these observations translate into a clinical benefit for patients and the development of robust indications for these therapies in orthopedic practice (17).

### **8. Side effects of bisphosphonates**

The esophageal or gastric irritation caused by the oral preparations is an established adverse effect. However, osteonecrosis of the jaw (ONJ) and subtrochanteric fractures have attracted most of the attention mainly because their pathophysiology remains unclear.

#### **8.1 Acute-phase reaction/response**

Twenty four to seventy two hours or even several days after the first administration of an IV nitrogen-containing bisphosphonate, approximately 40% of the patients will experience influenza-like illness with pyrexia, chills, myalgia and arthralgia that tend to resolve within



3 days. This symptomatology can also occur after high oral doses and is associated with an acute-phase reaction. Supportive and symptomatic management with NSAIDs and acetaminophen is sufficient. The proportion of patients affected is decreased substantially following subsequent infusions (18).

## **8.2 Ocular inflammation**

Nitrogen-containing bisphosphonates, usually IV pamidronate administration, have been associated with the development of ocular inflammation in the form of nonspecific conjunctivitis, uveitis, iritis, episcleritis and scleritis, with incidence ranging from 0.046% to 1%. Ocular inflammation can resolve after a short course of corticosteroid treatment and in cases of scleritis bisphosphonate administration must be discontinued. Also, avoidance of bisphosphonates or caution in their use (especially IV) for those with a history of inflammatory eye disease or uveitis is recommended (18).

## **8.3 Gastrointestinal side effects**

Gastrointestinal (GI) problems are often considered to be an inevitable consequence associated with the oral use of bisphosphonates, which are currently extensively prescribed (alendronate, risedronate, and ibandronate) for the prevention and treatment of osteoporosis. However, the results from the major prospective RCTs assessing the reduction of fractures are notable in not showing an excess of GI problems. It is generally acknowledged that upper GI symptoms are very common in elderly patients whether or not bisphosphonates are given. In contrast, the more severe side effects associated with esophageal events such as ulceration are rare but potentially more serious, and were noted in particular after giving oral pamidronate or alendronate. In terms of practical management, the interference of absorption by food as well as these esophageal problems are minimized in patients taking oral bisphosphonates on an empty stomach, first thing in the morning, with sufficient plain water, while remaining in an upright position without eating or further drinking for at least 30 minutes (60 minutes in the case of ibandronate). Strict adherence to these instructions is thought to reduce the incidence of serious esophageal adverse events (12).

## **8.4 Atrial fibrillation**

An international, multicenter, randomized, double-blind, placebo-controlled trial raised by the HORIZON found an increased incidence of serious atrial fibrillation in patients which use zoledronic-acid, as compared with the placebo group (19). While bisphosphonates are targeted to a patient group that is already at higher risk of atrial fibrillation than the background population, current studies from large health databases have identified either no increase or only a small increase in the risk of atrial fibrillation with oral bisphosphonate use, with no apparent added risk of thromboembolic complications (20). Despite the lack of a known biologically plausible explanation for bisphosphonate-induced atrial fibrillation, several potential mechanisms have been hypothesized. Given the absence of any proven mechanism for bisphosphonate-induced arrhythmia formation, continued reports of a possible association will justify the need for additional studies to more fully explore these and other potential mechanisms (21).

### 8.5 Atypical femoral fractures

Although bisphosphonates reduce the rates of fractures due to osteoporosis, recent reports suggested a link between bisphosphonate use and the development of atypical insufficiency fractures. This is thought to be due to long term oversuppression of bone turnover leading to impaired bone remodeling, accumulation of microdamage in bone and increased skeletal fragility (11).

Several publications demonstrated the occurrence of femoral fractures associated with long-term bisphosphonate use (22,23,24,25,26).

These fractures appear to be more common in patients who have been exposed to long-term BPs, usually for more than 3 years (median treatment 7 years). It must be emphasized that these fractures are rare, particularly when considered in the context of the millions of patients who have taken BPs and also when compared with typical and common femoral neck and intertrochanteric fractures. It also must be emphasized that BPs are important drugs for the prevention of common osteoporotic fractures. However, atypical femoral fractures are of concern, and more information is urgently needed both to assist in identifying patients at particular risk and to guide decision making about duration of BP therapy. Physicians and patients should be made aware of the possibility of atypical femoral fractures and of the potential for bilaterality through a change in labeling of BPs. Given the relative rarity of atypical femoral fractures, to facilitate future research, specific diagnostic and procedural codes should be created for cases of atypical femoral fractures, an international registry should be established, and the quality of case reporting should be improved. Research directions should include development of animal models, increased surveillance, and additional epidemiologic data to establish the true incidence of and risk factors for this condition and studies to address their surgical and medical management (27).

A position paper reported by Rizzoli et al, reviewed the evidence for an association between atypical subtrochanteric fractures and long-term bisphosphonate use. They demonstrated that the available evidence does not suggest that the well-known benefits of bisphosphonate treatment are outweighed by the risk of these rare, atypical, low-trauma subtrochanteric fractures. Nevertheless, it is recommended that physicians remain vigilant in assessing their patients treated with bisphosphonates for osteoporosis or associated conditions. They should continue to follow the recommendations on the drug label when prescribing bisphosphonates and advise patients of the potential risks. Patients with pain in the hips, thighs or femur should be radiologically assessed and, where a stress fracture is evident, the physician should decide whether bisphosphonate therapy should be discontinued pending a full evaluation, based on an individual benefit–risk assessment. The radiographic changes should be evaluated for orthopaedic intervention—since surgery prior to fracture completion might be advantageous—or be closely monitored (28).

### 8.6 Bone, joint, or muscle pain

In postmarketing experience, there are infrequent case reports describing severe and occasionally incapacitating bone, joint, and/or muscle pain in patients taking bisphosphonates. The pain could occur days, months, or even years after starting bisphosphonates. It is probably different or, at least, not only associated with the acute-

phase response and presents within the first few days after the first treatment with an IV bisphosphonate. Most patients reported relief of symptoms after discontinuing therapy and a subset had recurrence of pain when restarting treatment with the same or a different bisphosphonate (12).

### **8.7 Bisphosphonate-related Osteonecrosis of the Jaws (BRONJ)**

To distinguish BRONJ from other delayed healing conditions, the following working definition of BRONJ has been adopted by the American Association of Oral and Maxillofacial Surgeon. Patients may be considered to have BRONJ if all of the following 3 characteristics are present: Current or previous treatment with a bisphosphonate ; exposed bone in the maxillofacial region that has persisted for more than 8 weeks and no history of radiation therapy to the jaws. It is important to understand that patients at risk of, or with established, BRONJ can also present with other common clinical conditions not to be confused with BRONJ. Commonly misdiagnosed conditions can include, but are not limited to, alveolar osteitis, sinusitis, gingivitis/periodontitis, caries, periapical pathologic findings, and temporomandibular joint disorders (29,30).

A disease remarkably similar to the presentation of BRONJ was initially described in the match-making industry at the end of the 18th century. Considered by some to be the first identified instance of a disease caused by occupational exposure of a chemical (elemental phosphorus), "phossy jaw" was characterized by bone necrosis and infection that was isolated to the jaw. Recently, some reports have attempted to establish parallels with BRONJ and "phossy jaw." Although the clinical presentations of BRONJ and phossy jaw are quite similar, the chemical agents known to be the cause of these diseases are very different in structure and chemical properties. In reality, BRONJ is likely a disease entity that was no existent prior to the late 1990s, and is linked to the emergence of bisphosphonates as a popular mode of therapy for the treatment of osteolytic bone disease and osteoporosis (31).

BRONJ was first described by Marx and Stern in 2002. At that time it was only a curious finding of exposed, nonhealing bone when debridement was performed, the condition worsened and led to increased amounts of exposed bone. In 2003; Marx described 36 cases associated with intravenous bisphosphonates (pamidronate or zoledronate) in a medical alert published in the Journal of Oral and Maxillofacial Surgery (30,32). Since the original 2003 publication, more than 1,100 additional reports by over 4,500 authors and at least 14 position papers have been written about BRONJ (30).

### **8.8 Osteomyelitis, osteoradionecrosis and BRONJ**

Microscopically, BRONJ presents a picture that may be either suppurative osteomyelitis or osteoradionecrosis. However representative central bone biopsy specimens identify distinct and unique histopathologies that underscore the separate mechanisms of each. Suppurative osteomyelitis shows inflammatory cells in the marrow space. It shows also necrotic bone and viable reactive bone. Osteoradionecrosis, similarly shows necrotic bone but without any marrow inflammation. Instead, the marrow space contains poorly cellular or acellular collagen consistent with marrow fibrosis and the well-documented hypocellular, hypovascular, hypoxic characteristics of radiated tissue. Microorganisms colonize on the

bone surface but do not invade the tissue because osteoradionecrosis is an effect of radiation tissue damage and is not a primary bacterial process. BRONJ, in contrast, shows neither marrow inflammation nor marrow fibrosis. Instead, the marrow has empty acellular marrow spaces along with necrotic bone with numerous Howship lacunae. Surface microorganisms are frequently seen in association with necrotic bone and often prompt an inaccurate diagnosis of osteomyelitis. The clinical description and history remain the best tools available for distinguishing BRONJ from these other conditions of delayed bone and wound healing (30).

### 8.9 Comparison of long bone to alveolar bone and BRONJ

Alveolar bone exists to support the teeth. Its structure varies between individuals and generally it gets denser with age. Broadly, there is a dense bone wall near the gingivae and then the middle portion of the tooth root. There are larger marrow spaces near the tooth apex. The alveolar bone walls at the attachment of the periodontal membrane have a cribiform structure with open channels. The bone structure follows that of bone structure throughout the body with cortical bone containing osteons and Haversian systems. New bone is formed in a lamellar structure by osteoblasts with the osteocytes being incorporated within the bone. Older bone, or bone in the path of erupting or moving teeth is resorbed by osteoclasts. In keeping with all bone in the body, alveolar bone is a dynamic structure with the bone constantly remodelling and adapting to functional needs. The key question however, is whether alveolar bone is exactly the same as the long bones or whether it is subtly different. Alveolar bone develops as a membrane bone whereas the limbs and vertebrae develop as endochondral bones. The mandible is of neural crest origin whereas the limbs and vertebral column are of mesodermal origin. There are minor phenotypic differences between osteoblasts depending on their site of origin and anatomical location, which can be demonstrated biochemically. Membrane bone osteoblasts also have an increased rate of cell division as compared to iliac crest osteoblasts. Osteoclasts are derived from mononuclear precursor cells which migrate from the bone marrow via the vasculature to the bone site. Their function is dictated largely by interaction with the osteoblasts in the area. There are biochemical differences between osteoclasts of membrane bone origin and long bone origin. There are also differences in behaviour between giant cell tumours of the jaws and of the long bones. The long bone is deeply covered in soft tissue and they are not commonly exposed. On the other hand the alveolar bone is covered only mucoperiostally. The long bones are low vascular than the alveolar bone (10).

The alveolar crest remodels at 10 times greater than the rate of tibia, 5 times the rate of the mandible at the inferior border, and 3-5 times the rate of the mandible at the level of the mandibular canal. As a result, the alveolar bone of the jaws has a greater uptake of bisphosphonates and readily accumulates at higher concentrations. It is also reported that the alveolar bone depends more on osteoclastic bone resorption/remodeling and renewal than any other bone in the adult skeleton. The jaws are repeatedly traumatised by mastication and they expose to the oral environment and commensal micro-organisms more than the long bones. All these differences between the jaws and the other bones, explain why only the jaws are affected. To date it has not been reported in other skeletal sites as exposed bone; however, recent reports have identified femur fractures caused by long-term use of bisphosphonates (30).

### 8.10 Causality of BRONJ

Epidemiologic studies have established a compelling, albeit circumstantial, association between IV bisphosphonates and BRONJ in the setting of malignant disease. An association between IV bisphosphonate exposure and BRONJ may be hypothesised based on the following observations: (i) a positive correlation between bisphosphonate potency and risk for developing BRONJ; (ii) a negative correlation between bisphosphonate potency and duration of bisphosphonate exposure prior to developing BRONJ; and (iii) a positive correlation between duration of bisphosphonate exposure and developing BRONJ. However, the current level of evidence does not fully support a cause and effect relationship between bisphosphonate exposure and necrosis of the jaw. Although causality may never be proven, emerging experimental and epidemiologic studies have established a firm foundation for a strong association between monthly IV bisphosphonate therapy and BRONJ. The causal association between oral or IV bisphosphonates for treating osteoporosis and BRONJ is much more difficult to establish (29).

### 8.11 Incidence of BRONJ

IV bisphosphonate exposure in the setting of managing malignancy remains the major risk factor for BRONJ. According to case series, casecontrolled studies, and cohort studies, estimates of the cumulative incidence of BRONJ have ranged from 0.8% to 12%. Patients receiving oral bisphosphonate therapy are at a considerably lower risk of BRONJ than cancer patients treated with monthly IV bisphosphonates.

The clinical efficacy of oral bisphosphonates for the treatment of osteopenia/osteoporosis is well established and is reflected in the fact that over 190 million oral bisphosphonate prescriptions have been dispensed worldwide. Based on available data, the risk of BRONJ for patients receiving IV bisphosphonates is significantly greater than that for patients receiving oral bisphosphonates. Regardless, given the large number of patients receiving oral bisphosphonates for the treatment of osteoporosis/osteopenia, it is likely that most practitioners will encounter some patients with BRONJ. It is important to accurately determine the incidence of BRONJ in this population and to assess the risk associated with long-term use (ie, longer than 3 years) of oral bisphosphonates. The low prevalence of BRONJ in osteoporosis patients poses a significant challenge for future clinical trials aimed at establishing accurate incidence data (29).

### 8.12 Risk factors of BRONJ

BRONJ risks were categorized as drug-related, local, and demographic, systemic, genetic and preventative factors. Other medications, such as steroids and thalidomide, and other chemotherapeutic agents were thought to be risk factors, but no measurable associations were identified (29).

Drug-related risk factors include bisphosphonate potency and duration of therapy. Zoledronate (Zometa®) is more potent than pamidronate (Aredia®) and pamidronate (Aredia®) is more potent than the oral bisphosphonates; the IV route of administration results in a greater drug exposure than the oral route. Using a number of different risk measures, the BRONJ risk among cancer patients given IV bisphosphonate exposure



ranged from 2.7 to 4.2, suggesting that cancer patients receiving IV bisphosphonates have a 2.7- to 4.2-fold increased risk for BRONJ than cancer patients not exposed to IV bisphosphonates. Longer duration of the use of bisphosphonates appears to be associated with increased risk.

Local risk factors include; dentoalveolar surgery, including, but not limited to extractions, dental implant placement, periapical surgery, periodontal surgery involving osseous injury. Patients receiving IV bisphosphonates and undergoing dentoalveolar surgery are at least seven times more likely to develop BRONJ than patients who are not having dentoalveolar surgery.

It has been observed that lesions are found more commonly in the mandible than the maxilla (2:1 ratio) and more commonly in areas with thin mucosa overlying bony prominences such as tori, bony exostoses and the mylohyoid. No data are available to provide risk estimates for anatomic structures and BRONJ.

Cancer patients exposed to IV bisphosphonates with a history of inflammatory dental disease, for example periodontal and dental abscesses, are at a sevenfold increased risk for developing BRONJ.

#### **8.12.1 Demographic and systemic factors**

Sex was not statistically associated with BRONJ. Race was reported in one study to be a risk factor, with Caucasians having an increased risk for BRONJ compared with blacks. Other systemic factors or conditions, that is renal dialysis, low haemoglobin, obesity and diabetes, were variably reported to increase the risk for BRONJ. Malignancy type was not statistically associated with an increased risk for BRONJ.

#### **8.12.2 Genetic factors**

It is reported that genetic perturbations, that is single nucleotide polymorphisms (SNPs), in the cytochrome P450-2C gene (CYP2C8) gene were associated with an increased risk for BRONJ among multiple myeloma patients treated with IV bisphosphonates.

#### **8.12.3 Preventative factors**

Alternative dosing schedules that reduce IV bisphosphonate exposure have comparable outcomes in terms of preventing a decreased risk of BRONJ.

The two largest risk factors for BRONJ are IV bisphosphonate exposure and dentoalveolar procedures. Recent studies suggest that manipulation of IV bisphosphonates dosing may be effective for minimising BRONJ risk. In addition, preventative dental interventions before initiating IV bisphosphonate treatment can also effectively reduce, but not eliminate, the risk of BRONJ (29).

### **8.13 Clinical management of BRONJ**

The management of BRONJ currently is a dilemma. No effective treatment has yet been developed and interrupting bisphosphonate therapy does not seem to be beneficial because

the drugs accumulate at high levels inside the bone matrix. However, cessation of bisphosphonate therapy can have severe problems, such as bone metastasis, multiple myeloma or hypercalcemia associated with tumors. In general all the guidelines related to the management of BRONJ recommended a nonsurgical approach consisting of a mix of medical therapies.

Treatment of BRONJ focuses on controlling pain, limiting secondary infection and extension of the exposed bone and maintaining function. These are achieved with the use of 0.12 % chlorhexidine, 15 mL oral swish and spit three times daily. To control the pain of initial secondary infection Penicilin VK 500 mg by mouth four times daily can be used. If the patient is allergic to penicilin, alternatives are; doxycycline 100 mg once daily, levofloxacin 500 mg once daily, azithromycin 500 mg once daily. In patients who have a minimal response to these antibiotic regimens, adding metronidazole 500 mg three times daily for 10 days can resolve the secondary infection. More or less aggressive surgery is recommended only in advanced, nonresponsive cases. Surgical treatment, in accordance to AAOMS position paper, is reserved to patients affected by BRONJ lesions (30).

## 9. Clinical cases

The present chapter presents 3 clinical cases that were managed by the authors in Istanbul University, Dentistry Faculty, Department of Oral and Maxillofacial Surgery. The cases presented here show the importance of the clinical situation, to the all medical doctors which prescribe bisphosphonates. These cases presents also that the life quality of the patients can be very low because of this situation.

### 9.1 CASE 1

A 65-year-old woman has presented with a complaint of pain in the right side of the maxilla. Clinical examination of the patient showed a large necrotic mass of bone on the right half of the maxilla (Figure 1). The patients's medical history involved multiple myeloma disease resisting for more than 3 years. She informed that she had been using zoledronic acid for the last 1 year for the management of this disease. During this period, she had undergone multiple tooth extractions at the right side of the maxilla. MRI findings and orthopantomograph showed the necrotic bone (Figure 2, Figure 3). Clinical and radiological examinations, along with the medical anemnesis taken, revealed the diagnosis of "BRONJ".

Initially, a drug holiday has started for zoledronic acid after consultation with the patient's physician. Along with this, oral amoxicillin with clavulanic acid 1000 mg two times daily, combined with oral metronidazole 500 mg two times daily were prescribed. These were used for two months. 0.12% chlorhexidine oral rinsing 3 times daily was also used during this period for maintaining good oral hygiene. This type of treatment resolved the acute reactions and pain. Even though this treatment did not help the formation of a demarcation line of the necrotic bone, there wasn't either a progress in the enlargement of the necrotic area too. Bone resection was not permitted because of the severe multiple myeloma. The patient is still followed up continuously every three months.

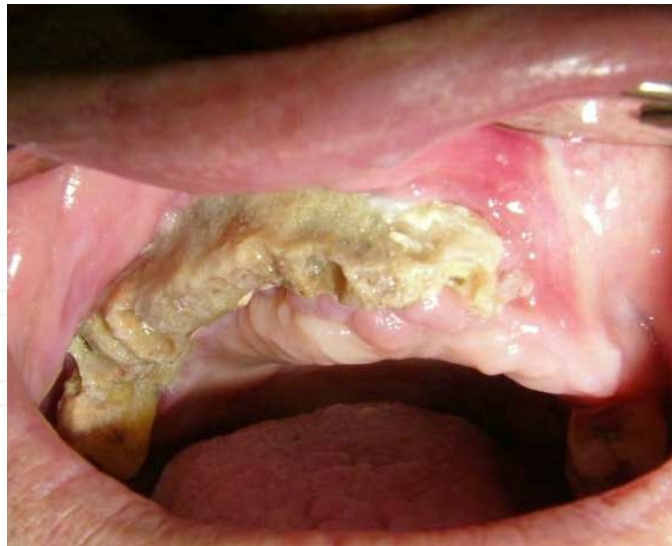

Fig. 1. Clinical view of the necrotic bone.

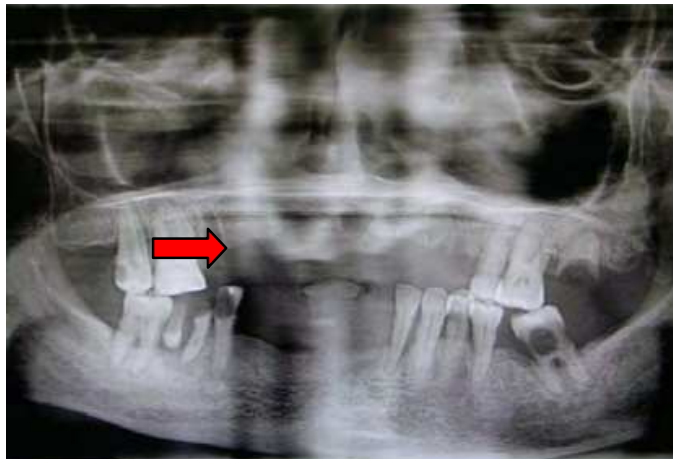


Fig. 2. Orthopantomograph showing the necrotic bone.

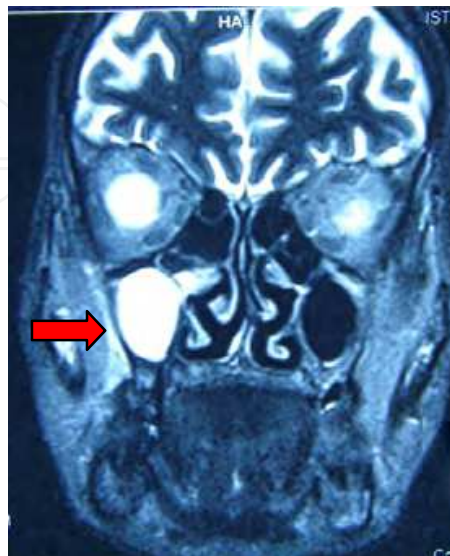


Fig. 3. MRI showing the infected right maxillary sinus.

## 9.2 CASE 2

A 75-year-old male patient has presented with a complaint of pain in the right side of the maxilla. Clinical examination has shown a large mass of exposed necrotic bone in the right side of the maxilla with the swelling of the palatal mucosa (Figure 4). The patient has been diagnosed with multiple myeloma for two years. He has informed that he had been using zoledronic acid since the beginning of his disease. Orthopantomograph has shown the necrotic area (Figure 5).

Initially, a drug holiday has started for zoledronic acid after consultation with the patient's physician. Along with this, oral amoxicillin with clavulanic acid 1000 mg two times daily, combined with oral metronidazole 500 mg two times daily were prescribed. These were used according to two months usage and one month holiday protocol. 0.12% chlorhexidine oral rinsing 3 times daily was also used during this period for maintaining good oral hygiene. This type of treatment resolved the acute reactions and pain. After one and a half years of conservative treatment, sequestrum formation was observed and it was peeled off by itself. (Figure 6 and Figure 7). The patient is followed up continuously every three months.

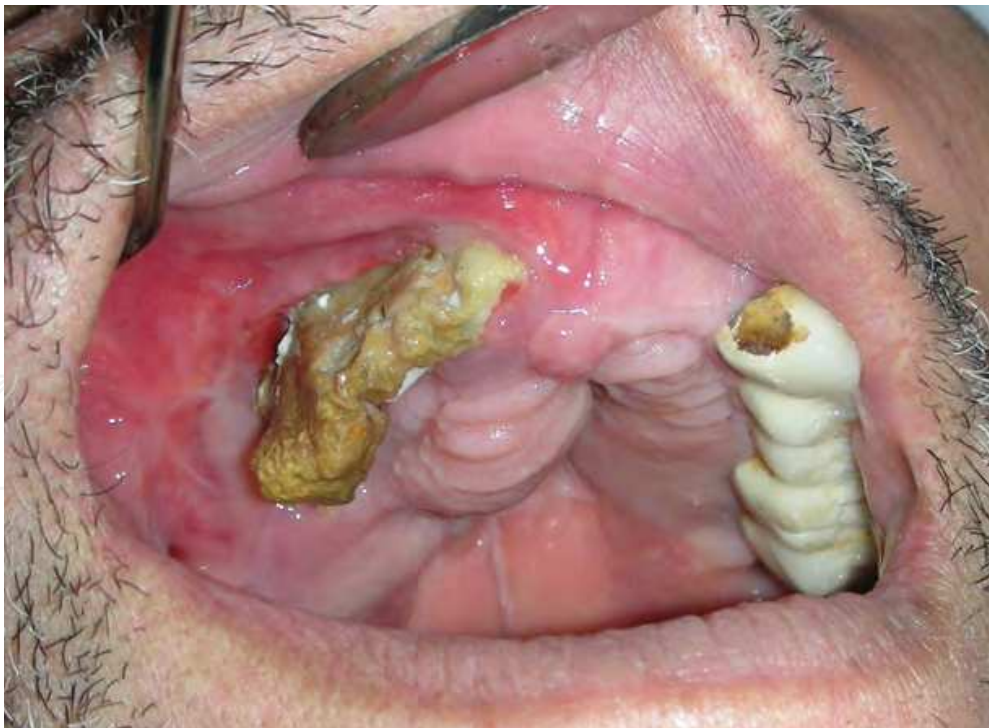


Fig. 4. Clinical view of the exposed bone.



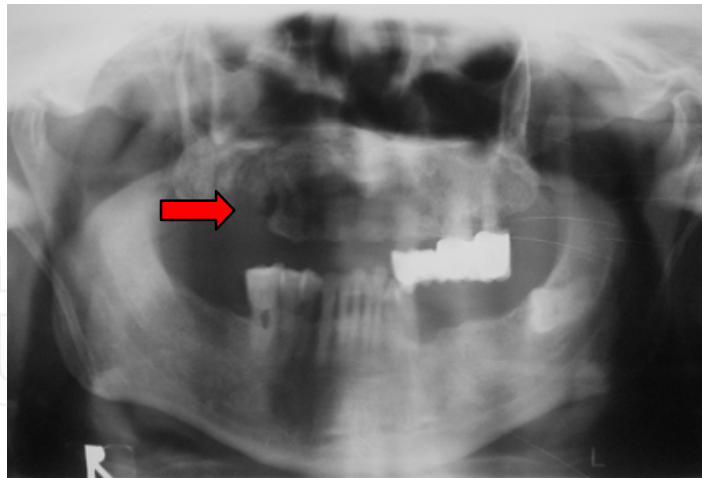


Fig. 5. Orthopantomograph showing the necrotic bone.

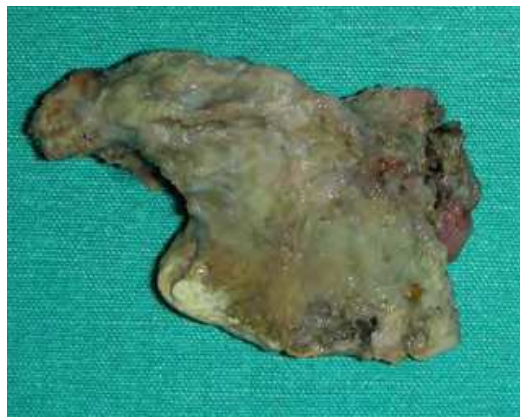

Fig. 6. Sequestrum's clinical appearance at the right side of the mandible.

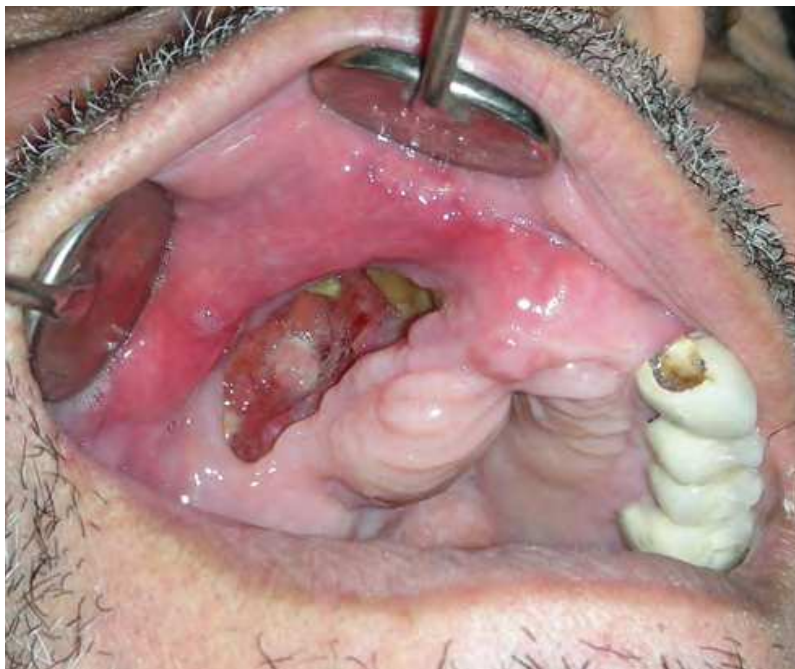


Fig. 7. Clinical view of the affected area after the removal of the sequestrum.



### 9.3 CASE 3

52-year-old woman was referred to our clinic with pain and exposed bone at the right mandibular posterior area (Figure 8). In 1997, she had undergone mastectomy for her breast cancer. In between the years 2001 and 2006, she had used zoledronic acid for her bone metastasis related with her breast cancer. In 2006, bisphosphonate related osteonecrosis of the right mandibular area was diagnosed in a private clinic. Her physician had decided to discontinue zoledronic acid and instead had prescribed ibandronat. A local curettage and debridement was performed in the private clinic before applying to our clinic. In the orthopantomograph, the necrotic bone was clearly observed (Figure 9). Amoxicillin with clavulonic acid combined with metronidazole was used to suppress her infection. After a drug holiday of three month; in december 2010, we performed local curettage and debridement using Er,Cr: YSGG laser and the wound was closed primarily (Figure 10, Figure 11). Postoperative clinical and radiological examination did not reveal any sign of osteonecrosis or infection, 6 months after the operation (Figure 12, Figure 13) The patient is followed up continuously every three months.

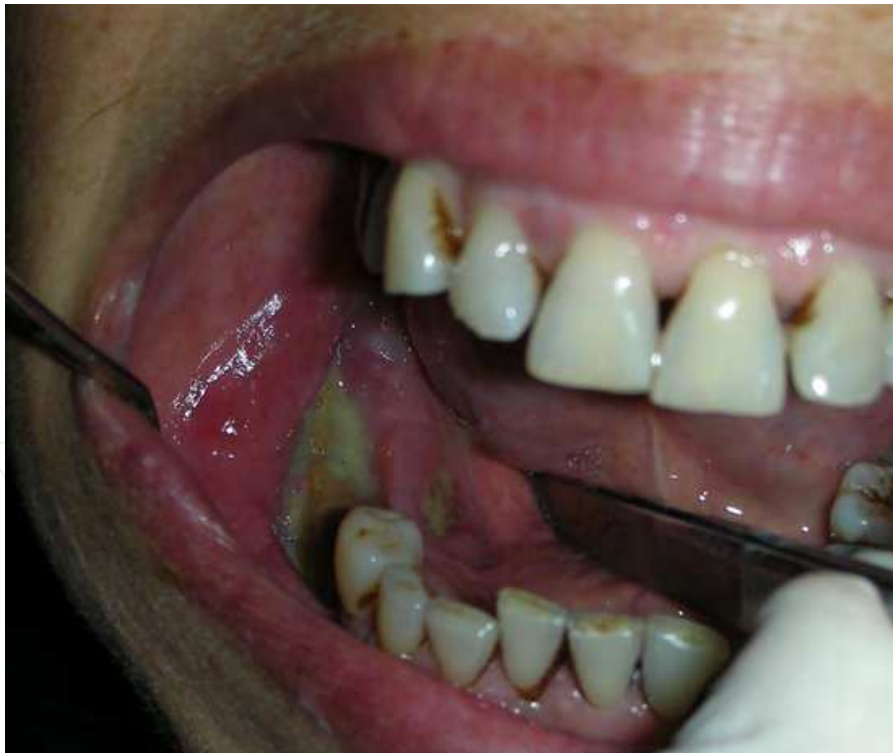

Fig. 8. Clinical view of the exposed bone at the vestibular and lingual part of the posterior right side of the mandible.

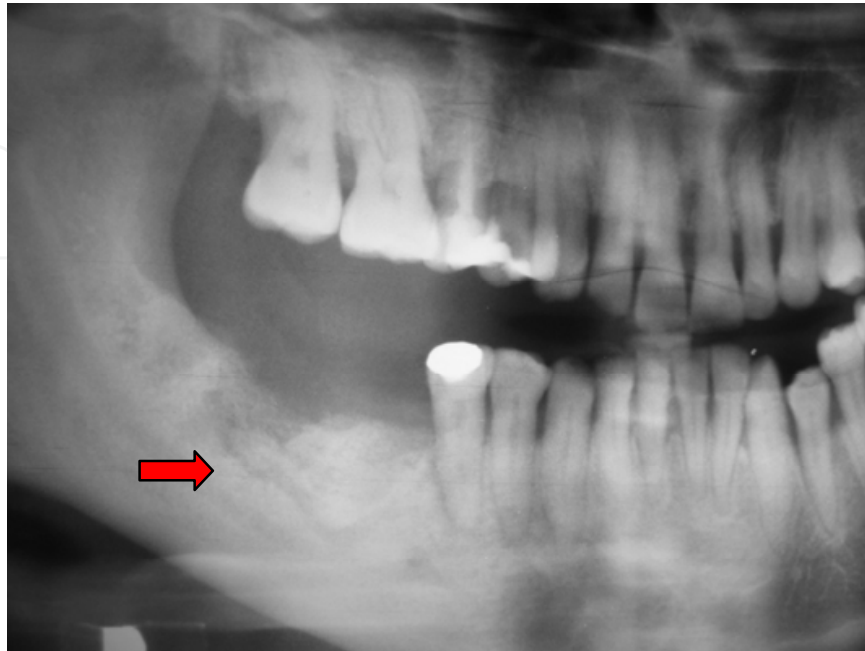


Fig. 9. Orthopantomograph showing the necrotic bone at the posterior right side of the mandible. Note the line of the demarcation.

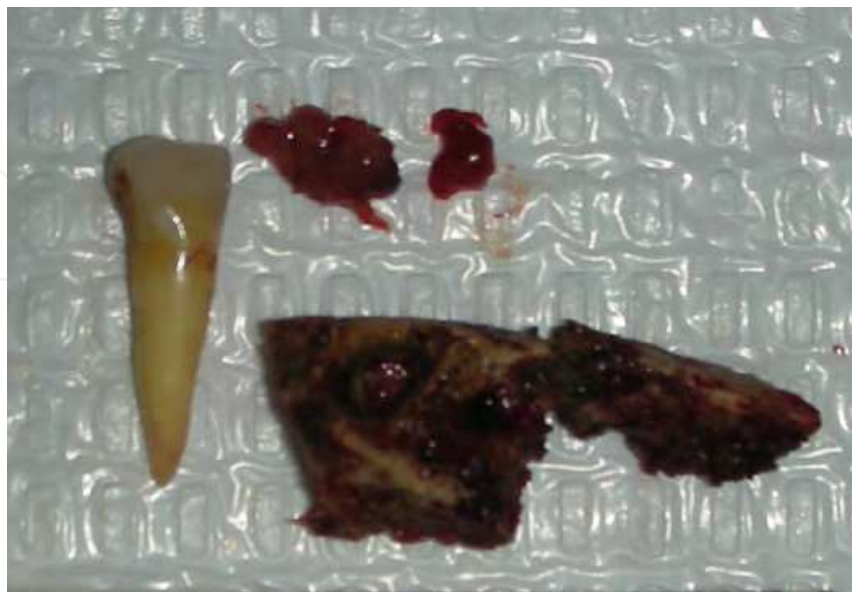

Fig. 10. Removed sequestrum and the associated teeth.

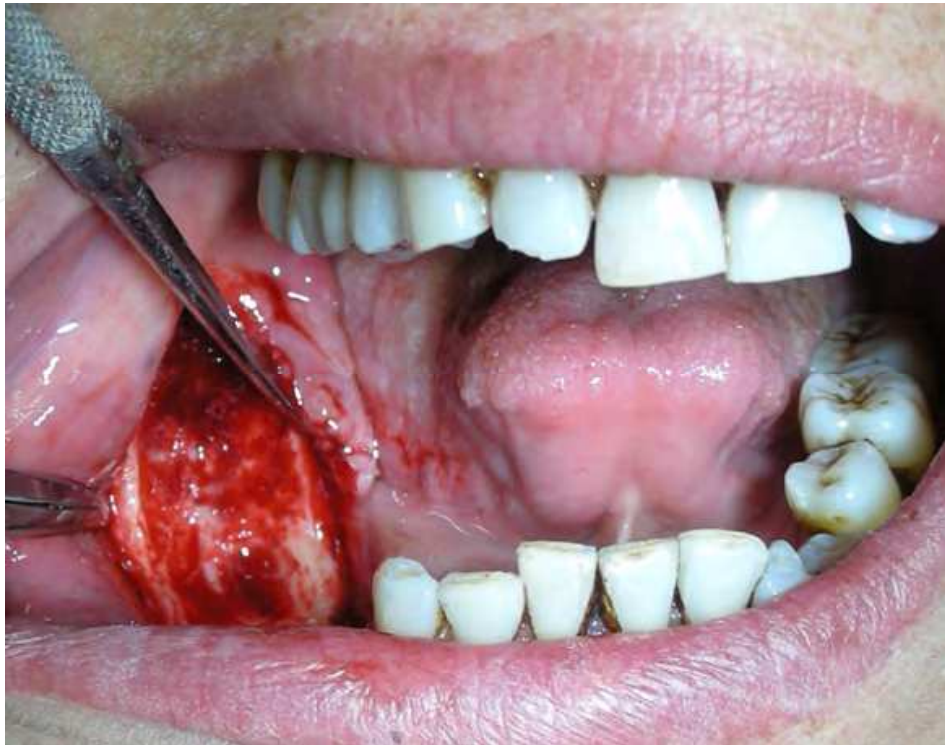

Fig. 11. Clinical view of the bone after the removal of the sequestrum and laser application.

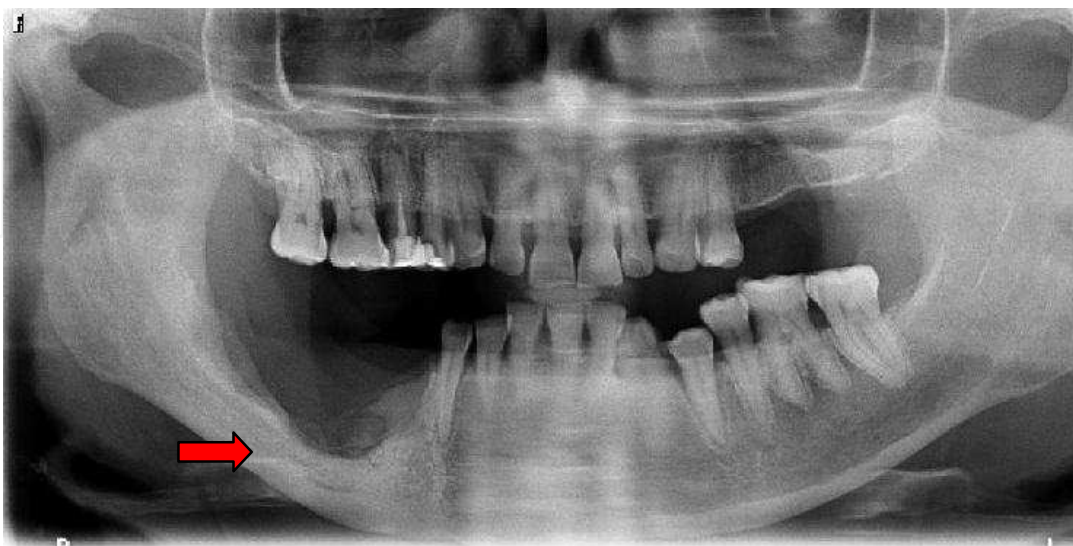

Fig. 12. Orthopantomograph showing the affected area 6 months after the operation.

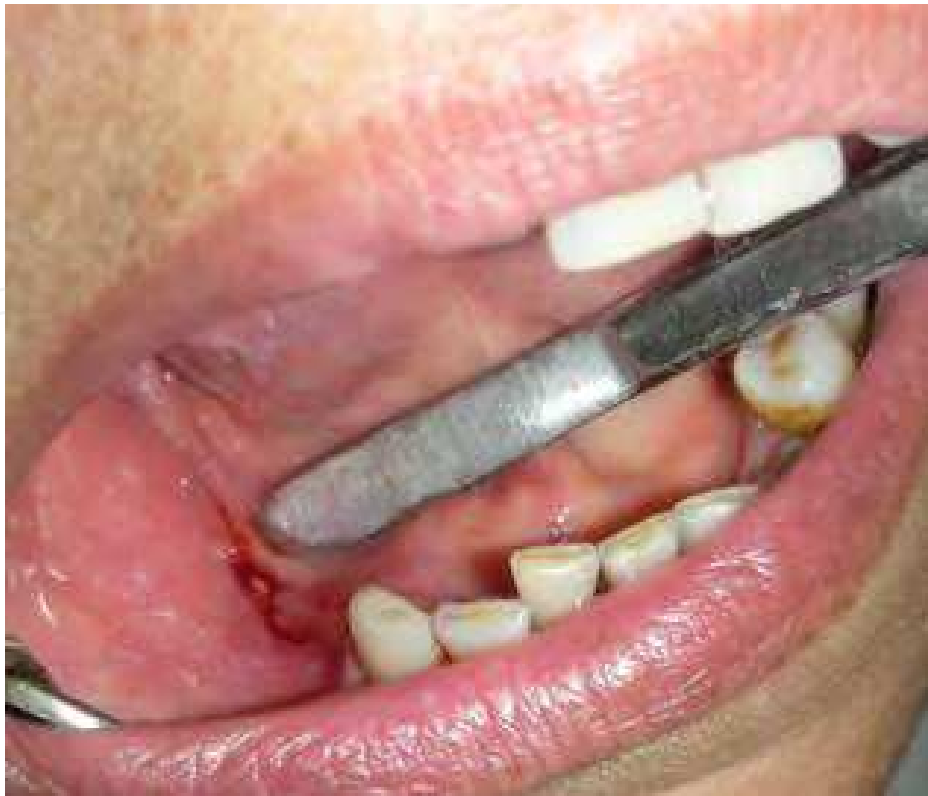

Fig. 13. Clinical appearance of the patient free of infection after 6 months post-operatively. Note that there's only a single small area of exposed bone.

## 10. Future research

Retrospective and prospective case studies have certainly established an association between bisphosphonates and jaw necrosis but the true incidence of this complication remains unknown. Clinical studies in the form of practitioner surveys or retrospective and prospective cohort investigations are needed to establish a more meaningful assessment of the associated risk factors and incidence of this problem in the population at risk. In addition, basic science research with the development of animal model system is needed to elucidate the cellular, molecular, and genetic mechanisms responsible for this process. Also, the development of an animal model for this disease process is important to establish treatment strategies that are evidenced based and associated with valid outcome data (33).

The effect of bisphosphonates on intraoral soft tissue wound healing; analysis of alveolar bone hemostasis and the response to bisphosphonate therapy; the antiangiogenic properties of bisphosphonates and their effects on jaw bone healing, pharmacogenetic research; and the development of valid BRONJ risk assessment tools should also be investigated in future. Continued governmental and institutional support is required to elucidate the underlying pathophysiologic mechanisms of BRONJ at the cellular and molecular level. Moreover, novel strategies for the prevention, risk reduction, and treatment of BRONJ need to be developed further so that more accurate judgments about risk, prognosis, treatment selection, and outcome can be established for patients with BRONJ (29).



## 11. Conclusions

All the medical doctors, who prescribe bisphosphonates, should strictly inform their patients about possible side effects of these drugs. One of the most important adverse effects of these drugs is BRONJ. This may occur spontaneously or following an oral surgical intervention such as a simple extraction, in patients with a history of bisphosphonate treatment. Prevention plays a crucial role since its management is difficult. Before prescribing these drugs, medical doctors should refer their patients to the dentists and maxillofacial surgeons in order to maintain optimum oral hygiene. All oral surgical operations should be completed prior to bisphosphonate therapy. Bisphosphonate therapy should only be started when the whole mucosal epithelization is formed.

BRONJ therapy has a more complicated management than the therapies for osteomyelitis and osteoradionecrosis. Its success rate is also less. These difficulties in the management of BRONJ leads to a very diminished life quality for the patients. Therefore, consultation in between medical doctors and dentists and oral and maxillofacial surgeons gains importance. All medical allied personals must be careful in using these drugs which also have life saving properties.

## 12. References


- [1] Fleisch H. Development of bisphosphonates. *Breast Cancer Res.* 2002; 4: 30-4.
- [2] Russell RG. Bisphosphonates: The first 40 years. *Bone.* 2011; 49 :2-19.
- [3] Russell RG, Rogers MJ. *Bone.* 1999;25: 97 -106. Bisphosphonates: from the laboratory to the clinic and back again.
- [4] Russell RG, Watts NB, Ebetino FE, Rogers MJ. Mechanisms of action of bisphosphonates: similarities and differences and their potential influence on clinical efficacy *Osteop Int* 2008; 19: 6733-75.
- [5] Frith JC, Mönkkönen J, Blackburn GM, Russell RG, Rogers MJ. Clodronate and liposome-encapsulated clodronate are metabolized to a toxic ATP analog, adenosine 5'-(beta, gamma-dichloromethylene) triphosphate, by mammalian cells in vitro. *J Bone Miner Res.* 1997; 12:1358-67.
- [6] van Beek ER, Cohen LH, Leroy IM, Ebetino FH, Löwik CW, Papapoulos SE. Differentiating the mechanisms of antiresorptive action of nitrogen containing bisphosphonates. *Bone.* 2003; 33: 805-11.
- [7] Papapetrou P. Bisphosphonate-associated adverse events. *Hormones.* 2009; 8: 96Y110.
- [8] McLeod NM, Davies BJ, Brennan PA. Bisphosphonate osteonecrosis of the jaws; an increasing problem for the dental practitioner. *Br Dent J.* 2007; 8: :641-4.
- [9] Sparidans RW, Twiss IM, Talbot S. Bisphosphonates in bone diseases. *Pharm World Sci.* 1998; 20: 206-13.
- [10] Cheng A, Daly CG, Logan RM, Stein B, Goss AN. Alveolar bone and the bisphosphonates. *Aust Dent J.* 2009;54 Suppl 1:S51-61.
- [11] Watts NB, Diab DL. Long-term use of bisphosphonates in osteoporosis. *J Clin Endocrinol Metab.* 2010; 95:1555-65.
- [12] Pazianas M, Cooper C, Ebetino FH, Russell RG. Long-term treatment with bisphosphonates and their safety in postmenopausal osteoporosis. *Ther Clin Risk Manag.* 2010; 21: :325-43.



- [13] Coleman RE, McCloskey EV. Bisphosphonates in oncology. *Bone*. 2011; 49: 71-6.
- [14] Ralston SH, Langston AL, Reid IR. *Lancet*. Pathogenesis and management of Paget's disease of bone. 2008; 12: 155-63.
- [15] Rachner TD, Khosla S, Hofbauer LC. Osteoporosis: now and the future. *Lancet*. 2011; 9: 1276-87.
- [16] Eastell R, Walsh JS, Watts NB, Siris E. Bisphosphonates for postmenopausal osteoporosis. *Bone*. 2011; 49: 82-8.
- [17] Bisphosphonates in orthopedic applications. Wilkinson JM, Little DG. *Bone*. 2011 ;49: 95-102.)
- [18] Pazianas M, Abrahamsen B. Safety of bisphosphonates. *Bone*. 2011; 49 :103-10.
- [19] Black DM, Delmas PD, Eastell R, Reid IR, Boonen S, Cauley JA, Cosman F, Lakatos P, Leung PC, Man Z, Mautalen C, Mesenbrink P, Hu H, Caminis J, Tong K, Rosario-Jansen T, Krasnow J, Hue TF, Sellmeyer D, Eriksen EF, Cummings SR; HORIZON Pivotal Fracture Trial. Once-yearly zoledronic acid for treatment of postmenopausal osteoporosis. *N Engl J Med*. 2007; 3: 1809-22.
- [20] Abrahamsen B. *Current Opinion in Rheumatology*. 2010; 22: 404-409 Bisphosphonate adverse effects, lessons from large databases Bo Abrahamsen.
- [21] Howard PA, Barnes BJ, Vacek JL, Chen W, Lai SM. Impact of bisphosphonates on the risk of atrial fibrillation. *Am J Cardiovasc Drugs*. 2010;10(6):359-67
- [22] Capeci CM, Tejwani NC. Bilateral low-energy simultaneous or sequential femoral fractures in patients on long-term alendronate therapy. *Journal of Bone and Joint Surgery. Series A*. 2009;91: 2556-2561.
- [23] Lenart BA, Lorich DG, Lane JM. Atypical fractures of the femoral diaphysis in postmenopausal women taking alendronate. *New England Journal of Medicine*. 2008;358: 1304-1306.
- [24] Neviasser AS, Lane JM, Lenart BA, Edobor-Osula F, Lorich DG. Low-energy femoral shaft fractures associated with alendronate use. *Journal of Orthopaedic Trauma*. 2008;22: 346-350.
- [25] Cheung RKH, Leung KK, Lee KC, Chow TC. Sequential non-traumatic femoral shaft fractures in a patient on long-term alendronate. *Hong Kong Medical Journal*. 2007;13: 485-489.
- [26] Schneider JP. Should bisphosphonates be continued indefinitely? An unusual fracture in a healthy woman on long-term alendronate. *Geriatrics*. 2006; 61: 31-33.
- [27] Shane E, Burr D, Ebeling PR, Abrahamsen B, Adler RA, Brown TD, Cheung AM, Cosman F, Curtis JR, Dell R, Dempster D, Einhorn TA, Genant HK, Geusens P, Klaushofer K, Koval K, Lane JM, McKiernan F, McKinney R, Ng A, Nieves J, O'Keefe R, Papapoulos S, Sen HT, van der Meulen MC, Weinstein RS, Whyte M; American Society for Bone and Mineral Research Atypical subtrochanteric and diaphyseal femoral fractures: report of a task force of the American Society for Bone and Mineral Research. *J Bone Miner Res*. 2010;25:2267-94.
- [28] Rizzoli R, Akesson K, Bouxsein M, Kanis JA, Napoli N, Papapoulos S, Reginster JY, Cooper C. Subtrochanteric fractures after long-term treatment with bisphosphonates: a European Society on Clinical and Economic Aspects of Osteoporosis and Osteoarthritis, and International Osteoporosis Foundation Working Group Report. *Osteoporos Int*. 2011; 22: 373-390.

- [29] Ruggiero SL, Dodson TB, Assael LA, Landesberg R, Marx RE, Mehrotra B; American Association of Oral and Maxillofacial Surgeons. American Association of Oral and Maxillofacial Surgeons position paper on bisphosphonate-related osteonecrosis of the jaws--2009 update. *J Oral Maxillofac Surg.* 2009;67(5 Suppl):2-12.
- [30] Oral and Intravenous Bisphosphonate-Induced Osteonecrosis of the Jaws. History, Etiology, Prevention, and Treatment, Second Edition. Marx RE, 2011.
- [31] Ruggiero SL. Bisphosphonate-related osteonecrosis of the jaw (BRONJ): initial discovery and subsequent development. *J Oral Maxillofac Surg.* 2009;67 (5 Suppl):13-8.
- [32] Marx R E. Pamidronate (Aredia) and Zoledronate (Zometa) induced avascular necrosis of the jaws: a growing epidemic. *J Oral Maxillofac Surg* 2003; 61: 115-118.
- [33] Ruggiero SL. Bisphosphonate-related osteonecrosis of the jaw: an overview. *Ann N Y Acad Sci.* 2011; 1218: 38-46.

IntechOpen



## **Orthopedic Surgery**

Edited by Dr Zaid Al-Aubaidi

ISBN 978-953-51-0231-1

Hard cover, 220 pages

**Publisher** InTech

**Published online** 09, March, 2012

**Published in print edition** March, 2012

Orthopaedic surgery is the widest and the strongest growing surgical specialty. It is clear, that the process of improving treatments and patients care, requires knowledge, and this requires access to studies, expert opinion and books. Unfortunately, the access to this knowledge is being materialized. As we believe that access to the medical knowledge should be reachable to everyone free of charge, this book was generated to cover the orthopaedic aspect. It will provide the reader with a mix of basic, but as well highly specialized knowledge. In the process of editing this book, my wife Jurgita has been, as usual, the most supportive person. I would like to thank her for being in my life. I would like to thank Mr. Greblo, the Publishing Process Manager, for all his help and last but not least thanks to our readers, as without them this book would have no meaning.

### **How to reference**

In order to correctly reference this scholarly work, feel free to copy and paste the following:

Sirmahan Cakarer, Firat Selvi and Cengizhan Keskin (2012). Bisphosphonates and Bone, Orthopedic Surgery, Dr Zaid Al-Aubaidi (Ed.), ISBN: 978-953-51-0231-1, InTech, Available from:  
<http://www.intechopen.com/books/orthopedic-surgery/bisphosphonates-and-bone>

**INTECH**  
open science | open minds

### **InTech Europe**

University Campus STeP Ri  
Slavka Krautzeka 83/A  
51000 Rijeka, Croatia  
Phone: +385 (51) 770 447  
Fax: +385 (51) 686 166  
[www.intechopen.com](http://www.intechopen.com)

### **InTech China**

Unit 405, Office Block, Hotel Equatorial Shanghai  
No.65, Yan An Road (West), Shanghai, 200040, China  
中国上海市延安西路65号上海国际贵都大饭店办公楼405单元  
Phone: +86-21-62489820  
Fax: +86-21-62489821

© 2012 The Author(s). Licensee IntechOpen. This is an open access article distributed under the terms of the [Creative Commons Attribution 3.0 License](#), which permits unrestricted use, distribution, and reproduction in any medium, provided the original work is properly cited.

IntechOpen

IntechOpen