

# We are IntechOpen, the world's leading publisher of Open Access books Built by scientists, for scientists

5,500

Open access books available

135,000

International authors and editors

165M

Downloads

Our authors are among the

154

Countries delivered to

TOP 1%

most cited scientists

12.2%

Contributors from top 500 universities



WEB OF SCIENCE™

Selection of our books indexed in the Book Citation Index  
in Web of Science™ Core Collection (BKCI)

Interested in publishing with us?  
Contact [book.department@intechopen.com](mailto:book.department@intechopen.com)

Numbers displayed above are based on latest data collected.  
For more information visit [www.intechopen.com](http://www.intechopen.com)



## New Technologies in Thyroid Surgery

Bahri Çakabay and Ali Çaparlar  
*Ankara University, Faculty of Medicine Department of Surgery  
Turkey*

### 1. Introduction

One of the earliest references to a successful surgical attempt for the treatment of goitre can be found in the medical writings of the Moorish physician Ali Ibn Abbas. In 952 A.D., he recorded his experience with the removal of a large goitre under opium sedation using simple ligatures and hot caustery irons as the patient sat with a bag around his neck to catch the blood. The first accounts of thyroid surgery for the treatment of goiters were given by Roger Frugardi in 1170. In response to failure of medical treatment, two setons were inserted at right angles into the goiter and tightened twice daily until the goiter separated. The open wound was treated with caustic powder and left to heal. The first successful typical partial thyroidectomy was performed by the French Surgeon, Pierre Joseph Desault, in 1791 during the French Revolution. Dupuytren followed in 1808 with the first total thyroidectomy, but the patient died 36 hours after the operation.

Despite these limited descriptions of early successes, the surgical approach to goitre remained shrouded in misunderstanding and superstition. Thyroid surgery in the 19th century carried a mortality of around 40% even in the most skilled surgical hands, mainly due to haemorrhage and infection. The French Academy of Medicine actually banned thyroid surgery in 1850 and German authorities called for restrictions on such 'foolhardy performances'. Leading surgeons avoided thyroid surgery if at all possible, and would only intervene in cases of respiratory obstruction. Samuel Gross wrote in 1848: "Can the thyroid gland when in the state of enlargement be removed...? If a surgeon should be so foolhardy as to undertake it. every step he takes will be environed with difficulty, every stroke of his knife will be followed by a torrent of blood and lucky it would be for him if his victim lives long enough to enable him to finish his horrid butchery. No honest and sensible surgeon would ever engage in it."

Early surgical approaches for treatment of thyroid disorders were associated with high rates of mortality and morbidity due to hemorrhage, asphyxia, air embolism, and infection. Surgical approach to thyroid disease was seen as the last resort. It was not until the late 1800s after the advent of ether as anesthesia, antiseptic technique, and effective artery forceps that allowed Theodor Kocher to perfect the technique for thyroidectomy. Kocher used the technique of precise ligation of the arterial blood supply to perform an unhurried, meticulous dissection of the thyroid gland, decreasing the morbidity and mortality associated with thyroid surgery to less than 1% (Giddings,1998).

Advancements could only take place in the field of thyroid surgery with the introduction of improved anaesthesia, antiseptic techniques, and improved ways of controlling

haemorrhage during surgery. The first thyroidectomy under ether anaesthesia took place in St Petersburg in 1849; the second half of the 19th century saw the introduction of Lister's antiseptic techniques through Europe, and the development of haemostatic forceps by such figures as Spencer Wells in London led to much better haemostasis than could be achieved by crude ligatures and cautery.

The most notable thyroid surgeons were Emil Theodor Kocher (1841–1917) and C.A. Theodor Billroth (1829–1894), who performed thousands of operations with increasingly successful results. However, as more patients survived thyroid operations, new problems and issues became apparent. After total thyroidectomy, patients became myxedematous with cretinous features. Myxedema effectively treated in 1891 by George Murray and Edward Fox. In 1909, Kocher was awarded the Nobel Prize for medicine in recognition "for his works on the physiology, pathology, and surgery of the thyroid gland."

The thyroid gland is removed traditionally through a small curvilinear incision approximately 3 cm above the sternal notch. While these original incisions allow for optimal exposure and successful removal of the diseased organ, they tend to subject the patients to lengthy hospital stays, significant postoperative pain, and in some cases, cosmetically undesirable results.

By the end of the twentieth century, laparoscopy was already accepted worldwide for a large number of operations in general surgery. By minimizing the size of the skin incisions while still permitting superior visualization of the operative field, laparoscopy was proven for certain operations to lessen postoperative pain, improve cosmesis, and shorten postoperative hospital stays.

As minimally invasive surgery became more popular, surgeons realized some true limitations. Sensory information is limited due to lack of tactile feedback and restriction to a two-dimensional (2D) image. In addition, compared to the human hand in an open case, laparoscopic instruments have restricted degrees of freedom mainly due to the lack of a wrist-like joint in the instrument tip and the lack of maneuverability due to a fixed axis point at the trocar (Hansen et al., 1997).

The advent of robot-assisted laparoscopic surgery seems to deal with many of the recognized limitations of hand-held laparoscopic surgery. In general, robots reduce the natural tremor of the human hand, reestablish comfortable ergonomics, reducing stress and surgeon fatigue, and, in certain cases, reestablish the three-dimensional (3D) view of the surgical field. In addition, surgical robots have the potential to be more precise and permit greater accuracy when it comes to suturing tasks and careful perivascular dissections. (Jacob et al., 2005)

## **2. Surgical instruments for improved hemostasis**

Thyroid surgery involves meticulous devascularization of the thyroid gland, which has one of the richest blood supplies of all organs, with numerous blood vessels and plexuses entering its parenchyma. Therefore, hemostasis is of paramount importance when dividing the various vessels before excising the gland (Çakabay et al., 2009).

Although nearly a century has passed since Halstead and Kocher first described thyroidectomy, it has changed little until recently, and is a procedure that is performed

extensively. Two of the most commonly used techniques for hemostasis are suture ligation and electrocoagulation. The disadvantage of suture ligation and electrocoagulation techniques is the prolonged operating time. Recently, a number of innovative methods of hemostasis in thyroid surgery have been tested, with promising results. New techniques developed over the past decade include hemostatic clipping, laser, LigaSure diathermy (ValleyLab, CO, USA) (or the LigaSure vessel sealing system), and ultrasonic instrumentation. Clips work for large vessels and are subject to dislodgment; whereas staples are wasted and costly for multiple single-vessel applications. Lasers are hindered by the risk of injury to many vital structures (such as the recurrent nerves) in the operative field, and bipolar electrocautery does not give the surgeon the freedom of applicability at different angles (Kennedy et al., 1998).

There have been significant advances in vessel sealing systems for the occlusion of blood vessels during general and gynecological surgical procedures. Two such devices are now commonly used in thyroid surgery: a bipolar energy sealing system and ultrasonic coagulation (Rahbari et al., 2011). Thyroid surgery is the most common endocrine surgical operation. Like all surgical procedures, the basic tenants of good exposure and hemostasis apply to thyroid surgery.

## 2.1 LigaSure

LigaSure (ValleyLab, CO, USA) is a bipolar diathermy system that seals vessels with reduced thermal spread. The device has been used successfully in abdominal surgery and has been introduced as a new method for hemostasis during thyroidectomy. The LigaSure diathermy system enables simultaneous selective sealing and division of a vessel without dispersion of the electric power, and with less heat production. The device is used in abdominal surgery and has proved suitable for use in thyroid surgery (Çakabay et al., 2009).

Any new surgical technology or operating technique should yield similar or improved patient outcomes and similar or lower rates of complications, compared with conventional methods. LigaSure, allowing vessel sealing and division with no dispersion of the electric power and with little or no heat production, has been widely used in diverse fields of surgery for its efficiency and safety. However, in thyroid surgery, where a considerable amount of minute vessels must be divided and hence microsurgical techniques required, LigaSure is also preferred for its further efficiency by shortening the duration of the operation.

Various specialties have reported shorter operating times with LigaSure (Lee et al., 2003, Levy et al., 2003, Jayne et al., 2002). However, in the literature, the postoperative outcome of thyroidectomy with LigaSure is controversial. Some studies (Petraakis et al., 2004) reported fewer complications and shorter operating times in the LigaSure, while others (Kiriakopoulos et al., 2004) did not observe a reduction in operating time for patients who underwent total or near-total thyroidectomy with LigaSure. According to two studies (Kirdak et al., 2005, Shen et al., 2005) the operating time was reduced substantially and the reduction in operating time in the LigaSure group was most probably a reflection of changes in operating technique (Shen et al., 2005). They reported that this change in technique facilitates dissection of the thyroid lobes and helps to reduce operating time and results in a decreased requirement for lateral skin retraction; the reduction in incision length in the

LigaSure group is probably a result of this decreased need for lateral retraction. The reduced operating time may result in decreased postoperative pain. The cause of postoperative pain is hyperextension of the neck (Defechereux et al., 2003); therefore, the pain can be reduced if the operating time is minimized. We found (Çakabay et al., 2009) that the use of the LigaSure significantly reduced the operating time for both total and one side total+other side subtotal thyroidectomy. The reduction in operating time was greatest in the total+subtotal thyroidectomy group. This is probably the result of faster but equally safe dissection of the thyroid gland compared with the conventional clamp-and-tie technique. In our experience, thyroid surgery using LigaSure does not require a significant learning period.

The major complications of thyroidectomy are laryngeal nerve injury and hypocalcemia. The reported permanent RLN palsy rate is 0%-14%. The use of LigaSure did not increase the RLN palsy risk (Çakabay2 et al., 009). Iatrogenic injury to the parathyroid glands resulting in hypocalcemia can occur from direct damage through inappropriate manipulation of surgery.

The cost of the LigaSure device is an important issue. According to some studies (Kirdak et al., 2005) the use of LigaSure is more expensive than the other conventional techniques. They reported that a cost-benefit analysis of this instrument may be helpful when choosing one of these techniques over the other. However, as the LigaSure device is produced to be disposable, the cost-effectiveness of LigaSure can be increased by using one device for several patients. The reuse of LigaSure hand pieces decreases its cost of purchase (Dilek et al., 2005). In our experience, we found that the additional cost of using LigaSure was \$95 per operation, and our observations indicate that the same device will provide safe hemostasis for no more than 10 patients.

## 2.2 Harmonic scalpel

New techniques, such as hemostatic clipping, monopolar/bipolar diathermy, and laser and ultrasonic instrumentation, have been developed over the past decade. Of these, the harmonic scalpel is the most frequently used. The harmonic scalpel uses high-frequency mechanical energy to cut and coagulate tissues at the same time, and it is widely used in otorhinolaryngological, cardiac, gastrointestinal, vascular, hemorrhoid, laparoscopic, obstetric, and gynecological surgery. The main advantages of ultrasonic coagulating /dissecting systems compared with a standard electro-surgical device are represented by minimal lateral thermal tissue damage (the harmonic scalpel causes lateral thermal injury 1-3 mm wide, approximately half that caused by bipolar systems), less smoke formation, no neuromuscular stimulation, and no electrical energy to or through the patient (Roye et al., 2000). Since its introduction, the harmonic scalpel has also gained popularity in thyroid and neck surgery. The proposed advantages of the harmonic scalpel include less lateral thermal tissue damage with no electrical energy transferred to the patient, as in electrocautery. In addition, the harmonic scalpel has some advantages over conventional techniques, particularly in terms of operative time, intraoperative bleeding, and hospitalization time.

The harmonic scalpel is a new surgical device for thyroid surgery and, to the best of our knowledge, studies in the English-language literature have been undertaken to compare



harmonic scalpel versus conventional techniques. The characteristics of these studies summarized in Table 1. The majority of these studies compared operative time, hospitalization time, drain use, incision size, postoperative pain, cosmetic results, cost analysis, and RLNP and other postoperative complications. The main advantage of using the harmonic scalpel in thyroid surgery is the reduction in operative time. Studies showed that the use of a harmonic scalpel significantly decreased the operative time (Yildirim et al., 2008, Voutilainen et al., 2000).

Some studies shown that no difference (Siperstein et al., 2002) was observed between the two techniques (harmonic scalpel and conventional techniques ) regarding the amount of blood loss, others (Miccoli et al., 2006, Kilic et al., 2007, Yildirim et al., 2008) have shown that drainage volume is significantly lower in patients treatment with a harmonic scalpel compared to those treated with conventional techniques.

Despite the safety demonstrated by harmonic scalpel in several studies, specific training and experience in the use of the device are necessary because the active blade in inexperienced hands can easily injure surrounding vital structures. Approximately 10 h of experience are required (Voutilainen et al., 2000). The majority of transient and permanent complications occurred in the period of early training. Hypocalcemia and nerve palsy rates will decrease in time as our experience with the harmonic scalpel technique increases.

	References	Year	Type of study	Number of patients (HS/CSL)	Summary of studies
1	Voutilainen et al.,	2000	Prospective	19/17	Hospitalization time, postoperative drainage, and intraoperative bleeding were similar between groups. Operative time was shorter in the HS group than in the CSL group.
2	Shemen	2002	Retrospective	105/20	The incision length was shorter and the operating time was reduced in the HS compared to CSL group. Bleeding was negligible and complications were few.
3	Siperstein et al.,	2002	Retrospective	86/85	Operative time was shorter in the HS group than in the CSL group. Thyroid size tended to be larger in the HS group than in the CSL group. The two groups were similar regarding blood loss.
4	Ortega et al.,	2004	Prospective	100/100	The operative time was shorter in the HS group than in the CSL group. Hospitalization was similar between groups, but the global cost per patient was significantly less in the HS group. Postoperative complications were similar between groups.

	References	Year	Type of study	Number of patients (HS/CSL)	Summary of studies
5	Cordon et al.,	2005	Prospective	30/30	Operative time and number of ligatures were significantly reduced in the HS group compared to the CSL group. Drainage and postoperative pain were similar between groups. No episode of persistent RLNP or hypoparathyroidism occurred in either group.
6	Miccoli et al.,	2006	Prospective	50/50	Postoperative pain, operative time, drainage volume, and transient hypocalcemia decreased significantly in the HS group compared to the CSL group.
7	Karvounaris et al.,	2006	Prospective	150/150	No significant difference was observed in terms of postoperative blood loss, temporary hypoparathyroidism, or RLNP, although use of the HS significantly decreased operative time.
8	Koutsoumanis et al.,	2007	Prospective	107/88	Use of the HS decreased operative time, but increased the cost of surgery.
9	Kilic et al.,	2007	Prospective	40/40	Use of the HS in thyroid surgery resulted in decreased operative time, number of ligatures, total drain time, average incision length, and number of blood-soaked gauzes; it also produced better cosmetic results, but did not increase postoperative complications.
10	Hallgrimsson et al.,	2008	Prospective	27/24	Operative time was significantly shorter in the HS group than in the CSL group.
11	Lombardi et al.,	2008	Prospective	100/100	Operative time and total operating room occupation time were significantly shorter in the HS group than in the CSL group. The cost of the disposable materials was significantly higher in the HS group.
12	Leonard et al.,	2008	Prospective	21/31	The two groups were similar regarding operative time and incision size. This was the first reported series in which HS usage did not reduce operative time.

	References	Year	Type of study	Number of patients (HS/CSL)	Summary of studies
13	Yildirim et al.,	2008	Prospective	50/54	Use of the HS in thyroid surgery decreased operative time, mean blood loss, drain usage, number of ligatures, and amount of bleeding, and did not increase postoperative complications.
14	Manouras et al.,	2008	Prospective	144/90	The operative time was shorter in the HS group than in the CSL group. The rate of postoperative complications and hospitalization time were similar between groups.
15	Sebaq et al.,	2009	Prospective	50/50	The two groups were similar regarding hospitalization time and operative cost. Operative time decreased significantly in the HS group compared to the CSL group.

Table 1. A summary of studies on the use of harmonic scalpel(HS) versus conventional suture ligation(CSL)

### 3. Endoscopic techniques

Neck surgery is one of the newest and most interesting applications of minimally invasive surgery. Several approaches have been proposed in the application of endoscopic thyroidectomy. The primary aim of all these different approaches has been to improve the cosmetic results of conventional surgery. Endoscopic thyroidectomy has been divided into two types, video-assisted and total endoscopic. Others classified it as with CO<sub>2</sub> insufflation or gasless.

Minimally invasive video-assisted thyroidectomy (MIVAT) is characterized by a single access of 1.5 cm in the middle area of the neck, approximately 1-2 cm above the sternal notch; the midline is incised, and a blunt dissection is carried out with tiny spatulas to separate the strap muscles from the underlying thyroid lobe. From this point on the procedure is performed endoscopically on a gasless basis with an external retraction. An laparoscope of 5 mm, 30 degrees, is used. After the insertion of laparoscope through the skin incision, the lobe was completely dissected from the strap muscles with 2-mm-diameter laparoscopic instruments and other instruments regularly used. The optical magnification allows an excellent vision of both the external branch of the superior laryngeal nerve and the recurrent nerve, which are prepared together with the upper parathyroid gland. The vessels are ligated between clips or with the harmonic scalpel until the lobe, completely freed, can be extracted by gently pulling it out through the skin incision. The isthmus is then dissected from the trachea and divided. After checking the recurrent laryngeal nerve once again, the lobe is finally removed (Miccoli et al., 2001). In this technique, no subplatysmal flaps are raised and no muscles are divided, resulting in reduced tissue edema when compared with conventional surgery. Initial experiences published on MIVAT underlined the advantages of



the procedure in terms of a better cosmetic result and less postoperative pain when compared with conventional surgery.

Endoscopic lateral cervical approach used for hemithyroidectomy, two 2-5 mm trocars and one 10-mm trocar are inserted along the anterior border of the sternocleidomastoid muscle on the ipsilateral side and using endoscopic instruments specially designed for this procedure. An additional advantage of this technique over endoscopically assisted midline technique was that no additional assistants were required to hold retractors (Palazzo et al., 2006).

Total endoscopic thyroidectomy is a more sophisticated variation of minimally invasive thyroid. Using special instrument and technique, part or all of the thyroid gland can be removed through small puncture site, avoiding any incision on the neck whatsoever. Various approaches have been devised and improved further to fulfill this goal, mainly including the cervical approach, anterior chest approach, axillary and breast approach. However, none of these approaches is exclusively advantageous and universally accepted. (Irawati, 2010). The cervical approach and anterior chest approach are minimally invasive, but not cosmetically excellent. The axillary and breast approaches have maximized cosmesis, but meanwhile cause much invasiveness. Furthermore, the axillary approaches are not suitable for bilateral manipulation and even more technically challenging with abnormal anatomic vision. Therefore, an axillary-bilateral-breast approach (ABBA) has been developed, which is actually a combination of the procedure. Bilateral-axillary-breast approach (BABA) was introduced later and was claimed to be easily applied for thyroid cancer as well. Whereas applicability of the endoscopic-assisted approach is limited by the size of the gland, the investigators noted that this constraint does not exist for BABA, as even large glands are easily retrieved through the axillary port (Becker et al., 2008). This technique now is even improved by using Da Vinci robotic system (Eun Lee et al., 2009). The endowrist function of the instrument is beneficial in doing complex tasks in difficult areas with limited access.

Disadvantages of endoscopic thyroidectomy include the requirement for additional equipment, namely high-resolution endoscopes and monitors for video-assisted techniques and insufflation units for purely endoscopic approaches. In addition, there is a distinct learning curve, which is more pronounced with purely endoscopic approaches. While video-assisted techniques clearly result in limited surgical dissection, purely endoscopic approaches, by virtue of their remote approaches, result in an equivalent amount of dissection. Because of this, most descriptions include the routine use of drains, which may increase the length of hospitalization (Becker 2008). The increased chest-wall dissection can result in hypoesthesia in this area, and cases of pneumothorax have been described (Choe et al., 2007). Operative time for endoscopic approaches may be up to 30% longer than they are for traditional approaches (Terris et al., 2007).

#### **4. Robotic surgery**

Robots have been in the operating room for approximately 15 years now, but their use in assisting laparoscopic endocrine surgery is very new. With the refinement of the technology, easier set up, better image quality, and smaller robotic systems, there has been an interest in using the robot for more general surgical laparoscopic procedures as well as for thyroid surgery. Thyroid surgery procedures are excellent targets for robotic instrumentation when compared with the conventional endoscopic techniques, since it

requires to work in a small space, significantly limiting the type of equipment that can be used. In spite of its deficiencies and unanswered questions especially about cost effectiveness, robotic technology seems to overcome the limitations of conventional laparoscopic technology in thyroid surgery.

The Da Vinci Surgical System consists of a “surgeon console” and a “surgical arm cart.”. The surgical arm cart holds the robotic instruments and the endoscopic camera. The endoscope for the Da Vinci system is a specially designed 12 mm dual-camera endoscope that is capable of sending a 3D image to a specialized viewing screen in the console called the InSite Vision System. By looking into this 3D-image system, which eliminates all extraperipheral images other than those on the screen, the surgeon immerses himself in the operative field. The camera and instruments are both controlled by maneuvering the joysticks on the console. To alternate the digital handle’s control back and forth between control of the camera and control of the instruments, the surgeon taps a foot pedal at the base of the console. At the current time there are 18 different robotic instruments in the Da Vinci system, which are appropriately called “endowrist instruments.”

Once immersed in the Da Vinci’s virtual field, the surgeon inserts his fingers into the handles, sits in an ergonomically correct position, and then maneuvers the endowrist instruments with up to 7 degrees freedom: yaw (side-to-side), pitch (up/down), insertion (in and out), grip, and three additional degrees of freedom provided by the second joint in the instrument tip. In effect, maneuvering the Da Vinci instruments is like miniaturizing your hands and wrists and placing them into cavities they normally could never fit into, thus permitting the performance of delicate, precise dissection and suturing in the smallest cavity – all through small skin incisions (Jacob BP & Gagner M, 2004).

Once the system was on the market, Intuitive continued perfecting it, and the second generation – the da Vinci S – was released in 2006 (Figure 1). The latest version, the da Vinci Si became available in April 2009 with improved full HD camera system, advanced ergonomic features, and most importantly, the possibility to use two consoles for assisted surgery.

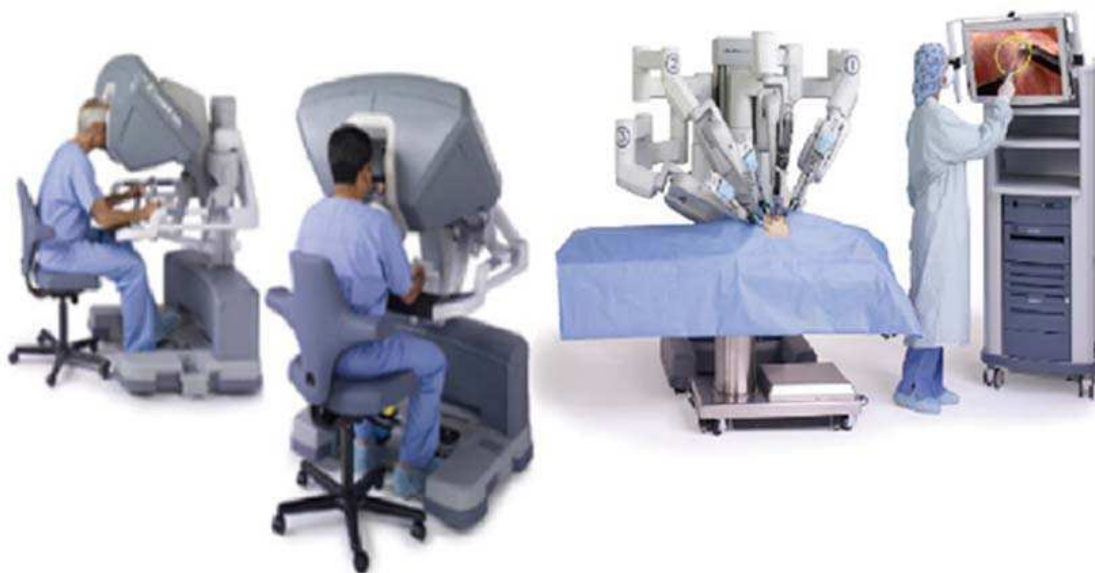

Fig. 1. Master controllers and the patient side manipulators of the new Da Vinci Si surgical system. (Photo: Intuitive Surgical Inc.)

The Zeus Robotic Surgical System also has two components: the surgeon console and the robotic instrument arms connected by a computer interface that can filter tremor and adjust the movement and rotational scale of the instruments. Unlike the Da Vinci system, the Zeus robotic arms are not on a cart, but instead can be attached directly to the operating room table. A second difference between the Zeus and the Da Vinci is that the Zeus uses a voice-activated camera control system called the AESOP Robotic Endoscope Positioner. Instead of requiring a special 12 mm endoscope as with the Da Vinci, the Zeus allows the use of routine 5 or 10 mm endoscopes with the AESOP arm. With this system the surgeon can continuously maneuver the camera's position with simple voice commands like "camera in, camera out." The third difference between the two robotic surgery systems is that currently the Zeus system uses robotic laparoscopic instruments that mimic the hand-held laparoscopic instruments, thus lacking the additional degrees of freedom that you would get with an "endowrist" instrument tip designed to mimic the human hand. Like standard laparoscopic instruments, these current Zeus instruments have only 5 degrees of freedom.

As the robotic technology is advancing rapidly, the Zeus is already in its third phase of design and is now available with instruments called "Microwrist technology." These new instruments, like the Da Vinci, have tips that offer a second joint mimicking the movements of the human wrist. Because this technology has just become available, there are no studies or published results demonstrating their efficiency, but the ability to perform wrist-like articulations inside the abdomen through small skin incisions is obviously promising.

The Zeus robot proved to be a solid platform to test and experiment different telesurgical scenarios. Between 1994 and 2003 the French Institut de Recherche contre les Cancres de l'Appareil Digestif (IRCAD) (Strasbourg, France) and Computer Motion Inc. Worked together in several experiments to learn about the feasibility of long distance telesurgery and effects of latency, signal quality degradation (Fig. 2).

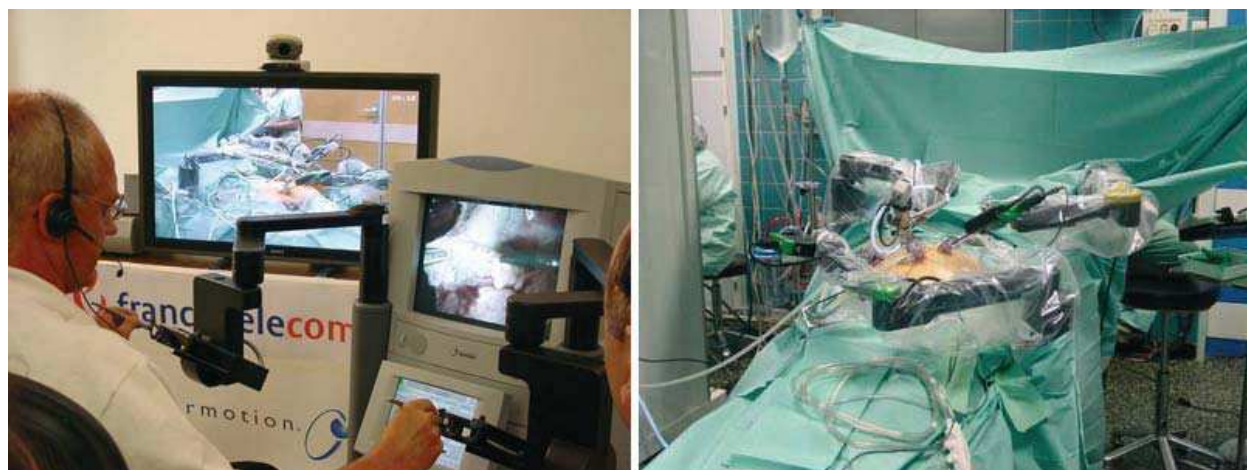

Fig. 2. The Zeus robot during the first intercontinental surgery, the colecystectomy was performed on the patient in Strasbourg from New York. (Photo: IRCAD)

Each robotic system has been used for a large number of different surgical procedures. The Da Vinci surgical robot system provides a three dimensional field of view and a more accurate sense of perspective (Ballantyne et al., 2007, Hartmann et al., 2008, Jacobsen et al., 2004). Moreover, because this system can magnify target structures, it more easily enables

the preservation of the parathyroid and recurrent laryngeal nerves. The robot arm can be driven in multi-angular motions with seven degrees freedom. This enables safe and complete central compartment node dissection in the deep and narrow operation space (Jacob et al., 2003). The hand-tremor filtration, the fine motion scaling, the negative motion reversal of the robot system (providing minute and precise manipulations of tissue), and the ergonomically designed console means that surgeons experience less fatigue (Gutt et al., 2004, Savitt et al., 2005, Link et al., 2006).

Despite these various advantages of the Da Vinci surgical robot system, it may prove cost prohibitive when factors such as general cost, fees of disposables, and maintenance are taken into consideration. Additionally, the large room space it requires may be another factor that limits its widespread use in thyroid surgery (Link et al., 2006).

The early surgical outcomes of robot-assisted endoscopic thyroidectomies were compared with the data for conventional open thyroidectomies. As described earlier, this transaxillary approach is a more time-consuming procedure than conventional open thyroidectomy. However, with accumulation of experience, the actual operation time is decreasing. The patients in the robotic group were highly selected for several reasons such as the expected risk group and the expensive operation fee, and the difference in operation method was expected. However, there was little difference in the retrieved lymph node numbers, postoperative hospital stays, and pain between the two groups. Moreover, the postoperative complications in the robotic group were somewhat fewer than in the conventional open thyroidectomy group.

Although robot-assisted endoscopic thyroid surgery showed cosmetic and various technical advantages for surgeons, the major concerns when a new treatment technique for malignant tumors is considered should be the safety and radicalness of the operation to prevent local recurrence and distant metastasis. The relative oncologic safety of endoscopic versus robot-assisted endoscopic thyroid surgery has not yet been established due to the newness of this technology. To prevent cancer cell dissemination and to minimize the possibility of local recurrence during endoscopic thyroidectomy, the safety of the operational methods and the degree of surgical skill are important. If the safety and radicalness of robotic thyroid surgery as a treatment for papillary thyroid microcarcinoma can be established by the performance of complete thyroidectomies with secure lymphadenectomies, then the application boundaries and development area of this technique can be gradually extended (Kang et al., 2009).

## 5. References

- Ballantyne GH.(2007). Telerobotic gastrointestinal surgery: phase 2 safety and efficacy. *Surg Endosc.* 2007;21:1054-1062
- Choe JH, Kim SW, Chung KW, et al.(2007). Endoscopic thyroidectomy using a new bilateral axillo-breast approach. *World J Surg.* 2007 Mar;31(3):601-6
- Cordón C, Fajardo R, Ramírez J, Herrera MF. (2005). A randomized, prospective, parallel group study comparing the Harmonic Scalpel to electrocautery in thyroidectomy. *Surgery.* 2005 Mar;137(3):337-41.
- Cakabay B, Sevinç MM, Gömceli I, et al. (2009). LigaSure versus clamp-and-tie in thyroidectomy: a single-center experience. *Adv Ther.* 2009 Nov;26(11):1035-41. Epub 2009 Dec 18




- Defechereux T, Rinken F, Maweja S, et al.(2003). Evaluation of the ultrasonic dissector in thyroid surgery. A prospective randomised study. *Acta Chir Belg.* 2003;103:274-227.
- Dilek ON, Yilmaz S, Degirmenci B, et al. (2005). The use of a vessel sealing system in thyroid surgery. *Acta Chir Belg.* 2005;105:369-372.
- Eun Lee K, Rao J, Kyu Youn Y, et al.(2009). Endoscopic Thyroidectomy with the da-Vinci Robot System Using the BABA Technique- Our Initial Experience. *Surg Laparosc, Endosc & Percutan Tech* 2009; 19 (3): e71-5
- Giddings AE.(1998). The history of thyroidectomy. *J R Soc Med.*1998;91 Suppl 33:3-6.
- Gutt CN, Oniu T, Mehrabi A, Kashfi A, Schemmer P, Buechler MW.(2004). Robot-assisted abdominal surgery. *Br J Surg.* 2004;91:1390-1397
- Hallgrimsson P, Lovén L, Westerdahl J, Bergenfelz A.(2008). Use of the harmonic scalpel versus conventional haemostatic techniques in patients with Grave disease undergoing total thyroidectomy: a prospective randomised controlled trial. *Langenbecks Arch Surg.* 2008 Sep;393(5):675-80. Epub 2008 Aug 2.
- Hansen P, Bax T, Swanstrom L.(1997). Laparoscopic adrenalectomy: history, indications, and current techniques for a minimally invasive approach to adrenal pathology. *Endoscopy* 1997; 29:309-314.
- Hartmann J, Jacobi CA, Menenakos C, Ismail M, Braumann C.(2008). Surgical treatment of gastroesophageal reflux disease and upside-down stomach using the Da Vinci robotic system: a prospective study. *J Gastrointest Surg* 2008 .12:504-509
- Irawati N.(2010). Endoscopic right lobectomy axillary-breast approach: a report of two cases. *Int J Otolaryngol.* 2010;2010:958764. Epub 2010 Dec 28.
- Jacobsen G, Elli F, Horgan S.(2004). Robotic surgery update. *Surg Endosc* 18:1186-1191
- Jacob BP, Gagner M.(2003). Robotics and general surgery. *Surg Clin North Am* 83:1405-1419
- Jacob BP & Gagner M. (2004). Robotic Endocrine Surgery, In: *Endocrine Surgery*, Arthur E. Schwartz, Demetrius Persemlidis, Michel Gagner , pp.(11-16), Library of Congress Cataloging-in-Publication Data, ISBN: 0-8247-4297-4, Canada
- Jayne DG, Botterill I, Ambrose NS, et al. (2002). Randomized clinical trial of Ligasure versus conventional diathermy for day-case haemorrhoidectomy. *Br J Surg.* 2002;89:428-432.
- Kang SW, Jeong JJ, Yun JS, et al.(2009). Robot-assisted endoscopic surgery for thyroid cancer: experience with the first 100 patients. *Surg Endosc.* 2009 Nov;23(11):2399-406. Epub 2009 Mar 5.
- Karvounaris DC, Antonopoulos V, Psarras K, Sakadamis A .(2006). Efficacy and safety of ultrasonically activated shears in thyroid surgery. *Head Neck.* 2006;28:1028-1031
- Kennedy JS, Stranahan PL, Taylor KD, Chandler JG. (1998). High-burst-strength, feedback-controlled bipolar vessel sealing. *Surg Endosc.* 1998;12:876-878.
- Kilic M, Keskek M, Ertan T, et al. (2007). A prospective randomized trial comparing the harmonic scalpel with conventional knot tying in thyroidectomy. *Adv Ther.* 2007 May-Jun;24(3):632-8.
- Kirdak T, Korun N, Ozguc H.(2005). Use of LigaSure in thyroidectomy procedures: results of a prospective comparative study. *World J Surg.* 2005;29:771-774.
- Kiriakopoulos A, Dimitrios T, Dimitrios L. (2004). Use of a diathermy system in thyroid surgery. *Arch Surg.* 2004;139:997-1000.
- Koutsomanis K, Koutras AS, Drimousis PG, et al.(2007). The use of a harmonic scalpel in thyroid surgery: report of a 3-year experience. *Am J Surg.* 2007;193



- Lee WJ, Chen TC, Lai IR, et al.(2003). Randomized clinical trial of LigaSure versus conventional surgery for extended gastric cancer resection.*Br J Surg.* 2003;90:1493-1496.
- Levy B, Emery L.(2003). Randomized trial of suture versus electrosurgical bipolar vessel sealing in vaginal hysterectomy. *Obstet Gynecol.* 2003;102:147-151.
- Leonard DS, Timon C.(2008).Prospective trial of the ultrasonic dissector in thyroid surgery. *Head Neck.* 2008 Jul;30(7):904-8.
- Link RE, Bhayani SB, Kavoussi LR.(2006). A prospective comparison of robotic and laparoscopic pyeloplasty. *Ann Surg* 2006,243:486-491
- Lombardi CP, Raffaelli M, Cicchetti A,et al.(2008). The use of "harmonic scalpel" versus "knot tying" for conventional "open" thyroidectomy: results of a prospective randomized study. *Langenbecks Arch Surg.* 2008 Sep;393(5):627-31. Epub 2008 Jul 15.
- Manouras A, Markogiannakis H, Koutras AS, et al. (2008).Thyroid surgery: comparison between the electrothermal bipolar vessel sealing system, harmonic scalpel, and classic suture ligation.*Am J Surg.* 2008 Jan;195(1):48-52
- Miccoli P, Berti P, Raffaelli M, et al.(2001). Comparison between minimally invasive video-assisted thyroidectomy and conventional thyroidectomy: a prospective randomized study. *Surgery.* 2001 Dec;130(6):1039-43
- Miccoli P, Berti P, Dionigi GL, et al. (2006). Randomized Controlled Trial of Harmonic Scalpel Use During Thyroidectomy *Arch Otolaryngol Head Neck Surg.* 2006;132:1069-1073
- Ortega J, Sala C, Flor B, Lledo S. (2004). Efficacy and cost-effectiveness of the UltraCision harmonic scalpel in thyroid surgery: an analysis of 200 cases in a randomized trial. *J Laparoendosc Adv Surg Tech A.* 2004 Feb;14(1):9-12
- Palazzo FF, Sebag F, Henry JF. (2006).Endocrine surgical technique: endoscopic thyroidectomy via the lateral approach.*Surg Endosc.* 2006 Feb;20(2):339-42. Epub 2005 Dec 9.
- Petrakis IE, Kogerakis NE, Lasithiotakis KG,et al. (2004). LigaSure versus clamp-and-tie thyroidectomy for benign nodular disease. *Head Neck.* 2004;26:903-909.
- Rahbari R, Mathur A, Kitano M et al.(2011). Prospective Randomized Trial of Ligasure Versus Harmonic Hemostasis Technique in Thyroidectomy. *Ann Surg Oncol* (2011) 18:1023-1027
- Roye GD, Monchik JM, Amaral JF. (2000). Endoscopic adrenalectomy using ultrasonic cutting and coagulating. *Surg Technol Int.* 2000;IX:129-138.
- Savitt MA, Gao G, Furnary AP, Swanson J, Gately HL, Handy JR. (2005) Application of robotic-assisted techniques to the surgical evaluation and treatment of the anterior mediastinum. *Ann Thorac Surg* 2005, 79:450-455
- Sebag F, Fortanier C, Ippolito G, et al.(2009). Harmonic scalpel in multinodular goiter surgery: impact on surgery and cost analysis. *J Laparoendosc Adv Surg Tech A.* 2009 Apr;19(2):171-4.
- Shemen L.(2002). Thyroidectomy using the harmonic scalpel: analysis of 105 consecutive cases. *Otolaryngol Head Neck Surg.*2002;127:234-238
- Shen WT, Baumbusch MA, Kebebew E, Duh QY. (2005).Use of the electrothermal vessel sealing system versus standard vessel ligation in thyroidectomy. *Asian J Surg.* 2005;28:86-89.

- Siperstein AE, Berber E, Morkoyun E. (2002). The Use of the Harmonic Scalpel vs Conventional Knot Tying for Vessel Ligation in Thyroid Surgery *Arch Surg.* 2002;137:137-142.
- Terris DJ, Chin E. (2006). Clinical implementation of endoscopic thyroidectomy in selected patients. *Laryngoscope.* 2006 Oct;116(10):1745-8
- Voutilainen PE, Haglund CH. (2000). Ultrasonically activated shears in thyroidectomies: a randomized trial. *Ann Surg.* 2000;231:322-328.
- Yildirim O, Umit T, Ebru M, et al. (2008). Ultrasonic harmonic scalpel in total thyroidectomies. *Adv Ther.* 2008 Mar;25(3):260-5.

IntechOpen



## **Thyroid and Parathyroid Diseases - New Insights into Some Old and Some New Issues**

Edited by Dr. Laura Ward

ISBN 978-953-51-0221-2

Hard cover, 318 pages

**Publisher** InTech

**Published online** 07, March, 2012

**Published in print edition** March, 2012

This book was designed to meet the requirements of all who wish to acquire profound knowledge of basic, clinical, psychiatric and laboratory concepts as well as surgical techniques regarding thyroid and parathyroid glands. It was divided into three main sections: 1. Evaluating the Thyroid Gland and its Diseases includes basic and clinical information on the most novel and quivering issues in the area. 2. Psychiatric Disturbances Associated to Thyroid Diseases addresses common psychiatric disturbances commonly encountered in the clinical practice. 3. Treatment of Thyroid and Parathyroid Diseases discusses the management of thyroid and parathyroid diseases including new technologies.

### **How to reference**

In order to correctly reference this scholarly work, feel free to copy and paste the following:

Bahri Çakabay and Ali Çaparlar (2012). New Technologies in Thyroid Surgery, Thyroid and Parathyroid Diseases - New Insights into Some Old and Some New Issues, Dr. Laura Ward (Ed.), ISBN: 978-953-51-0221-2, InTech, Available from: <http://www.intechopen.com/books/thyroid-and-parathyroid-diseases-new-insights-into-some-old-and-some-new-issues/new-technologies-n-thyroid-sugery>

**INTECH**  
open science | open minds

### **InTech Europe**

University Campus STeP Ri  
Slavka Krautzeka 83/A  
51000 Rijeka, Croatia  
Phone: +385 (51) 770 447  
Fax: +385 (51) 686 166  
[www.intechopen.com](http://www.intechopen.com)

### **InTech China**

Unit 405, Office Block, Hotel Equatorial Shanghai  
No.65, Yan An Road (West), Shanghai, 200040, China  
中国上海市延安西路65号上海国际贵都大饭店办公楼405单元  
Phone: +86-21-62489820  
Fax: +86-21-62489821

© 2012 The Author(s). Licensee IntechOpen. This is an open access article distributed under the terms of the [Creative Commons Attribution 3.0 License](#), which permits unrestricted use, distribution, and reproduction in any medium, provided the original work is properly cited.

IntechOpen

IntechOpen