

# We are IntechOpen, the world's leading publisher of Open Access books Built by scientists, for scientists

4,400

Open access books available

117,000

International authors and editors

130M

Downloads

Our authors are among the

154

Countries delivered to

TOP 1%

most cited scientists

12.2%

Contributors from top 500 universities



WEB OF SCIENCE™

Selection of our books indexed in the Book Citation Index  
in Web of Science™ Core Collection (BKCI)

Interested in publishing with us?  
Contact [book.department@intechopen.com](mailto:book.department@intechopen.com)

Numbers displayed above are based on latest data collected.  
For more information visit [www.intechopen.com](http://www.intechopen.com)



# Medical and Surgical Management of Intracranial Hypertension

James Scozzafava<sup>1,2</sup>, Muhammad Shazam Hussain<sup>3</sup> and Seby John<sup>4</sup>

<sup>1</sup>*Department of Adult Critical Care Medicine, Saskatoon Health Region, Saskatoon, Saskatchewan,*

<sup>2</sup>*Division of Stroke Neurology, Neurosciences Program, Department of Medicine, University of Alberta, Edmonton, AB,*

<sup>3</sup>*Medical Director, Primary Stroke Center, Vascular Neurology and Endovascular Surgical Neuroradiology, Cerebrovascular Section, Cleveland Clinic, Cleveland, OH*

<sup>4</sup>*Department of Neurology, Cleveland Clinic, Cleveland, OH*

<sup>1,2</sup>Canada

<sup>3,4</sup>USA

## 1. Introduction

Elevated intracranial pressure (ICP) is a frequently encountered problem in neurological and neurosurgical patients in the intensive care unit (ICU). It is most often seen in the setting of acute head trauma, however can also result from such causes as tumor, stroke, intracranial hemorrhage, or infection. Regardless of the cause, the degree and duration of ICP elevation has a direct and inverse relationship with morbidity and mortality. Consequently, despite the severity of the initial injury to the brain, a great deal of attention must often be focused on the monitoring and the management of ICP in acute neurological patients in the ICU setting.

## 2. Physiology

The brain is enclosed within inelastic container (the skull) or “closed box”, and the sum of volumes of intracranial contents is constant. The intracranial contents include blood, cerebrospinal fluid (CSF) and brain and an increase in the volume of one must be offset by a decrease in one or more of the other contents or an increase in ICP will result. Elevations in ICP are the result of an increase in cranial volume and a decrease in cranial compliance. This is best described by the Monro-Kellie hypothesis. (Figure 1) CSF is the most accommodating of the intracranial contents, however the compensatory capabilities of CSF are limited and once exhausted, small increases in intracranial volume result in large increases in ICP.

The most common cause for raised ICP is severe head trauma. Regardless of etiology, the pathophysiology underlying the secondary injury from raised ICP is similar for all patients with brain injury and it results from such issues as swelling, edema, and neuronal cytotoxicity. Brain edema is a frequent occurrence in neurological diseases and can accumulate intracellular or extracellular. Intracellular edema is usually the result of cytotoxic

edema damaging the cell membranes often destroying the sodium/potassium exchange pump. This leads to unregulated passage of sodium and water into neuronal cells. Extracellular edema often results from capillary injuries at specific areas. This leads to breakdown of the blood brain barrier and leakage of protein and fluids into the extracellular space affected. A third category of edema, interstitial edema, is sometimes seen in acute obstructive hydrocephalus (See Table 1)

Type of Edema	Pattern	Mechanism	Differential Diagnosis	Potential Therapies
Vasogenic	Extracellular spaces in white matter.	Blood brain barrier breakdown secondary to capillary injury near focal lesions.	Tumors. Hemorrhage. Infection. Inflammation.	Surgery Antibiotics Steroid
Hydrostatic	Extracellular spaces in white matter and grey matter. Often diffuse. Can favor posterior circulation in PRES. Can be unilateral in CHS.	Increased cerebral capillary water influx across blood brain barrier because of elevated pressure states.	Hypertensive Emergencies. Hyperperfusion Syndromes. Hepatic Encephalopathy	Antihypertensives
Interstitial	Prefers Periventricular white matter, especially frontal and occipital lobes.	Transepndymal flow of cerebrospinal fluid in hydrocephalus.	Acute Obstructive Hydrocephalus.	Shunt or EVD
Cytotoxic	Often intracellular. Prefers grey matter	Na/K Pump breakdown and damaged cell membranes leading to water entry into cells and cellular swelling.	Infarct. Trauma. Toxins. Hepatic Encephalopathy. Hypoxic Ischemic Encephalopathy	Mannitol Hypertonic Saline

Table 1. Types of Cerebral Edema

When ICP remains severely and persistently elevated it is sometimes referred to as malignant intracranial hypertension and secondary brain injury is often the far more severe and deadly issue for the patient. ICP monitoring should be considered in any traumatic head injury presenting with a Glasgow coma score (GCS) of less than 9 and an abnormal computed tomography (CT) of head. Even in the absence of an abnormal CT scan, evidence suggests severe head trauma patients are still at significant risk of elevated ICP, particularly those greater than 40 years of age, showing signs of motor posturing, or having a systolic

blood pressure less 90 mmHg or less.<sup>1</sup> A GCS of less than 9 and at least two of these three risk factors warrants consideration for continuous ICP monitoring, regardless of CT findings. ICP monitoring may also be warranted in cases where CSF flow appears disrupted or potentially disrupted. This is because of the potential for obstruction of drainage of flow of CSF and in the setting of acute brain injury, obstructive hydrocephalus can have an accelerating effect on ICP. This is often seen in the context of tumors, infections or hemorrhage either within the ventricular system or just outside of it. Whether the result of direct intraventricular obstruction or extraventricular mass effect with secondary ventricular system obstruction, these situations can lead to rapidly rising ICP and risk of deadly brain herniation.

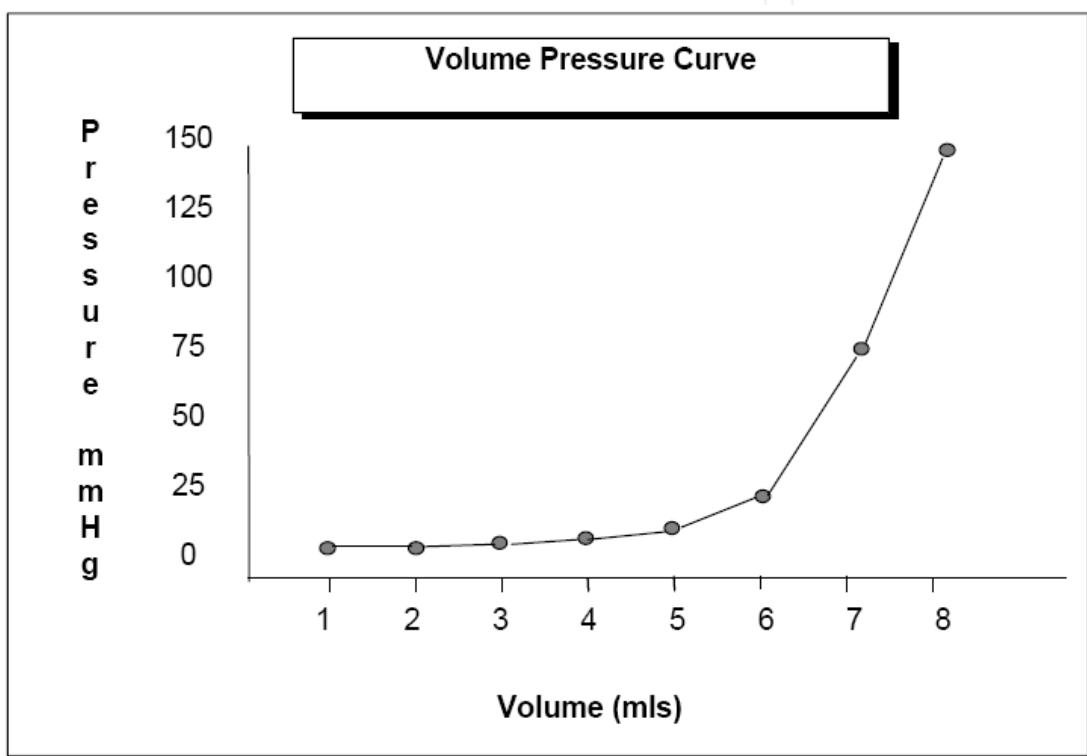


Fig. 1. ICP - Volume Curve showing exponential increases in ICP as skull compensatory mechanisms exhaust in the face of increasing intracranial volume.

### 3. Monitoring

Often by the time of clinical deterioration, ICP has been elevated for some time causing significant neuronal damage through progressive tissue swelling, ischemia, and hypoperfusion. Without emergent intervention, the process of deadly brain herniation may have already begun. Unfortunately, only the early stages are reversible and the clinical changes can be sudden. As a result, non-clinical modes of assessment such as continuous ICP monitoring have proven invaluable in head injury patients. Although there are several different forms of ICP monitoring devices, the external ventricular drain or catheter (EVD) has become the gold standard for accurate measurement and monitoring of ICP in the ICU. As its name implies, the EVD not only provides ICP monitoring, but allows for CSF drainage in response to ICP levels. Although associated with small risks of infection and

bleeding, the ability to recalibrate over time for sustained accuracy and the ability to drain CSF in response to ICP make the EVD superior to other ICP monitoring devices.

The goal of ICP management is to prevent secondary brain injury, particularly from herniation or ischemia and infarction. Brain herniations occur as a result of pressure gradients created in the skull by either localized or generalized mass effect. Although, herniation is more likely to occur with progressive increases in ICP, there is no specific ICP known to be a threshold for herniation. Furthermore, certain herniations can occur without raised ICP, resulting solely from a localized pressure gradient such as in tentorial (uncal) herniation from a temporal lobe mass.<sup>2</sup> Brain herniation is only reversible if treated early with aggressive medical and surgical intervention. Delays in treatment and inadequate treatment are associated with progressive herniation and severe and irreversible brain injury often leading to death. Special attention to the signs of brain herniation must be paid to all patients with raised ICP and to all patients with temporal lobe masses.

Marked elevations in ICP lead to compromise in cerebral perfusion either locally or diffusely which in turn leads to ischemia and eventually infarction. CBF is closely correlated to cerebral perfusion pressure (CPP) through cerebral vascular resistance (CVR). Although, measures of CBF and CVR are not easily accessible, CPP can be calculated as the difference between mean arterial pressure (MAP) and ICP and CPP is often used as a surrogate for CBF. Although there is some conflicting evidence and opinion regarding the optimal CPP for head injury patients with raised ICP, the largest group of patients studied is within the traumatic brain injury population. It suggests that a CPP between 60 to 70 mmHg and ICP less than 20 mmHg may be associated with improved outcome and fewer complications from therapy in patients with brain injury and elevated ICP.<sup>3</sup>

#### 4. Managing ICP

The medical management of ICP starts with principles of physiologic homeostasis including optimizing cerebral venous return. Evidence supports the practice of elevating the head of the bed to 30° or more for patients with raised ICP, however, in patients who are hypovolemic, this change in position may cause decreases in CPP by decreasing the MAP more than the ICP. Attention to CPP and ICP should be paid to ensure CPP is not compromised. Facilitating physiologic homeostasis also includes early treatment of factors that can worsen ICP such as fever, hypercarbia and seizures.

Other medical management aimed at treating elevated ICP has been investigated for several years with limited success. Although several strategies have been shown to reduce ICP for short periods of time, very few have proven to be effective long term therapies or have a significant impact on patient outcome. One of the more commonly accepted approaches is to minimize agitation and excess muscle activity which can worsen ICP. This usually involves the use of analgesics and sedatives. The agents most commonly used are narcotics such as morphine and fentanyl for analgesics and benzodiazepines such as midazolam and lorazepam for sedation. In many cases, barbituates and anesthetics such as propofol, can be used in small or large doses in an attempt to decrease cerebral metabolism and cerebral oxygen requirements. This has been shown to reduce ICP and the decrease in cerebral oxygen requirements may result in a decrease in the absolute amount of cerebral blood flow needed to prevent further brain injury. The use of “drug induced coma” to decrease cerebral

metabolic rate remains controversial. This is largely because of the lack of convincing evidence that this approach changes outcome and the significant systemic and hemodynamic complications associated with these medications at high doses for long periods of time.<sup>5,6</sup> Regardless, both barbituates and anesthetics such as propofol have been shown to be effective in decreasing ICP in a dose related fashion and assuming a patient is hemodynamically stable, these agents can often be used safely for extended periods with favorable responses on ICP.

Occasionally, neuromuscular blockers are required, however routine use of neuromuscular blockers has not been shown to improve outcome and is associated with increased complications including pneumonia and sepsis. In the setting where paralysis is considered to control excess movements in association with persistently elevated ICP, encephalography (EEG) be considered to rule out ongoing seizures. Continuous EEG is used in some centres to monitor brain wave activity and to observe for the potential of non-clinical seizures. Although standard 20 minute EEG has not been shown to correlate with a high detection rate of seizures, any concern regarding the possibility of non-clinical seizures warrants assessment with EEG, if not continuous then intermittent.<sup>5</sup>

Other medications focus on diuresing fluid, presumably edema, from the brain with osmotic diuretics or hypertonic solutions. The most extensively used agent is mannitol and various clinical and experimental studies have shown reductions in ICP with the use of mannitol.<sup>5</sup> The effect of mannitol on ICP involves several mechanisms including decreasing blood viscosity, decreasing CSF production, and fluid shift from brain tissue to intravascular compartments. The effects are usually not sustained and repeated doses over a prolonged period are often required. Earlier studies have also suggested the effects of mannitol on ICP could be prolonged with the concomitant use of furosemide. Whether used alone or in combination with another diuretic, prolonged mannitol use can lead to problems with dehydration, elevated serum osmolality, and renal impairment. Furthermore, the use of mannitol is less effective and potentially aggravating in cases of localized lesions with significant vasogenic edema, such as hemispheric ischemic strokes. In such cases, localized pressure gradient or a compartmentalized ICP is a more likely cause of neurological deterioration rather than a generalized increase in ICP.<sup>7</sup> The effects of mannitol in these cases will be seen maximally in normal and non affected areas of the brain which can potential worsen the pressure gradient further.<sup>8</sup> Kauffman et al investigated mannitol in the treatment of vasogenic cerebral edema following ischemic stroke and found that with multiple mannitol injections, non-infarcted hemisphere shrunk more compared to the infarcted hemisphere. He concluded that prolonged mannitol use may actually cause a reversal of the osmotic gradient between edematous brain and plasma, and worsen localized vasogenic edema in cases of large ischemic strokes with vasogenic edema.<sup>9</sup> Similarly, several stroke specific trials found that if hyperosmolar therapy was used continuously for greater than 48 hours, it was associated with worse outcome and increased risk of herniation. The effects are felt to be secondary to increasing ICP differentials between infarcted brain and healthy brain and thereby increasing the chances of herniation, as the osmotic agents may collect in the infarcted tissue and then induce increasing edema. Consequently, mannitol

---

<sup>5</sup> Scozzafava J, Hussain MS, Brindley PG, Jacka MJ, Gross D. The role of 20 minute EEG in the comatose patient. *Journal of Clinical Neurosciences*. Jan 2010;17(1):64-8.

should be used cautiously in any patient with hemispheric masses or lesions and in cases where repeated dose are to be used for a prolonged period of time. In more recent years, hypertonic saline has also been used and like mannitol, hypertonic saline acts by pulling water from brain tissue to the intravascular space. Hypertonic saline is associated with slightly less concerns regarding electrolyte disturbance, dehydration and renal injury, however similar precautions should be taken in regards to hemispheric lesions, particularly ischemic strokes with significant vasogenic edema. At the present time, there are no established guidelines for its use, however most studies have used 3% or 7.5% at rates of 20 to 40 cc/hr. Prolonged infusions should be run only in an ICU setting and discontinuation should be tapered slowly to prevent rebound hyponatremia.

Several other measures should be considered second tier in the management of ICP because of their lack of proven benefit and/or the significant risks associated with their use. These include hyperventilation and hypothermia. For years, hyperventilation was thought to be a safe and effective method of lowering ICP. Its action is through generalized vasoconstriction of small cerebral arteries in response to low carbon dioxide levels in the blood. It causes a relatively quick decrease in ICP at the expense of a corresponding decrease in CBF and at the risk of resultant cerebral ischemia. Further evidence has shown hyperventilation to be an ineffective method of managing ICP and possibly detrimental in several subgroups of patients.<sup>13</sup> Its use should be avoided in most circumstances.

The concept of hypothermia as a possible neuroprotectant has been explored for several years. Evidence exists that induced hypothermia lowers ICP, likely through decreasing cerebral metabolic rate, however it has not been shown to correlate to a decreased rate of secondary brain injury. Although increasing evidence suggests a role for therapeutic hypothermia to protect the brain from secondary injury following cardiac arrest, similar evidence has not developed in other situations, particularly primary brain injury such as trauma and stroke. A randomized controlled trial in severe closed head injury failed to show any benefit of induced hypothermia on outcome.<sup>14</sup> Further trials in various subgroups of patients are underway.

In many cases, ICP proves resistant to aggressive medical management and surgical intervention is required beyond the EVD. This is frequently seen in association with mass lesions. Mass lesions can include tumors, abscesses or hemorrhages which are all frequently prone to edema which further aggravates ICP and poses an increasing risk of herniation. In the case of tumors, resection often results in resolution of ICP issues. In the case of abscess, drainage not only serves to reduce ICP, but treats the infection and prevents further spread.

The recommended management of hematoma depends on location, size of hematoma and extent of neurological injury as well as ICP. Subdural and epidural hematomas causing increased ICP generally should be considered for surgical evacuation. Subarachnoid hemorrhage (SAH) is often the result of a ruptured cerebral artery aneurysm or arteriovenous malformation. Definitive management of the hemorrhage and the ICP must involve securing the ruptured vessel(s). In cases of parenchymal intracerebral hemorrhage (ICH) or hemorrhagic stroke, several randomized trials have failed to demonstrate benefit associated with surgical evacuation of supratentorial ICH, regardless of ICP.<sup>15</sup>

However, there is one sub-group of hemorrhagic stroke that has shown to benefit from aggressive and early surgical intervention. Although, there are no randomized trials looking

specifically at surgical evacuation of cerebellar hematomas, a non-randomized case series has shown urgent surgical evacuation of cerebellar hemorrhage improves outcome compared to medical management alone.<sup>16</sup> It included patients with GCS < 13, and hematoma > 40 mm. 45 patients were treated medically and 30 patients were treated with decompressive surgery. Good outcome occurred 58% with surgery while only 18% with conservative medical therapy. A large reason for this may be because of the reasonable potential for recovery regardless of stroke burden in cerebellum. The factor which is often more critical is the acute and progressing edema and/or hemorrhage which may prove to compromise the nearby fourth ventricle of the ventricular system and lead to obstructive hydrocephalus. As a result, a cerebellar hemorrhage which would otherwise have potentially good outcome, could rapidly progress to malignant intracranial hypertension and death. Our recommendation is for the prophylactic insertion of EVD or suboccipital decompressive craniectomy for patients with cerebellar hemorrhage and hematoma > 3 cm in diameter or obstructive hydrocephalus.

Medically intractable ICP is also frequently seen with severe head trauma. Unlike mass lesions and vascular anomalies, an underlying structural abnormality cannot be removed unless associated with significant secondary hematoma. Surgical treatment of ICP has focused on brain decompression in these patients. Both hemispheric and bifrontal craniectomy have both been shown to be effective in managing medically intractable ICP following head trauma and should be considered when medical measures have failed.<sup>17-22</sup>

Decompressive craniectomy for prevention of fatal brain herniation has been for almost 100 years. The rationale for surgery is to change the inelastic container or 'closed box' and provide a mechanical outlet for the edematous brain to stretch beyond the skull thereby preventing herniation. As a consequence, secondary benefits include rapid reduction of intractable ICP and restoration of cerebral perfusion.

## 5. Considerations specific to ischemic stroke

Issues regarding raised ICP are less often encountered in ischemic stroke compared to hemorrhagic stroke. Similarly, the management of malignant intracranial hypertension is far less seen in ischemic stroke patients compared to hemorrhagic stroke or other neurology and neurosurgery patients presenting with mass lesions. This is because in the case of ischemic stroke, a new mass or volume is not immediately introduced into our "closed box" model of intracranial contents like with other causes of brain injury like hemorrhage or tumor. However, immediately after the onset of ischemia changes begin to occur including cerebral edema.

It has been estimated that anywhere from 1-10% of supratentorial ischemic strokes can cause rapid neurological deterioration from space-occupying cerebral edema. Although ischemic strokes display some vasogenic edema as part of the inflammatory phase, the primary swelling is the result of cytotoxic edema. Cytotoxic edema is the result of damaged cell membranes during ischemia. The result is that neuronal cells fill with plasma ultrafiltrate. Although this usually occurs between the second and fifth day after stroke, it can occur as early as 24 hours. Such a presentation following an ischemic stroke involving the entire middle cerebral artery (MCA) territory is called 'malignant MCA infarction' (MMI). This is often a consequence of occlusion of the internal carotid artery or the proximal portion of the



middle cerebral artery. The prognosis of MMI is poor and mortality is as high as 80%, with most deaths occurring during the first week from cerebral edema and brain herniation.<sup>23</sup>

Multiple non-randomized studies have shown that decompressive surgery, consisting of a hemicraniectomy and duraplasty reduces mortality in patients with MMI.<sup>24-26</sup> However, its popularity decreased because clinicians were concerned as to whether survival was at the expense of poor functional outcome. In the midst of uncertainty regarding functional outcome, three European trials have addressed the role of decompressive hemicraniectomy on functional outcome since 2000: the French DECIMAL (decompressive craniectomy in malignant middle cerebral artery infarcts) trial; the German DESTINY (decompressive surgery for the treatment of malignant infarction of the middle cerebral artery) trial; and the Dutch HAMLET trial (hemicraniectomy after middle cerebral artery infarction with life-threatening edema trial). A pooled analysis of all three trials confirmed suggestions from earlier non-randomized trials. Decompressive hemicraniectomy undertaken within 48 hours of onset of MMI reduces mortality and increases the number of patients with a favorable functional outcome.<sup>27-30</sup>

The trials were both praised and criticized on many points. Analysis of all the trials was assumed possible due to similar design and use of the modified Rankin Scale (mRS) as a common primary outcome measure. Significant difference between the trials included imaging modalities and longer treatment window allowed in HAMLET, which allowed patients to be treated up to 96 hours after onset of stroke symptoms. However, the pooled analysis included only the patients randomized and treated within 48 hours. The primary outcome measure for the pooled analysis was the mRS dichotomized between “favorable” (defined as mRS 0-4) and “unfavorable” (mRS 5-6). There was clearly a difference between the two treatment arms, with 75% achieving a favorable outcome in the hemicraniectomy group as compared to 24% in the medical treatment alone arm ( $p < 0.01$ ). The most robust effect was seen on survival, which increased from 28% to nearly 80% with DCH. Perhaps the most significant result was the proportion of patients who were independent with disability (mRS 2) which increased more than five times with DCH from 2.5% to 14%. Forty three percent of patients had a good clinical outcome with mRS 2-3 after a DCH compared to 21.5% of patients who received conservative therapy. However, the proportion of patients surviving with moderate-to-severe disability was increased more than 12-fold (31% vs. 2.5%) but the rates of very severe disability was not increased after DCH (4% vs. 5%).

Despite the evidence provided by these trials, the most crucial question remains the selection of patients for surgery because not all middle cerebral infarctions lead to MMI and no single prognostic factor has been identified as a predictor of fatal outcome in MMI. Neuroimaging combined with clinical examination does provide valuable information to identify patients at risk. Early ischemic changes (less than 6 hours) on CT scan that involves greater than 50% of the MCA territory have been associated with fatal outcomes. This included such early CT changes as localized cerebral edema causing sulcal effacement or compression of the lateral ventricle.<sup>31</sup> The DECIMAL trial used a critical stroke volume of 145 mL on diffusion-weighted MRI and confirmed this cut off value suggested by previous authors. Analysis showed 78% mortality in strokes with >145 mL volume and no deaths when the stroke volume was less than 145mL. NIHSS  $\geq 20$  (dominant hemisphere) or  $\geq 15$  (non-dominant hemisphere) within 6 hours of symptom onset along with CT findings of hypodensity >50% were also associated with high risk for developing malignant cerebral edema.<sup>32</sup>

Age is another important consideration in this population following MMI. The upper age limit in the above randomized trials was 60-years and therefore the results are not easily transferable to individuals older than 60 years. As we have seen with many interventions, with older patient populations come more medically complex and often fragile patients. DESTINY II is underway to evaluate the benefit of surgery in this older patient population, which may be more indicative of the stroke population seen in most hospitals. However, non-randomized trials which investigated this question showed that mortality and poor outcome were significantly higher in patients older than 60 years of age.<sup>33,34</sup> Regardless of the results of DESTINY II, the decision to operate on patients older than 60 years of age should be individualized and must take into consideration patients declared wishes and social support. It must be kept in mind that outcomes in this population depend on several factors like admission functional status, cognitive ability and presence of social support.

The timing of surgery is also significant. From the individual results and pooled analysis of DECIMAL and DESTINY, patients who were surgically treated with decompressive hemicraniectomy within 48 hours did better when compared to the HAMLET trial in which there was no improvement in functional outcome despite decrease in mortality in patients who received delayed surgical treatment (up to 96 hours after symptoms onset). Early decompressive hemicraniectomy (<48hours) is recommended for all patients with MMI and impending herniation who are felt to have good potential for recovery from the initial ischemic injury of the stroke.

In contrast to supratentorial ischemic strokes, the question of surgical intervention in large cerebellar strokes is less controversial. Fatal space occupying edema can develop in 17% - 54% of cerebellar strokes resulting in obstructive hydrocephalus, transforaminal or transtentorial herniation and brain stem compression. Although lacking evidence from randomized clinical trials, it is widely accepted that surgical intervention with suboccipital decompressive craniectomy or insertion of an external ventricular drainage is lifesaving in malignant cerebellar infarctions and with the potential for good clinical outcomes. The long term outcome in survivors is also good, especially where there is no associated brainstem infarction.<sup>35,36</sup> Similar to cerebellar hematoma, these patients should be considered for early decompression.

## **6. ICP in aneurysmal subarachnoid hemorrhage**

Case report and case series evidence in aneurysmal SAH continues to emerge describing beneficial effects of decompressive craniectomy on elevated ICP and on outcome. The factors affecting ICP in aneurysmal SAH can include ongoing hemorrhage, edema and vasospasm with secondary ischemia. In cases of high grade SAH with severely and persistently elevated ICP, decompressive craniectomy should be considered in conjunction with early securing of aneurysm in an effort to maximize the chances of good outcome.<sup>37,38</sup> Location of SAH may also play a factor in both outcome and surgical approach. Case series evidence has described dramatic recoveries in patients with high grade SAH from anterior communicating artery aneurysm ruptures and malignant ICP managed with bifrontal decompressive craniectomy.<sup>39</sup> The evidence may be related to the observation that high grade SAH from anterior communicating artery aneurysm ruptures often present without

significant initial brain tissue injury but with significant subarachnoid hematoma and dramatic bilateral cerebral edema. The prominent edema associated with these SAH's often precipitates uncontrollable ICP levels and surgical management of the ICP with craniectomy may offer the opportunity for hematoma resolution and often dramatic recovery. A randomized controlled trial has been initiated to investigate this further.

## 7. Conclusion


The management of ICP is critical in patients with brain injury, whether from trauma, stroke or hemorrhage. Although recovery is inevitably limited by the degree of initial injury incurred, morbidity and mortality rise dramatically in the face of uncontrollable ICP. The management of elevated ICP has evolved significantly over the past century. Despite extensive research for many years, evidence for most medical therapies is lacking. In recent years, redirection toward early surgical intervention has re-emerged, particularly with subsets of trauma, stroke and subarachnoid hemorrhage patients. Evidence from case reports and small trials will need to be supported by larger trials. Even evidence from large trials needs to be scrutinized and challenged again with further trials to determine which patients may benefit the most from which therapies, particularly decompressive surgery. This may lead to more focused and more successful management of all patients with ICP issues. Inevitably all therapies have to be individualized to each individual case. In the mean time, courage and determination are needed by healthcare providers dealing with these emergencies since delays in recognition and intervention are often fatal.

## 8. References

- [1] Narayan RK, Kishore PR, Becker DP et al. Intracranial pressure: to monitor or not to monitor? A review of our experience with acute head injury. *J Neurosurg* 56:650-659, 1982.
- [2] Kincaid MS, Lam AM, Monitoring and Managing Intracranial Pressure. *Continuum: Lifelong Learning in Neurology*. 2006; 12(1): 93-108.
- [3] Robertson, C. S., Valadka, A. B., Hannay, H. J., Contant, C. F., Gopinath, S. P. Cormio, M., Uzura, M., Grossman, R. G. (1999). Prevention of secondary ischemic insults after severe head injury. *Critical Care Medicine*, 27, 2086-2095.
- [4] Fan JY, Effect of backrest position on intracranial pressure and cerebral perfusion pressure in individuals with brain injury: a systematic review. *J Neurosci Nurs*. 2004 Oct;36(5):278-88.
- [5] Piek J: Barbiturate coma in patients with severe head injuries: long-term outcome in 79 patients. *Adv Neurosurg* 21:178--183, 1993
- [6] Eisenberg H, Frankowski R, Contant C et al. Comprehensive central nervous system trauma centers: High dose barbiturate control of elevated intracranial pressure in patients with severe head injury. *J Neurosurg* 1988;69: 15-23
- [7] Weaver DD, Winn HR, Jane JA. Differential intracranial pressure in patients with unilateral mass lesion. *J Neurosurg* 1982;56:660-5.
- [8] Kalita J, Ranjan P, Misra UK. Current status of osmotherapy in intracerebral hemorrhage. *Neurology India* 2003; 51(1): 104-109.
- [9] Kaufmann AM, Cardoso ER. Aggravation of vasogenic cerebral edema by multiple dose of mannitol. *J Neurosurg*. 1992;77:584-9.

- [10] Juttler E, Schellinger P, Aschoff A, et al. Clinical review: therapy for refractory intracranial hypertension in ischaemic stroke. *Crit Care*. 2007;11:231-44.
- [11] Berezcki D, Liu M, Fernandes do Prado G, et al. Mannitol for acute stroke. *Cochrane Database Syst Rev*. 2007; Issue 3. Art No: CD001153.
- [12] Qureshi AI, Suarez JJ, Bhardwaj A, et al. Use of hypertonic (3%) saline/acetate infusion in the treatment of cerebral edema: effect on intracranial pressure and lateral displacement of the brain. *Crit Care Med*. 1998;26:440-6.
- [13] Muizelaar JP, Marmarou A, Ward JD, et al. Adverse effects of prolonged hyperventilation in patients with severe head injury: a randomized clinical trial. *J Neurosurg* 1991;75:731-9.
- [14] Clifton GL, Miller ER, Choi SC, et al. Lack of effect of induction of hypothermia after acute brain injury. *N Engl J Med* 2001;344:556-63.
- [15] Fernandes HM, Gregson B, Siddique S, et al. Surgery in intracerebral hemorrhage: the uncertainty continues. *Stroke*. 2000 Oct;31(10):2511-6.
- [16] Kobayashi S, Miyata A, Serizawa T, et al. Treatment of cerebellar hemorrhage – surgical or conservative. *Stroke*. 1990; 21(8) Suppl: I-62.
- [17] Kjellberg RN, Prieto A. Bifrontal decompressive craniotomy for massive cerebral edema. *J Neurosurg*. 1971;34:488-493.
- [18] Kleist-Welch Guerra W, Gaab MR, Dietz H, et al. Surgical decompression for traumatic brain swelling: indications and results. *J Neurosurg* 1999;90:187-96.
- [19] Polin RS, Shaffrey ME, Bogaev CA, et al. Decompressive bifrontal craniectomy in the treatment of severe refractory posttraumatic cerebral edema. *Neurosurgery* 1997;41:84-92.
- [20] Guerra WK, Gaab MR, Dietz H, Mueller JU, Piek J, Fritsch MJ. Surgical decompression for traumatic brain swelling: indications and results. *J Neurosurg*. 1999 Feb;90(2):187-96.
- [21] Ziai WC, Port JD, Cowan JA, Garonzik IM, Bhardwaj A, Rigamonti D. Decompressive craniectomy for intractable cerebral edema: experience of a single center. *J Neurosurg Anesthesiol*. 2003 Jan;15(1):25-32.
- [22] RS, Shaffrey ME, Bogaev CA, et al. Decompressive bifrontal craniectomy in the treatment of severe refractory posttraumatic cerebral edema. *Neurosurgery* 1997;41:84-92. *Surg Gyn Obstet* 1905, 1:297-314.
- [23] Hacke W, Schwab S, Horn M, et al. Malignant middle cerebral artery territory infarction: clinical course and prognostic signs. *Arch Neurol*. 1996;53:309-315.
- [24] Robertson SC, Lennarson P, Hasan DM, et al. Clinical course and surgical management of massive cerebral infarction. *Neurosurgery*. 2004;55:55- 61;discussion 61-2.
- [25] Walz B, Zimmermann C, Bo'ttger S, et al. Prognosis of patients after hemicraniectomy in malignant middle cerebral artery infarction. *J Neurol*. 2002;249:1183-90.
- [26] Schwab S, Steiner T, Aschoff A, et al. Early hemicraniectomy in patients with complete middle cerebral artery infarction. *Stroke*. 1998;29:1888 -1893.
- [27] Juttler E, Schwab S, Schmiedek P, et al. Decompressive surgery for the treatment of malignant infarction of the middle cerebral artery (DESTINY): a randomized, controlled trial. *Stroke*. 2007;38:2518 -2525.
- [28] Vahedi K, Vicaut E, Mateo J, et al. Sequential-design, multicenter, randomized, controlled trial of early decompressive craniectomy in malignant middle cerebral artery infarction (DECIMAL Trial). *Stroke*. 2007;38:2506 -2517.

- [29] Hofmeijer J, Kappelle LJ, Algra A, et al. Surgical decompression for space-occupying cerebral infarction (the Hemicraniectomy After Middle Cerebral Artery infarction with Life-threatening Edema Trial [HAMLET]): a multicentre, open, randomised trial. *Lancet Neurol.* 2009 Apr;8(4):326-33.
- [30] Vahedi K, Hofmeijer J, Juettler E, et al Early decompressive surgery in malignant middle cerebral artery infarction: a pooled analysis of three randomized controlled trials. *Lancet Neurol.* 2007;6:215-222.
- [31] von Kummer R, Meyding-Lamade U, Forsting M, et al. Sensitivity and prognostic value of early CT in occlusion of the middle cerebral artery trunk. *Am J Neuroradiol.* 1994;15:9-15; discussion 16-8.
- [32] von Kummer R, Meyding-Lamade U, Forsting M, et al. Sensitivity and prognostic value of early CT in occlusion of the middle cerebral artery trunk. *Am J Neuroradiol.* 1994;15:9-15; discussion 16-8.
- [33] Holtkamp M, Buchheim K, Unterberg A, et al Hemicraniectomy in elderly patients with space occupying media infarction: improved survival but poor functional outcome. *J Neurol Neurosurg Psych.* 2001;70:226-228.
- [34] Van der Worp HB, Kappelle LJ. Early decompressive hemicraniectomy in older patients with nondominant hemispheric infarction does not improve outcome. *Stroke.* 2011;42:845-846.
- [35] Adams HP Jr, del ZG, Alberts MJ, et al Guidelines for the early management of adults with ischemic stroke: a guideline from the American Heart Association/American Stroke Association Stroke Council, Clinical Cardiology Council, Cardiovascular Radiology and Intervention Council, and the Atherosclerotic Peripheral Vascular Disease and Quality of Care Outcomes in Research Interdisciplinary Working Groups: The American Academy of Neurology affirms the value of this guideline as an educational tool for neurologists. *Circulation.* 2007;115: e478-e534.
- [36] Thomas Pfefferkorn, Ursula Eppinger; Jennifer Linn, et al Long-Term Outcome After Suboccipital Decompressive Craniectomy for Malignant Cerebellar Infarction *Stroke.* 2009;40:3045-3050.)
- [37] Smith ER, Carter BS, Ogilvy CS. Proposed use of prophylactic decompressive craniectomy in poor-grade aneurysmal subarachnoid hemorrhage patients presenting with associated large sylvian hematomas. *Neurosurgery.* 2002 Jul;51(1):117-24; discussion 124.
- [38] Fisher CM, Ojemann RG. Bilateral decompressive craniectomy for worsening coma in acute subarachnoid hemorrhage. Observations in support of the procedure. *Surg Neurol* 1994;41:65-74.
- [39] Scozzafava J, Brindley PG, Mehta V, Findlay JM. Decompressive Bifrontal Craniectomy for Malignant Intracranial Pressure Following Anterior Communicating Artery Aneurysm Rupture: two case reports. *Neurocritical Care.* February, 2007; 6(1): 49-53.



## **Advances in the Treatment of Ischemic Stroke**

Edited by Dr. Maurizio Balestrino

ISBN 978-953-51-0136-9

Hard cover, 246 pages

**Publisher** InTech

**Published online** 02, March, 2012

**Published in print edition** March, 2012

In recent years research on ischemic stroke has developed powerful therapeutic tools. The novel frontiers of stem cells therapy and of hypothermia have been explored, and novel brain repair mechanisms have been discovered. Limits to intravenous thrombolysis have been advanced and powerful endovascular tools have been put at the clinicians' disposal. Surgical decompression in malignant stroke has significantly improved the prognosis of this often fatal condition. This book includes contributions from scientists active in this innovative research. Stroke physicians, students, nurses and technicians will hopefully use it as a tool of continuing medical education to update their knowledge in this rapidly changing field.

### **How to reference**

In order to correctly reference this scholarly work, feel free to copy and paste the following:

James Scozzafava, Muhammad Shazam Hussain and Seby John (2012). Medical and Surgical Management of Intracranial Hypertension, *Advances in the Treatment of Ischemic Stroke*, Dr. Maurizio Balestrino (Ed.), ISBN: 978-953-51-0136-9, InTech, Available from: <http://www.intechopen.com/books/advances-in-the-treatment-of-ischemic-stroke/medical-and-surgical-management-of-intracranial-hypertension>

**INTECH**  
open science | open minds

### **InTech Europe**

University Campus STeP Ri  
Slavka Krautzeka 83/A  
51000 Rijeka, Croatia  
Phone: +385 (51) 770 447  
Fax: +385 (51) 686 166  
[www.intechopen.com](http://www.intechopen.com)

### **InTech China**

Unit 405, Office Block, Hotel Equatorial Shanghai  
No.65, Yan An Road (West), Shanghai, 200040, China  
中国上海市延安西路65号上海国际贵都大饭店办公楼405单元  
Phone: +86-21-62489820  
Fax: +86-21-62489821

© 2012 The Author(s). Licensee IntechOpen. This is an open access article distributed under the terms of the [Creative Commons Attribution 3.0 License](#), which permits unrestricted use, distribution, and reproduction in any medium, provided the original work is properly cited.

IntechOpen

IntechOpen