

# We are IntechOpen, the world's leading publisher of Open Access books Built by scientists, for scientists

5,300

Open access books available

132,000

International authors and editors

160M

Downloads

Our authors are among the

154

Countries delivered to

TOP 1%

most cited scientists

12.2%

Contributors from top 500 universities



WEB OF SCIENCE™

Selection of our books indexed in the Book Citation Index  
in Web of Science™ Core Collection (BKCI)

Interested in publishing with us?  
Contact [book.department@intechopen.com](mailto:book.department@intechopen.com)

Numbers displayed above are based on latest data collected.  
For more information visit [www.intechopen.com](http://www.intechopen.com)



# Microorganisms and Atopic Dermatitis

Itaru Dekio

*Department of Dermatology, Faculty of Medicine, Shimane University, Izumo  
Japan*

## 1. Introduction

The relationship between microorganisms and human skin is complex. Some microorganisms are friendly residents, while others are harmful pathogens. Human skin has a variety of mechanisms for interacting with microorganisms, which promote the propagation of certain organisms while attacking others. Each of the different microorganisms discussed in this chapter has a unique relationship with humans. Their stories are not simple but are quite interesting.

To make the stories easier to understand, this chapter is divided into two sections. One section is devoted to the characteristics of the resident microbiota (microflora) of patients with atopic dermatitis (AD), while the other covers secondary infections that frequently occur in AD patients which are sometimes life-threatening. The microbiota of AD patients is significantly different from that of the normal population, and the relationship of microbiota with AD is widely accepted.

## 2. The microbiota (microflora) and atopic dermatitis

Human skin harbours many bacterial and fungal species, which are not apparently harmful. The total population of such residential microorganisms is known as the 'microbiota' (microflora). The microbiota is well balanced with the effect of natural human immunity, and the microorganisms have mechanisms to balance their population as a part of this community. Thus, it is appropriate to consider the microbiota as a 'microbial community'. It is generally accepted that the microbiota become stabilised at different points of balance in AD patients. This altered balance relates to the pathogenesis of AD as will be discussed below.

### 2.1 Ecology of skin microbiota

The microbiota of human skin differs largely according to skin sites. This is probably due to the fact that the structure and physiology of the surface of the skin differs at different sites of the body. This leads to the natural selection of certain species for particular sites. Thus, facial skin may be considered as a 'swamp' of sebum, soles could be considered as a 'pond' of sweat, axillae could be analogous to a 'rain forest', and forearms are 'deserts' which generally lack water and lipid.

As a reflection of this, for example, healthy facial skin harbours about  $10^8$  microbial cells per square centimetre, which comprises up to 2 g of microorganisms per face. On the other hand, healthy forearm skin harbours only  $10^3$  microbes per square centimetre. Therefore, in some body sites, the population is large enough to consider that the microbiota has a certain

physiological effects on the microecology of the skin. The scalp, face, neck, axilla, external genitalia, groin, and soles are examples of such sites. On the other hand, the microbiota seems to have little effect on the skin physiology at other sites with smaller populations, such as arms, hands, and legs.

## 2.2 Members of the normal skin microbiota

Because the skin microbiota differs considerably across different sites of the human body, it is not possible to describe the microbiota of the entire body in a single entity. In general terms, however, the major population of the normal microbiota consists of coagulase-negative *Staphylococcus* species, *Propionibacterium acnes*, and *Malassezia* species. Coagulase-negative *Staphylococcus* species are aerobic bacteria, *P. acnes* is a facultative anaerobic bacterium, and *Malassezia* species are yeasts (a single-cell form of fungus). All of these microorganisms live on the surface of the skin and in the hair follicles (Fig. 1). No other human organ has such a unique composition of microbiota. These three groups of microorganisms are retained in a balance between human immunity and each other.

### 2.2.1 Bacteria

Coagulase-negative *Staphylococcus* species are Gram-positive cocci. This group comprises *Staphylococcus* species other than *Staphylococcus aureus* and includes more than 10 species as *Staphylococcus epidermidis*. These bacteria grow under the aerobic condition and live in the colonisable layers of the skin. The term 'colonisable layers' here includes stratum corneum, the outermost barrier layer of the epidermis, and the outer thin section of viable layers of epidermis underneath the stratum corneum. These species can also grow under strict anaerobic conditions. This allows them to grow not only on the very surface of the skin but also deeper within skin layers where they compete for oxygen with other species. They are known to form grape-like clumps when cultured and normally also exist as clumps in skin layers.

*Propionibacterium acnes* is a Gram-positive bacillus, and is the most abundant in the human skin. Although this species is known to be an anaerobe, most strains also grow well in aerobic conditions (that is, facultative anaerobe). They live in the 'colonisable layers', in hair follicles, and in sebaceous glands. The genome analysis has revealed that they possess a lipase gene that enables them to degrade and metabolise lipids produced from sebaceous glands (Brüggemann et al., 2004). This species prospers in humans in the skin, conjunctiva, and prostate, but strangely, it is rarely found in other host species. This species usually forms a two-cell structure similar to the shape of eyeglasses when cultured, and they also take this form in human skin.

At certain skin sites, other species are the major species. For example, *Micrococcus* species, *Streptococcus* species, *Aerobacter* species, and *Proteus* species are cultured sometimes from the axilla and groin.

During the last decade, research on unculturable microorganisms using culture-independent molecular techniques has been carried out on various human organs. The results were surprising; the microbiota of some organs such as the oral cavity and gut are dominated mainly by unculturable or difficult-to-culture species. With regard to the skin, Dekio et al. first reported such an analysis of the skin microbiota including a large number of unculturable species in 2005 (Dekio et al., 2005). The microbiota included 22 species that remained unidentified on the skin, in addition to the 11 known skin bacteria (Table 1).

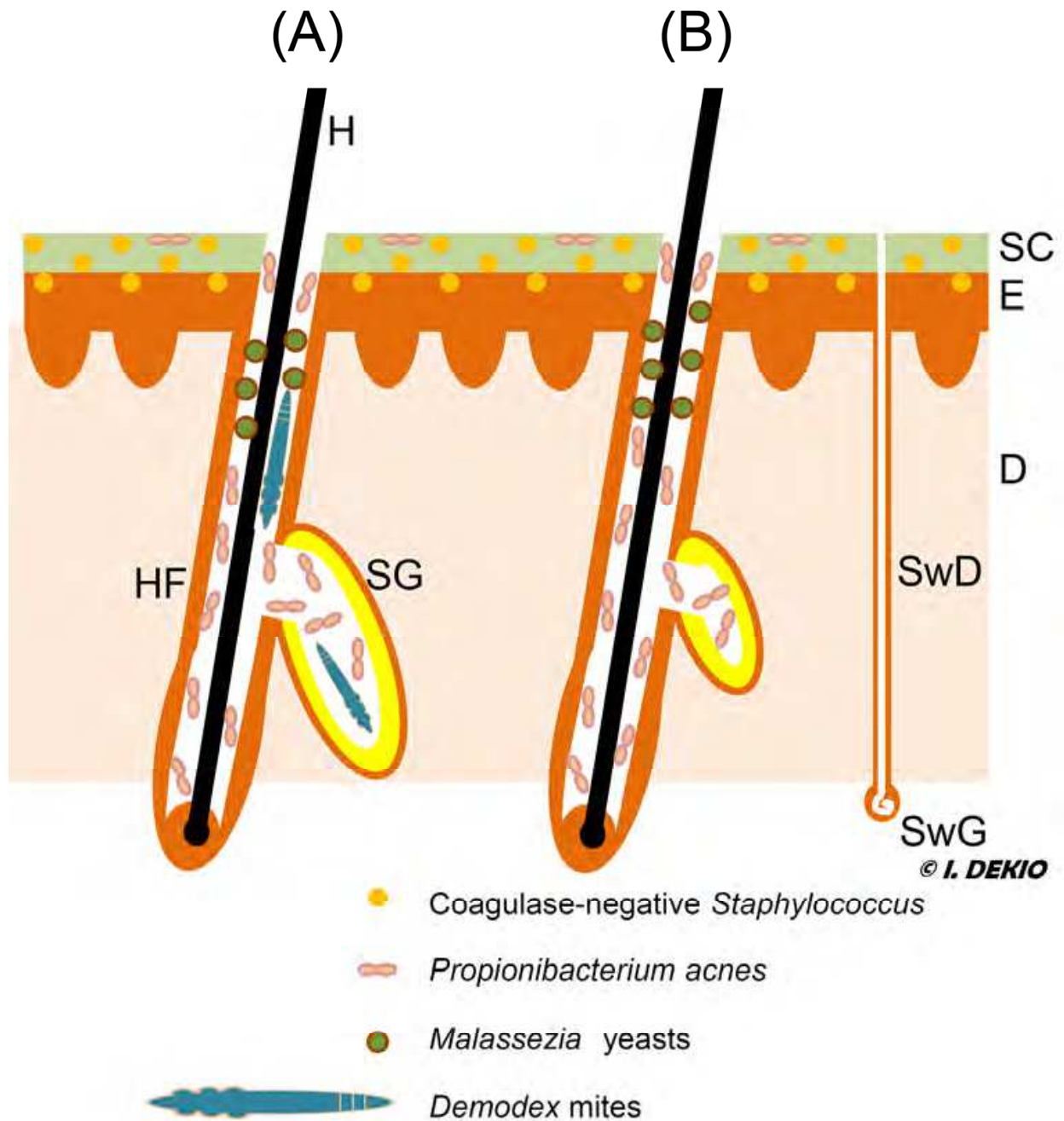


Fig. 1. Distribution of well-known skin inhabitants. (A) Typical hair follicle of the face. (B) Typical hair follicle of the trunk. SC, stratum corneum (a part of epidermis); E, viable portion of epidermis; D, dermis; H, hair; HF, hair follicle; SG, sebaceous gland; SwD, sweat duct; SwG, sweat gland. Note that the sweat duct and the sweat gland are considered to be sterile.

After this report, additional reports employing similar methods were published and a more complete picture of skin microbiota is emerging (Bek-Thomsen et al., 2008, Costello et al., 2009, Grice et al., 2009).

Known species	Unknown (uncultured) species
<i>Stenotrophomonas maltophilia</i>	Species close to <i>Methylophilus methylotrophus</i>
<i>Acidovorax temperans</i>	Species close to <i>Ideonella dechloratans</i>
<i>Corynebacterium</i> species	Species close to <i>Ammoniphilus oxalaticus</i>
<i>Dietzia maris</i>	Species close to <i>Anabaena cylindrica</i>
<i>Bacillus</i> species	Species close to <i>Aquaspirillum autotrophicum</i>

Table 1. Example of novel bacterial species identified in facial skin by molecular methods (Dekio et al., 2005)

### 2.2.2 Fungi

*Malassezia* species are fungal species that usually exist as yeasts in the healthy human skin. The major fungal members of human skin are *M. restricta* and *M. globosa* (Sugita et al., 2004). These fungi are aerobic and live only within the superficial portion of the hair follicle and the surface of the stratum corneum. The yeast forms are believed to be harmless to humans, but can change their shapes to form filaments if an unknown shift in the host-parasite relationship occurs. This shape change is associated with a disease known as tinea versicolor, a common infectious disease of the skin.

In addition, *Candida* species are detected in the skin less frequently. *Candida* species are well-known members of microbiota of the gut, but also colonise on the skin.

### 2.2.3 Viruses

It remains controversial whether viruses exist on the skin as members of the microbiota. The classical idea is that viruses do not exist on the healthy human skin. However, in a small percentage of healthy humans, there exists a phage PA6, which infects *P. acnes* cells. It is classified as a member of *Siphoviridae* family (Farrar et al., 2007). It is thought that the presence of this virus may explain why the resident bacteria cannot be cultured from certain skin samples.

In addition, there are some conditions that viruses lurk below the skin. Herpes simplex virus (HSV), which causes herpes simplex, becomes latent deep within the sensory ganglions after the first infection. Nearly 100% of adult humans are believed to have this virus somewhere in the ganglions. Certain healthy adults develop recurrent herpes simplex around the mouth or the genitalia, when exhausted. Under such conditions, HSV invades the skin from the ganglions via sensory nerves. Varicella-zoster virus (VZV) first invades humans from the throat when varicella, a febrile condition with small pustules also called chickenpox, appears. After relief from this condition, VZV remains in some of the sensory ganglions in 70% of the population, and after decades, it may appear via sensory nerves as herpes zoster. Both are categorised as members of the *Herpesviridae* (herpesvirus) family.

### 2.2.4 Arthropods

Surprisingly, mites also live within the hair follicle structures. *Demodex folliculorum* and *Demodex brevis* are such arthropods. Nearly 100% of the humans have these mites as a part of their microbiota. *D. folliculorum*, which has a long body, is believed to live in the follicles. *D. brevis* has a shorter body and lives in the sebaceous glands. These mites usually live in some but not all of the follicles of the facial skin without causing any harm. However, in some cases, the mites cause severe acne (demodex folliculitis), rosacea (rosacea-like demodicidosis [demodicosis]), or perioral dermatitis (Burns et al., 2010).

### 2.2.5 Possible interactions between a human host and microorganisms

Interactions of humans and members of the microbiota or among the members themselves (Fig. 2) are difficult to investigate because the phenomenon is often quite complex. Research is under way despite such difficulties.

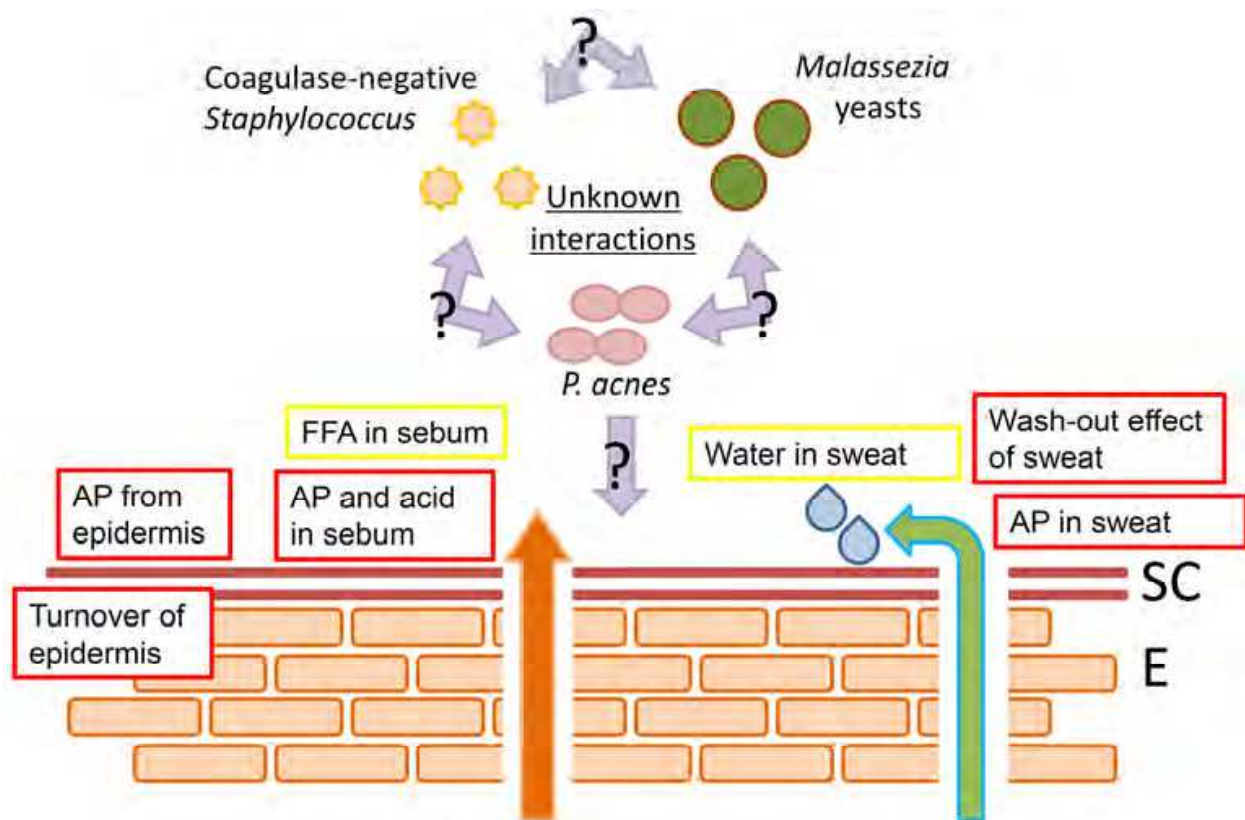


Fig. 2. Scheme of interactions between a human host and microorganisms. SC, stratum corneum; E, viable part of epidermis; AP, antimicrobial peptide; FFA, free fatty acid. The text encased in red rectangles indicates adverse effects towards microorganisms, and the text encased in yellow rectangles implies beneficial effects for them.

### 2.3 Characteristics of the microbiota in the skin of atopic dermatitis patients and its implications

Unlike the skin of healthy humans, the skin of AD patients is a 'rough ground' with less natural immunity. In a typical population of AD patients, the mutation in filaggrin gene (Palmer et al., 2006; Sasaki et al., 2008) results in impairment of the barrier function, and it allows the water content to evaporate. In addition, the sweat production is decreased because of the atrophy of the sweat glands. The resulting dry and rough surface allows easy colonisation of environmental bacteria. Moreover, a decrease in the amount of antimicrobial peptides in the sweat exaggerates the lack of immune function.

#### 2.3.1 Bacteria in AD

The major outcome of AD is the presence of *Staphylococcus* species in very high numbers. The staphylococcal population in AD patients is about 10-100 times larger than that of normal individuals (Gloor et al., 1982). The *Staphylococcus* species here includes both

coagulase-negative *Staphylococcus*, a major member of normal microbiota, and *S. aureus*, a harmful enemy from the environment that irritates the skin. In the skin of AD patients, the former is higher than usual while the latter also increases.

Coagulase-negative *Staphylococcus* provides a protective function to the skin by producing antimicrobial peptides against *S. aureus* (Cogen et al., 2010). Therefore, the growth of *S. aureus* leads to their production of exotoxins which exaggerate AD while the coagulase-negative *Staphylococcus* tries to eliminate them by they produce. The skin of AD patients is a battlefield of outnumbered 'the good' and growing 'the evil'.

Furthermore, *Stenotrophomonas maltophilia*, a previously unidentified bacterium on the skin and occasionally causes opportunistic sepsis in immunodeficient patients, was detected on the skin of patients with AD at a high frequency (Dekio et al., 2007). This species is closely related to *Pseudomonas* species and is considered to have high pathogenicity. This bacterial species may thus plays a specific role in development of AD.

### 2.3.2 Fungus in AD

In addition to bacteria, fungal species also contribute to the pathogenesis of AD. Although there is no convincing report that the *Malassezia* species in patients with AD differs from the *Malassezia* species of healthy humans, Sugita et al. (2004) reported that the genome sequence of the intergenic spacer (IGS) of *M. restricta*, one of the major members of the microbiota, differs between AD patients and healthy humans. Possessing a certain group of strains of *M. restricta* may be a worsening factor of AD.

Moreover, 10-20% of patients with AD have specific IgE against *Malassezia* species in the serum and show a positive result to the prick test of the fungus. Such AD patients tend to present a diffuse erythema on the face and neck (Darabi et al., 2008). This condition is often observed in adult humans and is improved by frequent washing, unlike most symptoms of AD.

### 2.3.3 Conclusion

A complete picture of the skin microbiota has not yet been attained. Therefore, its distinction in AD patients is also underinvestigated. However, biochemical and genomic techniques focused on specific molecules should lead to a total understanding in the near future.

## 3. Infections in atopic dermatitis

The skin of patients with AD often causes a variety of secondary infections. This may be due to dryness, impairment of natural immunity, scratching behaviour, and application of topical drugs. The dryness attracts pathogens because the rough surface yields a high point of scaling that easily captures environmental pathogens and deep crevices that make the pathogens accessible to deeper tissues. The presence of *S. aureus* in high numbers irritates the skin and results in aggravation of dryness. The decrease of antimicrobial peptides in the sweat exaggerates the possibility of the pathogen growing at the site. Extensive scratching by the patient enlarges the area of infection and also helps the pathogen to degrade the skin and invade it further. Topical drugs commonly used for treatment of AD, such as steroids and pimecrolimus/tacrolimus, suppress the immune function of the host and allows infectious microorganisms to grow at the site. In such cases, the diagnosis becomes difficult because it is not easy to ascertain that the lesion is caused by a secondary infection or by AD itself.

### 3.1 Colonisation and infection

Colonisation is a condition wherein parasitic organisms become attached to the skin and multiply without an apparent reaction of the host. Colonization is clinically invisible but may be detected in a culture test. When a microorganism colonises a host, there is a possibility that the microorganism will only harm the host incrementally. It may therefore become a hidden pathogen.

On the other hand, infection accompanies apparent host reaction in addition to colonisation. A host reaction is a kind of defence mechanism, and at the skin it is expressed as inflammation or oozing. Inflammation is a cytokine-mediated complex mechanism. Oozing is also a defensive reaction, because serum prevents microorganisms from multiplying. Therefore, when human skin is infected, a mixed reaction of inflammation and oozing occur. The clinical expression of this is redness, oozing, itching, and pain.

The colonisation may change to infection. This is due to a shift of the host defence mechanism (Table 2) and when it occurs, hidden pathogens increase in number and become infectious to do apparent harm; *Streptococcus* species is such an example in AD to develop impetigo. Therefore, doctors should be aware of this phenomenon and instruct patients to avoid activities that may cause such infections.

Possible triggers converting colonisation to infection	
-	Application of an anti-inflammatory ointment that is too strong for the site
-	Oral administration of steroids or immunodepressants
-	Scratching
-	Flare-up of AD due to other allergic disease or failure to perform appropriate skin care
-	Infrequent bathing

Table 2. Triggers to potentially causing a decline in the host defence mechanisms in the skin of AD patients

### 3.2 Impetigo

Impetigo is a bacterial infection caused by *S. aureus* or *Streptococcus* species. The former causes bullous impetigo and the latter causes non-bullous (or crusted) impetigo. This condition is typically seen in children but adult patients with AD are also affected and sometimes pre-sepsis occurs with high fever. In children without AD, the pathogen is considered to originate from the environment, but in patients with AD, it may also originate from their own colonising microbiota.

As these pathogens often reside on the skin of AD patients as members of the microbiota, they may not originate directly come from the outer environment, as they do for impetigo patients without AD. It is impossible to assess whether the pathogen originates from a patient's own microbiota or the environment, but it is meaningful to evaluate the patient's microbiota by using culture analysis after a successful treatment.

The clinical appearance of impetigo in AD patients includes sudden oozing, crust, and itching (Fig. 3). Culture tests using a scrubbed swab usually show the presence of pathogenic Gram-positive cocci. However, culture results require 2-3 days, so treatment should be administered before identification of the pathogen. Therefore, diagnosis by professional observation is needed. Otherwise, Gram stain may be used to visualise the pathogen at the point of consultation. Treatment should include a combination of oral and topical antibiotics. Usually treatment fails when only topical antibiotics are prescribed. Washing helps improvement of the healing process.



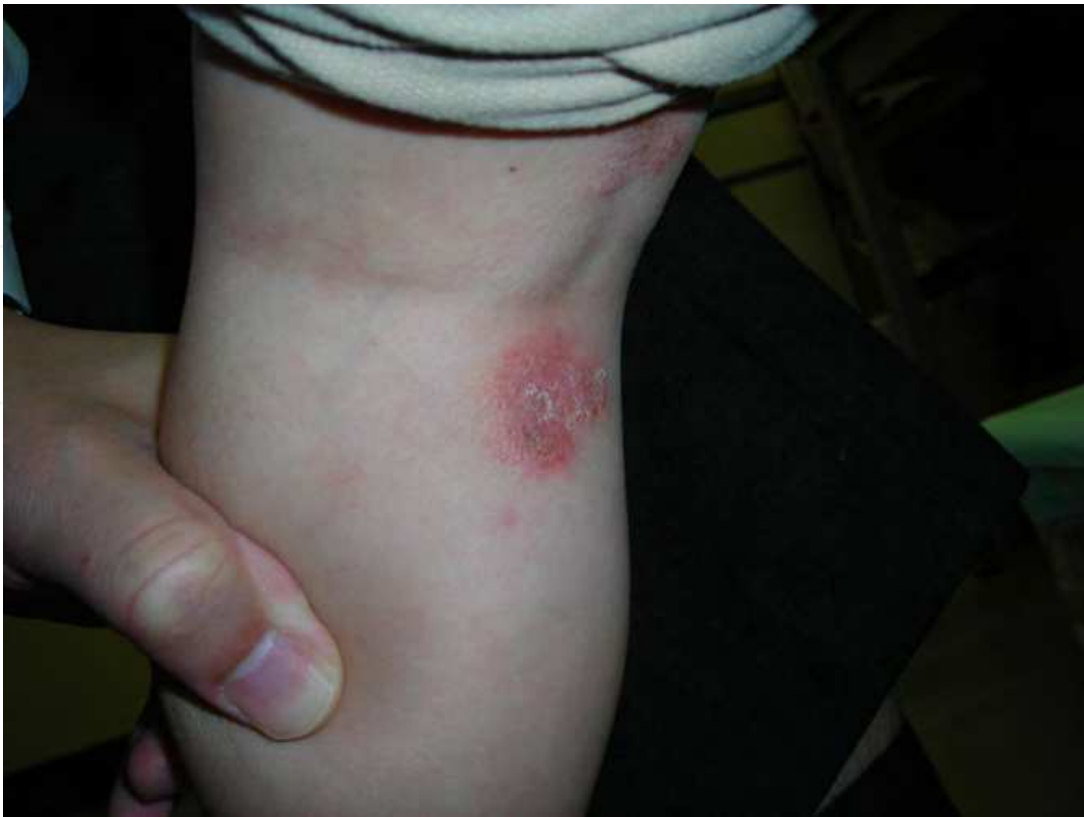

Fig. 3. Mild impetigo in a child with AD exhibiting erythema and crust.

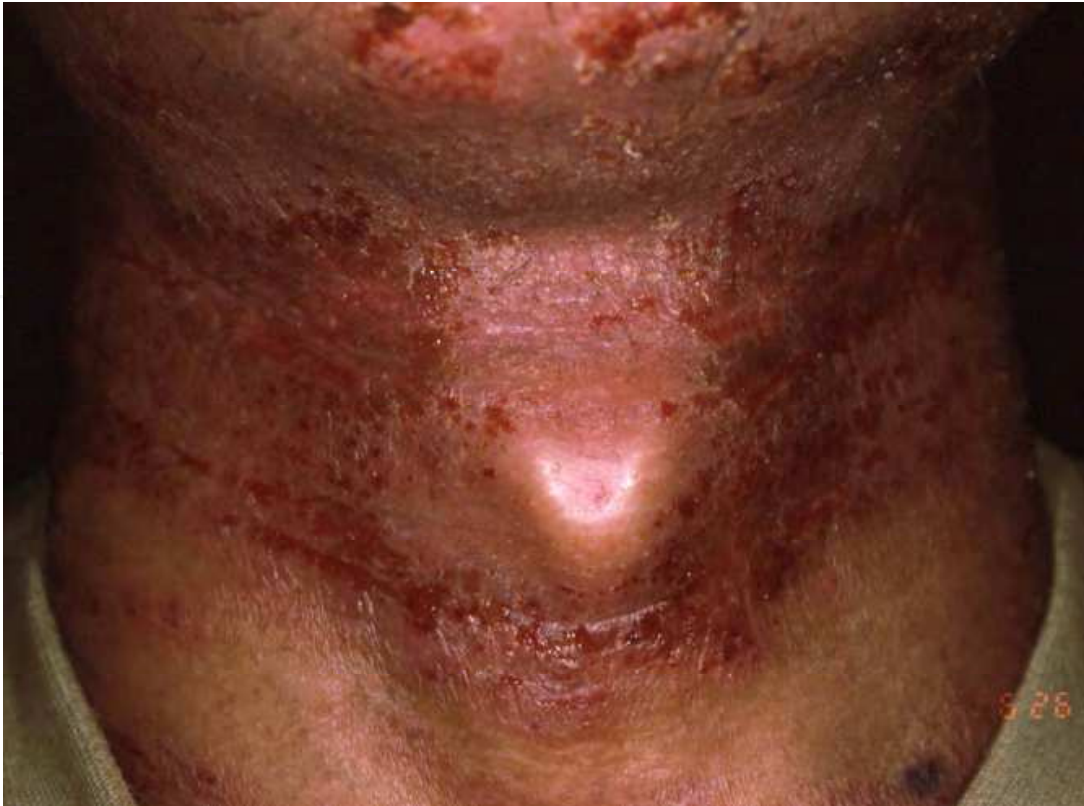

Fig. 4. Severe impetigo in an adult patient with AD. Erythema, oozing, and crust are visible.

The impetigo sites of AD patients are often very itchy and patients tend to scratch too much and exaggerate the infection. Scratching not only worsens the site but also inoculates the pathogen at other sites and other individuals. Doctors should advise the patient not to touch the site. Covering with a gauze or a sticking plaster helps to do this. The site should be kept dry beneath the covering.

In adult patients, it sometimes worsens at the neck (Fig. 4). This is because skin of the site is fragile and easy to scratch. A severe condition at this site causes difficulties in rotating the head because of the pain at the skin. This lowers activities of daily living of the patients.

### 3.3 Tinea corporis

Tinea corporis is a fungal infection caused by ringworm-forming fungi, such as *Trichophyton rubrum*. The pathogen is not contained in the microbiota and is thus considered to originate from patients with tinea pedis (athlete's foot) or from the outer environment.

The symptom is an erythema with a margin and slightly raised edge (Fig. 5). The erythema grows daily. In patients without AD, a strong itch is a hallmark, but patients with AD tend to suppress the itchy sensation with the use of ointments. This has the effect of masking this hallmark. Attention is needed to diagnose this infectious condition and careful examination with a microscope is required.

The filamentous fungus is easily seen in microscopic observation of the scales using the KOH technique (Fig. 6). Usually there is no need to perform a culture test, but it should be done if the patient is involved in close contact sports such as wrestling. This is because *Trichophyton tonsurans*, one of the pathogens transmitted by close contact, is difficult to observe using KOH technique. In most cases, the recommended treatment is a topical antifungal drug combined with discontinuance of topical application of drugs for AD. Oral antifungals should be administered in severe cases.

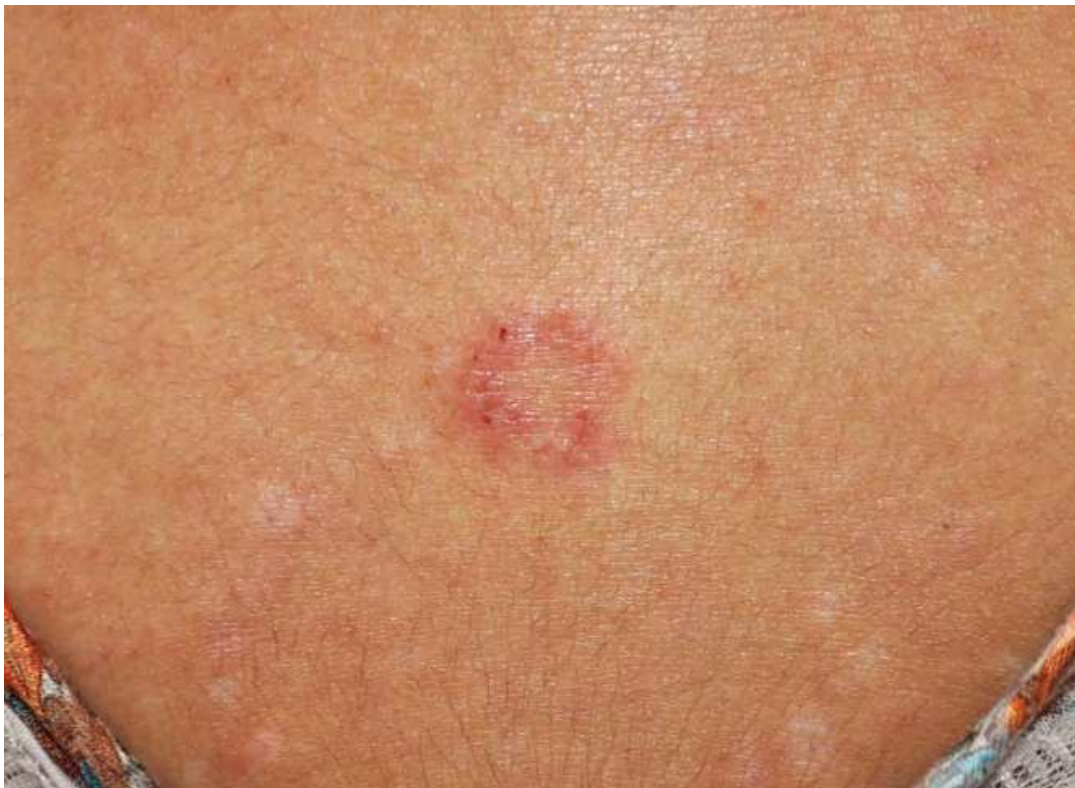

Fig. 5. Ring-like erythema on the back of a patient with AD.

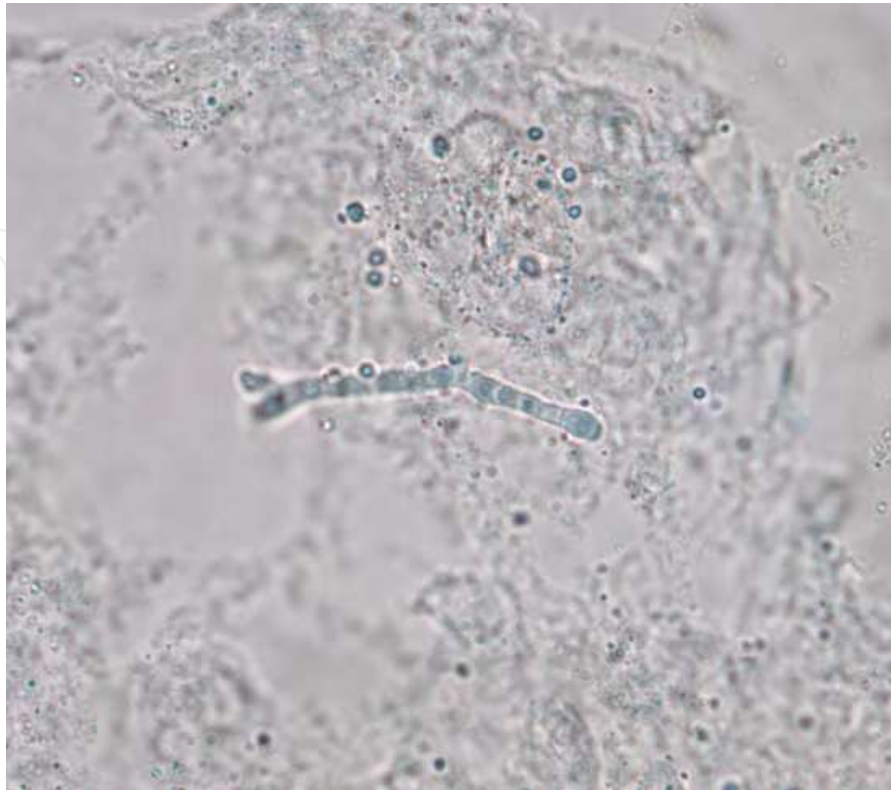

Fig. 6. Observation of a scale of the patient by KOH technique.

### 3.4 Kaposi's varicelliform eruption

Kaposi's varicelliform eruption (KVE) is an infection caused by herpes simplex virus (HSV). It rarely occurs in individuals without AD, but occurs often in patients with severe AD. HSV is also a pathogen of herpes simplex, a common latent infection of skin, and has life-long persistence in the ganglia of the sensory nerve. Regarding the aetiology of KVE, both persistent HSV in the ganglia and environmental HSV can be the possible cause of the disease. If the patient has a history of developing herpes simplex near the KVE site, it is natural to consider that the pathogen originated from the ganglia via sensory nerve, but otherwise it is impossible to determine the origin of the virus.

Once HSV begins to multiply on the surface of the skin, a varicella-like pustule with an erythematous surrounding appears. The number of the pustules increases and they become crusted. The formation of a crust usually reflects a secondary bacterial infection. Within a couple of days, the area of the lesion exceeds the size of a hand and a high fever develops (Fig. 7). Treatment must include a systemic antiviral drug for HSV (such as aciclovir or valaciclovir) and an antibacterial drug to treat the secondary bacterial infection with Gram-positive cocci.

In some rare cases, KVE recurs and it becomes difficult to manage. In such cases, preventive antivirals are efficient. Administration of topical acyclovir once in two days, in addition to the usual topical treatment of AD, is effective in many cases. In cases where this treatment is not effective, oral valaciclovir at a low dosage is reported to be effective (Dekio et al., 2011).

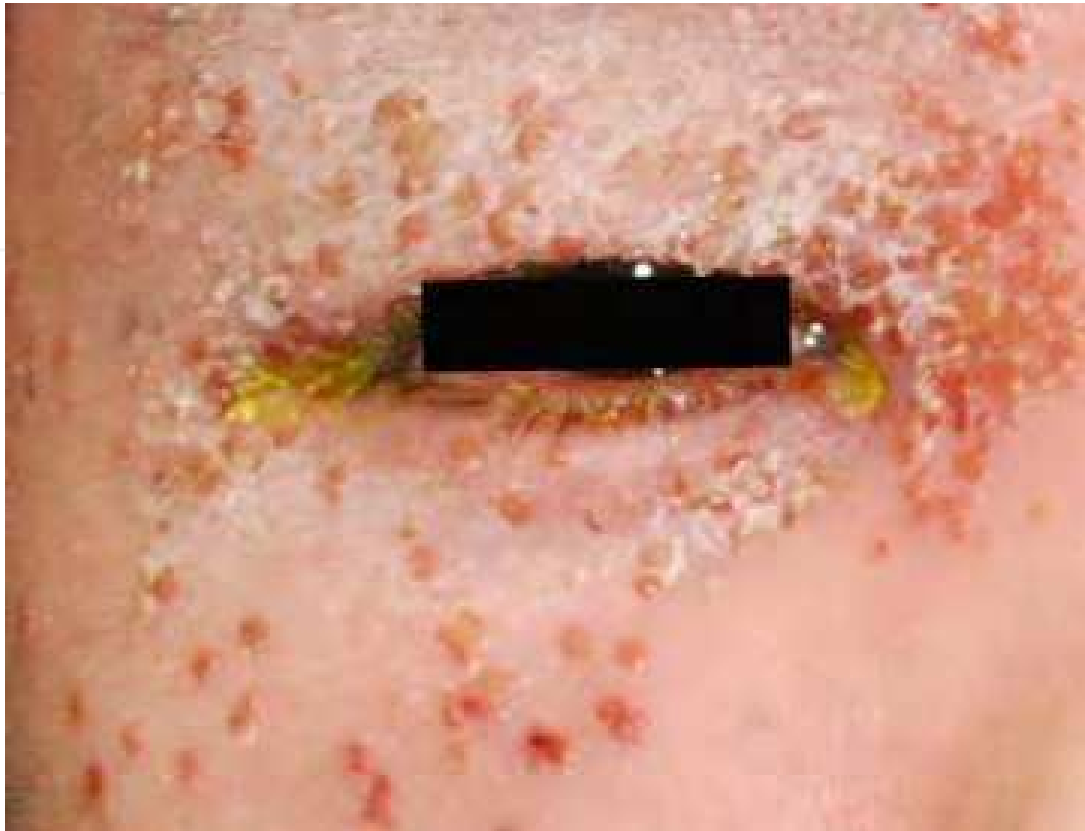

Fig. 7. Kaposi's varicelliform eruption. Crusted lesions around an eye of a patients with AD.

### 3.5 Molluscum contagiosum

Molluscum contagiosum is an infection caused by molluscum contagiosum virus (MCV). The condition is frequent in healthy children and also in patients (children and adults) with AD. The pathogen is not a member of the microbiota in AD skin so its presence reflects a simple infection from other patients or the environment. Because the clinical picture is far more severe in patients with AD and management strategy is different, it warrants a discussion in this chapter.

The skin lesions are whitish papules with diameters of 1 mm to 4 mm (Fig. 8). Scratching causes breakage of the surface of the papule and releases the viral ingredients. This leads to spreading of the lesions (Koebner phenomenon). In patients without AD, itch is not severe and often insensible, but patients with AD usually feel itch within the area of scattered lesion and scratching behaviour worsens the disease (Fig. 9).

In healthy children, the lesions disappear within months, but in patients with AD, the lesions may persist for years. The reason for this may be impairment of skin barrier and the use of topical anti-inflammatory drugs for the treatment. Molluscum contagiosum is not harmful to humans, but to prevent transmission to others, extirpation using tweezers is highly recommended.

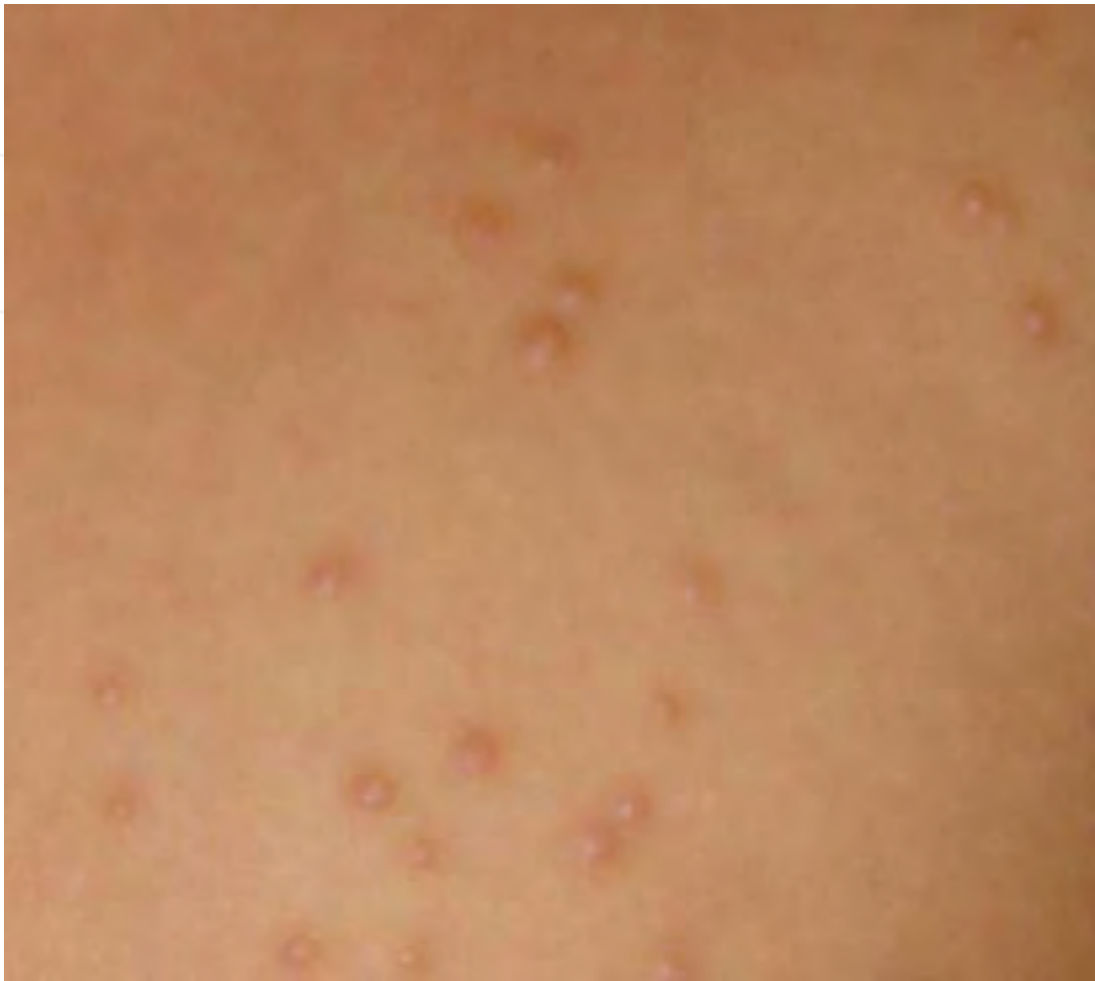

Fig. 8. Molluscum contagiosum on the chest of a patient with AD.

### 3.6 Verruca vulgaris (viral wart)

Verruca vulgaris is an infection caused by human papilloma virus (HPV). There are more than 70 types of HPV which are identified by type numbers, and types that infect the human skin are different from those that infect the mucous of the oropharynx and genitalia. Therefore, doctors should inform the patients that the disease is not sexually transmitted. The pathogen is not included in the microbiota of AD skin, so it is a simple infection from other patients or the environment. The condition is frequent in healthy children and also in patients (children and adults) with AD. The clinical picture is different in patients with AD and the management strategy is also different, so it is discussed in this chapter.

The lesions are slightly elevated papules with obvious margins. Sometimes the lesions grow like cauliflower with a rough surface. The colour is more yellowish-white than the uninfected skin (Fig. 10). HPV promotes the growth of capillaries for their survival. Therefore, small black dots are often seen within a lesion. HPV is observed in piles within the lesion by electron microscopy.

When the skin of the face and the neck is affected in AD patients, the lesions often become itchy, and scratching releases HPV into the nearby skin. It results in an assembled manner of the lesions (Koebner phenomenon). The itching of the lesions is often ignored because the lesions are not itchy in patients without AD. Patients often apply topical anti-inflammatory drug to the lesion but it should be avoided because it promotes the proliferation of HPV. Therefore, the treatment for such HPV is often complex and difficult.

The first step of treatment should include cryotherapy using liquid nitrogen. When the lesion successfully drops off as a consequence, it is appropriate to apply topical anti-inflammatory ointment immediately.

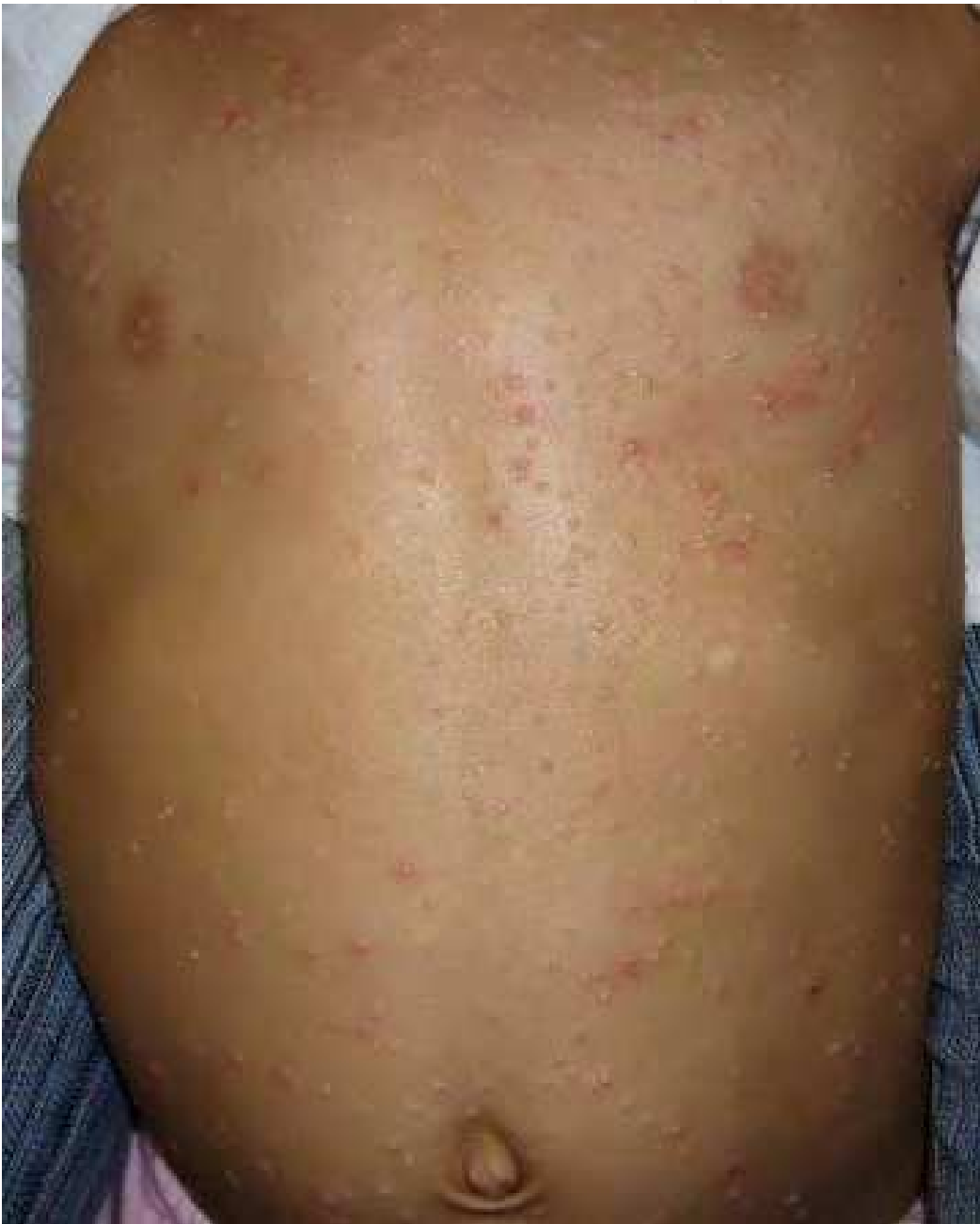

Fig. 9. Severe molluscum contagiosum in an infant with AD.

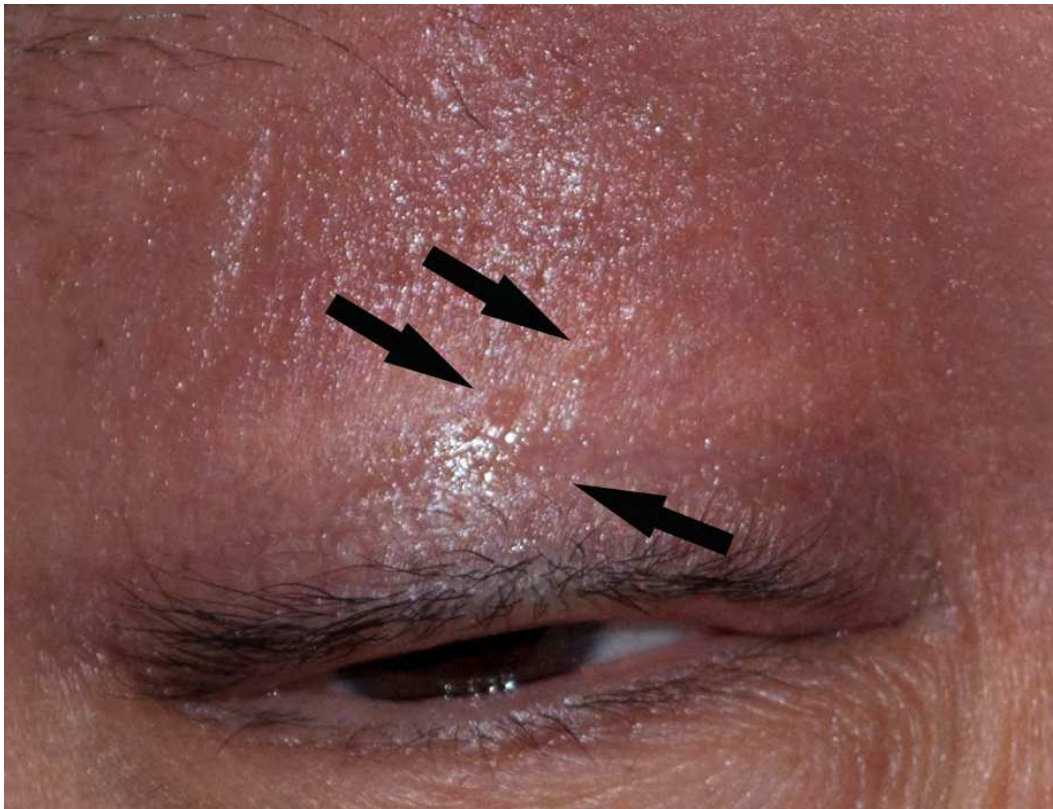


Fig. 10. Multiple verruca vulgaris on the eyelid of an adult patient with AD.

#### 4. Conclusion

As microorganisms have close and complex relationships with human skin, doctors and scientists should be aware of the presence of good and harmful species in the skin. Human skin has mechanisms to allow microbes to reside on the skin, and good microbes may help humans.

On the other hand, certain microbes may trigger AD under certain conditions and others are consistent pathogens. When considering microorganisms as exacerbating factors, research should be performed in order to clarify their roles. Such research may lead to advances in the treatment and prevention of AD.

In treatment of various infectious conditions in AD patients, careful and well-considered strategy by dermatologists is necessary.

#### 5. Acknowledgment

I thank Prof. Haroun N. Shah, London for the insightful comments on this manuscript.

This work is partly supported by Grant-in-Aid 22791073 from the Ministry of Education, Culture, Sports, Science and Technology (MEXT) of Japan.

#### 6. References

Bek-Thomsen, M., Lomholt, H.B., & Kilian, M. (2008). Acne is not associated with yet-uncultured bacteria. *Journal of Clinical Microbiology* Vol. 46, No. 10, pp. 3355-3360

- Brüggemann, H., Henne, A., Hoster, F., Liesegang, H., Wiezer, A., Strittmatter, A., Hujer, S., Dürre, P., & Gottschalk, G. (2004). The complete genome sequence of *Propionibacterium acnes*, a commensal of human skin. *Science* Vol. 305, pp. 671-673
- Burns, T., Breathnach, S., Cox, N., & Griffiths, C. (Eds.) (2010). *Rook's Textbook of Dermatology 8th ed.* Wiley-Blackwell, ISBN: 9781405161695
- Cogen, A.L., Yamasaki, K., Sanchez, K.M., Dorschner, R.A., Lai, Y., MacLeod, D.T., Torpey, J.W., Otto, M., Nizet, V., Kim, J.E., Gallo, R.L. (2010). Selective antimicrobial action is provided by phenol-soluble modulins derived from *Staphylococcus epidermidis*, a normal resident of the skin. *Journal of Investigative Dermatology* Vol. 130, No. 1, pp. 192-200
- Costello, E.K., Lauber, C.L., Hamady, M., Fierer, N., Gordon, J.I., Knight, R. (2009). Bacterial community variation in human body habitats across space and time. *Science* Vol. 326, No. 5960, pp. 1694-1697
- Darabi, K., Hostetler, S. G., Bechtel, M.A., & Zirwas, M. (2009). The role of *Malassezia* in atopic dermatitis affecting the head and neck of adults. *Journal of American Academy of Dermatology* Vol. 60, No. 1, pp. 125-136
- Dekio, I., Hayashi, H., Sakamoto, M., Kitahara, M., Nishikawa, T., Suematsu, M., & Benno, Y. (2005). Detection of potentially novel bacterial components of the human skin microbiota using culture-independent molecular profiling. *Journal of Medical Microbiology* Vol. 54, No.12, pp. 1231-1238
- Dekio, I., Sakamoto, M., Hayashi, H., Amagai, M., Suematsu, M., & Benno, Y. (2007). Characterization of skin microbiota in patients with atopic dermatitis and normal subjects using 16S rRNA gene-based comprehensive analysis. *Journal of Medical Microbiology* Vol.56, No.12, pp. 1675-1683
- Dekio, I., Chinuki, Y., Furumura, M., & Morita, E. (2011). Recurrent Kaposi's varicelliform eruption successfully controlled by low-dose oral valaciclovir. *The Journal of Dermatology* Epub Apr 2011, DOI: 10.1111/j.1346-8138.2011.01245.x
- Gloor, M., Peters, G., & Stoika, D. (1982). On the resident aerobic bacterial skin flora in unaffected skin of patients with atopic dermatitis and in healthy controls. *Dermatologica* Vol. 164, No. 4, pp. 258-265
- Farrar, M.D., Howson, K.M., Bojar, R.A., West, D., Towler, J.C., Parry, J., Pelton, K., & Holland, K.T. (2007). Genome Sequence and Analysis of a *Propionibacterium acnes* Bacteriophage. *The Journal of Bacteriology* Vol. 189, No. 11, pp. 4161-4167
- Grice, E.A., Kong, H.H., Conlan, S., Deming, C.B., Davis, J., Young, A.C., NISC Comparative Sequencing Program, Bouffard, G.G., Blakesley, R.W., Murray, P.R., Green, E.D., Turner, M.L., Segre, J.A. Topographical and temporal diversity of the human skin microbiome. (2009). *Science* Vol. 324, No. 5931, pp. 1190-1192
- Palmer, C.N., Irvine, A.D., Terron-Kwiatkowski, A., et al. (2006). Common loss-of-function variants of the epidermal barrier protein filaggrin are a major predisposing factor for atopic dermatitis. *Nature Genetics* Vol. 38, No. 4, pp. 441-446
- Sasaki, T., Kudoh, J., Ebihara, T., Shiohama, A., Asakawa, S., Shimizu, A., Takayanagi, A., Dekio, I., Sadahira, C., Amagai, M., Shimizu, N. (2008). Sequence analysis of




filaggrin gene by novel shotgun method in Japanese atopic dermatitis. *Journal of Dermatological Science* Vol. 51, No. 2, pp. 113-120

Sugita, T., Tajima, M., Amaya, M., Tsuboi, R., & Nishikawa, A. (2004). Genotype analysis of *Malassezia restricta* as the major cutaneous flora in patients with atopic dermatitis and healthy subjects. *Microbiology and Immunology* Vol. 48, No. 10, pp.755-759

IntechOpen

IntechOpen



## **Atopic Dermatitis - Disease Etiology and Clinical Management**

Edited by Dr. Jorge Esparza-Gordillo

ISBN 978-953-51-0110-9

Hard cover, 414 pages

**Publisher** InTech

**Published online** 22, February, 2012

**Published in print edition** February, 2012

Atopic Dermatitis is a common disease characterized by inflamed, itching and dry skin. This relapsing allergic disorder has complex etiology and shows a remarkably high clinical heterogeneity which complicates the diagnosis and clinical management. This book is divided into 4 sections. The first section (Disease Etiology) describes some of the physiological mechanisms underlying Atopic Dermatitis, including alterations in the immune system and the skin-barrier function. The important role of host-microorganism interactions on the pathophysiology of Atopic Dermatitis is discussed in the second section (Microorganisms in Atopic Dermatitis). An overview of the clinical diagnostic criteria and the disease management protocols commonly used is given in the third section (Diagnosis and Clinical Management). The last section (New Treatments) describes new therapeutic approaches that are not widely used but are currently being studied due to preliminary evidence showing a clinical benefit for Atopic Dermatitis.

### **How to reference**

In order to correctly reference this scholarly work, feel free to copy and paste the following:

Itaru Dekio (2012). Microorganisms and Atopic Dermatitis, Atopic Dermatitis - Disease Etiology and Clinical Management, Dr. Jorge Esparza-Gordillo (Ed.), ISBN: 978-953-51-0110-9, InTech, Available from: <http://www.intechopen.com/books/atopic-dermatitis-disease-etiology-and-clinical-management/microorganisms-and-atopic-dermatitis>

**INTECH**  
open science | open minds

### **InTech Europe**

University Campus STeP Ri  
Slavka Krautzeka 83/A  
51000 Rijeka, Croatia  
Phone: +385 (51) 770 447  
Fax: +385 (51) 686 166  
[www.intechopen.com](http://www.intechopen.com)

### **InTech China**

Unit 405, Office Block, Hotel Equatorial Shanghai  
No.65, Yan An Road (West), Shanghai, 200040, China  
中国上海市延安西路65号上海国际贵都大饭店办公楼405单元  
Phone: +86-21-62489820  
Fax: +86-21-62489821

© 2012 The Author(s). Licensee IntechOpen. This is an open access article distributed under the terms of the [Creative Commons Attribution 3.0 License](#), which permits unrestricted use, distribution, and reproduction in any medium, provided the original work is properly cited.

IntechOpen

IntechOpen