

We are IntechOpen, the world's leading publisher of Open Access books Built by scientists, for scientists

5,300

Open access books available

131,000

International authors and editors

160M

Downloads

Our authors are among the

154

Countries delivered to

TOP 1%

most cited scientists

12.2%

Contributors from top 500 universities



WEB OF SCIENCE™

Selection of our books indexed in the Book Citation Index
in Web of Science™ Core Collection (BKCI)

Interested in publishing with us?
Contact book.department@intechopen.com

Numbers displayed above are based on latest data collected.
For more information visit www.intechopen.com



Biliary Complications After Liver Transplantation

Julius Špičák and Renáta Bartáková
*Institute for Clinical and Experimental Medicine in Prague
Czech Republic*

1. Introduction

Despite logistical and immunological advantages, various refinements in organ procurement, surgical techniques, and postoperative management, biliary complications remain a significant cause of morbidity and even mortality after orthotopic liver transplantation (OLT). They may appear in the immediate post-liver transplant period as well as years thereafter. With respect to the generally increased patients' vulnerability after OLT, it is necessary to manage these complications promptly and effectively to prevent irreversible liver damage and threat to the recipient's life. Biliary complications cannot be considered as a single issue, even if significant. They often develop as a consequence of the underlying problems typically associated with liver transplantation in patients with immunosuppression modulating their clinical manifestations and laboratory findings. Not exceptionally, they may occur together with other complications such as primary disease recurrence, rejection, vascular lesions or cytomegalovirus (CMV) infection, and these problems may modify the management accordingly. They may also mask biliary complications contributing hugely to their varying rates reported in particular studies. To assess the individual patient comprehensively and to correctly organize the management of such a complicated case is a masterpiece of medical skill.

2. Biliary reconstruction of liver transplantation

To achieve high technical success of endoscopic treatment of biliary complications, meticulous knowledge of the anatomy of biliary reconstruction as well as knowledge of specific issues of posttransplant pathophysiology is essential. Surgical reconstruction of the biliary tree is undertaken as the final step of OLT after vascular anastomosis determining both the diagnostic and therapeutic approaches. The gallbladder interposition technique was used in the pioneering years utilizing the gallbladder as the graft conduit between the donor and recipient bile ducts. In the early reports by Starzl and Calne, the association of bile stasis with stone formation and cholangitis resulted in morbidity of up to 50% and mortality up to 30% quite fittingly referred to as the Achilles' heel of this demanding surgical technique (Lebeau et. al, 1990).

Clearly, an end-to-end duct-to-duct anastomosis is the preferred technique in most centres in recipients with healthy native bile ducts of compatible calibre as it maintains the anatomy and preserves the sphincter mechanism. Another advantage is that it provides continuity of

bile ducts with the original shape allowing access and effective treatment of complications by standard endoscopic techniques. Similarly good results were obtained by other centres using a side-to-side variant. More of historical interest, the reconstruction was complemented by temporary T-tube biliary drainage with two presumed goals: to visualise the bile ducts according to demand, and to prevent anastomotic stricture formation. The results of several comparative studies differ but the second expectation has never been reliably met, and frequent leaks prevailing in T-tube groups (Davidson et al., 1999; Graziadei et al., 2006) caused that the use of the preventive T-tube drainage has been rarely employed in choledocho-choledocho reconstruction.

Roux-en-Y hepaticojejunostomy is utilized in patients with bile ducts involved by the pre-existing disease like sclerosing cholangitis, occasionally also in patients with major incompatibility in size of ducts, and is usually preferred in the case of retransplantation because of inadequate recipient duct length. Roux-en-Y was also the routine reconstruction technique in the first series of living-related, reduced graft, and split liver transplantation procedures. With increasing knowledge of the blood supply around the biliary ducts and increasing experience, duct-to-duct anastomosis has been increasingly reported in reduced grafts of living-donor transplants and split transplant even if multiple anastomoses are needed.

References	Center	Year	N	Total, %	Leaks, %	Strictures, %
Duct - to - duct anastomosis						
Lebeau	Pittsburgh	1990	193	20	2	18
O'Connor	Boston	1995	147	33	22	12
Davidson	Royal Free	1999	100	31	17	14
Alazmi	Indianapolis	2006	916	NA	NA	16
Graziadei	Innsbruck	2006	515	16	NA	16
Roux - en Y hepaticojejunostomy						
Ringer	Hannover	1989	84	24	12	2
Lebeau	Pittsburgh	1990	187	12	9	3
Living donor liver transplantation						
Tsujino	Tokyo	2006	174	30	NA	NA
Giacomoni	Milano	2006	23	48	22	26
Wojcicki	Birmingham	2006	70	26	20	4
Cardiac death donors						
Suárez	A Coruña	2008	22	42	4	38
De Vera	Pittsburgh	2008	141	25	NA	NA
Kobayshi	Niigata	2009	63	46	29	32

Table 1. Biliary complications in various surgical anastomosis techniques

3. Manifestation and diagnosis

Manifestations of biliary complications comprise usual symptoms but often with different presentation as compared to non-transplant conditions. They involve fever, right upper quadrant pain, non-specific abdominal discomfort, and elevation of hepatic, particularly cholestatic enzymes. On the one hand, these manifestations may rapidly progress to the development of biliary peritonitis in large leaks but, more typically, they remain mild and indistinguishable from other causes of cholestasis such as hepatitis C virus (HCV) recurrence and acute rejection to mention at least two other common complications. The diagnosis comes after precise analysis of symptoms, laboratory examinations, liver biopsy and use of imaging methods. Usually, there is absence of intrahepatic bile ducts dilatation on ultrasound, particularly early after liver transplantation, even above a tight obstruction. The final step of diagnostic work-up is direct imaging by endoscopic retrograde cholangiopancreatography (ERCP) or percutaneous transhepatic cholangiography (PTC), which should be preceded by magnetic resonance cholangio-pancreatography (MRCP; Fig. 1). Nevertheless, even MRCP has its logistic limitations and the picture of ducts fully corresponds to the picture on ERCP in about 70% of cases (Wojcicki et al., 2008).

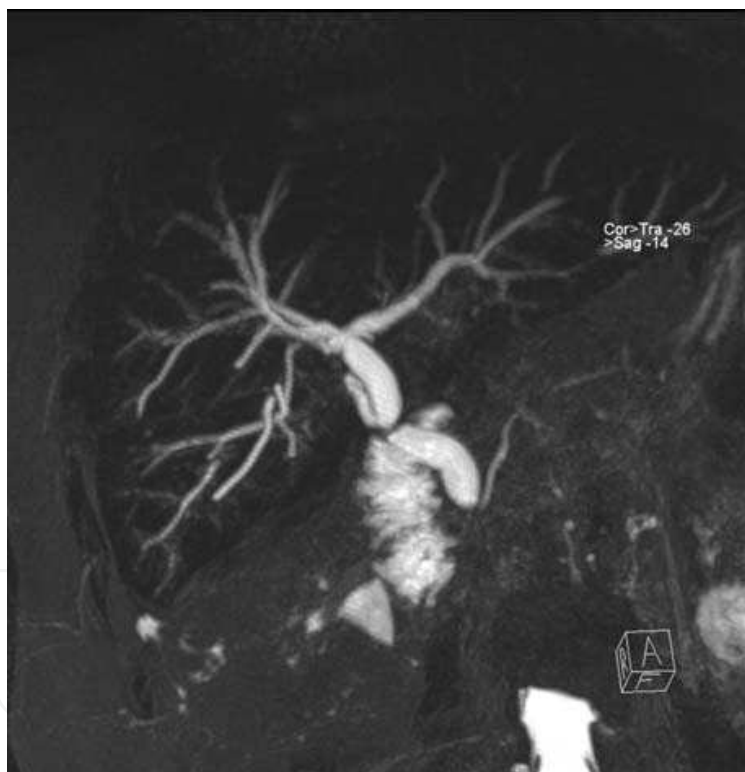

Fig. 1. Bile ducts with anastomotic stricture on MRCP

4. Classification and aetiology of biliary complications

Biliary complications comprise a wide and varied list of events with different frequency involving both direct ductal and extraluminal causes. In fact, the scope of complications corresponds to biliary problems appearing in non-transplant conditions. The difference is in the proportions and several specific aspects. The comprehensive pathogenesis of biliary complications is attributable to various factors including the rationale for selecting a

particular surgical technique, ischemic damage mostly due to hepatic artery thrombosis and ischemia-reperfusion injury, immunological principles such as ABO incompatibility, CMV infection, disease recurrence in primary sclerosing cholangitis, and others. The consequent cholestasis contributes to the generally increased vulnerability after liver transplantation strongly affecting namely the outcome in patients with recurrent hepatitis C (HCV) (Katz et al., 2006; Sanni et al., 2006). Technical reasons for biliary complications comprise imperfect suture with early T-tube-related leak or anastomotic stricture, leaks from the liver surface or inadvertent bile duct injuries.

Intrinsic biliary complications		Extrinsic biliary complications	
Strictures	Intrahepatic	PSC recurrence	False aneurysma
		Secondary cholangitis	Cystic duct mucocele
	Peri-hilar	Ischemic	Lymphoproliferative disease
		Idiopathic (ischemic-like)	Chronic pancreatitis
	Anastomotic		Recurrent/de novo cancer
Distal	Papillary dysfunction		
Leaks	Anastomotic duct-to-duct		
	Anastomotic HJA		
	T-tube location		
	Cut surface		
	Missed segmental duct		
Stones, cast, T-tube remnant			
Haemobilia			
Recurrent sclerosing cholangitis			

Table 2. Intrinsic and extrinsic biliary complications

5. Specific measurements before the scope is inserted

5.1 Infection prevention

After ERCP, infection remains to be a major complication occurring in about 1% of procedures overall. Several reasons may play a role. Similar to other invasive procedures, ERCP, even though rarely, may cause endocarditis in high-risk patients. Proper use of disposable accessories and utilization of standard technique can completely eliminate transmission of infection by the contaminated scope. Thanks to universally adopted measures, cases of endocarditis and nosocomial infection including hepatitis C, hepatitis B, and HIV related to endoscopy have been reported rarely in recent series. The American Heart Association recently revised their guidelines for prophylaxis of infective endocarditis, and a crucial change for endoscopic procedures is that antibiotic prophylaxis solely to prevent infective endocarditis is not recommended. Exceptions include high-risk cardiac conditions including: a prosthetic cardiac valve, a history of previous infective endocarditis, cardiac transplant recipients developing valvulopathy, patients with congenital heart disease with either uncorrected cyanosis or those with prosthetic material repair within 6

months after the procedure, or those with a residual defect. Since the enterococci making up part of the common bile duct flora in cholangitis are the invading agents in endocarditis, either amoxicillin or ampicillin should be included to the antibiotic protocol for enterococcal coverage.

The most common pathogenesis for cholangitis after ERCP is flare-up of infection already present in the bile ducts. The usual pathogens encountered in bile ducts involve *Pseudomonas aeruginosa*, *Klebsiella* spp., *E. coli*, *Bacteroides* spp., and Enterococci. The infection is precipitated by an elevated intraductal pressure when complete bile drainage has not been achieved. To eliminate these factors, it is highly recommended to aspirate bile before contrast injection and to complete endoscopic treatment (stones removal, drainage of all relevant visualised strictures). The basic principle is not to overfill the duct above the stricture, and particularly in complicated anatomy, but to fill only what can be drained. The risk factors to be considered include jaundice, previous endoscopic treatment, previous cholangitis, combined endoscopic-percutaneous procedures, transplant patients on an immunosuppressive regimen, hilar tumours, and primary sclerosing cholangitis, because the bile duct obstruction is difficult to be completely relieved. The technique of ERCP should correspond to the technique in non-transplant conditions. The role of antibiotic prophylaxis is controversial and a variety of practices exist. Several randomized controlled trials (RCTs) have been published showing reduction of bacteraemia with an inevitably limited value due to the small numbers of patients with clinical infection. No RCT has to date been conducted exclusively in transplant patients. Taken together, the general attitude to antibiotic prophylaxis is becoming more and more selective with its application only in conditions with suspected high risk. Transplant patients are exactly the case of the highest-risk group. ERCP should be attempted only in transplant patients with highly suspected biliary obstruction. If not clear from the clinical picture and other examinations, MRCP is a must. On the other hand, the finding of infection cannot be relied on absolutely. We recommend 400 mg of ciprofloxacin to be given intravenously (per oral administration is probably similarly effective) 2 hours before the procedure and to continue with the administration until complete drainage is achieved. Other options include gentamicin, quinolone, cephalosporin, and ureidopenicillin (ASGE guideline 2008; Cotton et al., 2008). In fact, most of these patients are already on an antibiotic regimen due to clinical/laboratory manifestations of infection of various organs.

5.2 Coagulopathy – bleeding disorders

After transplantation, abnormal coagulation due to liver dysfunction or anticoagulation therapy is a common concern. Other risk factors of invasive procedures include thrombocytopenia (included a haemodialysis-caused coagulation disorder) and initiation of anticoagulation therapy within three days of the invasive procedure; on the other hand, extension of previous sphincterotomy and the use of aspirin or non-steroidal anti-inflammatory drugs do not seem to raise the risk. No data dealing specifically with sphincterotomy in patients with liver disorders are available and the commonly shared opinion is that coagulopathy should be managed according to rules applied to liver biopsy. Generally, there are widely divergent opinions about the values at which abnormal coagulation indexes begin to pose a major risk for any kind of invasive procedures including endoscopic sphincterotomy. The utility of usual tests: platelet count, prothrombin time (PT)/international normalized ration (INR) in predicting bleeding risk is uncertain and

generally not supported by scientific evidence. Probably more important than any laboratory parameters is to take careful medical history whether any bleeding episode after an invasive procedure has appeared in the past, and to search for any possible signs of recent bleeding. Whether the use of prophylactic blood products alters the risk of bleeding is currently unknown. However, it is commonly assumed that platelet transfusion should be considered when thrombocytes count is less than 50,000-60,000/mL and, if prothrombin time is prolonged by 4-6 seconds, then transfusion of fresh frozen plasma may bring the presumed consequent increased bleeding risk into the desired range (Rockey et al., 2009). Appropriate practice of endoscopic procedures in patients on anticoagulation or antiplatelet therapy is precisely determined in the guidelines of endoscopic societies and the conditions of post-transplant care are not specific in any way. In short, sphincterotomy should not be performed by pure cutting current. Aspirin therapy can be maintained while clopidogrel should be withheld. Adoption of all these measures cannot completely eliminate the increased risk of haemorrhage in a complex bleeding disorder accompanying liver dysfunction in the post-transplant patient. The endoscopist should actively stop any bleeding appearing immediately after sphincterotomy by local endoscopic techniques.

5.3 Sedation and anaesthesia

Several specific features of this issue after transplantation should be addressed. During comprehensive pre-transplant evaluation and post-transplant follow-up, patients are often exposed to many endoscopic procedures which may possibly make them more anxious and less tolerant. Procedures early after transplantation or in patients in generally poor condition (ASA class IV-V-E) have to be performed with the assistance of an anaesthesiologist often under general anaesthesia. Therapeutic procedures are often prolonged due to the abnormal anatomy of reconstructed bile ducts. A considerable proportion of transplant procedures is performed in alcohol abusers. Chronic alcohol use increases dose requirements for general anaesthetic, sedative or analgesic agents. This is thought to be partly because of enzyme (particularly cytochrome P-450 2E1) induction or the development of cross tolerance. If the effective doses of propofol, opioids and other drugs are increased, the patient may – quite paradoxically – become agitated, uneasily controlled and less tolerant to any disturbing procedures. The increased anaesthetic demands may exacerbate the risk of cardiovascular instability in patients suffering from cardiomyopathy and increase the risk of adverse effects of all kinds. All these consequences make endoscopic procedures extraordinarily demanding. All the administered drugs have to be precisely titrated and the patient adequately monitored. The involvement of an anaesthesiologist in all procedures presumably associated with risk is highly recommended (Chapman & Plaat, 2009).

6. Biliary complications after liver transplantation – Specific issues and their management

Basically, treatment of biliary complications does not differ from that of the identical structural entities. Nevertheless, there are several specific features which have to be considered to avoid an unexpected surprise and to obtain optimal results. These specific techniques and tricks described below are based on our constantly expanding experience with more than 700 liver transplantations and management of approximately 200 biliary complications developing in a single department. This has given us the opportunity to follow the outcome from both immediate and long-term perspective and to discuss all

individual aspects with colleagues representing other specialties and involved in the transplant programme such as invasive radiologists, surgeons, and transplant hepatologists. In transplant medicine more than in non-transplant specialties, every patient is uniquely constituted and most of the conclusions and recommendations are based on observation rather than on comparative studies, which are enormously difficult to conduct.

6.1 Endoscopic sphincterotomy

The technique itself does not differ from sphincterotomy performed in other patients. Since the spontaneous motility of the bile duct is abolished due to the surgical reconstruction resulting in denervation of the biliary tree, evacuation of the contrast material cannot reliably serve as a measure of bile duct function. Even after standard-size sphincterotomy, which in a non-transplant condition be otherwise fully sufficient for what is aimed at – stent insertion or bile duct stone extraction – the cholestasis can persist. Therefore, we always recommend performing sphincterotomy to the maximal possible (safe) extent.

6.2 Anastomotic strictures

Anastomotic strictures being, together with leaks, the most common post-transplant biliary complication, are highly specific and almost unparalleled to non-transplant conditions. They are often asymmetrical with a shape that may be difficult to precisely project on x-ray due to overlap with one or two cysticus stumps. The shape of the prolonged reconstructed bile duct in the anastomotic area may resemble the letter S (Fig. 2, Fig. 3).

Given the irregular lumen of the anastomosis with cysticus stumps, it may be exceptionally uneasy to pass the guide wire through the stricture (Fig. 4). Often, several types of wire with

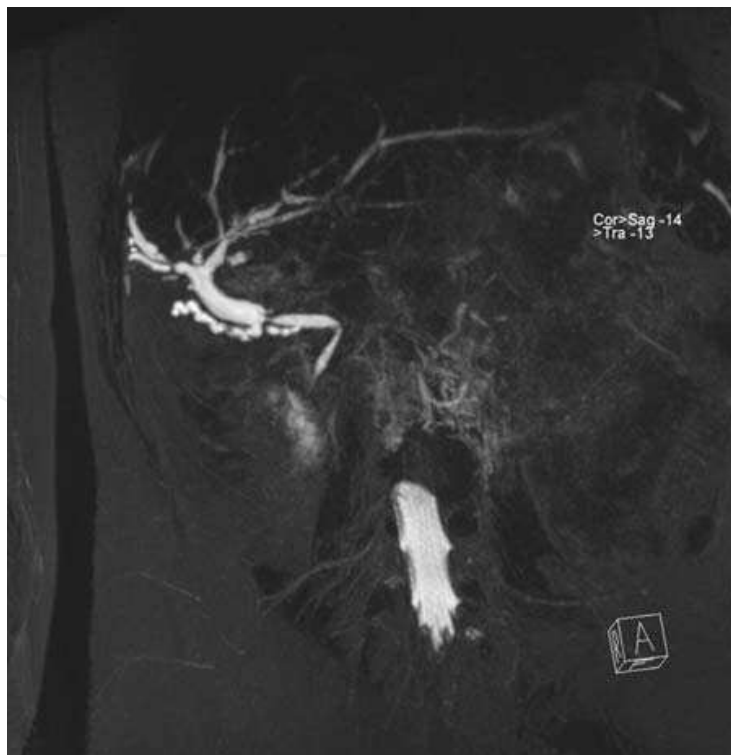

Fig. 2. S-shape of common bile duct after reconstruction on MRCP

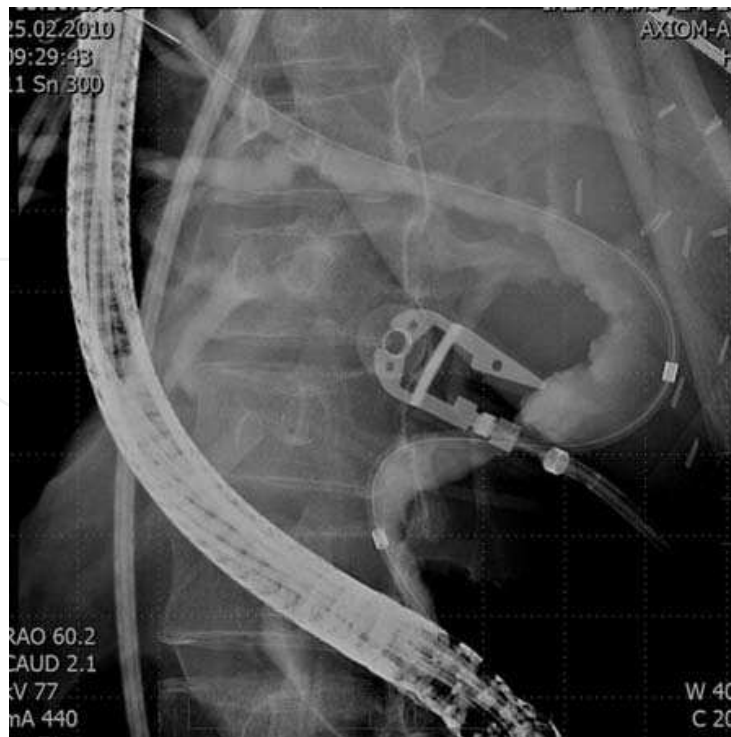


Fig. 3. S-shape of common bile duct after reconstruction on urgent ERCP

different properties in terms of diameter, flexibility/rigidity and slipperiness have to be tried. The direction of the wire tip can be enhanced by the use of an angled tip, sphincterotome or a balloon catheter.

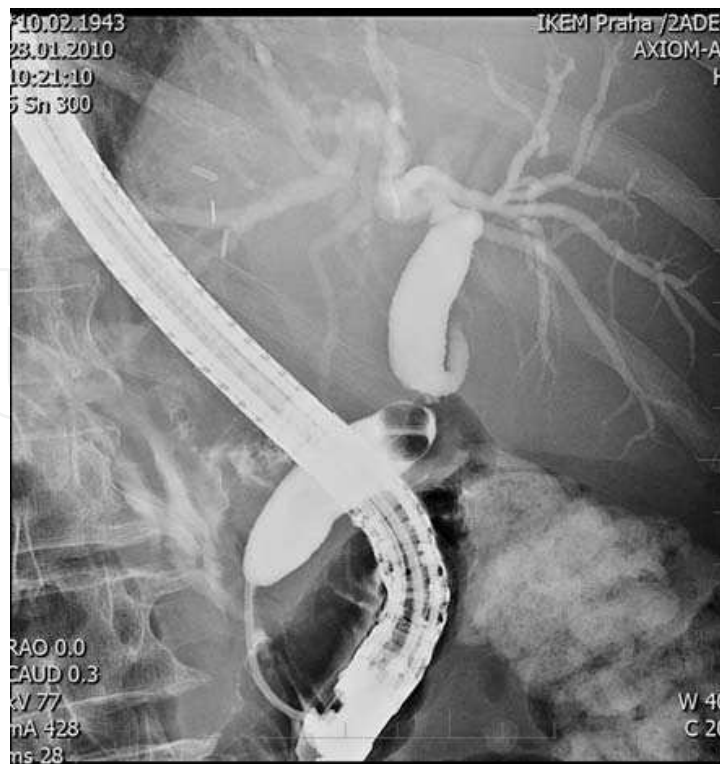


Fig. 4. Anastomotic stricture on ERCP with difficult access to common hepatic duct

Once the wire has been successfully inserted, a proper stent has to be selected. The stricture can be dilated by balloon before stenting, but we do not find it necessary if planning to insert a single stent. Both basic types of biliary stents, the Amsterdam with two flaps and the Tannenbaum with four flaps at their end are equally acceptable. The strategic principle is that a benign anastomotic stricture unlike a malignant stenosis needs not to be only bridged, but the lumen of the bile duct should to be completely reconstituted to correspond with normal anatomy. The chances for optimal remodelling of the anastomosis and the stricture seem to be higher if the diagnosis is established and treatment initiated early after transplantation and lower if a hard fibrotic stricture has already developed. If the reconstructed bile duct after liver transplantation is prolonged to form an S-shape, we select a longer stent than can be judged from the distance between the stricture and duodenum. The reason for this is that the stent passing through an S-shaped bile duct generates friction making the insertion more difficult. Should the stent be not long enough, the end may become impacted in the stricture orifice which makes it impossible to go through. On the other hand, when the curved stricture is overcome, the shape straightens and this may expel the proximal end of the stent far above the stricture, possibly above the hilar junction. This unfavourable position of the proximal end can hardly be prevented. We always place as many stents as possible according to the size of the bile ducts below and above the stricture (Fig. 5).

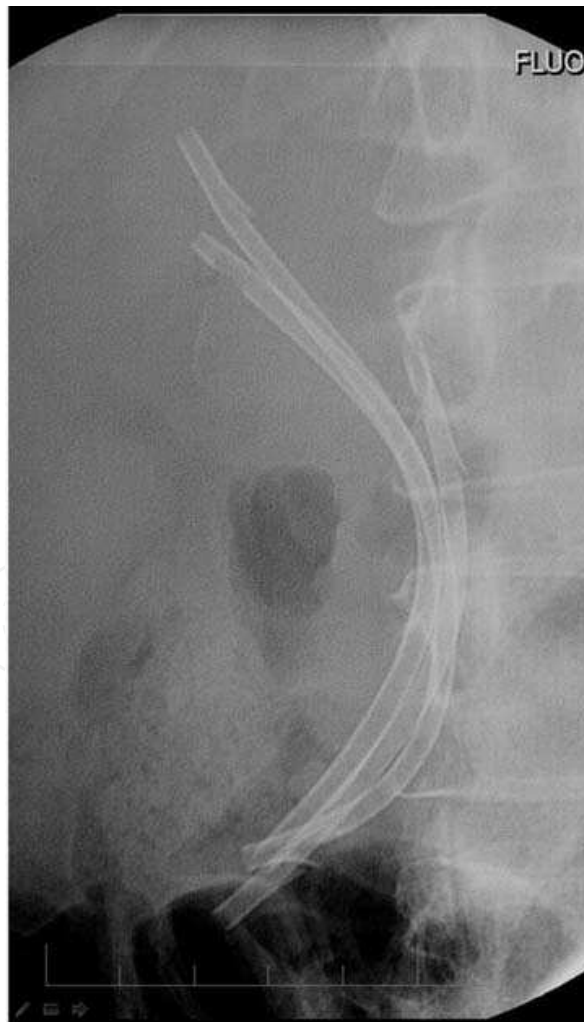


Fig. 5. Multiple biliary stents of various lengths

We use both basic techniques of multiple stents insertion: two wires prior to inserting either stent or to insert a wire along and after the first stent insertion. The optimal number and position of multiple stents are usually determined during several sessions at short one- or two-week intervals. If inserting one stent into an S-shaped bile duct with anastomotic stricture, it may adopt the curve of the bile duct, while multiple stents straighten the duct as the optimal outcome. If the first one or two inserted stents are located with their proximal end high above the stricture, we select a shorter third stent to drain the bile from various levels of the bile ducts to avoid cholestasis and debris accumulation above the stricture. A hard S-shaped bile duct may expand the stent back to the duodenum with the risk of duodenal perforation by the stent on the side opposite to the orifice. Therefore we always try to insert more stents in parallel making the expulsion less likely. We do exchange of stents at three-month intervals as recommended elsewhere, and the stents are removed usually after an interval of six months to one year. In cases where the endoscopic access has failed, the transhepatic approach follows (Fig. 6). The first plastic stent can be inserted either transhepatically or by a rendezvous transpapillary technique. The disadvantage of the single transhepatic technique is that it does not enable to insert multiple stents in one session (Holt et al., 2007; Pasha et al., 2007; Kulaksiz et al., 2008).

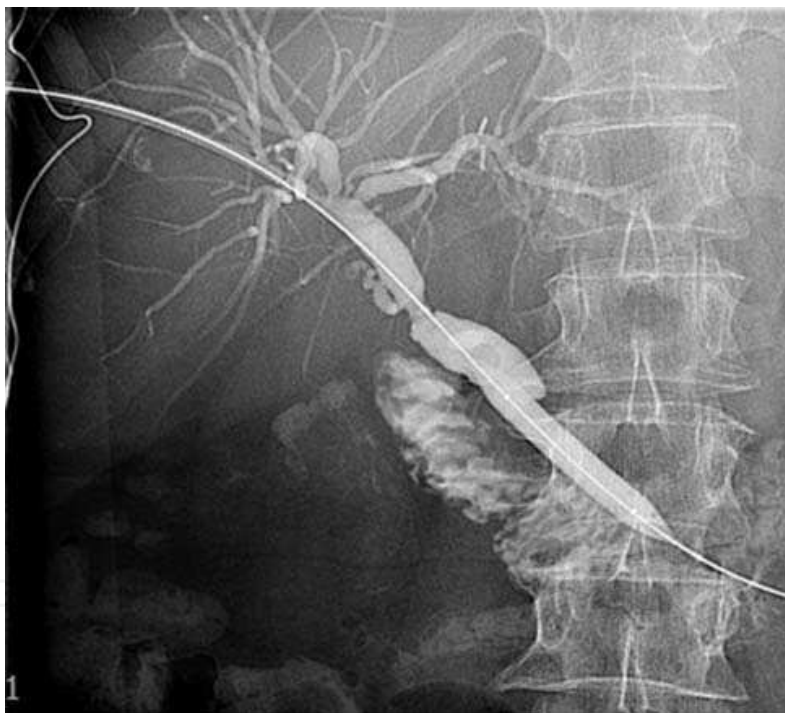


Fig. 6. Bridging of anastomotic stricture by the wire from transhepatic approach

6.3 Non-anastomotic hilar strictures (ischemic-type biliary lesions)

With an incidence in the range of between 5% and 15%, these biliary complications remain a substantial source of morbidity, graft loss, and even mortality after liver transplantation (Fig. 7). Their multifactorial origin involves various events (risk factors) including ischemia due to hepatic artery thrombosis or prolonged cold and warm ischemia, use of University of Wisconsin solution vs. histidine tryptophan ketoglutarate, ABO incompatibility, extramural pressure by lymph nodes or tumour, recurrence of the original disease or it remains obscure.

Also the altered bile composition with a significantly lower phospholipids/bile salts ratio after liver transplantation and graft steatosis may contribute to the pathogenesis of these complications (Buis et al., 2005, 2009; Pascher et al., 2005). Compared to anastomotic strictures, non-anastomotic strictures pose a higher risk of progressive disease with a severe outcome and limited graft survival. The shape of ischemic and ischemic-like strictures may change surprisingly quickly. Endoscopic treatment consists of stent insertion similar to non-transplant patients, but proper exploration and management of underlying conditions are essential. If the stricture involves the segmental branches, multiple stents bridging the strictures of all ducts are necessary. In specific conditions of malignant strictures, metallic stent insertion according to commonly shared rules is the choice. Full success of endoscopic treatment is less likely due to the location distant to the papilla making endoscopic manipulation less effective and, also, due to the various underlying conditions with different outcomes. Endoscopic treatment may be combined with the transhepatic approach if necessary. According to a recent study, percutaneous transhepatic Y-configured single-catheter stenting may enlarge the armamentarium of drainage techniques in hilar strictures (Wang et al., 2011).

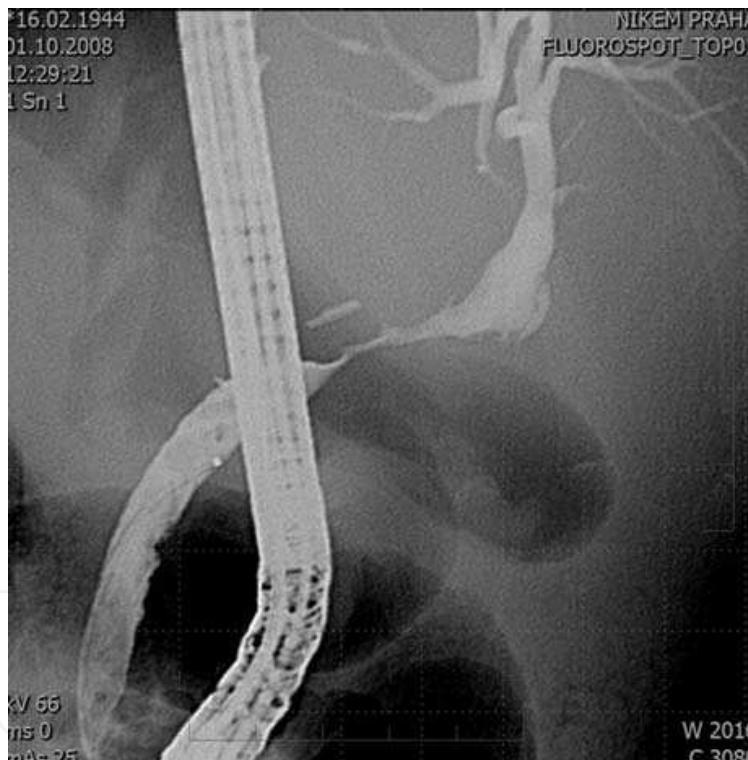


Fig. 7. Ischemic-type biliary lesion

6.4 Intrahepatic strictures

They are not unequivocally classified against non-anastomotic ischemic-type biliary lesions, and the pathogenesis shares identical principles. Wan Lee et al. classified intrahepatic stenoses into 4 groups: unilateral focal, confluence, bilateral multifocal and diffuse (Fig. 8). The success of non-surgical, either endoscopic or transhepatic interventions, is reversely related to the extent of duct involvement with a frequent need of early retransplantation (Lee et al., 2007).

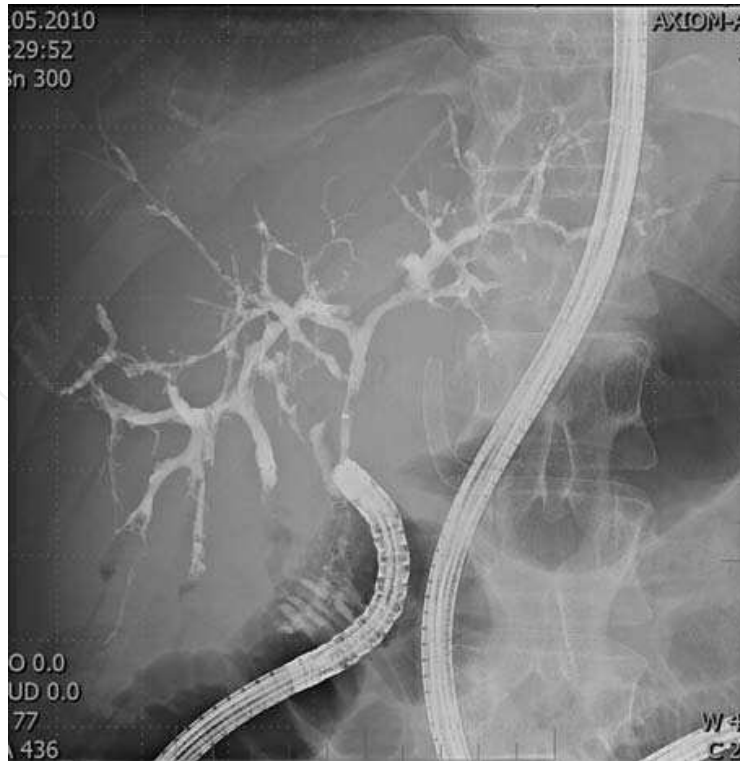


Fig. 8. Multiple intrahepatic strictures - the recurrence of primary sclerosing cholangitis. Approach to hepatico-jejunoanastomosis with the enteroscope

6.5 Distal strictures

Strictures below the anastomosis are usually caused by chronic pancreatitis. Surprisingly, pancreatitis is often asymptomatic and cholestasis is the only manifestation of advanced pancreatic disease. Other causes include extramural pressure by malignancies, mucocele, and biloma. They can be managed in the same manner as non-transplant conditions (Pascher et al., 2005).

6.6 Papillary stenosis (sphincter of Oddi dysfunction - SOD)

Data concerning the occurrence of papillary stenosis/dysfunction after liver transplantation are less consistent compared to other specific and well defined biliary complications (anastomotic strictures, leaks). Cholestasis was observed in 3-7% of patients following T-tube clamping early after liver transplantation but, according to some authorities, it used to be transient and self-limited. Papillary stenosis may be facilitated or unmasked by liver transplantation due to the abolished bile duct spontaneous motility by duct reconstruction and denervation. On the other hand, the fact that some patients develop sphincter of Oddi dysfunction (SOD) and others do not while undergoing the same surgical procedure, is intriguing (Douzdijan et al., 1994). The embarrassment and inevitable diversity of approaches can be demonstrated on a model case: a patient developed significant cholestasis several months after liver transplantation. Biopsy excluded other causes, sonography and MRCP showed dilatation of the recipient choledochus, as confirmed by ERCP. Multiple choices were as follows: either to perform manometry or sphincterotomy, to wait, or perhaps to insert a stent and wait; if the cholestasis has resolved, the patient can be either followed

only and, if it has appeared again, it would bring a strong argument for sphincterotomy. If sphincterotomy is the choice, a cut to a maximal safe extent is recommended.

6.7 Bile duct stones

While less frequent compared to leaks and anastomotic strictures, bile duct stones are still a relatively common complication after liver transplantation. Two basic categories of choledocholithiasis can be classified. Sludge or small stones usually develop as a late complication. A soft pigmented composition prevails suggesting that cholestasis and infection play a decisive role. Cholesterol supersaturation and related changes in lithogenicity are probably less important. The occurrence of stones is often associated with biliary strictures. More rarely, extensive casts completely filling biliary tree have been described. Casts usually appear relatively early after liver transplantation subsequently to prolonged ischemia resulting in severe diffuse biliary mucosal damage and defoliation. Endoscopic treatment responding to non-transplant conditions should be primarily preferred followed, alternatively, by the transhepatic approach or surgery in the case of failure. Nevertheless, the long-term outcome reflecting the underlying conditions may be limited when multiple stones or casts with diffuse bile duct damage occur (Sheng et al., 1996; Spier et al., 2008).

6.8 Post-transplant lymphoproliferative disorder (PTLD)

PTLD is a serious and complex clinicopathologic disorder that has been related to several specific factors, particularly overimmunosuppression and viral infection. The rate of PTLD is approaching 3%. The early cases are located in the liver hilum causing biliary stenosis with cholestasis. Treatment is based on several principles. The degree of immunosuppression should be reduced. Antiviral drugs have been used mostly in children. Chemotherapy has been given to patients with EBV-negative monoclonal lymphomas developing with delay after transplantation. Other options include rituximab, a chimeric anti-CD20 antibody, radiotherapy and interferon-alpha. Local biliary involvement can be relieved by stent insertion from either the endoscopic or transhepatic approach or, exceptionally, by surgery. Endoscopic treatment corresponds to the endoscopic approach to hilar strictures of other causes with a common need of transhepatic assistance. The survival is determined by the pathobiology of the PTLD with a worse prognosis in early disease similar to the prognosis of other post-transplant malignancies (Aucejo et al., 2006).

6.9 Bile leaks

Bile leaks have been reported in 1-25% of OLTs performed. They can be divided into early, defined by a time period of 1-3 months after OLT, and late leaks. Anastomotic leaks are related to technically imperfect suture, or ischemic damage of the (usually) donor bile duct (Fig. 9).

Other considered risk factors include recipient and donor age and the MELD score (Weilling et al., 2008). Bile leaks seem to be unrelated to the type of biliary duct-to-duct reconstruction. According to a recent RCT, neither end-to-end nor side-to-side choledocho-choledochostomy revealed significant differences in terms of the presentation of biliary complications. Early leakage may develop at the T-tube insertion site whenever yet typically after T-tube

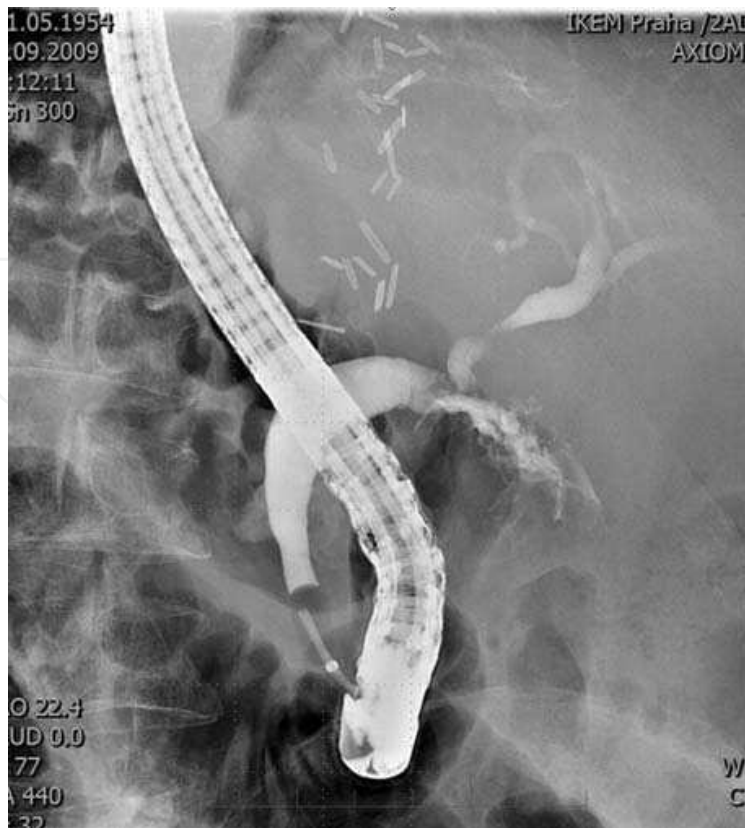

Fig. 9. Anastomotic bile leak

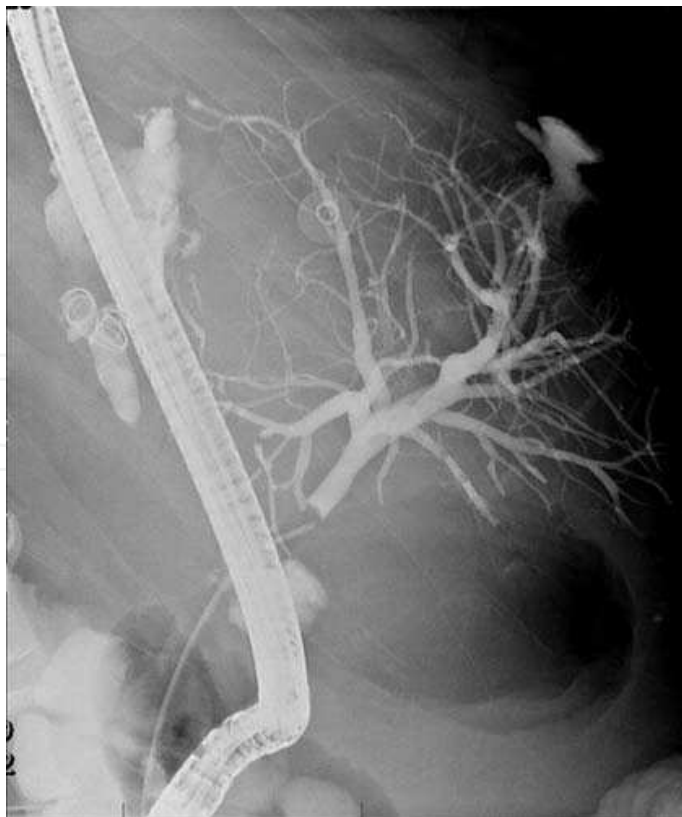

Fig. 10. Peripheral bile leak

removal, in up to 30% of procedures. The T-tube used to be inserted for a few months to maintain access to the biliary ducts and in the hope of preventing the development of a stricture at anastomosis. Other sites of leak comprise surface leaks and leaks from inadvertent bile ducts, usually after graft reduction (Fig. 10). The leaks can be treated either by stent or nasobiliary drainage insertion (after sphincterotomy). In small leaks, sphincterotomy alone may be sufficient (Skuhart et al., 1998).

6.10 Roux-en-Y anastomosis

Several small studies have focused on endoscopic treatment of patients with Roux-en-Y anastomosis, which in the past could be managed by either a standard duodenoscope or gastroscope with limited success only. Both with double- or single-balloon enteroscope, ERC is a feasible option with high success rate (Fig. 8). Limitations of this technique include the time requirement (1-2 hours) and the relatively narrow scale of accessories (Langer et al., 2009; Mönkenmüller et al., 2008).

6.11 Metal stents

The originally designed uncovered self-expanding metal stents have been shown to maintain longer patency than plastic stents in malignant strictures (Fig. 11). Nevertheless, in benign strictures, they were mostly rejected and failed due to mucosal hyperplasia and impossible removability. The advantage of covered metal stents is to prevent tissue ingrowth and removability using the snare or rat-tooth technique. In a recent study, fully

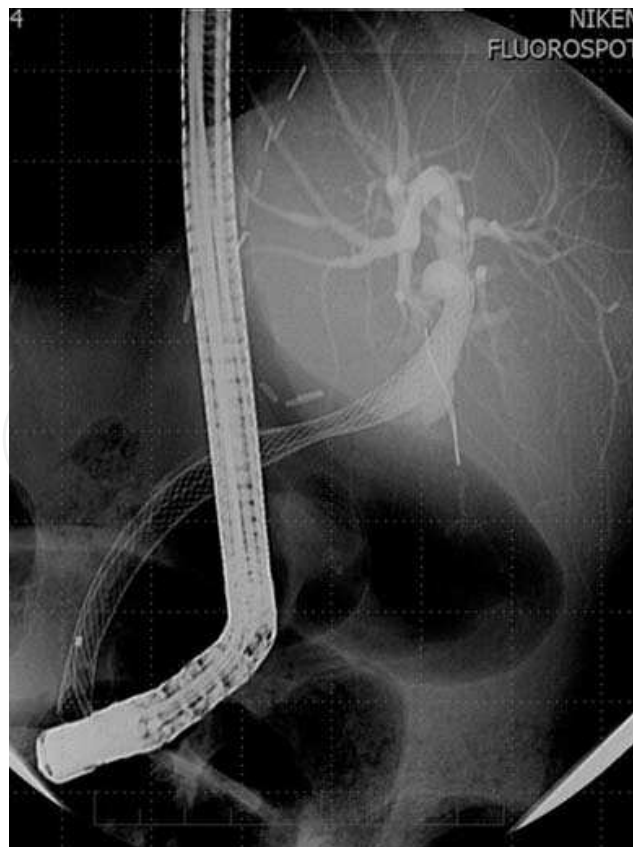


Fig. 11. Self-expanding metal stent due to ischemic-type stenosis

covered metal stents were inserted in 16 patients where plastic stent have failed. In six stents, migration occurred, nevertheless the stricture/leak resolved and a recurrent stricture developed in one patient. While a multicentre study is not easy to be designed, this is the only chance to reliably assess the potential of this modality (Costamagna et al. 2008; Kahaleh et al., 2008; Traina et al., 2009).

6.12 Living donor liver transplantation (LDLT)

The last decade has witnessed significant progress in LDLT. As compared to a whole liver transplant, the recipient of a partial graft in LDLT is faced with increased surgical complications associated with complicated hilar anastomotic variation requiring multiple biliary reconstructions. Since common biliary variations have been recognized, several types of biliary reconstructions have been developed. Both materials and type of the suture method have a major effect on the incidence biliary complications. To avoid bile duct devascularisation and consequent non-anastomotic biliary strictures, new surgical refinements have been also described. A variety of techniques have been reported to avoid injury to blood supply in LDLT. A detailed preoperative evaluation of the graft biliary system followed by an intraoperative cholangiogram through the cystic duct is a must. The optimal technique for biliary anastomosis in LDLT is still controversial. The currently most common techniques are either duct-to-duct or Roux-en-Y hepatico-jejunostomy. Since the late 1990, duct-to-duct anastomosis has been increasingly used, but the concerns regarding terms leaks and strictures seemed quite controversial. However, as the issue of LDLT is enormously complicated, prospective randomized studies are not realistic and so is not the ultimate judgment. Stenting of the anastomosis which was almost abandoned in whole liver transplantation remains another controversy in more complicating anastomoses. At this moment, several principles are universally accepted, but the type of anastomosis and possible stenting should be decided freely according to the aetiology of liver disease, duct anatomy, and type of presumed anastomosis. The endoscopist can expect greater engagement and, in the case of complicated anastomosis, a creative approach with the use of a wide range of instruments as described above (Giacomoni et al., 2006; Grande et al., 1999; Kobayashi et al., 2009; Wojcicki et al., 2006).

6.13 Donation after cardiac death donors

The increased number of patients listed for liver transplantation requires expansion of the pool of donors. To balance the donor organ shortage, livers donated after cardiac death is increasingly used. Nevertheless, both graft and patient survival rates compared to donation after brain death remain inferior, often due to biliary complications whose incidence ranges from 25% to 60%. Compared to brain death donors, in organs donated after cardiac death, ischemic cholangiopathy without hepatic artery injury frequently requires urgent retransplantation. Often there is a discrepancy between acceptable hepatocellular function and dim prognosis due to septic cholangitis. Therefore, the MELD score is useless when considering retransplantation. As a bridge, attempts of multiple endoscopic and transhepatic draining are often needed carrying the risk of other complications. Currently, the only way of minimizing the risk of cholangiopathy seems to be careful selection of young donors and cold ischemic time well below 8 hours (Feng et al., 2011; Foley et al., 2011; de Vera et al., 2009).

7. Conclusion

The high rates and wide range of biliary complications after liver transplantation remain a most important issue. The advent of new strategies and techniques, such as split- or reduced-size liver, living related liver transplantation, and non-heart beating donors incorporating new technical and pathogenetic principles will maintain the rate of complications on a significant level. Management has to arise from individual assessment of the patient with its unique complexity comprising the morphology of the lesion, presumed pathogenesis, comorbidities, and prior surgery including the patient's preference. Analyses that consider all these factors should determine the strategy that may offer optimal profit for the patient. Management of biliary complications requires a multidisciplinary approach, in which all three main options, endoscopic, radiologic and surgical, have to be weighed one against each other. Generally, endoscopic management has to be considered as the first therapeutic option due its complexity, efficacy and safety in the majority of patients. The radiologic approach can be used alternatively in the majority of complications, preferably if there is not transluminal access to the biliary tree. Proper location of the stent by x-ray alone is more difficult to control, and multiple stents usually cannot be inserted. Both approaches can be combined. The disadvantage of these methods is the need for multiple sessions annoying the patient and increasing the risk of complications. Surgery - usually Roux-en-Y anastomosis - is a demanding technique potentially eliminating the obstruction forever. However, anastomosis obstruction and episodes of reflux cholangitis may compromise long-term outcome in up to 20% of patients. The standard therapeutic approach to biliary complications has not been uniformly defined and local expertise, usually inevitably uneven, plays an important role. The same biliary complication, i.e. extrahepatic stricture can be (and used to be) either treated by endoscopy, interventional radiology, or surgery, without significant difference in the results among the studies. A direct comparative study has not been published yet and one cannot be expected to be conducted even in the future. The diverse nature of the complications requires usual endoscopic techniques of treatment and, similar to non-transplant conditions, sphincterotomy, stent insertion with or without dilatation, and stone extraction are the most common therapeutic modalities. With the advent of new technologies like metal (semi-) covered stents and balloon enteroscopes, the range of options will enlarge. Specific issues of endoscopic procedures after liver transplantation include prevention of postprocedural cholangitis, consideration of coagulation disorders, and sedation of patients with various mental impairments.

8. References


- ASGE guideline. (2008). Antibiotic prophylaxis for GI endoscopy. *Gastrointestinal endoscopy*, Vol.67, No.6, (May 2008), pp. 791-798, ISSN 0016-5107
- Aucejo, F.; Rofaiel, G.; Miller, C. (2006). Who is at risk for post-transplant lymphoproliferative disorders (PTLD) after liver transplantation?. *Journal of Hepatology*, Vol.44, No.1, (January 2006), pp. 19-23, ISSN 0168-8278
- Buis, C. I.; Hoekstra, H.; Verdonk, R. C. & al. (2006). Causes and consequences of ischemic-type biliary lesions after liver transplantation. *Journal of Hepato-Biliary-Pancreatic Surgery*, Vol.13, No.6, (November 2006), pp. 517-524, ISSN 0944-1166
- Buis, C. I.; Geuken, E.; Visser, D. S. & al. (2009). Altered bile composition after liver transplantation is associated with the development of nonanastomotic biliary

- strictures. *Journal of Hepatology*, Vol.50, No.1, (October 2008), pp. 69-79, ISSN 0168-8278
- Costamagna, G. (2008). Covered self-expanding metal stents in benign biliary strictures: not yet a “new paradigm” but a promising alternative. *Gastrointestinal endoscopy*, Vol.67, No.3, (March 2008), pp. 455-457, ISSN 0016-5107
- Cotton, P. B.; Connor, P.; Rawls, E. & al. (2008). Infection after ERCP and antibiotic prophylaxis: a sequential quality-improvement approach over 11 years. *Gastrointestinal endoscopy*, Vol.67, No.3, (March 2008), pp.471-475, ISSN 0016-5107
- Davidson, B. R.; Rai, R.; Kurzawinski, T. R. & al. (1999). Prospective randomized trial of end-to-end versus side-to-side biliary reconstruction after orthotopic liver transplantation. *The British Journal of Surgery*, Vol.86, No.4, (April 1999), pp. 447-452, ISSN 0007-1323
- De Vera, E. M.; Lopez- Solis, R.; Dvorchik, I. & al. (2009). Liver transplantation using donation after cardiac death donors. Long-term follow-up from a single center. *American Journal of Transplantation: official journal of the American Society of Transplantation and the American Society of Transplant Surgeons*, Vol.9, No.4, (April 2009), pp. 773-781, ISSN 1600-6143
- Douzdijan, V.; Abecassis, M. M.; Johlin, F. C. & al. (1994). Sphincter of Oddi Dysfunction following liver transplantation. Screening by bedside manometry and definitive manometric evaluation. *Digestive diseases and sciences*, Vol.39, No.2, (February 1994), pp. 253-256, ISSN 0163-2116
- Feng, X. N.; Ding, C. F.; Xing, M. Y. & al. (2011). Technical aspects of biliary reconstruction in adult living donor liver transplantation. *Hepatobiliary & Pancreatic Diseases International: HBPD INT*, Vol.10, No.2, (April 2011), pp. 136-142, ISSN 1499-3872
- Foley, D. P.; Fernandez, L. A.; Levenson, G. & al. (2011). Biliary complications after liver transplantation from donation after cardiac death donors: an analysis of risk factors and long-term outcomes from a single center. *Annals of Surgery*, Vol.253, No.4, (April 2011), pp. 817-825, ISSN 1528-1140
- Giacomini, A.; Lauterio, A.; Slim, A. Q. & al. (2006). Biliary complications after living donor adult liver transplantation. *Transplant international: official journal of the European Society for Organ Transplantation*, Vol.19, No.6, (June 2006), pp. 466-473, ISSN 0934-0874
- Grande, L.; Pérez-Castilla, A.; Matus, D. & al. (1999). Routine use of the T-tube in the biliary reconstruction of liver transplantation: is it worthwhile?. *Transplantation proceedings*, Vol.31, No.6, (September 1999), pp. 2396-2397, ISSN 0041-1345
- Graziadei, I. W.; Schwaighofer, H.; Koch, R. & al. (2006). Long-term outcome of endoscopic treatment of biliary strictures after liver transplantation. *Liver transplantation: official publication of the American Association for the Study of Liver Diseases and the International Liver Transplantation Society*, Vol.12, No.5, (May 2006), pp. 718-725, ISSN 1527-6465
- Holt, A. P.; Thorburn, D.; Mirza, D. & al. (2007). A prospective study of standardized nonsurgical therapy in the management of biliary anastomotic strictures complicating liver transplantation. *Transplantation*, Vol.84, No.7, (October 2007), pp. 857-863, ISSN 0041-1337
- Chapman, R.; Plaat, F. (2009). Alcohol and anaesthesia. *Continuing Education in Anaesthesia, Critical Care and Pain*, Vol.9, No.1, (February 2009), pp. 10-13, ISSN 1743-1816

- Kahaleh, M.; Behm, B.; Clarke, B. W. & al. (2008). Temporary placement of covered self-expandable metal stents in benign biliary strictures: a new paradigm?. *Gastrointestinal endoscopy*, Vol.67, No.3, (March 2008), pp. 446-454, ISSN 0016-5107
- Katz, L. H.; Mor, E.; Brown, M. & al. (2006). Recurrent hepatitis C virus disease after liver transplantation and concurrent biliary tract complications: poor outcome. *Clinical transplantation*, Vol.20, No.4, (August 2006), pp. 465-470, ISSN 0902-0063
- Kobayashi, T.; Sato, Y.; Yamamoto, S. & al. (2009). Long-term follow-up study of biliary reconstructions and complications after adult living donor liver transplantation: feasibility of duct-to-duct reconstruction with a T-tube stent. *Transplantation proceedings*, Vol.41, No.1, (February 2009), pp. 265-267, ISSN 0041-1345
- Kulaksiz, H.; Weiss, K. H.; Gotthardt, D. & al. (2008). Is stenting necessary after balloon dilation of post-transplantation biliary strictures? Results of a prospective comparative study. *Endoscopy*, Vol.40, No.9, (September 2008), pp. 746-751, ISSN 1438-8812
- Langer, F. B.; Györi, G. P.; Pokorny, H. & al. (2009). Outcome of hepaticojejunostomy for biliary tract obstruction following liver transplantation. *Clinical transplantation*, Vol.23, No.3, (July 2009), pp. 361-367, ISSN 0902-0063
- Lebeau, G.; yanaga, K.; Marsh, J. W. & al. (1990). Analysis of surgical complications after 397 hepatic transplantations. *Surgery, Gynecology & Obstetrics*, Vol.170, No.4, (April 1990), pp. 317-322, ISSN 0039-6087
- Lee, H. W.; Suh, K. S.; Shin, W. Y. & al. (2007). Classification and prognosis of intrahepatic biliary stricture after liver transplantation. *Liver transplantation: official publication of the American Association for the Study of Liver Diseases and the International Liver Transplantation Society*, Vol.13, No.12, (December 2007), pp. 1736-1742, ISSN 1527-6465
- Mönkemüller, K.; Bellutti, M.; Neumann, H. & al. (2008). Therapeutic ERCP with the double-balloon enteroscope in patients with Roux-en-Y anastomosis. *Gastrointestinal endoscopy*, Vol.67, No.6, (May 2008), pp. 992-996, ISSN 0016-5107
- Pasha, S. F.; Harrison, M. E.; Das, A. & al. (2007). Endoscopic treatment of anastomotic biliary strictures after deceased donor liver transplantation. Outcomes after maximal stent therapy. *Gastrointestinal endoscopy*, Vol.66, No.1, (July 2007), pp. 44-51, ISSN 0016-5107
- Pascher, A.; Neuhaus, P. (2005). Bile duct complications after liver transplantation. *Transplant international: official journal of the European Society for Organ Transplantation*, Vol.18, No.6, (June 2005), pp. 627-642, ISSN 0934-0874
- Rockey, D. C.; Caldwell, S. H.; Goodman, Z. D. & al. (2009). Liver biopsy. *Hepatology*, Vol.49, No.3, (March 2009), pp. 1017-1044, ISSN 1527-3350
- Sanni, A.; Asher, J.; Wilson, C. & al. (2006). Predisposing factors for biliary complications following liver transplantation. *Transplantation proceedings*, Vol.38, No.8, (October 2006), pp. 2677-2678, ISSN 0041-1345
- Sheng, R.; Ramirez, C. B.; Zajko, A. B. & al. (1996). Biliary stones and sludge in liver transplant patients: a 13-year experience. *Radiology*, Vol.198, No.1, (January 1996), pp. 243-247, ISSN 0033-8419
- Shuhart, M. C.; Kowdley, K. V.; McVicar, J. P. & al. (1998). Predictors of bile leaks after T-tube removal in orthotopic liver transplant recipients. *Liver transplantation: official publication of the American Association for the Study of Liver Diseases and the*

- International Liver Transplantation Society*, Vol.4, No.1, (January 1998), pp. 62-70, ISSN 1074-3022
- Spier, B. J.; Pfau, P. R.; Lorenze, K. R. & al. (2008). Risk factors and outcomes in post-liver transplantation bile duct stones and casts: A case-control study. *Liver transplantation: official publication of the American Association for the Study of Liver Diseases and the International Liver Transplantation Society*, Vol.14, No.10, (October 2008), pp. 1461-1465, ISSN 1527-6465
- Suárez, F.; Otero, A.; Solla, M. & al. (2008). Biliary complications after liver transplantation from Maastricht category-2 non-heart-beating donors. *Transplantation*, Vol.85, No.1, (January 2008), pp. 9-14, ISSN 0041-1337
- Traina, M.; Tarantino, I.; Barresi, L. & al. (2009). Efficacy and safety of fully covered self-expandable metallic stents in biliary complications after liver transplantation: a preliminary study. *Liver transplantation: official publication of the American Association for the Study of Liver Diseases and the International Liver Transplantation Society*, Vol.15, No.11, (November 2009), pp. 1493-1498, ISSN 1527-6465
- Wang, M. C.; Li, X.; Song, S. & al. (2011). Newly designed Y-configured single-catheter stenting for the treatment of hilar-type nonanastomotic biliary strictures after orthotopic liver transplantation. *Cardiovascular and interventional radiology*, (June 2011), Epub ahead of print, ISSN 1432-086X
- Welling, T. H.; Heidt, D. G.; Englesbe, M. J. & al. (2008). Biliary complications following liver transplantation in the model for end-stage liver disease era: effect of donor, recipient and technical factors. *Liver transplantation: official publication of the American Association for the Study of Liver Diseases and the International Liver Transplantation Society*, Vol.14, No.1, (January 2008), pp. 73-80, ISSN 1527-6465
- Wojcicki, M.; Silva, M. A.; Jethwa, P. & al. (2006). Biliary complications following adult right lobe ex vivo split liver transplantation. *Liver transplantation: official publication of the American Association for the Study of Liver Diseases and the International Liver Transplantation Society*, Vol.12, No.5, (May 2006), pp. 839-844, ISSN 1527-6465
- Wojcicki, M.; Milkiewicz, P.; Silva, M. (2008). Biliary tract complications after liver transplantation: a review. *Digestive Surgery*, Vol.25, No.4, (July 2008), pp. 245-257, ISSN 1421-9883

IntechOpen



Liver Transplantation - Technical Issues and Complications

Edited by Prof. Hesham Abdeldayem

ISBN 978-953-51-0015-7

Hard cover, 454 pages

Publisher InTech

Published online 10, February, 2012

Published in print edition February, 2012

This book covers a wide spectrum of topics including, but not limited to, the technical issues in living and deceased donor liver transplant procedures, cell and experimental liver transplantation, and the complications of liver transplantation. Some of the very important topics, such as the arterial reconstruction in living donor liver transplantation, biliary complications, and the post-transplant-lymphoproliferative disorders (PTLD), have been covered in more than one chapter.

How to reference

In order to correctly reference this scholarly work, feel free to copy and paste the following:

Julius Spicak and Renata Bartakova (2012). Biliary Complications After Liver Transplantation, Liver Transplantation - Technical Issues and Complications, Prof. Hesham Abdeldayem (Ed.), ISBN: 978-953-51-0015-7, InTech, Available from: <http://www.intechopen.com/books/liver-transplantation-technical-issues-and-complications/biliary-complications-after-liver-transplantation>

INTECH
open science | open minds

InTech Europe

University Campus STeP Ri
Slavka Krautzeka 83/A
51000 Rijeka, Croatia
Phone: +385 (51) 770 447
Fax: +385 (51) 686 166
www.intechopen.com

InTech China

Unit 405, Office Block, Hotel Equatorial Shanghai
No.65, Yan An Road (West), Shanghai, 200040, China
中国上海市延安西路65号上海国际贵都大饭店办公楼405单元
Phone: +86-21-62489820
Fax: +86-21-62489821

© 2012 The Author(s). Licensee IntechOpen. This is an open access article distributed under the terms of the [Creative Commons Attribution 3.0 License](#), which permits unrestricted use, distribution, and reproduction in any medium, provided the original work is properly cited.

IntechOpen

IntechOpen