

We are IntechOpen, the world's leading publisher of Open Access books Built by scientists, for scientists

3,500

Open access books available

108,000

International authors and editors

1.7 M

Downloads

Our authors are among the

151

Countries delivered to

TOP 1%

most cited scientists

12.2%

Contributors from top 500 universities



WEB OF SCIENCE™

Selection of our books indexed in the Book Citation Index
in Web of Science™ Core Collection (BKCI)

Interested in publishing with us?
Contact book.department@intechopen.com

Numbers displayed above are based on latest data collected.
For more information visit www.intechopen.com



The Omentum Flap

Sirlei dos Santos Costa and Rosa Maria Blotta
*Reconstructive Surgery Center of Porto Alegre,
Universidade Federal do Rio Grande do Sul,
Brazil*

1. Introduction

The omentum flap with its well known characteristics has been used in the last two centuries to recover the most different purposes. Nowadays, its most recently observed attributes permits new applications with superb results, mainly in breast surgery.

In 1888, Senn employed it to protect an intestinal anastomosis (Irons et al,1983) and in 1963, Kiricuta described the use of the great omentum as a flap in cases of breast cancer surgery (Kiricuta, 1963).

McLean and Buncke in 1972, described the omentum free flap (McLean & Buncke, 1972). Laparoscopic harvesting of the omentum was carried out for the first time by Saltz in 1993 in order to repair soft tissue defects in the knee (Saltz et al, 1993).

Costa presented a totally closed video laparoscopic procedure in 1996, where the flap was dissected in the abdominal cavity and transposed through a subcutaneous tunnel to the thoracic wall, used to treat breast cancer patients. In 1998, for the first time, Costa utilized the omentum flap to treat Poland's syndrome deformities (Costa, 1998).

Various options have been proposed to reconstruct the breast's volume, including local flaps, expanders and implants, transposition of the latissimus dorsi, gluteus or the rectus abdominis muscle flaps. Although these techniques may achieve excellent results, depending on the degree of deformity, satisfaction with aesthetic reconstruction of the more detailed deformities, have been disappointing. Moreover, an additional scar is left in the patient's donor region of those muscular flaps.

In an attempt to solve these problems, the laparoscopically harvested omentum flap can be considered an excellent reconstructive option that offers a very interesting aesthetic result. The advantages of the omentum flap are numerous and significant: it is extremely malleable, adapts easily to irregular surfaces, and has a long and reliable vascular pedicle. The omentum is composed of highly vascularized fatty connective tissue and is attached to the greater curvature of the stomach. It adheres to the transverse colon forming the gastrocolic ligament. It continues separating the transverse colon and folds of the small intestine from the anterior abdominal wall. Left and right gastroepiploic arteries supply blood and this vascular net is anatomically constant enough so as to enable systematic dissection. The flap measures approximately 25x35 cm and its volume varies according to patient size (Arnold et al, 1976; Das, 1976).

In the first six months after the procedure the omentum flap presents a variable growth that needs to be considered when planning repair of the deformity (Costa et al, 2010; Costa et al, 2011).

The omentum (Fig.1) has several advantages including the flap's large absorption capacity, which reduces the postoperative time period during which drains are needed, since the flap helps absorb the lymphatic fluid resulting from lymph node dissection. The use of laparoscopy to harvest the flap offers minimal insult to the abdominal wall (Fig. 2), ensuring a short and comfortable postoperative recovery period (Cothier-Savey et al, 2001; Ferron et al, 2007; Zaha et al, 2006). A review of all available literature about laparoscopically harvested omentum flaps indicates that there are no severe postoperative complications.

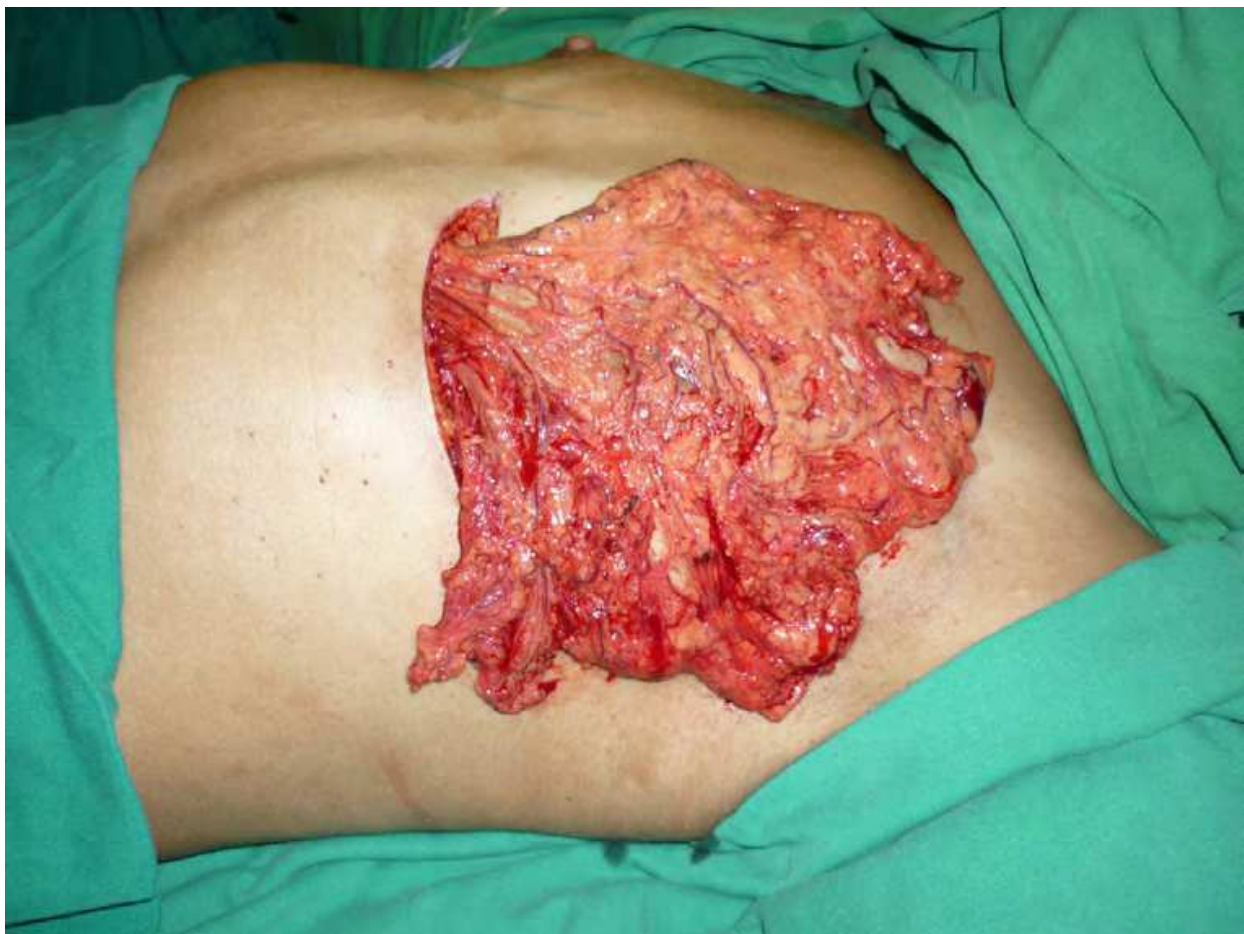

Fig. 1. The omentum flap over the thorax wall.

A difficulty of this technique is that it is not possible to precisely define the final omentum volume available in order to plan the reconstruction. The complementation of the volume and equalization with the contra-lateral breast may be done during the same surgical time or, even better, at another time, four to six months later; when it is possible to take into consideration the spontaneous growth of the flap that always occurs after its transposition.

Finally, the resulting consistency is very similar to the contra-lateral breast, enabling more satisfactory reparation of the anterior axillary pillar than any other reconstructive option.

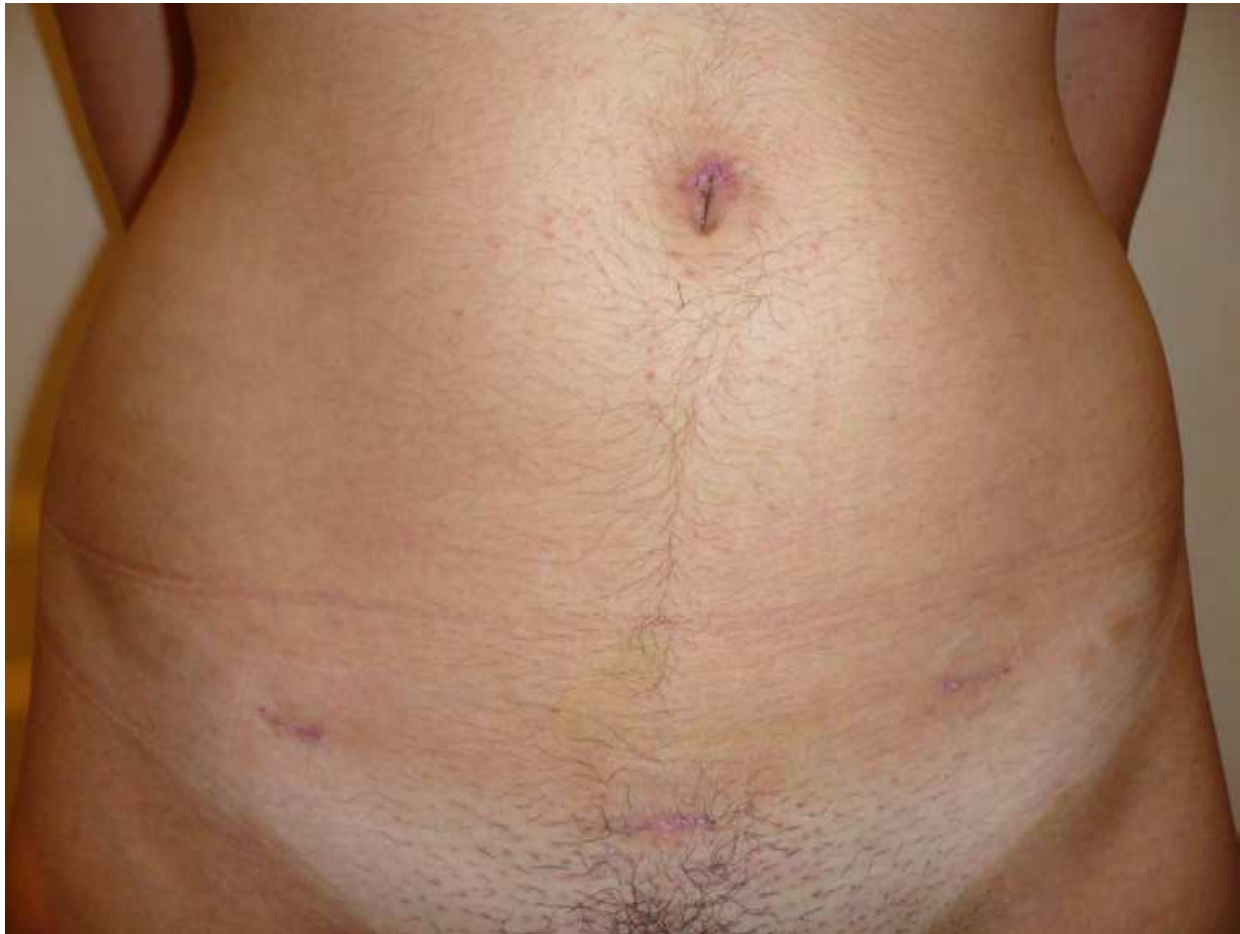

Fig. 2. Scars in the abdominal wall.

2. Indications

The omentum flap may be used in many different situations.

In breast reconstruction it can be used to treat congenital malformations and the principal utilization of the omentum flap is in the Poland's syndrome that is characterized by abnormalities in thorax wall, vertebrae and superior member. It is possible to treat the transverse sulcus in the anterior axillary's pillar, the infraclavicular depression and the anomalous breast contour with thin cover, unable to hide an implant (Fig. 3)

Benign diseases sequels, such as after a giant fibro adenoma resection (Fig. 4) or in visible wrinklings through the thin breast skin covering an implant that shows the visible muscle contraction, can be treated with the omentum flap (Fig. 5).

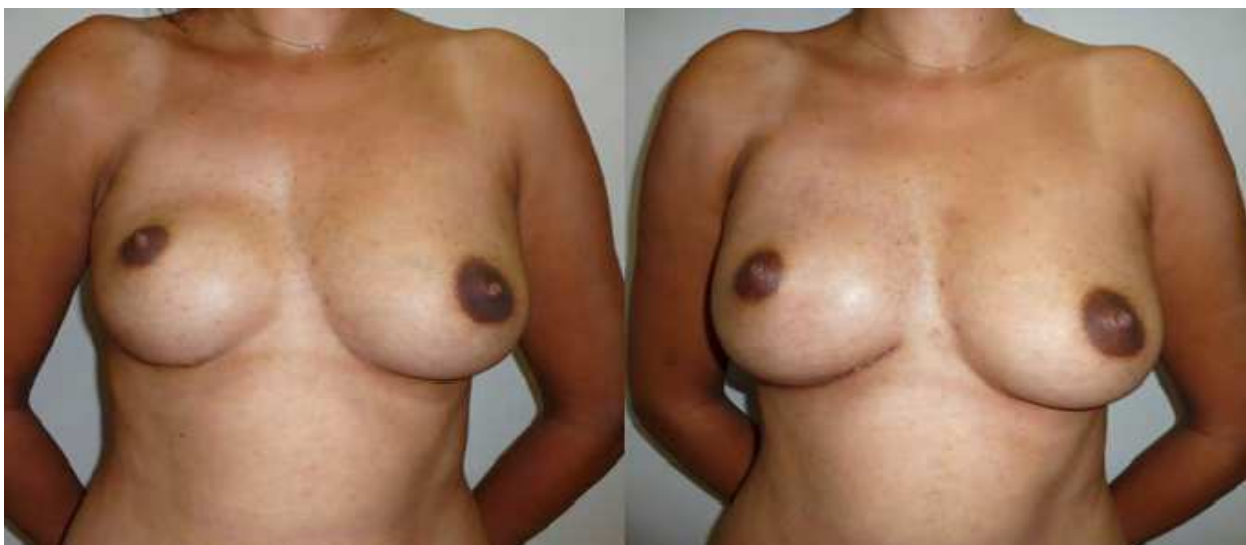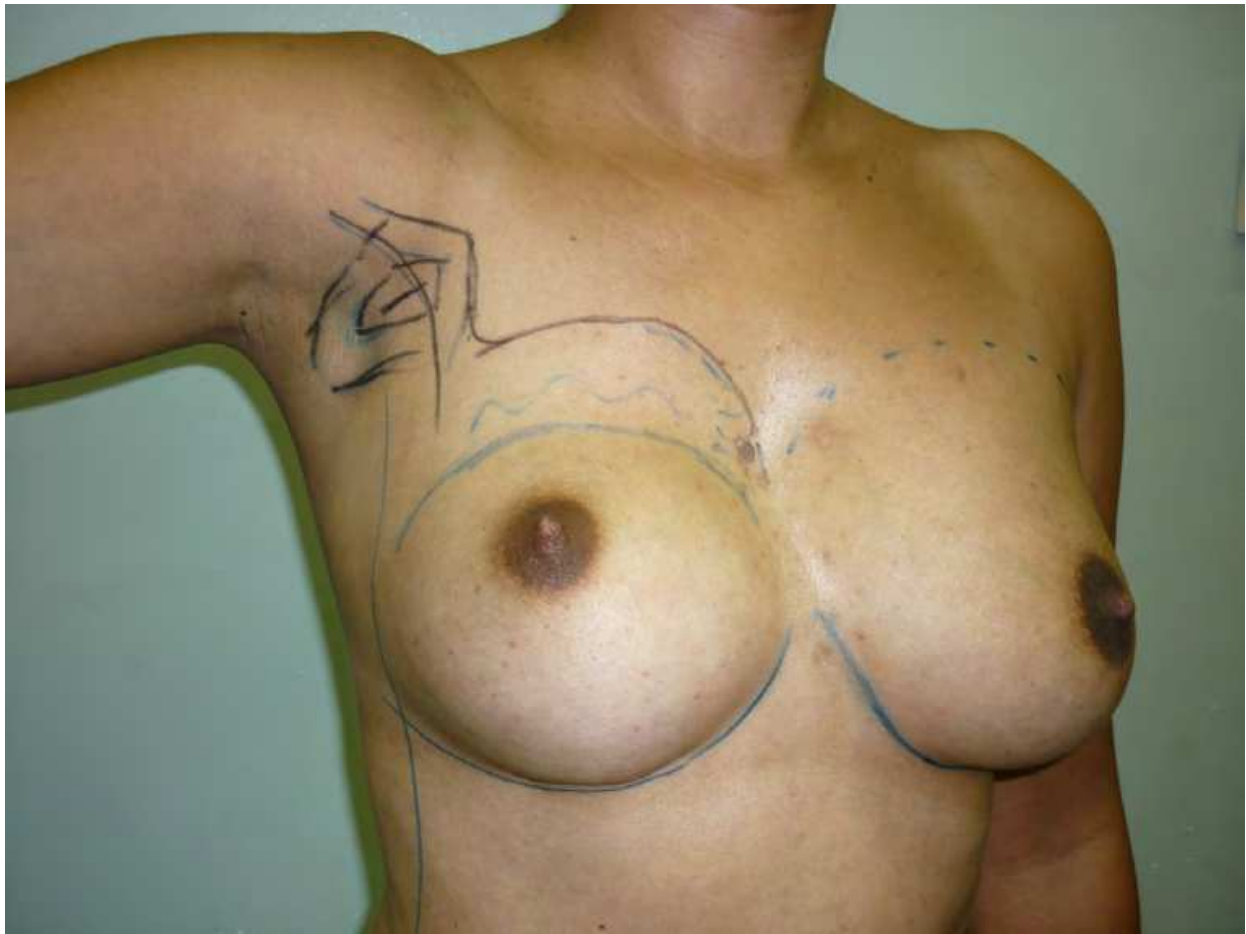


Fig. 3. Patient with Poland's syndrome treated with omentum flap.

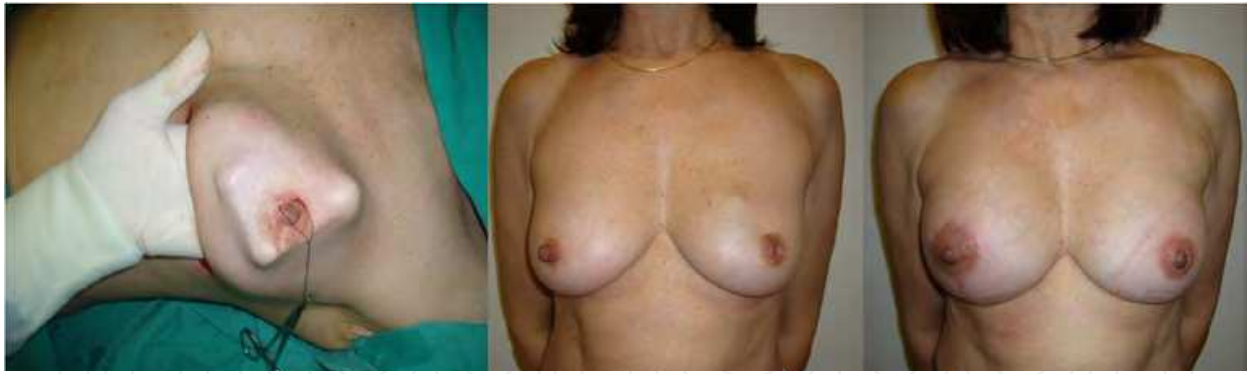

Fig. 4. Sequel of a giant fibro adenoma resection of the left breast treated with omentum flap.

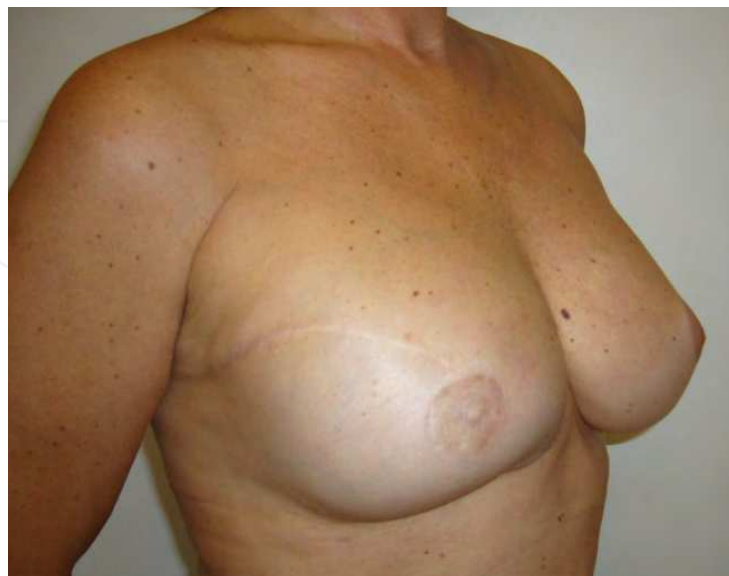
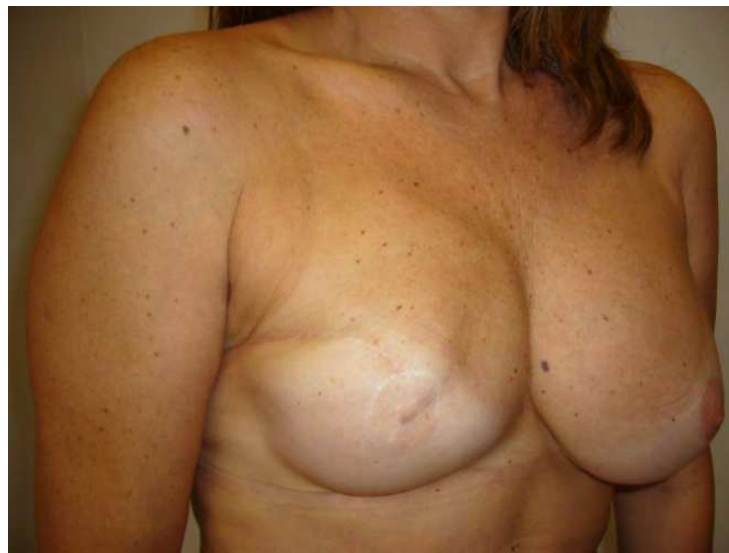
Fig. 5. The thin breast skin covering an implant and showing the visible muscle contraction treated with the omentum flap.

After breast cancer treatment, it can be used in partial or total resection of the breast, with or without prosthesis to complete the final volume.

The omentum is particularly interesting in radiotherapy sequels where its use may repair the ischemic condition of the skin, decreasing the local fibrosis and giving a soft appearance to the breast (Fig. 6).

There are many advantages to use the omentum flap: when dissected by video laparoscopy the abdominal wall is preserved with minimal scars. It is extremely malleable and adapts to the surface irregularities. It has a long pedicle with big caliber and the procedure presents minimal blood loss with short hospitalization time and fast recovery. The omentum flap has big absorption capability and stimulates new angiogenesis.

Other flaps like latissimus dorsi, gluteus or the rectus abdominis muscle flaps are preserved for another situation and the new breast consistency is similar to a natural one.

There are limitations for omentum use as the necessity of skin enough to cover the new breast, previous diseases in abdominal cavity that may damage the integrity of the omentum (inflammatory or surgical sequel), the variability of its volume and size and the necessity of the use of implants in some cases to complete the final volume desired.

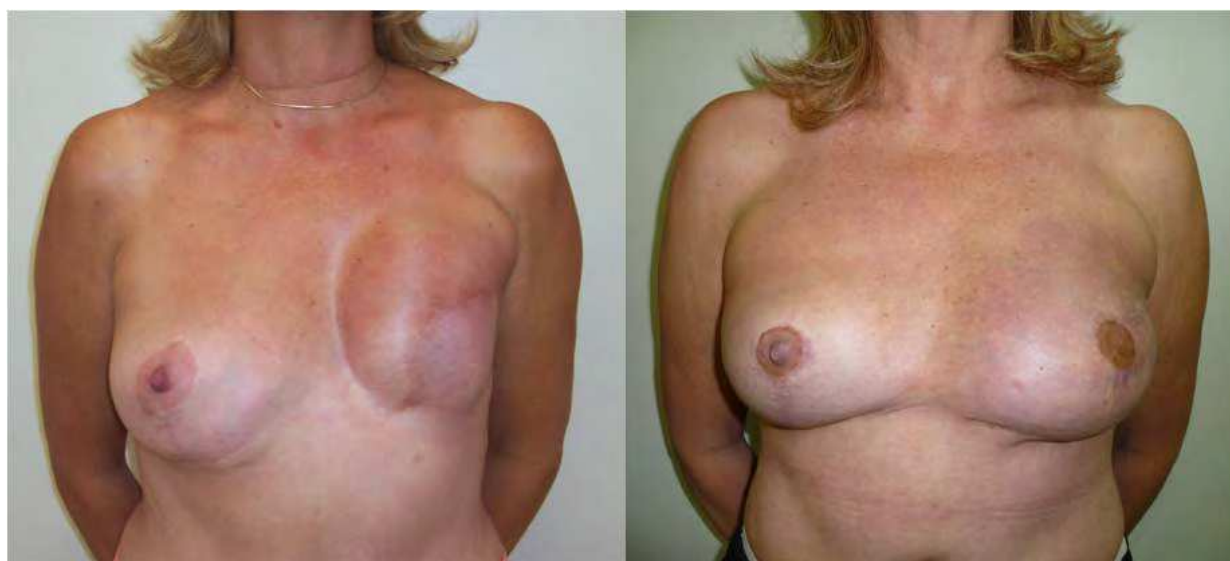

Fig. 6. Radiotherapy sequels treated with Omentum flap.

2.1 Omentum in breast cancer

The first breast reconstructions were carried out in surgical fields left by mastologists with great skin loss, which left the aesthetic result of the reconstruction difficult and poor. The advances in diagnosis and treatment of breast carcinoma over the last years have permitted greater preservation of the skin.

The omentum flap can be used in patients with sufficient skin to reconstruct a neo-breast, small than the first, but with a normal shape. In case of breast ptosis, where the removal of the entire breast is necessary, but part of the skin can be preserved, the omentum can be a good option.

Even in small breasts, in case of small tumors, where it is possible to conserve sufficient skin to reconstruct a neo-breast, the omentum flap can be an alternative to add volume (Fig. 7).

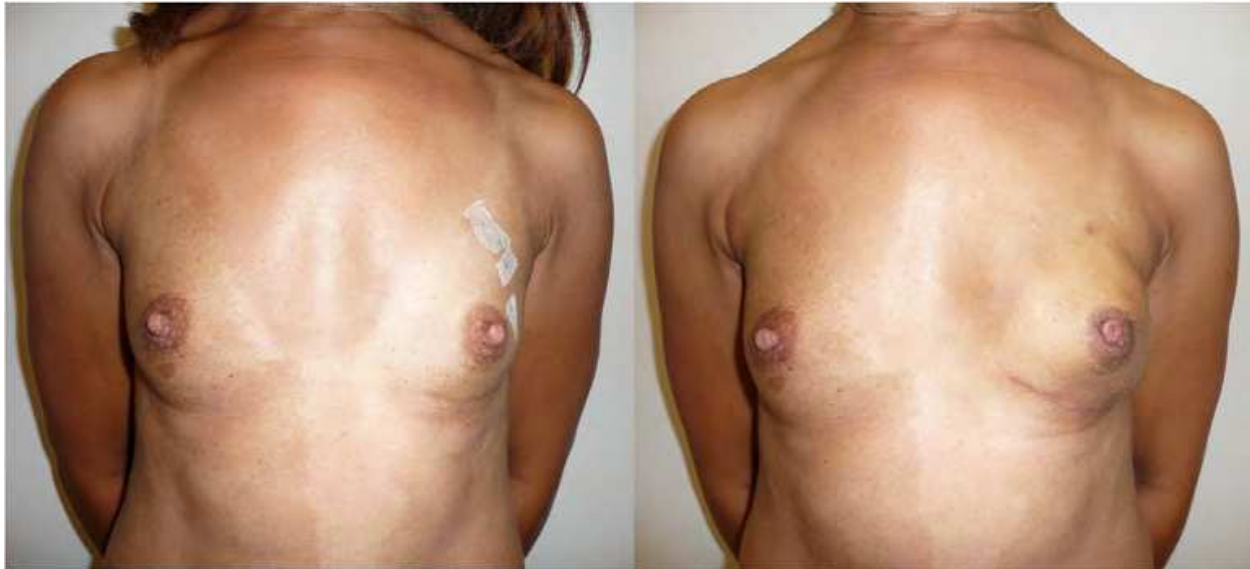


Fig. 7. Left breast reconstruction with omentum flap after left mastectomy.

The complementary post-operative treatment in patients with breast cancer using radiotherapy may cause fibrosis and vascular alterations resulting in a fragile skin which is inadequate to receive a prosthesis.

In these cases, the omentum can be transposed and offers a considerable improvement in vascularization and malleability of the skin flaps, enabling a breast reconstruction with expander and prosthesis (Fig. 6).

2.2 Omentum in breast malformations

The main congenital malformation of breast is the Poland's syndrome (Fig.8). Patients with Poland's syndrome may present with numerous ailments such as absence of the sternal-costal portion of the *pectoralis* major muscle, upper extremity hypoplasia, brachysyndactyly, and syndactyly. Various other muscles may also be affected: *pectoralis* minor, latissimus dorsi, serratus anterior, external oblique, and deltoid. Skeletal deformities such as partial agenesis of the ribs, *sternum*, and spine (sometimes with *scoliosis*) may occur. Breast hypoplasia or aplasia, nipple abnormalities, skin atrophy, and absence of the sweat glands and surrounding structures are other features (Cobben et al, 1989; Bainbridge et al, 1991; Perez et al, 1996).

In Poland's syndrome, thoracic wall deformities are not as obvious at birth as hand deformities. However, when female patients reach adolescence, the thoracic deformity seems to become more evident as absence or asymmetry of the developing breasts occurs. To minimize this, a tissue expander may be placed in the developing breast to accompany contra-lateral breast growth. Unfortunately, however, surgical treatment of the breast deformities cannot be accomplished before 17-19 years of age, when development of the body is complete.

The most uncomfortable physical alterations are the transversal skin fold in the anterior axillary pillar (caused by the absence or hypoplasia of the pectoral muscles), the infra-clavicular depression, and an anomalous breast contour (Seyfer et al, 1988). The resulting aesthetic derangement is difficult to hide, leads to thoracic asymmetry, and imposes significant psychological trauma and social withdrawal in both men and women.

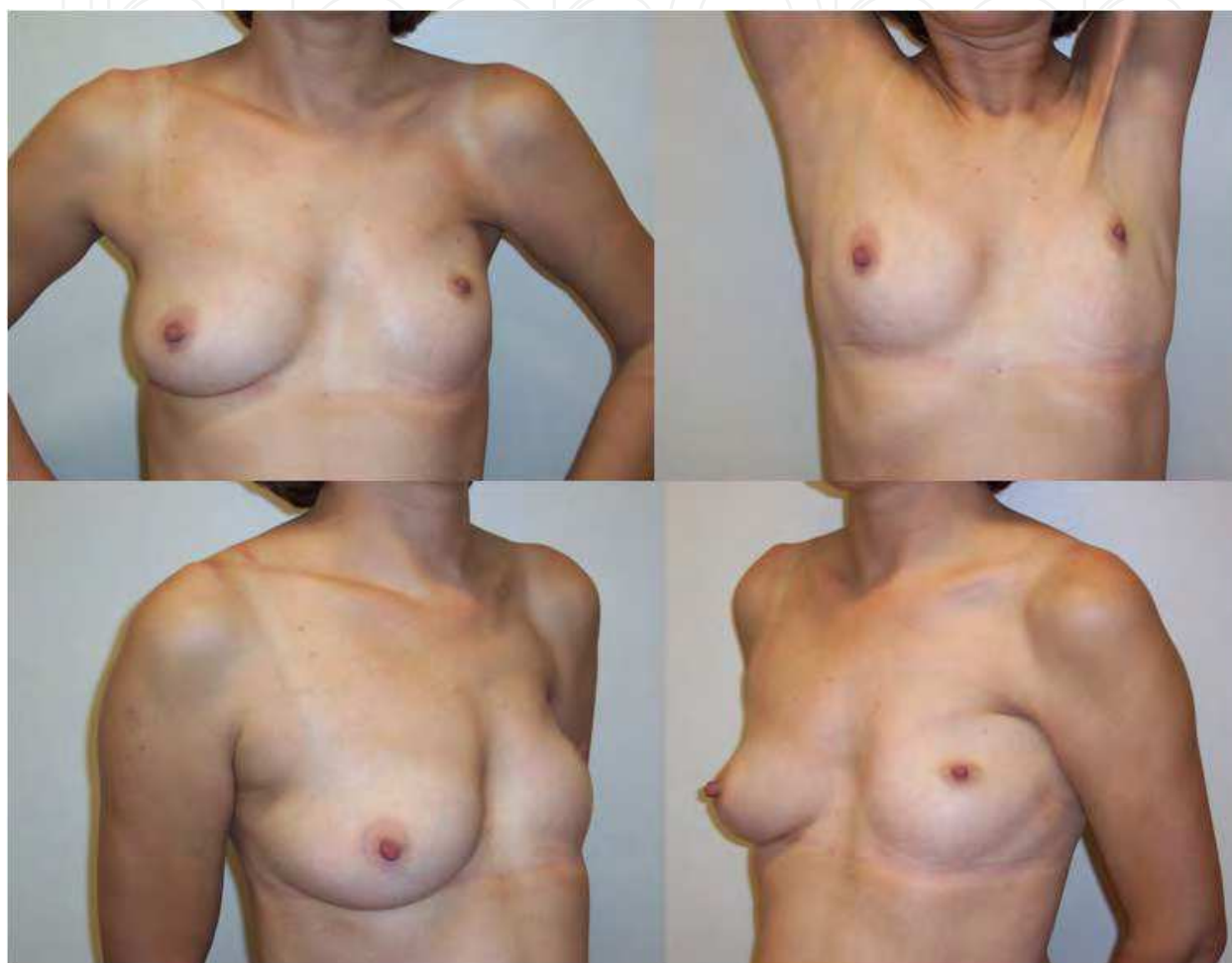

Fig. 8. Patient with Poland's syndrome in the left side.

Patients with Poland's syndrome treated with omentum flap achieved a final aesthetic result better than those patients who were treated with other techniques, as shown in figures 9 to 11. With the omentum flap, it is possible to correct particular details of breast contour due to flap tissue malleability, an outcome impossible to achieve with all other techniques. Utilization of the omentum flap improves breast contouring, filling in the infra-clavicular depression and reconstructing the anterior axillary pillar. When implants are employed below the flap, it provides appropriate concealment and a better quality coverage system that results in improved symmetry with the opposite hemi-thorax. The palpation of the flap in the new site is similar in consistency to a normal breast. This flap is the only one that gives the patient this possibility. All other flaps do not achieve such a perfectly similar consistency of the breast-like omentum.

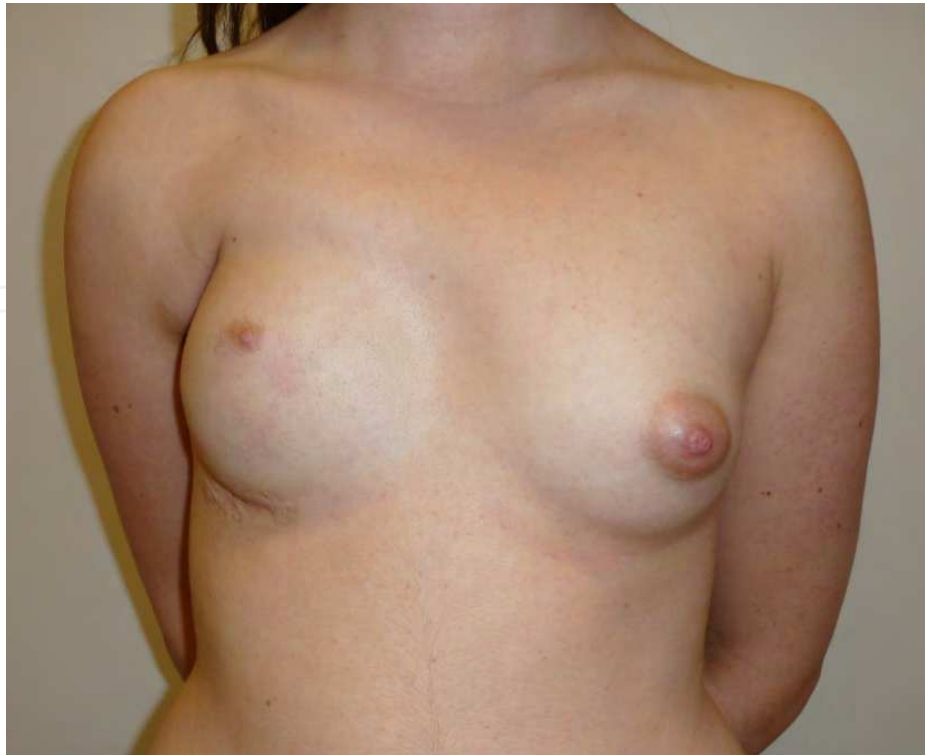

Fig. 9. Patient with Poland's syndrome in the right side first treated only with a prosthesis with a poor aesthetic result.

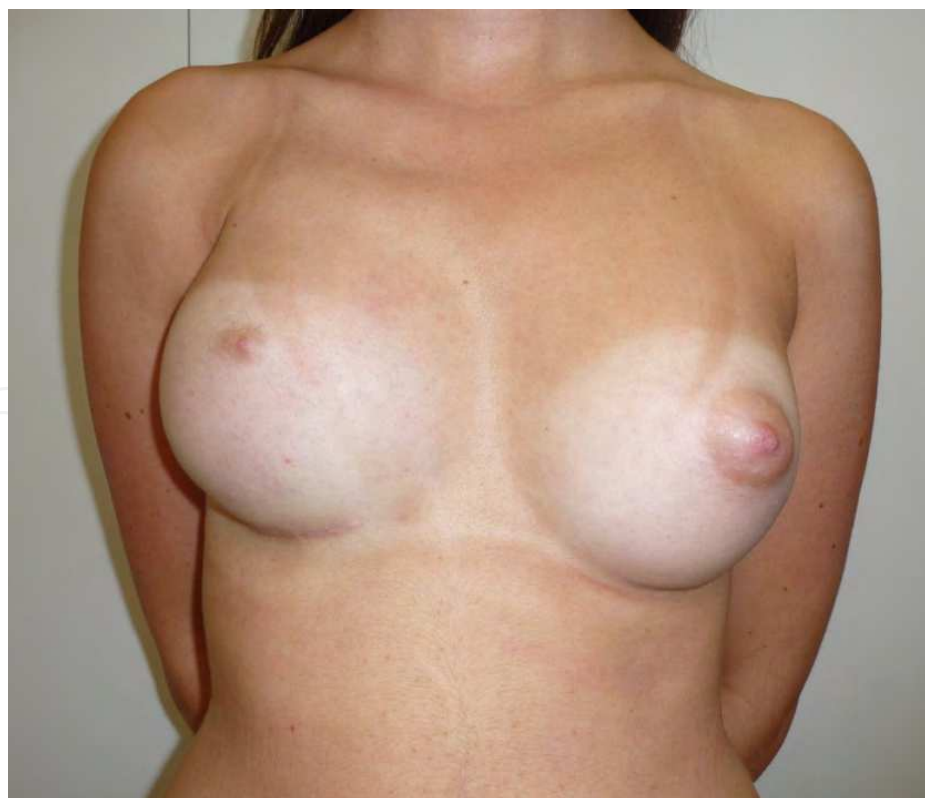

Fig. 10. Patient after omentum flap transposition to the right breast and bilateral breast augmentation with prosthesis.

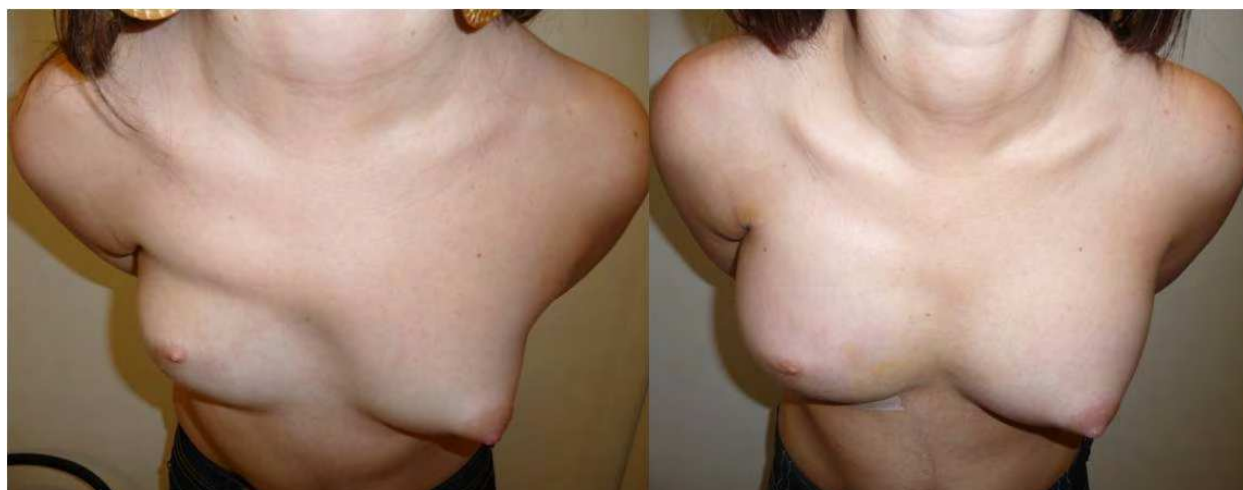

Fig. 11. A comparative view of the breasts.

3. Surgical technique

Harvesting of the omentum flap is performed using standard laparoscopic surgery techniques. Four ports are usually placed; CO₂ pneumoperitoneum of 8-10 mmHg is maintained during the procedure. Dissection of the flap is initiated by clamping and elevation of the gastric wall (Fig. 12). The right gastro-epiploic artery (RGEA) is isolated and preserved; ligations of the short gastric arteries along the greater curvature are then performed until the left gastro-epiploic artery (LGEA) is reached (Fig. 13). The omentum should be disconnected from the transverse colon by a carefully dissection in order to preserve the mesocolon vascularity (Fig. 14). The flap will be totally liberated when ligations of the LGEA are accomplished adjacent to the left colic flexure (Fig. 15).

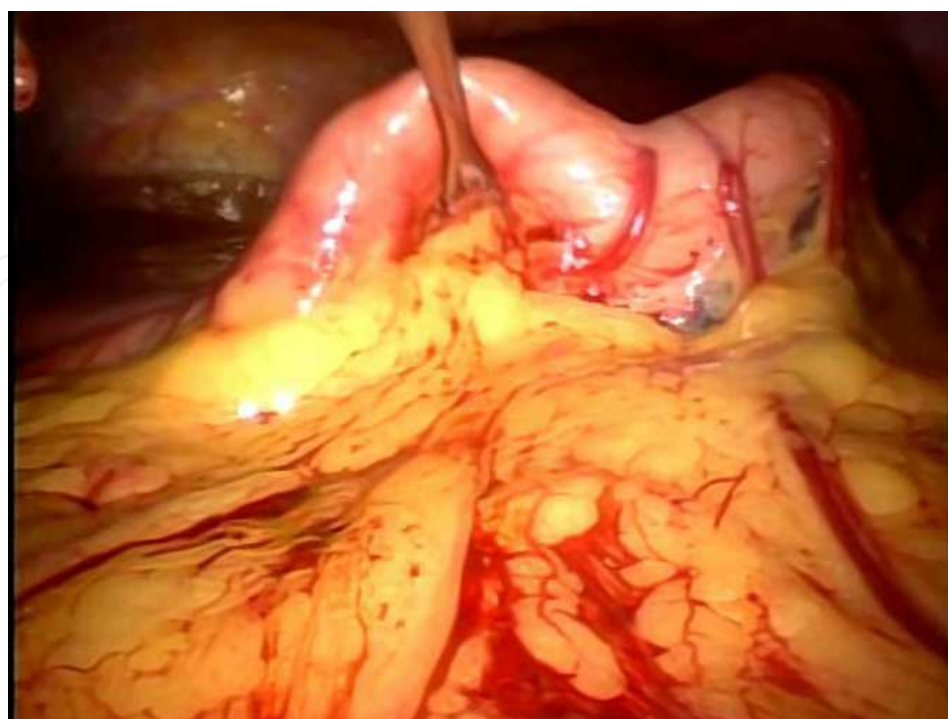


Fig. 12. Elevation of gastric wall.

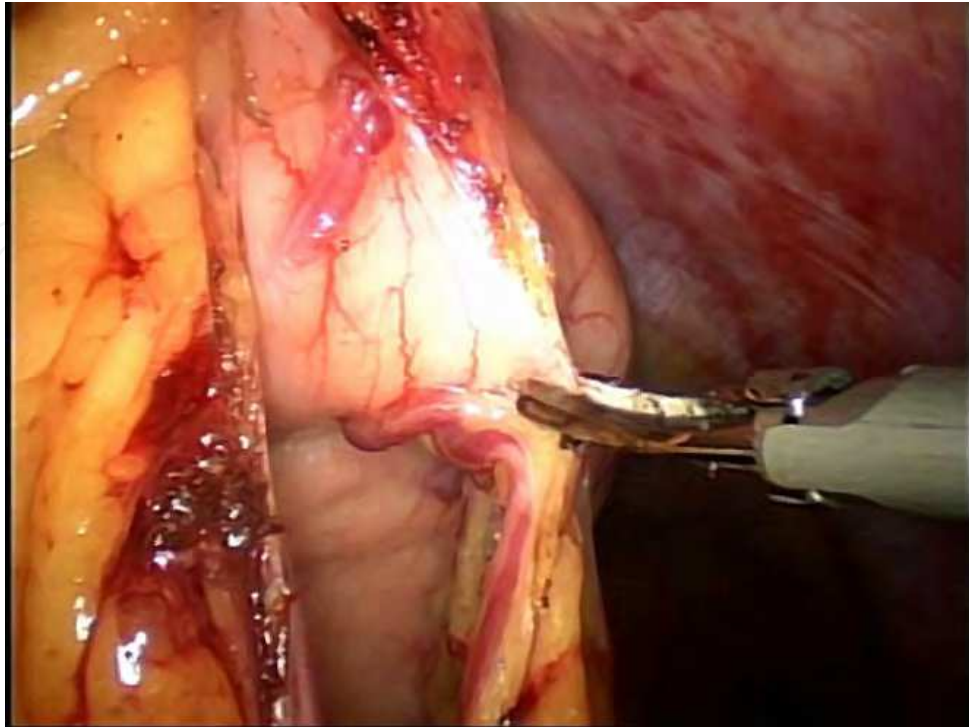


Fig. 13. Ligations of the short gastric arteries along the great gastric curvature showing the RGEA preserved.

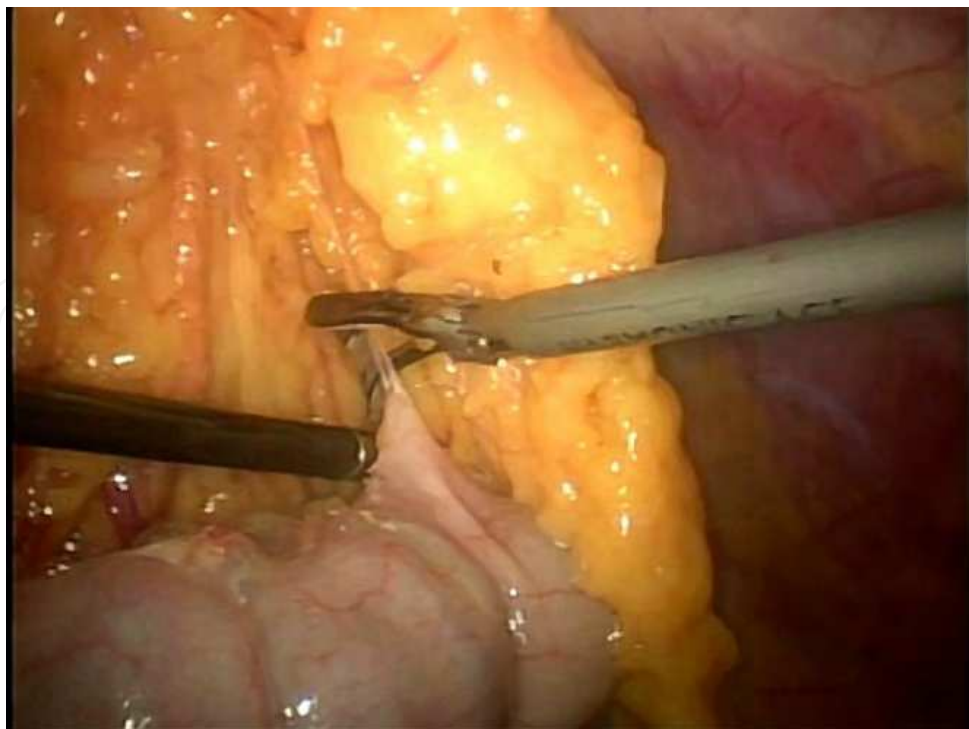


Fig. 14. Liberation of the colon segment of omentum attachment.

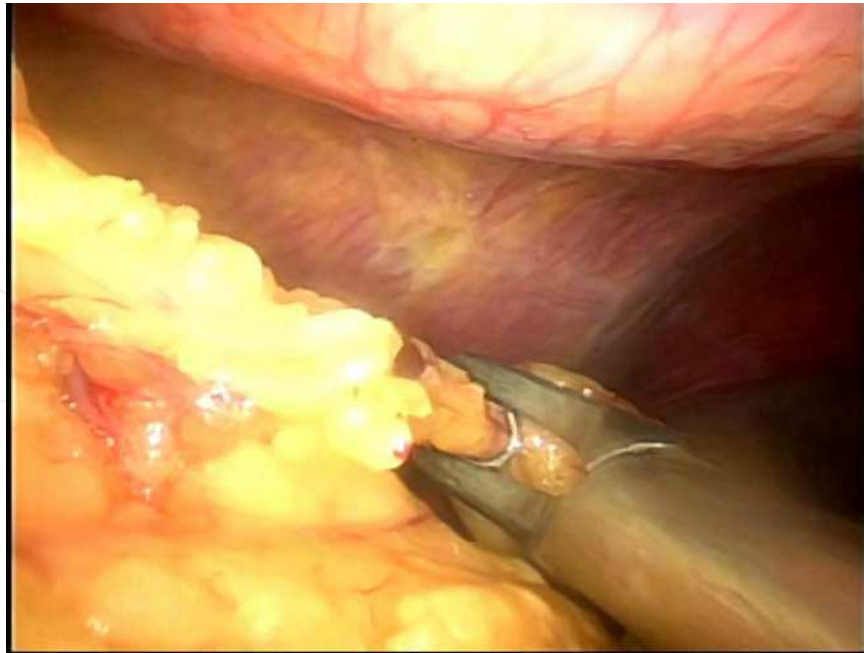


Fig. 15. Ligation of the LGEA.

Finally, through a small incision in the infra-mammary fold a subcutaneous tunnel is dissected until the costal border to open the aponeurose in the medial line, in the direction to the abdominal cavity (Fig. 16). With a digital maneuver the omentum is pulled from the abdominal cavity to the breast region to permit passage and placement of the flap over the specific thoracic wall region (Figs. 17-19). This tunnel is placed to the left or right side of the round ligament depending on the site that needs reconstruction. The location of the deformity is then dissected and filled in with the omentum flap, which is fixed into place. Both procedures are performed under video-assisted guidance.

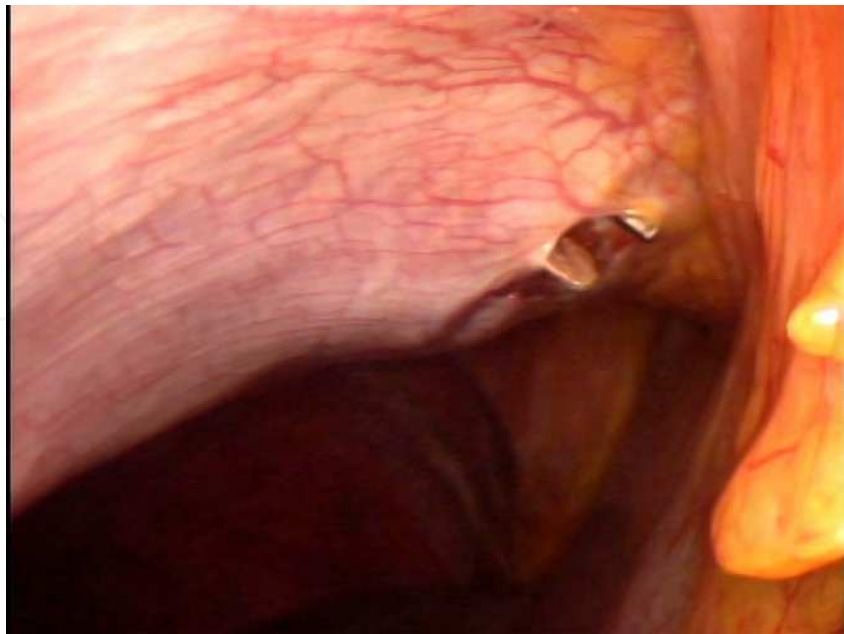


Fig. 16. Incision in the peritoneum to communicate the abdominal cavity with the breast region through a subcutaneous tunnel.

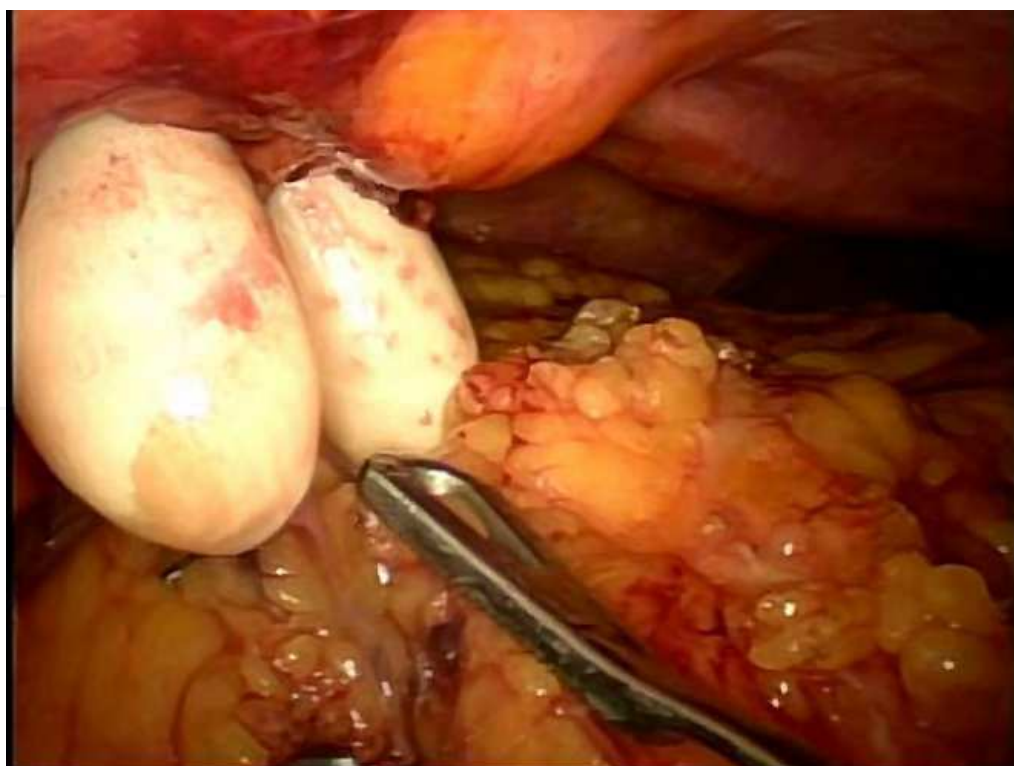


Fig. 17. Taking the omentum flap with finger maneuver to pull it from abdominal cavity to breast region.

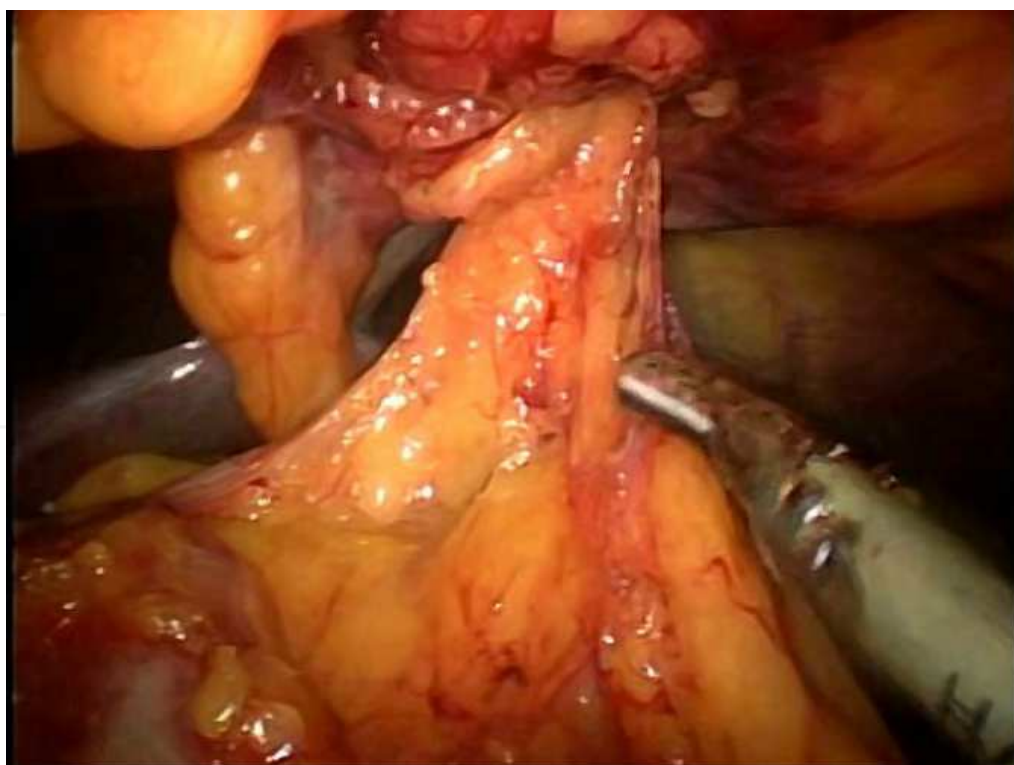

Fig. 18. Final position of the pedicle flap into the abdominal cavity.

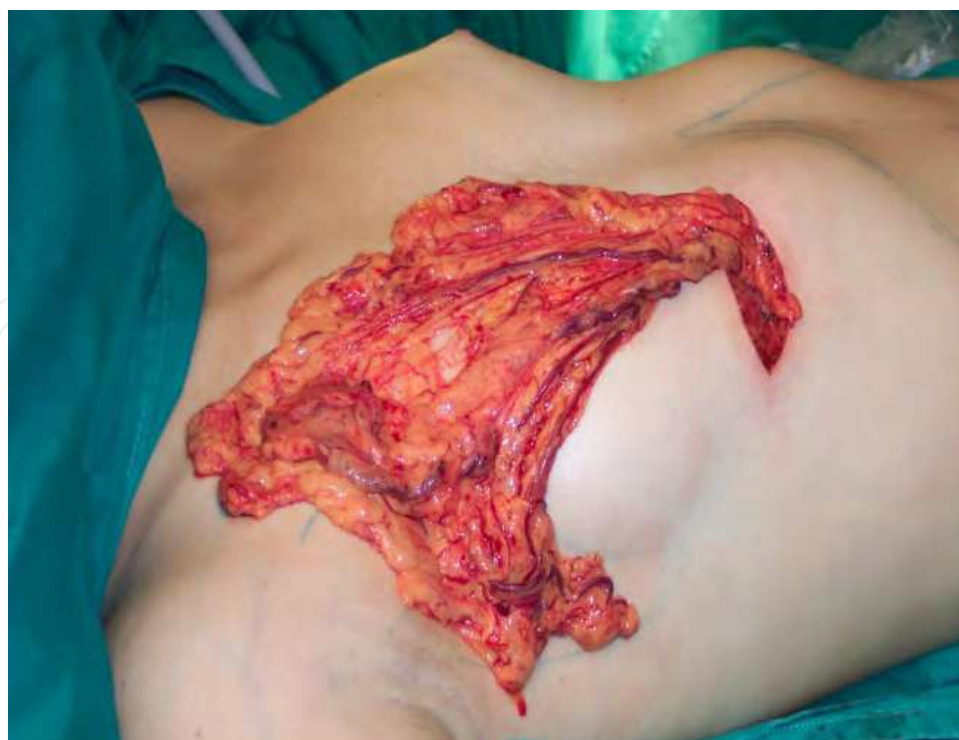

Fig. 19. Omentum flap upon thoracic wall.

4. Changes in the omentum flap after transposition

When laparoscopically harvested omentum flap was used to treat breast deformities, a significant volume increase of the omentum was noticed in the first months following its transposition in all the patients (Fig. 20 and 21).

The omentum is composed, predominantly, of mature adipocytes that do not have the capacity to multiply and that represent an important share of visceral fat in the human body. The omentum also has adult stem cells and progenitor cells or preadipocytes, which are smaller and able to differentiate (Fonseca-Alaniz et al, 2006).

The growth of the adipose tissue can be controlled by local vascularization. The degree of development of the adipocytes and of the vascular morphology is dependent on the volume of deposit of triglycerides whereas the size of the adipocytes does not depend on this volume of storage (Hausman & Richardson, 2004). When the supply of triglycerides for storage increases very much, preadipocytes may become mature adipocytes because the tissue needs storage room; thus, there will be hypertrophy and, then, hyperplasia. The increase in the bulk of adipocytes is accompanied by an increase in the microvascular net (Zhong et al, 2009) and, conversely, there is the need for an increase in neovascularization during the growth of adipose tissue. Evidence suggests that the O₂-sensitive signaling mechanism regulates adipogenesis (Lolmede et al, 2003). However, the differentiation of the preadipocyte is inhibited under hypoxic conditions, and, therefore, there would be only hypertrophy of the adipocytes and not hyperplasia (Frye et al, 2005).

The transposed omentum suffers hypoxia caused by a transitory ischemia. It causes a growth stimulation of VEGF (vascular endothelial growth factor) in the endothelial receptors that promotes neo-angiogenesis (Ignjatovic et al, 2001).

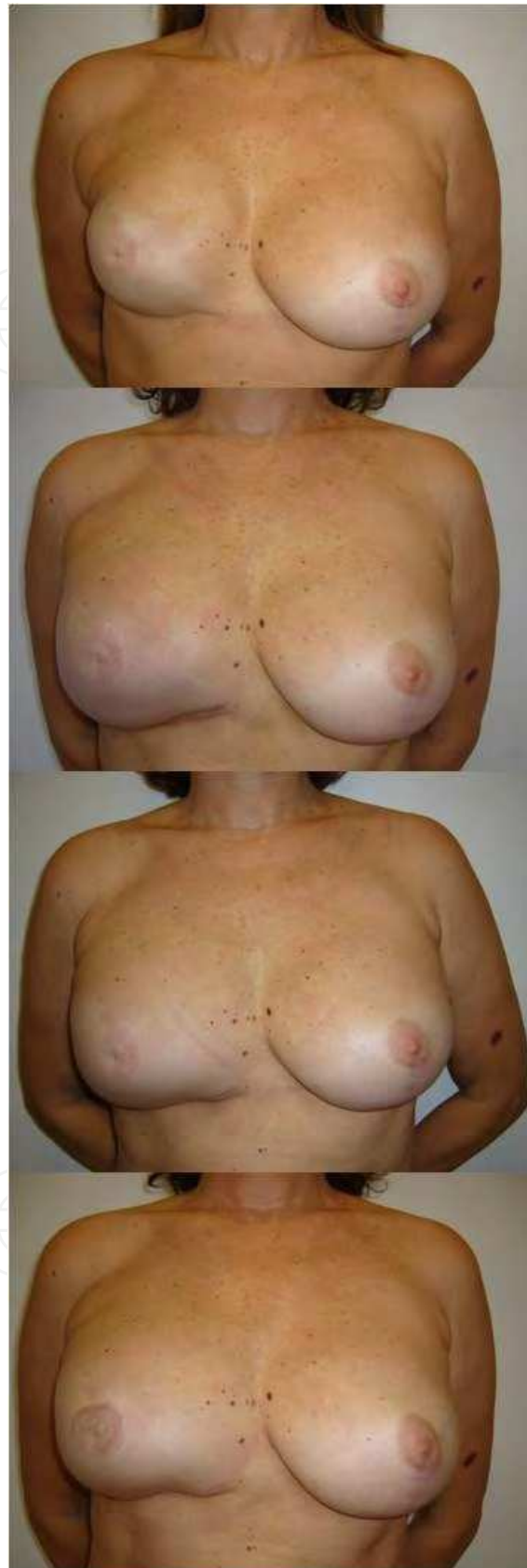

Fig. 20. Volume increase of the omentum in the first months following its transposition. Pre-operative and after 30, 60 and 100 days.

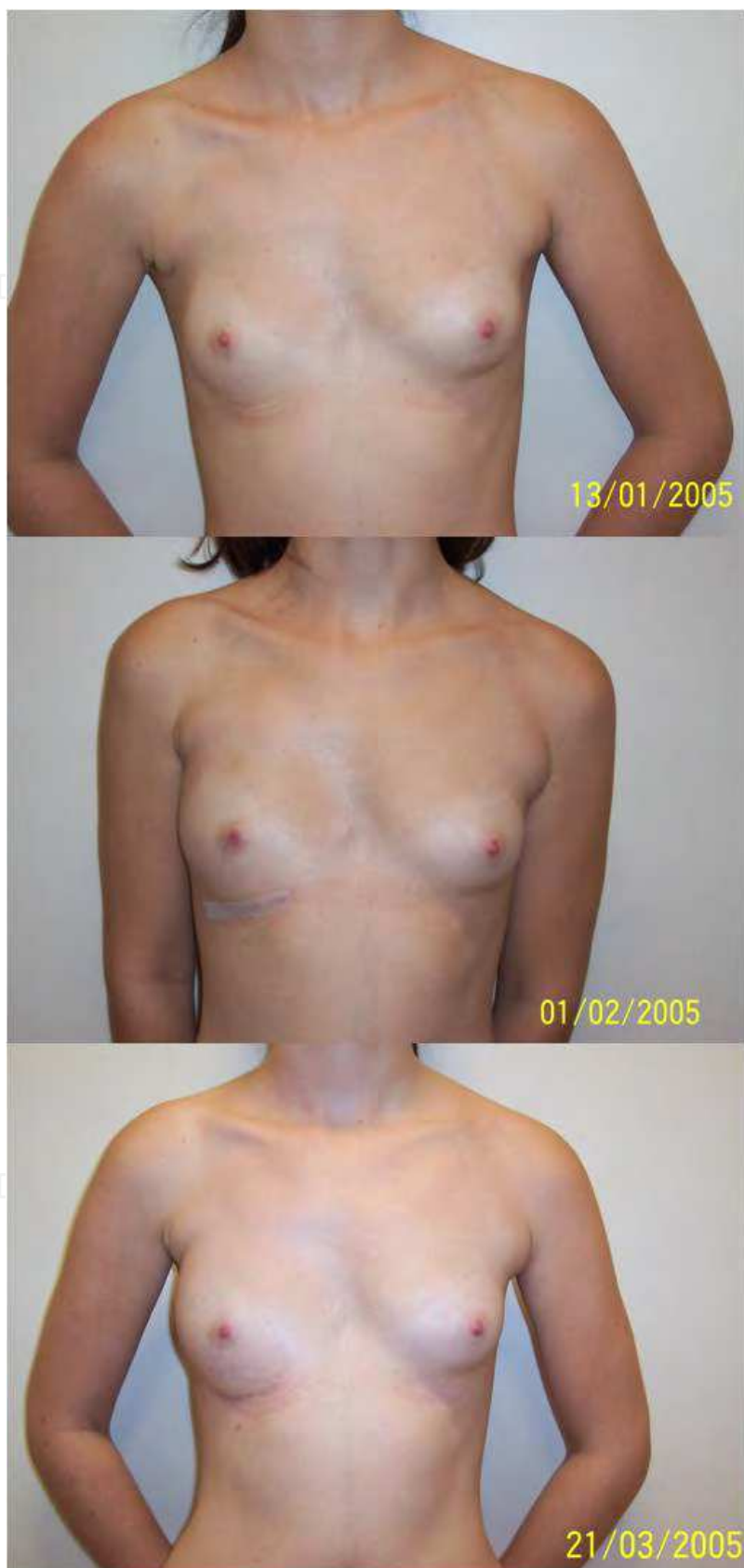

Fig. 21. Patient with Poland's syndrome in the right side showing the increase in volume of the omentum flap transposed to the right breast.

A high level of consistency is found in the literature so that we can safely use the measurement of VEGF, neoangiogenesis by the CD31(cluster of differentiation molecule) or PECAM-1 (Platelet Endothelial Cell Adhesion Molecule) and morphometric measurements of the adipocyte to investigate, clarify, and document the increase in postoperative volume of the omentum flap (Jernas et al, 2006; Fox & Harris, 2004).

In order to assess the nature of the apparent volume increase of the omentum when transposed to the breast, Costa et al studied patients that were treated with omentum flap. There was used the CD31 marker to do the measurement of angiogenesis as we do in cancer. The increase in the number of vessels in the second sample (Fig. 22) suggests neoangiogenesis stimulated by the initial increase in VEGF values documented in the first sample. The histological study of Costa, comparing the adipocyte size; before and after the omentum transposition, presented a significant statistical difference ($p < 0,001$) (Fig. 23). This difference ranged from a big to a very big effect. The confidence intervals of these effect sizes were always above moderate (Costa et al, 2011).

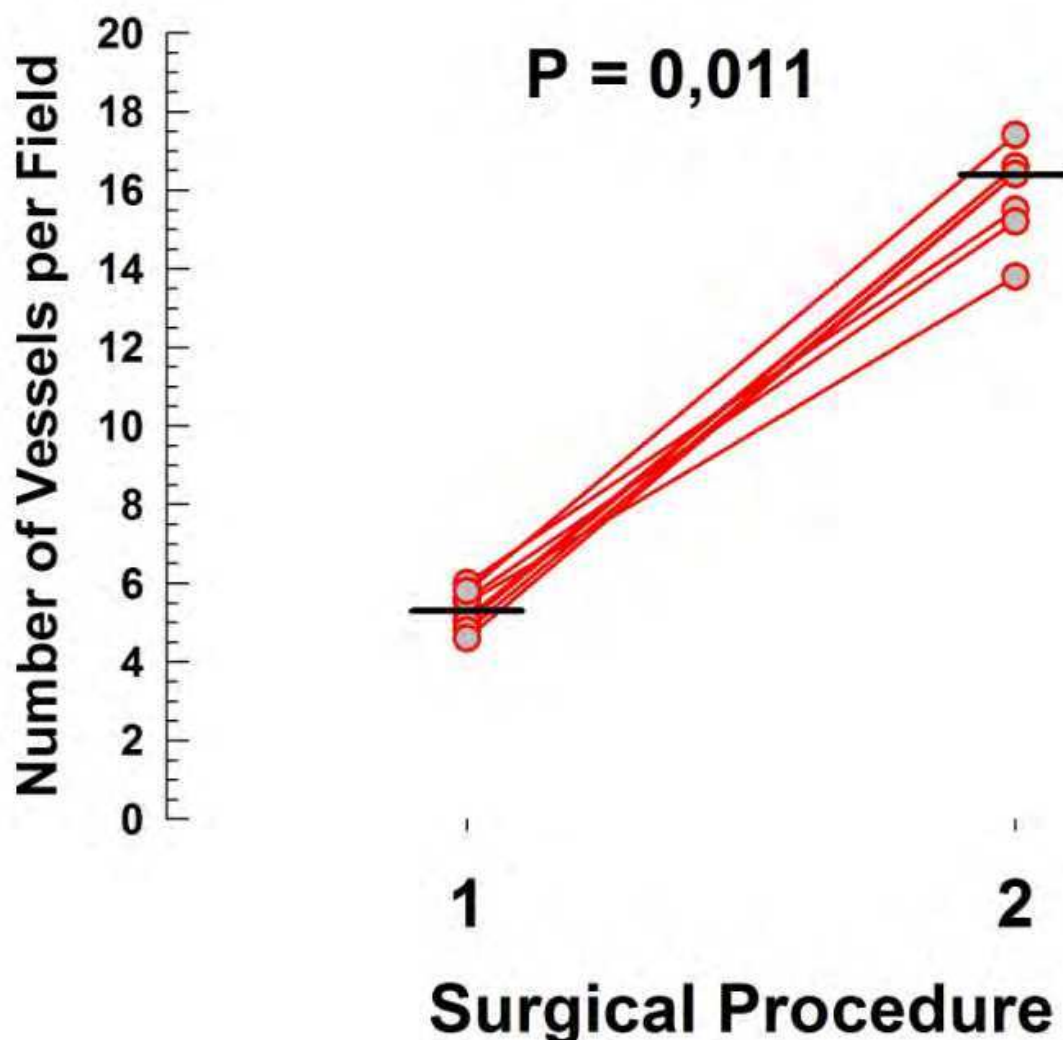


Fig. 22. Scoter plot with lines showing the variation of the number of vessels per field between surgical procedure 1 and 2. Short thick lines represent the series median values.

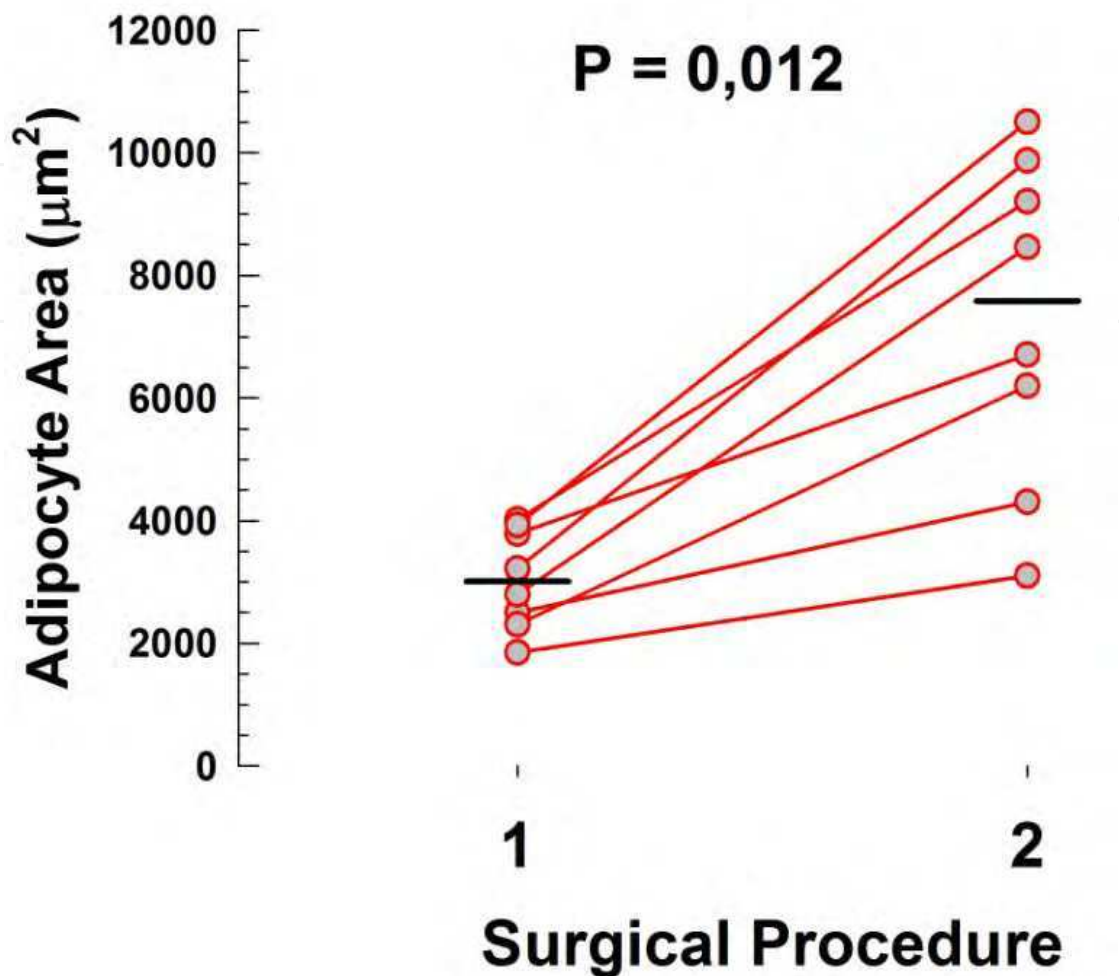


Fig. 23. Scoter plot with lines showing the variation of the adipocyte area between surgical procedure 1 and 2. Short thick lines represent the series median values.

5. Omentum flap versus adipocyte cells graft

Nowadays the use of adipocyte cells grafts can offers a possibility to treat small defects with good results, although it needs more than one surgical procedure even in small deformities. On the other hand, the omentum flap offers the possibility to restore a deformity in a single procedure without reabsorption of part of the volume transferred and even with a gain in the final volume after three or four months.

6. Conclusion

In conclusion, the employment of the omentum flap in the treatment of breast deformities enables reconstruction of the anterior axillary pillar as well as filling in of the infra-clavicular depression and provides volume and a soft coverage system that is thick enough to conceal silicone implants, a feature that no other technique seems able to achieve with so good aesthetic result.

7. Perspectives for the future

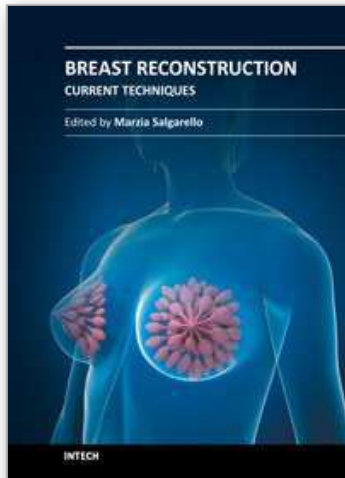
With the current knowledge regarding the new attributions and functions of the adipocytes and especially of the omentum cells, innumerable other indications of use of this tissue may arise in a near future. The omentum flap has great chances of becoming a rich source of material to correct and reconstruct segments or human organs unthinkable even today, but already exhaustively searched for by experimental medicine.

8. References

- Arnold, P.G.; Hartrampf, C.R. & Jurkiewicz, M.J. (1976). *One-stage reconstruction of the breast, using the transposed greater omentum. Case report.* *Plast Reconstr Surg.*; 57(4):520-2.
- Bainbridge, L.C.; Wright, A.R. & Kanthan, R. (1991). *Computed tomography in the preoperative assessment of Poland's syndrome.* *Br J Plast Surg*; 44(8):604-7.
- Cobben, J.M.; Robinson, P.H.; Van Essen, A.J.; Van der Wiel, H.L. & Ten Kate, L.P. (1989). *Poland anomaly in mother and daughter.* *Am J Med Genet*; 33(4):519-21
- Costa, S.S.; Pedrini, J.L.; Recamonde, A. & Penczek, F. (1998). *Tratamento cirúrgico da síndrome de Poland com omento transposto por Videolaparoscopia.* In: editors. XI Congresso Brasileiro de Mastologia. Foz do Iguaçu-Paraná: XI Congresso Brasileiro de Mastologia; p. 186.
- Costa, S.S.; Blotta, R.M.; Mariano, M.B.; Meurer, L. & Edelweiss, M.I.A. (2010) *Aesthetic Improvements in Poland's Syndrome Treatment with Omentum Flap.* *Aesth Plast Surg*:1-6, April 24.
- Costa, S.S.; Blotta, R.M.; Mariano, M.B.; Meurer, L. & Edelweiss, M.I.A. (2010). *Laparoscopic treatment of Poland's syndrome using the omentum flap technique.* *Clinics*; vol.65 no.4 São Paulo.
- Costa, S.S.; Blotta, R.M.; Meurer, L. & Edelweiss, M.I.A (2011). *Adipocyte morphometric evaluation and angiogenesis in the omentum transposed to the breast: a preliminary study.* *Clinics (Sao Paulo)*. February; 66(2): 307–312.
- Cothier-Savey, I.; Tamtawi, B.; Dohnt, F.; Raulo, Y. & Baruch, J. (2001) *Immediate breast reconstruction using a laparoscopically harvested omental flap.* *Plast Reconstr Surg*;15;107(5):1156-63; discussion 64-5.
- Das, S.K. (1976). *The size of the human omentum and methods of lengthening it for transplantation.* *Br J Plast Surg*; 29(2):170-44.
- Ferron, G.; Garrido, I.; Martel, P.; Gesson-Paute, A.; Classe, J.M. & Letourneur, B. (2007). *Combined laparoscopically harvested omental flap with meshed skin grafts and vacuum-assisted closure for reconstruction of complex chest wall defects.* *Ann Plast Surg*; 58(2):150-5.
- Fonseca-Alaniz, M.H.; Takada, J.; Alonso-Vale, M.I. & Lima, F.B. (2006). *[The adipose tissue as a regulatory center of the metabolism].* *Arq Bras Endocrinol Metabol*;50:216-29.
- Fox, S.B. & Harris, A.L. (2004). *Histological quantitation of tumour angiogenesis.* *APMIS*;112:413-30.
- Frye, C.A.; Wu, X. & Patrick, C.W. (2005). *Microvascular endothelial cells sustain preadipocyte viability under hypoxic conditions.* *In Vitro Cell Dev Biol Anim*;41:160-4.
- Hausman, G.J. & Richardson, R.L. (2004) *Adipose tissue angiogenesis.* *J Anim Sci*;82:925-34.
- Ignjatovic, M.; Pervulov, S.; Cuk, V.; Kostic, Z. & Minic, L. (2001) *Early angiogenic capabilities of the transposed omental flap after omentomyelopexy.* *Acta Chirf Iugosl*;48(2):41-3.

- Irons, G.B.; Witzke, D.J.; Arnold, P.G. & Wood, M.B. (1983). *Use of the omental free flap for soft-tissue reconstruction*. *Ann Plast Surg*;11(6):501-7.
- Jernas, M.; Palming, J. & Sjöholm, K. (2006). *Separation of human adipocytes by size: hypertrophic fat cells display distinct gene expression*. *FASEB J*;20:1540-2.
- Kiricuta, I. (1963). [*The use of the great omentum in the surgery of breast cancer.*]. *Presse Med*; 5;71:15-7.
- Lolmede, K.; Durand de Saint Front, V.; Galitzky, J.; Lafontan, M. & Bouloumie, A. (2003) *Effects of hypoxia on the expression of proangiogenic factors in differentiated 3T3-F442A adipocytes*. *Int J Obes Relat Metab Disord*;27:1187-95.
- McLean, D.H. & Buncke, H.J. (1972). *Autotransplant of omentum to a large scalp defect, with microsurgical revascularization*. *Plast Reconstr Surg*; 49(3):268-74.
- Perez Aznar, J.M.; Urbano, J.; Garcia Laborda, E.; Quevedo Moreno, P. & Ferrer Vergara, L. (1996) *Breast and pectoralis muscle hypoplasia. A mild degree of Poland's syndrome*. *Acta Radiol*; 37(5):759-62.
- Saltz, R.; Stowers, R.; Smith, M. & Gadacz, T.R. (1993). *Laparoscopically harvested omental free flap to cover a large soft tissue defect*. *Ann Surg*;217(5):542-6; discussion 6-7.
- Seyfer, A.E.; Icochea, R. & Graeber GM. (1988). *Poland's anomaly. Natural history and long-term results of chest wall reconstruction in 33 patients*. *Ann Surg*; 208(6):776-82.
- Zaha, H.; Inamine, S.; Naito, T. & Nomura, H. (2006). *Laparoscopically harvested omental flap for immediate breast reconstruction*. *Am J Surg*;192(4):556-8.
- Zhong, X.; Yan, W.; He, X. & Ni, Y. (2009). *Improved fat graft viability by delayed fat flap with ischaemic pretreatment*. *J Plast Reconstr Aesthet Surg*;62:526-31.

IntechOpen



Breast Reconstruction - Current Techniques

Edited by Prof. Marzia Salgarello

ISBN 978-953-307-982-0

Hard cover, 276 pages

Publisher InTech

Published online 03, February, 2012

Published in print edition February, 2012

Breast reconstruction is a fascinating and complex field which combines reconstructive and aesthetic principles in the search for the best results possible. The goal of breast reconstruction is to restore the appearance of the breast and to improve a woman's psychological health after cancer treatment. Successful breast reconstruction requires a clear understanding of reconstructive operative techniques and a thorough knowledge of breast aesthetic principles. Edited by Marzia Salgarello, and including contributions from respected reconstructive breast plastic surgeons from around the world, this book focuses on the main current techniques in breast reconstruction and also gives some insight into specific topics. The text consists of five sections, of which the first focuses on the oncologic aspect of breast reconstruction. Section two covers prosthetic breast reconstruction, section three is dedicated to autogenous breast reconstruction, and section four analyzes breast reconstruction with a fat graft. Finally, section five covers the current approaches to breast reshaping after conservative treatment.

How to reference

In order to correctly reference this scholarly work, feel free to copy and paste the following:

Sirlei dos Santos Costa and Rosa Maria Blotta (2012). The Omentum Flap, Breast Reconstruction - Current Techniques, Prof. Marzia Salgarello (Ed.), ISBN: 978-953-307-982-0, InTech, Available from: <http://www.intechopen.com/books/breast-reconstruction-current-techniques/the-omentum-flap>

INTECH
open science | open minds

InTech Europe

University Campus STeP Ri
Slavka Krautzeka 83/A
51000 Rijeka, Croatia
Phone: +385 (51) 770 447
Fax: +385 (51) 686 166
www.intechopen.com

InTech China

Unit 405, Office Block, Hotel Equatorial Shanghai
No.65, Yan An Road (West), Shanghai, 200040, China
中国上海市延安西路65号上海国际贵都大饭店办公楼405单元
Phone: +86-21-62489820
Fax: +86-21-62489821