

We are IntechOpen, the world's leading publisher of Open Access books Built by scientists, for scientists

4,400

Open access books available

118,000

International authors and editors

130M

Downloads

Our authors are among the

154

Countries delivered to

TOP 1%

most cited scientists

12.2%

Contributors from top 500 universities



WEB OF SCIENCE™

Selection of our books indexed in the Book Citation Index
in Web of Science™ Core Collection (BKCI)

Interested in publishing with us?
Contact book.department@intechopen.com

Numbers displayed above are based on latest data collected.
For more information visit www.intechopen.com



Hip Arthroplasty in Highly Dislocated Hips

Zoran Bascarevic^{1,2}, Zoran Vukasinovic^{1,2},
Violeta Bascarevic² and Vladimir Bascarevic^{1,3}

¹Faculty of Medicine, University of Belgrade, Belgrade

²Institute of Orthopaedic Surgery „Banjica“, Belgrade

³Institute of Neurosurgery, Clinical Center of Serbia, Belgrade
Serbia

1. Introduction

Developmental disorder of the hip (DDH) is the most frequent disease of this joint. It is manifested by dysplasia, subluxation or luxation in childhood period and arthrosis in adults. Early degenerative changes of the hip occur at the location of disordered anatomy and biomechanics already in youth, while in the childhood age they are mostly asymptomatic (Ando & Gotoh, 1990).

DDH mostly occurs in females, even 4-10 times more often than in males. Also, the disease is unevenly expanded, both ethnically and geographically, but also according to different habits in regard to the nursing care of neonates and infants. For example, the disease does not develop among the Bantu colored population, while in Canadian Indians it is very frequent rating even 12.3%, which is related to their habit of nursing babies in narrow wooden cradles. In those Indians who do not practice it the frequency is considerably lower (1.2%) (Vukasinovic et al., 1994, 2004).

In our regions data on the frequency of DDH vary between 0.5-34.8%, depending on the regional customs in nursing children, but also on the method applied in the diagnostics of the disease; clinically it is the lowest, radiographically higher, and ultrasonographically the highest (Klasic et al., 1984). Former classical term of the disease was “congenital dislocation of the hip”, which, over the years became unsustainable, since it has been disclosed that the disease is not congenital, but that it often develops after birth under the influence of environmental factors. In addition, it does not always involve a total dislocation, but only disturbed interrelationship among the joint surfaces of the hip. Although the former term can be still found in the literature, today the term “developmental disorder of the hip” is accepted worldwide (Klasic, 1989).

2. Etiopathogenesis and pathoanatomy of DDH

To understand the problem faced by the arthroplastic surgeon in treating a high luxation of the hip in adults, it is necessary to be acquainted with etiopathogenesis of the disease, because it is in a direct association with its pathoanatomic substrate.

After numerous years of research, attitudes of the leading world experts on this disease have been mostly brought in accordance (Ando & Gotoh 1990; Cherney & Westin 1989; Klasic et al. 1984, 1989; Vukasinovic & Bascarevic, 2004).

There is the predominating opinion that two groups of etiological factors contribute to the development of DDH; endogenous and exogenous (mechanical). (Vukasinovic & Djoric, 1994; Vukasinovic & Bascarevic, 2004).

Endogenous factors involve acetabular dysplasia, increased anteversion of the femoral neck and head, as well as joint laxity. Beside primary acetabular dysplasia, which is one of the causes of the disease, the so called secondary acetabular dysplasia is also mentioned, which develops due to hip dislocation itself. Although a lax joint capsule can be generalized, as for example when associated with Ehlers-Danlos syndrome, in DDH it is mostly only elongated in the superior-posterior portion, thus secondary, caused by luxation instead of being its major cause. (Vukasinovic & Djoric, 1994; Vukasinovic & Bascarevic, 2004).

Exogenous (mechanical) factors involve the basis of the so called mechanical theory which has been obtaining a rising number of supporters as it can explain the frequency of luxations in first pregnancies, pelvic positions, Cesarean section, high birth weight, oligohydramnion and fetopelvic disproportion. In addition, hip luxation due to DDH is often associated with other deformities of the feet, knees, neck (torticollis) and other. (Vukasinovic & Djoric, 1994; Vukasinovic & Bascarevic, 2004).

Exogenous (mechanical) factors can affect the fetus intrauterine, during delivery and postnatally. The intrauterine factors mostly involve three luxating fetal positions, while the postnatal ones above all refer to traditional baby diapering with bent knees and extended legs. Not only can such a position induce a spontaneous reduction of unstable joint, but it can also provoke the development of luxation. The mechanical factors occurring during birth can be discarded today, because even in newborns the hips are so stable that rough manual manipulation will sooner cause femoral head epiphyseal fracture than hip luxation. It is considered that action of two factors is necessary for DDH to develop; a specific position of the femur involving the head which is not orientated toward the base of the acetabulum and expulsion force pushing the baby's head out of the acetabulum. (Vukasinovic & Djoric, 1994; Vukasinovic & Bascarevic, 2004).

In short, DDH pathogenesis features the following: a predisposing base representing unstable genetic factors, above all acetabular dysplasia and capsular laxity, while the determinant mechanical factors exert pressure on the great trochanter in one of the luxating fetal positions. This can explain the growing incidence of bilateral luxations in pelvic births; forces act on both great trochanters, i.e. isolated left-sided luxations in normal birth (baby head down presentation with left turned back); the maternal promontorium exerting pressure on the great trochanter. (Vukasinovic & Djoric, 1994; Vukasinovic & Bascarevic, 2004).

Pathological changes involve all structures of the joint, while the pathoanatomical substrate differs depending on the degree of disorder.

The acetabulum changes in depth during physiological development becoming the shallowest in the perinatal period. Spherical formation (joint congruency) is caused by the presence and pressure of the femoral head. In DDH unfavorable intra-articular relationships lead to acetabular anterior and superior deficiency, as well as its anteversion. Consequently, the acetabulum becomes ovoid or even triangle-like insufficiently covering the femoral head. It is mostly dilated, but can be also completely undeveloped, narrowed due to the lack of

developmental stimulation caused by the absent head in the joint. (Vukasinovic & Djoric, 1994; Bascarevic & Vukasinovic, 2004).

The limbus gradually flattens and thickens first in the superoposterior portion. Gradually, a groove is formed enabling the head to slide out of the joint. It is partially grown together with the capsule and is lacking in some areas. In subluxations it is everted, while in full luxations it is inverted and interpolated between the head and the acetabulum. (Vukasinovic & Djoric, 1994; Bascarevic & Vukasinovic, 2004).

The ligamentum teres differs depending on the severity of disorder ranging from normal and occasionally hypoplastic, elongated and hypertrophic, up to fully atrophic in luxations.

The femoral head can be differently formed, from normal - spherical to flattened and deformed with limbal impression. It is most often decreased with highly expressed fovea. (Vukasinovic & Djoric, 1994; Bascarevic & Vukasinovic, 2004).

The femoral neck is usually shortened with increased anteversion. However, it can even be normal, but also retroverted. The collo-diaphyseal angle is usually normal, but can be also decreased or conversely increased.

The capsule of the joint is thickened and mostly lax, but can be also tightened. With the progression of luxation, it becomes lengthened and narrowed in the empty space between the head and the acetabulum resuming the form of a sand-clock. It grows adhering to the bones that form the acetabulum, thus impeding reduction. (Vukasinovic & Djoric, 1994; Bascarevic & Vukasinovic, 2004).

The ligamentum transversum is most frequently strong and thickened and additionally narrows the already dysplastic acetabulum. Its position is the only constant one in the pathological anatomy of the hip in high luxations and represents the major and occasionally the only orientation point in the attempt to find the true acetabulum in the total arthroplasty of the hip. (Bascarevic & Vukasinovic, 2004).

Muscular motion starters are also changed, particularly the iliopsoas; its tendon is short and thickened, while short external rotators are hypotrophic, but also shortened. However, the major hip abductors, primarily the gluteus medius, although hypotrophic, are not shortened and do not create resistance before reduction. In addition, after arthroplasty and induction of the necessary muscular length (close to physiological) they show unusual vitality in the restitution of strength and function of joints. (Vukasinovic & Djoric, 1994; Bascarevic & Vukasinovic, 2004).

Finally, when we speak of high luxations of the hip in the light of aloarthroplasty, attention should be turned to the fact that DDH is not the only condition causing high luxation of the hip in adults. Hip trauma, juvenile rheumatism, neonatal sepsis and some other similar conditions can also cause established hip luxation that can be resolved only when treated by a total hip arthroplasty (Besset et al., 2003; Betz et al., 1990; Choi et al., 1990; Learmonth et al., 1989; Maric & Haynes 1993; Ruddlesdin et al., 1986; Young-Hoo et al., 2009).

3. Classification of high hip dislocation in adults

In the literature there are several classifications that determine high hip dislocation in adults. **Crowe** classification of hip dislocation describes four stages, depending on the

position of the femoral head within the joint. The first three stages define the progressive migration of the head to the level of subluxation, while the fourth stage is luxation (Crowe et al., 1979).

According to the classification by **Eftekhar** the problem of the developmental disorders of the hip is viewed through acetabular changes. Four stages are also described; A/ slightly widened and dysplastic acetabulum with milder deformation of the head, B/ intermediately positioned false acetabulum, C/ high position of the false acetabulum, and D/ high non-weight bearing dislocation with the femoral head that has never been in contact with the iliac bone (Eftekhar 1978).

The most modern and up-to-now the best classification recommending total arthroplasty in relation to joint deficiency was given by **Hartofilakidis** et al. in 1996, according to which the condition was viewed as acetabular dysplasia, low dislocation and high dislocation (Hartofilakidis et al., 1996).

4. Treatment of high hip dislocation in adults

Treatment of the developmental disorder of the hip should be initiated at the moment of the disease detection, and the best results are achieved in the earliest childhood. At that period various forms of non-operative and operative treatments by biological surgeries are possible to be applied. (Vukasinovic & Djoric, 1994; Vukasinovic & Bascarevic, 2004). However, if the treatment is initiated only after the onset of arthrosis or under the conditions of high non-weight bearing hip luxation, operative treatment modalities are only reduced to total hip arthroplasty.

The operative procedure is most challenging because of changed anatomical correlations. The topographic correlation of muscles initiators of the hip, joint capsule and neurovascular elements are changed and unstable thus making the operative approach very difficult. The identification of bone structures, primarily of the true acetabulum, is also not at all easy (Lai et al., 1996, 2005; Charnley & Feagin 1973; Crowe et al., 1979; Dunn & Hess, 1976; Eskelinen et al., 2006; Hartofilakidis et al., 1998, 2004, 2008; Holinka et al., 2010; Paavilainen et al., 1990).

The ligamentum transversum is the only reliable parameter determining, not only the height and center of the artificial hip, but also the anteversion (flexion) position of the acetabular ring.

The proximal part of the femoral bone canal is very narrow, with markedly increased anteversion. The acetabular bone mass is underdeveloped, while the bone is insufficiently firm. The joint capsule is elongated, inelastic and thickened, while the surrounding muscles are without any strength, shortened and grown to the capsule. The neurovascular structures are shortened and dislocated from their anatomic positions (Carrlson et al., 2003; Holinka et al., 2010; Paavilainen et al., 1990).

In the past there were numerous unsuccessful attempts to perform total hip arthroplasty in adults at the location of high luxation caused by developmental disorder. Exactly due to excessively changed anatomic characteristics of the acetabulum and proximal femur, the operative procedure and the entire surgical concept are most complicated. Therefore, some authors consider high hip luxation as a contraindication for total arthroplasty (Figs. 1, 2, 3).

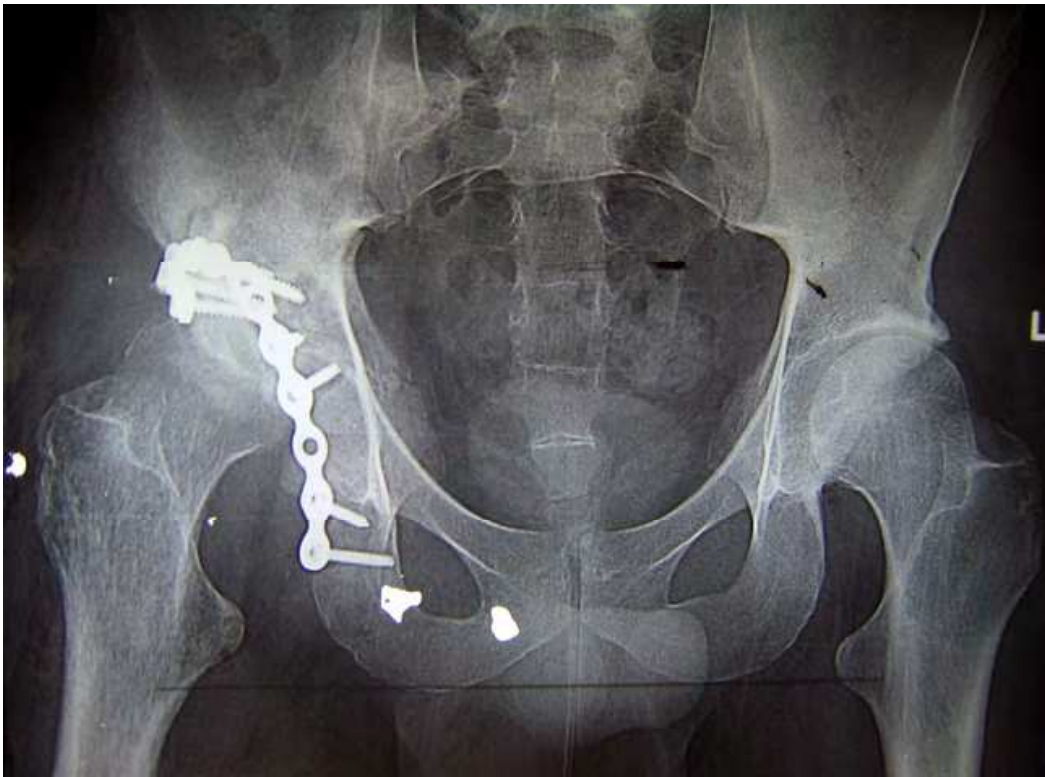

Fig. 1a. A 35-year old male after acetabular osteosynthesis performed due to traumatic dislocation of the right hip with superior and posterior acetabular wall fracture.

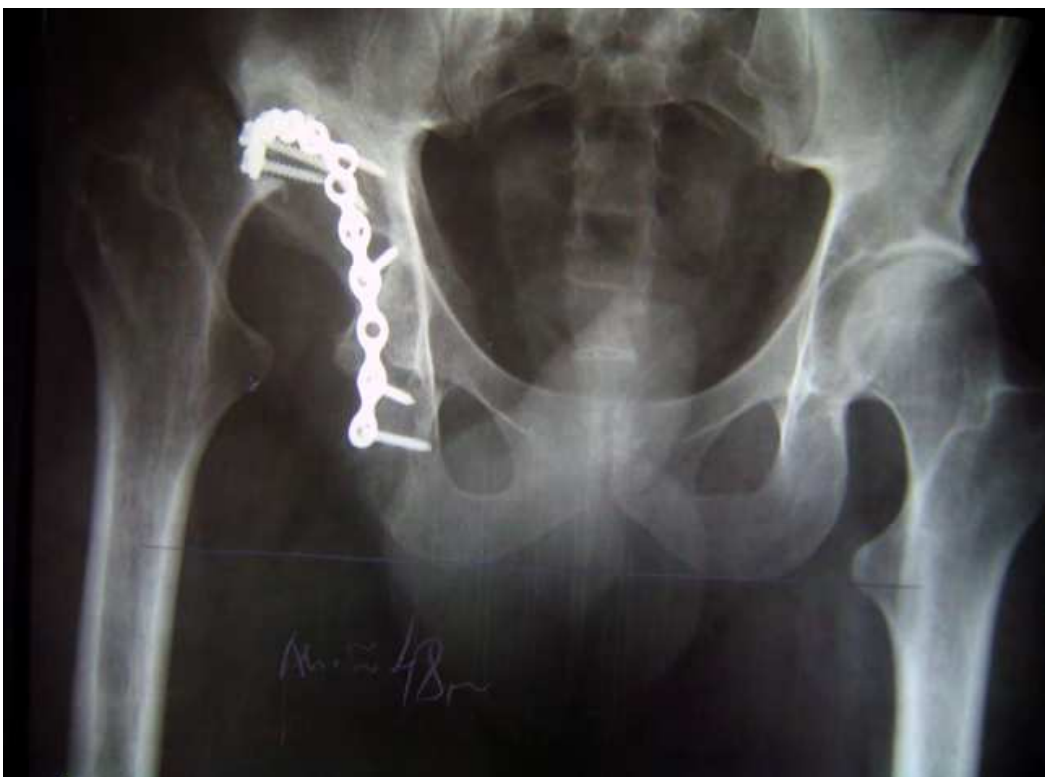

Fig. 1b. The same patient, six months later high dislocation of the hip occurred due to failed osteosynthesis. Full absence of superior and posterior acetabular walls. Leg length discrepancy was 48 mm.

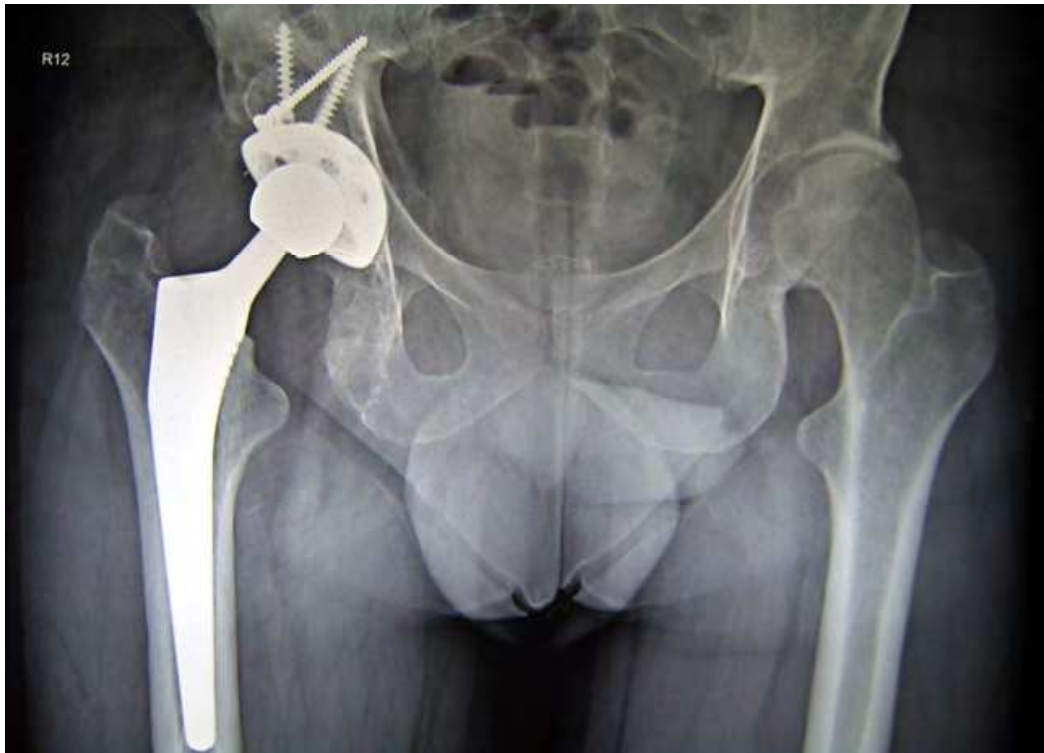


Fig. 1c. The same patient, three months after total arthroplasty of the hip, with the osteoplasty of the superior and posterior acetabular walls by solitary bone grafts from the bone bank. Restitution of leg length by positioning the acetabular component into the physiological hip rotation center.

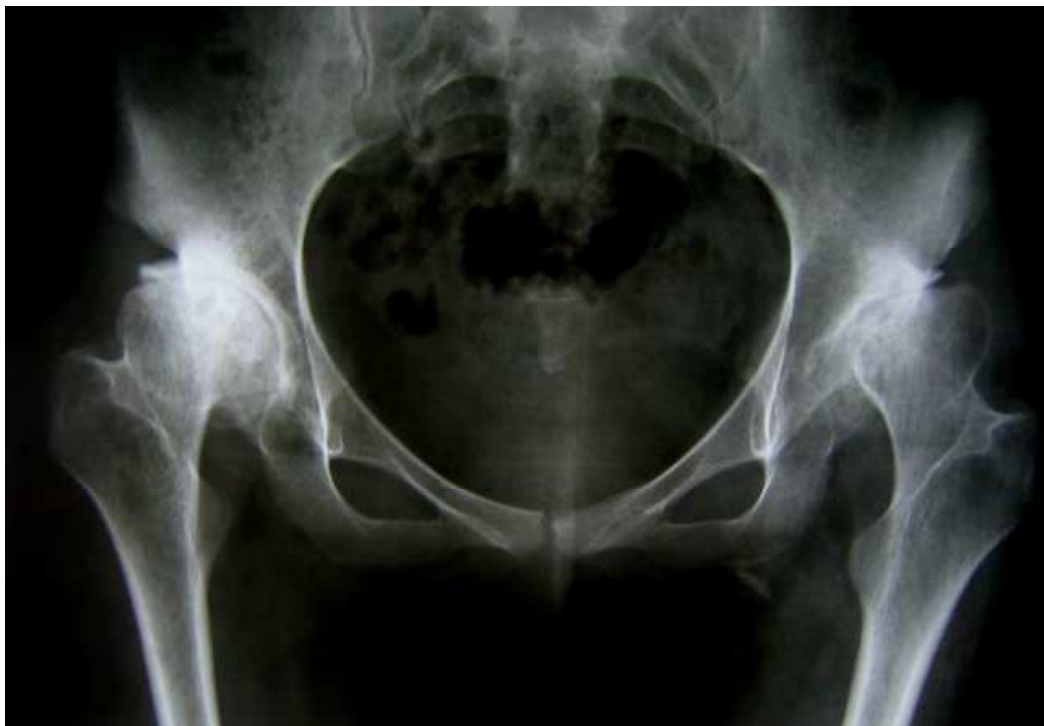

Fig. 2a. A 20-year old female with bilateral secondary arthrosis of the hips due to juvenile rheumatoid arthritis. Bilateral hip subluxation with various disorders of collo-diaphyseal femoral angle.

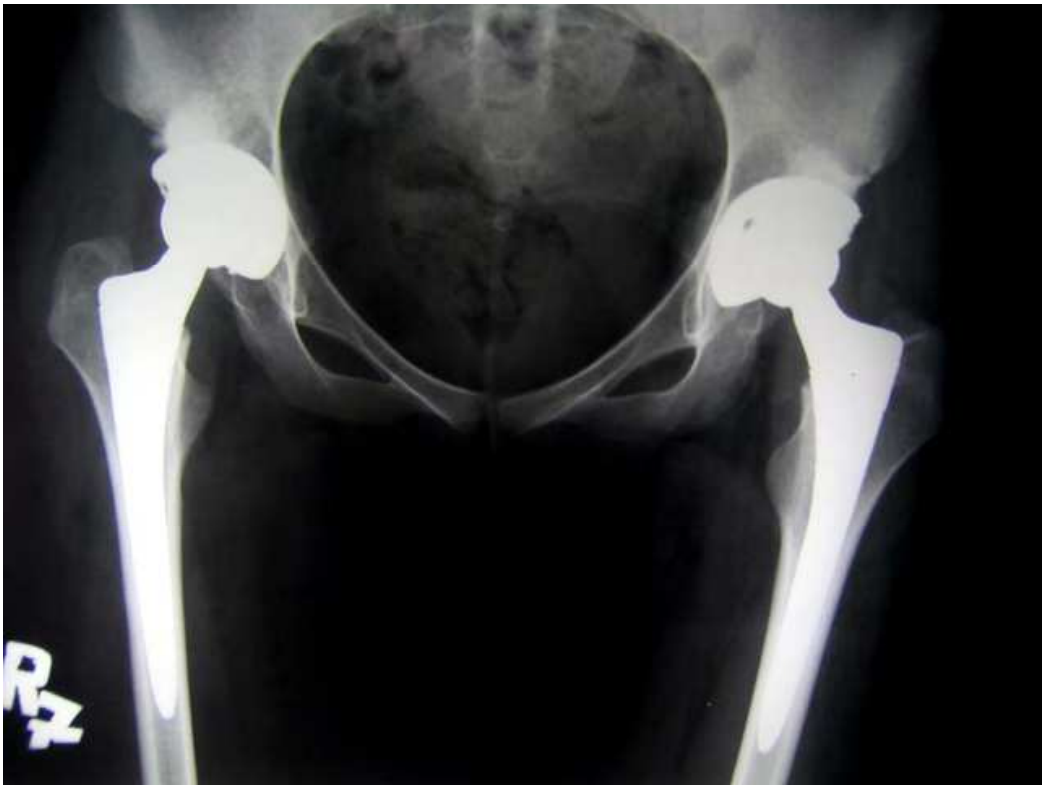

Fig. 2b. The same patient, one year after bilateral total arthroplasty of the hip with restitution of rotation centers.

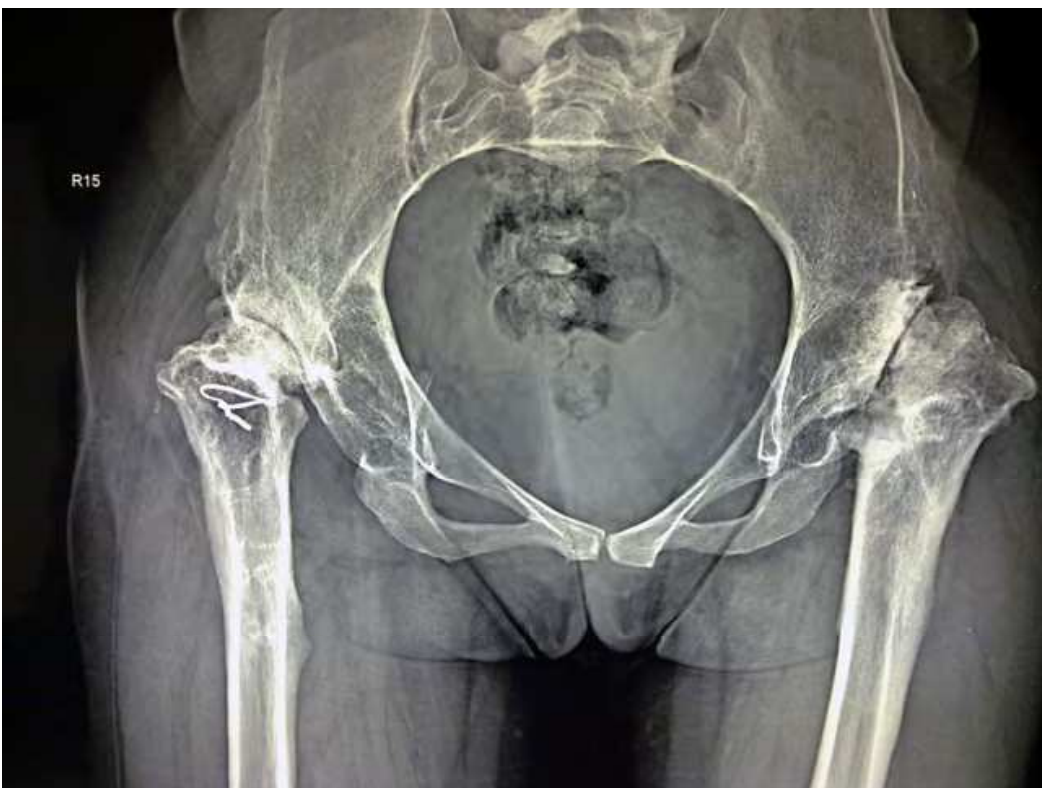

Fig. 3a. A 30-year old female with bilateral high dislocation of the hips after multiple surgeries due to neonatal sepsis.

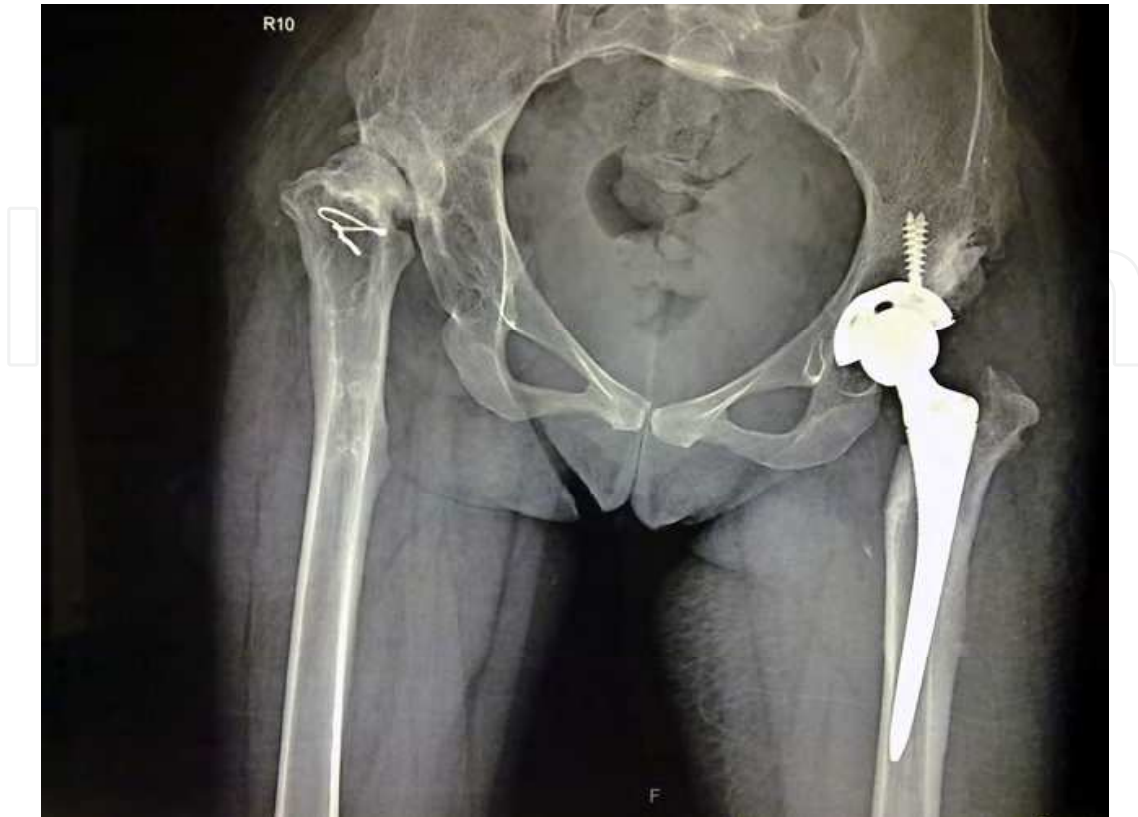


Fig. 3b. The same patient, one month after total arthroplasty of the left hip with restitution of rotation centers. The leg length equality is expected after the operation of the opposite hip.

4.1 Surgical procedures

The literature reports many operative techniques for total arthroplasty of the hip in patients with high dislocation. All agree on one point; the center of joint rotation should be restored, meaning that the acetabular component of the implant must be positioned in the primary paleo-acetabulum. This is the only way to expect good joint function, being the only mode to establish the physiological distance between the ends of the muscular initiators of hip motion, thus enabling their full strength. However, there is no full agreement as to the preparation and positioning of the proximal femur at the required level of the primary acetabulum (Carrlson et al., 2003; Crowe et al., 1979; Dunn & Hess, 1976; Eskelinen et al., 2006; Hartofilakidis et al., 1996, 1998, 2004; Holinka et al., 2010; Lai et al., 1996, 2005; Paavilainen et al., 1990).

Many surgical techniques have been described by authors discussing the type and modes of femoral abbreviation osteotomies. Some of them are performed through the very trochanteric mass (midtrochanteric), while others are done below it (subtrochanteric), with various forms of resection osteotomies with or without fixation of the proximal fragment or great trochanter. Some authors achieve the adequate position of the femur in correlation to paleo-acetabulum by extrafocal distraction after the resection of the joint. Arthroplasty is to follow as a new operative technique, where the entire operative procedure is performed in

two acts. (Carrlson et al., 2003; Eskelinen et al., 2006; Hartofilakidis et al., 1996; Holinka et al., 2010; Lai et al., 1996, 2005; Paavilainen et al., 1990).

4.1.1 Total hip arthroplasty with iliofemoral distraction in high hip dislocation

As a part of total arthroplasty, the surgical technique applied to achieve the reduction of a high luxation of the hip without using femoral osteotomy is a relatively rare operative procedure. In the literature it was described by Lai et al. in 1996 and 2005, and then by Holinka et al. in 2010 (Carrlson et al., 2003; Eskelinen et al., 2006; Holinka et al., 2010; Lai et al., 1996, 2005).

The leading idea of this surgical procedure is based on the hypothesis that operative procedures with femoral abbreviation osteotomies, regardless of the type, could generally leave a considerable leg-length discrepancy, as well as muscular weakness of hip motion starters. The authors found a back-up for this notion in the articles by Crowe et al., Charnley et al., Dunn et al., Hartofilakidis et al., Paavilainen et al., Eskelinen et al., and others (Charnley & Feagin 1973; Crowe et al., 1979; Dunn & Hess, 1976; Eskelinen et al., 2006; Hartofilakidis et al., 1998; Paavilainen et al., 1990).

The operative procedure is performed in two acts. Namely, total arthroplasty is preceded by iliofemoral distraction with the Wagner's apparatus positioned in the ilium and distal femur. Before the distraction, it is necessary to perform subcutaneous adductor tenotomy of the hip, while femoral head resection with a total soft tissue release can be done before the distraction (Holinka et al.) or in the second act, as a part of total arthroplasty (Lai et al.). The distraction is performed gradually, 2-5 mm daily with regular X-ray check-ups and follow-up of neurovascular status of extremities, until the required joint reduction is achieved, bringing the femoral small trochanter into the acetabular teardrop level. During this period the patient is kept in bed. The second surgical act is performed after a few weeks involving removal of the Wagner's distraction apparatus and total arthroplasty of the hip.

The principles of total arthroplasty with positioning of the acetabular ring into the paleo-acetabulum and the stem in the femoral channel are standard. (Carrlson et al., 2003; Holinka et al., 2010; Lai et al., 1996, 2005; Paavilainen et al., 1990).

Such a surgical procedure is very complicated and requires long-term hospitalization and inactivity of the patient. The fact itself that in achieving the goal, total arthroplasty of the hip, requires two operative acts makes it twice riskier for the patient. In addition, the positioning of an extrafocal external apparatus in the area of the hip before arthroplasty might be as such problematic, because of exposing bone tissue to external environment over a long period of time. Strong Schantz screws in the femoral diaphysis can also present areas of decreased biomechanical resistance, particularly as known that the femur is anyway dysplastic in high luxations. Problems can also arise intraoperatively if there is extensive femoral anteversion. Namely, the positioning of a stem of standard geometry under such conditions could prove impossible to perform in the correction of overextensive anteversion. A solution could be found in using special stems of small dimensions and/or modular geometry; however, this does not solve the problem of the residual anterior torsion of the femoral neck.

All this is probably the reason why such operative procedure is rarely described in the literature.

4.1.2 Total hip arthroplasty with femoral abbreviation osteotomies

Today there are basically two operative techniques for total arthroplasty of the hip in high luxations with femoral abbreviation osteotomies, and both are based on osteotomies in the subtrochanteric region.

One technique involves resection of a larger part of the trochanter mass, hence the entire metaphysis and a portion of diaphysis, with preservation of the great trochanter with abductor attachments, while by other operative procedures resection osteotomy is performed only on the diaphysis below the small trochanter, with the metaphysis remaining preserved.

Femoral abbreviation osteotomies in total arthroplasty of the hip, particularly when treating high luxations due to DDH, have been described by numerous authors (Dunn et al., 1976; Crowe et al., 1979 ; Paavilainen et al., 1990, 1993; Hartofilakidis et al., 1996, 1998, 2004, 2008 ; Papagelopoulos et al., 1996; Numair et al., 1997; Carrlson et al., 2003).

The original operative technique by Paavilainen et al. has been slightly modified by Carlsson et al., but basic postulates have remained the same. After exposing the hip through the posterolateral approach, abbreviation osteotomy of the proximal femur is performed at two levels, horizontal and sagittal. The diaphysis is osteotomized transversally 7-9 cm below the top of the great trochanter, and then osteotomy of the proximal fragment at the sagittal level is performed, thus leavening abductor attachments of the hip, primarily of the gluteus medius in the lateral part, which basically represents the great trochanter. The remaining portion of the proximal fragment is removed, i.e. if necessary it can be used as a graft. The conical stem of small dimensions is implanted into the distal fragment, namely directly into the femoral diaphysis. After having positioned the acetabular component of the endoprosthesis, the remaining proximal fragment is lowered onto the proximal portion of the diaphysis and fixed with screws and/or wire serclages. Walking with partial weight-bearing is immediately allowed, while full weight-bearing can be allowed after two months (Paavilainen et al., 1990, 1993; Carrlson et al., 2003).

This operative procedure has the advantage over those described above primarily because arthroplasty of the hip is performed in one act. Hospital stay is much shorter, with more rapid rehabilitation and without any significant limitation as to weight-bearing. Although osteotomy of the proximal femur is done, the function of the gluteus medius remains preserved. Rather, its strength is reinstated with the distalization of the trochanter attachments.

Theoretically, the problem of this operative procedure might be non-healing of the great trochanter dislocated onto the diaphysis, however, authors have reported no such incidence in any of the cases. Also, theoretically, a delayed problem of potential revisional surgery might present a full loss of the metaphyseal bone of the proximal femur. The necessity to use a slightly more specific dysplastic stems, i.e. the impossibility of standard femoral implants (due to absent metaphyseal) does not present a true problem if taken into consideration a relatively small number of patients with such a condition.

At the Institute of Orthopaedic Surgery "Banjica" in Belgrade, high dislocation of the hip in adults is treated by transverse subtrochanteric abbreviational femoral osteotomy and, of course, a mandatory implantation of the acetabular component into the primary acetabulum. The operative technique was developed in 1984, however, over the time it

has undergone minor modifications. The essence has remained identical, only some details were changed regarding the extent of capsular excision and the mode of femoral osteotomy. Namely, today we do not excise the entire joint capsule, although it is cautiously prepared and freed from attached muscles, while the stability of the femoral segments is achieved by the adapted transverse osteotomy and implantation of the standard stem with distal rotational stability. Also, over the last 11 years, with the emergence of new implants, above all hemispheric press-fit acetabular rings, the need for acetabuloplasty, which was almost regularly applied at the time of screw ring usage, nowadays is almost nonexistent (Radojevic & Zlatic, 1990; Tabak et al., 2003; Zlatic et al., 1990).

The relaxation of the neuromuscular elements is achieved by the postoperative positioning of the leg with the hip and the knee in flexion which is individually adapted to each patient. Gradual stretching is done during the next days and last on average for 2-3 days. Only then the patient is allowed to stand up and to begin walking. Individually tolerant weight bearing on the operated leg is immediately allowed. Discarding the crutches is also done on individual basis, above all depending on the patient's capability to achieve a stable weight bearing within a given time. Certainly, osteotomy bone consolidation and the incorporation of endoprosthetic components also contribute to the decision on when walking supports could be discarded. Thromboembolic profilactic therapy is applied with low molecular weight heparine from the day of surgery until elapsed 35 postsurgical days (Fig. 4).

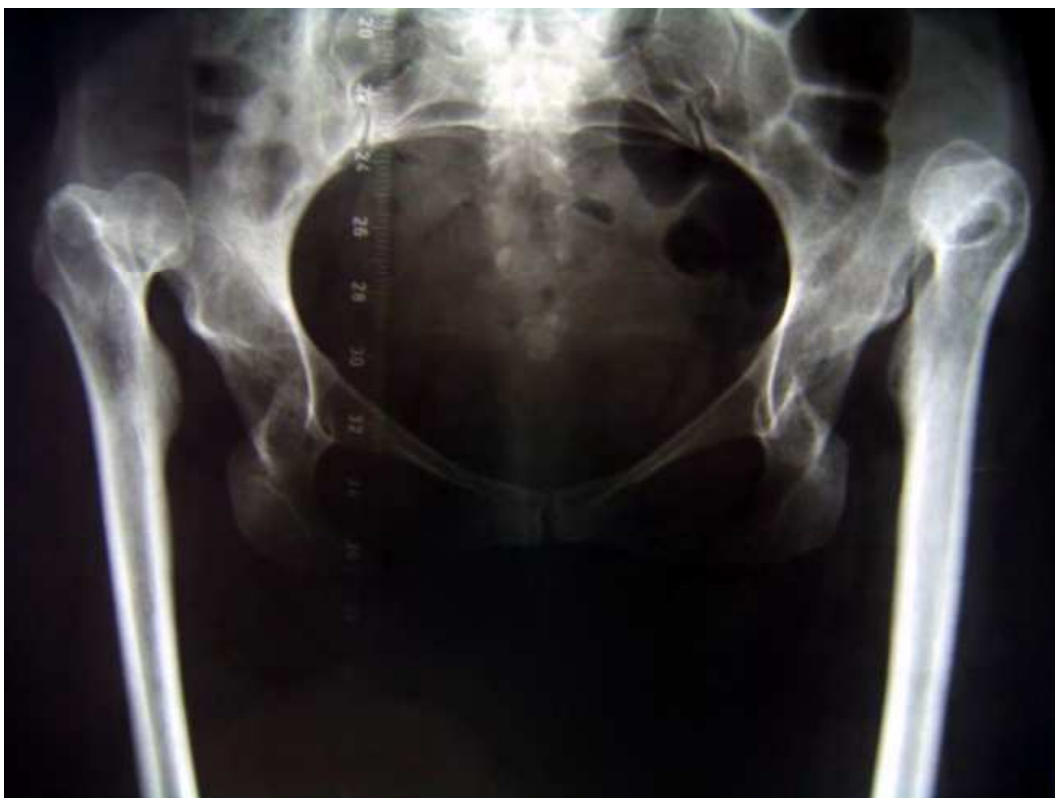

Fig. 4a. A 35-year old female with bilateral high dislocation of the hips due to DDH.

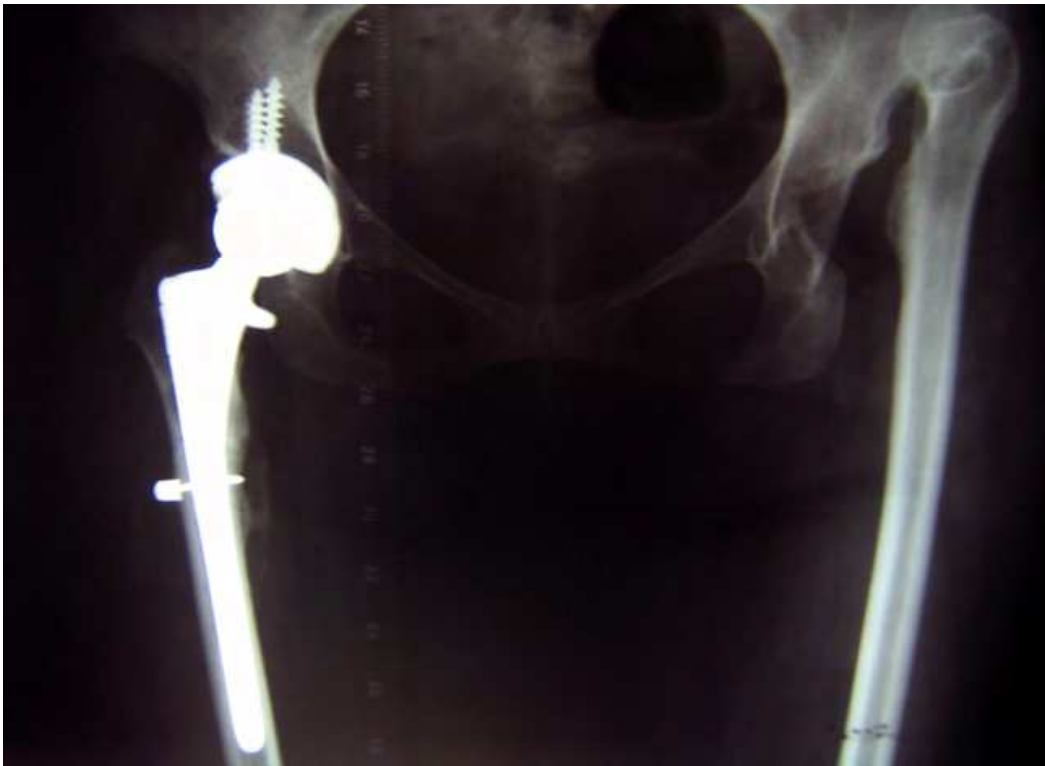

Fig. 4b. The same patient, nine months after total arthroplasty of the right hip. Good bone consolidation after four centimetres shortening subtrochanteric osteotomy.

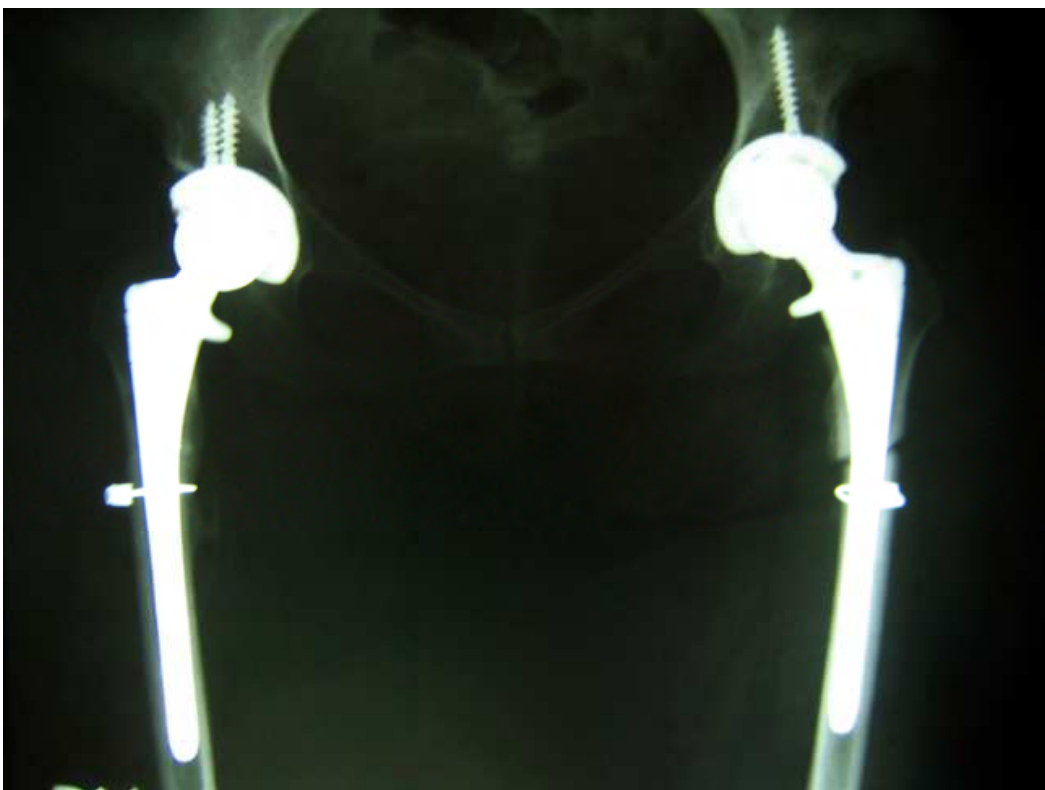


Fig. 4c. The same patient, three months after left hip arthroplasty with abbreviation subtrochanteric osteotomy. Leg length equality established. Bone consolidation in progress, femoral stem stable.

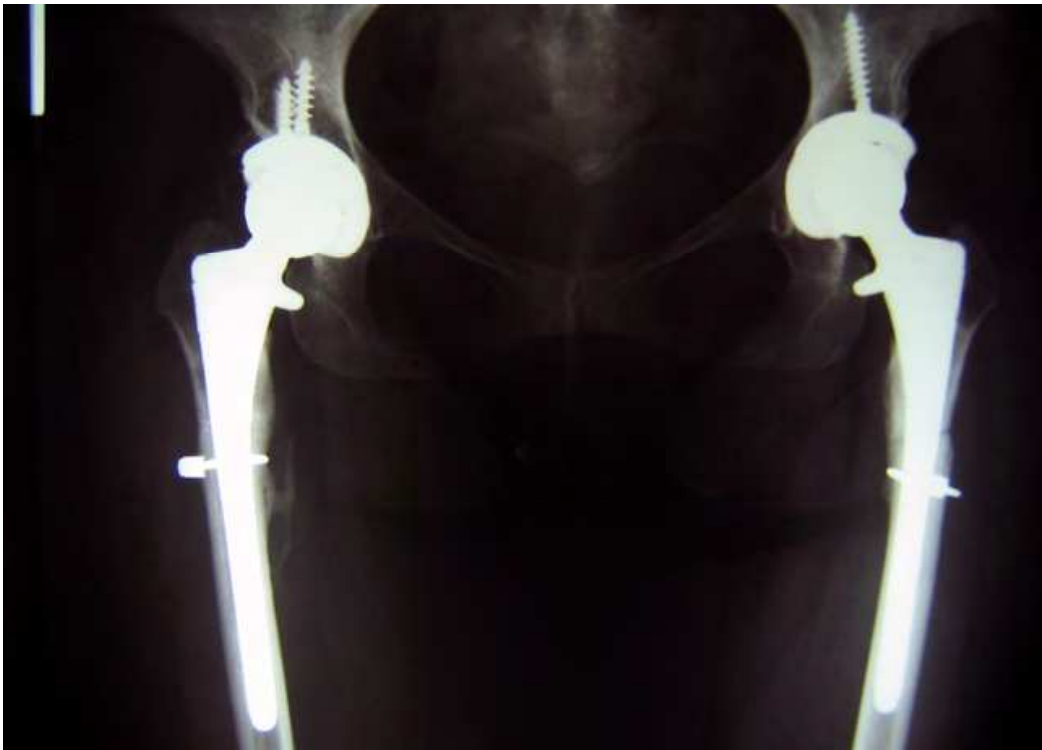


Fig. 4d. The same patient, 18 months after right total hip arthroplasty and nine months after left total hip arthroplasty. Both osteotomies were fully consolidated.

5. Conclusion

As can be seen, all previously described operative techniques for high hip luxation treatment with total hip arthroplasty are reliable in hands of experienced surgeons.

According to our opinion both operative techniques with femoral abbreviation osteotomies have significant advantages over two-act operative procedures. The theoretical advantage of the latter described operative technique, with diaphyseal subtrochanteric resection, over the former ones, with diaphyseal and metaphyseal resection, could be in the preservation of the bone metaphysis of the proximal femur with the possibility to use the standard midcoated implants without distal ingrowing and without additional fixation. On the other hand, the advantage of the former technique could refer to the healing of osteotomized fragments. Namely, a potentially delayed healing, and even non-healing of diaphyseal and metaphyseal bones in the subtrochanteric region is more probable than the fusion of firmly fixed great trochanter to the diaphysis.

6. Acknowledgment

This work was supported by Ministry of Education and Science, Republic of Serbia (Grant No. 41004).

7. References

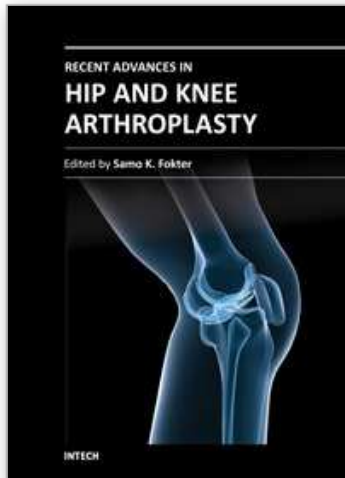
- Ando, M, Gotoh, E. (1990). Significance of inguinal folds for diagnosis of congenital dislocation of the hip in infants aged three to four months. *J Pediatr Orthop*, Vol. 10, No. 3, (May-Jun 1990) pp. (331-334), ISSN 0271-6798

- Bascarevic Z, Vukasinovic Z, Slavkovic N, Dulic B, Trajkovic G, Bascarevic V, Timotijevic S. (2010). Alumina on alumina ceramic versus metal-on-highly cross-linked polyethylene bearings in total hip arthroplasty: a comparative study. *Int Orthop*, Vol. 34, No. 8, (November 2009) pp. (1129-1135), ISSN 0341-2695
- Bascarevic, Z, Vukasinovic, Z. (2004). Diseases of the adult hip, In: *Special orthopaedics*, Vukasinovic, Z, pp. (275-303), Institute for orthopaedic diseases "Banjica" Belgrade, ISBN 86-82411-04-0, Belgrade
- Besset, B, Fassier, F, Tanzer, M, Brooks, C. (2003). Total hip arthroplasty in patients younger than 21 years: a minimum 10 year follow up. *Can J Surg*, Vol. 46, No. 4, (August 2003), pp. (257-262), ISSN 1488-2310
- Betz, R, Cooperman, D, Wopperer, J. (1990). Late sequelae of septic arthritis of the hip in infancy and childhood. *Je Pediatr Orthop*, Vol.10, No. 3, (May-Jun 1990), pp. (365-372), ISSN 0271-6798
- Carrlson, A, Bjorkman, A, Ringsberg, K, Schewelov, T. (August 2003). Untreated congenital and posttraumatic high dislocation of the hip treated by replacement in adult age. *Acta Orthop Scand*, Vol. 74, No. 4, (August 2003), pp. (389-396), ISSN 0001-6470
- Charnley, J, Feagin, JA. (1973). Low-friction arthroplasty in congenital subluxation of the hip. *Clin Orthop Relat Res*, Vol. 91, No. 3-4, (March-April 1973), pp. (98-113), ISSN 0009-921X
- Cherney, D, Westin, G. (1989). Acetabular development in the infants dislocated hips. *Clin Orthop Relat Res*, Vol. 242, No. 5, (May 1989), pp. (98-103), ISSN 0009-921X
- Choi IH, Pizzutillo PD, Bowen JR, Dragann R, Malhis T. (1990). Sequelae and reconstruction after septic arthritis of the hip in infants. *J Bone Joint Surg Am*, Vol. 72, No. 8, (September 1990), pp. (1150-1165), ISSN 0021-9355
- Crowe, JF, Mani, VJ, Ranawat, CS. (1979). Total hip replacement in congenital dislocation and dysplasia of the hip. *J Bone Joint Surg Am*, Vol. 61, No. 1, (January 1979), pp. (15-23), ISSN 0021-9355
- Delimar, D, Cicak, N, Klobucar, H, Pecina, M, Korzinek, K. (2002). Acetabular roof reconstruction with pedicled iliac graft. *Int Orthop*, Vol. 26, No. 6, (July 2002), pp. (344-348), ISSN 0341-2695
- Dunn, HK, Hess, WE. (1976). Total hip reconstruction in chronically dislocated hips. *J Bone Joint Surg Am*, Vol. 58, No. 6, (September 1976), pp. (838-845), ISSN 0021-9355
- Eftekhari, NS. (1978). *Principles of total hip arthroplasty*, CV Mosby, ISBN 0306439921, St. Louis
- Eskelinen, A, Helenius, I, Remes, V, Ylinen, P, Tallroth, K, Paavilainen, T. (2006). Cementless total hip arthroplasty in patients with high congenital hip dislocation. *J Bone Joint Surg Am*, Vol. 88, No. 1, (January 2006), pp. (80-91), ISSN 0021-9355
- Hartofilakidis, G, Georgiades, G, Babis, GC, Yiannakopoulos, CK. (2008). Evaluation of two surgical techniques for acetabular reconstruction in total hip replacement for congenital hip disease: results after a minimum ten-year follow-up. *J Bone Joint Surg Br*, Vol. 90, No. 6, (June 2008), pp. (724-730), ISSN 0301-620X
- Hartofilakidis, G, Karachalios, T. (2004). Total hip arthroplasty for congenital hip disease. *J Bone Joint Surg Am*, Vol. 86-A, No. 2, (February 2004), pp. (242-250), ISSN 0021-9355
- Hartofilakidis, G, Stamos, K, Karachalios, T. (1998). Treatment of high dislocation of the hip in adults with total hip arthroplasty. Operative technique and long-term clinical results. *J Bone Joint Surg Am*, Vol. 80, No. 4, (April 1998), pp. (510-517), ISSN 0021-9355

- Hartofilakidis, G, Stamos, K, Karachalios, T, Ioannidis, TT, Zacharakis, N. (1996). Congenital hip disease in adults. Classification of acetabular deficiencies and operative treatment with acetabuloplasty combined with total hip arthroplasty. *J Bone Joint Surg Am*, Vol. 78, No. 5, (May 1996), pp. (683-92), ISSN 0021-9355
- Holinka, J, Pfeiffer, M, Hofstaetter, JG, Lass, R, Kotz, RI, Giurea, A. (2010). Total hip replacement in congenital high hip dislocation following iliofemoral monotube distraction. *Int Orthop*, Vol. 35, No. 5, (March 2010), pp. (639-645), ISSN 0341-2695
- Kliscic, P. (1989). Congenital dislocation of the hip: a misleading term. *J Bone Joint Surg*, Vol. 71, No. 1, (January 1989), pp. (136-139), ISSN 0301-620X
- Kliscic, P, Rakic, D, Pajic, D. (1984). Triple prevention of congenital dislocation of the hip. *J Pediatr Orthop*, Vol. 4, No. 6, (November 1984), pp. (759-761), ISSN 0271-6798
- Lai, KA, Liu, J, Liu, TK. (1996). Use of iliofemoral distraction in reducing high congenital dislocation of the hip before total hip arthroplasty. *J Arthroplasty*, Vol. 11, No. 5, (August 1996), pp. (588-593), ISSN 0883-5403
- Lai, KA, Shen, WJ, Huang, LW, Chen, MY. (2005). Cementless total hip arthroplasty and limb-length equalization in patients with unilateral Crowe type-IV hip dislocation. *J Bone Joint Surg Am*, Vol. 87, No. 2, (February 2005), pp. (339-345), ISSN 0021-9355
- Learmonth, ID, Heywood, AW, Kaye, J, Dall, D. (1989). Radiological loosening after cemented hip replacement for juvenile chronic arthritis. *J Bone Joint Surg Br*, Vol. 71, No. 2, (March 1989), pp. (45-55), ISSN 0301-620X
- Maric, Z, Haynes, RJ. (1993). Total hip arthroplasty in juvenile rheumatoid arthritis. *Clin Orthop*, Vol. 290, No. 5, (May 1993), pp. (197-199), ISSN 0009-921X
- Numair, J, Joshi, AB, Murphy, JC, Porter, ML, Hardinge, K. (1997). Total hip arthroplasty for congenital dysplasia or dislocation of the hip. Survivorship analysis and long-term results. *J Bone Joint Surg Am*, Vol. 79, No. 9, (September 1997), pp. (1352-1360), ISSN 0021-9355
- Paavilainen, T, Hoikka, V, Solonen, KA. (1990). Cementless total replacement for severely dysplastic or dislocated hips. *J Bone Joint Surg Br*, Vol. 72, No. 2, (March 1990), pp. (205-211), ISSN 0301-620X
- Papachristou, G, Hatzigrigoris, P, Panousis, K, Plessas, S, Sourlas, J, Levidiotis, C, Chronopoulos, E. (2006). Total hip arthroplasty for developmental hip dysplasia. *Int Orthop*, Vol. 30, No. 1, (February 2006), pp. (21-25), ISSN 0341-2695
- Papagelopoulos, P, Trousdale, RT, Lewallen, DG. (1996). Cementless total hip arthroplasty with femoral osteotomy for proximal femoral deformity. *Clin Orthop*, Vol. 332, No. 11, (November 1996), pp. (151-162), ISSN 0009-921X
- Pitto, RP, Schikora, N. (2004). Acetabular reconstruction in developmental hip dysplasia using reinforcement ring with a hook. *Int Orthop*, Vol. 28, No. 4, (August 2004), pp. (202-205), ISSN 0341-2695
- Radojevic, B, Zlatic, M. (1990). An L-shaped bone graft for acetabular deficiency. *J Bone Joint Surg Br*, Vol. 72, No. 1, (January 1990), pp. (152-153), ISSN 0301-620X
- Ruddlesdin, C, Ansell, BM, Arden, GP, Swann, M. (1986). Total hip replacement in children with juvenile chronic arthritis. *J Bone Joint Surg Br*, Vol. 68, No. 2, (March 1986), pp. (218-222), ISSN 0301-620X
- Tabak, AY, Celebi, L, Muratli, H, Yagmurlu, F, Aktekin, C, Bicimoglu, A. (2003). Cementless total hip replacement in patients with high total dislocation: the results of femoral

- shortening by subtrochanteric segmental resection. *Acta Orthop Traumatol Turc*, Vol. 37, No.4, (April 2003), pp. (277-283), ISSN 1017-995x
- Vukasinovic, Z, Bascarevic, Z. (2004). Diseases of the infant hip, In: *Special orthopaedics*, Vukasinovic Z, pp (237-273), Institute for orthopaedic diseases "Banjica" Belgrade, ISBN 86-82411-04-0, Belgrade
- Vukasinovic, Z, Djoric, I. (1994). Developmental disorder of the hip, In: *Hip diseases in childhood*, Vukasinovic Z, pp. (37-78), Special orthopaedic hospital „Banjica“ Belgrade, ISBN 86-82411-01-6, Belgrade
- Kim YH, Seo HS, Kim JS. (2009). Outcomes after THA in patients with high hip after childhood sepsis. *Clin Orthop Relat Res*, Vol. 467, No. 9, (September 2009), pp. (2371-2378), ISSN 0009-921X
- Zlatic, M, Radojevic, B, Lazovic, C. (1990). Reconstruction of the hipoplastyc acetabulum in cementless arthroplasty of the hip. *Int Orthop*, Vol. 14, No.4, (April 1990), pp. (371-375), ISSN 0341-2695

IntechOpen



Recent Advances in Hip and Knee Arthroplasty

Edited by Dr. Samo Fokter

ISBN 978-953-307-841-0

Hard cover, 452 pages

Publisher InTech

Published online 27, January, 2012

Published in print edition January, 2012

The purpose of this book is to offer an exhaustive overview of the recent insights into the state-of-the-art in most performed arthroplasties of large joints of lower extremities. The treatment options in degenerative joint disease have evolved very quickly. Many surgical procedures are quite different today than they were only five years ago. In an effort to be comprehensive, this book addresses hip arthroplasty with special emphasis on evolving minimally invasive surgical techniques. Some challenging topics in hip arthroplasty are covered in an additional section. Particular attention is given to different designs of knee endoprotheses and soft tissue balance. Special situations in knee arthroplasty are covered in a special section. Recent advances in computer technology created the possibility for the routine use of navigation in knee arthroplasty and this remarkable success is covered in depth as well. Each chapter includes current philosophies, techniques, and an extensive review of the literature.

How to reference

In order to correctly reference this scholarly work, feel free to copy and paste the following:

Zoran Bascarevic, Zoran Vukasinovic, Violeta Bascarevic and Vladimir Bascarevic (2012). Hip Arthroplasty in Highly Dislocated Hips, *Recent Advances in Hip and Knee Arthroplasty*, Dr. Samo Fokter (Ed.), ISBN: 978-953-307-841-0, InTech, Available from: <http://www.intechopen.com/books/recent-advances-in-hip-and-knee-arthroplasty/hip-arthroplasty-in-highly-dislocated-hips>

INTECH
open science | open minds

InTech Europe

University Campus STeP Ri
Slavka Krautzeka 83/A
51000 Rijeka, Croatia
Phone: +385 (51) 770 447
Fax: +385 (51) 686 166
www.intechopen.com

InTech China

Unit 405, Office Block, Hotel Equatorial Shanghai
No.65, Yan An Road (West), Shanghai, 200040, China
中国上海市延安西路65号上海国际贵都大饭店办公楼405单元
Phone: +86-21-62489820
Fax: +86-21-62489821

© 2012 The Author(s). Licensee IntechOpen. This is an open access article distributed under the terms of the [Creative Commons Attribution 3.0 License](#), which permits unrestricted use, distribution, and reproduction in any medium, provided the original work is properly cited.

IntechOpen

IntechOpen