

We are IntechOpen, the world's leading publisher of Open Access books Built by scientists, for scientists

5,300

Open access books available

129,000

International authors and editors

155M

Downloads

Our authors are among the

154

Countries delivered to

TOP 1%

most cited scientists

12.2%

Contributors from top 500 universities



WEB OF SCIENCE™

Selection of our books indexed in the Book Citation Index
in Web of Science™ Core Collection (BKCI)

Interested in publishing with us?
Contact book.department@intechopen.com

Numbers displayed above are based on latest data collected.
For more information visit www.intechopen.com



Combined Therapies to Treat CNV in AMD: PDT + Anti-VEGF

Jorge Mataix, M. Carmen Desco, Elena Palacios and Amparo Navea
*Fundacion Oftalmologica Mediterraneo, Valencia
Spain*

1. Introduction

Age-related macular degeneration (AMD) causes a high incidence of morbidity in the elderly. The dry forms of the disease are the most usual, but wet forms (15% of the total of cases) are responsible for 80% of AMD-related cases of severe vision loss. Age-related macular degeneration is essentially a choroidal/retinal pigment epithelium (RPE) disease which affects the overlying neurosensory retina. Formation of choroidal neovessels that penetrate the subretinal space is the main cause of vision loss. Knowing what role the vascular endothelial growth factor (VEGF) plays in angiogenesis of the formation of these neovessels is a determining factor. Ferrara's studies describe the four main biological functions in VEGF agents (Ferrara & Gerber, 2001):

1. Increase in vascular permeability
2. Growth and proliferation of vascular endothelial cells
3. Migration of vascular endothelial cells
4. Survival of immature endothelial cells by preventing apoptosis

Since the formation of choroidal neovascularization (CNV) is a determining factor in vision loss in wet AMD, it is reasonable to expect a reduction in the risk of vision loss by inhibiting new vessel formation and preventing their growth. The efficacy of antiangiogenesis agents for this purpose has provided proof of the concept of therapy targeted at a specific molecular step in the process, namely the inhibition of VEGF (Gragouas et al. 2004). Therefore the appearance of antibodies against VEGF (anti-VEGF) brought about a considerable advance in the treatment of exudative forms of AMD. The most important effects are **regression** of existing vessels, **normalization** of surviving vessels, and **inhibition** of vessel growth.

Antiangiogenesis agents have proved to be beneficial but are often administered late in the process when the aim of the treatment is to salvage vision rather than to prevent vision loss. One obstacle in developing a single approach to treatment stems from the possibility that AMD is the product of multiple pathologic processes. A more exciting goal is halting the process at a subclinical stage or preventing the disease in patients identified as being at risk for vision loss. Progress in isolating multiple processes responsible for disease progression is creating new opportunities for combination therapies.

2. Composition of neovessels

Histopathologic examination of CNV shows granulation-like tissue, with the invasion of not only blood vessels, but also inflammatory and mesenchymal cells embedded in a loosely formed extracellular matrix. Although the majority of damage attributed to CNV is due to neovessel bleeding or leakage, there are other components and factors associated with CNV that influence the visual prognosis decisively.

A two-component model of CNV has been developed to offer a conceptual framework to structure combination treatments. One is the *vascular component*, which is composed of vascular endothelial cells and associated pericytes. The other is the *nonvascular component* which is made up of the remaining cells, such as the inflammatory cells, glial cells, myofibroblasts, and fibrocytes (Spaide, 2006a, 2009). Inhibiting one has the potential to inhibit, at least partially, the other due to mutual interactions between the two components and each component can potentially cause damage. Inhibiting either one would seem to offer some hope in slowing down or arresting the process, but inhibition of both would intuitively lead to the best theoretical outcome.

Blocking the vascular component is achieved mainly by administering anti-VEGF agents, although in advanced lesions with mature neovessels covered by pericytes, anti-VEGF on their own cannot make these neovessels regress. In these cases, a combination of other therapies has to be resorted to which act by means of selective mechanisms, such as blocking the platelet-derived growth factor (PDGF) to target the pericytes, or a non-selective attack mechanism, such as ionizing radiation which is explained further on (Jain RK, 2005) in this chapter.

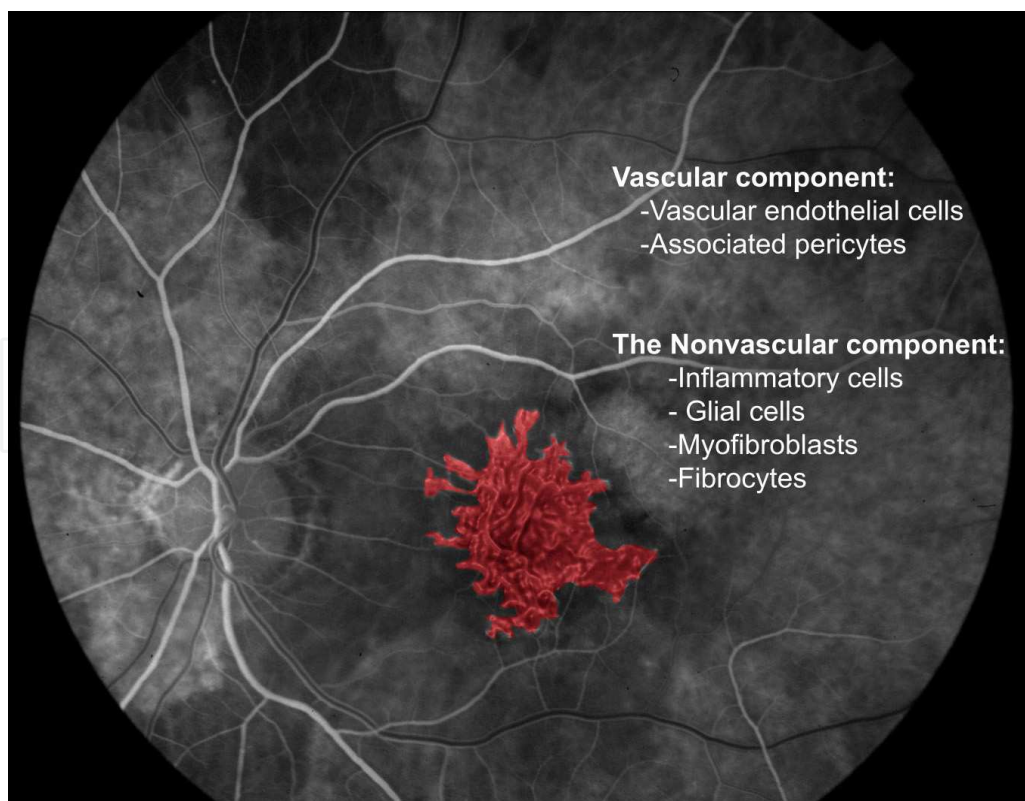


Fig. 1. CNV components: vascular and nonvascular components

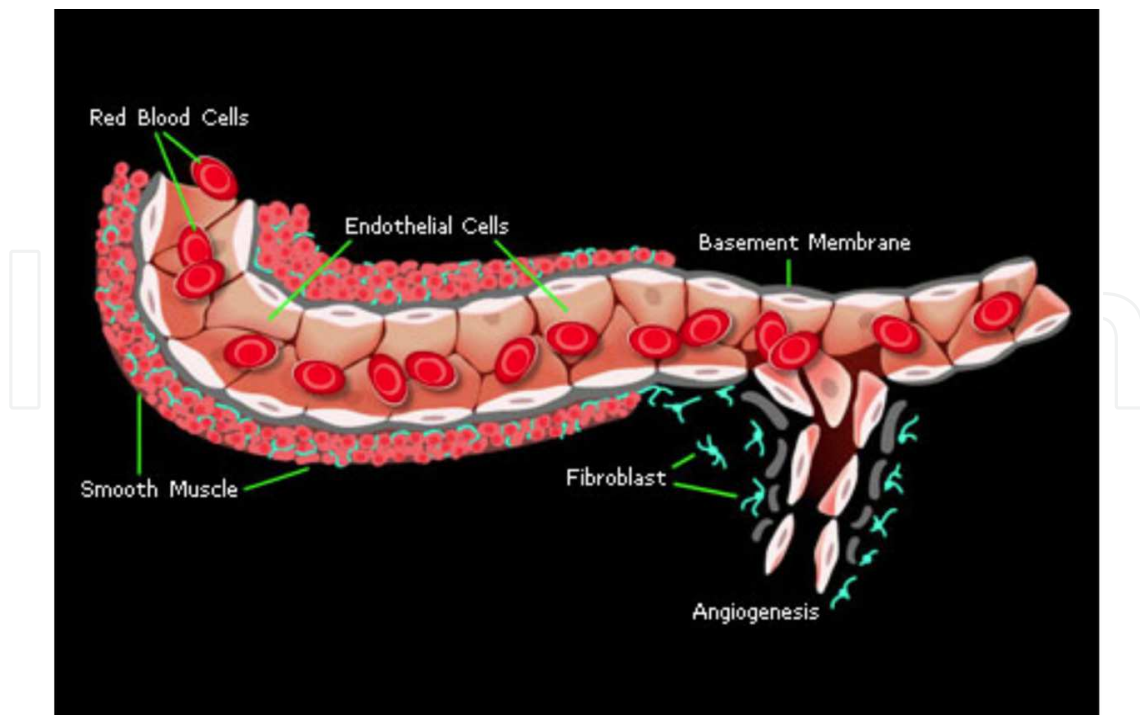


Fig. 2. Phases in angiogenesis in which the formation of a neovessel guided by the extracellular matrix is shown (Genentech image).

Blocking the extravascular component, like inhibiting subretinal fibrosis, can considerably reduce the morbidity of the disease. Biological therapies mediated by cytokines, such as the tumor necrosis factor, ionizing radiation which does not only act on the vascular component but also on the extravascular component, corticosteroid drugs combined with anti-VEGF can improve the therapeutic response, inhibiting the development of the extracellular matrix which, in the long term, often plays a determining role in vision loss.

Currently, the most relevant therapy available is VEGF inhibition. Possibly, greater success could be achieved if other key factors in pathogenesis were also inhibited. It would be more advantageous if angiogenesis, scarring, and inflammation were targeted simultaneously. Combination approaches may not only increase overall efficacy but also reduce the potential for side effects by allowing relatively low doses to yield a greater level of efficacy than higher doses of a single agent.

3. Limitations of anti-VEGF in CNV treatment

The appearance of anti-VEGF is a revolutionary treatment in wet AMD as, for the first time, the progression of the disease can be stopped. Nevertheless, it cannot restore vision and there are still many cases that progress in spite of repeated treatment with anti-VEGF. Listed below are several limitations of anti-VEGF that make the quest for other therapies, or a combination of therapies, necessary.

3.1 Anti-VEGF agents do not affect mature vessels

As described above, one of the functions of VEGF is favoring the survival of endothelial cells, but this function is just restricted to immature vessels in which angiogenesis

necessarily requires the activation of survival pathways to maintain the condition of the vessels (Gerber et al., 1998). Nonetheless, the mechanisms involved in the maturing process of the vessels, such as pericyte coverage and the formation of interaction between endothelial and periendothelial cells with the basal membrane, free the endothelial cell from the requirement of the survival function of VEGF.

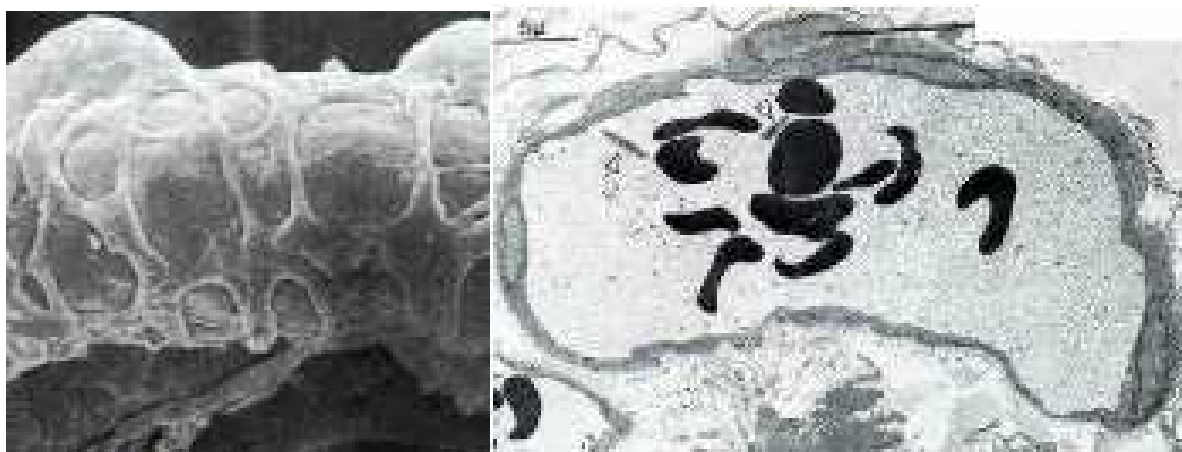


Fig. 3. Composition of a mature blood vessel, made up of endothelial cells, pericyte coverage, and the interactions between them.

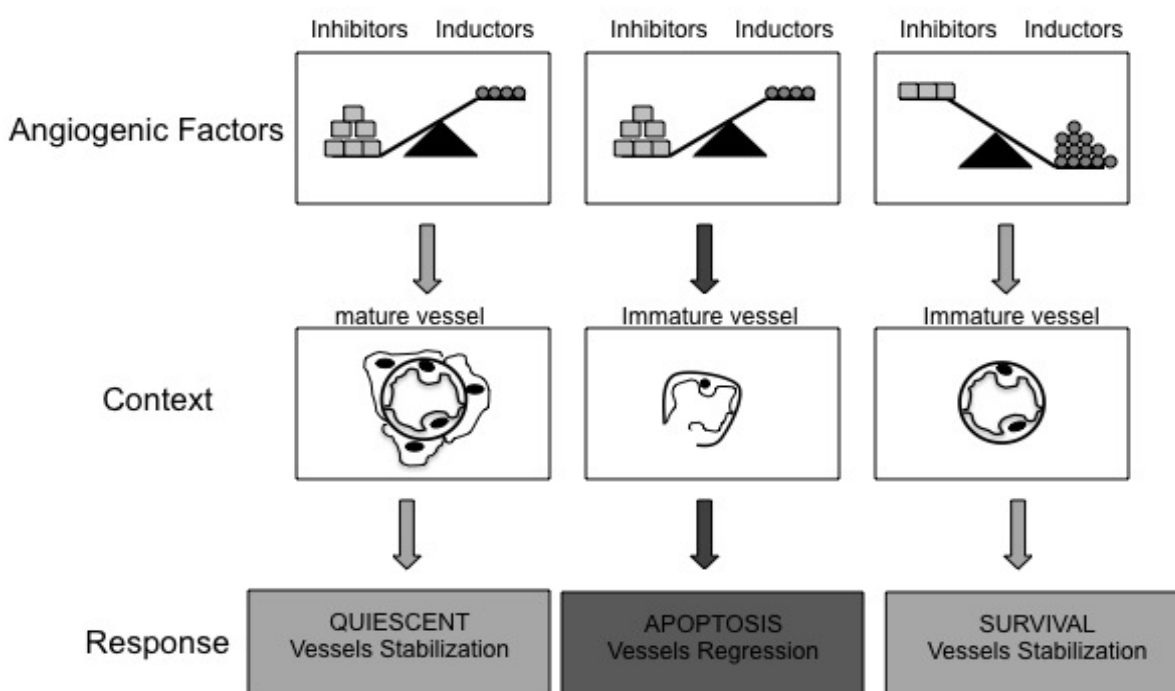


Fig. 4. When the factors that inhibit angiogenesis predominate over those that induce it, two things can occur, depending on the context. If the vessel is mature, it will show no response as it is quiescent and is not affected by the effect of the antiangiogenic drugs. However, if the vessels are immature, with no pericyte coverage, the angiogenesis inhibitors will favor apoptosis and the regression of the vessel. When proangiogenic factors predominate the immature vessel survives and stabilizes.

In this way, the angiogenic factors basically act as survival factors, while antiangiogenic factors act as apoptosis-inducing factors in the context of endothelial expansion, which is an immature endothelium. Thus the balance between the inducing and inhibiting factors determines the destiny of immature vessels, but they do not bear an influence on mature vessels that are in a quiescent state due to the interaction between endothelial cells, pericytes, and the extracellular matrix (Jimenez Cuenca B, 2003). Therefore, if the neovessels are already mature, they will not react to VEGF, nor will they respond to anti-VEGF (Benjamin et. al., 1999). This fact underpins the value of combined therapies like photodynamic therapy (PDT) with verteporfin, which is necessary to destroy the architecture of different mature components of the neovascular membrane that do not respond to anti-VEGF.

3.2 Anti-VEGF agents do not decrease the CNV size

Despite their beneficial clinical effects in AMD, anti-VEGF therapies are ineffective in regressing existing lesions. Endothelial cells and pericytes that form the structure of new vascular tissue typically do not regress with VEGF inhibition alone. This limitation is confirmed by data from the key prospective, randomized clinical trials with Ranibizumab, such as PIER, ANCHOR, and MARINA (Regillo et al., 2008; Brown et al., 2006; Rosenfeld et al., 2006) which did not produce any significant evidence of neovascular regression despite improvement in visual acuity. There are no changes from baseline in the CNV area. This lack of regression is also consistent with experimental models in which monotherapy with anti-VEGF agents inhibits new vascular formation but has little effect on existing capillaries.

Despite the importance of VEGF agents in the cascade of events that stimulates and sustains new vascular formation, VEGF inhibition may have limited effects on existing neovascular tissue once subsequent molecular events are triggered, making inhibition of additional molecular steps essential to build on the benefits of anti-VEGF therapies.

3.3 Tachyphylaxis

Recent publications refer to the possible existence of tachyphylaxis after use of intravitreal Bevacizumab. Forooghian and co-workers describe a decrease in the duration of the beneficial effect, and even a lack of response, after a mean of eight intravitreal injections (Forooghian et al., 2009) in six (n = 59) patients with AMD treated with Bevacizumab in monotherapy.

Currently, the existence of tachyphylaxis is under discussion and its mechanism is unknown. This author poses the possibility of an autoimmune mechanism after a patient, suffering from uveitis, presented tachyphylaxis immediately after intravitreal injection. It must be remembered that Bevacizumab, in spite of being a "humanized" antibody for decreasing immunogenicity, could trigger the formation of new anti-Bevacizumab antibodies after repeated treatments; this hypothesis has yet to be studied.

In addition, it should be considered that always inhibiting the same vascular pathway may potentiate other pathogenic pathways, such as the inflammatory pathway, or that it may increase other cytokines involved in wet AMD. Certainly, a greater inflammatory activity and a proliferation of macrophages in the membranes that were surgically extracted with prior Bevacizumab treatment were observed compared with those extracted without prior intravitreal treatment (Tatar et al., 2009).

Furthermore a better response to intravitreal corticoids has been observed in patients who stop responding to anti-VEGF intravitreal injections (Schaal et al., 2008). Therefore we pose a future problem regarding the use of anti-VEGF, i.e., how to avoid this occurrence. One of the most appropriate options would be to find the way to reduce the number of intravitreal injections in the treatment of AMD and, to date, the only way is with combined therapies.

3.4 Anti-VEGF agents do not act on fibrosis and atrophy

Long-term follow-up of patients who participated in the initial studies of anti-VEGF therapies suggests that late visual loss is often caused by processes that seem to be independent of neovascularization, particularly fibrosis and atrophy. Although more effective antiangiogenesis treatments, including combination strategies, for better blockade of new vessel formation are likely to improve outcome, it is appropriate to expand targets to other pathophysiologic processes associated with AMD. It is necessary to incorporate therapies that block fibrosis and inhibit atrophy or other pathophysiologic processes not directly related to neovascularization.

In Ranibizumab trials (Rosenfeld et al., 2006; Brown et al., 2006), protection against visual loss was highly significant relative to controls during a follow-up of twelve and 24 months. Gains in visual acuity were much smaller: only 34% achieved >15 letter gain at twelve months or 24 months on the most effective dose of Ranibizumab and 65% of patients with very modest gains, no gains, or visual loss over the course of these studies. The subgroup of patients with a loss of three or more lines of visual acuity tended to have better visual acuity than average at baseline, but a larger area of CNV and a larger area of CNV leakage. Over the course of treatment, these patients had a greater growth in total lesion area and more retinal pigment epithelium abnormalities.

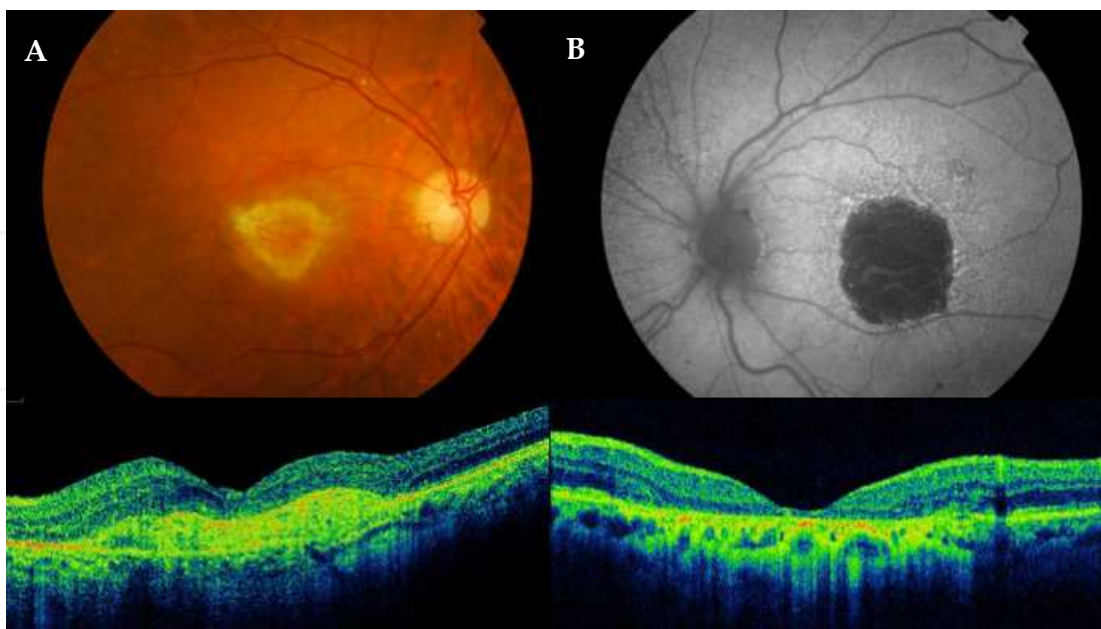


Fig. 5. (A) Retinograph and OCT of subretinal fibrosis of an AMD patient treated with anti-VEGF. (B) Autofluorescence of macular atrophy in the context of wet AMD that had already been treated. In both cases, the evolution of visual acuity was poor despite inactivating the lesion with repeated doses of anti-VEGF.

In a study in which 82 patients, treated with Ranibizumab monotherapy, were monitored in a follow-up of two to six years, reported that the rate of fibrosis was 50% and the rate of atrophy of the retinal pigment epithelium was 40%; 8% percent had both. The fibrosis may have been caused by ongoing inflammation and by maturation of vascular tissue. Hemorrhage above or below the subretinal pigment epithelium may have played a contributing role. Fibrosis was often observed after several years of antiangiogenesis therapy even among responders (Kaiser PK, 2009c).

These findings reinforce other evidence that fibrosis may be an important additional target to expand or preserve the benefits of Ranibizumab and other VEGF inhibitors in the treatment of AMD. Several strategies are being pursued. These include antagonists of integrin, inhibitors of the mammalian target of rapamycin, vascular disrupting agents, and radiation. Control of atrophy, which is generally observed at an earlier stage of AMD progression than fibrosis, is another potential target for improving outcome. The candidate targets for preventing atrophy include neurotrophic factors, free radical scavengers, and retinol binding competitors. Complement inhibition may be another viable strategy (Heier JS, 2009).

3.5 Several pathogenic pathways involved

Even the maximum inhibition of VEGF does not stop vascular growth due to the presence of redundant signaling pathways. Controlling one pathway, the inhibition of neovascularization is relatively modest due to the presence of redundant signaling pathways. The combination of molecules inhibit different parts of the angiogenic process and provide more profound inhibition of neovascularization relative to blocking a single proangiogenic signal (Frielander, 2009).

When one of two inhibitors of angiogenesis was used in experimental studies (Dorrell et al., 2007) complete inhibition of new vessel formation was achieved in a small proportion of animals. In contrast, complete inhibition of neovascularization was observed in more than half of the animals treated with triple combination therapy.

3.6 Route of administration, number and frequency of doses

Transscleral and intravitreal injections are alternative methods of local delivery. These methods may reduce the risk of systemic absorption, because topical therapy results in a significant amount of the drug draining away from the eye through the nasal lacrimal duct into the gut. Transscleral and intravitreal injections may also increase the percentage of the dose that reaches a posterior target. The efficacy of this approach is well documented with antiangiogenic therapies for AMD, but it is not risk-free for the patient, and moreover, it requires surgical administration, which in many cases can cause saturation of operating rooms and delays to the detriment of the patient. Moreover, as it is a chronic disease, retreatment is often necessary which increases these problems. Association of anti-VEGF with other therapies can be useful in reducing the number of anti-VEGF doses without reducing its effectiveness.

Not least important is the potential for unwanted effects on the biologic function controlled by drug targets, such as prolonged suppression of a complex molecule like VEGF, which while being a key factor in causing CNV associated with AMD, also plays an important role as a neuroprotectant in the mature retina.

Exudative AMD is a sub-acute process. Its natural progress from the first symptoms of CNV to scar formation takes over a year in most cases, but can even be active for years (Holz et al., 2004). In fact, the disease evolves to final subfoveal scarring, including the cases where the disease was extrafoveal initially. A well-known fact is that unfortunately, sometimes after years of thermal laser treatment of an extrafoveal lesion, there is foveal recurrence. Antiangiogenic drugs can prevent the growth of new blood vessels but it is not known how long antiangiogenic activity must be kept up to prevent CNV reactivation; it may be needed for years.

There is good justification for considering combination strategies in AMD to build on the initial success achieved with VEGF inhibitors, but combination strategies impose considerable challenges. The frequency of intravitreal injections causes significant difficulties in terms of clinical management and patient convenience and available devices for implantation do not seem to be viable for chronic treatment in their current form.

4. Combined therapies with anti-VEGF

Mediation synergies are used in medicine to potentiate the effect that two or more drugs provide separately, acting on the disease from a different etiopathogenic approach. As AMD is a complex process, it seems logical to focus its treatment from different physiopathological strategies. The combination of agents with different action mechanisms can give rise to a synergic effect, a lower number of overall treatments, and a greater duration of the response when compared with Ranibizumab monotherapy, while the outcome on visual acuity persists.

4.1 Action mechanisms: PDT and anti-VEGF

Photodynamic therapy with verteporfin has been used for years in the treatment of CNV in AMD and its action mechanism has been described repeatedly. Briefly, the action of verteporfin with non-thermal laser in the macular area where the CNV is present triggers processes that lead to apoptosis (Granville et al., 2001), alters the lipids of the cellular membranes of the endothelium, triggers plaquetary aggregation and thrombosis, and increases vascular permeability, blood stasis, and tissue hypoxia (Fingar, 1996). There is an increase in VEGF expression in this process which is the cause of the growth and reactivation of the common membrane before the third month; association of an anti-VEGF inhibits this effect.

Pharmacologic inhibition of VEGF-A decreases the proliferation of endothelial cells and recruitment of others, such as leukocytes, which can express the cytokines and proteases necessary to develop and maintain neovessels (Witmer, 2003; Ferrara, 2003). However, once neovascularization is stabilized, it will not respond to anti-VEGF treatment (Benjamin, 1999). This would explain the added benefit of associating PDT to destroy the architecture of the different components of the neovascular membrane that do not respond to anti-VEGF.

In 2003, Schmidt-Erfurth evaluated the impact PDT has on the expression and distribution of VEGF, VEGF receptor (VEGFR)-3, and pigment epithelium-derived factor (PEDF) after applying it to the retina. Said author reported that PDT using verteporfin induces a reproducible angiogenic response in elderly human eyes. Vascular endothelial growth factor, VEGFR-3, and PEDF expression is enhanced after PDT. Choroidal endothelial cells

appear to be the primary site of angiogenic stimulation (Schmidt-Erfurth et al., 2003). This suggests that combining PDT with anti-VEGF for decreasing the PDT response is advisable. The increase in the formation of VEGF, VEGF-3, and PEDF can favor the growth of CNV after initial PDT treatment. This has been observed constantly in our series of 262 cases treated with PDT with a 48-month follow-up. We noted an increase in the CNV size throughout the observation period. This growth was nearly 60% of the total size increase at month three after the first PDT treatment (Mataix et al. 2009).

Photodynamic therapy is very effective in the initial control of CNV because it achieves almost 100% closure of the neovessels in all patients in a period of seven days to one month (Miller et al., 1999). Its side effects include hypoxia, stimulation of inflammatory factors, and upregulation of VEGF expression (Schmith-Erfurth et al., 2001), which can be prevented by associating an anti-VEGF. Although monotherapy with PDT achieves inactivation of the lesion, it does not inhibit subsequent growth, bringing about a loss of vision that in many cases is difficult to recover (Awan, et al., 2009).

The benefits of PDT are documented in a great variety of cases with CNV due to AMD and there is encouraging evidence of improved outcomes when this angioocclusive modality is combined with antiangiogenic agents (Schmidt-Erfurth et al., 2009). It is known that treatment with verteporfin produces hypoperfusion in the treated area and that concomitant use of anti-VEGF can prolong this effect. Moreover, numerous analyses show minimal evidence that there is association with visual deterioration or other adverse effects. Furthermore, hypoperfusion helps to reduce recanalization of CNV and permits neuronal recovery by decreasing exposure to oxygen and oxidative radicals. The reduced need for frequent retreatments clearly has a major appeal due to the lower costs associated with fewer interventions and reduced burden of clinical monitoring and diagnostic reevaluations (Schmidt-Erfurth et al., 2009).

4.2 Clinical trials combining PDT + Ranibizumab

Various clinical assays have been performed with different designs in which combined treatment has been compared with monotherapy. A previous study - PROTECT (Schmidt-Erfurth, 2008) - evaluated the safety and efficacy of administering PDT and Ranibizumab on the same day. Photodynamic therapy was applied and an hour later the intravitreal injection was given. Photodynamic therapy was repeated every three months in accordance with the investigator's opinion and Ranibizumab was administered the first three months, then as required. The study served to show that combined treatment performed on the same day is safe and effective.

The FOCUS study (Heier, 2006) was designed to evaluate, in wet AMD with predominantly classic CNV the safety and efficacy of the combination of Ranibizumab and PDT as the first treatment, followed by monthly Ranibizumab for the first twelve months and PDT every three months according to the investigator's opinion. The control group only received PDT and a simulation injection. After twelve months, the study group showed 90.5% of eyes had lost less than 15 letters as opposed to 67.9% in the control group. The combined treatment group received a mean of 1.32 PDT and the control group 4 PDT per year the first year. After 24 months there was a difference of 12.4 letters in favor of the combined treatment group.

The most interesting assays are the SUMMIT with its two groups, the DENALI which was carried out in the United States and Canada, and the MONTBLANC which was performed in Europe. They were designed to determine whether PDT combined with Ranibizumab was better than monotherapy with Ranibizumab and they included patients with all types of lesions. They were divided randomly into two groups in the MONTBLANC study: in one, PDT was performed and basal intravitreal Ranibizumab and two more injections of Ranibizumab were administered; subsequent treatments were as required and PDT was associated in accordance with the investigator's opinion every three months. Monotherapy and simulating PDT were used in the control group. In the American group, a third group with combined treatment of low fluence PDT was added.

According to the results after twelve months of the MONTBLANC study presented at the European Retina Society in Amsterdam in 2010, the differences between combined and monotherapy treatment were slight in overall terms. The visual behavior was similar between the study and control groups. Neither was there a very significant difference regarding the need for retreatments in the two groups, although with combination therapy a tendency towards a decrease in repeated treatments with Ranibizumab was observed. After twelve months, the mean change in best-corrected visual acuity (BCVA) was +2.5 in the combined treatment group and +4.4 in the monotherapy group. Over 50% of the patients in the two groups gained at least one line of vision compared with their basal value. There was a mean improvement in VA of +2 letters in the combined group and +1.6 letters in the monotherapy group after twelve months in the predominantly classic lesions. Patients with ≤ 2 area of disc (AD) lesions experienced a mean improvement in VA of +9.7 letters in the combination group and +7.1 letters in the monotherapy group after twelve months.

The patients in the combination group received, on average, 0.3 times fewer Ranibizumab injections. The mean number of treatment repetitions with Ranibizumab after the loading phase in the combination group was 1.8 compared with 2.2 in the Ranibizumab monotherapy group. A tendency towards a decrease in repeated treatments with Lucentis was observed in the combination group. Patients with predominantly classic lesions and smaller lesions who received combined treatment seemed to present better visual results with combined treatment than with monotherapy. It was also observed that the monotherapy group conserved the vision obtained after the initial three loading injections when these were followed by individualized therapy and, on average, fewer injections were necessary.

In the RADICAL (*Reduced Fluence Visudyne-Anti-VEGF-Dexamethasone In Combination for AMD Lesions*) study, other combinations, as opposed to monotherapy, were analyzed which included PDT with reduced fluence + Ranibizumab, PDT with reduced fluence + Ranibizumab + dexamethasone, and PDT with very reduced fluence + Ranibizumab + dexamethasone. In general, there was a tendency to fewer repetitions in the combined groups, with similar outcomes and adverse effects in all the groups (Hughes et al., 2009).

4.3 Other studies

Several studies have been published in which combination treatments were used. Most of them were made up of small groups or with short follow-ups. An interesting study by Augustin's group (2007) included 104 eyes; a triple treatment of PDT, dexamethasone, and

Bevacizumab intravitreal injections was used. The mean improvement obtained was 1.8 lines in almost ten months with a low number of retreatments. A vitrectomy was associated to inject a greater volume of liquid. In a record of cases published recently, 1,073 patients were treated with PDT and Bevacizumab as required, with 1.6 PDT and three injections in twelve months, achieving 82% of patients with a loss of fewer than three lines (Kaiser, 2009a).

An increase in the treatment-free interval was observed in the PDT + anti-VEGF combination. Wan (Wan et al., 2010) in their study on 174 patients with AMD treated with PDT followed by intravitreal injection of Bevacizumab, obtained a mean of 193 days of treatment-free interval, and 52% of the patients did not require postinduction retreatment in the ten months of follow-up. Moreover, other studies report stabilizing the lesion with one single dose of PDT induction + anti-VEGF after twelve months follow-up. The percentage of cases varies in different studies ranging from 39.6% to 46% to 48% (Mataix, 2010; Navea 2009; Smith, 2008).

A systematic review published recently (Das et al., 2011) establishes that intravitreal treatment with anti-VEGF obtains an increase in vision in AMD patients. Combination with PDT brings about a reduction in the number and frequency of retreatments and maintains the improvement in the long term. It seems fairly conclusive that combined treatment for neovascular AMD is a therapeutic option for diseases which do not respond to monotherapy. Moreover, it has the advantage of minimizing the risk monotherapy does have, that of potentiating other chronification pathways of the neovascular disease as it could allow compensatory stimulation of other pathogenic mechanisms of the disease. Tao and Jonas used a combination of Bevacizumab and high-dose-triamcinolone-acetonide in a group of 29 patients who were being treated with Bevacizumab in monotherapy and obtaining no visual or anatomic response. They achieved a visual improvement and reduction in macular thickness (Tao & Jonas, 2010). However, Rudinsky reported finding no benefit in combination therapy in a retrospective study which compared 139 eyes treated with Bevacizumab with 236 treated with PDT + Bevacizumab. The monotherapy eyes showed an improvement of 5.05 letters versus 4.8 letters with combination therapy; there was no difference between the groups. The monotherapy eyes received 3.32 injections versus 3.14 injections in the combination therapy group (Rudinsky et al., 2010).

A recent study (Forte et al., 2011) compared PDT + dexamethasone + anti-VEGF (Ranibizumab or Bevacizumab) triple therapy with Ranibizumab or Bevacizumab monotherapy. Sixty-one eyes were included in the first group and 40 in the second. The mean follow-up was between 14 and 16 months. The triple-therapy group required fewer treatments (1.92 vs 3.12); furthermore, on average, this group took longer to require the first retreatment (5.4 vs 3.6 months). There was a significant improvement in vision and foveal thickness in both groups, therefore it can be concluded that triple therapy reduces the number of retreatments when compared with anti-VEGF monotherapy.

Use of reduced-fluence PDT in combination with anti-VEGF is another method that is obtaining good outcomes. Spielberg treated 27 cases with reduced-fluence PDT followed by intravitreal Ranibizumab on the same day. Retreatments administered with Ranibizumab during the 24-month follow-up stabilized 84% of the patients' vision or improved it at month 24 (Spielberg & Leys, 2010). A prospective comparative study was performed on 85 AMD patients divided into two groups, one treated with intravitreal Bevacizumab (IVB)

monotherapy and the other with IVB combined with low-fluence PDT (300 mW/cm² for 83 s, 25 J/cm²) with a twelve-month follow-up. The combination of IVB with low fluence PDT for the treatment of classic or predominantly classic neovascular AMD worked in a synergistic fashion with a significant reduction in IVB reinjection rate (Costagliola et al., 2009).

Kovacs recently published a retrospective analysis of triple combination therapy with IVB, posterior sub-tenon's triamcinolon acetonide and low fluence verteporfin PDT with good visual results and a reduction in macular thickness with a twelve-month follow-up (Kovacs et al., 2011).

4.4 Our experience

Our group has considerable experience in treatment combining PDT with anti-VEGF. In 2006 we began to treat patients with wet AMD using this method. A sample of this work appears in two publications showing the results of two groups using different treatments, one PDT + Bevacizumab and the other PDT + Ranibizumab.

The study groups included patients with active subfoveal and juxtafoveal CNV secondary to AMD, naïve cases, initial BCVA \geq 20/400, and maximum lesion size under 5.400 μ m defined on fluorescein angiography (FA).

The treatment included a single, initial dose of PDT + Bevacizumab/Ranibizumab. Criteria for retreatment were based on OCT, BCVA, and FA; an increase in central retinal thickness of over 100 μ m or the presence of subretinal fluid was a criterion for retreatment. Loss of more than five letters of vision since the previous visit or the presence of new macular bleeding was also a criterion for retreatment if any kind of fluid was present on the OCT. In both situations an FA was performed and treatment with PDT + Bevacizumab/Ranibizumab was provided if a CNV increase or fluorescein leakage was observed. If the FA did not show a CNV increase or fluorescein leakage, treatment was provided with Ranibizumab alone. Photodynamic treatment was only provided when over three months had elapsed since the previous PDT. If development of macular atrophic changes seemed to be the cause of vision loss, it was not treated.

We studied 53 eyes of 53 patients treated with PDT + Ranibizumab and 63 eyes of 63 patients treated with PDT + Bevacizumab, with a twelve-month follow-up. The demographic characteristics and the characteristics of the CNV were similar in both groups. The CNV localization was mainly subfoveal in both groups, with a mean size of 2386 and 2064 μ m in the Ranibizumab and Bevacizumab groups, respectively.

Evolution of retinal thickness: The OCT baseline central retinal thickness was 372 μ m. It decreased to 251 μ m in the first month of treatment and remained the same throughout the follow-up, reaching a mean thickness of 254 μ m twelve months later in the group with the Ranibizumab combination, with a mean reduction of -118 μ m. The OCT baseline central retinal thickness was 357 μ m, decreasing to 246 μ m in the first month of treatment and reaching a mean thickness of 227 μ m twelve months later in the group with the Bevacizumab combination, with a mean reduction of -129 μ m. Separate analysis of the two groups with Student's t-test showed the reduction in retinal thickness was statistically significant ($p < 0.05$) from the first month, remaining the same throughout the year.

	N	Follow-up (months)	Treatment	Loss < 15 letters	Gain ≥ 25 letters	VA change from baseline	Number of treatments (average)
MARINA	240	12	Ranibizumab 0,5 mg. (monthly)	94,6 %	33,8 %	+7,2	13 Ranibizumab
ANCHOR	146	12	Ranibizumab 0,5 mg. (monthly)	96,4%	40,3%	+11,3	13 Ranibizumab
PROTECT	32	4	PDT + Ranibizumab 0,5mg monthly	96,9%			1 PDT 4 Ranibizumab
FOCUS	106	12	PDT + Ranibizumab 0,5mg monthly	90,5%	23,8%	+4,9	1,4 PDT 13 Ranibizumab
MONT BLANC	122	12	PDT + Ranibizumab (3 initial doses) retreatments as required	87%	18%	+2,5	1,7 PDT 4,8 Ranibizumab
RADICAL	43	12	PDT (1/2 fluence) + Ranibizumab 0,5mg (3 initial doses) retreatments as required	88%	26%	+5	
Navea et. al.	63	12	PDT + Bevacizumab 1,25mg (single initial doses) retreatments as required	95,2%	19%	+5,7	1,46 PDT 2 Bevacizumab
Mataix et. al.	53	12	PDT + Ranibizumab (single initial doses) retreatments as required	92,3%	32,7%	+7,2	1,22 PDT 2,37 Ranibizumab
Kaiser et. al.	701	12	PDT + Ranibizumab (single initial doses) retreatments as required	82%	36%	+6	1,6 PDT 3,2 Bevacizumab
Rudinsky et. al.	236	12	PDT + Bevacizumab			+4,8	3,14 Bevacizumab
Spielberg et. al.	27	12 / 24	PDT (1/2 fluence) + Ranibizumab 0,5mg (3 initial doses) retreatments as required	84% (24 months)	16% (24 months)	+7,2 (24 months)	5,1 Bevacizumab (12 months) 7,1 Bevacizumab (24 months)

Table 1. Summary of studies with PDT + Anti-VEGF

Visual Acuity Evolution: In the Ranibizumab group, the mean initial BCVA was 8.26 lines which increased to 10.3 lines in the first month of treatment. This gain was maintained until the sixth month, after which it decreased slightly to 9.72 lines twelve months later, thus obtaining a mean increase of 1.21 lines, which is equivalent to a gain of 6.05 letters after twelve months. This slight decrease is due to the severe and occasional loss of vision in a few cases after the sixth month which affected the total mean. The mean initial BCVA was 8.41 lines in the Bevacizumab group and increased from the first month of treatment to 9.38 lines. This gain was maintained throughout the twelve months, undergoing small variations and reaching 9.54 lines, obtaining a mean increase of 1.12 lines after twelve months, which is a gain of 5.6 letters. The percentage of cases that lost 15 letters was 95.2% in the PDT + Bevacizumab group and 92.3% in the PDT + Ranibizumab group. Visual gain was 58.7% and 57.7%, respectively (Figures 6, 7).

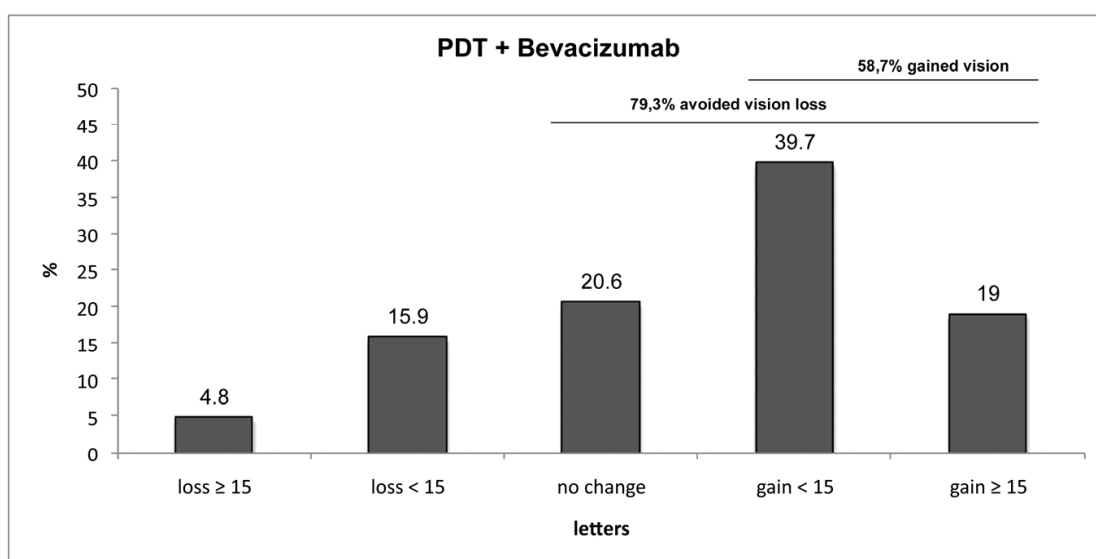


Fig. 6. Percentage of visual acuity variations throughout the follow-up in patients treated with PDT + Bevacizumab: 95.2% of cases lost fewer than 15 letters after twelve months. Visual loss was avoided in 79.3% of cases and 58.7% gained vision.

The distribution of the lines of vision between the beginning and end of the follow-up is statistically significant (p -value < 0.001) in both groups. The Mann-Whitney test concludes that the visual gain is significantly better (p -value < 0.05) in the first six months in the Ranibizumab group, but there were no differences between the two groups after one year.

Retreatments: A record of the number of treatments was kept throughout the study for both groups. The patients in the group treated with Bevacizumab received a mean of 1.46 therapies and 1.92 intravitreal injections, and those treated with Ranibizumab received a mean of 1.23 therapies and 2.38 intravitreal injections. The Mann-Whitney test showed that the Bevacizumab group received significantly more therapies (p -value < 0.05), but there was no difference in the number of intravitreal injections. In 21 cases (39.6%) only a single initial combination therapy was required in the Ranibizumab group versus 29 cases (46%) in the Bevacizumab group to keep the lesion stable until the end of the follow-up. In the Ranibizumab group, 77.4% of the patients were treated with a maximum of three injections and 79.2% of the patients needed a single PDT treatment at the initiation of the treatment. In the Bevacizumab group, 87.3% and 61.9% of the patients were treated, respectively.

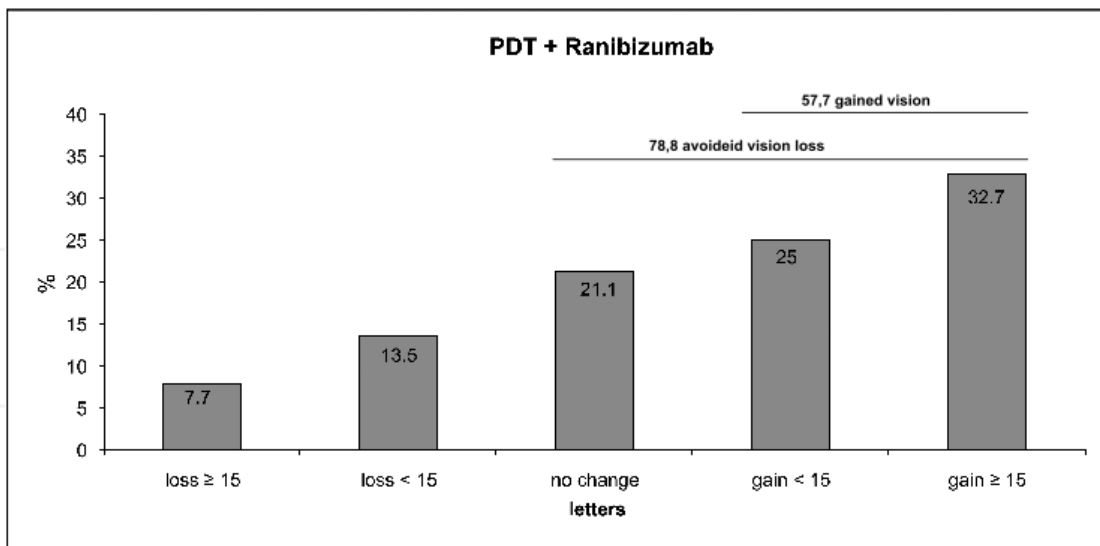


Fig. 7. Percentage of visual acuity variations throughout the follow-up in patients treated with PDT + Ranibizumab: 92.3% of cases lost fewer than 15 letters after twelve months. Visual loss was avoided in 78.8% of cases and 57.7% gained vision.

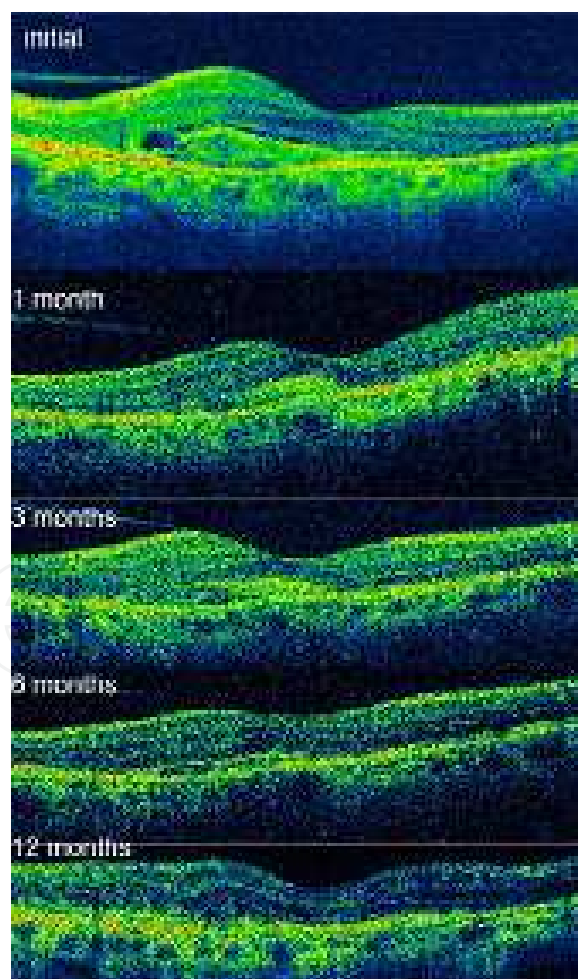


Fig. 8. Evolution of OCT from the beginning of the treatment until the end of the follow-up twelve months later.

Our results suggest that a combination of PDT and anti-VEGF is a good option for treating CNV in AMD more effectively by maintaining good visual results and decreasing the need for retreatments.

5. Other therapies

The etiology of AMD is multifactorial and there are several mechanisms that can lead to irreversible loss of vision. To achieve a complete therapy for CNV, we should not simply focus on neovessels, but rather act on both the vascular component (mature and immature vessels) and the non-vascular component (inflammatory cells, cytokines, glial cells, myofibroblasts, fibrocytes, etc.).

5.1 The vascular component (immature and mature vessels)

The antiangiogenesis agents currently used in the treatment of AMD inhibit VEGF by blocking the growth factor in the extra-cellular space, thereby preventing access to its receptor. Several VEGF inhibitors, including **Bevacizumab and Ranibizumab**, have demonstrated excellent safety and efficacy in exudative AMD (Rosenfeld PJ et al., 2006; Spaide RF et al., 2006b). The current strategy of blocking VEGF in the extracellular space may be an inadequate approach for long-term control of AMD. Combining drugs that act at different points of the angiogenesis pathway has the potential to build on the benefits of extracellular VEGF inhibitors, but a more profound inhibition of the disease process may require activity in additional pathways of the disease.

VEGF Trap-Eye is a fully human soluble VEGF receptor fusion protein that binds all forms of VEGF-A along with the related placental growth factor (PlGF). VEGF Trap-Eye is made by fusing two different domains from VEGF receptors 1 and 2 onto a human Fc fragment. VEGF Trap-Eye has tighter VEGF binding than the natural receptor and has greater affinity than the current VEGF inhibitors (Steward & Rosenfeld, 2007). Two parallel Phase 3 trials have been developed in patients with wet AMD (VIEW 1 and VIEW 2). VEGF Trap-Eye is being dosed at 0.5 mg every four weeks, 2 mg every four weeks, and 2 mg every eight weeks in direct comparison with Ranibizumab administered at 0.5 mg every four weeks during the first year of the studies. The primary endpoint was statistical non-inferiority in the proportion of patients who maintained (or improved) vision over 52 weeks compared to Ranibizumab. A generally favorable safety profile was observed for both VEGF Trap-Eye and Ranibizumab.

Small interfering RNA agents, such as **RTP-801i and Bevasiranib**, which turn off target genes, are extremely promising in a variety of therapeutic areas. **Bevasiranib** is designed to block the production of VEGF directly by inhibiting the messenger RNA from the VEGF gene. Studies in mice have demonstrated that Bevasiranib can inhibit and regress ocular neovascularization (Reich et al., 2003). Studies in rabbits have shown that an intravitreal injection of Bevasiranib achieved good distribution in the retina and in RPE (Dejneka NS et al., 2008). The agent is well distributed after intravitreal injection and well tolerated by human subjects (Karagiannis & El-Osta, 2005). A Phase 3 Clinical Trial tests this agent in combination with Ranibizumab because potentially the drug may prevent further production of VEGF while Ranibizumab blocks the VEGF that is present.

Experimental models show that monotherapy with anti-VEGF agents inhibits new vascular formation but has little effect on existing capillaries. Pericyte coverage provides survival

signals to neovascular endothelial cells and hence makes them resistant to VEGF (Bergers et al., 2003). Pericytes are essential in vascular maturation so their inhibition is important in inhibiting neovascularization and the regression of new mature vessels. **Anti-PDGF (Platelet-derived growth factor)** treatment strips away pericytes to leave the endothelial cells unprotected and vulnerable to anti-VEGF treatment (Erber R. et al., 2004). The combination of anti-VEGF and anti-PDGF produces inhibition and regression of corneal and choroidal neovascularization compared with anti-VEGF treatment alone. In models of pathologic tumor angiogenesis, strategies involving both anti-VEGF and anti-PDGF have also produced regression when an anti-VEGF therapy alone failed (Jo N et al., 2006).

Platelet-derived growth factor, which has an important role in recruiting the pericytes critical to maturation of vessel walls, may also be a viable target to augment the effects of a VEGF inhibitor. A recent phase 1 clinical trial with anti-PDGF (E10030) included patients with subfoveal CNV who received three monthly doses of E10030 in combination with a standard dose of Ranibizumab. The preliminary findings reveal a reduction in neovascular size (neovascular regression) in all patients. This regression is associated with a marked improvement in visual acuity, gain ≥ 15 ETDRS letters: 4 weeks (32%) 12 weeks (59%) and gain in numbers of letters: 4 weeks (10.9%) 12 weeks (14%). However, it is not yet clear whether the improvement was due to the E10030/Ranibizumab combination or simply a Ranibizumab effect (Boyer DS et al., 2009).

The inhibition of **Insulin-like growth factor** could be another option in the treatment of neovessels. It leads to endothelial cell proliferation and inhibits apoptosis of endothelial cells, the nicotinic acetylcholine receptor, which also induces endothelial cell migration, and tubular binding proteins, which govern endothelial cell shape formation.

5.2 The nonvascular component (inflammatory cells, cytokines, glial cells, myofibroblasts, and fibrocytes)

Antiangiogenesis agents are effective for preventing progression of CNV in a substantial proportion of patients, although regression is not typically observed. Experimental studies indicate that newly formed capillaries are no longer susceptible to regression with anti-VEGF agents within about two weeks after formation. Antiangiogenesis agents may still be effective for preventing the development of additional capillaries or reducing leakage in vessels invading the retina, but the persistence of CNV may stimulate inflammation or other pathologic processes that eventually result in vision loss due to the formation of fibrosis. Prevention of fibrosis is essential to the preservation of VA.

Radiation therapy has long been used to control fibrosis in a variety of tissues. In AMD, radiation may be particularly attractive because there is evidence of synergistic inhibition of neovascularization when radiation is combined with antiangiogenesis drugs (Nieder C. et al., 2007). Historically, radiation monotherapy sufficient to eradicate CNV effectively has been associated with a modest benefit for AMD. The growing evidence that antiangiogenic agents can increase the antitumor efficacy of radiotherapy includes studies in animal models: the combination of radiation and antiangiogenesis agents had a greater effect in reducing tumor regrowth than either alone (Gorski DH et al., 1999). In another animal study, the use of anti-VEGF and anti-PDGF agents in combination with radiation showed a significantly greater antitumor effect relative to radiation alone (Timke C et al., 2008). Mammalian target of rapamycin (mTOR) inhibitors (Sirolimus) radiosensitize cancer cells *in*

vitro and several studies have demonstrated their ability to radiosensitize *in vivo* (Shinohara ET et al., 2005). In a Phase I recent report, CNV was irradiated in a few patients with strontium 90 delivered by a specialized, 20-gauge, intravitreal probe that is placed over the lesion intraoperatively. All patients underwent a vitrectomy before radiotherapy and were treated with Bevacizumab before and after radiation. In a 4-minute exposure, the estimated dose at the lesion was 24 Gy. Results were excellent, with 76% of patients gaining at least 10 letters of visual acuity. Most of the responders required no more than one additional injection of Bevacizumab over the first year of follow-up.

Integrins as a mediator of adhesion both between cells and between cells and extracellular matrix, have a role in a variety of proliferative processes, including fibrosis. Integrin also seems to have a direct influence on proliferative kinase signaling, a mediator of adhesion between cells and extracellular matrix. It is a transmembrane protein that binds to extracellular matrix proteins (fibronectin) allowing cell adhesion and cytoskeletal organization. The $\alpha 5\beta 1$ is especially important in pathologic angiogenesis (not in normal vasculature) (Kim S et al., 2000). Many of the cellular effects of VEGF are duplicated downstream in the angiogenic cascade by the interaction between the transmembrane integrin $\alpha 5\beta 1$ receptor and its natural ligand, fibronectin. In addition to VEGF, the interaction of integrin $\alpha 5\beta 1$ with fibronectin is critical to endothelial cell survival. Integrin $\alpha 5\beta 1$ has been shown to be upregulated in all the cells associated with AMD pathogenesis, including endothelial cells, retinal pigment epithelium cells, macrophages, and fibroblasts. This implicates this molecule in multiple pathogenic processes involved in AMD, including neovascularization, vascular leakage, and inflammation (Klatt K et al., 2007). Two studies have demonstrated that once neovascular tissue begins to grow, the extracellular matrix needs to adhere to the neovascular endothelial cells for them to survive (Hynes RO, 2002; Hodivala-Dilke et al., 2003). Inhibiting the ligation of integrin $\alpha 5\beta 1$ and fibronectin may disrupt the process of neovascularization, regardless of the upstream growth factor pathway. **Volociximab** (M200), a chimeric monoclonal antibody targeting integrin $\alpha 5\beta 1$ to block its ligation of fibronectin, has robustly inhibited human umbilical vein endothelial cell tube formation in laboratory tests. It does so regardless of an initial growth factor stimulant. It has also inhibited neovascularization in primate choroid tissue and tumor angiogenesis in rabbits (Ramakrishnan V et al., 2006; Bhaskar V et al., 2008).

Vascular disrupting agents also have potential for the inhibition of fibrosis as well as formation of new blood vessels. Unlike antiangiogenesis agents that block formation of new blood vessels, vascular-disrupting agents attack newly formed endothelium by disrupting connectivity between cells. This activity is expected to be complementary to anti-VEGF agents because it takes place at a later stage of neovascularization. It may also exert an important antifibrotic effect. A vascular-disrupting agent called **combretastatin A4P** (CA4P) has been evaluated in a Phase 1 study in humans with myopic macular degeneration, where it demonstrated relatively modest effects, but the characteristics of AMD may be more suitable for its activity.

Compared with age-matched controls, individuals with AMD demonstrate elevations in a variety of systemic biomarkers of inflammation, including activated monocytes and interleukin-6 (Vine AK et al., 2005 & Seddon et al., 2005). An increased risk of AMD in individuals with polymorphisms in their genes coding for the complement regulatory proteins is another signal that complement driven inflammation is perhaps an important mediator of this disease (Klein RJ et al., 2005). Although terminal elements of the complement pathway are

implicated in the formation of drusen in primate models and human postmortem specimens (Anderson DH et al., 2002), patients with membranoproliferative glomerulonephritis type II, a disorder characterized by uncontrolled complement cascade activation, develop drusen histologically identical to drusen associated with AMD (Mullins RF et al., 2001). These findings support the potential for adding therapies directed at complement activation to those that already demonstrate activity in AMD, but it is not yet clear what incites the complement cascade or how to inhibit it at its source. Therefore, to attack the complement pathway, it may be necessary to address both membrane attack complex and C5a, while preserving the beneficial antimicrobial function of C3 (Giese MJ et al., 1994). There are numerous questions about where and when to block complement to inhibit best progression of AMD. An experimental treatment, known as ARC 1905, has been associated with the inhibition of C5a and C5b-9. In experimental models, this **inhibitor of C5aR** has demonstrated measurable activity in reducing the influx of neutrophils and macrophages and has also been associated with suppression of CNV (Adamis AP, 2009).

Mammalian target of rapamycin, a protein kinase linked to a variety of gene transcriptions and protein production, including VEGF, is strongly implicated in a number of proliferative processes and is a targetable mediator of fibrosis. Palomid 529 (mTOR inhibitor) has demonstrated a strong antifibrotic effect in retinal fibrosis models, including laser-induced retinopathy. The antifibrotic activity of this inhibitor has been measured, across a variety of endpoints, including inhibition of the inflammatory response as well as the extent of the fibrotic scar. Other mammalian targets of rapamycin inhibitors, such as sirolimus, have demonstrated good antiangiogenic, antiinflammatory, and antifibrotic effects (Chiang GC et al., 2007) and inhibit the response to interleukin-2 (IL-2) and thereby block activation of T- and B-cells.

6. Conclusion

The potential for a single therapy to control the complex process of AMD seems to be relatively remote. It is not clear that a combination of different agents, working on the same pathway of extracellular VEGF inhibition, will reduce AMD progression, but there may be a strong potential for additive or synergistic effects from combining drugs with independent mechanisms. The current strategy of blocking VEGF in the extracellular space may be an inadequate approach for long-term control of AMD. Combining drugs that act at different points of the angiogenesis pathway has the potential to build on the benefits of extracellular VEGF inhibitors, but a more profound inhibition of the disease process may require activity in additional pathways of the disease.

7. References

- Adamis AP. (2009). The Rationale for drug combinations in Age related macular degeneration. *Retina*, Vol. 29, No. Supplement 6, (June 2009), pp. 42-44, ISSN 0275-004X
- Anderson DH.; Mullins RF.; Hageman GS. & Johnson LV. (2002). A role for local inflammation in the formation of drusen in the aging eye. *American Journal Ophthalmology*, Vol. 134, No. 3, (September 2002), pp.411-431, ISSN 0002-9394

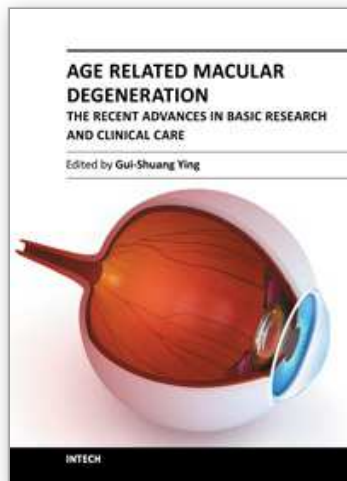
- Augustin AJ.; Puls S. & Offermann I. (2007). Triple therapy for choroidal neovascularization due to age-related macular degeneration: verteporfin PDT, bevacizumab, and dexamethasone. *Retina*, Vol. 27, No. 2, (February 2007), pp. 133-140, ISSN 0275-004X
- Awan MA.; Chavan R.; Peh KK. & Yang YC. (2009). The effect of the first application of verteporfin photodynamic therapy on lesion growth in choroidal neovascularisation and its potential impact on combination therapy. *Clinical & Experimental Optometry*, Vol. 92, No. 5, (September 2009), pp. 440-443, ISSN 144-0938
- Benjamin LE.; Golijanin D.; Itin A.; Pode D. & Keshet E. (1999). Selective ablation of immature blood vessels in established human tumors follows vascular endothelial growth factor withdrawal. *The Journal of Clinical Investigation*. Vol. 103, No. 2, (January 1999), pp.159-165, ISSN 0021-9738
- Bergers G.; Song S.; Meyer-Morse N.; Bergsland E. & Hanahan D. (2003). Benefits of targeting both pericytes and endothelial cells in the tumor vasculature with kinase inhibitors. *The Journal of Clinical Investigation*. Vol 111, No. 9, (May 2003), pp. 1287-1295, ISSN 0021-9738
- Bhaskar V.; Fox M.; Breinberg D.; Wong MH. & Wales PE. (2008). Volociximab, a chimeric integrin alpha5beta1 antibody, inhibits the growth of VX2 tumors in rabbits. *Investigational New Drugs*, Vol. 26, No. 1, (February 2008), pp. 7-12, ISSN 0167-6997
- Boyer DS. & Ophthotec Anti-PDGF in AMD Study Group. (2009). Combined Inhibition of Platelet Derived (PDGF) and Vascular endothelial Growth Factor (VEGF) for the Treatment of Nevascular Age-Related Macular Degeneration : Results of a Phase 1 study. *Proceedings of ARVO 2009 Annual Meeting*, IOVS E-abstract 1260, ISSN 1552-5783 Fort Lauderdale, Florida, USA, may 3-7, 2009
- Brown DM.; Kaiser PK.; Michels M.; Soubrane G. & Heier JS. (2006). ANCHOR Study Group. Ranibizumab versus verteporfin for neovascular age- related macular degeneration. *The New England Journal of Medicine*, Vol. 355, No. 14, (October 2006), pp. 1432- 1444, ISSN 0028-4793
- Costagliola C.; Romano MR.; Rinaldi M.; dell'Omo R. & Chiosi F. (2010). Low fluence rate photodynamic therapy combined with intravitreal bevacizumab for neovascular age-related macular degeneration. *The British Journal of Ophthalmology*, Vol. 94, No. 94, (February 2010), pp. 180-184, ISSN 0007-1161
- Chiang GG. & Abraham RT. (2007). Targeting the mTOR signaling net-work in cancer. *Trends in Molecular Medicine*, Vol. 13, No. 10, (October 2007), pp. 433-442, ISSN 1471-4914
- Das RA.; Romano A.; Chiosi F.; Menzione M, & Rinaldi M. (2011). Combined treatment modalities for age related macular degeneration. *Current Drug Targets*, Vol. 12, No. 2, (February 2011), pp. 182-189, ISSN 1389-4501
- Dejneka NS.; Wan S.; Bond OS.; Kornbrust DJ. & Reich SJ. (2008). Ocular biodistribution of bevasiranib following a single intravitreal injection to rabbit eyes. *Molecular Vision*, Vol. 18, No. 14. (May 2008), pp. 997-1005, ISSN 1090-0535.
- Dorrell MI.; Aguilar E.; Scheppke L.; Barnett FH. & Friedlander M. (2007). Combination angiostatic therapy completely inhibits ocular and tumor angiogenesis. *Proc Natl Acad Sci U S A*. Vol. 104, No. 3, (January 2007), pp. 967- 972, ISSN 0027-8424
- Erber R.; Thurnher A.; Katsen AD.; Groth G. & Kerger H. (2004). Combined inhibition of VEGF and PDGF signaling enforces tumor vessel regression by interfering with pericyte-mediated endothelial cell survival mechanisms. *FASEB J*. Vol. 18, No. 2, (February 2004), pp. 338-340, ISSN 1530-6860

- Ferrara N. & Gerber HP. (2001). The role of vascular endothelial growth factor in angiogenesis. *Acta Haematologica*, Vol. 106, No. 4, (2001), pp. 148-156, ISSN 0001-5792
- Ferrara N.; Gerber HP. & Le Couter J. (2003). The Biology of VEGF and its receptors. *Nature Medicine*, Vol. 9, No. 6, (June 2003), pp. 669-676, ISSN 1078-8956
- Fingar VH. (1996). Vascular effects of photodynamic therapy. *Journal of clinical laser medicine & surgery*, Vol. 14, No. 5, (October 1996), pp. 323-328, ISSN 1044-5471
- Forooghian F.; Cukras C.; Meyerle CB.; Chew EY. & Wong WT. (2009). Tachyphylaxis after intravitreal bevacizumab for exudative age-related macular degeneration. *Retina*, Vol. 29, No. 6, (June 2009), pp. 723-731, ISSN 0275-004X
- Forte R.; Bonavolontà P.; Benayoun Y.; Adenis JP. & Robert PY. (2011). Intravitreal ranibizumab and bevacizumab in combination with full-fluence verteporfin therapy and dexamethasone for exudative age-related macular degeneration. *Ophthalmic Research*, Vol. 45, No. 3, (September 2011), pp. 129-134, ISSN 0030-3747
- Gerber HP.; Dixit V. & Ferrara N. (1998). Vascular endothelial growth factor induces expression of the antiapoptotic proteins Bcl-2 and A1 in vascular endothelial cells. *Journal of biological chemistry*, Vol. 273, No 21, (May 1998), pp. 13313-13316, ISSN 0021-9258
- Giese MJ.; Mondino BJ.; Glasgow BJ.; Sumner HL. & Adamu SA- (1994). Complement system and host defense against staphylococcal endophthalmitis. *Investigative ophthalmology & visual science*, Vol. 35, No 3, (March 1994), pp. 1026-1032, ISSN 0146-0404
- Gorski DH.; Becket MA.; Jaskowiat NT.; Calvin DP. & Mauceri HJ. (1999). Blockage of the endothelial growth factor stress response increases the antitumor effects of ionizing radiation. *Cancer Research*. Vol. 59, No. 14, (July 1999), pp. 3374-3378, ISSN 0008- 5472
- Granville DJ.; Jiang H.; McManus BM. & Hunt DW. (2001). Fas ligand and TRAIL augment the effect of photodynamic therapy on the induction of apoptosis in JURKAT cells. *International Immunopharmacology*, Vol. 1, No 9-10, (September 2001), pp. 1832-1840. ISSN 1567-5769
- Gragoudas ES.; Adamis AP.; Cunningham ET Jr.; Feinsod M. & Guyer DR. (2004). VEGF Inhibition Study in Ocular Neovascularization Clinical Trial Group. Pegaptanib for neovascular age-related macular degeneration. *New england journal of medicine*, Vol. 351, No 27, (December 2004), pp. 2805-281, ISSN 0028-4793
- Heier JS.; Boyer DS.; Ciulla TA.; Ferrone PJ. & Jumper JM. (2006). FOCUS Study Group. Ranibizumab combined with verteporfin photodynamic therapy in neovascular age-related macular degeneration: year 1 results of the FOCUS Study. *Archives Ophthalmology*, Vol. 124, No. 11, (November 2006), pp. 1532-1542, ISSN 0003-9950
- Heier JS. (2009). Pathology beyond neovascularization. New targets in Age-Related Macular Degeneration.. *Retina*, Vol. 29, No 6, (June 2009), pp. 39-41, ISSN 0275-004X
- Hodivala-Dilke KM.; Reynolds AR. & Reynolds LE. (2003). Integrins in angiogenesis: multitasking molecules in a balancing act. *Cell and tissue research*, Vol. 314, No. 1, (October 2003), pp. 131-144, ISSN 0302-766X
- Holz FG., Pauleikhoff D.; Klein R. & Bird AC. (2004). Pathogenesis of lesions in late age-related macular disease. *American Journal Ophthalmology*, Vol. 137, No. 3, (March 2004), pp. 504-510, ISSN 002-9394
- Hynes RO. (2002). Integrins: bidirectional, allosteric signaling machines. *Cell*, Vol. 110, No. 6, (September 2002), pp. 673-687, ISSN 0092-8674
- Hughes M. & Sang DN. (2009). Triple plus therapy compared with monthly ranibizumab reduces the retreatment rate in a randomized study in age-related macular

- degeneration. Proceeding of ARVO 2009 annual meeting, IOVS 2009 E-abstract 1903, ISSN 1552-5783, Fort Lauderdale, Florida, USA, May 3-7, 2009.
- Jain RK. (2005). Normalization of tumor vasculature: an emerging concept in antiangiogenic therapy. *Science*, Vol. 307, No. 5706, (January 2005), pp. 58–62, ISSN 1095-9203
- Jiménez Cuenca B. (2003). Mechanism of inhibition of tumoral angiogenesis by thrombospondin-1. *Nefrologia*, Vol. 23, No. suppl 3, (2003), pp. 49-53, ISSN 0211-6995
- Jo N.; Mailhos C.; Ju M.; Cheung E. & Bradley J. (2006). Inhibition of platelet-derived growth factor B signaling enhances the efficacy of anti-vascular endothelial growth factor therapy in multiple models of ocular neovascularization. *American Journal of Pathology*, Vol. 168, No. 6, (June 2006), pp. 2036–2053, ISSN 0002-9440
- Kaiser PK.; Boyer DS.; Garcia R.; Hao Y. & Hughes MS. (2009a) Verteporfin photodynamic therapy combined with intravitreal bevacizumab for neovascular age-related macular degeneration. *Ophthalmology*. Vol. 116, No. 4, (April 2009), pp. 747-755, ISSN 0161-6420
- Kaiser PK. (2009b). Overview of radiation trials for age-related macular degeneration. *Retina*. Vol. 29, No. suppl 6, (June 2009), pp. 34-35, ISSN 0275-004X
- Kaiser PK. (2009c). Strategies for inhibiting vascular endothelial growth factor. *Retina*. Vol 29, No. suppl 6, (June 2009), pp. 15-17, ISSN 0275-004X
- Karagiannis TC. & El-Osta A. (2005). RNA interference and potential therapeutic applications of short interfering RNAs. *Cancer Gene Therapy*, Vol. 12, No. 10, (October 2005), pp. 787–795, ISSN 0929-1903
- Kim S.; Bell K.; Mousa SA. & Varner JA. (2000). Regulation of angiogenesis in vivo by ligation of integrin $\alpha 5\beta 1$ with the central cell-binding domain of fibronectin. *American Journal of Pathology*, Vol. 156, No 4, (April 2000), pp. 1345–1362, ISSN 0002-9440
- Klatt K.; Zahn CG., Heier JS.; Daniel P.; Holz FG. & Loeffler KU. (2007). Integrin $\alpha 5\beta 1$ in preretinal membranes associated with proliferative vitreoretinopathy (PVR). Proceedings of ARVO 2007 Annual meeting, Invest ophthalmol Vis Sci 2007 E-abstract 1233, ISSN 1552-5783, Fort Lauderdale, Florida, USA, May -10, 2007
- Klein RJ.; Zeiss C.; Chew EY.; Tsai JY. & Sackler RS. (2005). Complement factor H polymorphism in age-related macular degeneration. *Science*, Vol 308, No 5720, (April 2005), pp. 385–390, ISSN 1095-9203
- Kovacs KD.; Quirk MT.; Kinoshita T.; Gautam S. & Ceron OM. (2011). A retrospective analysis of triple combination therapy with intravitreal bevacizumab, posterior sub-tenon's triamcinolone acetate, and low-fluence verteporfin photodynamic therapy in patients with neovascular age-related macular degeneration. *Retina*, Vol 31, No 3, (March 2011), pp. 446-452, ISSN 0275-004X
- Mataix J.; Desco MC.; Palacios E.; Garcia-Pous M. & Navea A. (2009). Photodynamic therapy for age-related macular degeneration treatment: epidemiological and clinical analysis of a long-term study. *Ophthalmic surgery lasers & imaging*. Vol. 40, No 3. (May-June 2009), pp. 277-284, ISSN 1542- 8877
- Mataix J.; Palacios E.; Carmen DM.; Garcia-Pous M. & Navea A. (2010). Combined ranibizumab and photodynamic therapy to treat exudative age-related macular degeneration: an option for improving treatment efficiency. *Retina*. Vol. 30, No 8. (September 2010), pp. 1190-1196, ISSN 0275-004X
- Miller JW.; Schmidt-Erfurth U.; Sickenberg M.; Pournaras CJ. & Laqua H. (1999). Photodynamic therapy with verteporfin for choroidal neovascularization caused by age-related macular degeneration: results of a single treatment in a phase 1 and 2 study. *Archives of Ophthalmology*, Vol. 117, No 9, (September 1999), pp. 1161–1173, ISSN 0003-9950

- Mullins RF.; Aptsiauri N. & Hageman GS. (2001). Structure and composition of drusen associated with glomerulonephritis: implications for the role of complement activation in drusen biogenesis. *Eye*, Vol. 15, No 3, (June 2001), pp. 390-395, ISSN 0950-222X
- Navea A.; Mataix J.; Desco MC.; Garcia-Pous M. & Palacios E. (2009). One-year follow-up of combined customized therapy. Photodynamic therapy and bevacizumab for exudative age-related macular degeneration. *Retina*; Vol. 29, No. 1, (January 2009), pp. 13-9, ISSN 0275-004X
- Nieder C.; Wiedenmann N.; Andratschke NH.; Astner ST. & Molls M. (2007). Radiation therapy plus angiogenesis inhibition with bevacizumab: rationale and initial experience. *Reviews of recent clinical trials*, Vol. 2, No. 3, (September 2007), pp. 163-168, ISSN 1574-8871
- Ramakrishnan V.; Bhaskar V.; Law DA.; Wong MH. & DuBridg RB. (2006). Preclinical evaluation of an anti- $\alpha 5\beta 1$ integrin antibody as a novel anti-angiogenic agent. *Journal of experimental therapeutics & oncology*, Vol. 5, No.4, (2006), pp. 273-286, ISSN 1533-869X
- Regillo CD.; Brown DM.; Abraham P. Yue H. & Ianchulev T. (2008). Randomized, double-masked, sham-controlled trial of ranibizumab for neovascular age-related macular degeneration: PIER Study year 1. *American Journal of Ophthalmology*, Vol 145, No 2, (February 2008), pp. 239 -248, ISSN 0002-9343
- Rosenfeld PJ.; Brown DM.; Heier JS.; Boyer DS. & Kaiser PK. (2006) MARINA Study Group. Ranibizumab for neovascular age-related macular de- generation. *N Engl J Med*, Vol. 355, No 14. (October 2006), pp. 1419-1431, ISSN 0028-4793
- Rudnisky CJ.; Liu C.; Ng M.; Weis E. & Tennant MT. (2010). Intravitreal bevacizumab alone versus combined verteporfin photodynamic therapy and intravitreal bevacizumab for choroidal neovascularization in age-related macular degeneration: visual acuity after 1 year of follow-up. *Retina*; Vol. 30, No. 4, (April 2010), pp. 548-554, ISSN 0275-004X
- Schaal S.; Kaplan HJ. & Tezel TH. (2008). Is there tachyphylaxis to intravitreal anti-vascular endothelial growth factor pharmacotherapy in age-related macular degeneration?. *Ophthalmology*. Vol. 115, No. 12, (December 2008), pp. 2199-2205, ISSN ISSN 0161-6420
- Schmidt-Erfurth U.; Scholtzer-Schrehard U.; Cursiefen C.; Michels S. & Beckendorf A. (2003). Influence of photodynamic therapy on expression of vascular endothelial growth factor (VEGF), VEGF receptor 3, and pigment epithelium-derived factor. *Invest Ophthalmol Vis Sci*, Vol. 44, No. 10, (October 2003), pp. 4473-4480, ISSN 0146-0404
- Schmidt-Erfurth U.; Wolf S.; PROTECT Study Group. (2008). Same-day administration of verteporfin and ranibizumab 0.5 mg in patients with choroidal neovascularisation due to age-related macular degeneration. *Br J Ophthalmol*, Vol. 92, No. 12, (December 2008), pp. 1628-35, ISSN 1468-2079
- Schmidt-Erfurth U.; Kiss C. & Sacu S. (2009). The role of choroidal hypoperfusion associated with photodynamic therapy in neovascular age-related macular degeneration and the consequences for combination strategies. *Prog Retin Eye Res*, Vol. 28, No.2, (March 2009), pp. 145-54, ISSN 1350-9462
- Seddon JM.; George S.; Rosner B. & Rifai N. (2005). Progression of age-related macular degeneration: prospective assessment of C-reactive protein, interleukin 6, and other cardiovascular biomarkers. *Arch Ophthalmol*. Vol. 123, No. 6, (June 2005), pp. 774-782. ISSN 0003-9950
- Shinohara ET.; Cao C.; Niermann K.; Mu Y. & Zeng F. (2005). Enhanced radiation damage of tumor vasculature by mTOR inhibitors. *Oncogene*, Vol. 24, No. 35. (August 2005), pp. 5414 -5422, ISSN 1476-5594

- Smith BT.; Dhalla MS.; Shah GK.; Blinder KJ. & Ryan EH. Jr. (2008). Intravitreal injection of bevacizumab combined with verteporfin photodynamic therapy for choroidal neovascularization in age-related macular degeneration. *Retina*, Vol. 28, No. 5, (may 2008), pp. 675-681, ISSN 0275-004X
- Spaide RF. (2006a). Rationale for combination therapies for choroidal neovascularization. *Am J Ophthalmol*. Vol. 141, No. 1, (January 2006), pp. 149-156, ISSN 0002-9394
- Spaide RF.; Laud K.; Fine HF.; klanchnik JM. Jr. & Meyerle CB. (2006b). Intravitreal bevacizumab treatment of choroidal neovascularization secondary to age- related macular degeneration. *Retina*, Vol. 26, No. 4, (April 2006), pp. 383-390, ISSN 0275-004X
- Spaide RF. (2009). Rationale for combination therapy in age-related macular degeneration. *Retina*, Vol. 29, No. suppl 6, (June 2009), pp. 5-7, ISSN 0275-004X
- Spielberg L. & Leys A. (2010). Treatment of neovascular age-related macular degeneration with a variable ranibizumab dosing regimen and one-time reduced-fluence photodynamic therapy: the TORPEDO trial at 2 years. *Graefes Arch Clin Exp Ophthalmol*. Vol. 248, No. 7, (July 2010), pp. 943-956, ISSN 1435-702X
- Steward MW. & Rosenfeld PJ. (2008). Predicted biological activity of intravitreal VEGF Trap. *Br J Ophthalmol*, Vol. 92, No. 5, (May 2008), pp. 667-668. ISSN 1468-2079
- Reich SJ.; Fosnot J.; Kuroki A.; tang W. & Yang X. (2003). Small interfering RNA (siRNA) targeting VEGF effectively inhibits ocular neovascularization in a mouse model. *Molecular Vision*, Vol. 30, No. 9, (May 2003), pp. 210-216, ISSN 1090-0535
- Tao Y. & Jonas JB. (2010). Intravitreal bevacizumab combined with intravitreal triamcinolone for therapy-resistant exudative age-related macular degeneration. *J Ocul Pharmacol Ther*. Vol. 26, No. 2, (April 2010), pp. 207-212, ISSN 1557-7732
- Timke C.; Zieher H.; Roth A.; Hauser K. & Lipson KE. (2008). Combination of vascular endothelial growth factor receptor/platelet derived growth factor receptor inhibition markedly improves radiation tumor therapy. *Clin Cancer Res*. Vol. 14, No. 7, (April 2008), pp. 2210-2219, ISSN 1557-3265
- Tatar O.; Shinoda K.; Kaiserling E.; Claes C. & Eckardt C. (2009). Implications of bevacizumab on vascular endothelial growth factor and endostatin in human choroidal neovascularisation. *Br J Ophthalmol*, Vol. 93, No. 2, (February 2009), pp. 159-165, ISSN 1468-2079
- Vine AK.; Stader J.; Branham K.; Musch DC. & Swaroop A. (2005). Biomarkers of cardiovascular disease as risk factors for age-related macular degeneration. *Ophthalmology*, Vol. 112, No. 12, (December 2005), pp. 2076-2080, ISSN 0161-6420
- Wan MJ.; Hooper PL. & Sheidow TG. (2010). Combination therapy in exudative age-related macular degeneration: visual outcomes following combined treatment with photodynamic therapy and intravitreal bevacizumab. *Can J Ophthalmol*. Vol. 45, No. 4, (August 2010), pp. 375-380, ISSN 0008-4182
- Witmer AN.; Vrensen GF.; Van Noorden CJF. & Schlingemann RO. (2003). Vascular endothelial growth factors and angiogenesis in eye disease. *Prog Retin Eye Res*. Vol. 22, No. 1, (January 2003), pp. 1-29, ISSN 1350-9462



Age Related Macular Degeneration - The Recent Advances in Basic Research and Clinical Care

Edited by Dr. Gui-Shuang Ying

ISBN 978-953-307-864-9

Hard cover, 300 pages

Publisher InTech

Published online 20, January, 2012

Published in print edition January, 2012

Age-related Macular Degeneration (AMD) is the leading cause of vision loss and blindness in the developed countries. In the past decade, great progress has been made in understanding the pathobiology and genetics of this blinding disease, as well as in finding new therapies for its treatment. These include the discovery of several genes that are associated with the risk of AMD, new anti-VEGF treatments for wet AMD and new imaging techniques to diagnose and monitor the AMD. All chapters in this book were contributed by outstanding research scientists and clinicians in the area of AMD. I hope this timely book will provide the basic scientists and clinicians with an opportunity to learn about the recent advances in the field of AMD.

How to reference

In order to correctly reference this scholarly work, feel free to copy and paste the following:

Jorge Mataix, M. Carmen Desco, Elena Palacios and Amparo Navea (2012). Combined Therapies to Treat CNV in AMD: PDT + Anti-VEGF, Age Related Macular Degeneration - The Recent Advances in Basic Research and Clinical Care, Dr. Gui-Shuang Ying (Ed.), ISBN: 978-953-307-864-9, InTech, Available from: <http://www.intechopen.com/books/age-related-macular-degeneration-the-recent-advances-in-basic-research-and-clinical-care/combined-therapies-to-treat-nvc-in-amd-pdt-antivegf->

INTECH
open science | open minds

InTech Europe

University Campus STeP Ri
Slavka Krautzeka 83/A
51000 Rijeka, Croatia
Phone: +385 (51) 770 447
Fax: +385 (51) 686 166
www.intechopen.com

InTech China

Unit 405, Office Block, Hotel Equatorial Shanghai
No.65, Yan An Road (West), Shanghai, 200040, China
中国上海市延安西路65号上海国际贵都大饭店办公楼405单元
Phone: +86-21-62489820
Fax: +86-21-62489821

© 2012 The Author(s). Licensee IntechOpen. This is an open access article distributed under the terms of the [Creative Commons Attribution 3.0 License](#), which permits unrestricted use, distribution, and reproduction in any medium, provided the original work is properly cited.

IntechOpen

IntechOpen