

# We are IntechOpen, the world's leading publisher of Open Access books Built by scientists, for scientists

4,900

Open access books available

124,000

International authors and editors

140M

Downloads

Our authors are among the

154

Countries delivered to

TOP 1%

most cited scientists

12.2%

Contributors from top 500 universities



WEB OF SCIENCE™

Selection of our books indexed in the Book Citation Index  
in Web of Science™ Core Collection (BKCI)

Interested in publishing with us?  
Contact [book.department@intechopen.com](mailto:book.department@intechopen.com)

Numbers displayed above are based on latest data collected.  
For more information visit [www.intechopen.com](http://www.intechopen.com)



## Apoptosis Imaging in Diseased Myocardium

Junichi Taki, Hiroshi Wakabayashi, Anri Inaki,  
Ichiro Matsunari and Seigo Kinuya  
*Kanazawa University & Medical and Pharmacological Research Center Foundation,  
Japan*

### 1. Introduction

In various myocardial disorders including myocardial ischemia, infarction and subsequent cardiac remodelling and heart failure, myocarditis, cardiomyopathy, cardiac allograft rejection, chemotherapy induced cardiotoxicity, both necrosis and apoptosis are considered to play an important role in the underlying pathophysiology. Molecular and cellular dysfunction has been widely investigated in cardiovascular fields using various modalities. Of particular, radionuclide imaging technique has advantage for quantitative assessment of molecular function in vivo in patients. Especially in patients with coronary artery disease, perfusion imaging agents such as  $^{201}\text{Tl}$ ,  $^{99\text{m}}\text{Tc}$ -MIBI and tetrofosmin with combination of stress testing and ECG-gated data acquisition have been used for the simultaneous assessment of the ventricular function and severity of myocardial perfusion abnormality including its location and size in stress and resting condition. From these data, status of myocardial ischemia or jeopardized myocardium, myocardial viability and reversibility of wall motion abnormality can be diagnosed to some extent but still insufficiently. Molecular imaging may play an important role for assessing the pathophysiology and its severity in these various cardiovascular diseases beyond perfusion imaging. This chapter focuses on the apoptosis imaging that is one of the most possible nuclear molecular imaging in-vivo at this stage, and its clinical application might permit more precise assessment of the pathophysiology in various myocardial abnormalities beyond perfusion imaging.

Four decades ago, the term apoptosis has been introduced by Kerr et. al. as a special form of cell death different from necrosis (Kerr, et al., 1972). Necrosis is passive and unregulated form of cell death, characterized by irreversible loss of plasma membrane integrity with cell swelling and rupture after sudden severe insults which preclude adequate homeostatic energy-dependent cell functions, leading to release of intracellular contents and a subsequent inflammatory response. Apoptosis on the other hand is characterized morphologically by the condensation of nuclear chromatin, cytoplasmic condensation, cell shrinkage, followed by the nuclear and cellular fragmentation and phagocytosis of apoptotic bodies by neighboring cells in the absence of inflammation. Apoptosis is considered to be an active and highly regulated ATP dependent programmed cell death process and plays an important roles in embryonic development and maintenance of postnatal tissues and contributes to both normal physiology and pathology. Dysregulation of apoptosis results in either too little or too much cell death and implicated in various diseases. For instance, insufficient apoptosis may contribute carcinogenesis, on the otherhand, excessive apoptosis

may account for substantial portion of pathogenesis of myocardial infarction and heart failure.

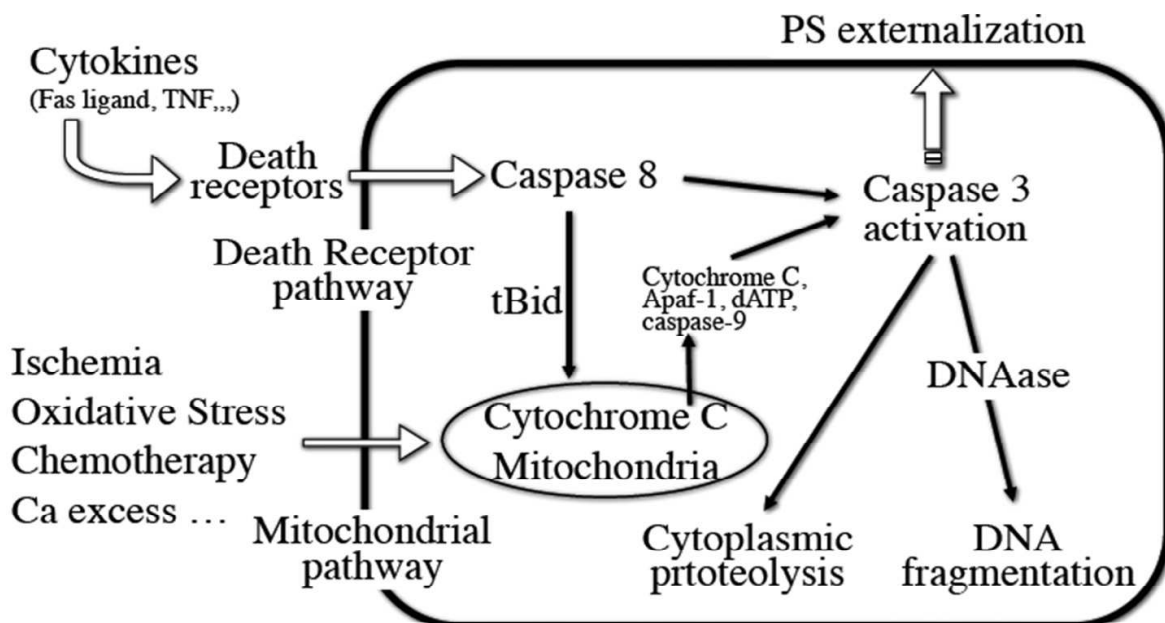


Fig. 1. Schema of two major pathway for apoptosis.

Apoptosis can be mediated through the death receptor pathway, or by mitochondrial pathway that is initiated by the release of cytochrome c into the cytosol. Both pathways result in activation of caspase-3, the final effector enzyme of apoptosis, leading to the cleavage of numerous structural and regulatory cellular proteins, thereby producing the apoptotic phenotype characterized by cell shrinkage, chromatin condensation, nucleus fragmentation, and externalization of phosphatidylserin (PS) on the outside of the cell membrane.

Apoptosis is mediated by 2 central pathway: the extrinsic (or death receptor) pathway that utilizes cell surface receptors (e.g. Fas) and the intrinsic (or mitochondrial) pathway that involves the mitochondria and cytoplasmic reticulum (Fig. 1.). The extrinsic or death receptor pathway relies on the binding of specific cytokines expressed by other cells, including Fas ligand, tumor necrosis factor alfa, or other factors that binds to specific cellular receptors. Ligand binding initiates the activation of caspase-8, which in turn activates downstream effector caspases including caspase-3, the final effector enzyme of apoptosis. In contrast to extrinsic pathway that transduces a specialized set of death stimuli, the intrinsic or mitochondrial pathway integrates a broad spectrum of extracellular and intracellular stresses such as ischemia, reperfusion injury, chemotherapy, oxidative stress etc. These stimuli converges on the mitochondria leading to the release of several factors into cytosol including cytochrome c, which activates the initiator caspase-9 via the apoptosome followed by the activation of effector caspases. The activation of down stream caspases leads to the cleavage of numerous structural and regulatory cellular proteins, thereby producing the apoptotic phenotype characterized by cell shrinkage, chromatin condensation, nucleus fragmentation, and externalization of phosphatidylserin (PS) on the outside of the cell membrane which serves as an "eat me" signal for phagocyte. Intracellular components are packaged by blebbing and the cell is fragmented into apoptotic bodies

and designated to be engulfed and phagocytosed by macrophages and neighbouring cells without causing inflammation.

## 2. Radiopharmaceuticals for molecular imaging of apoptosis

After the initial description of apoptosis based on the morphological features, several useful biochemical and immunohistochemical detection methods were subsequently introduced based on the understanding of the basic mechanisms of apoptosis. As a histochemical technique for the detection of apoptosis, terminal deoxynucleotidyltransferase-dUTP-nick end-labeling (TUNEL) assays has become a standard technique for in situ labeling and localization of DNA breaks in individual nuclei on tissue section (Gavrieli, et al., 1992). TUNEL is based on the specific binding of terminal deoxynucleotidyltransferase (TdT) to 3'-OH ends of fragmented DNA. As DNA ladder formation is quite a late feature of apoptosis, TUNEL assay appears to be uniquely associated with apoptotic cell death. For the in-vivo imaging initiator caspases and effector caspases can be distinguished and serve as potential targets inside the apoptotic cells. However, for molecular target for in-vivo imaging, it is favorable that the target exists on cell surface rather than in cytoplasm or nucleus. Accordingly, to date, most noninvasive imaging of apoptosis target PS on the cell membrane, which is a membrane aminophospholipid that is normally located on the inner leaflet of cell membrane but is rapidly translocated to the outer leaflet of cell membrane once the cell become apoptotic. Annexin V, a 36-kD physiologic protein, binds with nanomolar affinity to PS in a calcium dependent manner, therefore,  $^{99m}\text{Tc}$  labeled annexin V permits imaging of apoptosis in vivo in its early stage (Blankenberg, et al., 1998; Hofstra, et al., 2000; Kemerink, et al., 2003).

### 2.1 Radiolabeled annexin V

Annexin V (also known as annexin A5) is consisted of 319 amino acids and a 36-kD endogeneous human protein that is mainly distributed intracellularly with very high concentrations in placenta, and lower concentrations in endothelial cells, myocardium, skeletal muscle, kidneys, skin, red blood cells, platelets, and monocytes. Very low concentrations of annexin V (1-6 ng/ml) circulate in blood of healthy humans (Andree et al., 1992). Several advantages for the use of annexin V for apoptotic imaging have been described including very high affinity for PS with low nanomolar to subnanomolar dissociation constant values, ready production by recombinant DNA technology, and lack of toxicity of the protein.

In healthy cells, anionic phospholipid PS and phosphatidylethanolamine (PE) confined to the inner leaflet of the lipid bilayer plasma membrane by an ATP dependent enzyme called translocase. On the other hand, ATP dependent enzyme, floppase, pumps cationic phospholipids such as phosphatidylcholine (PC) and sphingomyelin to the cell surface. Therefore, an asymmetric distribution of different phospholipids between the inner and outer leaflet of the plasma membrane is maintained in normal cells. However, at the beginning of the execution phase of apoptosis, rapid redistribution of PS and PC across the cell membrane is facilitated by a calcium ion-dependent deactivation of translocase and floppase and activation of scramblase. Then, PS exposes on the cell surface and annexin V become accessible to PS. This PS exposure is attractive target for imaging apoptosis, since it is a near universal event in apoptosis, it occurs early after the apoptotic stimulus, and it presents millions of binding sites per cell on the cell surface.

Annexin V and its derivatives have been labeled with  $^{123}\text{I}$ ,  $^{124}\text{I}$ ,  $^{125}\text{I}$ ,  $^{99m}\text{Tc}$ ,  $^{18}\text{F}$ , thereby providing a broad range of imaging applications in apoptosis research from autoradiography

and single photon imaging including SPECT, and to PET. However, most of the radiolabeled annexin V used in clinical trials are  $^{99m}\text{Tc}$  labeled annexin V, because  $^{99m}\text{Tc}$  is characterized by the most suitable radionuclide properties for SPECT imaging in human and is inexpensive and easily available.

$^{99m}\text{Tc}$ -BTAP-annexin V using a diamide dimercaptide  $\text{N}_2\text{S}_2$  chelate for labeling ( $^{99m}\text{Tc}$ - $\text{N}_2\text{S}_2$ -annexin V) was introduced in early 1990s and examined to detect left atrial thrombi in vivo in swine (Stratton et al., 1995). Biodistribution and dosimetry study of  $^{99m}\text{Tc}$ -BTAP-annexin V in patients revealed that the radioactivity predominates in kidney, liver and urine bladder and fast and extensive bowel excretion of the tracer precludes the assessment of abdominal region (Kemerink, et al., 2001a).  $\text{N}_2\text{S}_2$  labeling method is cumbersome but radiochemical yield is low and had a high degree of non specific tracer excretion into bowel via excretion to bile.

Accordingly, an improved labeling method using the bifunctional agent hydrazinonicotinamide (HYNIC) was introduced (Blankenberg, et al., 1998).  $^{99m}\text{Tc}$ -labeling of reconstituted HYNIC-annexin V can be performed by simply reacting the conjugate with  $^{99m}\text{Tc}$ -pertechnetate in the presence of stannous tricine for 5-10min in room temperature and it provides  $^{99m}\text{Tc}$ -HYNIC-annexin V in high radiochemical yield (usually 92-95%) without requiring any additional purification step. Phase I clinical trial with  $^{99m}\text{Tc}$ -HYNIC-annexin V also demonstrated strongest uptake in kidney, liver and urine bladder. However, in contrast to  $^{99m}\text{Tc}$ -BTAP-annexin V no bowel excretion was observed in  $^{99m}\text{Tc}$ -HYNIC-annexin V, having a favorable biodistribution for imaging of the abdominal as well as thoracic area.

As an alternative methods for radiolabeling annexin V, self chelating annexin V mutants had been introduced (Tait, et al., 2000, 2005). Annexin V mutants with endogeneous site for  $^{99m}\text{Tc}$  chelation such as V-117 and V-128 have major advantages over the HYNIC chelator in terms with lower renal retention. Many other kind of  $^{99m}\text{Tc}$ -labeled annexin V have been introduced, however, only  $^{99m}\text{Tc}$ -i-annexin V (Kemerink, et al., 2001b) was tested in clinical trial in addition to  $^{99m}\text{Tc}$ -BTAP-annexin V and  $^{99m}\text{Tc}$ -HYNIC-annexin V.

As a PET tracer, several approaches to label annexin V with  $^{18}\text{F}$  have been developed (Grierson, et al. 2004; Murakami et al., 2004).  $^{18}\text{F}$ -annexin V has lower uptake in the liver, spleen, and kidneys than  $^{99m}\text{Tc}$ -HYNIC-annexin V.

## 2.2 Radiolabeled C2A

C2A domain of synaptotagmin I also binds PS with nanomolar affinity in a calcium-dependent manner. The C2A is labeled in the form of C2A-GST (GST: glutathione S-transferase) fusion protein. The fusion protein can be stably labeled with  $^{99m}\text{Tc}$  at a reasonably high radiochemical yield and purity through thiolation using 2-iminothiolane (Zhao, et al., 2006).  $^{99m}\text{Tc}$ -C2A-GST accumulates well in the area at risk in a rat model of acute myocardial infarction in both in-vivo imaging and autoradiography. Recently,  $^{18}\text{F}$ -C2A-GST was synthesized and significant uptake in the VX2 rabbit lung cancer with paclitaxel induced apoptosis was observed in small animal PET/CT (Wang, et al., 2011). Radiochemical purity of  $^{18}\text{F}$ -C2A-GST was more than 95% and stable for 4 h after formulation. Biodistribution in mice was favorable with major excretion from the kidneys and rapid clearance from blood and nonspecific organs.

## 2.3 Radiolabeled caspase targeted tracer

Caspase activation is the central role in the execution of cell death, therefore, caspases are the attractive targets for apoptosis imaging. Non-peptide based isatin sulfonamide analogs were synthesized with nanomolar potency for inhibiting caspase-3 and caspase-7 and one of

the analogs, WC-II-89 was labeled with  $^{18}\text{F}$  (Zhou et al., 2006).  $^{18}\text{F}$ - WC-II-89 showed a high uptake in the liver of chemically induced apoptosis. Although molecules that target caspase-3 is attractive, there are limited animal data and it is not yet known how sensitive this kind of agents will be for actual imaging in humans.

#### **2.4 Uncategorized tracer**

Recently a novel family of low molecular mass amphipatic apoptosis markers (ApoSense) was developed targeting the cell membrane of apoptotic cells.  $^{18}\text{F}$ -labeled 5-fluoropentyl-2-methyl-malonic acid ( $^{18}\text{F}$ -ML-10) belongs to this family of low-molecular-weight compounds used for the imaging of cell death in vivo. This compound responds to alterations in plasma membrane potential and phospholipid scrambling, which are hallmarks of apoptotic cells. To which cell membrane targets this probe binds is unknown. After systemic administration, the compound can detect apoptotic cells from the early stages of the death process, cross the intact plasma membrane, and accumulate in the cytoplasm. In animal model of cerebral infarction, selective uptake was observed in the region of ischemia at 24 hr after the middle cerebral artery occlusion (Reshef et al., 2008).

### **3. Apoptosis imaging in acute myocardial ischemia**

It has been believed that myocardium directly start to die via necrosis shortly after the onset of myocardial infarction that march of necrosis spread as a wavefront from endocardium to epicardium. However, recent animal experiments with permanent coronary artery occlusion revealed that cell death process starts as apoptosis and severe ATP depletion due to ischemia may preclude the execution of apoptosis and lead to plasma membrane permeability barrier breakdown and secondary necrosis. Therefore, apoptosis imaging might play important role in the assessment of myocardial cell death process in acute myocardial infarction, especially in its early stage.

#### **3.1 Animal experiment in permanent occlusion of coronary artery**

In a rat model of permanent coronary artery ligation, Kajstura et al. investigated the contribution of the apoptosis and necrosis to cardiomyocyte death using TUNEL method and DNA laddering for apoptosis and antimyosin monoclonal antibody labeling (Kajstura, et al., 1996). After 2 h of the left main coronary artery ligation, TUNEL positive myocytes appeared in the central portion of the left ventricular free wall and peaked at 4.5 h. Myosin labeled cells also appeared at 2 h after ligation and significantly increased after 6 h to 2 days. However, at 2 h after coronary ligation, number of apoptotic cells was  $2.8 \times 10^6$  and number of necrotic cells was  $9 \times 10^4$ . Therefore, early after myocardial infarction, apoptosis is the predominant form of cell death, and 1 to 2 days after infarction, necrosis is the dominant form of cell death followed by low levels of both apoptosis and necrosis at 7 days after infarction. If cells undergoing apoptosis are not cleared before they deplete their intracellular ATP stores that are necessary to maintain plasma membrane integrity, plasma membrane permeability barrier breakdown occurs and cells are converted from apoptosis to necrosis as known as secondary necrosis, results in inflammation.

#### **3.2 Animal experiment in acute ischemia and reperfusion**

In a mouse model of 15 and 30 min of ischemia and 90 min of reperfusion, percentage of cardiomyocytes staining positivity for biotinylated annexin V was far greater than the

percentage staining positivity for IgG, which indicates plasma cell membrane leakage (Dumont et al., 2000). Accordingly, at least 90 min of reperfusion, most of the annexin V uptake might represent PS externalization.

We investigated the temporal and spatial change of  $^{99m}\text{Tc}$ -annexin V accumulation in a rat model of 20 min coronary artery occlusion and reperfusion.  $^{99m}\text{Tc}$ -annexin V uptake was imaged at 30 min, 90 min, 6 h, 24 h, 3 day, 2 weeks after reperfusion. The strongest  $^{99m}\text{Tc}$ -annexin V uptake was observed in the mid myocardium of the area at risk at 30 m and 90 m of reperfusion and the uptake expanded to subendocardial and subepicardial layer at 6 h after reperfusion, followed by gradual reduction of the uptake over 3 days (Fig. 2) (Taki, et al., 2004). On the other hand, TUNEL positivity peaked at 6 h to 1 day after reperfusion. These findings are in keeping with the known temporal sequence of apoptosis, in which one of the earliest events is externalization of phosphatidylserine, followed by DNA fragmentation. Using fluorescent labeled annexin V, real time monitoring of annexin V binding to cardiomyocytes after 30 m ischemia and reperfusion demonstrated that cardiomyocytes started to bind annexin V within minute and the amount of binding reached a maximum within 20-25 m (Dumont, et al., 2001). These finding indicate that apoptosis commences just after ischemia and reperfusion and PS externalization reaches plateau around 30 m after reperfusion.

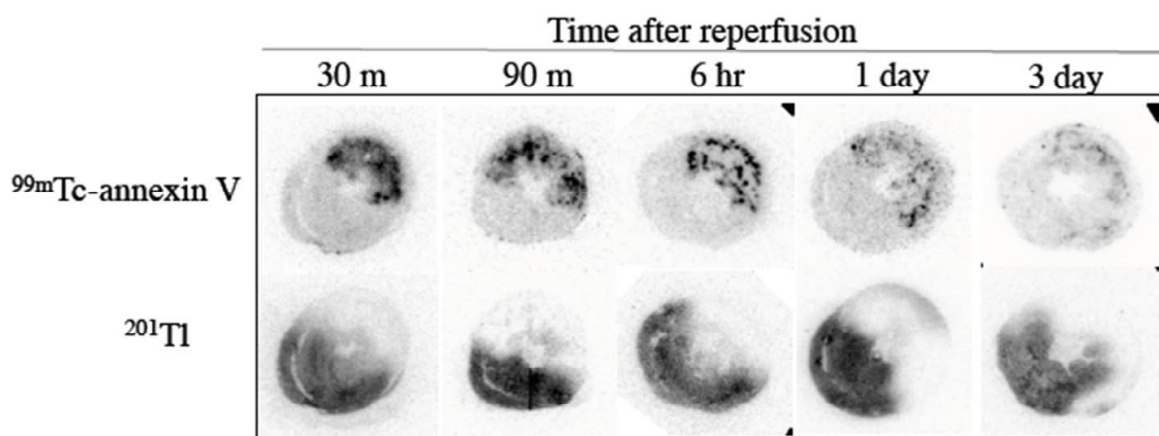


Fig. 2. Autoradiography of  $^{99m}\text{Tc}$ -annexin V and  $^{201}\text{Tl}$  at various reperfusion time after 20 min of coronary artery occlusion.

At a examination time after 20 min ischemia and reperfusion,  $^{99m}\text{Tc}$ -annexin V (80-150 MBq) was injected and 1 h later  $^{201}\text{Tl}$  (0.74 MBq) was injected just after the coronary artery reocclusion to verify the area at risk. Upper low demonstrated  $^{99m}\text{Tc}$ -annexin V images and lower low shows  $^{201}\text{Tl}$  image that represents area at risk.

The amount of annexin V binding to apoptotic cardiomyocytes after reperfusion depends on the severity of ischemia and reperfusion time (Taki, et al., 2007a). In a rat model of 5 min, 10 min, 15 min ischemia and reperfusion model, degree of  $^{99m}\text{Tc}$ -annexin V accumulation depend on the length of the coronary artery occlusion time and time period after reperfusion: significant uptake of  $^{99m}\text{Tc}$ -annexin V accumulation was observed in 15 min and 10 min ischemia (uptake ratio was  $4.46 \pm 3.16$  and  $2.02 \pm 0.47$ , respectively), whereas, no significant uptake was observed in 5 min ischemia at 30 min after reperfusion.  $^{99m}\text{Tc}$ -annexin V uptake in 15 min and 10 min ischemia reduced at 90 min (uptake ratio was  $3.49 \pm 1.78$  and

1.47±0.11, respectively) and only mild uptake was observed at 6 h and 24 h after reperfusion. Interestingly, no morphological sign of necrosis and apoptosis was observed until 24 h after reperfusion in 10 min ischemia and only micro foci of cell degeneration and cell infiltration were observed until 24 h after reperfusion in 15 min ischemia, with mild TUNEL positivity which peaked at 6 hr (1.03±0.40% in 10 min ischemia and 2.84±0.94% in 15 min ischemia). These data indicate that <sup>99m</sup>Tc-annexin V uptake can be observed after mild ischemic insults those do not result in myocardial infarction.

Several cardioprotective interventions such as ischemic preconditioning, postconditioning, and caspase inhibitor preparation attenuate <sup>99m</sup>Tc-annexin V uptake (Taki, et al., 2007). Ischemic preconditioning suppressed <sup>99m</sup>Tc-annexin V binding by 90 % of control and postconditioning and caspase inhibitor attenuate the binding by around 70 %.

Reversibility of PS externalization in brief ischemia was demonstrated (Kenis, et al., 2010). In murine myocardium with 5 min ischemia and 90 min and 6 h of reperfusion, fluorescent labeled annexin V injected before 10 min of sacrifice binds cell surface, but not at 24 h after reperfusion. On the other hand fluorescent-annexin V injected at the onset of reperfusion exclusively localized intracellularly at 90 min, 6 h, and 24h after reperfusion. No TUNEL positivity was observed in this 5 min ischemia and reperfusion model. These data indicate that in brief ischemia, PS externalizes transiently, which is amenable to targeting by annexin V for at least 6 h after reperfusion, and internalize after annexin V binding (reversibility of the apoptotic process).

### 3.3 Clinical findings and potential future application

In human pathological study by TUNEL staining and DNA electrophoresis, widespread apoptosis in infarcts was observed only a few hours in age before the appearance of coagulative necrosis (Veinot, et al. 1997). In addition, TUNEL positivity was observed primarily in myocytes containing contraction bands, which occur predominantly in regions of reperfused myocardium. These findings are consistent with animal experiment, and in infarcted human myocardium, apoptosis is the early and predominant form of cell death and its appearance is accelerated in reperfused myocardium.

First clinical imaging with <sup>99m</sup>Tc-annexin V in 7 patients with acute myocardial infarction demonstrated significant uptake of <sup>99m</sup>Tc-annexin V (injected 2 h after reperfusion) in the area corresponding to the perfusion defect in 6 patients (Hofstra, et al., 2000). Subsequent study in 9 patients with acute myocardial infarction, <sup>99m</sup>Tc-annexin V uptake (injected within 1.5 - 7 h after reperfusion) was again clearly visualized on SPECT performed at 15 h later in infarcted areas with a matching perfusion defect confirmed by <sup>99m</sup>Tc-sestamibi SPECT before reperfusion. Repeat <sup>99m</sup>Tc-sestamibi SPECT at 1 - 3 week after the onset of infarction demonstrated that the perfusion defects were significantly smaller than the defects in acute phase, suggesting that the significant amount of myocardium in perfusion defect with <sup>99m</sup>Tc-annexin V uptake in acute phase might be in reversible damage rather than irreversible necrosis. Imaging of the extent of apoptosis resulting from acute coronary syndromes could be a valuable tool to help guide revascularization strategies and therapy with anti-apoptotic drugs if available in near future. Other potential application of <sup>99m</sup>Tc-annexin V imaging would be in the detection of myocardial ischemic insults in patients with acute coronary syndrome without ST elevation and troponin leakage, in assessment of the effect of revascularization in acute coronary syndrome, in evaluation of the effect of postconditioning at reperfusion therapy, in detection of transient PS externalization due to brief spontaneous



or stress induced ischemia. However, several questions yet to be answered concerning the clinical application of  $^{99m}\text{Tc}$ -annexin V imaging. In vivo imaging 1 hr after tracer injection is feasible in rats because blood clearance of  $^{99m}\text{Tc}$ -annexin V was rather fast, although, the earliest optimal time for imaging after tracer injection should be investigate in human. In heart transplantation patients, it was revealed that  $^{99m}\text{Tc}$ -annexin V SPECT imaging was possible 1 h after tracer injection (Narula, et al., 2001). Speedy imaging after tracer injection is crucial especially in emergency situation. Are therapeutic interventions beneficial for all annexin-positive myocardium, or in only specific pathological status, or in only limited time window? How much of the shift from necrosis to apoptosis by therapeutic intervention is cardioprotective (Narula, et al., 2003)? Necrosis is more harmful than apoptosis, because cells are removed without inflammation in apoptosis but cells are removed with inflammation and fibrosis follows in necrosis. Is annexin V positive scan in stress induced ischemia related to subsequent prognosis, or indication of PCI? These potential imaging concepts of the assessment of myocardial injury, stress, cell death in acute ischemia should be validated in clinical studies.

It has been increasingly clear that apoptosis is a major contributor to early cardiomyocyte cell death after acute myocardial infarction, and is involved in post myocardial infarction ventricular dysfunction and adverse remodeling that develop heart failure. These findings emphasize the need for the reliable in-vivo imaging of apoptosis that assess the ongoing pathology so that rational preventive therapies can be applied and to assess the consequence of therapies.  $^{99m}\text{Tc}$ -annexin V imaging might be applied to assess myocardium at risk or cell death in acute coronary syndrome and prediction of the ventricular remodeling after myocardial infarction and heart failure by allowing visualization of ongoing PS externalization that might precede or underlie change in pathophysiology, morphology, and LV dysfunction.

#### **4. Apoptosis imaging in heart failure and cardiomyopathy**

In spite of dramatic improvement of therapies in acute coronary syndrome, post acute myocardial infarction mortality has reached a plateau and post infarction heart failure due to ventricular remodeling is on the increase. About 15 to 25 % of acute myocardial infarction patients develop heart failure that remains a progressive despite of continuous pharmacological therapy. It has been reported that myocardial apoptosis shortly after acute myocardial infarction might be a strong predictor of unfavorable LV remodeling and early post infarction symptomatic heart failure in 16 patients dying  $\geq 10$  days after myocardial infarction (Abbate, et al., 2003).

In rats with anterior myocardial infarction, 28-day infusion of caspase inhibitor after infarction ameliorated apoptosis, preserved myocardial contractile proteins, decreased myocardial interstitial collagen deposits, reduced systolic dysfunction, and attenuated LV remodeling (Chandrashekar, et al., 2004). If so, apoptosis imaging could be a promising noninvasive method to identify patients at risk of heart failure development due to LV remodeling and to monitor the treatment effect if some specific anti-apoptotic agents will reach the stage of clinical study.

In patients with advanced heart failure, low but abnormal rate of cardiac myocyte apoptosis persist for months (0.08% to 0.25% in heart failure vs 0.001% to 0.002% in normal subjects), thereby ultimately might result in a large loss of functional cardiomyocytes (Olivetti, et al.,

1997; Saraste, et al., 1999; Guerra, et al., 1999). In study with transgenic mice that express a conditionally active caspase exclusively in the myocardium, low rate of cardiomyocyte apoptosis as 0.023% is sufficient to cause a lethal dilated cardiomyopathy. Conversely, inhibition of cardiac myocyte apoptosis by caspase inhibitor in this murine model largely prevents the development of cardiac dilation and contractile dysfunction, indicating that myocyte apoptosis may be a causal mechanism of heart failure, and inhibition of this cell death process may constitute the basis for novel therapies (Wencker, et al., 2003). The low level of cell death due to apoptosis in heart failure makes detection of apoptosis with the current techniques very challenging.

In recent study in 9 consecutive patients with advanced nonischemic cardiomyopathy (8 dilated and 1 hypertrophic cardiomyopathy) and 2 relatives, 5 patients showed focal or global  $^{99m}\text{Tc}$ -annexin V uptake in the left ventricular myocardium. Interestingly, these 5 patients with  $^{99m}\text{Tc}$ -annexin V uptake had experienced a significant worsening or a recent onset of heart failure, on the contrary, 4 patients without  $^{99m}\text{Tc}$ -annexin V uptake had no recent evidence of worsening of heart failure. In addition, during a follow up of 1 year, 4 patients with  $^{99m}\text{Tc}$ -annexin V uptake showed a decline of LVEF, on the other hand, in patients without  $^{99m}\text{Tc}$ -annexin V uptake, clinical status and LVEF remained stable (Kietselaer, et al., 2007). These data indicate that the  $^{99m}\text{Tc}$ -annexin V imaging in advanced non-ischemic cardiomyopathy, may identify the patients with high risk who might benefit from cell death blocking therapies.

## 5. Apoptosis imaging in myocarditis

In a rat model of autoimmune myocarditis,  $^{99m}\text{Tc}$ -annexin V (HYNIC annexin V) and  $^{14}\text{C}$ -deoxyglucose (DG) uptakes were examined (Tokita, et al., 2003). Myocarditis was triggered by an immunization of rats by infusing porcine cardiac myosine and the rats formed antibodies against the myosin and developed myocarditis. In acute phase of myocarditis, both  $^{99m}\text{Tc}$ -annexin V (2.8 time more than normal rats) and  $^{14}\text{C}$ -DG (2.7 time more than normal rats) uptake increased significantly, however, only  $^{99m}\text{Tc}$ -annexin V distribution correlated with the TUNEL positive area, and the distribution of  $^{14}\text{C}$ -DG correlated with inflammatory cell infiltration. In subacute phase,  $^{99m}\text{Tc}$ -annexin V uptake returned normal level, on the other hand,  $^{14}\text{C}$ -DG uptake decreased but still higher uptake reflecting prolonged mild inflammatory cell infiltration. In this model of immune myocarditis, there was a marked difference in distribution of apoptotic cell death and inflammation. The data indicates that  $^{99m}\text{Tc}$ -annexin V uptake is specific in myocardial apoptotic process induced by inflammation and is independent of inflammatory cell infiltration.

Another animal experiment in a rat model that develops spontaneous myocarditis mimicking catecholamine induced subacute myocarditis demonstrated significantly increased  $^{99m}\text{Tc}$ -annexin V uptake in planar scintigraphy. Autoradiography confirmed increased  $^{99m}\text{Tc}$ -annexin V uptake. Histopathology demonstrated patchy areas of interstitial edema with inflammatory cells in the perivascular areas and at cardiocyte layers, and myocyte necrosis with nuclear extrusion, scattered throughout the myocardium and apostatin-positive cells were diffusely but inhomogeneously distributed throughout the myocardium (Peker, et al., 2004).

In myocarditis, apoptosis imaging might play an important role, in confirming the diagnosis in terms of the extent of the involvement and disease activity, selecting patients with antiapoptotic therapy and monitoring the effect of therapy.

## 6. Apoptosis imaging in cardiotoxicity induced by chemotherapy

The development of chemotherapy has played a significant role in the management of cancer patients. Of the classic cytotoxic agents, anthracyclines are still one of the most important agents for cancer therapy and are well known for their dose dependent acute and chronic cardiotoxicity, resulting in irreversible and progressive cardiac dysfunction and heart failure. Although new anticancer molecular targeting agents improved the prognosis of cancer patients, some agents may have serious cardiovascular side effect. Standard clinical approaches utilize the serial monitoring of the left ventricular ejection fraction to identify chemotherapy induced cardiotoxicity. For this purpose, radionuclide ECG gated blood-pool scintigraphy has been used as a gold standard technique. However, ejection fraction impairment is relatively late manifestation of myocardial damage. Therefore, the development of more sensitive methods is required to identify the cardiotoxicity before the onset of ventricular dysfunction.

In a rat model of doxorubicin cardiotoxicity (cumulative dose: 7.5mg/Kg, 10mg/Kg, 12.5mg/Kg), planar scintigraphy detected the increase of  $^{99m}\text{Tc}$ -annexin V uptake dose dependently and correlated with expression of left ventricular atrial natriuretic factor messenger RNA (Bennink, et al., 2004). Another study with doxorubicin treated rats (cumulative dose: 7.5mg/Kg and 15mg/Kg) demonstrated that dose dependent increase in  $^{99m}\text{Tc}$ -annexin V uptake by SPECT/CT and TUNEL positivity. In contrast in this study, echocardiography detected ventricular dysfunction only at the highest doxorubicin dose (Gabrielson, et al., 2008). These data suggest that apoptosis imaging could serve as a more sensitive early marker of doxorubicin cardiotoxicity than left ventricular dysfunction, might providing the opportunity to modify or stop the chemotherapy before clinically overt heart failure.

## 7. Apoptosis imaging heart transplantation

Acute rejection remains a limiting factor of cardiac transplantation. The histopathologic manifestation of transplant rejection comprises perivascular and interstitial mononuclear inflammatory cell infiltration associated with myocyte apoptosis and necrosis. To monitor the acute rejection, endomyocardial biopsies are required frequently. Current guidelines recommend 15-20 endomyocardial biopsies in the first year after transplantation to monitor potential allograft rejection. However, invasive endomyocardial biopsy may be associated with a small risk of complications. If non-invasive imaging for the detection of transplant rejection is feasible, endomyocardial biopsies might be reduced.

Study with rat model of allograft rejection demonstrated that significant  $^{99m}\text{Tc}$ -annexin V uptake correlated well with the histologic grade of rejection and scattered positive TUNEL stainings were observed in graft-infiltrating inflammatory cells, endothelial cells, and myocytes. In addition, after the treatment of rejection with cyclosporine, no TUNEL positivity was observed and  $^{99m}\text{Tc}$ -annexin V uptake decreased to baseline (Vriens, et al., 1998). In 18 patients with cardiac allograft recipients, 5 had positive myocardial uptake of  $^{99m}\text{Tc}$ -annexin V at 1 h after the tracer injection and all these 5 patients showed at least moderate transplant rejection and caspase-3 staining in their biopsy specimens. On the other hand, 11 of 13 patients with no cardiac uptake of  $^{99m}\text{Tc}$ -annexin V demonstrated no finding of rejection and other 2 patients showed only focal lymphomononuclear cell infiltration (Narula, et al., 2001). In another clinical study with 10 patients with cardiac transplant, 2

patients with moderate acute rejection by endomyocardial biopsy showed significant  $^{99m}\text{Tc}$ -annexin V uptake, however, specificity was suboptimal with 4 of 8 patients without rejection demonstrating significant  $^{99m}\text{Tc}$ -annexin V uptake.

All these animal and clinical studies revealed that the apoptosis imaging has potential to noninvasively identify patients with transplant rejection and monitor the response to immune modulation therapy.

## 8. Conclusions

For the imaging apoptosis, for the time being, it appears that agents that bind to markers expressing cell surface of apoptotic cells, such as annexin V and its derivatives, have advantage in terms of the sensitivity and specificity over other tracers. Based on the research achievement to date including experiences with  $^{99m}\text{Tc}$ -annexin V imaging in patients,  $^{99m}\text{Tc}$ -annexin V and its related tracers are considered as one of the most suitable tracers for clinical application at this stage, and also the positron labeled tracers such as  $^{18}\text{F}$ -annexin V are desired to apply clinical imaging. In cardiac diseases that involve cardiomyocytes, myocytes loss implies loss of cardiac function because cardiomyocytes cannot be regenerated through cell division. In acute coronary syndrome, measurement of cardiac biomarkers are standard diagnostic tool, but they reflect the results of cardiomyocytes death. Whereas, apoptosis imaging such as  $^{99m}\text{Tc}$ -annexin V can identify the cells starting or undergoing apoptosis, however, part of PS exposure of these cells might be reversible and some cells are capable of surviving. Therefore, apoptosis imaging might be beneficial for future strategy of the patient's management. Other than acute coronary syndrome, including heart failure, myocarditis, cardiomyopathies, and transplanted rejection, apoptotic cell death has turned out one of the crucial players in underlying pathophysiology. Hence, apoptosis imaging in patients with various cardiac diseases will enhance the understanding of the ongoing pathophysiology, identification of high risk patients, and lead to effective therapies to salvage the myocardium in risk and be helpful in monitoring the effect of therapy.

## 9. References


- Abbate A, Biondi-Zoccai GG, Bussani R, Dobrina A, Camilot D, Feroce F, Rossiello R, Baldi F, Silvestri F, Biasucci LM & Baldi, A. (2003). Increased myocardial apoptosis in patients with unfavorable left ventricular remodeling and early symptomatic post-infarction heart failure. *J Am Coll Cardiol* Vol.41(No. 5):753-760.
- Andree HA, Stuart MC, Hermens WT, Reutelingsperger CP, Hemker HC, Frederik PM, Willems G.M. (1992). Clustering of lipid-bound annexin V may explain its anticoagulant effect. *J Biol Chem* Vol.267(No. 25):17907-17912.
- Bennink RJ, van den Hoff MJ, van Hemert FJ, de Bruin KM, Spijkerboer AL, Vanderheyden JL, Steinmetz N & van Eck-Smit BL. (2004) Annexin V imaging of acute doxorubicin cardiotoxicity (apoptosis) in rats. *J Nucl Med* Vol.45(No. 5):842-848.
- Blankenberg FG, Katsikis PD, Tait JF, et al. (1998). In vivo detection and imaging of phosphatidylserine expression during programmed cell death. *Proc. Natl. Acad. Sci. U S A*. Vol.95(No. 111): 6349-6354
- Chandrashekar Y, Sen S, Anway R, Shuros A & Anand I. (2004). Long-term caspase inhibition ameliorates apoptosis, reduces myocardial troponin-I cleavage, protects

- left ventricular function, and attenuates remodeling in rats with myocardial infarction. *J Am Coll Cardiol* Vol. 43(No.2): 295-301.
- Dumont EA, Hofstra L, van Heerde WL, van den Eijnde S, Doevendans PA, DeMuinck E, Daemen MA, Smits JF, Frederik P, Wellens HJ, Daemen MJ & Reutelingsperger CP. (2000). Cardiomyocyte death induced by myocardial ischemia and reperfusion: measurement with recombinant human annexin-V in a mouse model. *Circulation* Vol.102(No. 13):1564-1568.
- Dumont EA, Reutelingsperger CP, Smits JF, Daemen MJ, Doevendans PA, Wellens HJ & Hofstra L. (2001). Real-time imaging of apoptotic cell-membrane changes at the single-cell level in the beating murine heart. *Nat Med* Vol.7(No.12):1352-1355.
- Gabrielson KL, Mok GS, Nimmagadda S, Bedja D, Pin S, Tsao A, Wang Y, Sooryakumar D, Yu SJ, Pomper MG & Tsui BM. (2008). Detection of dose response in chronic doxorubicin-mediated cell death with cardiac technetium 99m annexin V single-photon emission computed tomography. *Mol Imaging* Vol.7(No. 3):132-138.
- Gavrieli Y, Sherman Y & Ben-Sasson S. (1992). Identification of programmed cell death in situ via specific labeling of nuclear DNA fragmentation. *J Cell Biol* Vol.119(No. 3):493-501
- Grierson JR, Yagle KJ, Eary JF, Tait JF, Gibson DF, Lewellen B, Link JM, & Krohn KA. (2004). Production of [F-18]fluoroannexin for imaging apoptosis with PET. *Bioconjug Chem*. Vol.15(No.2):373-379.
- Guerra S, Leri A, Wang X, Finato N, Di Loreto C, Beltrami CA, Kajstura J & Anversa P. (1999) Myocyte death in the failing human heart is gender dependent. *Circ Res* Vol.85(No.9):856-866.
- Hofstra L, Liem IH, Dumont EA, Boersma HH, van Heerde WL, Doevendans PA, De Muinck E, Wellens HJ, Kemerink GJ, Reutelingsperger CP & Heidendal GA. (2000). Visualisation of cell death in vivo in patients with acute myocardial infarction. *Lancet*. Vol.356(No. 9225):209-212.
- Kajstura J, Cheng W, Reiss K, Clark WA, Sonnenblick EH, Krajewski S, Reed JC, Olivetti G & Anversa, P. (1996). Apoptotic and necrotic myocyte cell deaths are independent contributing variables of infarct size in rats. *Lab Invest* Vol.74(No. 1):86-107.
- Kemerink GJ, Boersma HH, Thimister PW, Hofstra L, Liem IH, Pakbiers MT, Janssen D, Reutelingsperger CP & Heidendal, GA. (2001a). Biodistribution and dosimetry of <sup>99m</sup>Tc-BTAP-annexin-V in humans. *Eur J Nucl Med* Vol.28(No. 9): 1373-1378.
- Kemerink GJ, Liem IH, Hofstra L, Boersma HH, Buijs WC, Reutelingsperger CP & Heidendal, G. A. (2001b). Patient dosimetry of intravenously administered <sup>99m</sup>Tc-annexin V. *J Nucl Med* Vol.42(No. 2):382-387.
- Kemerink GJ, Liu X, Kieffer D, Ceyssens S, Mortelmans L, Verbruggen AM, Steinmetz, ND, Vanderheyden, JL, Green, AM & Verbeke, K. (2003). Safety, biodistribution, and dosimetry of <sup>99m</sup>Tc-HYNIC-annexin V, a novel human recombinant annexin V for human application. *J Nucl Med* Vol.44(No. 6): 947-952.
- Kenis H, Zandbergen HR, Hofstra L, Petrov AD, Dumont EA, Blankenberg FD, Haider, N, Bitsch, N, Gijbels, M, Verjans, JW, Narula, N, Narula, J & Reutelingsperger, CP. (2010) Annexin A5 uptake in ischemic myocardium: demonstration of reversible phosphatidylserine externalization and feasibility of radionuclide imaging. *J Nucl Med* Vol.51(No. 2):259-267.

- Kerr JF., Wyllie AH. & Currie AR. (1972). Apoptosis: a basic biological phenomenon with wide ranging implications in tissue kinetics. *Br J Cancer* Vol.26(No. 4):239 -257
- Kietselaer BL, Reutelingsperger CP, Boersma HH, Heidendal GA, Liem IH, Crijns HJ, Narula J & Hofstra L. (2007) Noninvasive detection of programmed cell loss with <sup>99m</sup>Tc-labeled annexin A5 in heart failure. *J Nucl Med* Vol.48(No. 4):562-567.
- Kown MH, Strauss HW, Blankenberg FG, Berry GJ, Stafford-Cecil S, Tait JF, Goris ML & Robbins RC. (2001). In vivo imaging of acute cardiac rejection in human patients using (<sup>99m</sup>)technetium labeled annexin V. *Am J Transplant* Vol.1(No. 3):270-277.
- Murakami Y, Takamatsu H, Taki J, Tatsumi M, Noda A, Ichise R, Tait JF, Nishimura S. (2004). <sup>18</sup>F-labelled annexin V: a PET tracer for apoptosis imaging. *Eur J Nucl Med Mol Imaging* Vol.31(No. 4):469-474.
- Narula J, Acio ER, Narula N, Samuels LE, Fyfe B, Wood D, Fitzpatrick JM, Raghunath PN, Tomaszewski JE, Kelly C, Steinmetz N, Green A, Tait JF, Leppo J, Blankenberg FG, Jain D & Strauss HW. (2001). Annexin-V imaging for noninvasive detection of cardiac allograft rejection. *Nat Med* Vol.7(No. 12):1347-1352.
- Narula J & Strauss HW. (2003). Invited commentary: P.S.\* I love you: implications of phosphatidyl serine (PS) reversal in acute ischemic syndromes. *J Nucl Med* Vol.44(No. 3):397-399.
- Olivetti G, Abbi R, Quaini F, Kajstura J, Cheng W, Nitahara JA, Quaini E, Di Loreto C, Beltrami CA, Krajewski S, Reed JC & Anversa P. (1997). Apoptosis in the failing human heart. *N Engl J Med* Vol.336(No. 16):1131-1141.
- Peker C, Sarda-Mantel L, Loiseau P, Rouzet F, Nazneen L, Martet G, Vrigneaud JM, Meulemans A, Saumon G, Michel JB & Le Guludec D. (2004). Imaging apoptosis with (<sup>99m</sup>)Tc-annexin-V in experimental subacute myocarditis. *J Nucl Med* Vol.45(No. 6):1081-1086.
- Reshef A, Shirvan A, Waterhouse RN, Grimberg H, Levin G, Cohen A, Ulysse LG, Friedman G, Antoni G & Ziv I. (2008). Molecular imaging of neurovascular cell death in experimental cerebral stroke by PET. *J Nucl Med* Vol.49(No. 9):1520-1528.
- Saraste A, Pulkki K, Kallajoki M, Heikkila P, Laine P, Mattila S, Nieminen MS, Parvinen M & Voipio-Pulkki LM. (1999). Cardiomyocyte apoptosis and progression of heart failure to transplantation. *Eur J Clin Invest* Vol.29(No. 5):380-386.
- Stratton JR, Dewhurst TA, Kasina S, Reno JM, Cerqueira MD, Baskin DG, et al. (1995). Selective uptake of radiolabeled annexin V on acute porcine left atrial thrombi. *Circulation*. Vol.92(No.10):3113-3121.
- Tait JF, Brown DS, Gibson DF, Blankenberg FG & Strauss HW. (2000). Development and characterization of annexin V mutants with endogenous chelation sites for (<sup>99m</sup>)Tc. *Bioconjug Chem*. Vol.11(No. 6):918-925.
- Tait JF, Smith C & Blankenberg FG. (2005). Structural requirements for in vivo detection of cell death with <sup>99m</sup>Tc-annexin V. *J Nucl Med* Vol.46(No. 5):807-815.
- Taki J, Higuchi T, Kawashima A, Tait JF, Kinuya S, Muramori A, Matsunari I, Nakajima K, Tonami N & Strauss, HW. (2004). Detection of cardiomyocyte death in a rat model of ischemia and reperfusion using <sup>99m</sup>Tc-labeled annexin V. *J Nucl Med* Vol.45(No. 9):1536-1541.
- Taki J, Higuchi T, Kawashima A, Tait JF, Muramori A, Matsunari I, Nakajima K, Vanderheyden JL & Strauss HW. (2007a). <sup>99m</sup>Tc-Annexin-V uptake in a rat model of variable ischemic severity and reperfusion time. *Circ J*. Vol.71(No. 7):1141-1146.

- Taki J, Higuchi T, Kawashima A, Fukuoka M, Kayano D, Tait JF, Matsunari I, Nakajima, K, Kinuya S & Strauss HW. (2007b). Effect of postconditioning on myocardial  $^{99m}\text{Tc}$ -annexin-V uptake: comparison with ischemic preconditioning and caspase inhibitor treatment. *J Nucl Med* Vol.48(No. 8):1301-1307.
- Thimister PW, Hofstra L, Liem IH, Boersma HH, Kemerink G, Reutelingsperger CP, Reutelingsperger CP & Heidendal GA. (2003). In vivo detection of cell death in the area at risk in acute myocardial infarction. *J Nucl Med* Vol.44(No. 3):391-396.
- Tokita N, Hasegawa S, Maruyama K, Izumi T, Blankenberg FG, Tait JF, Strauss HW & Nishimura T. (2003).  $^{99m}\text{Tc}$ -Hynic-annexin V imaging to evaluate inflammation and apoptosis in rats with autoimmune myocarditis. *Eur J Nucl Med Mol Imaging* Vol.30(No. 2):232-238.
- Veinot JP, Gattinger DA & Fliss H. (1997). Early apoptosis in human myocardial infarcts. *Hum Pathol* Vol.28(No. 4):485-492.
- Vriens PW, Blankenberg FG, Stoot JH, Ohtsuki K, Berry GJ, Tait JF, Strauss HW & Robbins RC. (1998). The use of technetium Tc  $^{99m}$  annexin V for in vivo imaging of apoptosis during cardiac allograft rejection. *J Thorac Cardiovasc Surg* Vol.116(No. 5):844-853.
- Wang F, Fang W, Zhang MR, Zhao M, Liu B, Wang Z, Hua Z, Yang M, Kumata K, Hatori A, Yamasaki T, Yanamoto K & Suzuki K. (2011). Evaluation of chemotherapy response in VX2 rabbit lung cancer with  $^{18}\text{F}$ -labeled C2A domain of synaptotagmin I. *J Nucl Med* Vol.52(No. 4):592-599.
- Wencker D, Chandra M, Nguyen K, Miao W, Garantziotis S, Factor SM, Shirani J, Armstrong RC & Kitsis, RN. (2003). A mechanistic role for cardiac myocyte apoptosis in heart failure. *J Clin Invest* Vol.111(No. 10):1497-1504.
- Zhao M, Zhu X, Ji S, Zhou J, Ozker KS, Fang W, Molthen RC & Hellman RS. (2006).  $^{99m}\text{Tc}$ -labeled C2A domain of synaptotagmin I as a target-specific molecular probe for noninvasive imaging of acute myocardial infarction. *J Nucl Med* Vol.47(No. 8):1367-1374.
- Zhou D, Chu W, Rothfuss J, Zeng C, Xu J, Jones L, Welch, MJ, & Mach RH. (2006). Synthesis, radiolabeling, and in vivo evaluation of an  $^{18}\text{F}$ -labeled isatin analog for imaging caspase-3 activation in apoptosis. *Bioorg Med Chem Lett* Vol.16(No. 19):5041-5046.

IntechOpen



## **12 Chapters on Nuclear Medicine**

Edited by Dr. Ali Gholamrezanezhad

ISBN 978-953-307-802-1

Hard cover, 304 pages

**Publisher** InTech

**Published online** 22, December, 2011

**Published in print edition** December, 2011

The development of nuclear medicine as a medical specialty has resulted in the large-scale application of its effective imaging methods in everyday practice as a primary method of diagnosis. The introduction of positron-emitting tracers (PET) has represented another fundamental leap forward in the ability of nuclear medicine to exert a profound impact on patient management, while the ability to produce radioisotopes of different elements initiated a variety of tracer studies in biology and medicine, facilitating enhanced interactions of nuclear medicine specialists and specialists in other disciplines. At present, nuclear medicine is an essential part of diagnosis of many diseases, particularly in cardiologic, nephrologic and oncologic applications and it is well-established in its therapeutic approaches, notably in the treatment of thyroid cancers. Data from official sources of different countries confirm that more than 10-15 percent of expenditures on clinical imaging studies are spent on nuclear medicine procedures.

### **How to reference**

In order to correctly reference this scholarly work, feel free to copy and paste the following:

Junichi Taki, Hiroshi Wakabayashi, Anri Inaki, Ichiro Matsunari and Seigo Kinuya (2011). Apoptosis Imaging in Diseased Myocardium, 12 Chapters on Nuclear Medicine, Dr. Ali Gholamrezanezhad (Ed.), ISBN: 978-953-307-802-1, InTech, Available from: <http://www.intechopen.com/books/12-chapters-on-nuclear-medicine/apoptosis-imaging-in-diseased-myocardium>

**INTECH**  
open science | open minds

#### **InTech Europe**

University Campus STeP Ri  
Slavka Krautzeka 83/A  
51000 Rijeka, Croatia  
Phone: +385 (51) 770 447  
Fax: +385 (51) 686 166  
[www.intechopen.com](http://www.intechopen.com)

#### **InTech China**

Unit 405, Office Block, Hotel Equatorial Shanghai  
No.65, Yan An Road (West), Shanghai, 200040, China  
中国上海市延安西路65号上海国际贵都大饭店办公楼405单元  
Phone: +86-21-62489820  
Fax: +86-21-62489821



© 2011 The Author(s). Licensee IntechOpen. This is an open access article distributed under the terms of the [Creative Commons Attribution 3.0 License](#), which permits unrestricted use, distribution, and reproduction in any medium, provided the original work is properly cited.

IntechOpen

IntechOpen