

We are IntechOpen, the world's leading publisher of Open Access books Built by scientists, for scientists

5,800

Open access books available

142,000

International authors and editors

180M

Downloads

Our authors are among the

154

Countries delivered to

TOP 1%

most cited scientists

12.2%

Contributors from top 500 universities



WEB OF SCIENCE™

Selection of our books indexed in the Book Citation Index
in Web of Science™ Core Collection (BKCI)

Interested in publishing with us?
Contact book.department@intechopen.com

Numbers displayed above are based on latest data collected.
For more information visit www.intechopen.com



Early Marker for the Diagnosis of Parkinson's Disease

Silvia Marino, Pietro Lanzafame, Silvia Guerrera,
Rosella Ciurleo and Placido Bramanti
IRCCS Centro Neurolesi "Bonino-Pulejo"
Messina
Italy

1. Introduction

Parkinson's disease (PD) is a progressive disorder with a relentless neuronal cell loss in several brain areas and nuclei notably in the substantia nigra (SN). The course of this neuronal loss is still unclear and may be highly variable in different PD patients and at different phases of the disease.

At present, no treatment has proven to influence this progressive course of the disease by protecting neurons or by postponing cell death.

One potential reason for the lack of neuroprotective effects of various agents, which have been highly effective in animal experiments, is the fact that the neurodegenerative process has already substantially proceeded when the diagnosis is established on the basis of widely accepted diagnostic criteria for PD: when the patients fulfill the clinical criteria of PD, 60–70% of neurons of the SN are degenerated and the striatal dopamine content is reduced by 80%, suggesting that the remaining neurons of the SN are also altered.

The "preclinical" phase may give the incorrect impression of patients exhibiting no clinical signs or symptoms of the incipient disease. Conversely, it is known that motor signs develop insidiously and minor signs of asymmetric hypokinesia may be detected years before the diagnosis of PD can be established. In addition, non-motor symptoms such as mood disorders, olfactory, vegetative, sensory or neuropsychological signs may be noticed by the patients or physicians in advance of motor signs reflecting the dysfunction of dopaminergic or non-dopaminergic neurons.

Therefore, the term "early" or "prediagnostic" phase of PD would more appropriately characterize this stage of the disease. The clinical impression of autonomic, olfactory and affective symptoms preceding motor signs of PD are in line with the findings demonstrating that neuronal alteration, with regard to Lewy body formation, occurs first in the dorsal vagal nucleus, the olfactory bulb, the raphe and coeruleus nuclei before entering the SN.

According to neuropathological findings, it is suggested that approximately 10% of subjects older than 60 years are in the "prediagnostic" phase of PD. These subjects exhibit the pathological hallmarks of PD, like Lewy bodies and neuronal loss at the SN, without showing the motor signs during life time that allow the diagnosis of PD. In only 10% of this group with so-called "incidental Lewy body disease", neuronal loss will proceed reaching the degree where motor symptoms are distinct enough to allow the diagnosis of PD.

It would be of great interest with respect to research and treatment to identify those subjects at risk i) to initiate neuroprotective treatment earlier, giving them a better base to act and ii) to define the causes of more rapid neuronal loss and disease progression in those patients with "incidental Lewy body disease" who will cross the threshold of critical neuronal loss at the SN and develop PD.

The duration of the early or prediagnostic period remains unknown. The duration of this phase of PD was estimated to last from a few years up to several decades before the first symptoms are noticed by the patients.

Several procedures have been proposed to identify subjects in early ("prediagnostic") stages of PD. In the following we present some instrumental approaches to identify patients in the early stages of PD.

One set of simple behavioural tasks that may provide insight into the neural control of response suppression uses saccadic eye movements to investigate and quantify motor impairments in PD. The study of ocular movements has been increasingly used to detect subtle pathological modifications, caused by a wide variety of neurological diseases.

A recent method, a new vision-based, nonintrusive, eye tracker, previously described in de novo PD patients (Marino et al., 2007), was proposed as a possible tool for supporting the diagnosis of PD in association with levodopa test, as an add-on to the Unified Parkinson Disease Rating Scale (UPDRS) score (Marino et al., 2010).

In addition, conventional MR Imaging (cMRI), as well as different advanced MRI techniques, including magnetic resonance spectroscopy (MRS), magnetization transfer imaging (MTI), diffusion-weighted and diffusion tensor imaging (DWI/DTI) are helpful to distinguish PD from atypical or secondary PD, especially in early stage of disease where a differentiation of these conditions is not easy.

Objective olfaction tests, such as olfactory-evoked potentials or functional magnetic resonance imaging, can be used to assess the severity of olfactory dysfunction, an early clinical feature of PD, its correlation with cerebral changes, and then the risk of developing PD in asymptomatic subjects.

2. Analysis of pursuit ocular movements in Parkinson's disease by using a video-based eye tracking system

Patients with PD characteristically have difficulty initiating movements (akinesia). When movements are initiated, they are of low velocity (bradykinesia) and reduced amplitude (hypokinesia). In addition, patients with PD are unable to sustain repetitive motor action. When they attempt to open or close the hand rapidly or tap the foot on the ground, the movement rapidly decreases in amplitude and slows in speed until it ceases. This disability is easily appreciated in the progressive micrographia of the handwriting of PD patients.

Research in the past 30 years has established that PD impairs control of eye movements. Voluntary saccades, such as self-paced, predictive and remembered saccades, are hypometric, multistep, of reduced velocity and of increased duration. Visually guided saccades are normal. Advanced PD is known to be associated with reduced ocular smooth pursuit gain (Bares et al., 2003; Lekwuwa et al., 1999). This has been explained in terms of advanced PD affecting other structures outside the basal ganglia.

A recent study (Marino et al., 2007) described a new eye movement measurement and analysis system which was developed for generating a set of visual stimuli paradigms and which is able to measure, analyze and record the resulting horizontal eye movements.

Oculomotor movements are controlled by many brain areas including the cerebral cortex, basal ganglia, brain stem and cerebellum. PD is a condition of degeneration of dopaminergic neurons in the substantia nigra pars compacta, resulting in progressive basal ganglia dysfunction. Because important eye movement pathways travel through the basal ganglia, aspects of oculomotor movement control should be impaired by the disease progression. This study showed that deficit in Pursuit Ocular Movements (POM) also occurs in patients with non-advanced PD and is closely correlated with clinical stage and motor scores.

The authors used a vision-based non-intrusive eye tracker. The developed interface provides the patients a visual stimulation. This system was able to measure, analyze and record the resulting horizontal eye movements.

The subjects were seated at 60 cm from the scene monitor, in front of the camera, on a chair which could be raised or lowered so that the subject's eyes were at the same height as the PC monitor, when the visual stimulus was administered on. The subjects were asked to perform the test three times.

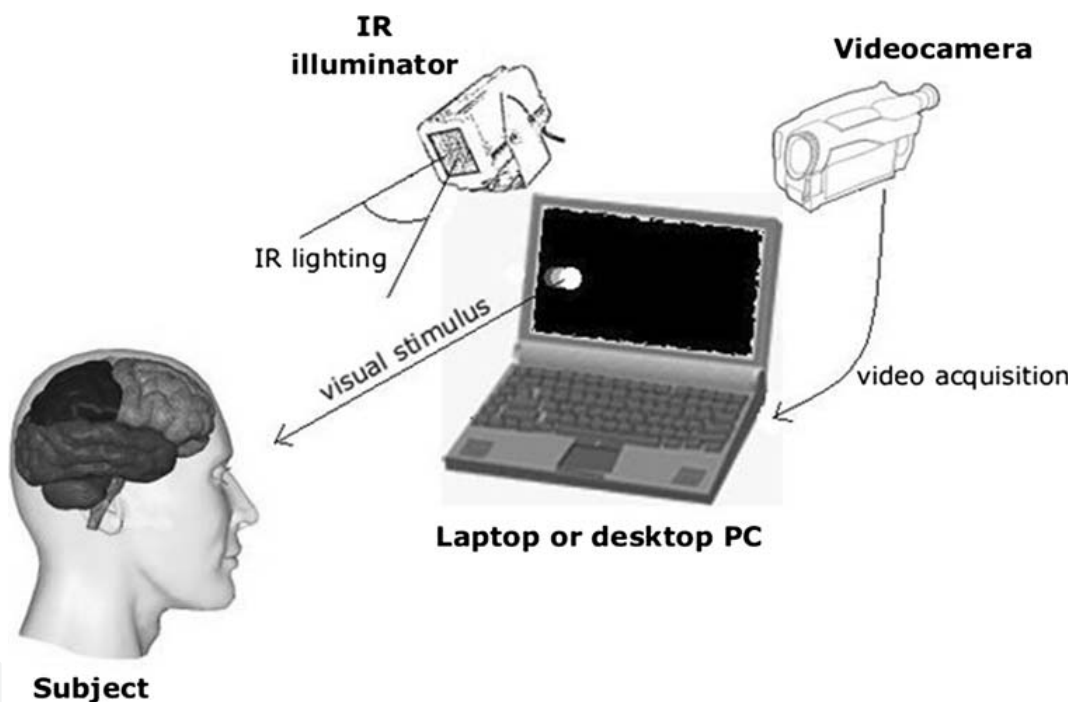


Fig. 1. Video-based eye-tracking functional scheme: subject looks at the screen (laptop or desktop PC) and all mechanical and electronic supports help to perform a real-time acquisition of eye movements.

The results of the study confirm that POM are clearly impaired in patients with de novo PD. The same authors (Marino et al., 2010) studied the POM by using the same vision-based non-intrusive eye tracker, in patients with suspected PD, before and after L-Dopa administration.

All patients had a positive test demonstrated by the improvement of UPDRS motor subscore, after L-Dopa administration, and as a new finding, by the improvement of POM.

A plausible explanation is that the improvement of horizontal eye displacement gain was induced by the dopaminergic action of L-Dopa. Some newly diagnosed PD patients have been shown to improve POM after L-Dopa treatment and this suggested the possibility of dopaminergic control of ocular movements, particularly smooth pursuit and saccades.

The POM methodology could be considered as a not invasive, objective and repetitive method (and these conditions could be an advantage with respect to only UPDRS examination) to support the clinical evaluation.

This method could be considered as a possible tool for supporting the diagnosis of PD in association with levodopa test, as an add-on to the UPDRS score. These results showed that this vision-based eye tracker can be used as reliable indices of disease severity in early and suspected PD patients.

3. Diagnosis of Parkinson's disease by using MR techniques

PD in its early stages can easily be mistaken for any number of disorders. Indeed PD is most likely to be confused with various Atypical Parkinsonian Disorders (APDs) such as Progressive Supranuclear Palsy (PSP), Multiple-System Atrophy (MSA), especially the Parkinson variant of MSA (MSA-P), and Corticobasal Degeneration (CBD).

A differentiation of these clinical entities, each characterized by completely different natural histories, may be challenging, particularly in the early stages of the disease, where overlapping clinical signs lead to a high rate of misclassification. However, a differentiation between APDs and PD, that may make easier early diagnosis, is crucial for determining the prognosis and choosing a treatment strategy.

Magnetic Resonance Imaging (MRI) plays an important role in the differential diagnosis in PD. Conventional MRI (cMRI) and advanced MRI techniques, including proton magnetic resonance spectroscopy, diffusion-weighted and diffusion tensor imaging and magnetization transfer imaging, are helpful to distinguish PD from atypical or secondary PD.

3.1 Magnetic Resonance Spectroscopy

MRS is a non-invasive technique that can be used to measure the concentrations of different low-molecular weight chemicals. The technique is based on the same physical principles as MRI, i.e. the detection of energy exchanges between external magnetic fields and specific nuclei within atoms. MRS is the more modern version of Nuclear Magnetic Resonance which over the past five decades has evolved from a technique used in chemistry to determine the structure of molecules to a method with which to probe the metabolism of cells, tissues, intact animals and humans (Allen, 1990; Avison et al., 1986).

MRS has been demonstrated in vivo for different nuclei, including ^1H , ^{31}P , ^{13}C , ^{15}N , ^{19}F and ^{23}Na . While most of these nuclei are very difficult to detect, ^1H and ^{31}P are available in the human brain in significant concentration and have the appropriate physical configuration to be detected by MRS. For instance, ^{31}P -MRS has been the first to be applied to medicine in vivo, and can be used to evaluate brain energy metabolism by directly and non-invasively measuring of Adenosine Triphosphate (ATP), Phosphocreatine (PCr) or Inorganic Phosphate (Pi) concentrations. While ^{31}P -MRS was the first spectroscopic technique to be applied in vivo, the main nucleus studied today in neurospectroscopy is ^1H , which provides information on markers of neurons, myelin, energy metabolism and other metabolically active compounds.

^1H -MRS detects very small differences in the frequencies of proton resonances from comparatively large volumes (1 ml or more) of brain tissue. The frequency of the resonance is affected by its local chemical environment, while the amplitude reflects its concentration. As such, ^1H -MRS is able to provide a measurement of certain proton-containing chemical

markers. Proton spectroscopy presents the problem that metabolites at millimolar concentration must be detected in the presence of a background water signal that is present at about 100 molar. For this reason solvent-suppression techniques have been combined with localization schemes to produce spatially localized solvent-suppressed spectra. The two most commonly used localization methods are STEAM and PRESS. These methods can be implemented as single-voxel and multi-voxels methods. With the single voxel localization, the signal is acquired from a single brick-shaped volume of various sizes (minimum volume 2-3 cm³). The multi-voxel or MR spectroscopic imaging (MRSI) or Chemical Shift Imaging (CSI) approach generates individual spectra from multiple voxels at the same time (minimum volume 0.5-1 cm³). Single-voxel spectroscopy detects the signal from a single region during one measurement, whereas MRS imaging, using additional phase-encoding pulses, obtains the signal from multiple regions at the same time and provides the information of spatial distribution of major cerebral metabolites. The spatial information in MRI is done in 2-D for one or more slices and can generate low-resolution images for each metabolite by integration of the MR signals from each voxel (Ross & Bluml, 2001). The possibility to acquire the spectra from 2D multi-voxel allows to study the metabolite distribution of a large area of the brain with the advantage of identifying more anatomical and functional details. Most importantly, collecting data from many different adjacent regions simultaneously reduces the potential for systemic errors that can affect sequential measurements and thus results in more accurate repeated studies.

The metabolites detectable with ¹H-MRS include the prominent resonances of *N*-acetylaspartate (NAA), choline-containing compounds (Cho), creatine + phosphocreatine (Cr), myo-inositol (mI), lactate (Lac), and a variety of other resonances that might not be evident depending on type and quality of spectra as well as on the pathological condition (Figure 2) (Bonavita et al., 1999; Lin et al., 2005).

NAA, which resonates at 2.02 parts per million (ppm), represents the largest proton metabolic concentration in the human brain after water. Indeed the concentration of NAA reaches on the order of 10 μmol/g. NAA is widely interpreted as a neuronal marker and implicated in several neuronal processes, mitochondrial functioning and osmoregulation. NAA synthesis occurs in mitochondria and requires acetyl-CoA and L-aspartic acid as substrates. NAA has been proposed to serve as a mitochondrial shuttle of acetyl-CoA used for fatty acid synthesis. NAA undergoes dramatic increase during brain development and significant decrease during lesion progression in various neurodegenerative diseases, suggesting an important, unknown role in brain metabolism (Clark, 1998).

The Cho peak (3.2 ppm) represents a combination of several choline-containing compounds, including free Cho, phosphorylcholine and glycerophosphorylcholine, and to a small extent acetylcholine. Free Cho acts as a precursor to acetylcholine, while glycerophosphorylcholine is a product of breakdown of membrane phosphatidylcholine and acts as an osmoregulator. The concentration of Cho is relatively low on the order of 0.5 to 1.5 μmol/g and can be altered in normal aging and many focal inflammatory diseases. The Cho peak is often viewed as a marker of membrane turnover or inflammation in ¹H MRS studies.

The concentration of total Cr is estimated on the order of 8 to 9 μmol/g and is approximately 20% higher in human gray matter than white matter. In ¹H-MRS, the resonance at 3.03 ppm represents total Cr and PCr supplies phosphate for conversion of ADP to ATP in creatine kinase reaction. Indeed these metabolites buffer the energy use and energy storage of cells. The level of total Cr mainly remains constant in many neuronal

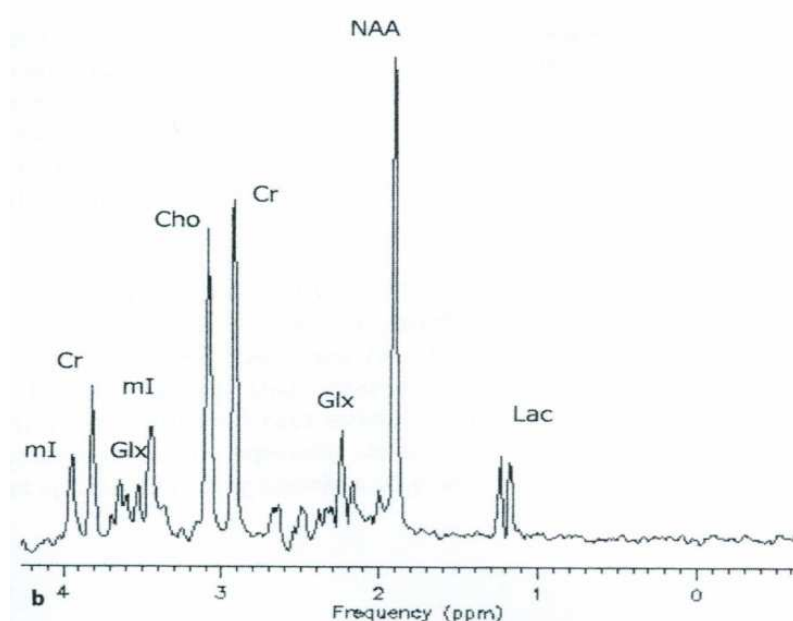
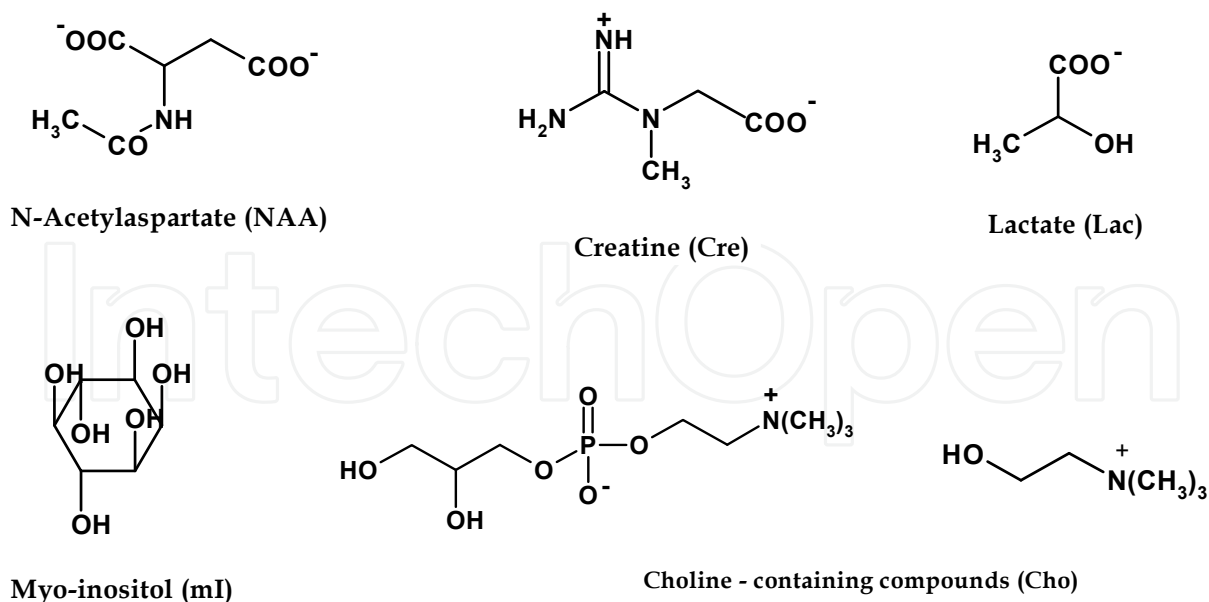


Fig. 2. Chemical structure of main cerebral metabolites detected by ¹H-MRS.

diseases. Thus, total Cr is often used as an internal reference (i.e., a denominator in metabolite signal ratio).

The mI (3.56 ppm) has been recognized as a cerebral osmolyte or an astrocyte marker due to its cellular specificity based on cell culture studies. mI is also been known as a breakdown product of myelin and precursor of inositol polyphosphate, an intracellular messenger. The concentration of mI is on the order of 5–10 $\mu\text{mol/g}$ while one of its isomers, sylo-inositol, has substantially lower concentrations of on the order of less than 1 $\mu\text{mol/g}$ in the brain and remains relatively consistent in many diseases.

The Lac (1.3 ppm) is an end product of anaerobic glycolysis, thus increase in Lac concentrations often serves as an index of altered oxidative metabolism, i.e., in ischemia, hypoxia, and cancer. The concentration of Lac is on the order of about 1 $\mu\text{mol/g}$ in normal

aerobic conditions. Increases of Lac in the brain are often accompanied by decreased intracellular pH and high-energy phosphates. The proposed role of Lac is a source of energy for neurons and the transport of Lac plays an essential role in the concept of metabolic coupling between neurons and glia.

The concentration changes of all metabolites detected by ^1H -MRS and ^{31}P -MRS could help to evaluate PD subjects in the "preclinical" stages, especially in early differential diagnosis.

^1H -MRS of striatal structures might differentiate PD from APDs by virtue of reduced NAA/Cr ratios in MSA but not PD. ^1H -MRS showed reduced NAA/Cr ratios in the lentiform nucleus in six of seven MSA-P cases, whereas normal levels of putaminal NAA were found in eight of nine PD subjects (Davie et al., 1995).

As compared to normal controls, in patients with PSP, CBD, and MSA, but not in those with PD, significant reduction of the NAA/Cr ratio in the frontal cortex was found (Abe et al., 2009). Patients with CBD showed significant reduction of the NAA/Cr ratio in the frontal cortex and putamen as compared to patients with PD and MSA. Patients with PSP showed a significant reduction of the NAA/Cr ratio in the putamen as compared with patients with PD and MSA. Patients with CBD showed clear asymmetry in the putamen as compared to controls and other patients (Abe et al., 2009). By application of ^1H -MRSI statistically significant difference in regional patterns of the NAA/Cr and NAA/Cho ratios between patients with PD and those with CBD and between patients with PD and those with PSP was found (Tedeschi et al., 1997).

Other ^1H -MRS examinations didn't show significant difference between the PD patients and the control subjects (Tedeschi et al., 1997), also in the striatum (Holshouser et al., 1995), in the putamen and globus pallidus (Federico et al., 1997), and in occipital lobe (Bowen et al., 1995). The NAA/Cho and NAA/Cr ratios were significantly reduced in the putamen and globus pallidus of MSA and the PSP patients, in which neuronal loss involves, compared with the control subjects (Federico et al., 1997). In another study Federico et al. showed that NAA/Cho peak ratio was significantly reduced in MSA and in PSP patients compared to PD patients and to control. Moreover the NAA/Cr peak ratio was significantly reduced in MSA, in PSP and in PD patients also compared to controls, but only in MSA compared to PD patients (Federico et al., 1999).

Normal ^1H -MRS data could suggest the clinical diagnosis of PD, whereas low striatal levels of NAA could suggest the diagnosis of MSA or PSP.

However, further MRS studies have shown reduced NAA/Cr and NAA/Cho ratios in the lentiform nucleus not only in APD, but also in PD (Clarke & Lowry, 2001; Firbank et al., 2002).

Technical factors such as MRS technique including different echo-time and relaxation-time, voxel sizes, field strength and pulse sequences used in the different studies, may be responsible for some of the variation of results seen in the published literature on ^1H -MRS for the differential diagnosis of neurodegenerative parkinsonism (Clarke & Lowry, 2001; Firbank et al., 2002). The development of ^1H -MRS at higher magnetic field strengths may lead ^1H -MRS to a more important role as imaging tool in the differential diagnosis of parkinsonian disorders.

^1H -MRS of the brain with high magnetic field at 3 Tesla has many advantages that, with respect to the well-established and technologically advanced 1.5 Tesla ^1H -MRS, include better signal to noise ratio (SNR) and increased spectral, spatial and temporal resolution,

allowing the acquisition of high quality, easily quantifiable spectra in acceptable imaging times (Di Costanzo et al., 2007).

The increase SNR associated with higher magnetic fields permits shorter imaging times for a given spatial resolution, higher resolution for a given imaging time or the combination of both.

The spectral resolution is linearly correlated with the field strength and is about twice at 3 Tesla as compared to 1.5 Tesla. Clinical 1.5 Tesla scanners equipped with ^1H -MRS packages allow the quantification of NAA, Cho, Cr and lactate at long echo-time, and further metabolites, such as mI and glutamate-glutamine (Glx), at short echo-time. mI is a strongly coupled system and resonates at four chemical shift positions. At 1.5 Tesla, only the singlet component at 3.57 ppm is detected. However, at 3 Tesla this resonance is resolved into its components at 3.55 and 3.61 ppm. Therefore by increasing of spectral resolution and SNR, the quantification precision of mI is significantly better at 3 Tesla relative to 1.5 Tesla (Srinivasan et al., 2004).

Despite shorter T2 relaxation times and increased field inhomogeneity, the chemical shift doubling at 3 Tesla yields better spectral resolution. This is reflected by improved baseline separation of Cho and Cr, which are only 0.2 parts per million (ppm) apart, and by slightly better resolution of Glu/Gln region, between 2.05 and 2.5 ppm, at shorter TE.

Higher field strengths also lead to a flatter baseline that contributes to more reliable estimation of peak area and, hence, more precise quantification, in addition to a more accurate identification of each metabolite.

This has been shown by a recent study applying multiple regional single voxel ^1H -MRS including putamen, pontine basis and cerebral white matter at 3 Tesla in 24 patients with MSA compared to 11 PD patients and 18 controls. Significant NAA/Cr reductions have been shown in the pontine basis of both patients with MSA-C (cerebellar ataxia variant of MSA) and MSA-P, while putaminal NAA/Cr was only reduced in the patients with MSA-P. Eight of the 11 MSA-P patients compared to none of the PD and control group were classified correctly by combining individual NAA/Cr reductions in the pontine basis and in the putamen. These results suggest that combined assessment of NAA/Cr in the pontine basis and putamen may be effective in differentiating MSA-P from PD in terms of the high specificity of reduced NAA/Cr in the pontine basis or in the putamen in patients with MSA-P (Watanabe et al., 2004).

Moreover, in these studies, the metabolite concentrations were expressed in terms of semiquantitative ratios such as NAA/Cr, NAA/Cho, Cho/Cr and mI/Cr. In relative quantification, one of the metabolite peaks measured is used as the concentration standard and serves as the denominator of the peak ratios. As a result, the total number of quantifiable metabolites is decreased by one. Furthermore, alterations in the peak ratio do not necessarily reflect a change in the concentration of the numerator. The alteration may be caused by change in the concentration of the numerator, the denominator, or both or may be due to changes in relaxation behavior. The assumption that the concentration of certain reference metabolites (e.g. total creatine, choline) remains constant may be incorrect under normal conditions, as well as in many pathologic states. It is therefore advisable to obtain concentration expressed in standard units (such as millimoles per kilogram wet weight) by applying absolute quantification.

Combined ^{31}P - and ^1H -MRSI at 3 Tesla measuring absolute adenosine diphosphate (ADP), ATP, Cr and PCr concentrations in two well-defined cohorts of patients with early and advanced PD has been performed to evaluate brain energy metabolism (Hattingen et

al., 2009). In the putamen and midbrain of both PD groups compared to control was found a bilateral reduction of high-energy phosphates such as ATP and PCr as final acceptors of energy from mitochondrial oxidative phosphorylation. In contrast, low-energy metabolites such as ADP and Pi were within normal ranges. Patients with early Parkinson's Disease, with clearly lateralized motor symptoms, exhibited a significant reduction of putamen high-energy phosphates in the less affected hemisphere with a less pronounced dopaminergic cell loss. Therefore, mitochondrial dysfunction is a rather early occurring and subsequently persistent event in the pathophysiology of dopaminergic degeneration in PD. These data strongly support the hypothesis that mitochondrial dysfunction is involved early in pathogenesis of PD and it may be used as early marker for this pathology.

In vivo MRS is increasingly utilized for the study of neurochemistry and cerebral energy metabolism in PD. Particularly, the recent technical advances of in vivo MRS including the availability of higher magnetic fields permitting improved spectral and spatial resolution, the development of a reliable method for absolute metabolite quantification, the development of various spectroscopic methods to enhance metabolite signal identification, and the application of combined ^{31}P - and ^1H -MRS can be used to examine the changes in neurochemical profile non-invasively and to achieve a differential diagnosis of PD versus other forms of parkinsonism, especially in early stages of disease when signs and symptoms of different forms of parkinsonism have greater overlap. However, several multicentre trials using a larger sample of patients, absolute quantification of tissue metabolite concentrations and a standardized technique are required to fully determine the place of MRS in early clinical differential diagnosis.

3.2 Conventional Magnetic Resonance

In the early disease stages the clinical separation of atypical parkinsonism disorders (APD)s from PD carries a high rate of misdiagnosis. An early differentiation between APD and PD, each characterized by completely different natural histories, is crucial for determining the prognosis and choosing a treatment strategy.

The principles of MR imaging are based on the ubiquitous presence of hydrogen in body tissues and the spin of the hydrogen atom proton, which induces a small magnetic field. In general, T2- weighted sequences are sensitive to changes in tissue properties, including tissue damage, due to changes of the transverse magnetization or T2 decay. Neurodegenerative processes characterized by cell loss, increased age-related deposition of iron or other paramagnetic substances, and by astroglial reaction and microglial proliferation may lead to signal changes in affected brain areas, like the basal ganglia or infratentorial structures, in neurodegenerative parkinsonism (Duguid et al., 1986; Gupta et al., 2008; Hirsch et al., 2007; Wilms et al., 2007).

Because cMRI is believed to be usually normal in patients with PD, while it frequently shows characteristic abnormalities in patients with APD, cMRI images takes a major part in excluding underlying pathologies such as vascular lesions, multiple sclerosis, brain tumors, normal pressure hydrocephalus, bilateral striopallidodentate calcinosis, and other potential, but rare, causes of symptomatic parkinsonism such as Wilson disease, manganese-induced parkinsonism, or different subtypes of neurodegeneration associated with brain iron accumulation.

At 1.5 T, patients with advanced PD, and sometimes those with APD, may show distinct abnormalities of the substantia nigra, including signal increase on T2-weighted MR images, smudging of the hypointensity in the substantia nigra towards the red nucleus or signal loss

when using inversion recovery MRI (Brooks, 2000; Rutledge et al., 1987; Savoiaro et al., 1994).

Biochemical studies have reported increased iron content in the substantia nigra pars compacta (SNc) in PD, with changes most marked in severe disease, suggesting that measurement of nigral iron content may provide an indication of the pathologic severity of the disease (Youdim et al., 1990). Iron accumulates in the brain as a function of age, primarily in the form of ferritin and particularly in oligodendrocytes, but also in neurons and microglia. The adult brain has a very high iron content, particularly in the basal ganglia. Brain iron concentration is highest in the globus pallidus, substantia nigra, red nucleus, caudate, and putamen. Abnormally elevated iron levels are evident in various neurodegenerative disorders, including PD where there is evidence of increased iron in the substantia nigra (Dexter et al., 1989; Sofic et al., 1988). Signal changes on T2-weighted images in the basal ganglia as well as in infratentorial structures have been reported for all APDs at 1.5 T, where they have been used as a differentiating criterion from PD. Furthermore, estimation of transverse relaxation in patients with PD, using a 1.5 Tesla whole body imaging system, showed shortened T2 values in substantia nigra, caudate and putamen in PD patients as compared to healthy controls (Antinoni et al., 1993). These data do suggest a potential utility of these measurements as a biomarker of disease progression.

3.3 Magnetization Transfer Imaging

Standard MR imaging detects signal only from hydrogen nuclei (protons) that are “mobile” (contained within a liquid); if a hydrogen atom is part of a molecule that is large and cannot move about freely, the signal from that hydrogen atom decays too quickly to be seen using a clinical MR imaging scanner. Such protons are found in large molecules (macromolecules), such as those of cell membranes and myelin. The mobile protons are in constant motion, however, and come into regular and intimate contact with the macromolecular protons, and the spin state (the proton magnetization state, which is measured with MR imaging) of the mobile protons can exchange with that of the macromolecular protons. This exchange of magnetization forms the basis of magnetization transfer imaging (Horsfield, 2005). Magnetization transfer is a physical phenomenon that results from interactions and exchanges between magnetized protons in water that are unrestricted in their molecular motion and those that are restricted because of their association with macromolecules. The latter have a much shorter T2 relaxation time and broader resonance, which makes it possible to selectively saturate their magnetization with an appropriate off-resonance pulse. The acquisition of two images, one obtained with the magnetization transfer saturation pulse turned on and the other with it turned off, can be used to generate a magnetization transfer ratio (MTR) image in which the signal intensity of each voxel is determined by the percent magnetization transfer in that voxel.

A MTR image is calculated from a pair of images acquired in an identical way, except that one has extra off-resonance RF pulses applied, which saturates the macromolecular magnetization pool. The MTR is calculated for every corresponding pair of pixels in the two images. If the intensity of the pixel in the image without saturation pulses is M_0 and the corresponding intensity in the image with saturation pulses is M_s , the MTR is as follows:

$$\text{MTR} = [(M_0 - M_s) / M_0] * 100\%$$

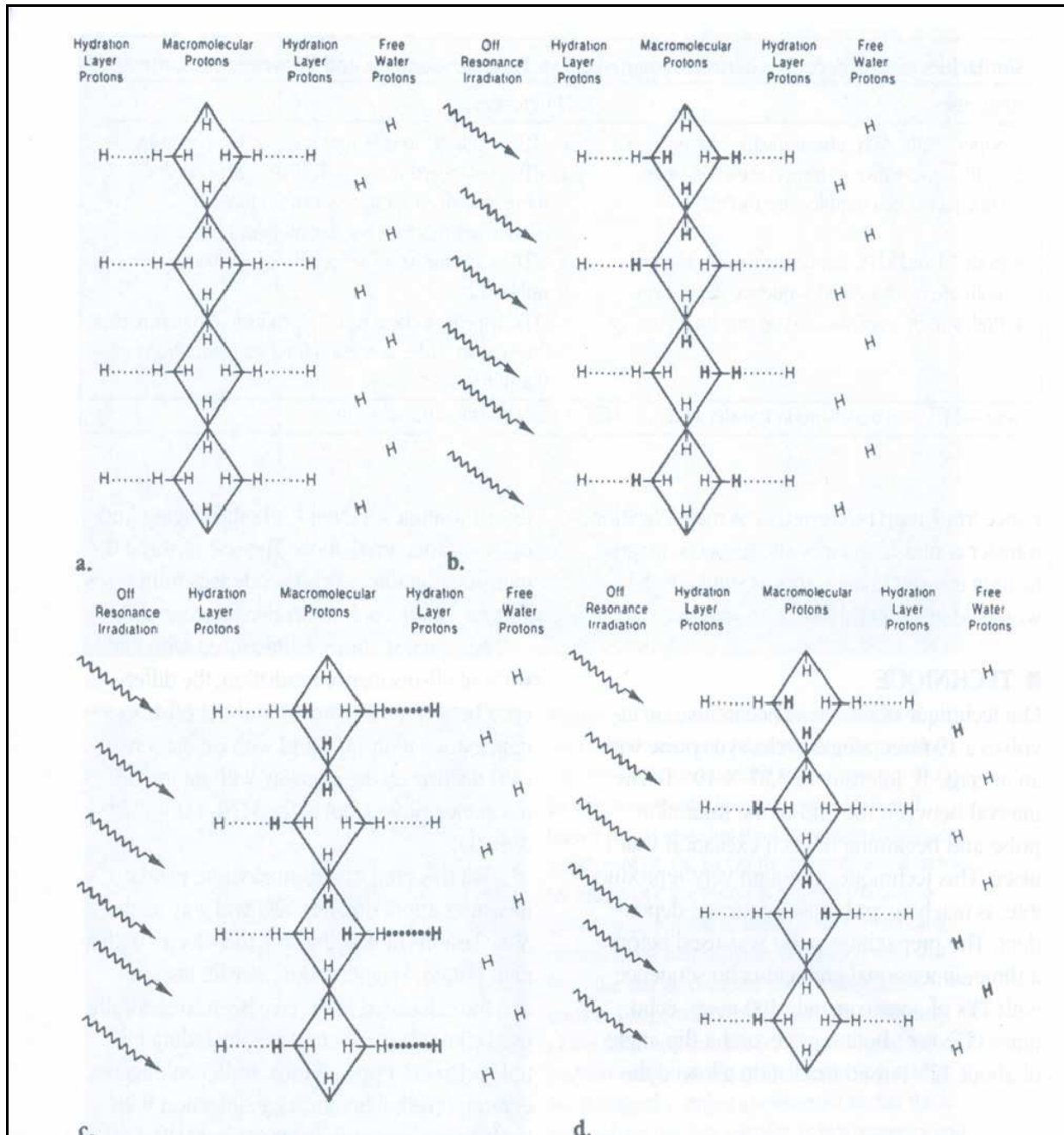


Fig. 3. Diagrams illustrate magnetization transfer, that is, the exchange of longitudinal magnetization between restricted protons associated with rigid macromolecules and free water protons. (a)Diagram shows macromolecular protons (H), including hydration layer protons and free water protons. (b) Off-resonance irradiation (arrows) saturates the immobile macromolecular protons (unsaturated protons are designated H, while saturated are designated H). (c) Saturation is transferred to hydration layer protons (...H). (d) Saturated protons diffuse into the free water proton pool and decrease the signal from this pool.

Misregistration can occur if the subject moves between the two scans, but the M0 and Ms images must be in register; otherwise, artifacts appear at the edges of features in the calculated MTR image, with false MTR values. It is best to acquire the two images in an interleaved way (Barker et al., 1996; Inglese et al., 2001) although it is possible to register

them after acquisition. Two forms of data analysis have been used extensively for MTR images: region of interest (ROI) and histogram analysis. ROI analysis may be useful for elucidating the degree of tissue damage within individual lesions seen on T2-weighted scans or within anatomic regions associated with particular symptoms. ROI analysis, however, can be subject to operator bias, because the placement of regions is normally done manually. This could be overcome by first registering scans to an anatomic template and using ROIs defined on the template image. With MTR histogram analysis, a histogram of pixel MTR values is formed from the whole of the brain parenchyma; thus, focal damage and more widespread diffuse tissue damage are reflected in changes to the shape of the histogram, with a general shift toward lower MTR values as the density of macromolecules is reduced with demyelination or axonal loss. Extraction of the brain parenchyma, using the same procedures that are used in atrophy measurements, is a necessary preprocessing step. After normalization (to remove any effect of the absolute brain size), the MTR histogram can be characterized by several simple statistics, such as the histogram peak position, the peak height, and the average MTR. The employment of off-resonance irradiation was first proposed by Wolff and Balaban (Wolff & Balaban, 1989), who found that use of an off-resonance radio-frequency preparation pulse could generate excellent tissue contrast in images of rabbit kidney, and they referred to the technique as "magnetization transfer contrast." The initial magnetization transfer occurs between the macro-molecular protons and the transiently bound hydration layer protons. The efficiency of this interaction is directly related to the number of irradiation sites (hydrogen bonds) and their mobility. The utilization of magnetization transfer was extended to clinical imaging, including its use with gradient-echo imaging and MR angiography (Wolff et al., 1991; Pike et al., 1992). A decrease in the MTR, which reflects a reduction in the exchange of magnetization of protons that are tumbling freely and those that are bound to macromolecules, is evidence of demyelination in cerebral white matter. MTR imaging is sensitive to both microscopic and macroscopic pathology and provides quantitative data on the extent of myelin loss in MS.

By using MTR, abnormalities of the basal ganglia and SN have been reported in patients with PD, MSA and PSP. One study (Eckert et al., 2004) investigated the potential of MTR imaging in the differential diagnosis of neurodegenerative parkinsonism, including 37 patients with different parkinsonian syndromes and 20 age-matched controls. The main finding in this study was a change in the MTR in the globus pallidus, putamen, caudate nucleus, SN, and white matter in PD, MSA, and PSP patients, matching the pathologic features of the underlying disorder. MTR were significantly reduced in the putamen in MSA patients compared with PD patients and healthy controls, as well as in the SN in patients with PSP, MSA, and PD. Another study (Yonca et al., 2007) determined the role of MTR in the early period of 33 patients with PD, comparing the findings with those in 30 normal healthy volunteers. Signal intensity measurements were obtained from 15 anatomic regions: SNc, substantia nigra pars reticulata (SNPR), red nucleus, dentate nucleus, cerebellum, pons, globus pallidus, putamen, caudate nucleus, thalamus, internal capsule posterior horn, forceps major, forceps minor, genu, and splenium of corpus callosum. Results showed a significant decrease of MTR in the SNc, SNPR, red nucleus, and pons compared with normal healthy volunteers. No significant decrease in MTR were found at supratentorial paraventricular white matter and cerebellum, which may be attributed to the duration of the disease.

Perhaps in the initial stages of PD, supratentorial paraventricular white matter is not influenced by the disease. The decrease of MTR at SNc, SNPR, red nucleus, and pons in PD patients can be attributed to neurodegeneration (Tambasco et al., 2003)).

These studies show that MTR analysis may be a useful technique for PD diagnosis and decrease in MTR probably begins previously than the clinical onset of the disease.

3.4 Diffusion-Weighted Imaging

DWI imaging visualizes the random movement of water molecules in the tissue by applying diffusion-sensitizing gradients to assess changes in diffusion magnitude and orientation of water molecules in tissue. Quantification of the diffusivity is achieved by applying diffusion-sensitizing gradients of different degrees in 3 orthogonal directions and calculating the apparent diffusion coefficient (ADC) for each direction. The ADC is very dependent on the direction of diffusion encoding.

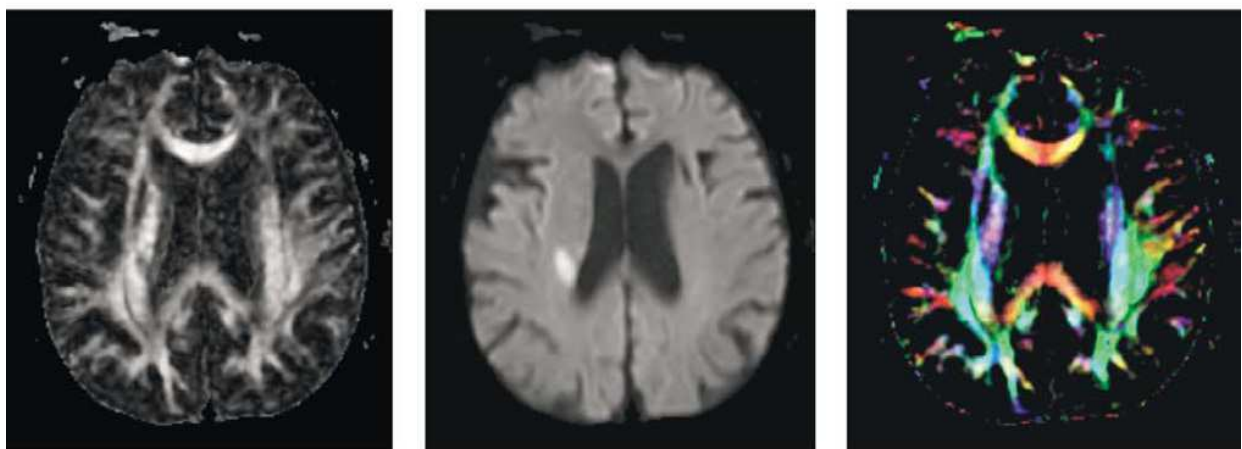
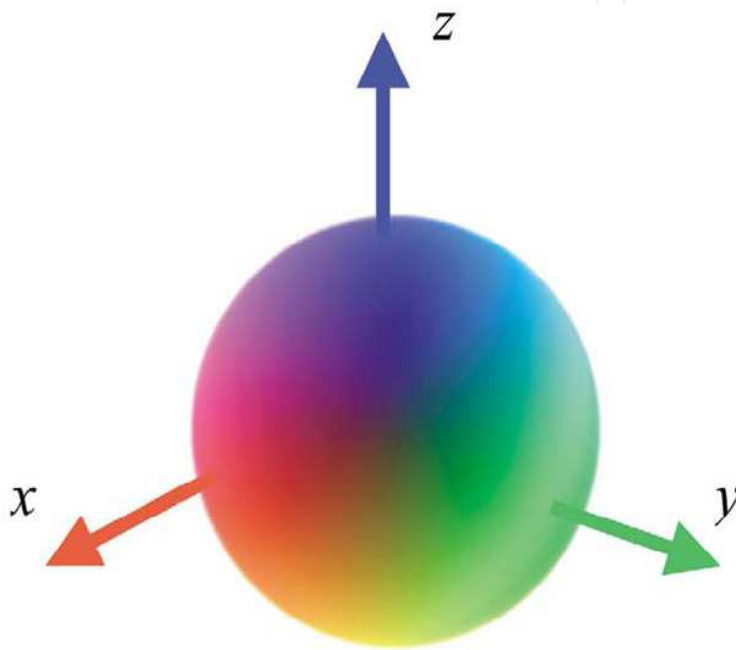


Fig. 4. Image-based visualization of diffusion tensor data. Top: Sphere representing directional color encoding. Second row: 2D images of image based visualization (from left: FA image, mean diffusivity image, and color-encoded image).

The random translational motion (diffusion) of water molecules in tissue is restricted by the highly organized architecture of fiber tracts in the central nervous system. Neuronal loss and gliosis disrupt this architecture, resulting in an increase of diffusivity and ADC. The complex neuronal architecture with its organization in fiber bundles that are surrounded by dense myelin sheaths leads also to a distinct anisotropy of water diffusion, which is facilitated along the direction of fiber tracts and restricted perpendicular to the fibers.

The degree of anisotropy can be quantified by applying diffusion-sensitizing gradients in at least 6 directions, which permits calculation of fractional anisotropy (FA). Decreased FA values represent tissue degeneration due to normal aging or due to pathologic reasons such as neurodegeneration. Both diffusivity and FA can be combined to form the so-called diffusion tensor, which indicates direction and extent of diffusivity with the help of a vector (Hagmann et al., 2006; Le Bihan, 2003; Schocke et al., 2004). The central nervous system (CNS) is highly organized in numerous tracts of myelinated fibre bundles, whereby the movement of the water molecules is restricted perpendicular to these fibre bundles. The resulting anisotropic diffusion is quantified by the FA, which is determined by diffusion-sensitised gradients in at least six directions. Both the diffusivity and the FA form the diffusion tensor (Le Bihan, 2003).

Widespread cerebral changes are observed in advanced stages of PD, suggesting that PD is a multisystem disorder.

Recently, several studies pointed out the capability of the histogram analysis of the apparent diffusion coefficient computed from diffusion-weighted images and of the mean diffusivity and FA computed from DTI to reveal brain-tissue damage in early clinical stages of neurodegenerative diseases. A recent study including 27 patients with de novo drug-naïve PD hypothesized that global measurements of brain volume and structure, such those possible with SIENAX software (part of FSL 4.0 <http://www.fmrib.ox.ac.uk/fsl/>) and histogram analysis of DTI could reveal subtle tissue changes in the early clinical phase of PD (Tessa et al., 2008). Accordingly, a group of patients with drug-naïve de novo PD and a group of 16 healthy controls, were investigated with SIENAX and DTI. Results showed no significant differences for total brain, GM, and WM volumes and histogram-derived mean diffusivity metrics between controls and the whole group of patients with PD or any subgroup of patients with PD. As compared with controls, patients with PD as a whole and patients with the akinetic-rigid type showed an increase of the twenty-fifth percentile of the FA histogram. In patients with the akinetic-rigid type, there also was a trend toward an increase of the mean and fiftieth and seventy-fifth percentiles, and a reduction of the skewness of the FA histogram. This finding is consistent with the hypothesis that subtle GM loss is present in patients with PD since the early clinical phases and that this feature is more pronounced in patients with akinetic-rigid type. Another recent study including only patients with newly diagnosed PD used high-resolution DTI at 3 Tesla to evaluate rostral, middle, and caudal ROIs within the SN on a single slice of the midbrain and this study found that PD patients could be completely separated from the control group based on reduced FA values in the caudal ROI of the SN, such that further confirmatory studies seem to warrant. By using statistical parametric mapping analysis of DT imaging, changes in FA were found in the frontal lobes, including the supplementary motor area, the presupplementary motor area, and the cingulum in non demented PD patients relative to controls, whereas VBM analysis in the same patients revealed no volume loss (Karagulle

Kendi et al., 2008). These results confirm that the neurodegenerative process extends beyond the basal ganglia in PD (Tessa et al., 2008).

Olfactory impairment, which is common in PD and often predates clinical diagnosis, may be a useful biomarker for early PD. One study (Rolheiser et al., 2011) compared newly diagnosed PD patients with a matched control group using both olfactory testing and diffusion tensor imaging of the substantia nigra and anterior olfactory structures. Fourteen PD patients with stage 1-2 of Hoehn & Yahr were matched to a control group by age and sex. All subjects completed the University of Pennsylvania Smell Identification Test, as well as a series of MRI scans designed to examine diffusion characteristics of the olfactory tract and the substantia nigra. Olfactory testing revealed significant impairment in the patient group. Diffusion tensor imaging revealed significant group differences in both the substantia nigra and anterior olfactory region, with fractional anisotropy of the olfactory region clearly distinguishing the Parkinson's subjects from controls. This study has suggested that there may be value in combining behavioral (olfaction) and MRI testing to identify early Parkinson's disease (Rolheiser et al., 2011; Fulton & Barret, 2008).

Concluding DWI/DTI imaging especially bears several advantages. DWI/DTI imaging may detect diffusion abnormalities in the basal ganglia and infratentorial structures in patients with PD at an early stage of disease. Furthermore, DWI/DTI imaging sequences are widely available on whole body MR scanners and can be acquired within a few minutes.

3.5 Functional Magnetic Resonance Imaging

fMRI is based on the increase in blood flow to the local vasculature that accompanies neural activity in the brain. This results in a corresponding local reduction in deoxyhemoglobin because the increase in blood flow occurs without an increase of similar magnitude in oxygen extraction (Roy & Sherrington, 1890; Fox & Raichle, 1985). Since deoxyhemoglobin is paramagnetic, it alters the T2 weighted magnetic resonance image signal (Ogawa et al, 1990). Thus, deoxyhemoglobin is sometimes referred to as an endogenous contrast enhancing agent, and serves as the source of the signal for fMRI. Using an appropriate imaging sequence, human cortical functions can be observed without the use of exogenous contrast enhancing agents on a clinical strength (1.5 T) scanner (Bandettini et al., 1992, 1993; Kwong, et al, 1992; and Turner, et al, 1993; Schneider et al, 1993). Functional activity of the brain determined from the magnetic resonance signal has confirmed known anatomically distinct processing areas in the visual cortex (Belliveau, et al, 1991; Ogawa, et al, 1992; Schneider, et al, 1993), the motor cortex, and Broca's area of speech and language-related activities (Hinke et al., 1993; Kim et al., 1995). Further, a rapidly emerging body of literature documents corresponding findings between fMRI and conventional electrophysiological techniques to localize specific functions of the human brain (Atlas et al., 1996; Puce, et al, 1995; Burgess, 1995; Detre, et al, 1995; George, et al, 1995; Ives, et al, 1993). Consequently, the number of medical and research centers with fMRI capabilities and investigational programs continues to escalate.

The main advantages to fMRI as a technique to image brain activity related to a specific task or sensory process include:

- the signal does not require injections of radioactive isotopes
- the total scan time required can be very short
- the in-plane resolution of the functional image is generally about 1.5 x 1.5 mm although resolutions less than 1 mm are possible.

The function or dysfunction of the several cortical regions involved in many disease, like PD, can be investigated *in vivo* by means of functional imaging techniques such as fMRI.

4. Olfactory dysfunction as a early diagnostic marker for Parkinson's Disease

Olfactory dysfunction is a frequent non-motor symptom in PD and may be considered as an early clinical feature of the disease preceding motor symptoms by years (Ansari & Johnson, 1975). More than 96% of patients with PD present with olfactory dysfunction, compared with an established olfactory loss of at least 25% in the normal population over 52 years of age (Haehner et al., 2009). The majority of PD patients are functionally anosmic or severely hyposmic. Several studies have demonstrated an absence of correlation between olfactory loss and both duration of disease (Doty et al., 1988; Hawkes et al., 1997) and the clinical severity of PD (Ramaker et al., 2002), while other studies have found a correlation between the severity of PD and certain measures of olfactory function, such as latencies of olfactory event-related potentials (OERPs) (Hummel, 1999) and results from an odor discrimination task (Tissingh et al., 2001).

The cause of hyposmia in PD is not yet fully understood. It has been proposed that the develop of inclusion bodies, starting from the medulla oblongata and the anterior olfactory nucleus before the involvement of other central nervous structures, constitutes the reason of olfactory impairment before the motor symptoms appearance (Braak et al., 2003).

Moreover olfactory loss in PD is not a primary consequence of damage to the olfactory epithelium but rather result from distinct CNS abnormalities (Hummel et al., 2010). Studies based on biopsies from the olfactory epithelium did not reveal specific changes in the nasal mucosa of PD patients compared to patients who were hyposmic for other reasons (rhinitis, smoking or toxic agents). With regard to volumetrics of the olfactory bulb (OB) results indicated that there is little or no difference between PD patients with anosmia/hyposmia and healthy normosmic controls in terms of OB volume (Huisman et al., 2004; Hummel et al., 2010; Müller et al., 2005). Support for these results has come from a study that found an increase of (inhibitory) dopaminergic neurons in the OB in PD patients (Huisman et al., 2004). These findings have been interpreted within the context of a possible compensatory mechanism in response to the loss of dopaminergic neurons in the basal ganglia.

While cardinal motor symptoms in PD are closely related to a severe loss of dopaminergic cells in the nigro-striatal pathway, early clinical features such as olfactory impairment are more likely to be associated with extranigral pathology. Indeed atrophy in olfactory regions of the limbic and paralimbic cortex in early PD patients was found (Wattendorf et al., 2009). Moreover fMRI in PD patients indicated altered neuronal activity in the amygdaloid complex and hippocampal formation during olfactory stimulation (Takeda et al., 2010; Welge-Lüssen et al., 2009; Westermann et al., 2008). In addition, neuronal activity in components of cortico-striatal loops appears to be up-regulated indicating compensatory processes involving the dopaminergic system (Westermann et al., 2008).

Changes in olfactory function can also be observed using electrophysiological techniques such as recording OERPs (Kobal & Pattig, 1978). OERPs are the result of the sequential activation of numerous brain areas, starting with amygdala and regions of medial temporal lobe followed by the mid-orbito-frontal cortex and insular cortex, along with regions of the temporal lobe (Kettenmann et al., 1997). In PD patients OERPs are typically strongly delayed or even absent (Hawkes et al., 1999).

In a study combining fMRI and OERPs analysis in patients with PD, non-detectable OERPs patients exhibited reduced activity in the anterior cingulate gyrus and portions of the left striatum, while detectable ERP patients exhibited higher activation, especially in the amygdala, parahippocampal cortex, inferior frontal gyrus, insula, cingulate gyrus, striatum, and inferior temporal gyrus. The relationship between the expression of olfactory ERPs and cortical activation patterns seen during olfactory stimulation in fMRI in PD patients supports the idea that OERPs are a sensitive marker of neurodegeneration in olfactory regions, independent of the typically observed nigro-striatal degeneration in PD (Welge-Lüssen et al., 2009).

Olfactory dysfunction is more common in PD compared to atypical parkinsonian syndromes like PSP or MSA (Doty, 1991, 1993; Wenning et al., 1995). In a study including 37 patients with PD (Hoehn and Yahr I to IV) and 13 patients with MSA, CBD or PSP, 86 % of PD patients showed diminished sense of smell, or severe hyposmia, and 14 % were found to have moderate hyposmia, whereas 70 % of the patients with atypical parkinsonian syndromes exhibited moderate to mild hyposmia and 30 % normosmia (Muller et al., 2002). Olfactory testing may be an additive, helpful and inexpensive diagnostic instrument to support the discrimination of PD from healthy subjects and atypical parkinsonian syndromes, before onset of motor symptoms.

For the clinical assessment of olfactory function, several validated psychophysical tests exist. The best-validated olfactory tests include the University of Pennsylvania Smell Identification Test, the Connecticut Chemosensory Clinical Research Center Test and the Sniffin' Sticks Test (Cain et al., 1988; Doty et al., 1984; Hummel, 1997, 2007; Kobal et al., 2000). The Sniffin' Sticks is based on pen-like odor dispensing devices. It consists of three tests namely for odor threshold, discrimination and identification, the sum of which is defined as "TDI score". This score can give an indication of patient's olfactory performance (normosmia: $TDI \geq 30.5$, hyposmia: $TDI \leq 30.5$, functional anosmia: $TDI \leq 16.5$).

A useful help for the clinical diagnosis of olfactory deficits is represented by system using human electro-physiological methods such as OERPs that requests an adequate methods to produce a selective and controlled stimulation of the olfactory system.

Based on the principles of air-dilution olfactometry, Kobal and Platting introduced a chemosensory stimulation with stimuli having a rectangular shape with rapid onset, precisely controlled in terms of timing, duration, intensity, not simultaneously activating other sensory systems (Kobal & Platting, 1978). This can be achieved by the olfactometer which is a complex instrument for creation of well defined, reproducible smell or pain stimuli in the nose without tactile or thermal stimulation.

In conclusion the detection of early olfactory dysfunction, less frequent in other form of parkinsonism, can be used to assess risk for developing PD in asymptomatic subjects.

5. Conclusions

The defining features of PD are characterized by their insidious onset and inexorable but variable progression. Reliable and well validated early markers for PD to identify individuals "at risk" before motor and non motor symptoms, accurately diagnose individuals at the threshold of clinical PD, and monitor PD progression throughout its course would dramatically improve patient care and accelerate research into both PD cause and therapeutics. During the past two decades, much progress has been made in identifying and assessing PD markers, but as yet, no fully validated marker for PD is available.

Nonetheless, there is increasing evidence that POM evaluation and advanced in vivo brain imaging will provide critical clues to assist in the early diagnosis and medical management of PD patients.

These methods are broadly defined as characteristics that are objectively measured and evaluated as indicators of normal biological processes, pathogenic processes, or pharmacological responses to a therapeutic intervention.

The lack of success of recent disease-modifying therapeutic trials coupled with the huge expense of other methods, such as the nuclear medicine, has highlighted the need for such an ambitious approach to identify and validate early markers of PD progression for future clinical studies of disease-modifying drugs.

6. References

- Abe, K.; Terakawa, H.; Takanashi, M.; Watanabe, Y.; Tanaka, H. et al. Proton magnetic resonance spectroscopy of patients with parkinsonism. *Brain Research Bulletin*, Vol.52, No.6, (August 2000), pp. 589-595, ISSN 0361-9230
- Allen, P.S. In vivo nuclear-magnetic-resonance spectroscopy applied to medicine. *Canadian Association of Radiologists Journal*, Vol.41, No.1, (February 1990), pp. 39-44, ISSN 0008-2902
- Ansari, K.A. & Johnson, A. Olfactory function in patients with Parkinson's disease. *Journal of Chronic Diseases*, Vol.28, No.9, (October 1975), pp. 493-497, ISSN 0021-9681
- Atlas, S.W.; Howard, II R.S.; Maldjian, J.; Alsop, D.; Detre, J.A. et al. Functional magnetic resonance imaging of regional brain activity in patients with intracerebral gliomas: findings and implications for clinical management. *Neurosurgery*, Vol.38, No2, (February 1996), pp. 329-338, ISSN 0148-396X
- Avison, M.J.; Hetherington, H.P. & Shulman R.G. Application of NMR to studies of tissue metabolism. *Annual Review of Biophysics and Biophysical Chemistry*, Vol.15, (June 1986), pp. 377-402, ISSN 0883-9182
- Bandettini, P.A.; Jesmanowicz, A.; Wong, E.C. & Hyde, J.S. Processing strategies for time-course data sets in functional MRI of the human brain. *Magnetic Resonance in Medicine*, Vol.30, No2, (August 1993), pp. 161-173, ISSN 07403194
- Bares, M.; Bràzdil, M.; Kanovsky, P.; Jurak, P.; Daniel, P.; et al. The effect of apomorphine administration on smooth pursuit ocular movements in early Parkinsonian patients. *Parkinsonism & Related Disorders*, Vol. 9, No.3, (January 2003), pp. 139-144, ISSN 1353-8020
- Barker, G.J.; Tofts, P.S. & Gass, A. An interleaved sequence for accurate and reproducible clinical measurement of magnetization transfer ratio. *Magnetic Resonance Imaging*, Vol.14, No.4, (1996), pp. 403-411, ISSN 0730-725X
- Bonavita, S.; Di Salle, F. & Tedeschi, G. Proton MRS in neurological disorders. *European Journal of Radiology*, Vol.30, No.2, (May 1999), pp. 125-131, ISSN 0720-048X
- Bowen, B.C.; Block, R.E.; Sanchez-Ramos, J.; Pattany, P.M.; Lampman, D.A. et al. Proton MR Spectroscopy of the Brain in 14 Patients with Parkinson Disease. *American Journal of Neuroradiology*, Vol.16, No.1, (January 1995), pp. 61-68, ISSN 0195-6108
- Braak, H.; Del Tredici, K.; Rüb, U.; De Vos, R.A.I.; Jansen Steur, E.N.H. et al. Staging of brain pathology related to sporadic Parkinson's disease. *Neurobiology of Aging*, Vol.24, No.2, (April 2003), pp. 197-211, ISSN 0197-4580

- Brooks, D.J. Morphological and functional imaging studies on the diagnosis and progression of Parkinson's disease. *Journal of Neurology*, Vol. 247, No2, (April 2000), pp. 11-18, ISSN 0340-5354
- Cain, W.S.; Gent, J.F.; Goodspeed, R.B. & Leonard, G. Evaluation of olfactory dysfunction in the Connecticut Chemosensory Clinical Research Center (CCCRC). *Laryngoscope*, Vol.98, No.1, (January 1988), pp. 83-88, ISSN 1531-4995
- Clark, J.B. N-acetylaspartate: a marker for neuronal loss or mitochondrial dysfunction. *Developmental Neuroscience*, Vol.20, No.4-5, (July-October 1998), pp. 271-276, ISSN 0378-5866
- Clarke, C.E. & Lowry, M. Systematic review of proton magnetic resonance spectroscopy of the striatum in parkinsonian syndromes. *European Journal of Neurology*, Vol.8, No.6, (November 2001), pp. 573-577, ISSN 1351-5101
- Davie, C.A.; Wenning, G.K.; Barker, G.J.; Tofts, P.S.; Kendall, B.E. et al. Differentiation of multiple system atrophy from idiopathic Parkinson's disease using proton magnetic resonance spectroscopy. *Annals of Neurology*, Vol.37, No.2, (February 1995), pp. 204-210, ISSN 0364-5134
- Dexter, D.T.; Wells, F.R.; Lees, A.J.; Agid, F.; Agid, Y. et al. Increased nigral iron content and alterations in other metal ions occurring in brain in Parkinson's disease. *Journal of Neurochemistry*, Vol.52, No6, (June 1989), pp. 1830-6, ISSN 0022-3042
- Di Costanzo, A.; Trojsi, F.; Tosetti, M.; Schirmer, T.; Lechner, S.M. et al. Proton MR spectroscopy of the brain at 3T: an update. *European Radiology*, Vol.17, No.7, (July 2007), pp. 1651-1662, ISSN 0938-7994
- Doty, R.L.; Deems, D. & Steller, S. Olfactory dysfunction in Parkinson's disease: a general deficit unrelated to neurologic signs, disease stage, or disease duration. *Neurology*, Vol.38, No.8, (August 1988), pp. 1237-1244, ISSN 0028-3878
- Doty, R.L.; Golbe, L.I.; McKeown, D.A.; Stern, M.B.; Lehrach, C.M. et al. Olfactory testing differentiates between progressive supranuclear palsy and idiopathic Parkinson's disease. *Neurology*, Vol.43, No.5, (May 1993), pp. 962-965, ISSN 0028-3878
- Doty, R.L.; Perl, D.P.; Steele, J.C.; Chen, K.M.; Pierce, J.D. Jr. et al. Olfactory dysfunction in three neurodegenerative diseases. *Geriatrics*, Vol.46, No.1, (August 1991), pp. 47-51, ISSN 0016-867X
- Doty, R.L.; Shaman, P.; Kimmelman, C.P. & Dann, M.S. University of Pennsylvania Smell identification test: a rapid quantitative olfactory function test for the clinic. *Laryngoscope*, Vol.94, No.2, (February 1984), pp. 176-178, ISSN 1531-4995
- Duguid, JR.; De La, P.R. & DeGroot, J. Magnetic resonance imaging of the midbrain in Parkinson's disease. *Annals of Neurology*, Vol.20, No.6, (December 1986), pp. 744-747, ISSN 0364-5134
- Eckert, T.; Sailer, M.; Kaufmann, J.; Schrader, C.; Peschel, T. et al. Differentiation of idiopathic Parkinson's disease, multiple system atrophy, progressive supranuclear palsy, and healthy controls using magnetization transfer imaging. *Neuroimage*, Vol.21, No.1, (January 2004), pp. 229-235, ISSN 1053-8119
- Edelman, R.R.; Ahn, S.S.; Chien, D.; Li, W.; Goldmann, A. et al. Improved time-of-flight MR angiography of the brain with magnetization transfer contrast. *Radiology*, Vol.184, No.2, (August 1992), pp. 395-399, ISSN 0033-8419

- Federico, F.; Simone, I.L.; Lucivero, V.; Iliceto, G.; De Mari, M. et al. Proton magnetic resonance spectroscopy in Parkinson's disease and atypical parkinsonian disorders. *Movement Disorders*, Vol.12, No.6, (November 1997), pp. 903-909, ISSN 0885-3185
- Federico, F.; Simone, I.L.; Lucivero, V.; Mezzapesa, D.M.; De Mari, M. et al. Usefulness of proton magnetic resonance spectroscopy in differentiating parkinsonian syndromes. *Italian Journal of Neurological Sciences*, Vol.20, No.4, (August 1999), pp. 223-229, ISSN 0392-0461
- Firbank, M.J.; Harrison, R.M. & O'Brien, J.T. A comprehensive review of proton magnetic resonance spectroscopy studies in dementia and Parkinson's disease. *Dementia And Geriatric Cognitive Disorders*, Vol.14, No.2, (July 2002), pp. 64-76, ISSN 1420-8008
- Fox, P.T. & Raichle, M.E. Stimulus rate determines regional brain blood flow in striate cortex. *Annals of Neurology*, Vol.17, No3, (March 1985), pp.303-305, ISSN 0364-5134
- Fulton, HG. & Barrett, SP. A demonstration of intravenous nicotine self-administration in humans? *Neuropsychopharmacology*, Vol.33, No8, (Jule 2008), pp. 2042-2043, ISSN 0893-133X
- George, JS.; Aine, CJ.; Mosher, JC.; Schmidt, MD.; Ranken, DM. et al., Mapping function in the human brain with magneto encephalography, anatomical magnetic resonance imaging, and functional magnetic resonance imaging. *Journal of Clinical Neurophysiology*, Vol.12, No5, (September 1995), pp. 406-429 ISSN 1676-2649
- Gupta, A.; Dawson, V.L. & Dawson, T.M. What causes cell death in Parkinson's disease? *Annals of Neurology*, Vol.64, No6, (December 2008), pp. S3-S15, ISSN 0364-5134
- Haehner, A.; Boesveldt, S.; Berendse, H.W.; Mackay-Sim, A. Fleischmann, J. et al. Prevalence of smell loss in Parkinson's Disease - a multicenter study. *Parkinsonism & Related Disorders*, Vol.15, No.7, (August 2009), pp. 490-494, ISSN 1353-8020
- Hagmann, P.; Jonasson, L.; Maeder, P.; Thiran, J.P.; Wedeen, V.J. et al. Understanding diffusion MR imaging techniques: from scalar diffusion-weighted imaging to diffusion tensor imaging and beyond. *Radiographics*, Vol.26, Sp. Iss, (October 2006), pp. S205-U219, ISSN 0271-5333
- Hattingen, E.; Magerkurth, J.; Pilatus, U.; Morez, A.; Seifried, C. et al. Phosphorus and proton magnetic resonance spectroscopy demonstrates mitochondrial dysfunction in early and advanced Parkinson's disease. *Brain*, Vol.132, No.12, (December 2009), pp. 3285-3297, ISSN 0006-8950
- Hawkes, C.H.; Shephard, B.C. & Daniel, S.E. Olfactory dysfunction in Parkinson's disease. *Journal of Neurology Neurosurgery and Psychiatry*, Vol.62, No.5, (May 1997), pp. 436-446, ISSN 0022-3050
- Hawkes, C.H.; Shephardm, B.C. & Daniel, S.E. Is Parkinson's disease a primary olfactory disorder? *Qjm-An International Journal of Medicine*, Vol.92, No.8, (August 1999), pp. 473-480, ISSN 1460-2725
- Hinke, R.M.; Hu, X.; Stillman, A.E.; Kim, S.G.; Merkle, H. et al. Functional magnetic resonance imaging of Broca's area during internal speech. *NeuroReport*, Vol.4, No6, (June 1993) pp. 675-678 ISSN 0959-4965
- Hirsch, E.C. & Hunot S. Neuroinflammation in Parkinson's disease: a target for neuroprotection? *Lancet Neurology*, Vol.8, No.4, (April 2009), pp. 382-397, ISSN: 1474-4422
- Holshouser, B.A.; Komu, M.; Moller, H.E.; Zijlmans, J.; Kolem, H. et al. Localized proton NMR spectroscopy in the striatum of patients with idiopathic Parkinson's disease: a


- multicenter pilot study. *Magnetic Resonance in Medicine*, Vol.33, No.5, (May 1995), pp. 589-594, ISSN 0740-3194
- Horsfield, M.A. Magnetization transfer imaging in multiple sclerosis. *Journal of Neuroimaging*, Vol.15, No.4, (2005), pp. 58-67, ISSN 1051-2284
- Huisman, E.; Uylings, H.B. & Hoogland, P.V. A 100% increase of dopaminergic cells in the olfactory bulb may explain hyposmia in Parkinson's Disease. *Movement Disorders*, Vol.19, No.6, (June 2004), pp. 687-692, ISSN 0885-3185
- Hummel, T. (1999). Olfactory evoked potentials as a tool to measure progression of Parkinson's disease. In: *Focus medicine - New development in the drug therapy of Parkinson's Disease*, T. Chase & P. Bedard, (Eds.), 47-53, ISBN 0-632-05174-4, Blackwell Science, Oxford, UK
- Hummel, T.; Kobal, G.; Gudziol, H. & Mackay-Sim, A. Normative data for the "Sniffin' Sticks" including tests of odor identification, odor discrimination, and olfactory thresholds: an upgrade based on a group of more than 3.000 subjects. *European Archives of Oto-Rhino-Laryngology*, Vol.264, No.3, (March 2007), pp. 237-243, ISSN 0937-4477
- Hummel, T.; Sekinger, B.; Wolf, S.; Pauli, E. & Kobal G. "Sniffin' Sticks": olfactory performance assessed by the combined testing of odor identification, odor discrimination and olfactory threshold. *Chemical Senses*, Vol.22, No.1, (February 1997), pp. 39-52, ISSN 0379-864X
- Hummel, T.; Witt, M.; Reichmann, H.; Welge-Luessen, A & Haehner A. Immunohistochemical, volumetric, and functional neuroimaging studies in patients with idiopathic Parkinson's disease. *Journal of the Neurological Sciences*, Vol.298, No.1-2, (February 2010), pp. 119-122, ISSN 0022-510X
- Inglese, M.; Horsfield, M.A. & Filippi, M. Scan-rescan variation of measures derived from brain magnetization transfer ratio histograms obtained in healthy volunteers by use of a semi-interleaved magnetization transfer sequence. *American Journal of Neuroradiology*, Vol.22, No.4, (April 2001), pp. 681-684, ISSN 0195-6108
- Karagulle Kendi, A.T.; Lehericy, S.; Luciana, M.; Ugurbil, K. & Tuite, P. Altered diffusion in the frontal lobe in Parkinson disease. *AJNR American Journal of Neuroradiology*, Vol.38, No3, (March 2008), pp. 501-5, ISSN 1936-959X
- Kettenmann, B.; Hummel, C.; Stefan, H. & Kobal, G. Multiple olfactory activity in the human neocortex identified by magnetic source imaging. *Chemical Senses*, Vol.22, No.5, (October 1997), pp. 493-502, ISSN 0379-864X
- Kim, K.; Hirsch, J.; DeLaPaz, R.L.; Relkin, N. & Lee, K.M. Comparison of cortical areas activated by primary and secondary languages in human brain using functional magnetic resonance imaging (fMRI). *Abstracts: Society of Neuroscience*, Vol.21, No3, (1993), pp.1763, ISSN 0270-6474
- Kobal, G. & Plattig, K.H. Objective olfactometry: methodological annotations for recording olfactory EEG-responses from the awake human. *EEG EMG Z Elektroenzephalogr Elektromyogr Verwandte Geb.*, Vol.9, No.3, (September 1978), pp. 135-145, ISSN 0012-7590
- Kobal, G.; Klimek, L.; Wolfensberger, M.; Gudziol, H.; Temmel, A. et al. Multicenter investigation of 1.036 subjects using a standardized method for the assessment of olfactory function combining tests of odor identification, odor discrimination, and

- olfactory thresholds. *European Archives of Oto-Rhino-Laryngology*, Vol.257, No.4, (April 2000), pp. 205-211, ISSN 0937-4477
- Le Bihan, D. Looking into the functional architecture of the brain with diffusion MRI. *Nature Reviews Neuroscience*, Vol.4, No.6, (June 2003), pp. 469-480, ISSN 1471-0048
- Lekwuwa, G.U.; Barnes, G.R.; Collins, C.J.S.; Limousin, P. Progressive bradykinesia and hypokinesia of ocular pursuit in Parkinson's disease. *Journal of Neurology Neurosurgery and Psychiatry*, Vol.66, No.6, (June 1999), pp. 746-753, ISSN 0022-3050
- Lin, A.; Ross, B.D.; Harris, K. & Wong, W. Efficacy of proton magnetic resonance spectroscopy inneurological diagnosis and neurotherapeutic decision making. *NeuroRx: the journal of the American Society for Experimental NeuroTherapeutics*, Vol.2, No.2, (April 2005), pp. 197-214, ISSN 1545-5343
- Marino, S.; Sessa, E.; Di Lorenzo, G.; Lanzafame, P.; Scullica, G.; et al. Quantitative analysis of pursuit ocular movements in Parkinson's disease by using a video-based eye tracking system. *European Neurology*, Vol. 58, No. 4, (September 2007), pp. 193-7, ISSN 0014-3022
- Marino, S.; Lanzafame, P.; Sessa, E.; Bramanti, A.; Bramanti, P. The effect of L-Dopa administration on pursuit ocular movements in suspected Parkinson's disease. *Neurological Sciences*, Vol. 31, No. 3 (June 2010), pp. 381-385, ISSN 0022-510X
- Muller, A.; Reichmann, H.; Livermore, A. & Hummel T. Olfactory function in idiopathic Parkinson's disease (IPD): results from cross-sectional studies in IPD patients and long-term follow-up of de-novo IPD patients. *Journal of Neural Transmission*, Vol.109, No.5-6, (May 2002), pp. 805-811, ISSN 0300-9564
- Ogawa, S.; Lee, T.M.; Nayak, A. S.; & Glynn, P. Oxygenation-sensitive contrast in magnetic resonance image of rodent brain at high magnetic fields. *Magnetic Resonance in Medicine*, Vol.14, No1, (April 1990) pp.68-78, ISSN 07403194
- Pike, G.B.; Hu, B.S.; Glover, G.H. & Enzmann, D.R. Magnetization transfer time-of-flight magnetic resonance angiography. *Magnetic Resonance in Medicine*, Vol.25, No.2, (June 1992), pp. 372-379, ISSN 0740-3194
- Ramaker, C.; Marinus, J.; Stiggelbout, A.M. & Van Hilten, B.J. Systematic evaluation of rating scales for impairment and disability in Parkinson's disease. *Movement Disorders*, Vol.17, No.5, (September 2002), pp. 867-876, ISSN 0885-3185
- Rolheiser, T.M.; Fulton, H.G.; Good, K.P.; Fisk, J.D.; McKelvey, J.R. et al. Diffusion tensor imaging and olfactory identification testing in early-stage Parkinson's disease. *Journal of Neurology*, (February 2011), ISSN 0340-5354
- Ross, B. & Bluml, S. Magnetic resonance spectroscopy of the human brain. *The Anatomical Record*, Vol.265, No.2, (April 2001), pp. 54-84, ISSN 0003-276X
- Roy, C. & Sherrington, C. On the regulation of the blood-supply of the brain. *The Journal of Physiology*, Vol.11, No1-2, (January 1890), pp.85-108, ISSN 1469-7793
- Rutledge, J.N.; Hilal, S.K.; Silver, A.J.; Defendini, R. & Fahn S. Study of movement disorders and brain iron by MR. *AJR American Journal of Roentgenology*, Vol.149, No2, (August 1987), pp.365-379, ISSN 0361-803X
- Savoirdo, M.; Girotti, F.; Strada, L. & Ciceri, E. Magnetic resonance imaging in progressive supranuclear palsy and other parkinsonian disorders. *Journal of Neural Transmission*, Vol.42, (1994), pp. 93-110, ISSN 0303-6995

- Schneider, W.; Noll, D.C. & Cohen, J. D. Functional topographic mapping of the cortical ribbon in human vision with conventional MRI scanners. *Nature*, Vol.365, No.6442, (September 1993), pp. 150-152, ISSN 0028-0836
- Schocke, M.F.; Seppi, K.; Esterhammer, R.; Kremser, C.; Mair, K.J. et al. Trace of diffusion tensor differentiates the Parkinson variant of multiple system atrophy and Parkinson's disease. *Neuroimage*, Vol.19, Suppl.9, (2004), pp. S53-S53, ISSN 08853185
- Sofic, E.; Riederer, P.; Heinsen, H.; Beckmann, H.; Reynolds, G.P. et al. Increased iron (III) and total iron content in post mortem substantia nigra of parkinsonian brain. *Journal of Neural Transmission*, Vol.74, No.3, (August 1988), pp.199-205, ISSN 0300-9564
- Srinivasan, R.; Vigneron, D.; Sailasuta, N.; Hurd, R. & Nelson, S. A comparative study of myo-inositol quantification using LCmodel at 1.5 T and 3.0 T with 3D 1H proton spectroscopic imaging of the human brain. *Magnetic Resonance Imaging*, Vol.22, No.4, (May 2004), pp. 523-528, ISSN 0730-725X
- Takeda, A.; Saito, N.; Baba, T.; Kikuchi, A.; Sugeno, N. et al. Functional imaging studies of hyposmia in Parkinson's disease. *Journal of the Neurological Sciences*, Vol.298, No.1-2, (February 2010), pp. 36-39, ISSN 0022-510X
- Tambasco, N.; Pelliccioli, G.P.; Chiarini, P.; Montanari, G.E.; Leone, F. et al. Magnetization Transfer changes of gray and white matter in Parkinson 's disease. *Neuroradiology*, Vol.45, No.4, (April 2003), pp. 224-230, ISSN 0028-3940
- Tedeschi, G.; Litvan, I.; Bonavita, S.; Bertolino, A.; Lundbom, N. et al. Proton magnetic resonance spectroscopic imaging in progressive supranuclear palsy, Parkinson's disease and corticobasal degeneration. *Brain*, Vol.120, No.9, (September 1997), pp. 1541-1552, ISSN 0006-8950
- Tessa, C.; Giannelli, M.; Della Nave, R.; Lucetti, C.; Berti, C.A. et al. A whole-brain analysis in de novo Parkinson disease. *AJNR American Journal of Neuroradiology*, Vol.29, No.4, (April 2008), pp. 674-680, ISSN 01956108
- Tissingh, G.; Berendse, H.W.; Bergmans, P.; DeWaard, R.; Drukarch, B. et al. Loss of olfaction in de novo and treated Parkinson's disease: possible implications for early diagnosis. *Movement Disorders*, Vol.16, No.1, (January 2001), pp. 41-46, ISSN 0885-3185
- Watanabe, H.; Fukatsu, H.; Katsuno, M.; Sugiura, M.; Hamada, K. et al. Multiple regional 1H-MR spectroscopy in multiple system atrophy: NAA/Cr reduction in pontine base as a valuable diagnostic marker. *Journal of Neurology, Neurosurgery, and Psychiatry*, Vol.75, No.1, (January 2004), pp. 103-109, ISSN 0022-3050
- Wattendorf, E.; Welge-Lüssen, A.; Fiedler K.; Bilecen, D.; Wolfensberger, M. et al. Olfactory Impairment Predicts Brain Atrophy in Parkinson's Disease. *The Journal of Neuroscience*, Vol.29, No.49, (December 2009), pp. 15410-15413, ISSN 0270-6474
- Welge-Lüssen, A.; Wattendorf, E.; Schwerdtfeger, U.; Fuhr, P.; Bilecen, D. et al. Olfactory induced brain activity in Parkinson's disease relates to the expression of event-related potentials – an fMRI study. *Neuroscience*, Vol.162, No.2, (August 2009), pp. 537-543, ISSN 0306-4522
- Wenning, G.K.; Shephard, B.; Hawkes, C.; Petrukevitch, A.; Lees, A. et al. Olfactory function in atypical parkinsonian syndromes. *Acta Neurologica Scandinavica*, Vol.91, No.4, (April 1995), pp. 247-250, ISSN 0001-6314

- Westermann, B.; Wattendorf, E.; Schwerdtfeger, U.; Husner, A.; Fuhr, P. et al. Functional imaging of the cerebral olfactory system in patients with Parkinson's disease. *Journal of Neurology, Neurosurgery, and Psychiatry*, Vol.79, No.1, (January 2008), pp. 19-24, ISSN 0022-3050
- Wilms, H.; Zecca, L.; Rosenstiel, P.; Sievers, J.; Deuschl, G. et al. Inflammation in Parkinson's diseases and other neurodegenerative diseases: cause and therapeutic implications. *Current Pharmaceutical Design*, Vol.13, No18, (June 2007), pp. 1925-1928, ISSN: 1381-6128
- Wolff, S.D. & Balaban, R.S. Magnetization transfer contrast (MTC) and tissue water proton relaxation in vivo. *Magnetic Resonance in Medicine*, Vol.10, No.1, (April 1989), pp. 135-144, ISSN 0740-3194
- Wolff, S.D.; Eng, J. & Balaban, R.S. Magnetization transfer contrast: method for improving contrast in gradient-recalled-echo images. *Radiology*, Vol.179, No.1, (April 1991), pp. 133-137, ISSN 0033-8419
- Yonca, A.; Pervin, I.; Ali, D.; Sezer, K. & Naighan, I. Magnetization Transfer Ratio in Early Period of Parkinson Disease. *Academic Radiology*, Vol.14, No.2, (February 2007), pp. 189-192, ISSN 1076-6332
- Youdim, M.B.H.; Ben-Schachar, D.; Yehuda, S. & Riederer, P. The role of iron in the basal ganglia. *Advances in Neurology*, Vol.53, (1990) pp.155-162, ISSN: 0091-3952

IntechOpen



Diagnostics and Rehabilitation of Parkinson's Disease

Edited by Dr. Juliana Dushanova

ISBN 978-953-307-791-8

Hard cover, 528 pages

Publisher InTech

Published online 07, December, 2011

Published in print edition December, 2011

Diagnostics and Rehabilitation of Parkinson's Disease presents the most current information pertaining to news-making topics relating to this disease, including etiology, early biomarkers for the diagnostics, novel methods to evaluate symptoms, research, multidisciplinary rehabilitation, new applications of brain imaging and invasive methods to the study of Parkinson's disease. Researchers have only recently begun to focus on the non-motor symptoms of Parkinson's disease, which are poorly recognized and inadequately treated by clinicians. The non-motor symptoms of Parkinson's disease have a significant impact on patient quality of life and mortality and include cognitive impairments, autonomic, gastrointestinal, and sensory symptoms. In-depth discussion of the use of imaging tools to study disease mechanisms is also provided, with emphasis on the abnormal network organization in parkinsonism. Deep brain stimulation management is a paradigm-shifting therapy for Parkinson's disease, essential tremor, and dystonia. In the recent years, new approaches of early diagnostics, training programmes and treatments have vastly improved the lives of people with Parkinson's disease, substantially reducing symptoms and significantly delaying disability. Written by leading scientists on movement and neurological disorders, this comprehensive book should appeal to a multidisciplinary audience and help people cope with medical, emotional, and practical challenges.

How to reference

In order to correctly reference this scholarly work, feel free to copy and paste the following:

Silvia Marino, Pietro Lanzafame, Silvia Guerrero, Rosella Ciurleo and Placido Bramanti (2011). Early Marker for the Diagnosis of Parkinson's Disease, *Diagnostics and Rehabilitation of Parkinson's Disease*, Dr. Juliana Dushanova (Ed.), ISBN: 978-953-307-791-8, InTech, Available from:
<http://www.intechopen.com/books/diagnostics-and-rehabilitation-of-parkinson-s-disease/early-marker-for-the-diagnosis-of-parkinson-s-disease>

INTECH
open science | open minds

InTech Europe

University Campus STeP Ri
Slavka Krautzeka 83/A
51000 Rijeka, Croatia
Phone: +385 (51) 770 447
Fax: +385 (51) 686 166

InTech China

Unit 405, Office Block, Hotel Equatorial Shanghai
No.65, Yan An Road (West), Shanghai, 200040, China
中国上海市延安西路65号上海国际贵都大饭店办公楼405单元
Phone: +86-21-62489820
Fax: +86-21-62489821

www.intechopen.com

www.intechopen.com

IntechOpen

IntechOpen

© 2011 The Author(s). Licensee IntechOpen. This is an open access article distributed under the terms of the [Creative Commons Attribution 3.0 License](#), which permits unrestricted use, distribution, and reproduction in any medium, provided the original work is properly cited.

IntechOpen

IntechOpen