

We are IntechOpen, the world's leading publisher of Open Access books Built by scientists, for scientists

5,000

Open access books available

125,000

International authors and editors

140M

Downloads

Our authors are among the

154

Countries delivered to

TOP 1%

most cited scientists

12.2%

Contributors from top 500 universities



WEB OF SCIENCE™

Selection of our books indexed in the Book Citation Index
in Web of Science™ Core Collection (BKCI)

Interested in publishing with us?
Contact book.department@intechopen.com

Numbers displayed above are based on latest data collected.
For more information visit www.intechopen.com



Percutaneous Endoscopic Gastrostomy in Pediatric Patients

Omar I. Saadah

*Department of Pediatrics, Faculty of medicine, King Abdulaziz University
Saudi Arabia*

1. Introduction

Adequate nutrition is important in the management of children with chronic illnesses. Patients who are unwilling or unable to eat will starve. Starvation depletes tissue stores, and ultimately leads to impaired organ function and tissue structure. Appropriate caloric intake enables growth, promotes tissue repair, and improve immune function.

Access to the intestinal tract may be via a nasal tube or by the percutaneous route, with delivery to the stomach or jejunum. Nasogastric tubes are employed for short-term feeding, usually up to four weeks. In children requiring long term tube feeding, nasogastric feeding may be uncomfortable, disfiguring and often traumatic. Percutaneous access is usually by either endoscopic or radiological techniques. Percutaneous gastrostomy is basically a sutureless approximation of the stomach to the abdominal wall. The percutaneous endoscopic gastrostomy (PEG) becomes the most popular technique nowadays.

The first PEG was performed in the pediatric operating room of University Hospitals of Cleveland on June 12, 1979 on a four-and-half-month-old child with inadequate oral intake. The procedure was performed under sedation and local anesthesia. The child did remarkably well. However, because the initial tube used was a 12F catheter with small mushroom head, external migration ensued after 3 weeks. The catheter was changed under direct visualization, using a small laparotomy (Gauderer, 2002). Since then the procedure has been adopted worldwide for both children and adults.

Because the procedure is considered minimally invasive, rapid, and associated with low risk of complications, and short hospital stay, it has become the preferred method for delivering nutritional support in vulnerable pediatric patients. The benefits not only include successful nutritional rehabilitation, but also accelerated growth (Craig et al., 2006, Sullivan et al., 2005) enhanced carer satisfaction (Avitsland et al., 2006) and quality of life (Sullivan et al., 2004).

2. Indications

The main clinical indications for PEG placement in children are as follows (Table 1):

2.1 Inability to swallow

Children with neurological impairment comprise the majority of this category. They often have difficulty eating and drinking. These difficulties are due to problems with oro-

pharyngeal control (Gisel et al., 1998, Reilly and Skuse, 1992) and esophageal motility (Ross et al., 1988, Heikenen et al., 1999, Fonkalsrud et al., 1995), related gastro-esophageal reflux (Ross et al., 1988), and the high risk of aspiration of food and fluids into the lungs (Rogers et al., 1994, Morton et al., 1999, Taylor et al., 1994). Among the consequences for these feeding difficulties are undernutrition (Stallings et al., 1993, Sullivan et al., 2000), esophagitis (Sondheimer and Morris, 1979), recurrent chest infections (Morton et al., 1999), and progressive lung disease (Taylor et al., 1994). Much of this feeding difficulty can be overcome by giving nourishment through a gastrostomy. Unfortunately, the placement of a gastrostomy in a child with neurological impairment does carry some risk, and parents are frequently reluctant to have a gastrostomy placed (Sullivan, 1992). Families with affected children need better information when making the difficult decision about whether to accept or request a gastrostomy for their child. Most children undergoing PEG tube feeding showed improved weight gain after PEG tube feeding (Rempel et al., 1988, Shapiro et al., 1986, Sanders et al., 1990, Brant et al., 1999). Changes in rate of length growth appeared to be less predictable and occurred only in a minority of children. The improvement of physical growth coupled with improvement in the general health and the family quality of life (Stevenson, 2005). Direct aspiration of orally ingested material and saliva may be a reason for recommending PEG tube feeding (Brant et al., 1999, Sulaeman et al., 1998). But gastro-esophageal reflux is also thought to contribute to aspiration indirectly (Morton et al., 1999). Both gastro-esophageal reflux and aspiration can occur without symptoms (Rogers et al., 1994) and the investigations that are often used to diagnose gastro-esophageal reflux appear to be unreliable. Therefore, the decision of anti-reflux procedure together with gastrostomy may not be easy unless a child's symptoms are severe despite appropriate medications (Puntis et al., 2000, Sullivan, 1999).

| Clinical indications | |
|-----------------------------|--|
| 1. | Inability to swallow, most commonly neurologically impaired children |
| 2. | Chronic illnesses with inadequate caloric intake |
| | Chronic renal failure |
| | Cystic fibrosis |
| | Congenital heart disease |
| | Childhood cancer |
| | Human immune deficiency virus infection (HIV) |
| | Crohn's disease |
| 3. | Unpalatable medication |
| 4. | Permanent enteral access and gastric decompression |

Table 1. Indications for PEG insertion

2.2 Chronic illnesses with inadequate intake

Children with chronic illnesses are usually anorexic, have increased metabolic demands and usually cachectic. Children with the following conditions fall under this category:

2.2.1 Chronic renal disease

Chronic renal disease is characterized by a predisposition to anorexia and vomiting. Poor appetite may be due to abnormal taste sensation (Bellisle et al., 1995), the requirement for multiple medications, the preference for water in the polyuric child, and elevated level of circulating cytokines, which act through the hypothalamus to affect appetite and satiety (Mak et al., 2006). Vomiting may result from gastro-esophageal reflux and delayed gastric emptying in association with increased polypeptide hormones (Ravelli et al., 1992).

When the caloric and protein intake become insufficient to maintain growth despite dietary manipulation and medication (Rees and Shaw, 2007), enteral feeding is preferred through a gastrostomy. Enteral feeding can allow catch-up growth even in infants and young children with severe chronic renal failure (Kari et al., 2000). It is better to place the PEG tube prior to commencement of peritoneal dialysis in order to decrease the risk of fungal peritonitis (von Schnakenburg et al., 2006).

Children on dialysis have even more problems that affect their nutritional intake. Such children are likely to be on fluid restriction, the presence of full abdomen due to indwelling dialysate in patients on peritoneal dialysis may affect their appetite, and there may be considerable loss of protein in the dialysate.

Children with chronic renal failure, post renal transplantation tends to improve their appetite, and they succeed in the transition to oral feeding, therefore it becomes possible to remove the PEG tube (Ledermann, 2005, Pugh and Watson, 2006).

2.2.2 Cystic fibrosis

Children with cystic fibrosis (CF) commonly fail to thrive due to increased resting energy expenditure (Buchdahl et al., 1988), associated anorexia (Shepherd et al., 1980), increased energy requirements associated with chronic respiratory infection (Lapey et al., 1974, Kraemer et al., 1978), maldigestion and malabsorption (Lapey et al., 1974).

Nutritional repletion and intervention involving prescription of energy rich food and fluids, optimization of pancreatic enzyme replacement therapy, oral supplements may be required (Anthony et al., 1999). However, in a proportion of patients, particularly those with more advanced pulmonary disease, these measures alone are insufficient to maintain body weight (Durie and Pencharz, 1992).

Few studies have assessed the efficacy of gastrostomy feeding in malnourished children with CF (Efrati et al., 2006, Truby et al., 2009, Oliver et al., 2004, Van Biervliet et al., 2004). It has been suggested that the early restoration of nutritional status may result in improved weight gain, improved response to treatment for respiratory exacerbations, amelioration of the progressive decline in lung function, extended survival, and perhaps improved quality of life.

2.2.3 Congenital heart disease

Children with heart disease often have a normal birth weight but show poor weight gain and cannot maintain their growth after birth. The cause of this thought to be multifactorial and may include factors such as inadequate caloric intake, increased oxygen consumption, hypermetabolism, reduced absorption, and feeding intolerance (Mitchell et al., 1995, Leitch, 2000). These factors reflect the need for increased energy intake, and thus

the dietary intervention is often necessary to improve the nutritional status of these children.

Delivering enteral nutritional support through PEG for 15 child with congenital cardiac problems was reported to be safe with rare minor complications and no major complications, and effective in terms of improving weight gain at 4 weeks and at 6 months after PEG tube insertion (Hofner et al., 2000). The rate of gastrostomy complications was more when percutaneous radiological technique was used in 58 children with cardiac disease. Major complications included intestinal perforation (3.4%) and aspiration pneumonia (12.1%). Significant weight gain was observed despite complications (Sy et al., 2008).

2.2.4 Childhood cancer

Almost half of children with cancer experience malnutrition due to numerous tumor- and treatment-related factors (Smith et al., 1991, Sala et al., 2004). It is recognized that a diminished nutritional status may be a contributing factor for decreased immune function, delayed wound healing, and disturbed drug metabolism influencing prognosis (Bosaeus et al., 2001, Tisdale, 1997). Children with cancer are particularly vulnerable to malnutrition, because they exhibit elevated nutritional needs due to the disease and its treatment. At the same time, children have increased requirements of nutrients to attain appropriate growth and neurodevelopment (Han-Markey, 2000). It has been demonstrated that adequate nutrition is an important determinant for several clinical outcome measures such as treatment response, quality of life, and cost of care (van Eys, 1979, Rickard et al., 1986). Various types of high energy protein formulas and liquid supplements are offered to increase energy density in pediatric patients, but with less success and poor tolerance because of taste and smell perception. Children with painful severe mucositis may have problem tolerating oral feeding. A PEG is successfully used method with high acceptance by oncologists, children, and parents demonstrating improvements in weight gain and reduced family frustration due to eating problems (Skolin et al., 2002, Pedersen et al., 1999). The placement of a PEG is indicated when oral ingestion is not sufficient to cover the daily energy needs. It is rarely associated with more than minor complications. The most common complication was superficial wound infection occurred during neutropenic episodes (Skolin et al., 2002, Pedersen et al., 1999).

2.2.5 Human immunodeficiency virus (HIV) infection

Malnutrition, one of the most common and obvious signs of pediatric human immunodeficiency virus (HIV) disease, may influence the infected child's already compromised immune response. In HIV-infected children, reduced growth and lean body mass appears early (Miller et al., 1993, Halsey et al., 1990). Gastrostomy tube feedings have become a major means of nutrition in children with HIV infection when other oral methods fail (Henderson et al., 1994). HIV-infected children with higher CD4 counts and lower weight-for-height z scores are likely to respond favorably to gastrostomy tube feedings and had a 2.8-fold reduction in the risk of dying for every positive unit change in weight z score (Miller et al., 1995). The HIV-infected children who received gastrostomy tube feeding had more complications associated with the tube than has been reported in the non-HIV pediatric literature (Marin et al., 1994). The newer combination antiretroviral therapies used

to treat HIV-infected children have result in dramatic delays in HIV progression, with reduction in the mortality and morbidity. However adherence to highly effective antiretroviral therapy in children may be problematic (Matsui, 1997). Reasons for non compliance include refusal, drug tolerability, and adverse reactions. PEG was suggested as a mean to administer medications to overcome such problems and improve adherence (Temple et al., 2001, Shingadia et al., 2000). PEG also significantly reduced parent reported times for medication administration and, therefore, may have the potential to improve the quality of life of HIV-infected children and their families (Shingadia et al., 2000).

2.2.6 Crohn's disease

Malnutrition and growth failure are common at presentation in children with Crohn's disease (Kirschner et al., 1978) . Nutritional rehabilitation is often an important part of the management of children with Crohn's disease, but hampered by anorexia and the unpalatability of elemental formulas commonly used in children with Crohn's disease. An elemental formula has been shown to be as effective as steroids in reducing the remission of active disease while avoiding the negative effects on growth (Sanderson et al., 1987). It has been suggested that the more palatable polymeric formulas can be used for treatment of active Crohn's disease rather than the unpalatable elemental formulas. Large amounts are required to be consumed daily with no solid food ingestion in order to achieve such therapeutic effect, and this may remain difficult to take by mouth. Nasogastric tube has been used for this reason (Belli et al., 1988), but has the advantage of being uncomfortable, disfiguring, and embarrassing for the child or adolescent if the tube left in place during the day time. A PEG can overcome this problem as it is hidden under clothing and is not visible. The use of PEG in children with Crohn's disease to deliver enteral nutrition has been reported to be safe and effective (Israel and Hassall, 1995, Pashankar and Israel, 1997, Cosgrove and Jenkins, 1997). Most of the complications of gastrostomy were minor and easily treatable. Closure of the gastrostomy tract after removal was almost complete. Only one study reported no closure of the gastrocutaneous fistula after PEG removal in one patient requiring surgical closure (Israel and Hassall, 1995). PEG remains a good and safe option if nasogastric tube feeding is not possible.

2.3 Unpalatable medications

Occasionally, PEG can be used in children with long-standing renal or cardiac failure who are dependent on large quantities of drugs for survival but resist medication provided orally (Gauderer, 2002).

2.4 Permanent enteral feeding

Patients with limited intestinal function, such as short bowel syndrome (Buchman, 2007) and intestinal pseudo-obstruction (Michaud et al., 2001) may benefit from PEG. PEG tube can also be used for gastric decompression in patients with intestinal pseudo-obstruction.

3. Contraindications

The contraindications for PEG insertion are related to conditions that cause pharyngeal or esophageal obstruction, interfere with gastrostomy site identification, or have been identified as being more likely to produce complications (Table 2).

| Contraindications |
|---|
| Patients who are unfit for endoscopy |
| Pharyngeal / esophageal obstruction |
| Active coagulopathy |
| Portal hypertension with gastric varices |
| Severe ascites |
| Peritoneal dialysis |
| Epidermolysis bullosa |
| Significant kypho-scoliosis when access to the stomach may be compromised |
| Failure of translumination through abdominal wall or clear point of indentation |

Table 2. Contraindications for PEG insertion

4. PEG placement

4.1 Technique

The 'pull' technique described by Gauderer and Stellato is recommended and is probably the technique most widely employed (**Fig.1**). After preparation of the abdomen, administration of prophylactic antibiotic and preparing the appropriate PEG equipment, under general anaesthesia, a flexible gastroscope appropriate to the size and weight of the child is passed into the stomach, which is gently insufflated. The abdominal wall is transilluminated by the endoscope. The assistant's finger then indents the anterior abdominal wall, and this indentation must be seen clearly through the endoscope to confirm close apposition of the stomach to the ventral abdominal wall. A small skin incision is made at the intended gastrostomy site. The percutaneous needle and trocar is passed directly into the stomach under endoscopic vision. The guidewire is introduced through the needle and grasped by the endoscopist's snare. The scope is gently withdrawn, bringing the guidewire with it. An appropriately sized PEG tube is looped to the thread and lubricated along its whole length to enable smooth passage through the throat and oesophagus. The thread is gently pulled back from the abdominal insertion site and the PEG placed in position. The outer flange of the tube is positioned loosely against the anterior abdominal wall. The opposition of the inner flange with the gastric wall can be checked by repeat endoscopy.

4.2 Post-operative care

Postoperatively, the child will be closely monitored. The PEG tube should not be used for 24 hours. Feeding usually start with small amount of oral rehydration solution and then gradually increased to the desired volume. It is generally best to use diluted formulas (quarter-strength or half-strength) and then advance the diet first in volume and then in

concentration over 3-4 days. Inability to tolerate increased volume is evident by abdominal distension, vomiting, or increased gastric residuals. Inability to tolerate increased osmolarity is evidenced by diarrhea. Once the child is able to tolerate formula sufficiently in volume and concentration, intravenous fluids can be discontinued. Initially, bolus feeding can be delivered slowly using enteral feeding pump several times a day. Gastric residuals should be checked before application of every bolus of enteral feeding. Careful assessment of the gastric residuals may help in improving feeding tolerance and minimising the risk of pulmonary aspiration. Children who are taking medications for seizures will have their medications converted to an intravenous form until they are able to tolerate gastric route of administration.

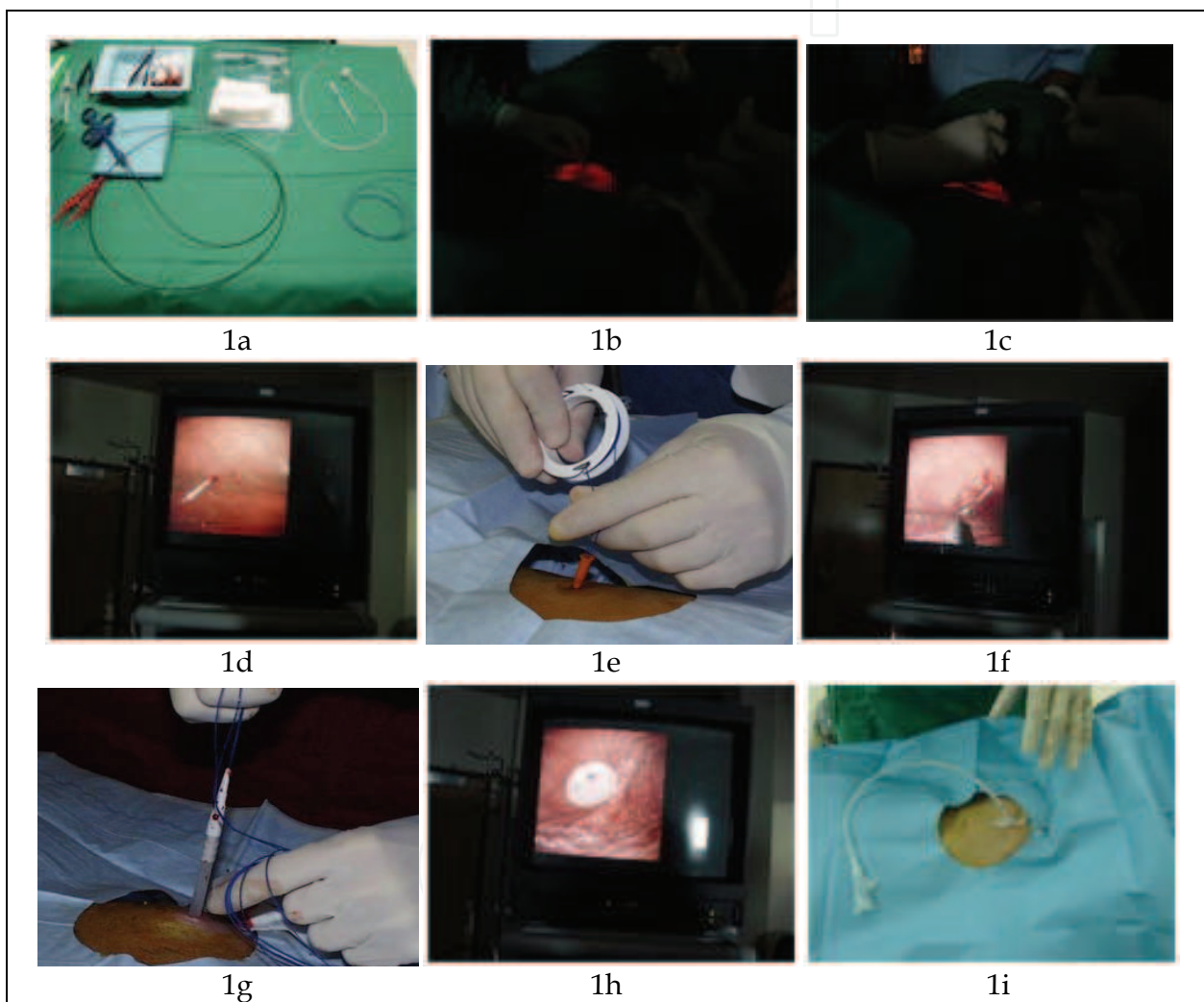


Fig. 1. The technique of PEG insertion. 1a. The main PEG equipment including, a PEG tube, a guidewire, a needle with a trocar and a snare. 1b. Abdominal wall transillumination by the endoscope with testing for indentation. 1c. Making a small skin incision at the intended gastrostomy site. 1d. Passing the needle and trocar directly to the stomach under endoscopic vision. 1e. Passing the guidewire through the needle. 1f. Grasping the guidewire by the snare to bring through the mouth. 1g. Pulling the guidewire and the anchored tube back from the abdominal insertion site. 1h. Checking the opposition of the inner flange with the gastric wall. 1i. PEG tube after insertion

5. Feeding through PEG tube

In Infants less than 12 months of age, an infant formula should be used. In patients with high caloric needs or with poor tolerance to increased formula volume, the formula may be concentrated and/or modular nutrients, such as glucose polymer or lipid, may be added. Infants with Cow's milk protein allergy, gastrointestinal maldigestion or absorption, and short bowel syndrome may benefit from amino acid-based or casein-based formulas.

Older children may be offered any of the following options depending on the underlying disease and the socio-economic status:

5.1 Polymeric feeds

Polymeric feeds are the most commonly used enteral feeds. Most children will tolerate a polymeric formula. They contain whole protein as a nitrogen source and energy of 1 kcal/ml. They are lactose and gluten free. Moreover they contain enough vitamins, trace elements and essential fatty acids to prevent deficiencies. Adult formulas should be avoided because the caloric-to-nutrient ratio is inadequate for children. Their use may result in calcium, phosphorus and vitamin deficiency, especially in patients with low-caloric needs.

5.2 Elemental feeds

Elemental feeds contain either amino acid or hydrolyzed protein. They are relatively expensive with unpalatable taste. It should be used only in situations where there is profound impairment in the gastrointestinal digestive and absorptive functions.

5.3 Blended food

This is used in many developing countries primarily because it is cheaper than commercially prepared feeds. It is viscous and chunks of food may block the feeding tube and increase the risk of complications. Feeding contamination is a further risk that may predispose to fungal growth in the lumen of the tube (**Fig. 2**).

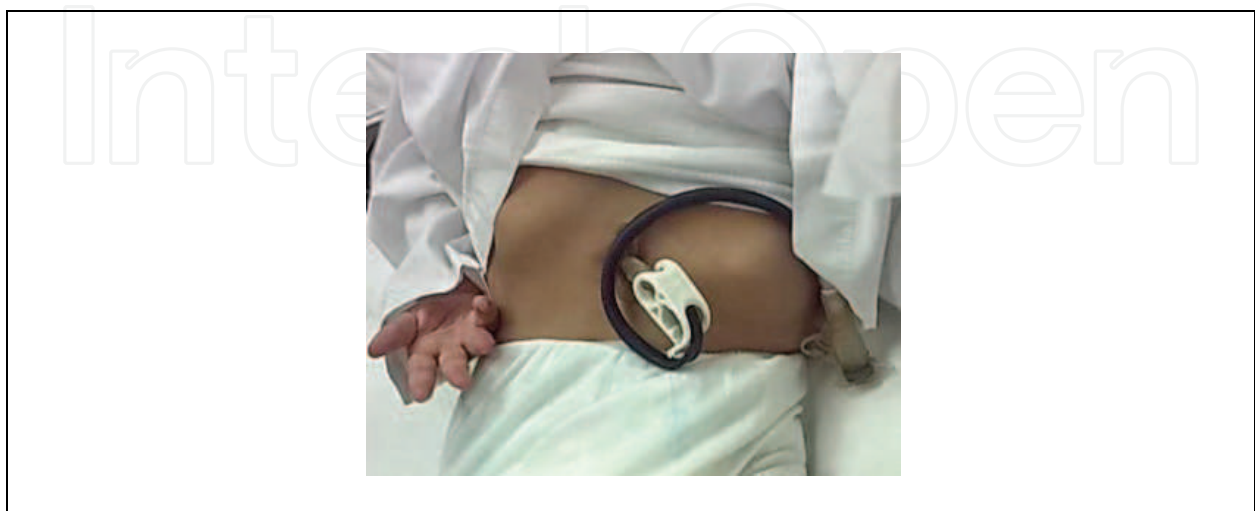

Fig. 2. Fungal contamination of the PEG tube

6. Care of the PEG tube

The care of the child with the PEG differs from that of adults, because of the child's smaller yet growing body and because nutritional needs change in time. Moreover, children, especially if chronically underfed, have very sensitive skin that must be protected effectively (Hagelgans and Janusz, 1994). Two main problems are the accurate selection of a properly sized device and then frequent checks and replacement with a more suitable size if necessary. The device should grow with the child. It must be as small as possible; both to minimize annoyance to the child, but it also must prevent leakage of gastric content or pressure necrosis and allow feeding to pass through easily.

It is important to secure the external flange of the tube nearly 3 mm above skin level (Ricciardi and Brown, 1994) to prevent leakage of the gastric content and to allow freedom of movement, which is very important for children to avoid traumatizing the gastric mucosa or pulling the bumper into the tract. It also allows air circulation to the skin around and underneath the disc to avoid pressure necrosis.

Skin care includes careful daily control of the position of the external flange with rotation and careful cleaning of the skin near the gastrostomy. It is important to protect the skin with zinc oxide cream or with absorbent powder or paste if there is any leakage (Hagelgans and Janusz, 1994).

Tube obstruction can easily occur. It is necessary to flush with 10 to 15 ml warm water before and after any introduction. You may need to flush only after feeding in very small babies. Food must be fluids such as liquid enteral formula. Medicine must be well dissolved before administration through the tube. If the tube is blocked, it should be flushed with a solution of water and half a capsule of crushed and dissolved pancreatic enzymes.

Bolus feeding must take at least 20 minutes and can be administered by a gravity flow system, by pump, or by syringe. If the child has fever or when the weather is warm, it is necessary to administer additional water, especially if the child is exclusively fed by tube.

In children with PEG oral function should always be stimulated. Babies can be provided with a dummy especially during meals while older children can be offered something to chew or suck, such as chewing gum, piece of bread etc. It can comfort them and help the anatomical and functional development of the mouth (Tawfik et al., 1997). Mouth cleaning should be performed daily to allow a healthy growth of teeth.

7. Replacement of the PEG tube

Once placed, PEG tubes are left *in situ* until signs of cracking appear, usually after 12 months. Damaged tubes need replacing; this can easily be done at bedside, with balloon gastrostomy. Initial PEG needs to be removed before replacement. PEG removal techniques are varied. PEGs may be removed endoscopically by grasping the inner flange with a snare or basket and delivering it via the oral cavity in a retrograde fashion after cutting the external tube at skin level. Alternatively, the device can be removed percutaneously by traction provided that the inner flange is collapsible. This approach precludes the need for endoscopy unless complications are anticipated or encountered. The third approach involves cutting the device at skin level and allowing the inner flange to pass via the

alimentary tract (“cut and push” technique). This is commonly performed in adult practice, but is generally thought to be unacceptable in children due to risks of esophageal and intestinal obstruction. Esophageal obstruction, perforation, mediastinitis, retropharyngeal abscess formation, gastric outlet, intestinal and ileostomy obstruction, enterocutaneous fistula formation, tract disruption and death have been variously described with PEG removal (Yaseen et al., 1996, Siegel and Douglass, 2004, Palmer et al., 2006, Mollitt et al., 1998, Lattuneddu et al., 2003, Kobak et al., 2000, El-Rifai et al., 2004). Traction removal is performed under general anesthesia in children and involves application of a significant pulling force to deliver the device in full. Dilatation of the tract may be required in some cases.

For PEG replacement, parents may prefer a skin-level gastrostomy. This option should not be considered until the PEG tube has been *in situ* for at least 3 months, ensuring that the seal between the stomach and abdominal wall is intact and thus avoiding peritoneal soiling. Different types of skin-level replacement gastrostomy tubes including Bard® mushroom-shaped tube and the MICKEY® balloon type tube (Fig.3) are available. These tubes differ in the manner in which they are inserted and secured to the abdominal wall. The MICKEY® tube is inserted without using a stylet, while Bard® tube is inserted with assistance of a stylet. In addition, the MICKEY® tube is secured by a balloon, while the Bard® tube is secured by a mushroom-shaped tip. The MICKEY® tube can easily be inserted at bedside without the need for endoscopy or dye study to confirm location. The Bard® tube insertion using a stylet requires some force. This may increase the risk of disrupting the fistula tract (Fox et al., 1997). It requires endoscopy or dye study for confirmation. Replacement of skin-level devices may be required if the initial device gets blocked, dislodged, or poorly secured, especially after balloon rupture when using The MICKEY® tube. When gastrostomy tube dislodged, timely replacement is important because the fistulous tract will begin to close within hours, making subsequent replacement more difficult. If commercial replacement skin-level devices are not available, a similar size Foley catheter can be temporarily inserted.




Fig. 3. Skin-level gastrostomy tubes

8. Complications of the PEG tube

The peri-operative and post-operative complications of the PEG tube are summarized in Table 3.

| Complications |
|--|
| 1. Peri-operative complications |
| Tension pneumoperitoneum |
| Peritonitis |
| Esophageal perforation |
| Intra-abdominal bleeding |
| 2. Post-operative complications |
| Wound infection |
| Necrotizing fasciitis |
| Granulation tissue |
| Buried bumper syndrome |
| Tube migration |
| Inadvertent tube removal |
| Bloody PEG aspirate / hematemesis |
| Bowel perforation |
| Gastroesophageal reflux and pulmonary aspiration |

Table 3. Complications of PEG insertion

8.1 Peri-operative complications

8.1.1 Tension pneumoperitoneum

Benign pneumoperitoneum is common after PEG tube insertion, with reported incidence of over 50% (Hillman, 1982, Gottfried et al., 1986, Wojtowycz et al., 1988). Conservative management of patients with pneumoperitoneum, who have undergone a recent PEG in the absence of additional symptoms, is suggested. It should be of concern if the intraabdominal air is worsening or when it is found in the presence of signs of peritonitis, portal and/or mesenteric venous gas, systemic inflammatory response and/or sepsis (Wojtowycz et al., 1988). It may occasionally be a sign of possible bowel injury (Milanchi and Allins, 2007). A tension pneumoperitoneum may occur with excessive endoscopic insufflations and a

large leak occurs around the gastric needle entry site (Kealey et al., 1996). This can result in rapid respiratory embarrassment and cardiopulmonary arrest. Urgent management involves cessation of insufflations, gastric aspiration through the endoscope and peritoneal decompression via a large cannula placed percutaneously into the peritoneal cavity.

8.1.2 Peritonitis

Peritonitis occurring shortly after PEG insertion is either due to associated visceral trauma (usually colon), or due to gastric leakage because of separation of the stomach from the anterior abdominal wall (Kimber et al., 1998). Delay in making the diagnosis and institution of appropriate treatment may result in death (Lowe et al., 1997). Children with peritonitis may develop abdominal distension, guarding and generalized abdominal tenderness, with tachycardia, and pallor, and may be fever. Their clinical condition progressively deteriorates. Laparoscopy or laparotomy is warranted after stabilization for children with suspected peritonitis. PEG placement in children with chronic renal failure following initiation of peritoneal dialysis is associated with a high risk of fungal peritonitis (von Schnakenburg et al., 2006, Ledermann et al., 2002). The mortality and morbidity reported create more apprehension of recommending the PEG approach after chronic peritoneal dialysis has been initiated. At present, the evidence would favor placement of the gastrostomy early, before or preferably at the same time as peritoneal catheter insertion (Watson, 2006).

8.1.3 Esophageal perforation

Esophageal perforation is a rare complication that occurs as a result of using inappropriately large gastroscope in small infants or due to poor technique in retrieval of the guidewire especially if metallic guidewire is used (Beasley et al., 1995, Haynes et al., 1996). The presence of unrecognized esophageal stricture or abnormal fragile mucosa such as epidermolysis bullosa can be a predisposing factor for esophageal perforation (Haynes et al., 1996). This complication can be avoided with careful examination of the patient, and with using an appropriate gastroscope suitable for the age and body weight of the child. Metallic guidewires are not commonly used nowadays and being replaced with softer guidewires.

8.1.4 Intra-abdominal bleeding

PEG can be associated with life-threatening bleeding, especially when multiple needle punctures have been made. Acute hemorrhage following PEG is rarely reported (Lau and Lai, 2001, Wiggins et al., 2007). Unsuccessful passage of the needle could have caused the gastric artery branch laceration or breaches in the splenic and superior mesenteric veins or due to a liver laceration. It presents with unexplained post-procedure hypotension. Early recognition and treatment are essential.

8.2 Post-operative complications

8.2.1 Wound infection

PEG is a foreign body, and therefore creates and maintains a potential nidus for bacterial colonization. Children who require gastrostomy are often malnourished and have other

medical problems that make them more susceptible to gastrostomy wound infection(**Fig. 4**). Approximately 10% of children develop erythema and tenderness at the insertion site (Khattak et al., 1998). The most common causative organism was *staphylococcus aureus* (Saadeddin et al., 2005, Ahmad et al., 2003). Children tend to harbor polymicrobial aerobic-anaerobic flora and *Candida* at the gastrostomy site wound infection (Brook, 1995). Factors that contribute to the development of infection may include gastric acid leakage and pressure areas from an excessively tight tube (Iber et al., 1996, Bell et al., 1995). Preventing measures including checking the position of the external flange, cleaning the skin and rotating the tube daily can be followed. Meta-analysis of randomized-controlled trials of antibiotic prophylaxis prior to PEG insertion in adults (Jafri et al., 2007) has shown that prophylactic antibiotics are effective in reducing the incidence of PEG site wound infection. Both cephalosporin-based prophylaxis, such as cefazolin and penicillin-based prophylaxis, such as co-amoxiclav are equally effective. If infection diagnosed early, oral broad-spectrum antibiotics for 5-7 days may be all that is required for a PEG site infection. If there are more systemic signs, intravenous broad-spectrum antibiotics coupled with local wound care are necessary.

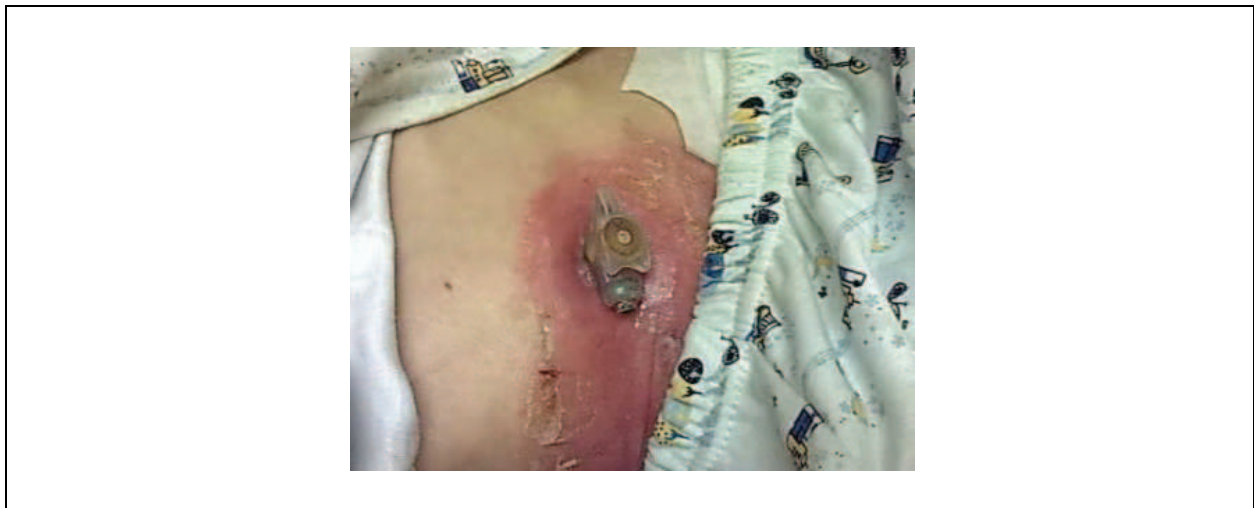

Fig. 4. Wound infection with associated cellulitis

8.2.2 Necrotizing fasciitis

A rare but potentially life-threatening complication is the development of necrotizing fasciitis. Children with pre-existing wound infections, malnutrition, and impaired immunity are at increased risk (Fox et al., 1997, Farrell et al., 1988). The microbiology of necrotizing fasciitis is complex. Multiple aerobic and anaerobic microorganisms display synergy and are responsible for the lethality of this condition (Giuliano et al., 1977). Management consists of broad spectrum intravenous antibiotics and aggressive surgical debridement.

8.2.3 Granulation tissue formation

Granulation tissue following insertion is common (**Fig.5**). It may occur in response to chronic leakage or infection. The granulation tissue can cause discharge, irritation, and discomfort. It can bleed in response to trauma. Frequent topical application of silver nitrate is often required and recurrence is common. It is important to protect the

surrounding normal skin with petroleum jelly during cauterization with silver nitrate to avoid chemical burns. Daily cleaning of the stoma and rotation of the PEG tube may help in its prevention.

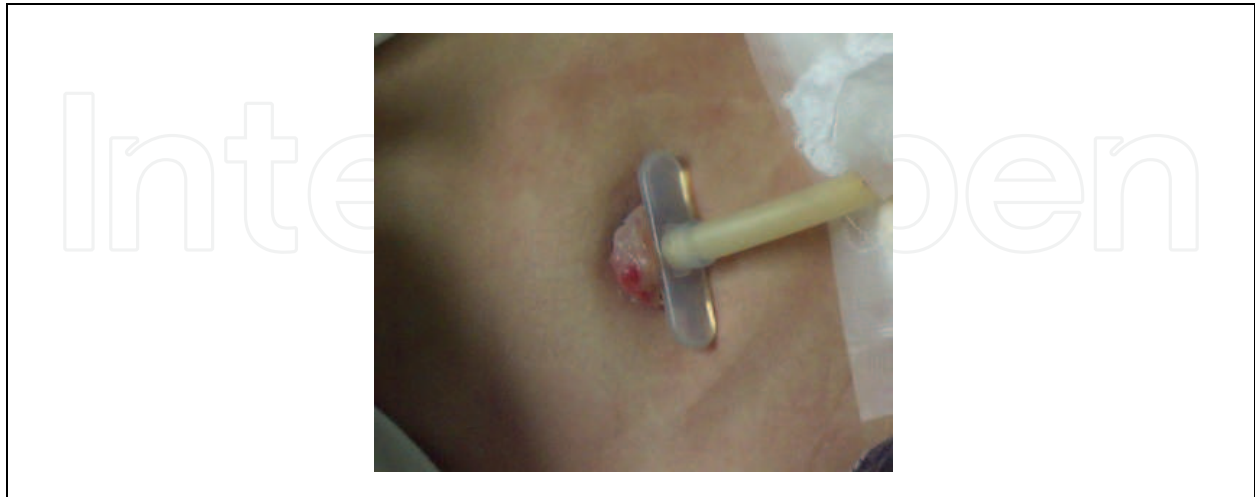

Fig. 5. Granulation tissue formation

8.2.4 Buried bumper syndrome

Buried bumper syndrome is a rare but serious complication of PEG. Published experience in children with buried bumper syndrome is very scarce (Furlano et al., 2008, Kohler et al., 2008, Hodges et al., 2001). The bumper becomes lodged anywhere between the gastric wall and the skin along the PEG tract. Partial or complete growth of gastric mucosa over the internal bolster may occur. The inability to infuse the feeding formula through the tube and leakage around the tube with abdominal pain are the most common manifestation (Schwartz et al., 1989). Other symptoms that may be experienced are erythema and edema at the gastrostomy site. The endoscopic examination may reveal small irregular slit or a raised mound of the mucosa at the previous tube site. A buried bumper should be removed even if the patient is asymptomatic, because of the risk of tube impaction in the abdominal wall and/or gastric perforation. Computed tomography and ultrasonography can be helpful in localizing the bumper and in deciding the appropriate approach for removing the PEG either surgical or endoscopic. A number of approaches have been used for the treatment of buried bumper syndrome. Initial reports used incision of the skin and dissection to remove the impacted bumper, followed by insertion of the replacement tube (Shallman et al., 1988, Nelson, 1989, Lee, 1990). Another strategy involves placing a guidewire through the impacted tube, followed by pushing the impacted bumper into the stomach using dilators externally. The bumper is removed endoscopically and replacement tube is inserted through the fistula (Klein et al., 1990, Ma et al., 1995). The selected method has to be safe and should be tailored to the individual patient's needs.

8.2.5 Gastrostomy tube migration

The inner flange may enter the pylorus causing complete or partial obstruction (Hussain and Thambidorai, 2000, Berry and Vellacott, 1992). If the PEG is within mobile bowel it may act as an axis for volvulus causing intestinal obstruction (Waxman et al., 1991, Senac and

Lee, 1983). This complication occurs if the PEG has been inserted in the distal antrum, close to the pylorus. This complication can be avoided by careful placement of the PEG on the greater curve, proximal to the antrum and pyloric canal.

8.2.6 Inadvertent tube removal

PEG tract maturation usually occurs within the first 7-10 days but may be delayed up to 4 weeks in the presence of malnutrition. Inadvertent PEG tube removal can rarely occur (Larson et al., 1987, Dwyer et al., 2002). Irritable and hyperactive children are more liable to this complication. A PEG tube accidentally removed before the PEG tract maturation completed, should be replaced endoscopically. The stomach and the abdominal wall can separate from each other, resulting in free perforation. If the PEG tube is dislodged less than one month after placement, repeat endoscopy should be performed to replace the tube. When recognized early, the replacement PEG tube can be placed either near or even through the same PEG tube site (Galat et al., 1990). Blindly reinserting a new tube may lead to its placement inside the peritoneal cavity. If recognition is delayed, the patient should be kept NPO (nothing per oral), a nasogastric tube should be placed, and broad-spectrum antibiotics should be started. A new PEG should be placed after 7-10 day. Surgical exploration is indicated if signs of peritonitis/sepsis are present. A replacement tube can be placed without endoscopy through presumably mature tract, when a PEG tube dislodged more than one month after placement.

8.2.7 Bloody PEG aspirate / hematemesis

Gastrointestinal bleeding after PEG placement has been reported rarely in children (Kazi et al., 1997, Weiss et al., 1999). If the PEG flange is loose and mobile within the stomach it can irritate the gastric mucosa, and if too tight it can erode the gastric wall by pressure necrosis. Either process may lead to gastric bleeding. Most patients present with bleeding between two weeks and 6 months. Delayed presentation after 12 years from PEG placement was reported in one child. (Weiss et al., 1999). Because upper gastrointestinal bleeding is not always related to the PEG, endoscopy is recommended for diagnosis. Esophagitis and gastritis may both occur in chronically ill children, especially in neurologically impaired children with reflux esophagitis.

8.2.8 Bowel perforation

Gastro-colo-cutaneous fistulae may occur rarely when the colon is inadvertently punctured and traversed during PEG placement (Gauderer, 1991, Hacker and Cattau, 1987). Patients may present acutely with colonic perforation and peritonitis (Kimber et al., 1998). More commonly, patients present chronically with stool leaking around the PEG tube or through the stoma during tube removal or replacement. The diagnosis is made using contrast radiography via the PEG tube. In most cases, there is no evidence of intraperitoneal leakage or gastro-colic fistula. Management consists of removing the tube and allowing the fistula to close (Berger and Zarling, 1991). Should the patient develop signs of peritonitis or the fistula fail to close, surgery is often required.

To avoid this complication, the introducing needle should not be inserted into the stomach without adequate gastric insufflations, appropriate transillumination, and endoscopically visible focal indentation upon external palpation.

8.2.9 Gastroesophageal reflux and pulmonary aspiration

Gastroesophageal reflux is a common problem in neurologically impaired children (Bozkurt et al., 2004, Gangil et al., 2001). Children with symptoms of reflux who do not respond to medical therapy or with evidence of pulmonary aspiration caused by their reflux should undergo a surgical gastrostomy along with an anti-reflux procedure. In children without symptoms of reflux or with mild reflux responding well to medical treatment, an endoscopic percutaneous approach may be used. There is no role for a prophylactic anti-reflux procedure (Sulaeman et al., 1998, Khattak et al., 1998, Isch et al., 1997). The choice between a gastrostomy with or without an anti-reflux procedure has to be carefully evaluated because the failure rate and the incidence of major complications are high in neurologically impaired children undergoing anti-reflux procedure (Borgstein et al., 1994). In difficult cases, it may be useful to attempt a trial of nasogastric feeds for one month to assess tolerance before making a decision. It has been suggested that symptomatic Gastroesophageal reflux occurs frequently after PEG (Cameron et al., 1995). Pulmonary aspiration has been rarely reported in children following percutaneous gastrostomy feeding (Morton et al., 1999, Sy et al., 2008). It is unclear whether this is a consequence of the change in volume, consistency and composition of the feeds or a consequence of the procedure. If this problem occurs, medical treatment with prokinetics and changes in the formula or in the rate and volume of feeds should be attempted before restoring to an anti-reflux procedure.

9. Conclusion

PEG insertion in children who cannot achieve adequate oral intake is an established route for providing long term enteral nutrition. Feeding through PEG tube helps improving the physical growth and general health of the chronically ill patients, with subsequent effect on the family quality of life. The procedure is associated with frequent minor morbidity. Awareness of these complications and the use of preventive strategies can allow the endoscopist to maximize outcomes and to identify complications early.

10. References

- Ahmad, I., Mouncher, A., Abdoolah, A., Stenson, R., Wright, J., Daniels, A., Tillett, J., Hawthorne, A. B. & Thomas, G. (2003) Antibiotic prophylaxis for percutaneous endoscopic gastrostomy--a prospective, randomised, double-blind trial. *Aliment Pharmacol Ther*, 18, 209-15.
- Anthony, H., Paxton, S., Catto-Smith, A. & Phelan, P. (1999) Physiological and psychosocial contributors to malnutrition in children with cystic fibrosis: review. *Clin Nutr*, 18, 327-35.
- Avitsland, T. L., Kristensen, C., Emblem, R., Veenstra, M., Mala, T. & Bjornland, K. (2006) Percutaneous endoscopic gastrostomy in children: a safe technique with major symptom relief and high parental satisfaction. *J Pediatr Gastroenterol Nutr*, 43, 624-8.
- Beasley, S. W., Catto-Smith, A. G. & Davidson, P. M. (1995) How to avoid complications during percutaneous endoscopic gastrostomy. *J Pediatr Surg*, 30, 671-3.

- Bell, S. C., Elborn, J. S., Campbell, I. A. & Shale, D. J. (1995) Candida albicans infection complicating percutaneous gastrostomy in cystic fibrosis. *Br J Clin Pract*, 49, 109-10.
- Belli, D. C., Seidman, E., Bouthillier, L., Weber, A. M., Roy, C. C., Pletincx, M., Beaulieu, M. & Morin, C. L. (1988) Chronic intermittent elemental diet improves growth failure in children with Crohn's disease. *Gastroenterology*, 94, 603-10.
- Bellisle, F., Dartois, A. M., Kleinknecht, C. & Broyer, M. (1995) [Alteration of the taste for sugar in renal insufficiency: study in the child]. *Nephrologie*, 16, 203-8.
- Berger, S. A. & Zarling, E. J. (1991) Colocutaneous fistula following migration of PEG tube. *Gastrointest Endosc*, 37, 86-8.
- Berry, D. P. & Vellacott, K. D. (1992) High jejunal obstruction: a complication of percutaneous endoscopic gastrostomy. *Br J Surg*, 79, 1171.
- Borgstein, E. S., Heij, H. A., Beugelaar, J. D., Ekkelkamp, S. & Vos, A. (1994) Risks and benefits of antireflux operations in neurologically impaired children. *Eur J Pediatr*, 153, 248-51.
- Bosaeus, I., Daneryd, P., Svanberg, E. & Lundholm, K. (2001) Dietary intake and resting energy expenditure in relation to weight loss in unselected cancer patients. *Int J Cancer*, 93, 380-3.
- Bozkurt, M., Tutuncuoglu, S., Serdaroglu, G., Tekgul, H. & Aydogdu, S. (2004) Gastroesophageal reflux in children with cerebral palsy: efficacy of cisapride. *J Child Neurol*, 19, 973-6.
- Brant, C. Q., Stanich, P. & Ferrari, A. P., JR. (1999) Improvement of children's nutritional status after enteral feeding by PEG: an interim report. *Gastrointest Endosc*, 50, 183-8.
- Brook, I. (1995) Microbiology of gastrostomy site wound infections in children. *J Med Microbiol*, 43, 221-3.
- Buchdahl, R. M., Cox, M., Fulleylove, C., Marchant, J. L., Tomkins, A. M., Brueton, M. J. & Warner, J. O. (1988) Increased resting energy expenditure in cystic fibrosis. *J Appl Physiol*, 64, 1810-6.
- Buchman, A. L. (2007) Use of percutaneous endoscopic gastrostomy or percutaneous endoscopic jejunostomy in short bowel syndrome. *Gastrointest Endosc Clin N Am*, 17, 787-94.
- Cameron, B. H., Blair, G. K., Murphy, J. J., 3rd & Fraser, G. C. (1995) Morbidity in neurologically impaired children after percutaneous endoscopic versus Stamm gastrostomy. *Gastrointest Endosc*, 42, 41-4.
- Cosgrove, M. & Jenkins, H. R. (1997) Experience of percutaneous endoscopic gastrostomy in children with Crohn's disease. *Arch Dis Child*, 76, 141-3.
- Craig, G. M., Carr, L. J., Cass, H., Hastings, R. P., Lawson, M., Reilly, S., Ryan, M., Townsend, J. & Spitz, L. (2006) Medical, surgical, and health outcomes of gastrostomy feeding. *Dev Med Child Neurol*, 48, 353-60.
- Durie, P. R. & Pencharz, P. B. (1992) Cystic fibrosis: nutrition. *Br Med Bull*, 48, 823-46.
- Dwyer, K. M., Watts, D. D., Thurber, J. S., Benoit, R. S. & Fakhry, S. M. (2002) Percutaneous endoscopic gastrostomy: the preferred method of elective feeding tube placement in trauma patients. *J Trauma*, 52, 26-32.
- Efrati, O., Mei-Zahav, M., Rivilin J., Kerem, E., Blau, H., Barak, A., Bijanover, Y., Augarten, A., Cochavi, B., Yahav, Y. & Modan-Moses, D. (2006) Long term

- nutritional rehabilitation by gastrostomy in Israeli patients with cystic fibrosis: clinical outcome in advanced pulmonary disease. *J Pediatr Gastroenterol Nutr*, 42, 222-8.
- El-Rifai, N., Michaud, L., Mention, K., Guimber, D., Caldari, D., Turck, D. & Gottrand, F. (2004) Persistence of gastrocutaneous fistula after removal of gastrostomy tubes in children: prevalence and associated factors. *Endoscopy*, 36, 700-4.
- Farreli, L. D., Karl, S. R., Davis, P. K., Bellinger, M. F. & Ballantine, T. V. (1988) Postoperative necrotizing fasciitis in children. *Pediatrics*, 82, 874-9.
- Fonkalsrud, E. W., Ellis, D. G., Shaw, A., Mann, C. M., JR., Black, T. L., Miller, J. P. & Snyder, C. L. (1995) A combined hospital experience with fundoplication and gastric emptying procedure for gastroesophageal reflux in children. *J Am Coll Surg*, 180, 449-55.
- Fox, V. L., Abel, S. D., Malas, S., Duggan, C. & Leichtner, A. M. (1997) Complications following percutaneous endoscopic gastrostomy and subsequent catheter replacement in children and young adults. *Gastrointest Endosc*, 45, 64-71.
- Furlano, R. I., Sidler, M. & Haack, H. (2008) The push-pull T technique: an easy and safe procedure in children with the buried bumper syndrome. *Nutr Clin Pract*, 23, 655-7.
- Galat, S. A., Gerig, K. D., Porter, J. A. & Slezak, F. A. (1990) Management of premature removal of the percutaneous gastrostomy. *Am Surg*, 56, 733-6.
- Gangil, A., Patwari, A. K., Bajaj, P., Kashyap, R. & Anand, V. K. (2001) Gastroesophageal reflux disease in children with cerebral palsy. *Indian Pediatr*, 38, 766-70.
- Gauderer, M. W. (1991) Percutaneous endoscopic gastrostomy: a 10-year experience with 220 children. *J Pediatr Surg*, 26, 288-92; discussion 292-4.
- Gauderer, M. W. (2002) Percutaneous endoscopic gastrostomy and the evolution of contemporary long-term enteral access. *Clin Nutr*, 21, 103-10.
- Gisel, E. G., Birnbaum, R. & Schwartz, S. (1998) Feeding impairments in children: diagnosis and effective intervention. *Int J Orofacial Myology*, 24, 27-33.
- Giuliano, A., Lewis, F., JR., Hardey, K. & Blaisdell, F. W. (1977) Bacteriology of necrotizing fasciitis. *Am J Surg*, 134, 52-7.
- Gottfried, E. B., Plumser, A. B. & Clair, M. R. (1986) Pneumoperitoneum following percutaneous endoscopic gastrostomy. A prospective study. *Gastrointest Endosc*, 32, 397-9.
- Hacker, J. F., 3rd & Cattau, E. L., JR. (1987) Conversion of percutaneous endoscopic gastrostomy to a tube colostomy. *South Med J*, 80, 797-8.
- Hagelgans, N. A. & Janusz, H. B. (1994) Pediatric skin care issues for the home care nurse: Part 2. *Pediatr Nurs*, 20, 69-74, 76.
- Halsey, N. A., Boulos, R., Holt, E., Ruff, A., Brutus, J. R., Kissinger, P., Quinn, T. C., Coberly, J. S., Adrien, M. & Boulos, C. (1990) Transmission of HIV-1 infections from mothers to infants in Haiti. Impact on childhood mortality and malnutrition. The CDS/JHU AIDS Project Team. *JAMA*, 264, 2088-92.
- Han-Markey, T. (2000) Nutritional considerations in pediatric oncology. *Semin Oncol Nurs*, 16, 146-51.
- Haynes, L., Atherton, D. J., Ade-Ajayi, N., Wheeler, R. & Kiely, E. M. (1996) Gastrostomy and growth in dystrophic epidermolysis bullosa. *Br J Dermatol*, 134, 872-9.

- Heikenen, J. B., Werlin, S. L. & Brown, C. W. (1999) Electrogastrography in gastrostomy-tube-fed children. *Dig Dis Sci*, 44, 1293-7.
- HEenderson R. A., Saavedra, J. M., Perman, J. A., Hutton, N., Livingston, R. A. & Yolken, R. H. (1994) Effect of enteral tube feeding on growth of children with symptomatic human immunodeficiency virus infection. *J Pediatr Gastroenterol Nutr*, 18, 429-34.
- Hillman, K. M. (1982) Pneumoperitoneum--a review. *Crit Care Med*, 10, 476-81.
- Hodges, E. G., Morano, J. U. & Nowicki, M. J. (2001) The buried bumper syndrome complicating percutaneous endoscopic gastrostomy in children. *J Pediatr Gastroenterol Nutr*, 33, 326-8.
- Hofner, G., Behrens, R., Koch, A., Singer, H. & Hofbeck, M. (2000) Enteral nutritional support by percutaneous endoscopic gastrostomy in children with congenital heart disease. *Pediatr Cardiol*, 21, 341-6.
- Hussain, M. & Thambidorai, C. R. (2000) Intussusception as a complication of gastrostomy tube: a case report. *Med J Malaysia*, 55, 271-2.
- Iber, F. L., Livak, A. & Patel, M. (1996) Importance of fungus colonization in failure of silicone rubber percutaneous gastrostomy tubes (PEGs). *Dig Dis Sci*, 41, 226-31.
- Isch, J. A., Rescorla, F. J., Scherer, L. R., 3rd, West, K. W. & Grosfeld, J. L. (1997) The development of gastroesophageal reflux after percutaneous endoscopic gastrostomy. *J Pediatr Surg*, 32, 321-2; discussion 322-3.
- Israel, D. M. & Hassall, E. (1995) Prolonged use of gastrostomy for enteral hyperalimentation in children with Crohn's disease. *Am J Gastroenterol*, 90, 1084-8.
- Jafri, N. S., Mahid, S. S., Minor, K. S., Idstein, S. R., Hornung, C. A. & Galandiuk, S. (2007) Meta-analysis: antibiotic prophylaxis to prevent peristomal infection following percutaneous endoscopic gastrostomy. *Aliment Pharmacol Ther*, 25, 647-56.
- Kari, J. A., Gonzalez, C., Ledermann, S. E., Shaw, V. & Rees, L. (2000) Outcome and growth of infants with severe chronic renal failure. *Kidney Int*, 57, 1681-7.
- Kazi, S., Gunasekaran, T. S., Berman, J. H., Kavin, H. & Kraut, J. R. (1997) Gastric mucosal injuries in children from inflatable low-profile gastrostomy tubes. *J Pediatr Gastroenterol Nutr*, 24, 75-8.
- Kealey, W. D., Mccallion, W. A. & Boston, V. E. (1996) Tension pneumoperitoneum: a potentially life-threatening complication of percutaneous endoscopic gastrojejunostomy. *J Pediatr Gastroenterol Nutr*, 22, 334-5.
- Khattak, I. U., Kimber, C., Kiely, E. M. & Spitz, L. (1998) Percutaneous endoscopic gastrostomy in paediatric practice: complications and outcome. *J Pediatr Surg*, 33, 67-72.
- Kimber, C. P., Khattak, I. U., Kiely, E. M. & Spitz, L. (1998) Peritonitis following percutaneous gastrostomy in children: management guidelines. *Aust N Z J Surg*, 68, 268-70.
- Kirschner, B. S., Voinchet, O. & Rosenberg, I. H. (1978) Growth retardation in inflammatory bowel disease. *Gastroenterology*, 75, 504-11.
- Klein, S., Heare, B. R. & Soloway, R. D. (1990) The "buried bumper syndrome": a complication of percutaneous endoscopic gastrostomy. *Am J Gastroenterol*, 85, 448-51.

- Kobak, G. E., Mcclenathan, D. T. & Schurman, S. J. (2000) Complications of removing percutaneous endoscopic gastrostomy tubes in children. *J Pediatr Gastroenterol Nutr*, 30, 404-7.
- Kohler, H., Lang, T. & Behrens, R. (2008) Buried bumper syndrome after percutaneous endoscopic gastrostomy in children and adolescents. *Endoscopy*, 40 Suppl 2, E85-6.
- Kraemer, R., Rudenberg A., Hadorn, B. & Rossi, E. (1978) Relative underweight in cystic fibrosis and its prognostic value. *Acta Paediatr Scand*, 67, 33-7.
- Lapey, A., Kattwinkel, J., Di Sant'Agnesse, P. A. & Laster, L. (1974) Steatorrhea and azotorrhea and their relation to growth and nutrition in adolescents and young adults with cystic fibrosis. *J Pediatr*, 84, 328-34.
- Larson, D. E., Burton, D. D., Schroeder, K. W. & Dimagno, E. P. (1987) Percutaneous endoscopic gastrostomy. Indications, success, complications, and mortality in 314 consecutive patients. *Gastroenterology*, 93, 48-52.
- Lattuneddu, A., Morgagni, P., Benati, G., Delvecchio, S. & Garcea, D. (2003) Small bowel perforation after incomplete removal of percutaneous endoscopic gastrostomy catheter. *Surg Endosc*, 17, 2028-31.
- Lau, G. & Lai, S. H. (2001) Fatal retroperitoneal haemorrhage: an unusual complication of percutaneous endoscopic gastrostomy. *Forensic Sci Int*, 116, 69-75.
- Ledermann, S. (2005) When should gastrostomy tubes be removed following successful renal transplantation? *Pediatr Transplant*, 9, 553-4.
- Ledermann, S. E., Spitz, L., Moloney, J., Rees, L. & Trompeter, R. S. (2002) Gastrostomy feeding in infants and children on peritoneal dialysis. *Pediatr Nephrol*, 17, 246-50.
- Lee, M. P. (1990) Impaction of gastrostomy tube in the abdominal wall. *J Am Geriatr Soc*, 38, 956.
- Leitch, C. A. (2000) Growth, nutrition and energy expenditure in pediatric heart failure. *Prog Pediatr Cardiol*, 11, 195-202.
- Lowe, J. B., Page, C. P., Schwesinger, W. H., Gaskill, H. V. & Stauffer, J. S. (1997) Percutaneous endoscopic gastrostomy tube placement in a surgical training program. *Am J Surg*, 174, 624-7; discussion 627-8.
- Ma, M. M., Semlacher, E. A., Fedorak, R. N., Lalor, E. A., Duerksen, D. R., Sherbaniuk, R. W., Chalpelsky, C. E. & Sadowski, D. C. (1995) The buried gastrostomy bumper syndrome: prevention and endoscopic approaches to removal. *Gastrointest Endosc*, 41, 505-8.
- Mak, R. H., Cheung, W., Cone, R. D. & Marks, D. L. (2006) Leptin and inflammation-associated cachexia in chronic kidney disease. *Kidney Int*, 69, 794-7.
- Marin, O. E., Glassman, M. S., Schoen, B. T. & Caplan, D. B. (1994) Safety and efficacy of percutaneous endoscopic gastrostomy in children. *Am J Gastroenterol*, 89, 357-61.
- Matsui, D. M. (1997) Drug compliance in pediatrics. Clinical and research issues. *Pediatr Clin North Am*, 44, 1-14.
- Michaud, L., Guimber, D., Carpentier, B., Sfeir, R., Lambilliotte, A., Mazingue, F., Gottrand, F. & Turck, D. (2001) Gastrostomy as a decompression technique in children with chronic gastrointestinal obstruction. *J Pediatr Gastroenterol Nutr*, 32, 82-5.


- Milanchi, S. & Allins, A. (2007) Early pneumoperitoneum after percutaneous endoscopic gastrostomy in intensive care patients: sign of possible bowel injury. *Am J Crit Care*, 16, 132-6.
- Miller, T. L., Awnetwant, E. L., Evans, S., Morris, V. M., Vazquez, I. M. & McIntosh K. (1995) Gastrostomy tube supplementation for HIV-infected children. *Pediatrics*, 96, 696-702.
- Miller, T. L., Evans, S. J., Orav, E. J., Morris, V., McIntosh, K. & Winter, H. S. (1993) Growth and body composition in children infected with the human immunodeficiency virus-1. *Am J Clin Nutr*, 57, 588-92.
- Mitchell, I. M., Logan, R. W., Pollock, J. C. & Jamieson, M. P. (1995) Nutritional status of children with congenital heart disease. *Br Heart J*, 73, 277-83.
- Mollitt, D. L., Dokler, M. L., Evans, J. S., Jeiven, S. D. & George, D. E. (1998) Complications of retained internal bolster after pediatric percutaneous endoscopic gastrostomy. *J Pediatr Surg*, 33, 271-3.
- Morton, R. E., Wheatley, R. & Minford, J. (1999) Respiratory tract infections due to direct and reflux aspiration in children with severe neurodisability. *Dev Med Child Neurol*, 41, 329-34.
- Nelson, A. M. (1989) PEG feeding tube migration and erosion into the abdominal wall. *Gastrointest Endosc*, 35, 133.
- Oliver, M. R., Heine, R. G., NG, C. H., Volders, E. & Olinsky, A. (2004) Factors affecting clinical outcome in gastrostomy-fed children with cystic fibrosis. *Pediatr Pulmonol*, 37, 324-9.
- Palmer, G. M., Frawley, G. P., Heine, R. G. & Oliver, M. R. (2006) Complications associated with endoscopic removal of percutaneous endoscopic gastrostomy (PEG) tubes in children. *J Pediatr Gastroenterol Nutr*, 42, 443-5.
- Pashankar, D. & Israel, D. M. (1997) Gastrostomy in children with Crohn's disease. *Arch Dis Child*, 77, 369.
- Pedersen, A. M., Kok, K., Petersen, G., Nielsen, O. H., Michaelsen, K. F. & Schmiegelow, K. (1999) Percutaneous endoscopic gastrostomy in children with cancer. *Acta Paediatr*, 88, 849-52.
- Pugh, P. & Watson, A. R. (2006) Transition from gastrostomy to oral feeding following renal transplantation. *Adv Perit Dial*, 22, 153-7.
- Puntis, J. W., Thwaites, R., Abel, G. & Stringer, M. D. (2000) Children with neurological disorders do not always need fundoplication concomitant with percutaneous endoscopic gastrostomy. *Dev Med Child Neurol*, 42, 97-9.
- Ravelli, A. M., Ledermann, S. E., Bisset, W. M., Trompeter, R. S., Barrat, T. M. & Milla, P. J. (1992) Foregut motor function in chronic renal failure. *Arch Dis Child*, 67, 1343-7.
- Rees, L. & Shaw, V. (2007) Nutrition in children with CRF and on dialysis. *Pediatr Nephrol*, 22, 1689-702.
- Reilly, S. & Skuse, D. (1992) Characteristics and management of feeding problems of young children with cerebral palsy. *Dev Med Child Neurol*, 34, 379-88.
- Rempel, G. R., Colwell, S. O. & Nelson, R. P. (1988) Growth in children with cerebral palsy fed via gastrostomy. *Pediatrics*, 82, 857-62.
- Ricciardi, E. & Brown, D. (1994) Managing PEG tubes. *Am J Nurs*, 94, 29-31.

- Rickard, K. A., Grosfeld, J. L., Coates, T. D., Weetman, R. & Baehner, R. L. (1986) Advances in nutrition care of children with neoplastic diseases: a review of treatment, research, and application. *J Am Diet Assoc*, 86, 1666-76.
- Rogers, B., Arvedson, J., Buck, G., Smart, P. & Msall, M. (1994) Characteristics of dysphagia in children with cerebral palsy. *Dysphagia*, 9, 69-73.
- Ross, M. N., Haase, G. M., Reiley, T. T. & Meagher, D. P., JR. (1988) The importance of acid reflux patterns in neurologically damaged children detected by four-channel esophageal pH monitoring. *J Pediatr Surg*, 23, 573-6.
- Saadeddin, A., Freshwater, D. A., Fisher, N. C. & Jones, B. J. (2005) Antibiotic prophylaxis for percutaneous endoscopic gastrostomy for non-malignant conditions: a double-blind prospective randomized controlled trial. *Aliment Pharmacol Ther*, 22, 565-70.
- Sala, A., Pencharz, P. & Barr, R. D. (2004) Children, cancer, and nutrition--A dynamic triangle in review. *Cancer*, 100, 677-87.
- Sanders, K. D., Cox, K., Cannon, R., Blanchard, D., Pitcher, J., Papathakis, P., Varella, L. & Maughan, R. (1990) Growth response to enteral feeding by children with cerebral palsy. *JPEN J Parenter Enteral Nutr*, 14, 23-6.
- Sanderson, I. R., Udeen, S., Davies, P. S., Savage, M. O. & Walker-Smith, J. A. (1987) Remission induced by an elemental diet in small bowel Crohn's disease. *Arch Dis Child*, 62, 123-7.
- Schwartz, H. I., Goldberg, R. I., Barkin, J. S., Phillips, R. S., Land, A. & Hecht, M. (1989) PEG feeding tube migration impaction in the abdominal wall. *Gastrointest Endosc*, 35, 134.
- Senac, M. O., JR. & Lee, F. A. (1983) Small-bowel volvulus as a complication of gastrostomy. *Radiology*, 149, 136.
- Shallman, R. W., Norfleet, R. G. & Hardache, J. M. (1988) Percutaneous endoscopic gastrostomy feeding tube migration and impaction in the abdominal wall. *Gastrointest Endosc*, 34, 367-8.
- Shapiro, B. K., Green, P., Krick, J., Allen, D. & Capute, A. J. (1986) Growth of severely impaired children: neurological versus nutritional factors. *Dev Med Child Neurol*, 28, 729-33.
- Shepherd, R., Cooksley, W. G. & Cooke, W. D. (1980) Improved growth and clinical, nutritional, and respiratory changes in response to nutritional therapy in cystic fibrosis. *J Pediatr*, 97, 351-7.
- Shingadia, D., Viani, R. M., Yogev, R., Binns, H., Dankner, W. M., Spector, S. A. & CHADWICK, E. G. (2000) Gastrostomy tube insertion for improvement of adherence to highly active antiretroviral therapy in pediatric patients with human immunodeficiency virus. *Pediatrics*, 105, E80.
- Siegel, T. R. & Douglass, M. (2004) Perforation of an ileostomy by a retained percutaneous endoscopic gastrostomy (PEG) tube bumper. *Surg Endosc*, 18, 348.
- Skolin, I., Hernell, O., Larsson, M. V., Wahlgren, C. & Wahlin, Y. B. (2002) Percutaneous endoscopic gastrostomy in children with malignant disease. *J Pediatr Oncol Nurs*, 19, 154-63.
- Smith, D. E., Stevens, M. C. & Booth, I. W. (1991) Malnutrition at diagnosis of malignancy in childhood: common but mostly missed. *Eur J Pediatr*, 150, 318-22.

- Sondheimer, J. M. & Morris, B. A. (1979) Gastroesophageal reflux among severely retarded children. *J Pediatr*, 94, 710-4.
- Stallings, V. A., Charney, E. B., Davies, J. C. & Cronk, C. E. (1993) Nutrition-related growth failure of children with quadriplegic cerebral palsy. *Dev Med Child Neurol*, 35, 126-38.
- Stevenson, R. (2005) Beyond growth: gastrostomy feeding in children with cerebral palsy. *Dev Med Child Neurol*, 47, 76.
- Sulaeman, E., Udall, J. N., JR., Brown, R. F., Mannick, E. E., Loe, W. A., Hill, C. B. & Schmidt-Sommerfeld, E. (1998) Gastroesophageal reflux and Nissen fundoplication following percutaneous endoscopic gastrostomy in children. *J Pediatr Gastroenterol Nutr*, 26, 269-73.
- Sullivan, P. B. (1992) Gastrostomy and the disabled child. *Dev Med Child Neurol*, 34, 552-5.
- Sullivan, P. B. (1999) Gastrostomy feeding in the disabled child: when is an antireflux procedure required? *Arch Dis Child*, 81, 463-4.
- Sullivan, P. B., Juszczak, E., Bachlet, A. M., Lambert, B., Vernon-Roberts, A., Grant, H. W., Eltumi, M., Mclean, L., Alder, N. & Thomas, A. G. (2005) Gastrostomy tube feeding in children with cerebral palsy: a prospective, longitudinal study. *Dev Med Child Neurol*, 47, 77-85.
- Sullivan, P. B., Juszczak, E., Bachlet, A. M., Thomas, A. G., Lambert, B., Vernon-Roberts, A., Grant, H. W., Eltumi, M., Alder, N. & Jenkinson, C. (2004) Impact of gastrostomy tube feeding on the quality of life of carers of children with cerebral palsy. *Dev Med Child Neurol*, 46, 796-800.
- Sullivan, P. B., Lambert, B., Rose, M., Ford-Adams, M., Johnson, A. & Griffiths, P. (2000) Prevalence and severity of feeding and nutritional problems in children with neurological impairment: Oxford Feeding Study. *Dev Med Child Neurol*, 42, 674-80.
- Sy, K., Dipchand, A., Atenafu, E., Chait, P., Bannister, L., Temple, M., John, P., Connolly, B. & Amaral, J. G. (2008) Safety and effectiveness of radiologic percutaneous gastrostomy and gastro jejunostomy in children with cardiac disease. *AJR Am J Roentgenol*, 191, 1169-74.
- Tawfik, R., Dickson, A., Clarke, M. & Thomas, A. G. (1997) Caregivers' perceptions following gastrostomy in severely disabled children with feeding problems. *Dev Med Child Neurol*, 39, 746-51.
- Taylor, L. A., Weiner, T., Lacey, S. R. & Azizkhan, R. G. (1994) Chronic lung disease is the leading risk factor correlating with the failure (wrap disruption) of antireflux procedures in children. *J Pediatr Surg*, 29, 161-4; discussion 164-6.
- Temple, M. E., Koranyi, K. I. & Nahata, M. C. (2001) Gastrostomy tube placement in nonadherent HIV-infected children. *Ann Pharmacother*, 35, 414-8.
- Tisdale, M. J. (1997) Cancer cachexia: metabolic alterations and clinical manifestations. *Nutrition*, 13, 1-7.
- Truby, H., Cowlshaw, P., O'Neill C. & Waineright, C. (2009) The long term efficacy of gastrostomy feeding in children with cystic fibrosis on anthropometric markers of nutritional status and pulmonary function. *Open Respir Med J*, 3, 112-5.
- Van Biervliet, S., De Waele, K., Van Winckel, M. & Robberecht, E. (2004) Percutaneous endoscopic gastrostomy in cystic fibrosis: patient acceptance and effect of overnight tube feeding on nutritional status. *Acta Gastroenterol Belg*, 67, 241-4.

- Van Eys, J. (1979) Malnutrition in children with cancer: incidence and consequence. *Cancer*, 43, 2030-5.
- Von Schnakenburg, C., Feneberg, R., Plank, C., Zimmering, M., Arbeiter, K., Bald, M., Fehrenbach, H., Griebel, M., Licht, C., Konrad, M., Timmermann, K. & Kemper, M. J. (2006) Percutaneous endoscopic gastrostomy in children on peritoneal dialysis. *Perit Dial Int*, 26, 69-77.
- Watson, A. R. (2006) Gastrostomy feeding in children on chronic peritoneal dialysis. *Perit Dial Int*, 26, 41-2.
- Waxman, I., Al-Kawas, F. H., Bass, B. & Glouderman, M. (1991) PEG ileus. A new cause of small bowel obstruction. *Dig Dis Sci*, 36, 251-4.
- Weiss, B., Fradkin, A., Ben-Akun, M., Avigad, I., Ben-Shlush, A. & Jonas, A. (1999) Upper gastrointestinal bleeding due to gastric ulcers in children with gastrostomy tubes. *J Clin Gastroenterol*, 29, 48-50.
- Wiggins, T. F., Kaplan, R. & Delegge, M. H. (2007) Acute hemorrhage following transhepatic PEG tube placement. *Dig Dis Sci*, 52, 167-9.
- Wojowycz, M. M., Arata, J. A., JR., Micklos, T. J. & Miller, F. J., JR. (1988) CT findings after uncomplicated percutaneous gastrostomy. *AJR Am J Roentgenol*, 151, 307-9.
- Yaseen, M., Steele, M. I. & Grunow, J. E. (1996) Nonendoscopic removal of percutaneous endoscopic gastrostomy tubes: morbidity and mortality in children. *Gastrointest Endosc*, 44, 235-8.

IntechOpen



Gastrostomy

Edited by Dr. Pavel Kohout

ISBN 978-953-307-365-1

Hard cover, 152 pages

Publisher InTech

Published online 02, December, 2011

Published in print edition December, 2011

The gastrostomy placement is a method of providing nutrition to the patients who are unable to eat. In this book you can find chapters focused on the use of gastrostomy in children, patients with neurological impairment and patients with head and neck tumours. Home enteral nutrition is suitable for all of these groups of patients and is far easier with gastrostomy. The new indications (especially in very young children) required new techniques such as: laparoscopic gastrostomy, laparoscopy assisted endoscopic gastrostomy with/without fundoplication, ultrasonography assisted gastrostomy. All information about these techniques can be found in this book. This book does not serve as a basic textbook, but as an interesting reading material and as an aid for physicians who are already familiar with the indication for gastrostomy and want to know more.

How to reference

In order to correctly reference this scholarly work, feel free to copy and paste the following:

Omar I. Saadah (2011). Percutaneous Endoscopic Gastrostomy in Pediatric Patients, Gastrostomy, Dr. Pavel Kohout (Ed.), ISBN: 978-953-307-365-1, InTech, Available from:

<http://www.intechopen.com/books/gastrostomy/percutaneous-endoscopic-gastrostomy-in-pediatric-patients>

INTECH

open science | open minds

InTech Europe

University Campus STeP Ri
Slavka Krautzeka 83/A
51000 Rijeka, Croatia
Phone: +385 (51) 770 447
Fax: +385 (51) 686 166
www.intechopen.com

InTech China

Unit 405, Office Block, Hotel Equatorial Shanghai
No.65, Yan An Road (West), Shanghai, 200040, China
中国上海市延安西路65号上海国际贵都大饭店办公楼405单元
Phone: +86-21-62489820
Fax: +86-21-62489821

© 2011 The Author(s). Licensee IntechOpen. This is an open access article distributed under the terms of the [Creative Commons Attribution 3.0 License](#), which permits unrestricted use, distribution, and reproduction in any medium, provided the original work is properly cited.

IntechOpen

IntechOpen