

We are IntechOpen, the world's leading publisher of Open Access books Built by scientists, for scientists

5,000

Open access books available

125,000

International authors and editors

140M

Downloads

Our authors are among the

154

Countries delivered to

TOP 1%

most cited scientists

12.2%

Contributors from top 500 universities



WEB OF SCIENCE™

Selection of our books indexed in the Book Citation Index
in Web of Science™ Core Collection (BKCI)

Interested in publishing with us?
Contact book.department@intechopen.com

Numbers displayed above are based on latest data collected.
For more information visit www.intechopen.com



MTX Could Be First-Line Therapy Even in Cases Where hCG Level is Greater than 5,000 IU/ml

Yoshiki Yamashita et al.*

*Department of Obstetrics and Gynecology, Osaka Medical College
Japan*

1. Introduction

Ectopic pregnancy (EP) accounts for approximately 75% of deaths in the first trimester, and 9% of all pregnancy-related deaths are the result of EP.

Recently, EP can be diagnosed accurately at a very early stage using transvaginal ultrasound and serum hCG measurement (1). Methotrexate (MTX) is in a class of drugs known as folic acid antagonists, and folic acid is an essential component in the synthesis of DNA precursors such as purines and thymidylate. MTX was originally used to treat cancer, trophoblastic disease, psoriasis, and rheumatoid arthritis; however, since 1982, it has been used to successfully treat EP (2). Treatment with MTX now reportedly achieves results comparable to surgery for the treatment of appropriately selected ectopic pregnancies and is now commonly used (3). The American Society of Reproductive Medicine (ASRM) introduced the relative and absolute contraindications to MTX therapy, as indicated in Table 1 and 2 (4, 5). Lipscomb et al reported that the rate of success with MTX is relatively low in cases where serum hCG levels are higher than 5,000 IU/ml (Table 3) (6), however, MTX treatment has recently been favored in cost-effectiveness analyses. In this study, we reviewed EP cases treated with MTX regardless of high initial-hCG levels (>5,000 IU/ml) and evaluated the effectiveness of MTX by comparing them with cases where hCG levels were less than 5,000 IU/ml.

1. Embryonic cardiac activity detected by transvaginal ultrasonography
2. High initial hCG concentration (5,000>mIU/ml)
3. Ectopic pregnancy >4 cm in size as imaged by transvaginal ultrasonography
4. Refusal to accept blood transfusion
5. Inability to participate in follow-up

Table 1. Relative contraindication to MTX

*Sousuke Katoh, Yoko Yoshida, Satoe Fujiwara, Sachiko Kawabe, Mika Hayashi, Atsushi Hayashi, Yoshito Terai and Masahide Ohmichi

1. Intrauterine pregnancy
2. Evidence of immunodeficiency
3. Moderate to severe anemia, leukopenia or thrombocytopenia
4. Sensitivity to MTX
5. Active pulmonary disease
6. Active peptic ulcer disease
7. Clinically important hepatic dysfunction
8. Clinically important renal dysfunction
9. Breast feeding

Table 2. Absolute contraindication to MTX

| Initial serum hCG level(mIU/ml) | Success (n=30) | Failure (n=14) | Success rate % |
|---------------------------------|----------------|----------------|----------------|
| <1000 | 118 | 2 | 98 |
| 1000-1999 | 40 | 3 | 93 |
| 2000-4999 | 90 | 8 | 92 |
| 5000-9999 | 39 | 6 | 87 |
| 10,000-14,999 | 18 | 4 | 82 |
| ≥15,000 | 15 | 7 | 68 |

Table 3. Initial hCG level and success rate

2. Materials and method

We performed MTX treatment in 44 cases, 14 of which were high-hCG EP cases with initial serum hCG levels greater than 5,000 IU/ml. In our department, diagnosis of EP was confirmed, as shown in Figure 1. After getting informed consent for the possibility of additional surgical intervention, we administered MTX IM at a dosage of 50 mg/m². If a decline of more than 15% was not identified between days 4 and 7, an additional 50 mg/m² of MTX was administered. Weekly MTX treatment was stopped when hCG levels declined to less than 25 IU/ml (Table 4). Alteration to surgical intervention was adopted according to the patients' requirements.

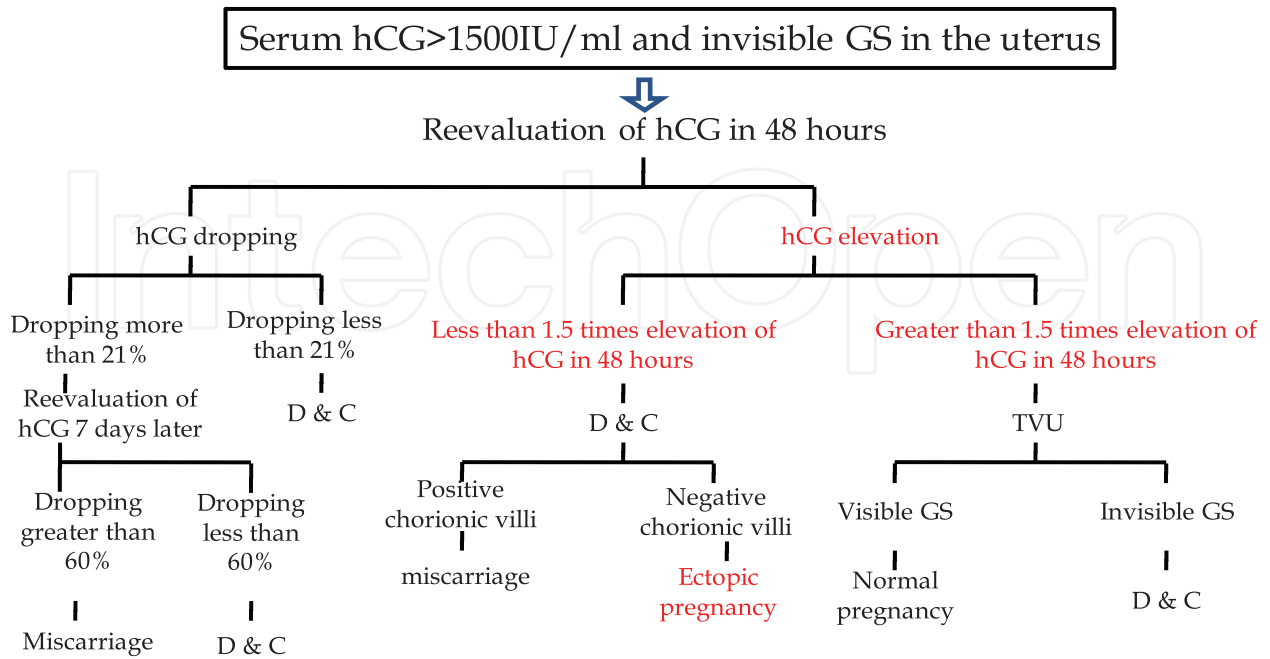


Fig. 1.

| Serum hCG (mIU/ml) | Ampurally | Interstitial | Cervical |
|--------------------|-----------|--------------|----------|
| <1000 | 12 | - | - |
| 1000-1999 | 7 | - | - |
| 2000-4999 | 11 | - | - |
| 5000-9999 | 6 | 2 | - |
| 10000-14999 | - | - | 1 |
| >15000 | 1 | 4 | - |

Table 4. Initial serum hCG and pregnancy site

3. Results

Fourteen cases of ectopic pregnancy, with initial hCG levels >5,000 IU/ml were treated with MTX. Of those 14 cases, 1 had IVF treatment, 1 undertook ovulation induction, and 12 were spontaneous pregnancies. It took 3.85 days from the initial visit to confirm the diagnosis of EP, and the average gestational week was 7.31 weeks. Hospitalization days were 13.57 days,

and MTX was administered 1.35 times. Implantation sites were 7 ampullary, 6 interstitial, and 1 cervical (Table 5). The range of initial hCG was from 5,713 to 92,670 IU/ml, and the average was 19619.7 IU/ml. More than two administrations of MTX were necessary in 2 cases, one of which was a case of persistent EP. In that case, additional dactinomycin was given. Laparoscopic surgery was adopted in one case of ampullary pregnancy, where initial hCG was 8952 IU/ml (Table 6).

In the following, we present one successful case and one difficult case where additional Actinomycin D was necessary.

| Serum hCG (mIU/ml) | Success (%) | Multiple dose | Failure (%) |
|--------------------|-------------|---------------|-------------|
| <1000 | 11(91.6) | 2 | 1(8.4) |
| 1000-1999 | 6(85.7) | 0 | 1(14.3) |
| 2000-4999 | 7(63.6) | 2 | 4(34.6) |
| 5000-9999 | 7(87.5) | 2 | 1(12.5) |
| 10000-14999 | 1(100) | 0 | 0(0) |
| >15000 | 5(100) | 2 | 0(0) |

Table 5. Clinical outcomes

| Regimen | |
|---------------|--|
| Multiple dose | Methotrxate 1 mg per kg intramuscularly, alternate days (days 1, 3, 5, 7) +leucovorin 0.1mg per kg intramuscularly, alternate days (days 2, 4, 6, 8). Continue until beta-hCG falls >15% in 48h or four doses methtorexate. If beta-hCG concentration not <40% of initial value on day 14. |
| Single dose | Methotrxate 50 mg per m ² intramuscularly. If beta-hCG is not <15% between days 4 and 7, repeat dose. Up to 4 doses can be given if beta-hCG does not decline by 15% every week. |

Table 6. Regiment of MTX

Case I

In the first case, a patient was referred to our hospital for a suspected right interstitial pregnancy. Initial serum hCG was 5979 IU/ml and clinical findings were consistent with the criteria for the diagnosis of an interstitial pregnancy. The patient selected MTX treatment because of her past history with a left salpingectomy for a right ampullary pregnancy.

Therefore, a single dose of MTX was administered. Serum hCG was followed up according to routine, and hCG declined within the normal range after a triple administration (Figure 2).

IntechOpen

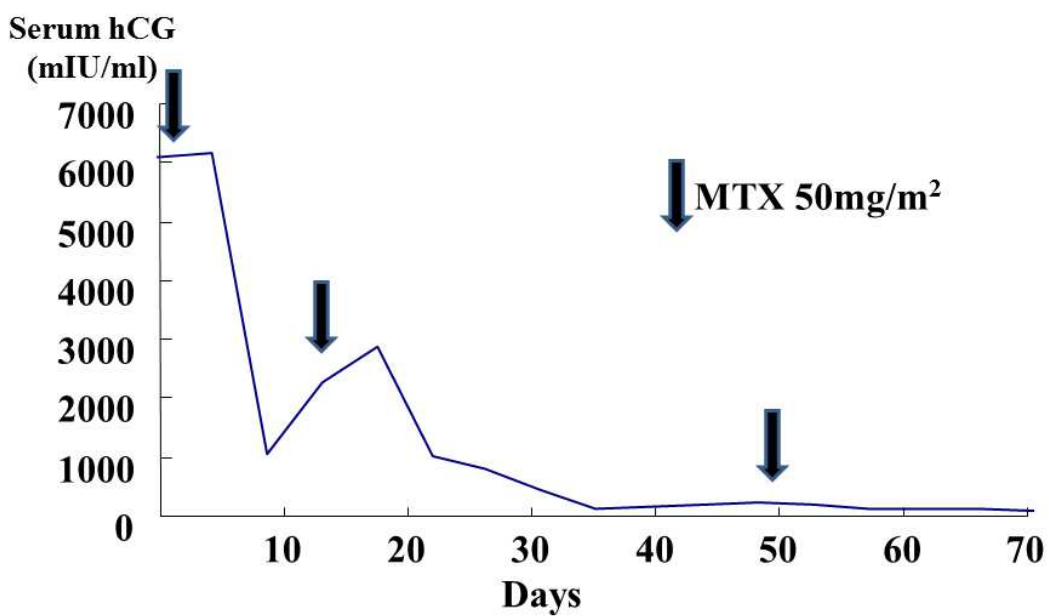


Fig. 2. Time-course of serum hCG level in Case I

IntechOpen

Case II

In the second case, the diagnosis of a right interstitial pregnancy was confirmed by MRI and a high serum hCG level of 26128 IU/ml. Twice before, the patient experienced ectopic pregnancy followed by surgical intervention so, therefore, therefore MTX treatment was started. However, her serum hCG level elevated to 172 IU/ml following three administrations of MTX following the usual single-dose regiment. Therefore, Actinomycin D at a dosage of 12 µg/kg was administered, and an MTX-resistant ectopic pregnancy was suspected (Figure 3). Post-treatment was uneventful, and the side effect of Actinomycin D and MTX was slight nausea alone.

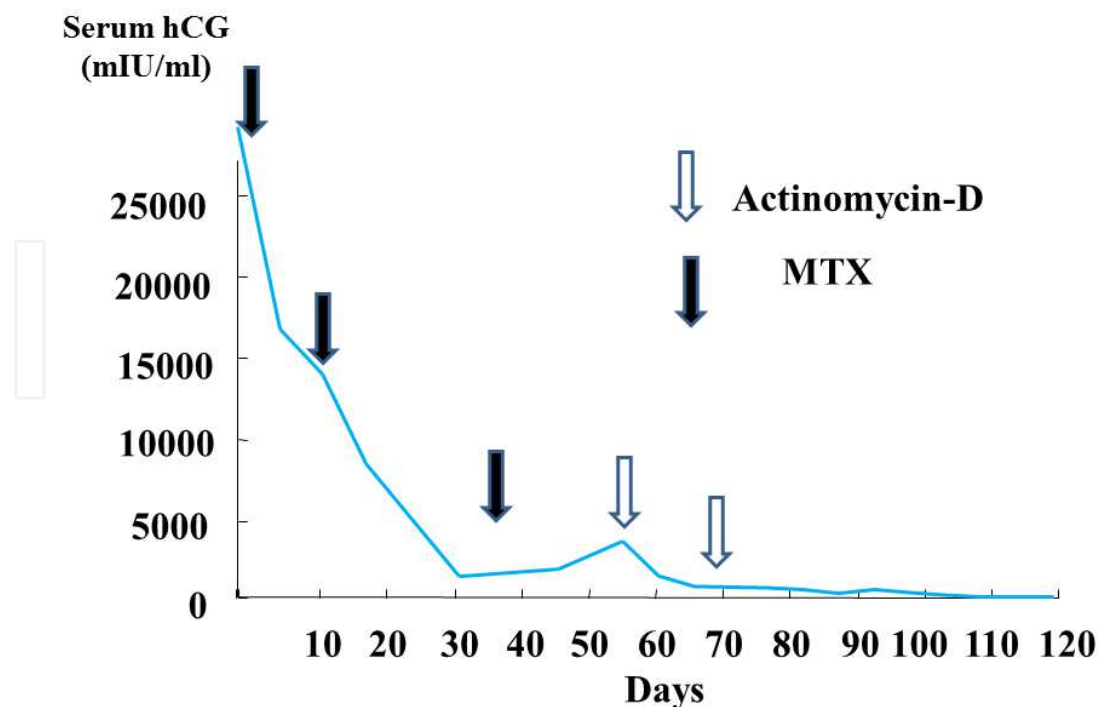


Fig. 3. Time-course of serum hCG level in Case II

4. Discussion

The treatment of EP with MTX was established in the late 1980s and has become an alternative to surgical intervention. Recently, cost-effectiveness analysis has put a priority on the patient's subsequent fertility, rather than on detection and/or complication rates, as previously reported (7-9). Effort should be made to confirm the diagnosis of ectopic pregnancy definitively before starting MTX treatment; otherwise, complication rates or costs could rise on the contrary. Seror et al reported that MTX treatment appeared to be cost-effective in EP cases where the preservation of fertility was important (10). About 40% of women with ectopic pregnancy are treated medically (11), and 90% of them are successfully treated without any surgical intervention at all (12). Medical treatment can be carried out on an outpatient basis, thus making MTX cheaper than the cost of surgical treatment. Surgical intervention is generally adopted when a high possibility of failure and a prolonged time of resolution is predicted. A particularly high serum hCG level or the presence of fetal heart movement results in medical treatment (13).

It is actually difficult to diagnose interstitial pregnancy correctly because of the slight difference between cornual implantation and interstitial pregnancy. Cornual implantation is usually identified in the upper and lateral uterine cavity, whereas interstitial ectopic pregnancy is within the proximal intramural portion of the tube. Therefore, the accurate diagnosis of an interstitial pregnancy requires precise ultrasound imaging (14). Two regimens are commonly used for the administration of MTX (15) (Table 3). The first contains the administration of MTX and leucovorin on alternate days until beta-hCG concentrations begin to drop. This regimen has a success rate of 93%. The second regimen involves the administration of a single dose of MTX, followed by repeated doses every week if beta-hCG concentrations do not fall by 15% within days 4 and 7. It has been reported that at least 13% of women require two doses, and 1% need more than two; however, more than 90% of

women who need a second administration avoid surgical intervention (12). The initial level of hCG is the best prognostic indicator of the need for MTX; however, it is still controversial as to what IU should be the cut-point in deciding whether the administration of MTX is necessary. Lipscomb et al. reported that 94% of 350 women whose initial hCG was less than 10,000 IU/ml had success with MTX treatment, therefore suggesting that an initial hCG level greater than 10,000 IU/ml was a factor in the failure of the treatment (12). On the other hand, Gamzu et al. stated that the cut-point to determine the effectiveness of MTX should be lowered to between 2000 mIU/ml and 3000 mIU/ml (16). The hCG incremental rate both before and after MTX represents an independent risk factor for subsequent tubal rupture. Pre-diagnosis concentrations of hCG which increase at least 66% over 48 hours, followed by persistently rising hCG concentrations after treatment with MTX, may lower the threshold for surgical intervention (17).

It is widely accepted that above the discriminatory zone of 1,500 IU/l-2500 IU/l, a normal intrauterine pregnancy (IUP) should be visible via TVU. At our clinic, we consider an initial hCG greater than 1500 IU/ml and an invisible GS clear indicators of a possible ectopic pregnancy, and an elevation of hCG greater than 1.5 times in 48 hours without GS confirms the diagnosis. Orivieto et al. reported that single-dose MTX treatment for EP does not have a negative effect on ovarian function nor on the outcome of following IVF-ICSI (18). Paul et al. reported that when hCG is >4000 IU/ml, the failure rate of MTX treatment is 65% (17). In this study, the MTX-failure rate of 14 cases where initial hCG was >5000 IU/ml was 7.1% (1/14); however, the failure rate of low hCG cases <5000 IU/ml was 16.6%. In tubal pregnancy, EP become less vascularized as it invades the tubal serosa, and tubal rupture is likely to occur, compared with that in interstitial pregnancy, before MTX treatment can solve the EP. Compared with cases of tubal pregnancy, the difficulty in diagnosing interstitial pregnancy is thought to be the reason why hCG levels are higher at the time of confirming the diagnosis. However, in our study, 14 cases consisted of 7 ampullary, 6 interstitial and one cervical pregnancy, indicating that tubal pregnancy does not always rupture in high-hCG cases. Therefore, more study is necessary to determine the cut-off for MTX treatment.


Recently the cost-effectiveness of treatment has been considered in attempts to save on health insurance costs. Seror reported that, although frequent diagnostic ultrasound is necessary, MTX is cost-effective compared with surgical intervention (10). However, subsequent pregnancies should be followed with extreme caution, and elective cesarean section should be considered as an alternative.

In conclusion, a serum hCG level greater than 5,000 IU/ml is not necessarily resistant to MTX treatment, and interstitial pregnancy is a particularly good candidate for conservative treatment, even if initial hCG is higher than 5,000 IU/ml. However, MTX failure and tubal rupture was identified irrespective of an initial hCG level of 800 IU/ml in tubal pregnancy. Emergent access to surgical intervention must be made available. As well, the patient's awareness of risk and her availability for admission and surgery are equally important. Therefore, preparation for surgical intervention for emergent situations, even after conservative treatment is determined, is essential.

5. References

- [1] Satoe Fujiwara, Yoshiki Yamashita, Sachiko Kawabe, Hideki Kamegai, Yoshito Terai, Masahide Ohmichi. A case of a methotrexate-resistant ectopic pregnancy in which

- dactinomycin was effective as a second-line chemotherapy. *Fertil Steril* 2009;91:929. e13-15.
- [2] Tanaka T, Hayashi H, Kutsuzawa T, Fujimoto S, Ichinoue K. Treatment of interstitial ectopic pregnancy with methotrexate : report of a successful case. *Fertil Steril* 1982;37:851-2.
- [3] Havenius PJ, Engelsbel S, Mol BW, et al. Systemic methotrexate versus laparoscopic salpingostomy in tubal pregnancy: a randomized clinical trial. *Lancet* 1997; 350:774-79.
- [4] Stovall TG, Ling FW, Buster JE. Outpatient chemotherapy of unruptured ectopic pregnancy. *Fertil Steril* 1989;51:435-8.
- [5] Pisarska MD, Crason SA, Buster JE. Ectopic pregnancy. *Lancet* 1998;351:115-20.
- [6] Lipscomb GH, Stovall TG, Ling SW. Nonsurgical treatment of ectopic pregnancy. *N Engl J Med* 2000;343:1325-9.
- [7] The practice committee of the ASRM. Medical treatment of ectopic pregnancy. *Fertil Steril* 2008;Supply 3:S206-212.
- [8] Morlock RJ, Lafata JE, Eisenstein D. Cost-effectiveness of single-dose methotrexate compared with laparoscopic treatment of ectopic pregnancy. *Obstet Gynecol* 2000;95:407-12.
- [9] Dourston WE, Carl ML, Guerra W, Eaton A, Ackerson LM. Ultrasound availability in the evaluation of ectopic pregnancy in the ED: comparison of quality and cost-effectiveness with different approaches. *Am J Emerg Med* 2000;18:408-17.
- [10] Sowter MC, Farquhar CM, Gudex G. An economic evaluation of single dose systemic methotrexate and laparoscopic surgery for the treatment of unruptured ectopic pregnancy. *BJOG* 2001;108:204-12.
- [11] Seror V, Gelfucci F, Gerbaud L, Pouly JL, Fernandez H, Job-Spira N, Bouyer J, Coste J. Care pathways for ectopic pregnancy: a population-based cost-effectiveness analysis. *Fertil Steril* 2007;87:737-748.
- [12] Barnhart KT, Gosman G, Ashby R, Sammel M. The medical management of ectopic pregnancy: meta-analysis comparing "single dose and multidose" regimens. *Obstet Gynecol* 2003;101:778-84.
- [13] Lipscomb GH, McCord ML, Stovall TG, Huff G, Portera SG, Ling FW. Predictors of success of methotrexate treatment in women with tubal ectopic pregnancies. *New Engl J Med* 1999;341:1974-8
- [14] Morlock RJ, Lafata JE, Eisenstein D. Cost-effectiveness of single-dose methotrexate compared with laparoscopic treatment of ectopic pregnancy. *Obstet Gynecol* 2000;95:407-12.
- [15] Malinowski A, Bates SK. Semantics and pitfalls in the diagnosis cornual/interstitial pregnancy. *Fertil Steril* 2006;86:e11-14.
- [16] Farquhar CM. Ectopic pregnancy. *Lancet* 2005;366:583-591.
- [17] Gamezu R, Almog B, Levin Y, Amiram a, Jaffa A, Lessing J, Baram A. Efficacy of methotrexate treatment in extrauterine pregnancies defined by stable or increasing human gonadotropin concentrations. *Fertil Steril* 2002;77:761-765.
- [18] Dudley PS, Heard MJ, Sangi-Haghpeykar H, Carson SA, Buster JE. Characterizing ectopic pregnancies that rupture despite of treatment with methotrexate. *Fertil Steril* 2004;82:1374-1378.
- [19] Orivieto R, Kruchkovich J, Zohav E, Rabinson J. Does methotrexate treatment for ectopic pregnancy influence the patient's performance during a subsequent in vitro fertilization/embryo transfer cycle? *Fertil Steril* 2007;88:1685-86.



Ectopic Pregnancy - Modern Diagnosis and Management

Edited by Dr. Michael Kamrava

ISBN 978-953-307-648-5

Hard cover, 248 pages

Publisher InTech

Published online 26, October, 2011

Published in print edition October, 2011

Ectopic pregnancy is the second major cause of maternal mortality in the United States and a leading cause of maternal morbidity and mortality in the world. This book contains the practical methods to early diagnosis of various forms of ectopic pregnancies and their modern management. Ectopic Pregnancy - Modern Diagnosis and Management is a comprehensive book which guides the reader through all features of ectopic pregnancy, both practical and academic, covering all aspects of diagnosis and management of ectopic pregnancy in a clear, concise, and practical fashion. The book is organized so that it can either be read cover to cover for a comprehensive tutorial or be kept desk side as a reference to the ectopic pregnancies. Each chapter introduces a number of related ectopic pregnancy and its diagnosis, treatment and co-morbidities supported by examples. Included chapters bring together valuable materials in the form of extended clinical knowledge from practice to clinic features.

How to reference

In order to correctly reference this scholarly work, feel free to copy and paste the following:

Yoshiki Yamashita, Sousuke Katoh, Yoko Yoshida, Satoe Fujiwara, Sachiko Kawabe, Mika Hayashi, Atsushi Hayashi, Yoshito Terai and Masahide Ohmichi (2011). MTX Could Be First-Line Therapy Even in Cases Where hCG Level is Greater than 5,000 IU/ml, Ectopic Pregnancy - Modern Diagnosis and Management, Dr. Michael Kamrava (Ed.), ISBN: 978-953-307-648-5, InTech, Available from:

<http://www.intechopen.com/books/ectopic-pregnancy-modern-diagnosis-and-management/mtx-could-be-first-line-therapy-even-in-cases-where-hcg-level-is-greater-than-5-000-iu-ml>

INTECH
open science | open minds

InTech Europe

University Campus STeP Ri
Slavka Krautzeka 83/A
51000 Rijeka, Croatia
Phone: +385 (51) 770 447
Fax: +385 (51) 686 166
www.intechopen.com

InTech China

Unit 405, Office Block, Hotel Equatorial Shanghai
No.65, Yan An Road (West), Shanghai, 200040, China
中国上海市延安西路65号上海国际贵都大饭店办公楼405单元
Phone: +86-21-62489820
Fax: +86-21-62489821

© 2011 The Author(s). Licensee IntechOpen. This is an open access article distributed under the terms of the [Creative Commons Attribution 3.0 License](#), which permits unrestricted use, distribution, and reproduction in any medium, provided the original work is properly cited.

IntechOpen

IntechOpen