

We are IntechOpen, the world's leading publisher of Open Access books Built by scientists, for scientists

5,000

Open access books available

125,000

International authors and editors

140M

Downloads

Our authors are among the

154

Countries delivered to

TOP 1%

most cited scientists

12.2%

Contributors from top 500 universities



WEB OF SCIENCE™

Selection of our books indexed in the Book Citation Index
in Web of Science™ Core Collection (BKCI)

Interested in publishing with us?
Contact book.department@intechopen.com

Numbers displayed above are based on latest data collected.
For more information visit www.intechopen.com



Myocarditis in HIV Positive Patients

Simona Claudia Cambrea

"Ovidius" University, Faculty of Medicine

Romania

1. Introduction

Myocarditis is an acute or chronic inflammatory process that affects the myocardium in response to the action of various infectious, chemical or physical agents. In most patients the disease is self-limiting. The natural course of myocarditis varies greatly, ranging from an asymptomatic state secondary to local inflammation, through development of dilated cardiomyopathy with a variable course, to fatal heart failure due to disseminated myocarditis [Subinas et al., 2005].

In patients infected with human immunodeficiency virus (HIV) cardiovascular abnormalities are frequent but clinically discrete. Cardiologists and physicians throughout the world are increasingly reporting cardiac muscle disease in association with HIV. With current advances in HIV and acquired immunodeficiency syndrome (AIDS) management and increased survival, cardiac manifestations of HIV disease including HIV related myocardial disease will become more important and will be encountered more frequently. Because cardiac complications in HIV positive patients are often clinically inapparent, periodic screening of these patients is recommended, especially in those with low CD4 counts or receiving treatment with cardiotoxic drugs. The heart may be a marker of the HIV infected patient's overall health, and a decline in cardiac function should trigger more comprehensive evaluation. As the role of infection and inflammation in many other cardiovascular diseases is now recognized, identification of the molecular mechanisms of HIV related myocarditis might have broader implications for a wide range of patients [Azis F et al., 2010].

The diagnosis of myocarditis in HIV positive patients during an acute episode may prove difficult, due to the lack of diagnostic techniques with acceptable degrees of specificity and sensitivity. For these patients although endomyocardial biopsy is still considered the diagnostic gold standard, the developments of new imaging techniques, such as cardiac magnetic resonance imaging (CMR), and nuclear imaging by antimyosin scintigraphy have contributed greatly to the diagnosis of myocarditis.

2. Myocarditis in HIV positive patients

HIV infection and AIDS have a well-recognized association with myocarditis and dilated cardiomyopathy [Azis F et al., 2010]. This increased predisposition is multifactorial and may include the direct effects of HIV itself, co-infection by opportunistic organisms, toxic effects of commonly used medications or illicit drugs, and nutritional deficiencies [Azis F et al., 2010]. Further, autoimmunity can be an important contributor to the pathogenesis of cardiomyopathy in these patients as many studies demonstrated the presence of cardiac-

specific antibodies in HIV positive patients when compared with HIV negative controls [Currie & Boon 2003, Currie et al., 1998]. Thus, although the precise mechanisms are poorly understood, alterations in the immune system likely play an important role in the pathogenesis of heart muscle disease in HIV-infected patients. The prevalence of myocarditis in HIV infected patients has been difficult to establish with estimates ranging from 6% [Barbaro et al., 1998b] to 52% [Levy et al., 1989]. In other studies about 10 percent of people with HIV develop myocarditis, either because HIV directly invades the heart muscle or because the patient's weakened immune system makes the heart muscle more susceptible to attack by other infectious agents, especially toxoplasmosis [Grange et al., 1990, Matturi et al., 1990].

HIV deserves special mention because it seems to function differently than other viruses. HIV-1 glycoprotein 120 can directly disrupt cardiac contractility without any inflammatory response [Currie & Boon, 2003]. This may explain why HIV genomes can be amplified from patients without histologic signs of inflammation. Myocarditis is the most commonly cardiac abnormality found on biopsy tissue, present in some degree, in more than 50% of HIV patients [Howes et al., 2010]. In addition, in patients who are infected with HIV, T-cell - mediated immune suppression increases the risk of contracting myocarditis due to other infectious causes [Howes et al., 2010].

2.1 Etiology

The actual pathogenesis of cardiac injury in HIV infection is not clear. It is however generally agreed that several factors come into play either singly or in combination to produce cardiac pathology [Aziz 2010]. There is a wide range of hypotheses regarding the pathogenesis of HIV associated heart muscle disease. These include myocardial invasion with HIV itself, opportunistic infections, viral infections, and autoimmune response to viral infection, drug-related cardiac toxicity, nutritional deficiencies, endothelial dysfunction, autonomic dysfunction, and prolonged immunosuppression. Zidovudine (AZT), an antiretroviral drug used in treatment of HIV, has also been associated with myocarditis [Herskowitz et al., 1992a].

Opportunistic infections are common complications of AIDS and the most frequent cause of morbidity and mortality. However, relatively few pathogens have been isolated from the myocardium of AIDS patients [Olson 2003]. Myocardial involvement is usually associated with disseminated disease and multiple foci of infection. Typically, infectious organisms are identified in patients dying of noncardiac causes, and the findings of myocardial abnormalities are regarded as incidental. Opportunistic pathogens represent diverse causes of infectious disease, including bacteria, fungi, protozoa, and viruses [Olson 2003].

Toxoplasma gondii (T gondii) is the most frequently documented infectious cause of myocarditis associated with AIDS, and the heart is the second most common site of infection after the brain. Autopsy series have described T gondii myocarditis (myocardial toxoplasmosis) in 1% to 16% of patients dying of AIDS [Baroldi et al., 1988, Anderson et al., 1988, Matturi et al., 1990]. Evidence of myocardial toxoplasmosis includes trophozoites or pseudocysts in myocardial fibers. A minority of cases has associated myocarditis with focal areas of necrosis and lymphocytic infiltrates [Jautzke 1993]. Antemortem diagnosis of toxoplasma myocarditis associated with left ventricular (LV) dysfunction has been described, including its successful treatment [Grange et al., 1990, Albrecht et al., 1994].

Pericardial tuberculosis has been reported in association with AIDS, typically in the setting of widespread disease. However, myocardial tuberculosis appears rare [Miller-Catchpole et al., 1989, Kinney et al., 1989].

Fungal myocarditis is an unusual complication of disseminated infection that is identified most often at autopsy [Olson 2003]. Various fungal organisms identified in the myocardium at autopsy with associated myocarditis have included *Aspergillus fumigatus*, *Candida albicans*, *Histoplasma capsulatum*, *Coccidioides immitis*, and *Cryptococcus neoformans*. Cardiac cryptococcus has been diagnosed in association with congestive heart failure and shown to resolve after therapy with amphotericin B and flucytosine [Kinney et al., 1989, Lewis et al., 1985, Lafont et al., 1987].

Several viruses have been implicated in myocarditis associated with AIDS. Cytomegalovirus (CMV) is a common opportunistic pathogen in AIDS, but it is associated less frequently with myocarditis [Michaels et al., 1997]. When inclusion bodies are the criterion for the detection and diagnosis of solid organ involvement by CMV, the rate of infection is underestimated compared to in situ DNA hybridization techniques [Wu et al., 1992, Myerson et al., 1984].

Other viruses identified by culture or polymerase chain reaction (PCR) within the myocardium of HIV-infected or AIDS patients, either at antemortem endomyocardial biopsy or from autopsy material, have included Epstein-Barr and coxsackie B virus in adults [Barbaro et al., 1988a] and adenovirus in children [Bowles et al., 1999]. These viruses may be present as either primary infection or as coinfection and can occur with or without associated myocarditis and with or without associated LV dysfunction.

2.2 Pathogenesis

The first clinical report to suggest a relationship between nonspecific myocarditis and dilated cardiomyopathy in AIDS patients appeared in 1986 [Cohen et al., 1986]; 3 patients had clinical, echocardiographic, and pathologic findings of dilated cardiomyopathy and 2 of the patients had focal lymphocytic infiltration associated with myocyte necrosis. Subsequent reports suggested an association between focal nonspecific myocarditis at autopsy and clinical cardiomyopathy [Barbaro et al., 1998a, Reilly et al., 1988]. Numerous hypotheses have been suggested to account for the etiology of nonspecific myocarditis and cardiomyopathy observed in HIV-infected patients, including direct HIV-1 infection of myocardial cells or coinfection with other cardiotropic viruses, [Olson 2003] cytokine cardiotoxicity [Suffredini et al., 1989, Lahdevirta et al., 1988, Levine et al., 1990], postviral cardiac autoimmunity [Herskowitz et al., 1989, 1993], nutritional deficiencies [Olson 2003], and cardiotoxicity due to illicit drugs [Olson 2003] or pharmacologic agents [Herskowitz et al., 1992a, Olson 2003].

The histologic findings of a monoclonal or oligoclonal inflammatory cellular infiltrate suggest a viral or autoimmune cause for the myocarditis associated with HIV infection. Myocarditis is more likely in individuals with more profound immunosuppression because CD4 < 400 cells/ μ L is more frequently observed in patients with dilated cardiomyopathy [Barbaro et al., 1998b]. In this same series, inflammatory myocardial cellular infiltrates were predominantly CD3 lymphocytes in 12 patients and CD8 lymphocytes in 64 patients. A separate report [Herskowitz et al., 1992b] described 35 HIV-infected patients with global LV dysfunction who underwent endomyocardial biopsy in which active or borderline myocarditis was observed in 55% of patients. For those patients with biopsy-proven myocarditis, mean LV ejection fraction was 28% whereas for patients without myocarditis it was 48%. The cellular infiltrate was primarily composed of CD8 T lymphocytes.

Although it has been suspected that myocarditis and cardiomyopathy associated with HIV-1 infection may be caused by direct viral infection of myocytes, definite evidence for this is lacking. Difficulty in demonstration of a link among HIV-1 infection, myocarditis, and cardiomyopathy in AIDS is related, in part, to lack of a suitable *in vivo* model of the disease. Because of the limited host range of HIV-1 and the difficulty in handling nonhuman primates infected with simian immunodeficiency virus-1, little investigation has been reported of myocarditis or cardiomyopathy associated with AIDS in animal models [Lewis et al., 2000].

What is the potential for direct myocardial infection? HIV-1 invades T cells by attachment to a CD4 surface-membrane receptor. However, there are no CD4 receptors on myocyte surface membranes. It is possible that the virus gains access to myocytes by other mechanisms, although the evidence to support this concept is limited. It is also possible that injury to myocytes may facilitate entry of the HIV virion; Epstein-Barr virus (EBV) promotes entry of HIV into CD4 receptor negative cells, with subsequent replication [Olson 2003].

The presence of viral genomic material within the myocytes of HIV-infected patients with myocarditis and cardiomyopathy does not definitely establish viral infection as causal. Furthermore, the significance of the finding of viral transcripts within cells is uncertain because patients may or may not have LV dysfunction [Herskowitz et al., 1993]. HIV-1 genomic material reportedly was detected within the genome of myocardial cells, although typically the findings have been sparse and may not have represented myocyte infection because the HIV nucleic acid sequence may actually have been located in endothelial cells or macrophages [Grody et al., 1990, Lipshultz et al., 1990, Flomenbaum et al., 1989, Cenacchi et al., 1990].

In one study, in 58 of 63 patients with AIDS, LV dysfunction, and biopsy-proven nonspecific lymphocytic myocarditis, a positive hybridization signal was observed but staining was weak and affected myocytes were generally not surrounded by inflammatory cells [Barbaro et al., 1998a].

In adults with AIDS-associated myocarditis, non-HIV viruses or viral genomic material identified in myocardial tissue has included CMV, Coxsackie virus group B, and EBV [Barbaro et al., 1998b, Wu et al., 1992]. In an autopsy study of 32 children who died with advanced HIV disease, including 23 with histologic evidence of myocarditis, viral sequences detected by polymerase chain reaction included adenovirus in 6, CMV in 3, and both adenovirus and CMV in 2. No other viruses were detected by polymerase chain reaction, including HIV [Bowles et al., 1999].

A high proportion of HIV-seropositive patients with LV dysfunction have evidence of latent infection of myocytes with CMV immediate-early genes [Wu et al., 1992]. Although observation of the intranuclear inclusions of active, lytic CMV infection is unusual, it has been suggested that latent viral infection may promote enhanced major histocompatibility complex expression, thereby provoking immune-mediated injury typical of animal models of myocarditis [Wu et al., 1992].

Immune-mediated mechanisms other than direct myocardial viral infection may account for the cellular infiltrates and cardiomyopathy observed in AIDS patients. Studies performed by Herskowitz demonstrated circulating autoantibodies in 4 of 6 AIDS patients with cardiomyopathy, whereas AIDS patients without cardiomyopathy did not have these antibodies [Herskowitz et al., 1989]. In the patients with autoantibodies, antimyosin antibodies were identified. In these same individuals, no evidence of HIV-1 or other viruses was identified from myocardial biopsy specimens evaluated by *in situ* hybridization,

lending support to an autoimmune mechanism of disease. A study by Gu et al. [Gu et al., 1992] used monoclonal antibodies to HIV core proteins that reacted with myocyte antigens in 38 of 42 AIDS patients (and 11 of 28 non-AIDS patients), suggesting antibodies occurring in AIDS patients may react with antigenic epitopes of myocytes, thereby promoting autoimmune-mediated heart muscle disease.

Multiple cytokines are suspected of having a role in the mediation of myocardial inflammation, myocyte necrosis and ventricular dysfunction in myocarditis, although specifics are incompletely understood in human disease [Liu et al., 2001]. The mononuclear cells characteristic of lymphocytic myocarditis, including the focal nonspecific myocarditis of AIDS, are a likely source of cytokines that promote inflammation and maintenance of immune response, which may lead to impaired contractile function and fibrosis. Matsumori et al. 1994 showed that patients with myocarditis have markedly increased concentrations of cytokines, including tumor necrosis factor alfa (TNF- α) and interleukin -1 and -6. In animal models of myocarditis, similar profiles of cytokine activation have been described and have been demonstrated directly in cardiac tissue [Yamada et al., 1994]. TNF- α has been demonstrated to be a negative inotrope [Suffredini et al., 1989] and is increased in patients with congestive heart failure [Sharma et al., 2000], AIDS [Odeh et al., 1990, Yamamoto et al., 1995], and myocarditis [Matsumori et al., 1994]. HIV may cause myocyte injury by an "innocent bystander destruction" mechanism, as may occur in AIDS-associated encephalitis [Ho et al., 1987]. However, whether these mechanisms operate in the myocarditis and dilated cardiomyopathy of AIDS is unknown.

Three histological patterns of myocarditis have been described in patients with AIDS:

- lymphocytic infiltration with myocyte necrosis [Anderson et al., 1988], which meets the Dallas criteria;
- lymphocytic infiltration without inflammation [Lewis et al., 1992];
- myocyte damage without evidence of inflammatory infiltrate [Lafontet al., 1987].

2.3 Clinical manifestation

Clinical presentation of HIV associated myocarditis in symptomatic patients is generally similar to myocarditis due to other causes. The absence of symptoms and signs of heart disease does not however exclude cardiac involvement, as occurrence of sub-clinical cardiac abnormalities with possible fatal consequences in this population has been described [Kaminski et al., 1990]. Diagnosis requires the possibility of cardiac involvement to be constantly in mind and symptoms associated with myocarditis are varied, and relate either to the actual inflammation of the myocardium, or the weakness of the heart muscle that is secondary to the inflammation. Signs and symptoms of myocarditis include: **chest pain** (often described as "stabbing" in character); **congestive heart failure** (leading to edema, breathlessness and hepatic congestion); **palpitations** (due to arrhythmias); **sudden death** (in young adults, myocarditis causes up to 20% of all cases of sudden death); **fever** (especially when infectious); symptoms in infants and toddlers tend to be more non-specific with generalized malaise, poor appetite, abdominal pain, chronic cough. Later stages of the illness will present with respiratory symptoms with increased work of breathing and is often mistaken for asthma.

Since myocarditis is often due to a viral illness, many patients give a history of symptoms consistent with a recent viral infection, including fever, rash, diarrhea, joint pains, and frequent fatigue.

Myocarditis is often associated with pericarditis, and many patients present with signs (pericardial friction rub) and symptoms that suggest concurrent myocarditis and pericarditis.

2.4 Diagnostic

Myocarditis refers to an underlying process that causes inflammation and injury of the heart. It does not refer to inflammation of the heart as a consequence of some other insult. Many secondary causes, such as a heart attack, can lead to inflammation of the myocardium and therefore the diagnosis of myocarditis cannot be made by evidence of inflammation of the myocardium alone.

Myocardial inflammation can be suspected on the basis of electrocardiographic (ECG) results, elevated C-reactive protein (CRP) and/or erythrocyte sedimentation rate (ESR) and increased IgM (serology) against viruses known to affect the myocardium. Markers of myocardial damage (troponin or creatine kinase cardiac isoenzymes) are elevated.

The difficulty in diagnosing myocarditis lies in the known absence of specificity and sensitivity of the various diagnostic techniques used. Systematic biochemical measurements are not diagnostic and an increase in cardiotropic virus antibodies only reflects the response to a recent viral infection, but does not indicate active myocarditis. Endomyocardial biopsy, considered to be the diagnostic gold standard, is associated with a not inconsiderable risk of injury, as well as with sampling errors due to the focal involvement of the myocardium, which therefore reduces its diagnostic sensitivity. Radioactive isotope studies, widely used for the diagnosis of myocarditis, are limited by their low specificity, the exposure to radiation, and their cost [Subinas et al. 2005].

2.4.1 Physical examination

Physical findings of myocarditis can range from a normal examination, through all classes of congestive heart failure (CHF) to cardiovascular collapse and shock. Patients with mild cases of myocarditis have a nontoxic appearance and simply may appear to have a viral syndrome. Tachypnea and tachycardia are common. Tachycardia is often out of proportion to fever [Howes 2010].

More acutely ill patients have signs of circulatory impairment due to left ventricular failure. A widely inflamed heart shows the classic signs of ventricular dysfunction including the following: jugular venous distention, bibasilar crackles, ascites and peripheral edema.

Third heart sound (S_3) or a summation gallop may be noted with significant biventricular involvement. Intensity of the first heart sound (S_1) may be diminished. S_3 generally occur between 0.12 and 0.24 second after the aortic component of the second heart sound. Clinically, the third heart sound (S_3 gallop) may be a physiologic sound in children and young adults. It may be produced by factors that generate increased rate or volume of flow with high cardiac output or by conditions associated with cardiac dilatation and altered ventricular compliance, as in CHF [Smiteman TC and Willerson JT, 2007].

Cyanosis may occur. Murmurs of mitral or tricuspid regurgitation may be present due to ventricular dilation [Howes 2010].

In cases where a dilated cardiomyopathy has developed, signs of peripheral or pulmonary thromboembolism may be found [Howes 2010].

Diffuse inflammation may develop leading to pericardial effusion, without tamponade, and pericardial and pleural friction rub as the inflammatory process involves surrounding structures [Howes 2010].

2.4.2 Invasive techniques

Cardiac angiography: This is often indicated to rule out coronary ischemia as a cause of new-onset heart failure, especially when clinical presentation mimics acute myocardial infarction. It usually shows high filling pressures and reduced cardiac outputs [Tang et al., 2009].

The gold standard is still **biopsy of the myocardium**, generally done in the setting of angiography. A small tissue sample of the endocardium and myocardium is taken, and investigated by a pathologist by light microscopy and—if necessary—immunochemistry and special staining methods [Cunningham et al., 2006]. Histopathological features are: a myocardial interstitium with abundant edema and inflammatory infiltrate, rich in lymphocytes and macrophages. Focal destruction of myocytes explains the myocardial pump failure. The need for routine myocardial biopsy in patients with HIV is controversial and associated risks are significant – sensitivity is low, especially in patchy lesions, and beyond research protocols, its use is limited to patients with extensive cardiac damage with no identifiable cause [Wu et al., 1990].

Myocarditis identified at autopsy or on endomyocardial biopsy in HIV-infected patients is most often nonspecific and manifested as focal, inflammatory lymphocytic infiltrates without myocyte necrosis. Other reported histopathologic findings include lymphocytic infiltration with myocyte necrosis fulfilling the Dallas criteria or myocyte damage without associated cellular inflammatory infiltrate [Anderson et al., 1988, Barbaro et al., 1998]. The autopsy finding of focal myocarditis in many patients who die of AIDS-related complications, but have no known premortem heart disease, suggests that focal lymphocytic infiltration may have no clinical significance. By comparison, diffuse lymphocytic myocarditis meeting the Dallas criteria appears rare [Anderson et al., 1988].

The prevalence of nonspecific myocarditis is related to the stage of HIV infection and the presence of structural heart disease. In one study of HIV-infected patients with a premortem diagnosis of dilated cardiomyopathy, histologic findings consistent with lymphocytic myocarditis by the Dallas criteria were identified in 63 of 76 patients (83%) [Barbaro et al., 1998].

2.4.3 Non-invasive techniques

Electrocardiography (ECG) is a useful screening tool in patients with HIV infection, and ECG changes may precede echocardiographic abnormalities. Patients with abnormal ECG patterns should be further investigated [Tang et al., 2009].

Electrocardiography is often nonspecific (eg, sinus tachycardia, nonspecific ST or T-wave changes). Occasionally, heart block (atrioventricular block or intraventricular conduction delay), ventricular arrhythmia, or injury patterns with ST- or T-wave changes mimicking myocardial ischemia or pericarditis (pseudoinfarction pattern) may indicate poorer prognosis [Gorgels 2007].

A chest X-ray can offer data about the size and shape of heart, as well as identification of fluid in or around the heart that might indicate heart failure [Round 2007].

Echocardiography has been shown to be extremely useful for the diagnosis and monitoring of HIV associated myocardial disease. Echocardiography is performed to exclude other causes of heart failure (eg, valvular, amyloidosis, congenital) and to evaluate the degree of cardiac dysfunction (usually diffuse hypokinesis and diastolic dysfunction). It also may allow gross localization of the extent of inflammation (ie, wall motion abnormalities, wall thickening, and pericardial effusion). In addition, echocardiography may distinguish

between fulminant and acute myocarditis by identifying near-normal left ventricular diastolic dimensions and increased septal thickness in fulminant myocarditis (versus increased left ventricular diastolic dimensions and normal septal thickness in acute myocarditis), with marked improvement in systolic function in time [Tang et al., 2009].

De Castro et al., in 1994 performed a study of 136 HIV-infected patients without clinical, electrocardiographic or echocardiographic evidence of cardiovascular dysfunction on admission who were prospectively studied with serial echocardiograms; 93 of these patients had AIDS. During a mean follow-up period of 415 days, seven patients, all in the AIDS subgroup, developed clinical and echocardiographic findings of acute global left ventricular dysfunction; six of these seven patients died of congestive heart failure. Necropsy findings in five of these patients revealed acute lymphocytic myocarditis in three, cryptococcal myocarditis in one, and interstitial edema and fibrosis in one.

Cardiac computed tomography (CT) can have a role in the management of the undifferentiated heart failure patient, principally in excluding the presence of significant obstructive epicardial disease using CT angiography. Current generation 64-slice scanners demonstrate excellent diagnostic accuracy for both proximal coronary vessels and smaller distal vessels [Leber et al., 2005, Raff et al., 2005, Fine et al., 2006]. These recent studies especially demonstrate a high (greater than 95%) negative predictive value for the exclusion of significant epicardial stenosis.

Hence, although it has not been prospectively evaluated in the newly diagnosed heart failure population, the data would indicate that this modality can be used to stratify the patient with heart failure into an ischemic or non-ischemic etiology group.

Cardiac MRI (CMR) shows the accumulation of contrast in the myocardium as a consequence of the breakdown of the myocyte membrane resulting from the inflammatory process. The uptake of contrast usually has a characteristic patchy pattern for about the first 2 weeks after the acute event, later becoming progressively more disseminated. [Friedrich 1998] Moreover, this pattern of contrast uptake is easily distinguished from the subendocardial pattern of uptake seen in acute myocardial infarction.

CMR with contrast in association with cine-MRI is a useful tool for the diagnosis of myocarditis and provides an alternative to endomyocardial biopsy.

The availability of this diagnostic technique in the context of an acute episode might obviate the use of other, invasive diagnostic techniques which are not exempt from associated disease.

Roditi et al., in 2000 evaluated 20 patients with T1 spin-echo cine MR angiography and gadolinium-enhanced spin-echo imaging. Focal myocardial enhancement was associated with regional wall motion abnormalities in 10 of the 12 patients with suspected or proven myocarditis. The authors concluded that focal myocardial enhancement combined with regional wall motion abnormalities (hypokinesis, akinesis, or dyskinesis) strongly supported a diagnosis of myocarditis.

A combined CMR approach using T2-weighted imaging and contrast-enhanced T1-weighted images yields high diagnostic accuracy and thus, is a useful tool in the diagnosis and assessment of patients with suspected acute myocarditis [Abdel-Aty et al., 2005]. Friedrich et al. in 1998 were the first to propose CMR for the noninvasive diagnosis of acute myocarditis. Using T1-weighted images, they found that the myocardium in patients with suspected myocarditis has greater signal intensity relative to skeletal muscle [Friedrich et al., 1998]. T2-weighted images early after symptom onset can show focal increases of subepicardial and mid-wall myocardial signal, defining areas of myocardial edema [Abdel-

Aty et al., 2005]. Late gadolinium enhancement (LGE) - CMR has been shown to have additional value in the detection of active myocarditis as defined by histopathology [Mahrholdt et al., 2004].

LGE in the setting of myocarditis has a “nonischemic” pattern, typically affecting the subepicardium and the midmyocardial wall. This focal enhancement becomes diffuse over a period of days to weeks, then decreases during healing and may become invisible after recovery [Mahrholdt et al., 2004]. Alternatively, large areas of scarring might still be visible after healing, causing distinctive enhancing linear mid-wall striae. CMR-guided endomyocardial biopsy can result in a greater yield of positive findings than routine right ventricular biopsy [Mahrholdt et al., 2004].

This technique has not yet been fully evaluating in asymptomatic HIV infected subjects to establish the prevalence of unrecognized myocarditis.

Nuclear imaging: Antimyosin scintigraphy (using antimyosin antibody injections) can identify myocardial inflammation with high sensitivity (91-100%) and negative predictive power (93-100%) but has low specificity (31-44%) and low positive predictive power (28-33%). In contrast, gallium scanning is used to reflect severe myocardial cellular infiltration and has a good negative predictive value, although specificity is low [Tang et al., 2009].

In preliminary studies, a positive gallium scan improved the diagnostic yield of biopsy fourfold (baseline incidence of myocarditis - 8%; incidence associated with a positive scan - 36%). Gallium is an inflammatory avid isotope, whereas antimyosin antibodies are capable of labeling myocytes. Because histologic myocarditis consists of active inflammation in the presence of myocyte necrosis, indium 111 antimyosin antibodies may be useful in detecting this condition [O'Connell 1987].

Specific outcome data in HIV infected patients are missing.

2.5 Personal contribution

In Romania as in many other developing countries over the world cardiac MRI cannot be used widely for diagnosis. In the last several years within our cohort of adolescents and young adults HIV infected since their childhood we have noticed an increased number of patients with symptoms that suggest cardiac involvement. Dilative cardiomyopathy noticed more often in children infected by HIV was diagnosed especially postmortem at necropsy. As long as these patients present an increased rate of survival we are challenged to perform accurate diagnosis of cardiac involvement during their life.

During the last 2 years we have the opportunity to evaluate 10 patients with HIV and symptoms of cardiac involvement by performing: ECG, echocardiography, and nuclear imaging using technetium 99 (^{99}Tc). The 10 patients, 5 women and 5 men, were aged between 17 and 55 years. Echocardiography demonstrated in 4 cases normal left ventricular diastolic dimensions and small increases in septal thickness and in other 6 cases increased left ventricular diastolic dimensions and normal septal thickness. From the 4 patients with minimal echocardiography changes, nuclear imaging using technetium 99 showed no wall motions disorders and no changes in myocardial perfusions in 3 patients. In one patient we found no changes in echocardiography and ECG, while myocardial scintigraphy with ^{99}Tc showed changes in wall motility (akinesia) at rest and on stress and ischemic areas at the antero-septal wall and myocardial apex (4%), while at rest the affected area by myocardial scintigraphy was about 2%, as we can noticed in figure no. 1 [Cambrea et al., 2009]. From those 6 patients who presented changes on echocardiography, nuclear imaging with ^{99}Tc 2 patients demonstrated dilatative cardiomyopathy with no ischemic area, as shown in figure

no. 2. The other 4 patients presented with dilative cardiomyopathy and ischemic areas on stress, as demonstrated in figure no. 3. All 10 patients had received HAART including protease inhibitors for at least 5 years and significant changes in lipid profile.

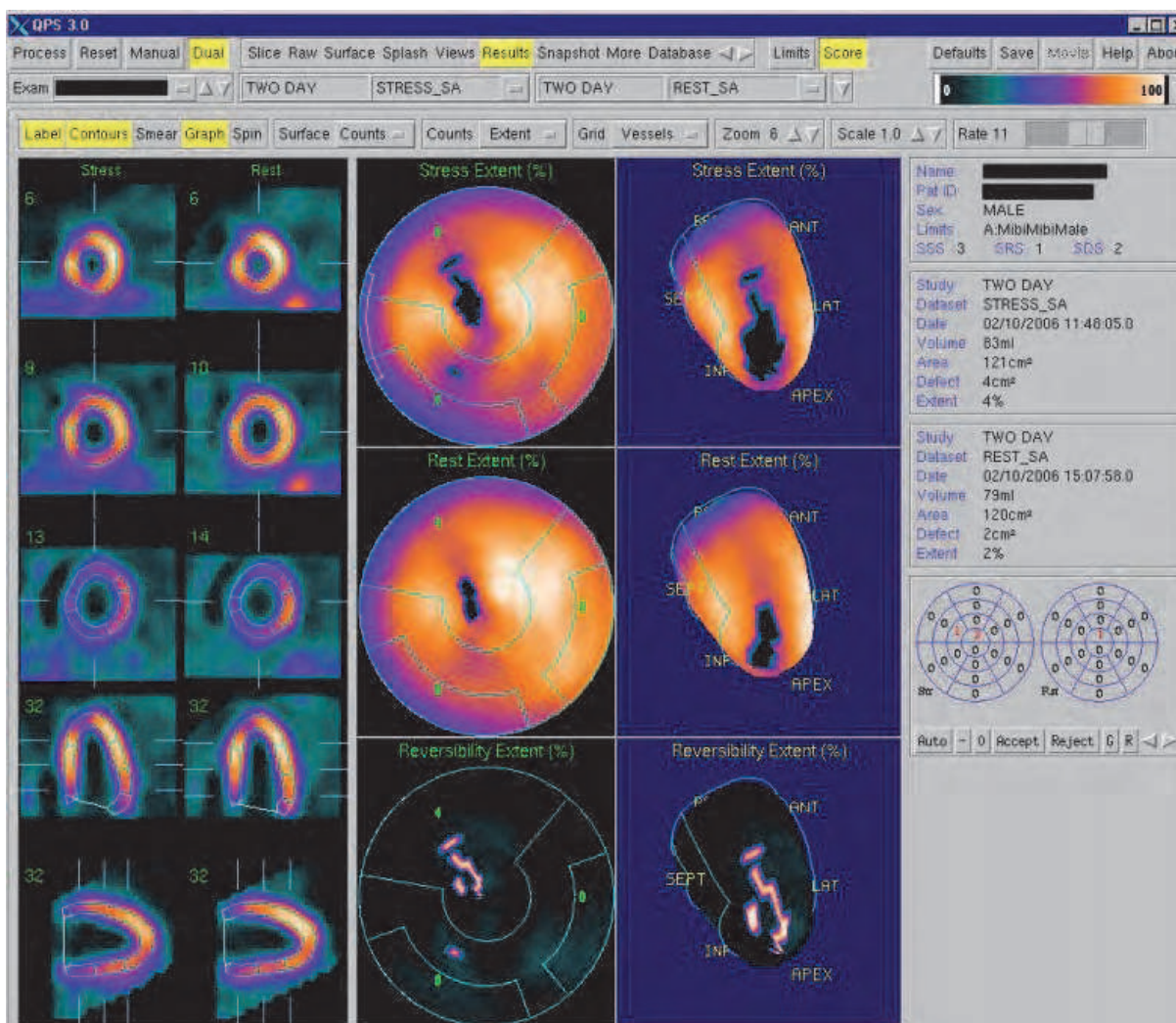


Fig. 1. Myocardial scintigraphy - ischemic areas at the antero-septal wall and myocardial apex.

2.6 Differential diagnosis of myocarditis in HIV

It is difficult to assess the clinical significance of viral infection of the myocardium in HIV-infected patients. AIDS or HIV-infected patients with myocarditis most often present with signs and symptoms of congestive heart failure or asymptomatic left ventricular dysfunction. The diagnosis of dilative cardiomyopathy in this setting is best established by echocardiography. More specific diagnosis can be established by endomyocardial biopsy, as clinically indicated. However, in the vast majority of cases endomyocardial biopsy will not identify a specific cause that will modify therapy. In a minority of patients, biopsy may establish a treatable cause of myocarditis. Therefore, the clinician should consider the specifics of each case before making a recommendation regarding whether endomyocardial biopsy is necessary [Olson 2003].

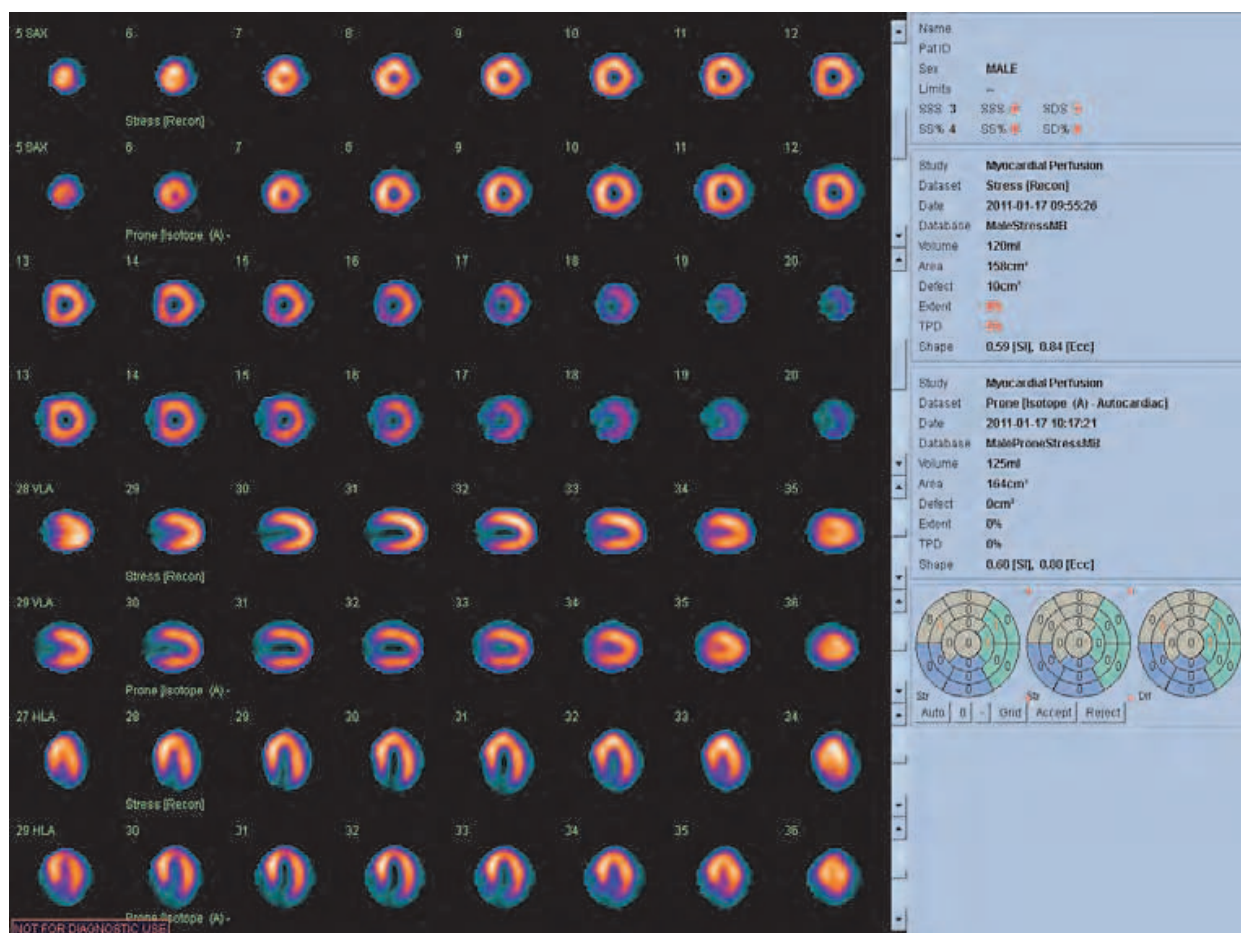


Fig. 2. Myocardial scintigraphy - dilative cardiomyopathy with no ischemic area.

Aside from nonspecific or infectious myocarditis, the differential diagnosis of LV dysfunction in the AIDS patient includes drug toxicity from either abuse of illicit substances or iatrogenic disease from agents used in the therapy for AIDS. AIDS patients often take a great variety of prescription and nonprescription drugs and use illicit drugs. Alcohol, cocaine, or heroin may contribute to LV dysfunction in many cases [Virmani et al., 1988; Regan et al., 1990; Soodini et al., 1991]. Pharmacotherapy is also potentially associated with LV dysfunction in AIDS patients. Therapeutic agents implicated as potential cardiac toxins include zidovudine [Herskowitz et al., 1992b; d'Amati et al., 1992], and interferon alfa-2 [Deyton et al., 1989; Zimmerman et al., 1994].

If neoplastic infiltration is suspected as a cause of LV dysfunction, cardiac computed tomography or magnetic resonance imaging may be a useful adjunct to echocardiography for characterizing cardiac involvement. Neoplastic infiltration of the heart by Kaposi sarcoma is frequently seen at autopsy and usually associated with widespread disease in the terminal phases of AIDS [Silver et al., 1984]. Non-Hodgkin lymphoma is also observed in this setting and also associated with widespread disease [Holladay et al., 1992].

In addition to HIV-related cardiac conditions, differential diagnosis also includes non-HIV disease, because the latency of HIV disease may be long and patients are at risk for development of hypertensive heart disease, coronary artery disease, or other causes of left ventricular dysfunction [Olson 2003].

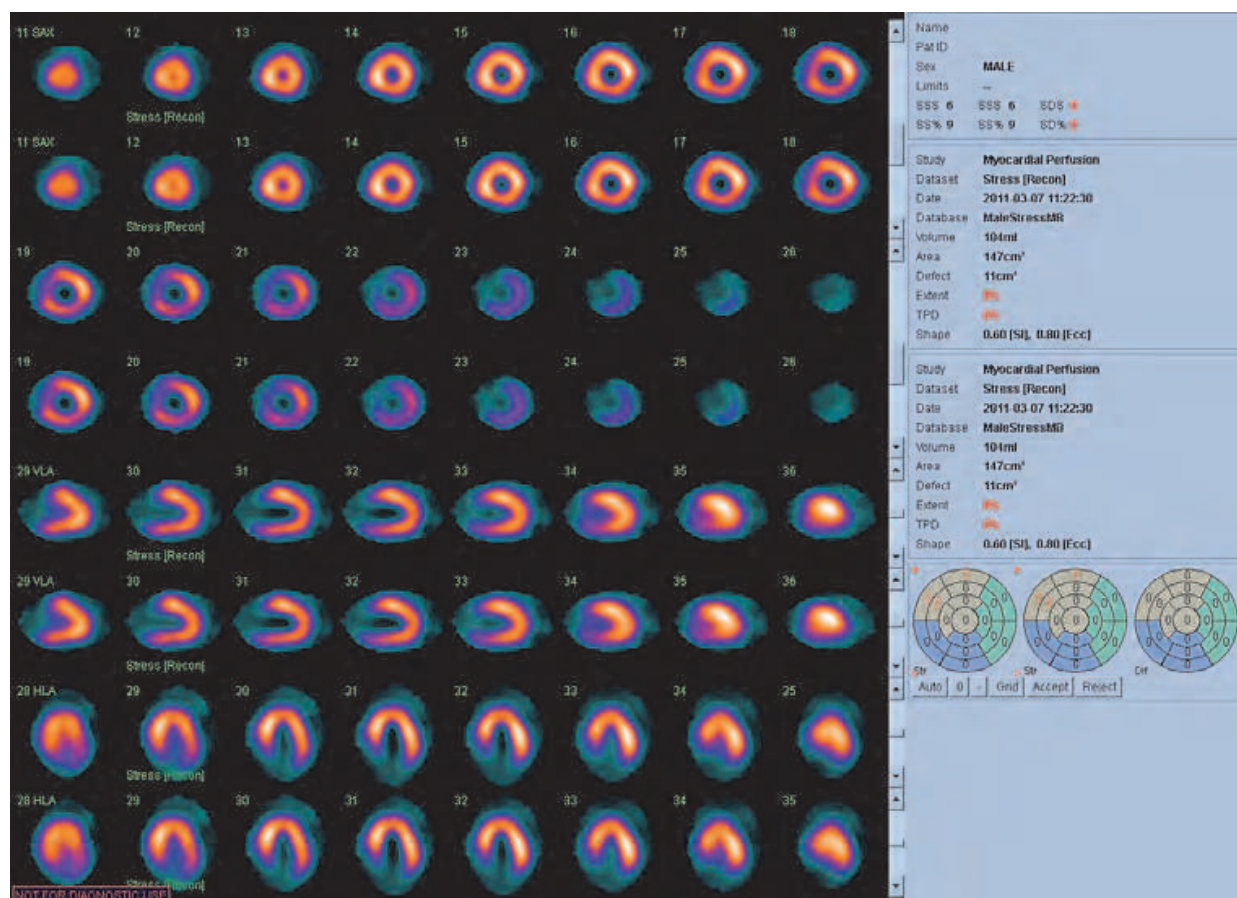


Fig. 3. Myocardial scintigraphy - dilative cardiomyopathy and ischemic areas on stress.

2.7 Treatment

Treatment for HIV related myocarditis is generally similar to that for non-HIV related myocarditis. Symptomatic treatment is the only form of therapy for HIV positive patients with myocarditis. In the acute phase, supportive therapy including bed rest is indicated. For symptomatic patients, digoxin and diuretics provide clinical improvement. For patients with moderate to severe dysfunction, cardiac function can be supported by use of inotropes such as Milrinone in the acute phase followed by oral therapy with ACE inhibitors (Captopril, Lisinopril) when tolerated. Patients who do not respond to conventional therapy are candidates for bridge therapy with left ventricular assist devices. Heart transplantation is reserved for patients who fail to improve with conventional therapy. Patients with HIV and myocarditis have enhanced sensitivity to digoxin and anticoagulation presents risks to patients with cerebral vasculopathy and possible aneurysm formation [Howes et al., 2010]. The use of immunosuppressive regimens in these patients is controversial and no convincing benefits have been reported other than with intravenous immunoglobulin [Lipshultz et al., 1995], whose efficacy may reflect inhibition of cardiac auto antibodies by competition with Fc receptors or dampened effects of cytokines and cellular growth factors. The introduction of highly active antiretroviral therapy (HAART) regimens has substantially modified the course of HIV disease by lengthening survival and improving quality of life of HIV-infected patients [Zareba & Lipshultz 2003]. There is also good evidence that HAART significantly reduces the incidence of cardiovascular manifestations of HIV infection. By preventing opportunistic infections and reducing the incidence of

myocarditis, HAART regimens have reduced the prevalence of HIV-associated myocarditis to about 30% [Barbaro 2005]. One Italian study reported an almost 7-fold reduction of the prevalence of HIV-associated myocarditis from the pre-HAART era [Pugliese et al., 2000]. In that study there is no conclusive evidence that HAART reverses cardiomyopathy, but it does appear that by preventing profound immunosuppression and the development of AIDS, heart muscle remains healthier [Pugliese et al., 2000].

3. Conclusions

Cardiac dysfunction should be considered in the differential diagnosis of any HIV-infected patient with dyspnea or cardiomegaly. In the setting of AIDS or HIV infection, the diagnosis of dilated cardiomyopathy is established by echocardiography. A significant proportion, perhaps exceeding 80%, of patients with dilated cardiomyopathy may have focal, non-specific lymphocytic myocarditis [Barbaro et al., 1998a].

Although viruses, in general, are well established as a cause of acute myocarditis, a causal role for viruses in the pathogenesis of dilated cardiomyopathy has not been demonstrated conclusively, including HIV infection.

A low CD4 count is an excellent predictor of the presence of LV dysfunction. The risk of dilated cardiomyopathy may also be increased with a history of illicit drug use [Soodini et al., 2001].

Myocarditis due to HIV-1 myocyte infection does not seem to be the most likely cause of LV dysfunction in patients with AIDS. It is more likely that the cause of LV dysfunction and congestive heart failure in this setting is multifactorial, related to drug toxicity, non-HIV viral infection, poor nutrition, or cytokines. Another situation in HIV positive patients that can cause myocarditis with or without ischemia is dyslipidemia as a consequence of highly active antiretroviral therapy that included protease inhibitor for a long period of time.

The evaluation and management of HIV positive patients with myocarditis and specific dilated cardiomyopathies remains clinically challenging. Essential to the appropriate care of these patients is not only an understanding of the patient's cardiac morphology and function but also identification of pathologic and modifiable substrate.

The ultimate proof that the patient has myocarditis is provided by endomyocardial biopsy, but the patchy nature of the disease limits its diagnostic role [Karamitsos et al., 2009].

Computed tomography or magnetic resonance imaging may help but are not widely used for diagnosis. Gadolinium-enhanced magnetic resonance imaging is used for assessment of the extent of inflammation and cellular edema, although it is still nonspecific. Delayed-enhanced MRI has also been used to quantify the amount of scarring that occurred following acute myocarditis [Al-Mallah & Kwong 2009].

By virtue of its safety, high degree of accuracy and reproducibility, and multiparametric nature, cardiac MRI represents the principal imaging modality that potentially addresses each of these points of care for heart failure patients. However, coronary CT angiography can aid in ruling out epicardial coronary artery stenosis as the cause of LV dysfunction in selected patients presenting with congestive heart failure.

In addition to clinical examination and biological evaluation, in the absence of cardiac MRI, a combination of ultrasound and scintigraphic investigations of the heart can provide sufficient data to establish myocardial dysfunction with or without ischemia.

Because cardiac CT, CMR and cardiac scintigraphy were not widely used in patients with myocarditis and in HIV cases are only sporadic presentations, to identify particular aspects

of myocarditis in HIV positive patients is necessary to extend these new investigational noninvasive methods to a large number of patients.

4. References

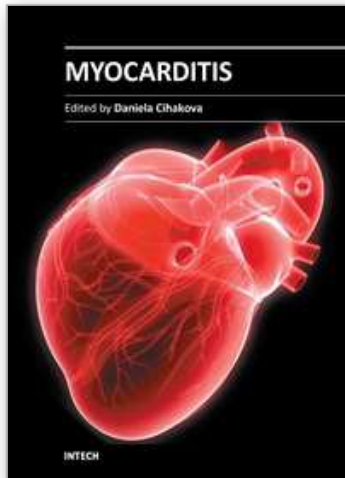
- Abdel-Aty H., et al., (2005) Diagnostic performance of cardiovascular magnetic resonance in patients with suspected acute myocarditis: comparison of different approaches. *J Am Coll Cardiol* Vol. 45, No, 11 (June 2005) pp: 1815-1822, ISSN: 0735-1097.
- Albrecht H., et al., (1994) Successful treatment of *Toxoplasma gondii* myocarditis in an AIDS patient. *Eur J Clin Microbiol Infect Dis* 1994; Vol. 13, No. 6 (June 1994) pp: 500-504, ISSN: 0934-9723.
- d'Amati G., Kwan W. & Lewis W. (1992) Dilated cardiomyopathy in a zidovudine-treated AIDS patient. *Cardiovasc Pathol*; Vol.1 No. 4 (October - December, 1992), pp: 317-320, ISSN: 1054-8807.
- Anderson D.W., et al., (1988) Prevalent myocarditis at necropsy in the acquired immunodeficiency syndrome. *J Am Coll Cardiol*; Vol. 11, No. 4, (April 1988), pp: 792-799, ISSN: 0934-9723.
- Aziz F., Doddi S. & Penupolu S. (2010) Human Immunodeficiency Virus-Associated Myocarditis. *The Internet Journal of Internal Medicine*. Vol. 8, No. 2, (2010), ISSN: 1528-8382
- Barbaro G., et al., (1998a) Cardiac involvement in the acquired immunodeficiency syndrome: a multicenter clinical-pathological study. Gruppo Italiano per lo Studio Cardiologico dei pazienti affetti da AIDS Investigators. *AIDS Res Hum Retroviruses*; Vol. 14, No. 12, (August 1998), pp: 1071-1077, ISSN: 0889-2229
- Barbaro G., et al., (1998b) Incidence of dilated cardiomyopathy and detection of HIV in myocardial cells of HIV-positive patients. Gruppo Italiano per lo Studio Cardiologico dei Pazienti Affetti da AIDS. *N Engl J Med*; Vol. 339, no. 16, (October 1998), pp: 1093-1099, ISSN: 0028-4793.
- Barbaro G. (2005) Reviewing the cardiovascular complications of HIV Infection after the introduction of highly active antiretroviral therapy. *Curr Drug Targets Cardiovasc Haematol Disord*; Vol. 5, No. 4 (August 2005), pp: 337-343, ISSN: 1568-0061.
- Baroldi G., et al., (1988) Focal lymphocytic myocarditis in acquired immunodeficiency syndrome (AIDS): a correlative morphologic and clinical study in 26 consecutive fatal cases. *J Am Coll Cardiol*; Vol. 12, No. 2 (August 1988), pp: 463-469, ISSN: 0934-9723.
- Bowles N.E., et al., (1991) The detection of viral genomes by polymerase chain reaction in the myocardium of pediatric patients with advanced HIV disease. *J Am Coll Cardiol*; Vol. 34, No. 3, (September 1999), pp: 857-865, ISSN: 0934-9723.
- De Castro S., et al., (1994) Frequency of development of acute global left ventricular dysfunction in human immunodeficiency virus infection. *J Am Coll Cardiol* Vol. 24, No. 4 (October 1994), pp: 1018-1024, ISSN: 0934-9723.
- Cambrea S.C., et al., (2009) Coronary artery disease in an HIV+ adolescent. *Archives of the Balkan Medical Union*; Vol. 44, No.2, (June 2009), pp: 157-160, ISSN: 0041-6940.
- Cenacchi G., et al., (1990). Human immunodeficiency virus type 1 antigen detection in endomyocardial biopsy: an immunomorphological study. *Microbiologica*; Vol. 13, No. 2, (April 1990); pp: 145-149, ISSN: 0391-5352.

- Cohen I.S., et al., (1986). Congestive cardiomyopathy in association with the acquired immunodeficiency syndrome. *N Engl J Med*; Vol. 315, No. 10, (September 1986), pp: 628-630, ISSN: 0028-4793.
- Cunningham K.S., Veinot J.P. & Butany J. (2006). An approach to endomyocardial biopsy interpretation, *J Clin Pathol*; Vol. 59, No. 2, (February 2006), pp:121-129, ISSN: 0021-9746.
- Currie P.F. & Boon N.A. (2003) Immunopathogenesis of HIV-related heart muscle disease: current perspectives. *AIDS*; Vol 17, Suppl. 1, (April 2003), pp:S21-S28, ISSN: 0269-9370.
- Currie P.F., et al., (1998) Cardiac autoimmunity in HIV related heart muscle disease. *Heart*; Vol. 79, No. 6, (June 1998), pp: 599-604, ISSN: 1468-201X.
- Deyton L.R., et al., (1989) Reversible cardiac dysfunction associated with interferon alfa therapy in AIDS patients with Kaposi's sarcoma. *N Engl J Med*; Vol. 321, No. 18, (November 1989), pp: 1246-1249, ISSN: 0028-4793.
- Fine J.J., et al., (2006) Comparison of accuracy of 64-slice cardiovascular computed tomography with coronary angiography in patients with suspected coronary artery disease. *Am J Cardiol*; Vol. 97, No. 2, (January 2006), pp: 173-174, ISSN: 0002-9149.
- Flomenbaum M., et al., (1989) Proliferative membranopathy and human immunodeficiency virus in AIDS hearts. *J Acquir Immune Defic Syndr*; Vol.2, No. 2, (April 1989), pp: 129-135, ISSN: 1525-4135.
- Friedrich, M.G., et al., (1998) Contrast media-enhanced magnetic resonance imaging visualizes myocardial changes in the course of viral myocarditis. *Circulation*; Vol. 97, No. 18, (May 1998), pp: 1802-1809, ISSN: 0009-7322.
- Gorgels A.P.M. (2007) - Electrocardiography in *Cardiovascular Medicine* - Willerson et al., pp: 43- 78, Springer 2007; ISBN-10: 1-84628-188-1 3rd edition, London 2007.
- Grody W.W., Cheng L. & Lewis W. (1990) Infection of the heart by the human immunodeficiency virus. *Am J Cardiol*; Vol. 66, No. 2, (July 1990), pp: 203-206, ISSN: 0002-9149.
- Gu J., et al., (1992) Evidence for an autoimmune mechanism of the cardiac pathology in AIDS patients (abstract). *Circulation*; Vol. 86, Suppl 1, (1992), pp: I-795, ISSN: 0009-7322.
- Grange F., et al., (1990) Successful therapy for *Toxoplasma gondii* myocarditis in acquired immunodeficiency syndrome. *Am Heart J*; Vol. 120, No. 2 (August 1990), pp: 443-444, ISSN: 0002-8703.
- Herskowitz A., et al., (1989) Cardiomyopathy in acquired immunodeficiency syndrome: evidence for autoimmunity (abstract). *Circulation*; Vol. 80, Suppl 2, (1989), pp: II-322, ISSN: 0009-7322.
- Herskowitz A., et al., (1993) Immunopathogenesis of HIV-1-associated cardiomyopathy. *Clin Immunol Immunopathol*; Vol. 68, No. 2 (August 1993), pp: 234-241, ISSN: 0014-2980.
- Herskowitz A., et al., (1992a) Cardiomyopathy associated with antiretroviral therapy in patients with HIV infection: a report of six cases. *Ann Intern Med*; Vol. 116, No. 4, (February 1992) pp: 311-313, ISSN: 0003-4819.
- Herskowitz A., et al., (1992b) Myocarditis associated with severe left ventricular dysfunction in late stage HIV infection (abstract). *Circulation*; Vol. 86, Suppl 1, (1992), pp:I-6, ISSN: 0009-7322.

- Cunningham K., et al., (2005) Pathologic quiz case: a young woman with eosinophilia and heart failure. Primary hypereosinophilic syndrome with Loeffler endocarditis. *Arch Pathol Lab Med*; Vol. 129, No.1, (January 2005), pp: e29-30. ISSN: 1543-2165 [Medline].
- Ho D.D., Pomerantz R.J. & Kaplan J.C. (1987) Pathogenesis of infection with human immunodeficiency virus. *N Engl J Med* Vol. 317, No. 5, (July 1987), pp: 278-286, ISSN: 0028-4793.
- Holladay A.O., Siegel R.J. & Schwartz D.A. (1992) Cardiac malignant lymphoma in acquired immune deficiency syndrome. *Cancer*; Vol. 70, No. 8, (October 1992) pp: 2203-2207, ISSN: 1097-0142.
- Howes D.S., et al., (2010) Myocarditis in Emergency Medicine Clinical Presentation Updated: Dec 8, 2010 <http://emedicine.medscape.com/article/759212-clinical>
- Jautzke G., et al., (1993) Extracerebral toxoplasmosis in AIDS. (1993) Histological and immunohistological findings based on 80 autopsy cases. *Pathol Res Pract*; Vol. 189, No. 6, (July 1993), pp: 428-436, ISSN: 0344-0338.
- Kaminski H.J., et al., (1988) Cardiomyopathy associated with the acquired immune deficiency syndrome. *J Acquir Immune Defic Syndr*; Vol. 1, No. 2, (April 1988), pp: 105-110, ISSN: 1525-4135.
- Karamitsos T.D., et al., (2009) The Role of Cardiovascular Magnetic Resonance Imaging in Heart Failure. *J Am Coll Cardiol*; Vol. 54, No. 15, (October 2009), pp: 1407-1424, ISSN: 0934-9723.
- Kinney E.L., et al., (1989) Treatment of AIDS-associated heart disease. *Angiology*; Vol. 40, No. 11, (November 1989) pp: 970-976, ISSN: 0003-3197.
- Lafont A., et al., (1987) Overwhelming myocarditis due to *Cryptococcus neoformans* in an AIDS patients. *Lancet*; Vol. 330, No. 8568 (November 14, 1987) pp: 1145-1146, ISSN: 0140-6736.
- Lahdevirta J., et al., (1988) Elevated levels of circulating cachectin/tumor necrosis factor in patients with acquired immunodeficiency syndrome. *Am J Med*; Vol. 85 complete, (1988), pp :289-291, ISSN: 0002-9343.
- Leber A.W., et al., (2005) Quantification of obstructive and nonobstructive coronary lesions by 64-slice computed tomography: a comparative study with quantitative coronary angiography and intravascular ultrasound. *J Am Coll Cardiol*; Vol. 46, No. 1 (July 2005), pp: 147-154, ISSN: 0934-9723.
- Levine B., et al., (1990) Elevated circulating levels of tumor necrosis factor in severe chronic heart failure. *N Engl J Med*; Vol. 323, No. 4, (July 1990) pp: 236-241, ISSN: 0028-4793.
- Levy W.S., et al., (1989) Prevalence of cardiac abnormalities in human immunodeficiency virus infection. *Am J Cardiol* Vol. 63, No. 1, (January 1989) pp: 86-89, ISSN: 0002-9149.
- Lewis W. & Grody W.N. (1992) AIDS and the heart: review and consideration of pathogenic mechanisms. *Cardiovasc Pathol* Vol. 1, No. 1 (Jan- March 1992), pp: 53-64, ISSN: 1054-8807.
- Lewis W., Lipsick J. & Cammarosano C. (1985) Cryptococcal myocarditis in acquired immune deficiency syndrome. *Am J Cardiol*; Vol. 55, No. 9, (April 1985), pp:1240, ISSN: 0002-9149.
- Lewis W. (2000) Cardiomyopathy in AIDS: a pathophysiological perspective. *Prog Cardiovasc Dis*; Vol. 43, No. 2 (October 2000), pp: 151-170, ISSN: 0033-0620.

- Lipshultz SE, et al., (1990) Identification of human immunodeficiency virus-1 RNA and DNA in the heart of a child with cardiovascular abnormalities and congenital acquired immune deficiency syndrome. *Am J Cardiol*; Vol. 66, No. 2, (July 1990), pp: 246-250, ISSN: 0002-9149.
- Lipshultz S.E., et al., (1995) Immunoglobulins and left ventricular structure and function in pediatric HIV infection. *Circulation*; Vol. 92, No. 8, (October 1995) pp: 2220-2225, ISSN: 0009-7322.
- Liu P.P. & Mason J.W. (2001) Advances in the understanding of myocarditis. *Circulation*; Vol. 104, No. 9, (August 2001), pp: 1076-1082, ISSN: 0009-7322.
- Mahrholdt H., et al., (2004) Cardiovascular magnetic resonance assessment of human myocarditis: a comparison to histology and molecular pathology. *Circulation*; Vol. 109, No. 10, (March 2004), pp: 1250-1258, ISSN: 0009-7322.
- Al-Mallah M. & Kwong R.Y. (2009) Clinical application of cardiac CMR. *Rev Cardiovasc Med*; Vol. 10, No. 3 (Summer 2009), pp: 134-141, ISSN: 1530-6550.
- Matsumori A., et al., (1994) Increased circulating cytokines in patients with myocarditis and cardiomyopathy. *Br Heart J*; Vol. 72, No. 6, (December 1994), pp: 561-566, ISSN: 0007-0769.
- Matturri L., et al., (1990) Cardiac toxoplasmosis in pathology of acquired immunodeficiency syndrome. *Panminerva Med*; Vol. 32, No. 3, (September 1990) pp: 194-196, ISSN: 0031-0808.
- Michaels A.D., et al., (1997) Cardiovascular involvement in AIDS. *Curr Probl Cardiol*; Vol. 22, No. 3, (March 1997), pp: 115-148, ISSN: 0146-2806.
- Miller-Catchpole R., et al., (1989) The Chicago AIDS autopsy study: opportunistic infections, neoplasms, and findings from selected organ systems with a comparison to national data. Chicago Associated Pathologists. *Mod Pathol*; Vol. 2, No. 4 (July 1989), pp:277-294, ISSN: 0893-3952.
- Myerson D., et al. (1984) Widespread presence of histologically occult cytomegalovirus. *Hum Pathol*; Vol. 15, No. 5, (May 1984), pp: 430-439, ISSN: 0046-8177.
- Odeh M. (1990) The role of tumour necrosis factor-alpha in acquired immunodeficiency syndrome. *J Intern Med*; Vol. 228, No. 6, (December 1990), pp: 549-556, ISSN: 0955-7873.
- Olson L.J. - Myocarditis Associated With Human Immunodeficiency Virus Infection and Acquired Immunodeficiency Syndrome Humana Press, Totowa, New Jersey 2003 pp: 545 - 558 in Myocarditis: From Bench to Bedside Leslie T. Cooper ISBN 1-58829-112-X/03.
- Pugliese A., et al., (2000) Impact of highly active antiretroviral therapy in HIV-positive patients with cardiac involvement. *J Infect*; Vol. 40, No. 3, (May 2000), pp: 282-284, ISSN: 0163-4453.
- Raff, G.L., et al., (2005) Diagnostic accuracy of noninvasive coronary angiography using 64-slice spiral computed tomography. *J Am Coll Cardiol*; Vol. 46, No. 3, (August 2005), pp: 552-557, ISSN: 0934-9723.
- Regan T.J. (1990) Alcohol and the cardiovascular system. *JAMA*; Vol. 264, No. 3, (July 18, 1990), pp: 377-381, ISSN: 0098-7484.
- Reilly J.M., et al., (1988) Frequency of myocarditis, left ventricular dysfunction and ventricular tachycardia in the acquired immune deficiency syndrome. *Am J Cardiol*; Vol. 62, No. 10, Part 1, (October 1988), pp: 789-793, ISSN: 0002-9149.

- Roditi G.H., Hartnell G.G. & Cohen M.C. (2000) MRI changes in myocarditis: evaluation with spin echo, cine MR angiography and contrast enhanced spin echo imaging. *Clin Radiol*. Vol. 55, No. 10, (October 2000), pp: 752-758, ISSN: 0009-9260.
- Round M.E. (2007) - Chest X- ray in *Cardiovascular Medicine* - Willerson et al., pp: 79-92, Springer, ISBN-10: 1-84628-188-1 3rd edition, London 2007.
- Silver M.A., et al., (1984) Cardiac involvement by Kaposi's sarcoma in acquired immune deficiency syndrome (AIDS). *Am J Cardiol*; Vol. 53, No. 7, (March 1984), pp: 983-985, ISSN: 0002-9149.
- Sharma R., Coats A.J. & Anker S.D. (2000) The role of inflammatory mediators in chronic heart failure: cytokines, nitric oxide, and endothelin-1. *Int J Cardiol*; Vol. 72, No. 2, (January 2000), pp: 175-186, ISSN: 0167-5273.
- Smilterman T.C. & Willerson J.T. (2007) - The history and Physical examination in *Cardiovascular Medicine* - Willerson et al., pp: 19-42, Springer, ISBN-10: 1-84628-188-1 3rd edition, London 2007.
- Soodini G. & Morgan J.P. (2001) Can cocaine abuse exacerbate the cardiac toxicity of human immunodeficiency virus? *Clin Cardiol*; Vol. 24, No. 3, (March 2001), pp: 177-181, ISSN: 0160-9289.
- Subinas A., et al., (2005) Diagnosis of Acute Myocarditis by Contrast-Enhanced Cardiac Magnetic Resonance Imaging *Rev Esp Cardiol*. Vol. 58, No. 6, (June 2005), pp: 753-755, ISSN: 0300-8932.
- Suffredini A.F., et al., (1989) The cardiovascular response of normal humans to the administration of endotoxin. *N Engl J Med*; Vol. 321, No. 5, (August 1989), pp: 280-287, ISSN: 0028-4793.
- Tang W.H.W., et al., (2009) - Myocarditis Workup, Updated: Dec 7, 2009; <http://emedicine.medscape.com/article/156330-workup>.
- Virmani R., et al., (1988) Cardiovascular effects of cocaine: an autopsy study of 40 patients. *Am Heart J*; Vol. 115, No. 9, (May 1988), pp: 1068-1076, ISSN: 0002-8703.
- Yamada T., Matsumori A. & Sasayama S. (1994) Therapeutic effect of anti-tumor necrosis factor-alpha antibody on the murine model of viral myocarditis induced by encephalomyocarditis virus. *Circulation*; Vol. 89, No. 2, (February 1994), pp: 846-851, ISSN: ISSN: 0009-7322.
- Yamamoto N. (1995) The role of cytokines in the acquired immunodeficiency syndrome. *Int J Clin Lab Res*; Vol. 25, No. 1, (March 1995), pp: 29-34, ISSN: 0940-5437.
- Wu T.C., et al., (1992) In situ detection of human cytomegalovirus immediate-early gene transcripts within cardiac myocytes of patients with HIV-associated cardiomyopathy. *AIDS*; Vol. 6, No. 8, (August 1992), pp: 777-785, ISSN: 0269-9370.
- Zareba K.M. & Lipshultz S.E. (2003) Cardiovascular complications in patients with HIV infection. *Curr Infect Dis Rep*; Vol. 5, No. 6, (December 2003), pp: 513-520, ISSN: 1523-3847.
- Zimmerman S., et al., (1994) Irreversible, severe congestive cardiomyopathy occurring in association with interferon alpha therapy. *Cancer Biother* Vol. 9, No. 4, (Winter 1994), pp: 291-299, ISSN: 1062-8401.



Myocarditis

Edited by Dr. Daniela Cihakova

ISBN 978-953-307-289-0

Hard cover, 428 pages

Publisher InTech

Published online 19, October, 2011

Published in print edition October, 2011

Myocarditis, the inflammation of the heart muscle, could be in some cases serious and potentially fatal disease. This book is a comprehensive compilation of studies from leading international experts on various aspects of myocarditis. The first section of the book provides a clinical perspective on the disease. It contains comprehensive reviews of the causes of myocarditis, its classification, diagnosis, and treatment. It also includes reviews of Perimyocarditis; Chagasâ€™ chronic myocarditis, and myocarditis in HIV-positive patients. The second section of the book focuses on the pathogenesis of myocarditis, discussing pathways and mechanisms activated during viral infection and host immune response during myocarditis. The third, and final, section discusses new findings in the pathogenesis that may lead to new directions for clinical diagnosis, including use of new biomarkers, and new treatments of myocarditis.

How to reference

In order to correctly reference this scholarly work, feel free to copy and paste the following:

Simona Claudia Cambrea (2011). Myocarditis in HIV Positive Patients, Myocarditis, Dr. Daniela Cihakova (Ed.), ISBN: 978-953-307-289-0, InTech, Available from: <http://www.intechopen.com/books/myocarditis/myocarditis-in-hiv-positive-patients>

INTECH
open science | open minds

InTech Europe

University Campus STeP Ri
Slavka Krautzeka 83/A
51000 Rijeka, Croatia
Phone: +385 (51) 770 447
Fax: +385 (51) 686 166
www.intechopen.com

InTech China

Unit 405, Office Block, Hotel Equatorial Shanghai
No.65, Yan An Road (West), Shanghai, 200040, China
中国上海市延安西路65号上海国际贵都大饭店办公楼405单元
Phone: +86-21-62489820
Fax: +86-21-62489821

© 2011 The Author(s). Licensee IntechOpen. This is an open access article distributed under the terms of the [Creative Commons Attribution 3.0 License](#), which permits unrestricted use, distribution, and reproduction in any medium, provided the original work is properly cited.

IntechOpen

IntechOpen