

We are IntechOpen, the world's leading publisher of Open Access books Built by scientists, for scientists

5,800

Open access books available

142,000

International authors and editors

180M

Downloads

Our authors are among the

154

Countries delivered to

TOP 1%

most cited scientists

12.2%

Contributors from top 500 universities



WEB OF SCIENCE™

Selection of our books indexed in the Book Citation Index
in Web of Science™ Core Collection (BKCI)

Interested in publishing with us?
Contact book.department@intechopen.com

Numbers displayed above are based on latest data collected.
For more information visit www.intechopen.com



Impact of Dopamine Transporter Scan in Parkinson's Disease

Jörg Spiegel

¹Department of Neurology, Saarland University,
Germany

1. Introduction

1.1 Technique of nigrostriatal FP-CIT SPECT

The density of the presynaptic dopamine reuptake transporters (DAT) can be quantified with [¹²³I]FP-CIT SPECT. The tracer Fluorpropyl-Carbomethoxy-Iodophenyl-Tropan (FP-CIT), marked by radioactive ¹²³iodine [¹²³I] (therefore the name [¹²³I]FP-CIT), binds reversibly to the DAT on the presynaptic membrane. Before application of FP-CIT, the iodine uptake of the thyroid gland is blocked with sodium perchlorate. Then the radioactive tracer [¹²³I]FP-CIT (110 - 185 MBq, specific activity: 580 - 1040 GBq/mg) is injected intravenously. 3 - 6 hours following the intravenous tracer injection, cerebral SPECT images are obtained by a gamma camera. At the moment, FP-CIT is the preferred tracer to visualize DAT due to its pharmacokinetic properties including fast (3 - 6 hours after intravenous injection) and highly affine binding ($K_i = 3.1$ nM) at DAT (4, 22). The exposure to radiation at the examination of an individual with a body weight of 70 kilograms amounts to 4.35 milli-Sievert (mSv). For comparison: the average effective exposure to natural background radiation in middle Europe at sea level runs up to 2.4 mSv.

Due to the similarity between dopamine reuptake transporters and serotonin reuptake transporters, serotonin reuptake inhibitors, widely used as antidepressants, must not be taken in the last two weeks before FP-CIT SPECT examination (fluoxetine for a period of six weeks). Furthermore therapy with selegiline should be discontinued to avoid interaction of its metabolites with FP-CIT at the dopamine transporter (19). Further anti-parkinsonian medication may be continued during SPECT examination, since present data (11, 16, 19, 21) do not show any effect of antiparkinsonian drugs on dopamine transporter binding.

Beyond FP-CIT-SPECT there exist further nuclear medicine methods to quantify the nigrostriatal presynaptic DAT density: [¹²³I]-beta-CIT SPECT (2beta-Carbomethoxy-Iodophenyl-Tropan; late SPECT after application of beta-CIT; [9, 15, 16]) and TRODAT SPECT (6, 23).

2. Evaluation of nigrostriatal FP-CIT SPECT

Registration and semiquantitative analysis are performed on a workstation. The caudate nucleus, putamen and occipital lobe binding of [¹²³I]FP-CIT is assessed semiquantitatively

by a regions of interest (ROI) technique. The work station performs an automatic fitting of the studies to a model database. This fitting is controlled by an experienced nuclear medicine physician and if necessary manually adjusted. The special binding ratios of *caudate nucleus / occipital lobe* and *putamen / occipital lobe* are calculated. The quotients [*caudate nucleus binding / occipital lobe binding*] and [*putamen binding / occipital lobe binding*] for both sides are calculated. The occipital lobe serves as reference region. In healthy people these quotients amount to 3 up to 4.

FP-CIT SPECT has to be considered as pathological, if 1) absolute FP-CIT binding into putamen or caudate nucleus remains below a lower norm value or 2) side-to-side difference (right versus left or vice versa) exceeds an upper norm value. The norm values of the department of Nuclear Medicine of the Saarland University were obtained in healthy volunteers without any present or previous neurological or psychiatric disease (age 38 - 76 years, 59 ± 11 years, mean \pm SD). In these volunteers the ratio *putamen / occipital lobe binding* was 3.44 ± 0.35 (resulting norm value = mean - 2 SD: ≥ 2.74) for the right putamen and 3.52 ± 0.36 (norm value ≥ 2.80) for the left putamen. The ratio *caudate nucleus / occipital lobe binding* was 3.67 ± 0.36 (norm value ≥ 2.95) for the right caudate nucleus and 3.67 ± 0.37 (norm value ≥ 2.93) for the left caudate nucleus. The norm value for the side-to-side difference (affected versus unaffected striatal area) is $\leq \Delta 0.15$ (mean + 2 SD; [25]).

3. Clinical impact of FP-CIT SPECT

With reference to the definite post-mortem histopathological diagnosis of PD, the UK Brain Bank criteria (13) disclose a predictive value for PD of 90%. However, 10% of real PD patients ("real" means: with regard to the definite post-mortem histopathological diagnosis) 1) are not diagnosed as having PD or 2) make the differential diagnostic difficult even for experienced neurologists (13, 14). Therefore additional apparative measurements are necessary that support the clinical PD diagnosis. At the moment, the nuclear medicine measurement of DAT density, which is reduced in PD, represents one of the best apparative methods to clarify the PD diagnosis. Primarily the [^{123}I]FP-CIT SPECT represents an established method to quantify the nigrostriatal DAT density.

Motor symptoms of PD are based on a functional loss of the presynaptic dopaminergic nigrostriatal neuron. This functional loss correlates inversely with the DAT density on the membrane of the presynaptic neuron. Thus, a reduced nigrostriatal DAT density is typical for PD (Figures 1 and 2). FP-CIT SPECT correlates significantly with the extent of motor PD symptoms (2, 5, 25). At all PD stages presynaptic dopaminergic degeneration is more advanced in the putamen than that in the caudate nucleus (10, 25). The test-retest reliability of FP-CIT SPECT in PD patients is very high (26).

The prognostic validity of FP-CIT concerning the clinical progression of PD is unclear. Djaldetti et al. (8) applied FP-CIT SPECT in 19 patients with early PD and observed the following 12-15 months: striatal [^{123}I]FP-CIT uptake correlated significantly with the progression of motor symptoms (= difference [*motor symptom* at follow-up visit] - [*motor symptom* at baseline visit]) within these 12 - 15 months. These results suggest that a single SPECT may predict the disease severity over a period of 12 - 15 months. In contrast, another study (12) reported that the FP-CIT SPECT does not allow forecasting the progress of motor symptoms of PD over a longer time period of 3-7 years.

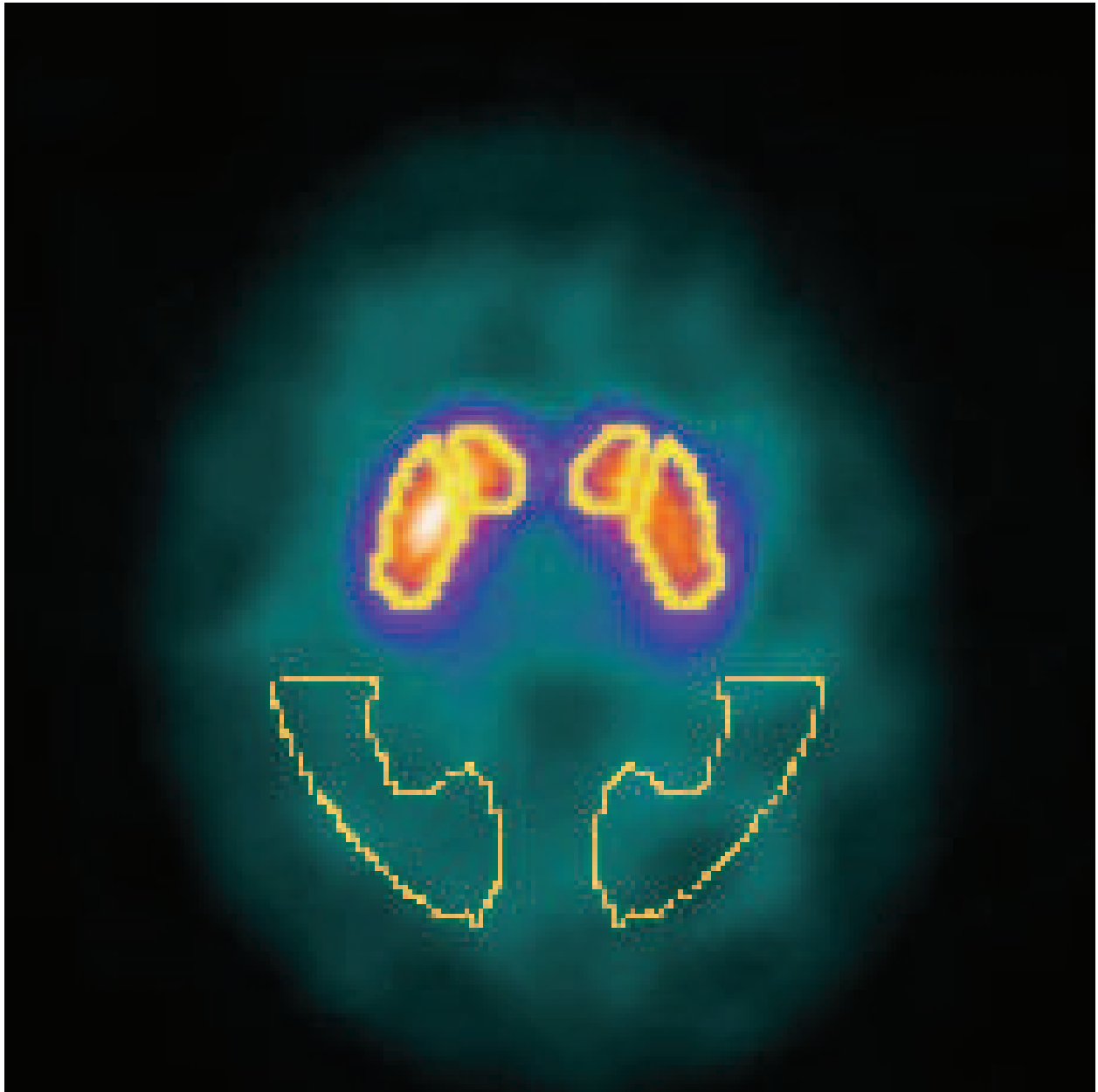


Fig. 1. FP-CIT SPECT in a patient with PD of the tremor dominant type. The striatal FP-CIT uptake is reduced bilaterally.

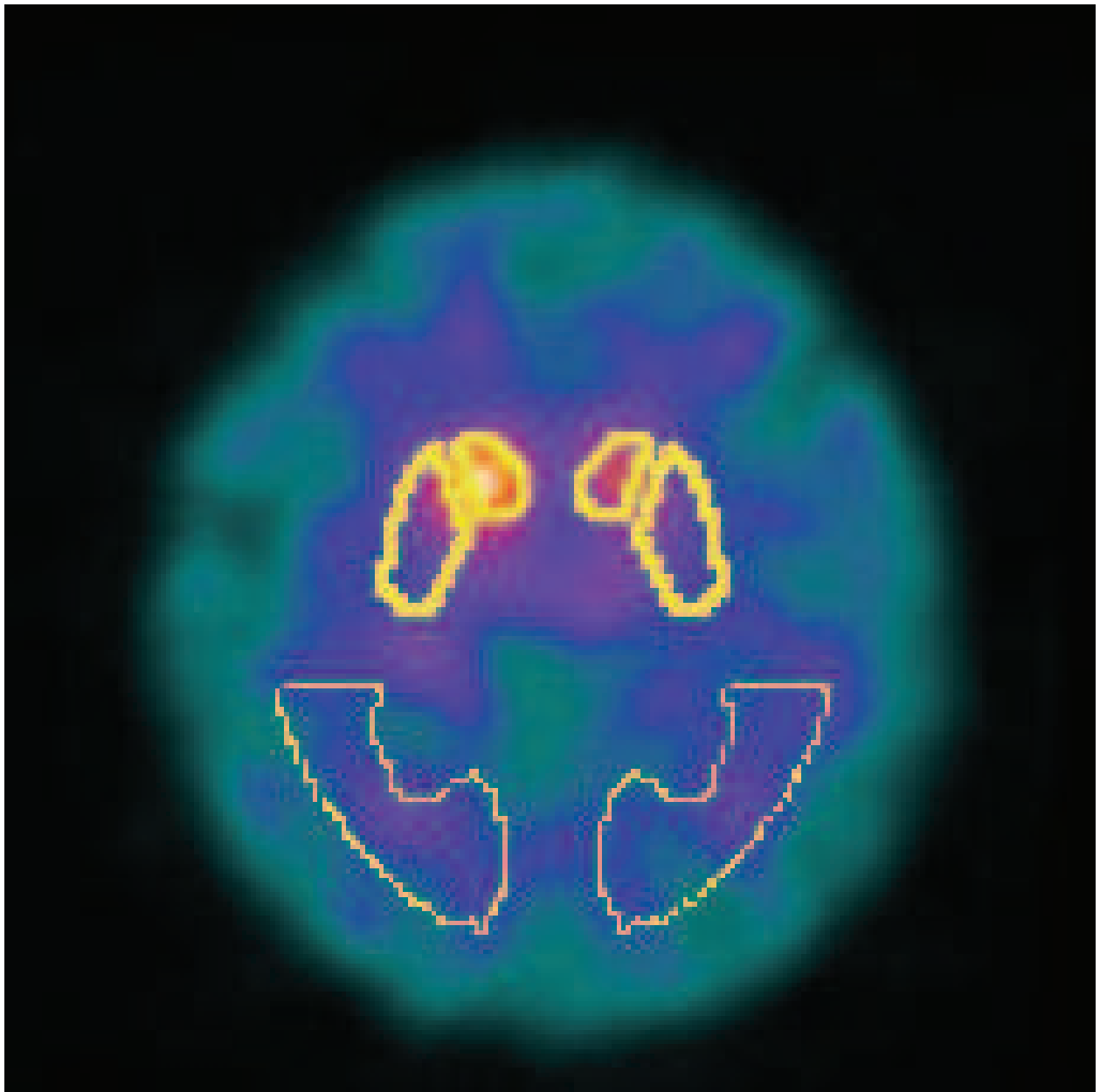


Fig. 2. FP-CIT SPECT in a patient with PD of the hypokinetic rigid type. The striatal FP-CIT uptake is bilaterally more reduced than in Figure 1.

4. Sensitivity, specificity and predictive value of FP-CIT SPECT

A multicenter study with 158 PD patients, 27 patients with essential tremor and 35 healthy volunteers reported a sensitivity of FP-CIT SPECT concerning PD of 95% (2, 3). Already in the earliest stage of PD, the sensitivity of the FP-CIT SPECT reaches between 95% and 100% (10, 18, 25) and amounts to nearly 100% in the more advanced stages of PD (24).

The differentiation between PD and essential tremor represents the main clinical indication for the FP-CIT SPECT. The specificity of FP-CIT SPECT concerning PD versus essential tremor is high (100%, [3]). In contrast to this, specificity of FP-CIT SPECT against atypical parkinsonian syndromes is very low. The term "atypical parkinsonian syndromes" (APS) denotes idiopathic neurodegenerative disorders, clinically characterized by a combination of an akinetic rigid symptoms with additional symptoms, which are different from those in PD. The group of APS includes the multiple system atrophy, the corticobasal degeneration and the progressive supranuclear palsy. In contrast to PD, which is induced by a presynaptic nigrostriatal dopaminergic degeneration, the APS are based on a postsynaptic nigrostriatal dopaminergic degeneration. This postsynaptic degeneration in the APS is followed by a secondarily reduced density of presynaptic DAT. Since the DAT density is secondarily impaired in the APS, the FP-CIT SPECT cannot sufficiently differentiate between APS and PD (1, 17, 20).

5. Scientific impact of FP-CIT SPECT

As explained above, FP-CIT SPECT measures the density of presynaptic dopamine reuptake transporters. This means that FP-CIT SPECT reflects exactly the underlying pathophysiology of PD. This allows further insights into the pathophysiological processes of PD. In the following we present some of these insights.

Recent studies found that the reduction of dopaminergic function - quantified by FP-CIT SPECT - correlates significantly with the extent of parkinsonian cardinal symptoms bradykinesia and rigidity but not with the extent of tremor in PD (2, 25). PD patients with tremor dominant type show a significantly higher striatal FP-CIT uptake than patients with akinetic rigid or equivalence type at the same stage of disease (Figure 1 and 2, [25]). These findings correlate with the clinical observation that bradykinesia and rigidity respond better to levodopa or dopamine agonists than tremor (7). The missing correlation between striatal FP-CIT uptake and tremor suggests, that further systems besides the nigrostriatal dopaminergic system may contribute to generation of parkinsonian tremor.

In addition, the FP-CIT SPECT may play an important role in the diagnosis of preclinical stage of PD (preclinical means: before first motor symptoms occur). Booij et al. (5) applied FP-CIT SPECT in 33 patients with suspected beginning Parkinsonism and performed a clinical follow-up of these patients 2-4 years after SPECT imaging. In nine of these 33 patients, SPECT was pathological; all these nine patients developed PD in the clinical follow-up. None of the 24 subjects without normal SPECT developed PD in the clinical follow-up. These data suggest a high positive predictive value of the FP-CIT SPECT. A study of Filippi et al. (10) involved 29 de-novo PD patients with one-sided clinical symptoms and 18 gender- and age-matched controls. In the PD patients, both ipsilateral

and contralateral putamen and caudate nucleus showed a significantly reduced FP-CIT uptake. The pathological ipsilateral FP-CIT SPECT indicates that a pathological FP-CIT SPECT precedes clinical symptoms at the not affected body side.

6. References


- Antonini A, Benti R, De Notaris R, Tesei S, Zecchinelli A, Sacilotto G, et al. 123I-Ioflupane/SPECT binding to striatal dopamine transporter (DAT) uptake in patients with Parkinson's disease, multiple system atrophy, and progressive supranuclear palsy. *Neurol Sci* 2003; 24: 149-150.
- Benamer HT, Patterson J, Wyper DJ, Hadley DM, Macphee GJ, Grosset DG. Correlation of Parkinson's disease severity and duration with 123I-FP-CIT SPECT striatal uptake. *Mov Disord* 2000a; 15: 692-698.
- Benamer TS, Patterson J, Grosset DG, Booij J, de Bruin K, van Royen E, et al. Accurate differentiation of parkinsonian and essential tremor using visual assessment of [123I]-FP-CIT-SPECT imaging: the [123I]-FP-CIT study group. *Mov Disord* 2000b; 15: 503-510.
- Booij J, Sokole EB, Stabin MG, Janssen AGM, de Bruin K, van Royen EA. Human biodistribution and dosimetry of [123I]FP-CIT: a potent radioligand for imaging of dopamine transporters. *Eur J Nucl Med* 1998; 25: 24-30.
- Booij J, Speelman JD, Horstink MW, Wolters EC. The clinical benefit of imaging striatal dopamine transporters with [123I]FP-CIT SPECT in differentiating patients with presynaptic Parkinson from those with other forms of parkinsonism. *Eur J Nucl Med* 2001; 28: 266-272.
- Chou KL, Hurtig HI, Stern MB, Colcher A, Ravina B, Newberg A, Mozley PD, Siderowf A. Diagnostic accuracy of [99mTc]TRODAT-1 SPECT imaging in early Parkinson's disease. *Parkinsonism Relat Disord* 2004; 10: 375-379.
- Deuschl G, Krack P. *Morbus Parkinson, Bd. 2*. In: Hopf HC, Deuschl G, Diener HC, Reichmann H: *Neurologie in Praxis und Klinik, 3. Auflage* 1999, Georg Thieme Verlag Stuttgart New York, pp. 49-69.
- Djaldetti R, Treves TA, Ziv I, Melamed E, Lampl Y, Lorberboym M: Use of a single [(123)I]-FP-CIT SPECT to predict the severity of clinical symptoms of Parkinson disease. *Neurol Sci* 2009; 30:301-305.
- Eerola J, Tienari PJ, Kaakkola S, Nikkinen P, Launes J. How useful is [123I]beta-CIT SPECT in clinical practice? *J Neurol Neurosurg Psychiatry* 2005; 76:1211-1216.
- Filippi L, Manni C, Pierantozzi M, Brusa L, Danieli R, Stanzione P, Schillaci O. 123I-FP-CIT semi-quantitative SPECT detects preclinical bilateral dopaminergic deficit in early Parkinson's disease with unilateral symptoms. *Nucl Med Commun* 2005; 26: 421-426.
- Guttman M, Stewart D, Hussey D, Wilson A, Houle S, Kish S. Influence of L-dopa and pramipexole on striatal dopamine transporter in early PD. *Neurology* 2001; 56: 1559-1564.
- Hubbich M, Farmakis G, Schaefer A, Behnke S, Schneider S, Hellwig D, Fassbender K, Kirsch CM, Dillmann U, Spiegel J. FP-CIT SPECT does not predict the

- progression of motor symptoms in Parkinson's disease. *Eur Neurol* 2011; 65: 187-192.
- Hughes A, Daniel SE, Kilford L, Lees AJ. Accuracy of clinical diagnosis of idiopathic Parkinson's disease: a clinico-pathological study of 100 cases. *J Neurol Neurosurg Psychiatry* 1992a; 55: 181-184.
- Hughes AJ, Ben-Shlomo Y, Daniel SE, Lees AJ. What features improve the accuracy of clinical diagnosis in Parkinson's disease: a clinicopathologic study. *Neurology*. 1992 Jun; 42(6):1142-6. Erratum in: *Neurology* 1992b; 42: 1142-1146.
- Ichise M, Kim YJ, Ballinger JR, Vines D, Erami SS, Tanaka F, Lang AE (1999) SPECT imaging of pre- and postsynaptic dopaminergic alterations in L-dopa untreated Parkinson's disease. *Neurology* 52: 1206-1214.
- Innis RB, Marek KL, Sheff K, Zoghbi S, Castronuovo J, Feigin A, Seibyl JP. Effect of treatment with L-dopa/carbidopa or L-selegiline on striatal dopamine transporter SPECT imaging with [¹²³I]beta-CIT. *Mov Disord* 1999; 14: 436-442.
- Kim YJ, Ichise M, Ballinger JR, Vines D, Erami SS, Tatschita T, et al. Combination of dopamine transporter and D2 receptor SPECT in the diagnostic evaluation of PD, MSA und PSP. *Mov Disord* 2002; 17: 303-312.
- Van Laere K, De Ceuninck L, Dom R, Van den Eynden J, Vanbilloen H, Cleynhens J, et al. Dopamine transporter SPECT using fast kinetic ligands: ¹²³I-FP-beta-CIT versus ^{99m}Tc-TRODAT-1. *Eur J Nucl Med Mol Imaging* 2004; 31:1119-1127.
- Laruelle M, Baldwin RM, Malison RT, Zea-Ponce Y, Zoghbi SS, Al-Tikriti MS, et al. SPECT imaging of dopamine and serotonin transporters with [¹²³I]β-CIT: pharmacological characterization of brain uptake in non-human primates. *Synapse* 1993; 13: 295-309.
- Plotkin M, Amthauer H, Klaffke S, Kühn A, Lüdemann L, Arnold G, et al. Combined ¹²³I-FP-CIT and ¹²³I-IBZM SPECT for the diagnosis of parkinsonian syndromes: study on 72 patients. *J Neural Transm* 2005; 112: 677-692.
- Schillaci O, Pierantozzi M, Filippi L, Manni C, Brusa L, Danieli R, et al. The effect of levodopa therapy on dopamine transporter SPECT imaging with(¹²³I)-FP-CIT in patients with Parkinson's disease. *Eur J Nucl Med Mol Imaging* 2005; 32: 1452-1456.
- Seibyl JP, Marek K, Sheff K, Zoghbi S, Baldwin RM, Charney DS, et al. Iodine-123-beta-CIT and iodine-123-FPCIT-SPECT measurement of dopamine transporters in healthy subjects and Parkinson's patients. *J Nucl Med* 1998; 39: 1500-1508.
- Siderowf A, Newberg A, Chou KL, Lloyd M, Colcher A, Hurtig HI, et al. [^{99m}Tc]TRODAT-1 SPECT imaging correlates with odor identification in early Parkinson disease. *Neurology* 2005; 64: 1716-1720.
- Spiegel J, Möllers MO, Behnke S, Hellwig D, Jost WH, Samnick S, Dillmann U, Becker G, Kirsch CM: Transcranial sonography and [¹²³I]FP-CIT SPECT disclose complementary aspects of Parkinson's disease. *Brain* 2006; 129: 1188-1193.
- Spiegel J, Hellwig D, Samnick S, Jost WH, Möllers MO, Fassbender K, Kirsch CM, Dillmann U. Striatal FP-CIT uptake differs in the subtypes of early Parkinson's disease. *J Neural Transm*. 2007; 114: 331-335.

Tsuchida T, Ballinger JR, Vines D, Kim YJ, Utsunomiya K, Lang AE, Ichise M. Reproducibility of dopamine transporter density measured with ¹²³I-FPCIT SPECT in normal control and Parkinson's disease patients. *Ann Nucl Med* 2004; 18: 609-616.

IntechOpen

IntechOpen



Diagnosis and Treatment of Parkinson's Disease

Edited by Prof. Abdul Qayyum Rana

ISBN 978-953-307-465-8

Hard cover, 264 pages

Publisher InTech

Published online 22, September, 2011

Published in print edition September, 2011

Parkinson's disease is diagnosed by history and physical examination and there are no laboratory investigations available to aid the diagnosis of Parkinson's disease. Confirmation of diagnosis of Parkinson's disease thus remains a difficulty. This book brings forth an update of most recent developments made in terms of biomarkers and various imaging techniques with potential use for diagnosing Parkinson's disease. A detailed discussion about the differential diagnosis of Parkinson's disease also follows as Parkinson's disease may be difficult to differentiate from other mimicking conditions at times. As Parkinson's disease affects many systems of human body, a multimodality treatment of this condition is necessary to improve the quality of life of patients. This book provides detailed information on the currently available variety of treatments for Parkinson's disease including pharmacotherapy, physical therapy and surgical treatments of Parkinson's disease. Postoperative care of patients of Parkinson's disease has also been discussed in an organized manner in this text. Clinicians dealing with day to day problems caused by Parkinson's disease as well as other healthcare workers can use beneficial treatment outlines provided in this book.

How to reference

In order to correctly reference this scholarly work, feel free to copy and paste the following:

Jörg Spiegel (2011). Impact of Dopamine Transporter Scan in Parkinson's Disease, Diagnosis and Treatment of Parkinson's Disease, Prof. Abdul Qayyum Rana (Ed.), ISBN: 978-953-307-465-8, InTech, Available from: <http://www.intechopen.com/books/diagnosis-and-treatment-of-parkinson-s-disease/impact-of-dopamine-transporter-scan-in-parkinson-s-disease>

INTECH
open science | open minds

InTech Europe

University Campus STeP Ri
Slavka Krautzeka 83/A
51000 Rijeka, Croatia
Phone: +385 (51) 770 447
Fax: +385 (51) 686 166
www.intechopen.com

InTech China

Unit 405, Office Block, Hotel Equatorial Shanghai
No.65, Yan An Road (West), Shanghai, 200040, China
中国上海市延安西路65号上海国际贵都大饭店办公楼405单元
Phone: +86-21-62489820
Fax: +86-21-62489821

© 2011 The Author(s). Licensee IntechOpen. This chapter is distributed under the terms of the [Creative Commons Attribution-NonCommercial-ShareAlike-3.0 License](#), which permits use, distribution and reproduction for non-commercial purposes, provided the original is properly cited and derivative works building on this content are distributed under the same license.

IntechOpen

IntechOpen