

We are IntechOpen, the world's leading publisher of Open Access books Built by scientists, for scientists

5,000

Open access books available

125,000

International authors and editors

140M

Downloads

Our authors are among the

154

Countries delivered to

TOP 1%

most cited scientists

12.2%

Contributors from top 500 universities



WEB OF SCIENCE™

Selection of our books indexed in the Book Citation Index
in Web of Science™ Core Collection (BKCI)

Interested in publishing with us?
Contact book.department@intechopen.com

Numbers displayed above are based on latest data collected.
For more information visit www.intechopen.com



Stereotactic Radiosurgery for Brain Tumors

Susan C. Pannullo, Cecile Yama and A. Gabriella Wernicke
*New York Presbyterian Hospital- Weill Cornell Medical College, New York
USA*

1. Introduction

Stereotactic Radiosurgery (SRS) is a non-invasive technique for the delivery of highly focused ionizing radiation with extreme precision. It is used in neurosurgical practice as a less invasive means of targeting benign and malignant brain tumors, vascular malformations, and functional disorders. Its ability to elicit a desired response (e.g. tumor cell death) with minimal effect on normal surrounding structures is one of the many benefits that have led to more widespread use of stereotactic radiosurgical procedures in recent years. Current standard practice involves utilizing high resolution imaging for “stereotactic” 3-dimensional (3-D) treatment planning under the guidance of a multidisciplinary team comprised of a neurosurgeon, radiation oncologist and medical physicist. To achieve the desired outcome, the SRS procedure can be performed in either a single treatment or in several applications (fractionated)^{1,2}.

2. Stereotactic radiosurgery: Brief history

In 1951 neurosurgeon Lars Leksell developed the first stereotactic radiosurgery technique at Karolinska Hospital in Stockholm, Sweden. Dr. Leksell pioneered the stereotactic headframe for use in noninvasive lesioning in functional neurosurgery by attaching an orthovoltage x-ray tube to a stereotactic frame in order to produce converging beams which would intersect at the treatment target¹. In one of his first publications on the novel device he described how he could use the directed narrow beams of radiant energy in order to produce local destruction of undesirable brain tumor tissue. By adjusting the width of the beam to the size of the structure to be irradiated, and moving the beam guide transversely along the frame, the targeted radiation would meet at desired tissue site³.

After finding his early work with the proton beam and linear accelerator radiosurgery overly cumbersome and inefficient, Dr. Leksell collaborated with Borge Larson in 1968 to design the first Gamma Knife device. This device contained 179 Cobalt 60 (Co-60) sources arranged symmetrically to irradiate a volume of brain tissue with a diameter of approximately 4, 8, or 14 mm¹. The production and use of the Leksell Gamma Unit expanded in the late 1980s with the introduction of angiography, which enabled surgeons to delineate and therefore target arteriovenous malformations (AVMs). After getting the Food and Drug Administration (FDA) approval in 1982, the 201 Co-60 source gamma knife was used for the first time in the United States at the University of Pittsburgh, where it proved to

be a therapeutically effective and economical alternative to some conventional neurosurgery practices⁴.

In recent years novel imaging techniques have been developed to optimize and expand the uses of the gamma knife and other stereotactic devices. Computer tomography (CT) and magnetic resonance imaging (MRI) techniques have improved the quality of the brain image and achieved a more precise localization of abnormalities and tumors in the brain. Combining these innovative imaging technologies with high-speed workstations that rapidly calculate and display 3-D dose distributions enables more effective and productive uses of these technologies¹. In addition, positron emission tomography (PET) scans provide images that include metabolic data and functional data and in doing so add another layer of sophistication in the treatment of more complex targets such as rapidly proliferating tumors, including gliomas and metastases. The metabolic information provided by using PET scan imaging is complementary to anatomical information derived from CT or MRI imaging and assists in more precise identification of the target in dose-planning procedures⁵.

3. Stereotactic radiosurgery technologies: Gamma Knife, LINAC, CyberKnife, Proton Beam

3.1 Gamma Knife

The Gamma Knife, developed by Leksell in 1968, has been reported to have been used in 350,000 treatments by Leksell Society in 2005, at 237 centers⁶. It is made up of an 18,000 kg shield surrounding a hemispherical array of 201 sources of cobalt-60 with an average activity of 30 curie (Ci); as the cobalt-60 decays, the photons pass through various sized collimator holes in a helmet designed for the stereotactic procedure⁴. It has both fixed central and secondary beams on separate axes, with interchangeable outer collimator helmets that are used with respect to the lesion size—larger collimators are used for larger lesions, and smaller collimators for smaller diameter lesions⁴. The number of “shots” used to achieve the maximal target dose is dependent on the collimator size selected⁴.

While Gamma Knife radiosurgery was originally designed to treat well-delineated lesions and targets, making it particularly useful for AVMs and benign tumors of the skull base, its uses have been expanded to include metastases, gliomas and other tumor types⁵. In addition to delineation of glial tumors, PET imaging technology has allowed for more accuracy in patients who have undergone previous surgery, which would otherwise make it difficult to define tumor recurrence accurately⁵.

3.2 LINAC

The development of linear accelerators (LINAC) allowed scientists and physicians to mimic the sharply defined small volumes of radiation produced by the Gamma Knife. Presently, LINAC systems utilized for SRS represent a predominant majority of the stereotactic systems worldwide. Such treatment applications have undergone a technical evolution. Early linear accelerators developed included the use of the Talairach stereotactic coordinate system with a 10-MV photon beam in 1983, and a 4-MV linear accelerator in 1985¹. Winston and Lutz later made use of the Brown-Roberts-Wells stereotactic frame with a floor stand in 1986 to achieve mechanical accuracy of 0.5mm, an accuracy comparable to that of the Gamma Knife⁷. In 1994 the FDA standardized commercial distribution of linear accelerator radiosurgery systems in the United States, and the expansion of such systems began¹.



Fig. 1. Gamma Knife Perfexion Unit

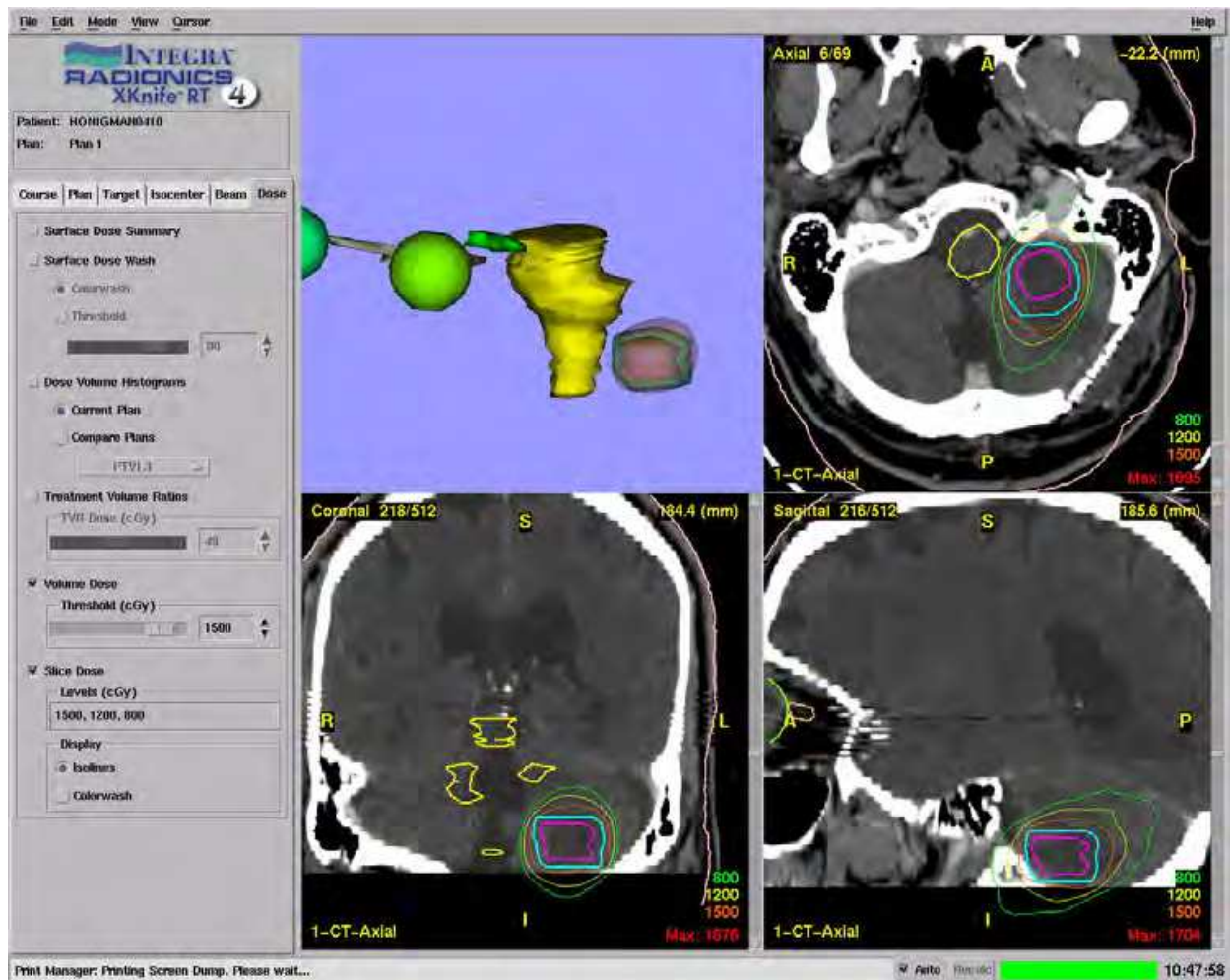


Fig. 2. LINAC Treatment Planning

The LINAC systems employ accelerated photons, much like the Gamma Knife system but rely on a different software and hardware than the Gamma Knife. It can be used with a frame or as a frameless system, and it has the advantage of being used for fractionated stereotactic radiotherapy which is for the most part not possible with Gamma Knife¹.

3.3 CyberKnife

The CyberKnife has been developed in recent years as a frameless, robotic, image-guided stereotactic radiosurgery system that manipulates an X-band linear accelerator⁸. This recent adaptation allows for a more flexible treatment both in terms of the ability to deliver the therapy without using a frame (making the experience more comfortable for the patient), increasing fractionation flexibility, as well as increasing the ability to treat extracranial lesions⁸. The CyberKnife radiosurgery system computes the dose range and quantity by using data from the robot and camera image tracking system software, along with contributions from the assembled team's treatment planning, based on CT imaging⁸.

The CyberKnife enables facile stereotactic fractionation, eases patient discomfort due to lack of stereotactic frame, and does not require anesthesia in pediatric patients which is necessary with frame-based systems⁸. Additional applications of frameless radiosurgical methods include use in other organ systems and locations such as the spinal column, the mediastinum, pelvis and the retroperitoneal space⁸.

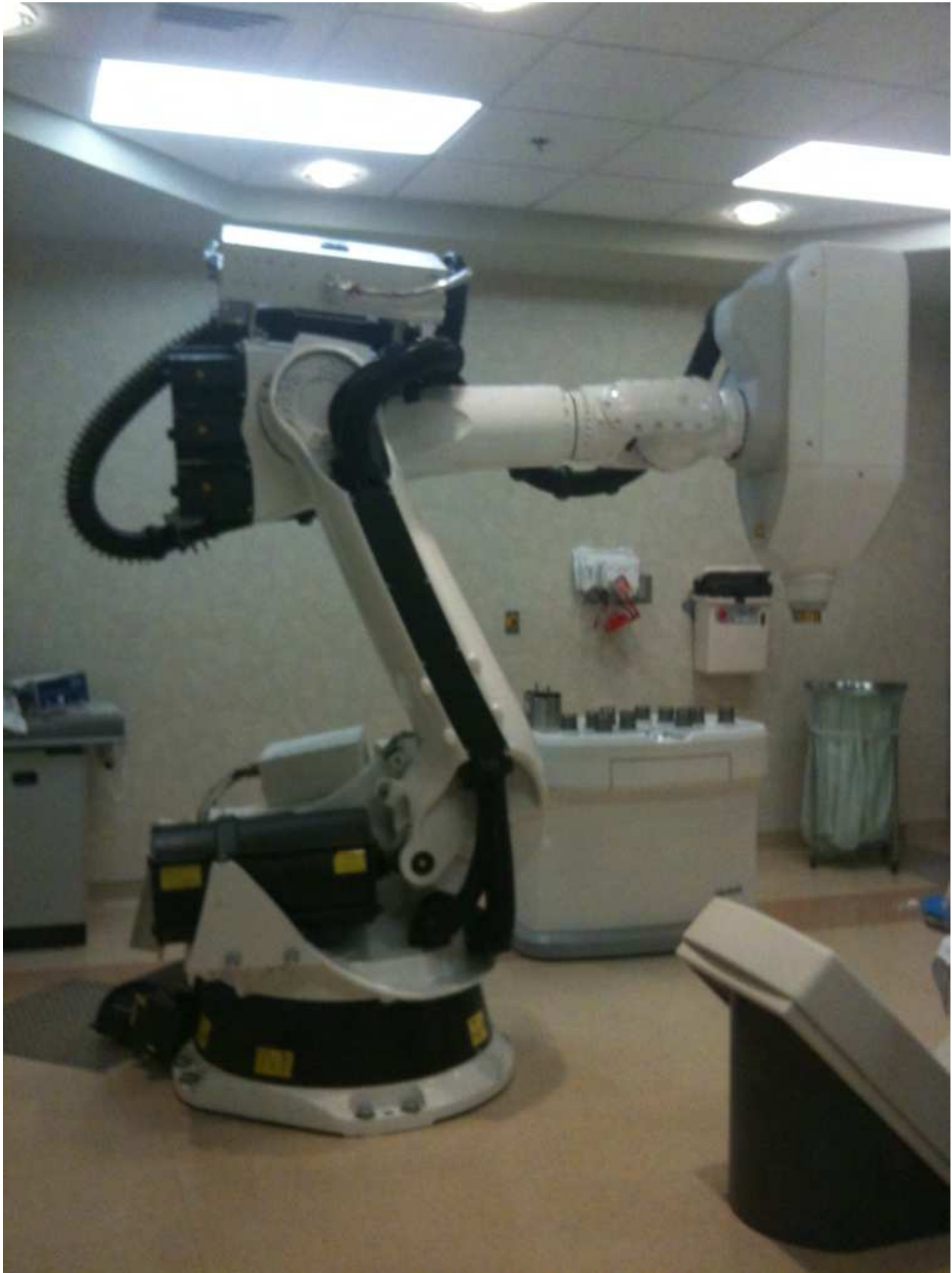

Fig. 3. CyberKnife Unit

3.4 Proton Beam

The proton beam is a significantly more costly and far less frequently used stereotactic system than the above-described applications. Due to its prohibitively high cost and special shielding, proton beam facilities are very few in the United States or worldwide. Proton beam SRS relies on generating a charged particle. Charged particle intracranial SRS was first implemented in the 1950s and 1960s when Tobias et al began to irradiate brain tumors in 1956 with high-energy, positively charged particles with a synchrocyclotron⁹. It was later used to treat intracranial lesions such as AVMs and pituitary adenomas¹. Raju has estimated that a total of 6,500 patients had been treated with intracranial SRS using charged particle beams by 1995¹⁰. The beam generated can manipulate the Bragg's peak to adjust to the size of the tumor. The particular characteristics of proton radiation is a very low entry dose and a very sharp fall off dose past the Bragg peak, i.e., past the tumor. Such beam properties render proton beam application in the brain most useful for the lesions near critical structures which may produce untoward permanent damage if not spared - the optic chiasm or a brain stem - and/or special pathologies requiring very high doses of radiation (e.g., chordoma, chondrosarcoma).

4. Indications for stereotactic radiosurgery

While the first Gamma Unit using Co-60 was installed in the Sophiahemmet Hospital in Sweden in 1968 and was primarily intended for neurosurgery in deep fiber tracts or nuclei⁸, its expansion to other hospitals both in Sweden and abroad allowed it to evolve in its function and use, as its capabilities were questioned and expanded. Indications for current use of stereotactic radiosurgery are multifarious, and includes certain malignant or benign tumors that meet the criteria for radiosurgical treatment as well as AVMs¹¹. Radiosurgery is an especially attractive therapeutic option for brain metastases because it can be used to treat small lesions that would be otherwise inaccessible with invasive surgery due to sensitive adjacent critical structures. It presents an especially attractive alternative option to invasive surgery for patients with co-morbidities¹¹. Radiosurgery continues to be constantly evaluated for its benefits, risks, and effectiveness in comparison to standard surgical, radiation and pharmacological options.

In addition to these more common uses, stereotactic radiosurgery is also used in a smaller percentage of cases for its original purpose—the treatment of functional disorders such movement disorders or intractable pain¹². Of these functional SRS cases, the most common indication is trigeminal neuralgia, but experimental procedures for epilepsy and other psychiatric illness are also conducted in several centers under strict protocol. Ventrolateral thalamotomy is being studied as a possible radiosurgical treatment of tremor in patients with Parkinson disease or multiple sclerosis, as well as for treatment of essential tremor. A study by Friehs has shown success rates that are comparable to other treatments in older groups of patients¹³.

5. Patient selection and preparation

Selecting patients for stereotactic radiosurgery involves a comprehensive account and balance of the benefits and risks of the procedure, in relation to the history of the disease, the condition of the patient, and other alternative therapies¹⁴. This includes thorough consideration of the demographic and medical profile of the patient as well as the nature, size, shape, and location of the lesion. Such assessment requires the expertise of several

medical professionals including neurodiagnosticians, neurosurgeons, radiation oncologists, and medical physicists¹⁴. Each of these medical practitioners is trained to contribute and collaborate to the procedure according to their capabilities.

Considerations with respect to the specifications of the tumor play a critical role both in deciding whether stereotactic radiosurgery is the appropriate treatment, and if so, how to approach the treatment. Radiosurgery is most often used to treat relatively small, well-circumscribed tumors or vascular malformations less than 35 mm in diameter^{14,15}. Patients with larger lesions are usually poor candidates. This is due to the delayed radiation-related complications from the gradual as opposed to steep fall-off of large doses of radiation as well as other adverse symptoms related to mass effect¹⁵. Both of these complications lead to the destruction of surrounding tissues. As a result, a neurosurgical approach is likely required for patients with larger lesions, as opposed to a radiosurgical one. In addition to the size of the lesion, the location of adjacent neural structures, such as the optic chiasm, must be considered in treatment planning as these structures often make it difficult or impossible to access the target site¹³.

In terms of patient demographic, the selection of radiosurgery as opposed to other modes of treatment also involves the assessment of patient preference, the neurological hazards of open surgical resection with general anesthesia for a particular patient, and the efficacy of alternative radiation techniques¹⁴. Considerations such as mental and physical patient motivation and cooperation (whether they are claustrophobic or are physically able to lie flat and still for the designated amount of time of the procedure) are important in determining whether radiosurgery is the optimal choice for the patient. It is preferable that a candidate for SRS has a Karnofsky Performance Status (KPS) >70.

5.1 Patient preparation and frame application

Stereotactic radiosurgery is most often an outpatient single day procedure. After the patient is determined to be a good candidate for this treatment and a date has been selected, pre-operative measures must be undertaken to explain the procedure to the patient and they must also sign a form of consent. It is important that the patient understands that they will be required to lie flat and still for a prolonged period of time. Diuretics to prevent edema and anticonvulsants to prevent seizures during the procedure can be administered to the patient two weeks before the procedure.

Administration of a mild oral sedative and local anesthetic are essential for gamma-knife radiosurgery because the treatment requires rigid fixation of the patient's head in a metal head frame, which would otherwise cause discomfort. After the sedative and anesthesia is administered and allowed to take effect, the frame is then applied. Optimal frame placement is critical for frame-based radiosurgery as the placement of the frame must be precise in order to avoid cranial defects. Targets must be placed in the center of the frame so that the beams of radiation will meet properly at the planning target volume (PTV).

Accurate placement of the frame requires comprehensive imaging and treatment planning by the radiosurgical team. Essential to the placement of the frame is defining the intracranial targets in stereotactic space¹⁶. This is done with various combinations of cerebral angiography, CT scan and MRI technologies both before the procedure and then again once the frame has been applied, with the latter set of coordinates specifying the PTV coordinates in relationship to the frame⁴. Stereotactic localization defines the coordinates of the volume of interest within the brain in terms of the external coordinates of the frame in order to align with the radiosurgical unit¹⁶. A fusion of the CT scan and an MRI provides a special

orientation of the target with respect to the stereotactic coordinates. The imaging data is analyzed by dose planning system software and the radiosurgical team. In recent years, advanced technologies such as positron emission tomography (PET) have been developed and implemented as previously mentioned, which enable the possibility of more accurate determination of PTV location in complicated cases. Examples of PET uses include glial tumors which are difficult to delineate from the surrounding tissue without additional metabolic data, which differentiates malignant tumor tissue based on its proliferation, as evidenced by the uptake of the radiolabeled glucose (^{18}F)⁵.

5.2 Imaging and treatment planning

Because the dosage planning for stereotactic radiosurgery is done for the most part by computer software, data including the rectilinear (x, y, z) coordinates of the target, head configuration measurements and treatment angle data must be gathered in order for the appropriate dose to be localized to the target area⁴. Stereotaxis relates the patient to a mathematic coordinate system by using the head frame's ring as a template on which the coordinate system can be applied¹⁷. A fiducial system attaches to the frame with imaging elements appropriate to the image modality used for treatment planning, and the data collected is inputted into a computer dose-planning system to create a stereotactic space¹⁵. In this way the treatment planning system identifies the coordinates of the target tissue and will administer the appropriate dosage only to that specific region.

The software used to calculate the appropriate isodose must take into account the summated isodose curves that show the cumulative effect of beam isocenter placements, collimator size, beam weighing and head angulation¹⁵. The system also calculates the amount of radiation that non-PTV structures are exposed to, allowing the treatment team to adjust the plan in order to minimize the effect on these surrounding structures. It is important that the software recognizes incorrect or dangerous treatment, and that the delivery system is contained in a room that protects treatment personnel as well as the public from harmful radiation¹⁵.

Dosimetric evaluation by the clinical team often includes both qualitative and quantitative histograms, including isodose surface displays and integral dose-volume histograms¹⁸. Computing the appropriate dose makes up a majority of the time of the planning procedure as it requires computational algorithms in addition to clinical input in order to optimize the treatment. In computing the isocenter, small movements can alter the minimum surface dose by as much as 30%¹⁸.

6. Selected clinical brain tumor applications of stereotactic radiosurgery

The clinical applications of stereotactic radiosurgery are numerous and include acoustic neuroma, meningioma, brain metastases, pituitary adenoma, glioblastoma multiforme, craniopharyngioma, trigeminal and other cranial nerve schwannoma, glomus jugulare tumors, hemangiopericytomas, ependymomas, and recurrent medulloblastoma. The following section will describe the specific indications for a number of these tumor types as well as the outcomes as examined by various studies. To improve treatment of many of these tumor types further research must be done in order to understand and optimize the benefits and detriments of different procedures. Contradictory data has been presented both within studies and between studies in choosing between a surgical, radiosurgical or radiation approach to tumor treatment planning.

6.1 Vestibular schwannoma / acoustic neuroma

Ideal active management for small-to-medium-sized vestibular schwannomas is still disputed and unclear, as a recent study by Pollock favored the radiosurgical over microsurgical approach, while Di Maio and Akagami showed no difference between groups of patients that were treated microsurgically, radiosurgically, or untreated with observation^{19,20,21}. These studies were measured based on quality of life outcomes (QOL).

Nonetheless, stereotactic surgery is presently used to treat vestibular schwannomas with favorable disease stabilization rates upwards of 90% with some studies showing tumor control rates up to 97%^{22,23}. While rates of tumor control are comparable to those of conventional microsurgery, both treatments demonstrate a preservation of hearing as well of other quality of life effects that are far from optimal. Facial weakness and facial numbness due to trigeminal and facial nerve damage during resection or radiosurgical treatment of vestibular schwannomas have presented additional challenges to current practice, but occur at a low frequency (<3%)²². The preservation of cochlear nerve function poses the predominant challenge to the surgical approach as well as the radiosurgical approach with a resultant preservation of useful hearing between 33-50% for small-to-medium-sized tumors, and considerably lower for larger tumors²².

A fractionated approach has been investigated in the attempt to preserve hearing and minimize incidental cranial nerve injury²². Poen's study of 33 patients with vestibular schwannoma demonstrated that a 24 hour three-fraction approach allows for a preservation of useful hearing (Gardner-Robertson Class 1-2) in 77% of patients two years after the treatment procedure²². The fractionated SRS protocol that was designed incorporated the physical advantages of rigid stereotactic localization, the practicality of a 1-day treatment, and the potential biological advantages of an abbreviated fractionation schedule²². It also takes advantage of the radiobiological principles that predict that fractionated radiotherapy will allow for repair of sublethal damage in normal tissues, reoxygenation of hypoxic tumor cells and redistribution of surviving tumor cells into a more radiosensitive cell cycle phase that is more susceptible to further radiation²².

While facial weakness and numbness is less common than hearing loss in the treatment of vestibular schwannomas, a review study by Yang has demonstrated that up to 3.8% of patients treated with Gamma Knife radiosurgery for vestibular schwannomas have poor to no facial nerve preservation after surgery²⁴. As a result, facial nerve preservation is still a great concern of patients undergoing radiosurgery for vestibular schwannomas. Treatment with radiation less than 13 Gy has been shown to have better facial nerve preservation rates after Gamma Knife radiosurgery for vestibular schwannoma (≤ 13 Gy = 98.5% vs. ≥ 13 Gy = 94.7%, $P < 0.0001$)²⁴.

6.2 Stereotactic radiosurgery for meningiomas

Stereotactic radiosurgery is presently an alternative or adjuvant approach alongside surgical resection for treatment and management of intracranial meningiomas. Radiosurgery presents a favorable approach to microsurgery in patients with residual or recurrent small volume tumors who have had previous resection, those with high risk symptomatic primary tumors, as well as in patients with medical illness or advanced age²⁵. It is not recommended for optic sheath tumors in patients with preserved vision²⁵. A study by Konziolka examined the rate of tumor growth control in 972 patients with 1045 intracranial meningiomas and found the control rate to be 93% in patients with benign meningiomas and low concurrent

risks²⁵. In this study a mean of 7.5 isocenters were used to provide conformal radiosurgery, with a mean dose to tumor margin at 14 Gy and mean maximum delivered dose of 28 Gy²⁵. Overall morbidity rate was 7.7% in patients who underwent stereotactic radiosurgical treatment for intracranial meningiomas at an average time of 11 months, and symptomatic peritumoral imaging changes were present in 4% of patients at 8 months²⁵.

In another study by Lee of the long-term outcomes in 176 patients who had undergone stereotactic radiosurgery for cavernous sinus meningiomas, neurological status improved in 46 patients (29%), was stabilized in 99 (62%), and worsened in 14 (9%)²⁶. While microsurgical approach to skull base has become more feasible in present years to achieve rates of 22.9-100% due to technique developments, complete resection still has the likely possibility of resultant disease and death while the alternative, incomplete resection, usually fails to arrest tumor progression²⁶. With a radiosurgical approach in treating cavernous sinus meningiomas, tumor volume was shown to decrease in 54 patients (34%), was stabilized in 96 (60%), and increased in nine (6%)²⁶. By placing the 50% or greater isodose at the irregular tumor margin, three-dimensional conformation radiosurgery was achieved with a median maximum dose of 26 Gy, and median dose delivered to margin at 13 Gy²⁶. Adverse effects of radiation occurred in 6.7% of patients where clinical or neurological deterioration occurred despite lack of tumor growth including visual deterioration, trigeminal nerve dysfunction and partial complex seizures²⁶.

Overall, multiple isocenter stereotactic radiosurgery allows for focused irradiation of irregular meningioma tumor margins and volumes, and prevents adjacent critical structures from injury in comparison to microsurgical techniques. Stereotactic radiosurgery is often recommended for smaller tumors, as large tumors respond poorly to due to mass effect^{25,26}. Several studies have analyzed various types of intracranial meningiomas and demonstrated that tumor recurrence or progression is statistically similar in both patients who have undergone resection and those who have been treated radiosurgically, with low morbidity in small- to-moderate-sized meningiomas without the risks associated with invasive surgery^{27,28}.

6.3 Stereotactic radiosurgery for brain metastases

Stereotactic radiosurgery is currently being used to treat newly diagnosed metastatic tumors, recurrent brain metastases after previous whole brain radiation therapy (WBRT), and as a "boost" after WBRT. Brain metastases are the most common adult brain tumor, affecting 100,000-170,000 people annually in the United States²⁹. Metastatic brain tumors have high incidence and follow a rapidly progressive course, requiring complex management which includes a combination of surgery, radiation and radiosurgery³⁰. Even with the multimodal treatment, low median survival rates of around 6 months after WBRT persist, and these low survival rates have historically led the oncology community to desist from aggressive treatment of these tumors³⁰.

Stereotactic radiosurgery presents a non-invasive, less aggressive approach to depress the rate of growth in solitary brain metastases. Solitary metastases are especially good targets for radiosurgical treatment when they are caught in earlier stages by MRI surveillance at less than 3.5 cm, because they are usually spherical, discrete and contrast enhancing, allowing for accurate lesion delineation³⁰. In addition, most metastases are uniformly sensitive to single fraction radiotherapy³⁰.

For multiple brain metastases, treatment becomes less effective as the number of tumors increases. A study by Pollock demonstrated that the probability of tumor control after surgery and WBRT or radiosurgery decreases from 64% for one intracranial metastasis, to 51% for two tumors, and to 41% for three³¹. Patients with fewer than four small- or medium-sized tumors can respond favorably to stereotactic radiosurgery³². Hypofractionated radiosurgery is the preferred option for patients that are poor surgical candidates due to co-morbidities or advanced systemic disease and it can be combined with resection for treatment of larger tumors³². In general, algorithms are followed to treat brain metastases through multimodal techniques that combine resection, WBRT and radiosurgery in attempt to maximize survival rates.

7. Stereotactic radiosurgery for brain tumors: Risks and benefits

7.1 Risks

The risks associated with stereotactic radiosurgery can be categorized by the time of their presentation and are determined by various factors including tumor type, size, location, prior radiation and the radiation dose given.

In a study by Warnick, complications were analyzed and categorized temporally. Acute complications occurring in the first seven days after radiosurgical treatment were rare and included nausea in 2-11% of patients within the first 24 hours, which was controlled with anti-emetics³⁰. Edema was reported in 2-6% of patients, with improvement seen with corticosteroids administered pre-operatively in tumors more frequently associated with this complication³⁰. Seizures were reported in 2-6% of patients within 24 hours, with greater occurrence in patients with pre-existing seizures and tumors near epileptogenic areas³³.

Subacute complications occurring within six months of the procedure, included uncommon occurrences of alopecia in 6% of patients, and the 'flare' phenomenon that presents as increased lesion volume, contrast enhancement and edema, resolving itself 9-12 months after the procedure³⁰. Flare is a result of accumulation of necrotic tumor tissue. Chronic complications, referring to those persisting for longer than six months after the procedure, include radiation necrosis, which is the most severe of such side effects and is dependent on the diameter of the tumor diameter being radiated. To reduce the risk of late radiation effects on surrounding structures, WBRT is increasingly being omitted from the initial management strategy of brain metastases^{34,35}. Finally, radiation-induced secondary neoplasms have been reported infrequently in few case studies.

7.2 Potential benefits

The potential benefits of stereotactic radiosurgery are extensive, making it an attractive alternative or even replacement treatment for tumor resection. It is a safe, effective, and non-invasive procedure, and as a result is well tolerated in older patients as well as those with concurrent disease. It also allows most patients to return immediately to normal activities. Single or few treatments can produce a sustained effect in a wide variety of tumors, and multiple small tumors can be treated simultaneously while avoiding the systemic toxicity that accompanies pharmacological treatment. In addition, radiosurgery can be combined with other therapies for comprehensive, patient-specific treatment. As a result, stereotactic radiosurgery is being increasingly utilized tool in the treatment of brain tumors and its applications are bound to grow and develop in future years.

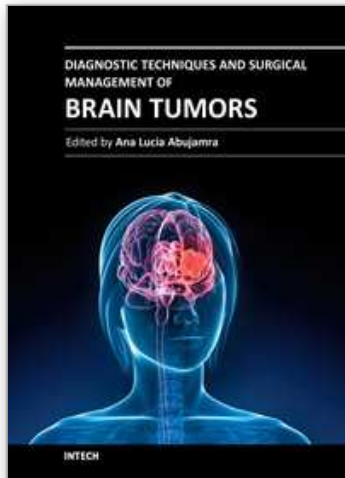
8. References

- [1] Goetsch SJ. Linear accelerator and gamma knife-based stereotactic cranial radiosurgery: challenges and successes of existing quality assurance guidelines and paradigms. *International journal of radiation oncology, biology, physics*. 2008;71(1 Suppl):S118-21. Available at: <http://www.ncbi.nlm.nih.gov/pubmed/18406908>.
- [2] Larson DA, Bova F, Eisert D, et al. Current radiosurgery practice: results of an ASTRO survey. Task Force on Stereotactic Radiosurgery, American Society for Therapeutic Radiology and Oncology. *International journal of radiation oncology, biology, physics*. 1994;28(2):523-6. Available at: <http://www.ncbi.nlm.nih.gov/pubmed/8276670> [Accessed May 19, 2011].
- [3] Leksell L. The stereotaxic method and radiosurgery of the brain. *Acta chirurgica Scandinavica*. 1951;102(4):316-9. Available at: <http://www.ncbi.nlm.nih.gov/pubmed/14914373> [Accessed May 19, 2011].
- [4] Lunsford. Stereotactic radiosurgery of the brain using the first United States 201 cobalt-60 source gamma knife. *Neurosurgery*. 1989;24(2):151. Available at: http://journals.lww.com/neurosurgery/Abstract/1989/02000/Stereotactic_Radiosurgery_of_the_Brain_Using_the.1.aspx [Accessed May 19, 2011].
- [5] Levivier, M. Wikier, D. et al. Integration of the metabolic data of positron emission tomography in the dosimetry planning of radiosurgery with the Leksell gamma knife: early experience with brain tumors. *Journal of neurosurgery*. 2000; 93 (Supplement 3):233-238. Available at: <http://thejns.org/doi/pdf/10.3171/jns.2000.93.supplement.3.0233> [Accessed May 19, 2011].
- [6] Leksell L. Occasional Review: Stereotactic Radiosurgery. *Journal of Neurology, Neurosurgery, and Psychiatry*. 1983;46:797-803. Available at: <http://jnci.oxfordjournals.org/content/87/1/34.short> [Accessed May 20, 2011].
- [7] Alexander E, Moriarty TM, Davis RB, et al. Stereotactic radiosurgery for the definitive, noninvasive treatment of brain metastases. *Journal of the National Cancer Institute*. 1995;87(1):34-40. Available at: <http://www.ncbi.nlm.nih.gov/pubmed/7666461>.
- [8] Friehs GM, Park MC, Goldman M a, et al. Stereotactic radiosurgery for functional disorders. *Neurosurgical focus*. 2007;23(6):E3. Available at: <http://www.ncbi.nlm.nih.gov/pubmed/18081480> [Accessed May 23, 2011].
- [9] Lunsford L, Alexander E, Chapman P, Coffey R. Consensus Statement on Stereotactic Radiosurgery: Quality Improvement. *Neurosurgery*. 1994. Available at: <http://scholar.google.com/scholar?hl=en&btnG=Search&q=intitle:Consensus+Statement+on+Stereotactic+Radiosurgery:+Quality+Improvement#1> [Accessed May 19, 2011].
- [10] Pollock BE. *Contemporary stereotactic radiosurgery: technique and evaluation*. Wiley-Blackwell; 2002:354. Available at: http://books.google.com/books?id=yEvjyys11ugC&pg=PA1&lpg=PA1&dq=Stereotactic+radiosurgery:+evolution,+lessons+learned,+and+integration+into+neurosurgical+practice&source=bl&ots=KOApP19wgd&sig=1wn-wXe_N5GFpMYi1Pt2KDUFwUk&hl=en&ei=Jm7VTeHkNITL0AGxpZiCDA&sa=X&oi=book_result&ct=result&resnum=1&ved=0CB4Q6AEwAA#v=onepage&q=Stereotactic+radiosurgery%3A+evolution%2C+lessons+learned%2C+and+integration+into+neurosurgical+practice&f=false [Accessed May 19, 2011].

- [11] Phillips MH, Stelzer KJ, Griffin TW, Mayberg MR, Winn HR. Stereotactic radiosurgery: a review and comparison of methods. *Journal of clinical oncology*. 1994;12(5):1085. Available at: <http://www.jcojournal.org/content/12/5/1085.short> [Accessed May 23, 2011].
- [12] Buatti JM, Friedman W a, Meeks SL, Bova FJ. The radiobiology of radiosurgery and stereotactic radiotherapy. *Medical dosimetry : official journal of the American Association of Medical Dosimetrists*. 1998;23(3):201-7. Available at: <http://www.ncbi.nlm.nih.gov/pubmed/9783273>.
- [13] Kooy HM, Nedzi LA, Loeffler JS, et al. Treatment Planning for Stereotactic Radiosurgery of Intra-Cranial Lesions. *International Journal of Radiation Oncology• Biology• Physics*. 1991;21(3):683-693. Available at: <http://linkinghub.elsevier.com/retrieve/pii/036030169190687Y> [Accessed June 2, 2011].
- [14] Conley GS, Hirsch BE. Stereotactic radiation treatment of vestibular schwannoma: indications, limitations, and outcomes. *Current Opinion in Otolaryngology & Head and Neck Surgery*. 2010;18(5):351. Available at: http://journals.lww.com/otolaryngology/Abstract/2010/10000/Stereotactic_radiation_treatment_of_vestibular.2.aspx [Accessed June 2, 2011].
- [15] Di Maio S, Akagami R. Prospective comparison of quality of life before and after observation, radiation, or surgery for vestibular schwannomas. *Journal of neurosurgery*. 2009;111(4):855-62. Available at: <http://www.ncbi.nlm.nih.gov/pubmed/19301957> [Accessed April 17, 2011].
- [16] Pollock BE. Vestibular schwannoma management: an evidence-based comparison of stereotactic radiosurgery and microsurgical resection. *Progress in neurological surgery*. 2008;21:222-7. Available at: <http://www.ncbi.nlm.nih.gov/pubmed/18810223> [Accessed June 2, 2011].
- [17] Poen JC, Golby a J, Forster KM, et al. Fractionated stereotactic radiosurgery and preservation of hearing in patients with vestibular schwannoma: a preliminary report. *Neurosurgery*. 1999;45(6):1299-305; discussion 1305-7. Available at: <http://www.ncbi.nlm.nih.gov/pubmed/10598696>.
- [18] Paek SH, Chung H-T, Jeong SS, et al. Hearing preservation after gamma knife stereotactic radiosurgery of vestibular schwannoma. *Cancer*. 2005;104(3):580-90. Available at: <http://www.ncbi.nlm.nih.gov/pubmed/15952200> [Accessed December 13, 2010].
- [19] Yang I, Sughrue ME, Han SJ, et al. Facial nerve preservation after vestibular schwannoma Gamma Knife radiosurgery. *Journal of neuro-oncology*. 2009;93(1):41-8. Available at:
- [20] Kondziolka D, Mathieu D, Lunsford LD, et al. Radiosurgery as Definitive Management for Intracranial Meningiomas. *Neurosurgery*. 2008;62(1):53. Available at: http://journals.lww.com/neurosurgery/Abstract/2008/01000/Radiosurgery_As_Definitive_Management_of.4.aspx [Accessed May 26, 2011].
- [21] Lee JYK, Niranjana A, McInerney J, et al. Stereotactic radiosurgery providing long-term tumor control of cavernous sinus meningiomas. *Journal of neurosurgery*. 2002;97(1):65-72. Available at: <http://www.ncbi.nlm.nih.gov/pubmed/12134934>.
- [22] Pollock B, Stafford S, Utter a, Giannini C, Schreiner S. Stereotactic radiosurgery provides equivalent tumor control to Simpson Grade 1 resection for patients with

- small- to medium-size meningiomas. *International Journal of Radiation OncologyBiologyPhysics*. 2003;55(4):1000-1005. Available at: <http://linkinghub.elsevier.com/retrieve/pii/S0360301602043560> [Accessed February 15, 2011].
- [23] Duma CM, Lunsford LD, Kondziolka D, Harsh GR, Flickinger JC. Stereotactic radiosurgery of cavernous sinus meningiomas as an addition or alternative to microsurgery. *Neurosurgery*. 1993;32(5):699-704; discussion 704-5. Available at: <http://www.ncbi.nlm.nih.gov/pubmed/8492844> [Accessed June 3, 2011].
- [24] Nussbaum ES, Djalilian HR, Cho KH, Hall WA. Brain metastases. Histology, multiplicity, surgery, and survival. *Cancer*. 1996;78(8):1781-8. Available at: <http://www.ncbi.nlm.nih.gov/pubmed/8859192> [Accessed June 3, 2011].
- [25] Warnick RE, Darakchiev BJ, Breneman JC. Stereotactic radiosurgery for patients with solid brain metastases: current status. *Journal of neuro-oncology*. 2004;69(1-3):125-37. Available at: <http://www.ncbi.nlm.nih.gov/pubmed/15527085>.
- [26] Pollock B. Management of patients with multiple brain metastases. *Contemp Neurosurg* 21. 1999;21.
- [27] Chang SD, Adler JR. Current treatment of patients with multiple brain metastases. *Neurosurgical focus*. 2000;9(2):e5. Available at: <http://www.ncbi.nlm.nih.gov/pubmed/16836291>.
- [28] Aoyama H, Shirato H, Tago M, et al. Stereotactic radiosurgery plus whole-brain radiation therapy vs stereotactic radiosurgery alone for treatment of brain metastases: a randomized controlled trial. *JAMA : the journal of the American Medical Association*. 2006;295(21):2483-91. Available at: <http://www.ncbi.nlm.nih.gov/pubmed/16757720>.
- [29] Kaido T, Hoshida T, Uranishi R, et al. Radiosurgery-induced brain tumor. Case report. *Journal of neurosurgery*. 2001;95(4):710-3. Available at: <http://thejns.org/doi/abs/10.3171/jns.2001.95.4.0710> [Accessed June 3, 2011].
- [30] McIver JI, Pollock BE. Radiation-induced Tumor after Stereotactic Radiosurgery and Whole Brain Radiotherapy: Case Report and Literature Review. *Journal of Neuro-Oncology*. 2004;66(3):301-305. Available at: <http://www.springerlink.com/content/x7120602t456q812/> [Accessed June 3, 2011].

IntechOpen



Diagnostic Techniques and Surgical Management of Brain Tumors

Edited by Dr. Ana Lucia Abujamra

ISBN 978-953-307-589-1

Hard cover, 544 pages

Publisher InTech

Published online 22, September, 2011

Published in print edition September, 2011

The focus of the book *Diagnostic Techniques and Surgical Management of Brain Tumors* is on describing the established and newly-arising techniques to diagnose central nervous system tumors, with a special focus on neuroimaging, followed by a discussion on the neurosurgical guidelines and techniques to manage and treat this disease. Each chapter in the *Diagnostic Techniques and Surgical Management of Brain Tumors* is authored by international experts with extensive experience in the areas covered.

How to reference

In order to correctly reference this scholarly work, feel free to copy and paste the following:

Susan C. Pannullo, Cecile Yama and A. Gabriella Wernicke (2011). Stereotactic Radiosurgery for Brain Tumors, *Diagnostic Techniques and Surgical Management of Brain Tumors*, Dr. Ana Lucia Abujamra (Ed.), ISBN: 978-953-307-589-1, InTech, Available from: <http://www.intechopen.com/books/diagnostic-techniques-and-surgical-management-of-brain-tumors/stereotactic-radiosurgery-for-brain-tumors>

INTECH
open science | open minds

InTech Europe

University Campus STeP Ri
Slavka Krautzeka 83/A
51000 Rijeka, Croatia
Phone: +385 (51) 770 447
Fax: +385 (51) 686 166
www.intechopen.com

InTech China

Unit 405, Office Block, Hotel Equatorial Shanghai
No.65, Yan An Road (West), Shanghai, 200040, China
中国上海市延安西路65号上海国际贵都大饭店办公楼405单元
Phone: +86-21-62489820
Fax: +86-21-62489821

© 2011 The Author(s). Licensee IntechOpen. This chapter is distributed under the terms of the [Creative Commons Attribution-NonCommercial-ShareAlike-3.0 License](#), which permits use, distribution and reproduction for non-commercial purposes, provided the original is properly cited and derivative works building on this content are distributed under the same license.

IntechOpen

IntechOpen