

We are IntechOpen, the world's leading publisher of Open Access books Built by scientists, for scientists

5,200

Open access books available

129,000

International authors and editors

155M

Downloads

Our authors are among the

154

Countries delivered to

TOP 1%

most cited scientists

12.2%

Contributors from top 500 universities



WEB OF SCIENCE™

Selection of our books indexed in the Book Citation Index
in Web of Science™ Core Collection (BKCI)

Interested in publishing with us?
Contact book.department@intechopen.com

Numbers displayed above are based on latest data collected.
For more information visit www.intechopen.com



An Infected Drug-Eluting Stented Coronary Aneurysm Forming Intracardiac Fistula

Ken Kishida

*Department of Metabolism and Atherosclerosis,
Graduate School of Medicine, Osaka University, Osaka
Japan*

1. Introduction

Many cardiologists have usually operated percutaneous coronary intervention (PCI) for coronary artery disease practically. Sometimes, complications following stent implantation rarely include thrombosis, rupture, sepsis and infected coronary aneurysm [Baddour, 2004; Berkalp, 1999]. Particularly, infected coronary aneurysm causes fatal outcome. In addition to contamination at the time of catheterization, there are other mechanisms how stents can become infected, including transient bacteremia from skin flora via access-site hematomas, pseudoaneurysms, delayed bleeding, prolonged arterial sheath insertion, and several procedures performed from the same access site over a short time period [Baddour, 2004]. Previous report demonstrated that 18% of patients who underwent complex PCIs had detectable bacteremia [Ramsdale, 2004]. However, prophylactic antibiotics administrations are not conducted routinely prior to coronary stenting in the current PCI procedures, because the incident rate of stent infections was reported to be less than one in 10,000 cases [Myles, 2000].

The drug-eluting stent (DES) era was ushered in with the first published human study by Sousa *et al.* in 2001, showing a nearly complete abolition of neointimal hyperplasia by use of sirolimus-eluting stent (SES) [Sousa, 2001]. The role of DES is very questionable, because of long term anticoagulant therapy, but in the patients with comorbidity (diabetes mellitus) DES are recommend. Despite the dramatic capacity of SES to reduce the restenosis rate after PCI, several SES-related problems have been raised [Ong & Serruys, 2005]; 1) the requirement of a prolonged dual anti-platelet regimen to avoid the risk of DES thrombosis [McFadden, 2004], 2) the occurrence of acquired late malapposition 3) the late formation of coronary artery aneurysm (SES having an antiproliferative action may be responsible for the delayed and inappropriate healing, which should lead to weakening of the arterial wall and delayed aneurysm formation) [Abreu, 2005; Degertekin, 2003], 4) a severe localized hypersensitivity consisting predominantly of T lymphocytes and eosinophils, which was caused by the metallic stent, polymer, or sirolimus [Virmani, 2004; Nebeker, 2005; Stabile, 2004].

2. Case report

A 70-year-old man with hypertension, type 2 diabetes mellitus, mild renal dysfunction and old cerebral infarction, was admitted to our hospital with sustained angina. The patient

suffered an inferior wall ST-depression unstable angina that required immediate PCI with two SESs (Cypher[®], Cordis Johnson & Johnson, Japan) in the proximal right coronary artery (RCA) (Figure 1). Satisfactory angiographic results were obtained with smooth luminal outline, and then the arterial sheath was removed (Figure 1). The patient had other significant stenosis lesions in the proximal left anterior descending artery (LAD) and the middle circumflex artery (LCX).

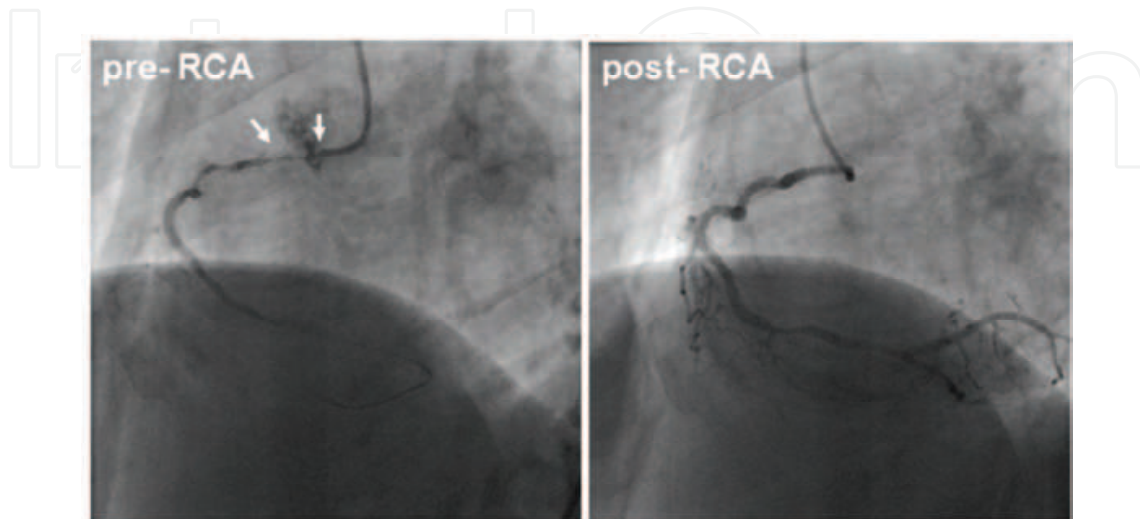


Fig. 1. Right coronary artery angiogram performed during the initial procedure. Preangioplasty (left anterior oblique (LAO) view): the RCA was affected with severe stenosis in the proximal site (arrow) (A). The RCA was opened and SESs was inserted (B). Satisfactory angiographic results were obtained with smooth luminal outline. No contrast extravasation outside the vessel wall was noted on the image [Reproduced Kishida, 2007].

Next day after the procedure, this patient had fever without suppuration on the access site, and grew *Staphylococcus aureus* on repeat blood cultures. Despite exhaustive screenings for a potential source of the infection, no infectious focus was detected. The patient was treated with intravenous adapted antibiotics, however, remained poor.

Three weeks after PCI, the patient had fever, convulsion and syncope attack with the torsades de pointes in ECG. The causes were considered due to trouble of the residual left coronary arteries (LCAs) lesions, and the patient was successfully implanted two SESs in the target LAD stenosis and a SES in the target LCX stenosis. The postprocedural course was uneventful, and the inflammatory sings were improved by the treatment with adapted antibiotics.

Two months later, the patient has recurrence fever with eosinophilia and an inferolateral wall ST-depression angina. Coronary angiography revealed no obvious changes in the LCAs, but an occluded proximal RCA stent, a large aneurysm off the stent, and a fistula into the right ventricular chamber with rapid clearance (Figure 2). A 16-slice multidetector computed tomographic angiogram scan confirmed both an occluded proximal RCA, and the aneurysm (50x30 mm in size) forming fistula (10 mm in size) into right ventricle (Figure 3).

The patient underwent a resection of the RCA stents and aneurysm, and a reconstruction of the right ventricular wall without coronary bypass grafting. Microscopic specimen from the resected aneurismal wall revealed an extensive inflammatory reaction with a predominance of neutrophils consistent with the micro-abscess (Figure 4). The patient is doing well 5 years after operation [Kishida, 2007].

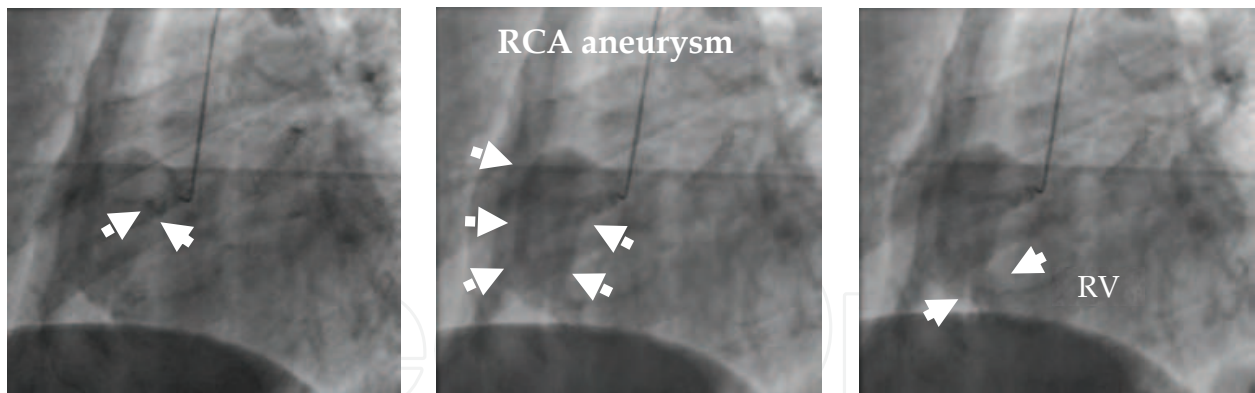


Fig. 2. Right coronary artery angiogram performed at the fever period

Angiography of the RCA demonstrated occlusion of proximal stent site, an entry point to aneurysm, and the saccular aneurysm in the area of proximal stents and its coronary artery fistula originating from the RCA stents, with contrast spillage into the right ventricular chamber through the fistula. Rapid clearance of contrast was observed, with none in the pericardial space [Reproduced Kishida, 2007].

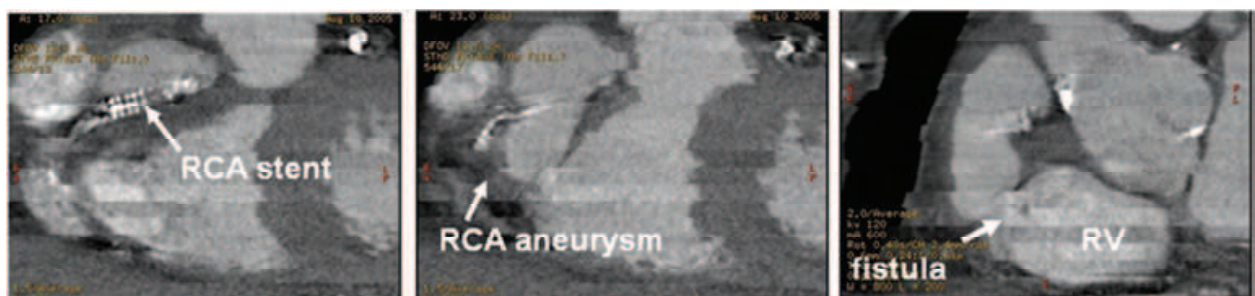


Fig. 3. The 16-slice multidetector computed tomographic angiogram disclosed huge RCA aneurysm (10x10 mm in diameter) and draining image into right ventricular chamber via fistula [Reproduced Kishida, 2007].

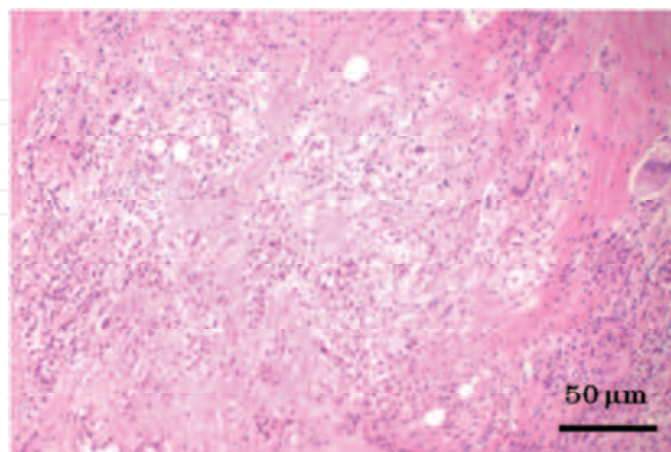


Fig. 4. Histopathology from pseudoaneurysm after surgical excision. Its histopathologic examination revealed marked inflammatory reaction with a predominance of neutrophils consistent with an abscess. Hematoxylin and eosin staining. (original magnification, x200) [Reproduced Kishida, 2007].

2.1 Comments for case report

To date, there have been only 7 reported cases of infected drug-eluting stented coronary aneurysm, including our case [Kishida, 2007; Marcu, 2005; Alfonso, 2006; Singh, 2005; Jang, 2007; Le, 2007; Furutado, 2011] (Table 1). In six cases *Staphylococcus aureus* and one *Pseudomonas aeruginosa* bacteremia was responsible for causing mycotic stent complications. Of these cases, there were two cases of an infected drug-eluting stented coronary aneurysm forming fistula to cardiac chamber. The mechanism of infection at the site of drug-eluting stenting is not well understood. Potential caused for drug-eluting coronary stent infections include local suppression of immune response and endothelialization which should lead to weakening of the arterial wall and delayed aneurysm formation [Degertekin, 2003]. The potential role of SES in locally blunting the innate response to bacterial agents may be considered. Formation of mycotic aneurismal fistula in our case may be partly accounted for by this mechanism.

Case	Vessel	Stent	Fistula	Organism	Days	Max size	Ope	Outcome	Reference
55yo Male	LAD	P	—	<i>S. aureus</i>	90	15	+	Alive	2005 Marcu
47yo Male	RCA	S	—	<i>S. aureus</i>	2	—	—	Dead	2005 Alfonso
56yo Male	LAD	S	—	<i>S. aureus</i>	30	28	+	Alive	2005 Singh
70yo Male	RCA	S	RV	<i>S. aureus</i>	120	50	+	Alive	2005 our case
54yo Male	RCA	P	RA	<i>S. aureus</i>	120	—	+	Alive	2007 Jang
73yo Male	LCX	S	—	<i>S. aureus</i>	90	5	+	Dead	2007 Le
62yo Male	LAD	S	—	<i>P. aeruginosa</i>	20	20	+	Alive	2011 Furtado

P: paclitaxel eluting stent, S: sirolimus eluting stent, RA: right atrium, RV: right ventricle, S.:*Staphylococcus*., P.: *Pseudomonas*., Days: onset of aneurysm, Max size (mm): max diameter of aneurysm, Ope: surgical operation

Table 1. Infected drug-eluting stented coronary aneurysm

3. Conclusion

Infections specificity, related to the use of intracoronary DESs, is exceedingly rare. However, stent infection should be considered in the differential diagnosis of patients presenting unexplained fever and relapsing bacteremia at any time following drug-eluting stenting.

4. References

- Baddour LM, et al. (2004) Nonvalvular cardiovascular device-related infections. *Clinical Infectious Diseases*. Vol.38, No.8, (April 2004), pp.1128-1130
- Berkalp B, et al. (1999) Coronary artery aneurysm formation after balloon angioplasty and stent implantation. *International Journal of Cardiology*. Vol.69, No.1, (April 1999), pp.65-70
- Ramsdale DR, et al. (2004) Bacteremia following complex percutaneous coronary intervention. *The Journal of Invasive Cardiology*. Vol.16, No.11, (Nov 2004), pp. 632-634

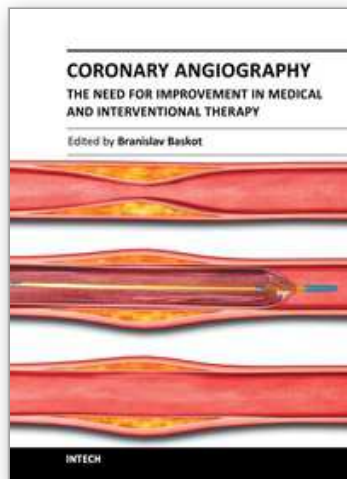
- Myles O, et al. (2000) Infected endovascular stents managed with medical therapy alone. *Catheterization and Cardiovascular Interventions*. Vol.51, No.4, (Dec 2000), pp.51: 471-476
- Sousa JE, et al. (2001) Lack of neointimal proliferation after implantation of sirolimus-coated stents in human coronary arteries: a quantitative coronary angiography and three-dimensional intravascular ultrasound study. *Circulation*. Vol.104, No.17, (Oct 2001), pp.192-195
- Ong AT & Serruys PW. (2005) Drug-eluting stents: current issues. *Texas Heart Institute Journal*. Vol.32, No.3, pp372-377
- McFadden EP, et al. (2004) Late thrombosis in drug-eluting coronary stents after discontinuation of antiplatelet therapy. *Lancet*. Vol.364, No.9444, (Oct 2004), pp1519-1521
- Abreu L, et al. (2005) Coronary artery aneurysm one year and five months after sirolimus-eluting stent placement. *Arquivos Brasileiros de Cardiologia*. Vol.85, No.8, (Nov 2005) pp.340-342
- Degertekin M, et al. (2003) Long-term follow-up of incomplete stent apposition in patients who received sirolimus-eluting stent for de novo coronary lesions: an intravascular ultrasound analysis. *Circulation*. Vol.108, No.22, (Dec 2003) pp.2747-2750
- Virmani R, et al. (2004) Localized hypersensitivity and late coronary thrombosis secondary to a sirolimus-eluting stent: should we be cautious? *Circulation*. Vol.109, No.6, (Feb 2004) pp.701-705
- Nebeker JR, et al. (2005) Hypersensitivity cases associated with drug-eluting coronary stents: a review of available cases from the Research on Adverse Drug Events and Reports (RADAR) project. *Journal of the American College Cardiology*. Vol.47, No.1, (Jan 2006), pp175-181
- Stabile E, et al. (2004) Marked malapposition and aneurysm formation after sirolimus-eluting coronary stent implantation. *Circulation*. Vol.110, No.5, (Aug 2004), pp47-48
- Kishida K, et al. (2007) Successful surgical treatment of an infected right coronary artery aneurysm-to-right ventricle fistula after sirolimus-eluting stent implantation. *Internal Medicine*. Vol.46, No.12, (Jun 2007), pp865-871
- Marcu CB, et al. (2005) Post-infectious pseudoaneurysm after coronary angioplasty using drug eluting stents. *Heart Lung & Circulation*. Vol.14, No.2, (Jun 2005), pp85-86
- Alfonso F, et al. (2006) Mycotic aneurysms after sirolimus-eluting coronary stenting. *Catheterization and Cardiovascular Interventions*. Vol.67, No.2, (Feb 2006), pp327-328
- Singh H, et al. (2005) Mycotic aneurysm of left anterior descending artery after sirolimus-eluting stent implantation: a case report. *Catheterization and Cardiovascular Interventions*. Vol.65, No.2, (Jun 2005), pp282-285
- Jang JJ, et al. (2007) Images in cardiovascular medicine. Pseudoaneurysm and intracardiac fistula caused by an infected paclitaxel-eluting coronary stent. *Circulation*. Vol.116, No.14, (Oct 2007), pp364-365
- Le MQ & Narins CR. (2007) Mycotic pseudoaneurysm of the left circumflex coronary artery: a fatal complication following drug-eluting stent implantation. *Catheterization and Cardiovascular Interventions*. Vol.69, No.4, (Mar 2007), pp508-512

Furtado AD, et al. (2011) Infected pseudoaneurysm involving a drug-eluting stent. *Interactive Cardiovascular and Thoracic Surgery*. Vol.12, No.4, (Apr 2011), pp636-638.

This research was supported in part by a Grant-in-Aid for Scientific Research on Innovative Areas No. 22126008.

IntechOpen

IntechOpen



Coronary Angiography - The Need for Improvement in Medical and Interventional Therapy

Edited by Prof. Baskot Branislav

ISBN 978-953-307-641-6

Hard cover, 206 pages

Publisher InTech

Published online 06, September, 2011

Published in print edition September, 2011

In this book we examined a periprocedural complication of coronary angiography, and coronary intervention. That includes related to cardiac catheterization and diagnostic coronary angiography, and those that occur as a consequence of the specific equipment. However, improvements in devices, the use of stents, and aggressive antiplatelet therapy have significantly reduced the incident of major periprocedural complications. This book giving knowledge and experiences many of interventional cardiologists from all over the world, and provide possibility to recognize new approach in this domain. Book gives lecture on how we image and how we decide on what to treat, how to treat it, and then results of that treatment. They offer many answers to what we have today and what we will have tomorrow.

How to reference

In order to correctly reference this scholarly work, feel free to copy and paste the following:

Ken Kishida (2011). An Infected Drug-Eluting Stented Coronary Aneurysm Forming Intracardiac Fistula, *Coronary Angiography - The Need for Improvement in Medical and Interventional Therapy*, Prof. Baskot Branislav (Ed.), ISBN: 978-953-307-641-6, InTech, Available from:

<http://www.intechopen.com/books/coronary-angiography-the-need-for-improvement-in-medical-and-interventional-therapy/an-infected-drug-eluting-stented-coronary-aneurysm-forming-intracardiac-fistula>

INTECH
open science | open minds

InTech Europe

University Campus STeP Ri
Slavka Krautzeka 83/A
51000 Rijeka, Croatia
Phone: +385 (51) 770 447
Fax: +385 (51) 686 166
www.intechopen.com

InTech China

Unit 405, Office Block, Hotel Equatorial Shanghai
No.65, Yan An Road (West), Shanghai, 200040, China
中国上海市延安西路65号上海国际贵都大饭店办公楼405单元
Phone: +86-21-62489820
Fax: +86-21-62489821

© 2011 The Author(s). Licensee IntechOpen. This chapter is distributed under the terms of the [Creative Commons Attribution-NonCommercial-ShareAlike-3.0 License](#), which permits use, distribution and reproduction for non-commercial purposes, provided the original is properly cited and derivative works building on this content are distributed under the same license.

IntechOpen

IntechOpen