

We are IntechOpen, the world's leading publisher of Open Access books Built by scientists, for scientists

5,000

Open access books available

125,000

International authors and editors

140M

Downloads

Our authors are among the

154

Countries delivered to

TOP 1%

most cited scientists

12.2%

Contributors from top 500 universities



WEB OF SCIENCE™

Selection of our books indexed in the Book Citation Index
in Web of Science™ Core Collection (BKCI)

Interested in publishing with us?
Contact book.department@intechopen.com

Numbers displayed above are based on latest data collected.
For more information visit www.intechopen.com



Sentinel Skin Allograft for Monitoring of Composite Tissue Transplants Rejection

Zamfirescu DG¹, Lascar I¹ and Lanzetta M²

¹*Carol Davila Bucharest Medical University*

²*University of Canberra*

¹*Romania*

²*Australia*

1. Introduction

In contrast to visceral solid-organ transplants, a vascularized composite tissue allograft (CTA) is not a single tissue, and is histologically heterogeneous. It is a neurovascularized module of nonvital tissues which include structural, functional and aesthetic units. CTAs are composed of a large spectrum of ectodermal tissues: epidermis and epidermal derivatives such as nails and hair, nerves and mesodermal tissues such as dermis, muscles, bones, articular cartilage, ligaments, tendons and paratenon and other supportive and connective tissues, adipose tissue, vessels. In addition there are hematopoietic tissues and cells from bone marrow and lymph nodes and these latter elements are immunocompetent. Each tissue has differing antigenicity, displays different antigen expression and presentation mechanisms. As a result, CTAs elicit nonsynchronized immune responses, of differing intensity, among their tissue components.

So far only 135 CTA transplantations were carried out on human patients: 68 hand transplantations (49 patients), 12 abdominal wall transplantations, 9 bone and vascularized articulations transplantations, 7 peripheral nerves, 2 tendons, 23 larynxes, 1 right abdominal muscle, 1 tongue, a lobe made of the cephalic cervical skin and 2 ears, and 11 faces.

The transplantation of a composite tissue allograft is only justified when excellent functional outcome can be achieved. This aim is more important for CTAs than for organ allografts as the procedure is not lifesaving and lifelong immunosuppressive therapy, with its associated risks and side effects, is difficult to justify. Even mild and reversible rejection episodes can decrease the chance of a favorable outcome.

Skin is an important component of a CTA and is the most immunogenic of the component tissues. The skin is more sensitive to rejection than any other tissues or visceral organ, and the primary reason is probably its unique immunologic defense function, with its special intrinsic antigenic and immunologic properties. Boss et al. identified these properties as "the skin immune system" and demonstrate, that the skin is not only the largest organ in the body but is itself an immunologic effector organ, with almost half its cells belonging or related to the immune system (especially the large quantity of dendritic cells within epidermis and dermis). For CTAs the best marker of rejection is by visual and histopathological examination of the skin, as it is the skin that is first involved in the rejection process.

Skin is an important component of a CTA and is the most immunogenic of the component tissues. The skin is more sensitive to rejection than any other tissues or visceral organ, and

the primary reason is probably its unique immunologic defense function, with its special intrinsic antigenic and immunologic properties. Boss et al. identified these properties as "the skin immune system" and demonstrate, that the skin is not only the largest organ in the body but is itself an immunologic effector organ, with almost half its cells belonging or related to the immune system (especially the large quantity of dendritic cells within epidermis and dermis). For CTAs the best marker of rejection is by visual and histopathological examination of the skin, as it is the skin that is first involved in the rejection process.

Monitoring of CTA rejection is facilitated because the first tissue to be rejected is the skin, which is the outermost tissue of a CTA. Skin biopsy provides a more specific diagnosis to confirm the visual assessment but delays diagnosis. Repeated skin biopsies also lead to scarring that represents a considerable aesthetic problem in the case of a hand or face transplants. The ideal marker of CTA rejection should therefore obviate the need for biopsy of the transplant and provide easily warning of rejection of the graft itself. Early detection of the first stages of rejection enables advanced administration of salvage therapy, resulting in a rapid and efficient reversal of rejection.

2. Distant sentinel skin allograft (DSSG) - experimental study

Some studies report a more rapid rejection of isolated skin grafts compared to rejection of skin that is part of a CTA. This has led us to examine the use of distant sentinel skin allograft (DSSG) of donor origin transplanted simultaneously with a limb, as a marker of rejection.

In one of our studies, using a hind limb transplantation model in rats we demonstrated that the DSSG serves as a predictive marker for visual assessment, as well as a site for repeated biopsies that does not damage the CTA itself.

Sixty rats with hind limb transplants were included in this study. They were divided into two groups. Group 1 (n=15) received limb transplants and immunosuppressive therapy (control group). Group 2 (n=45) received a limb transplant and a simultaneous sentinel skin graft, plus immunosuppressive therapy.

Surgical procedure

Brown Norway (BN) rats served as donors and Lewis rats as recipients of orthotopic hind limb transplants and free skin flap allografts. The previously described surgical technique for limb replantation and transplantation was used.⁷⁻¹¹ A free full thickness skin graft 4 cm x 5 cm was obtained from the abdominal region of BN donors and transplanted to the inter

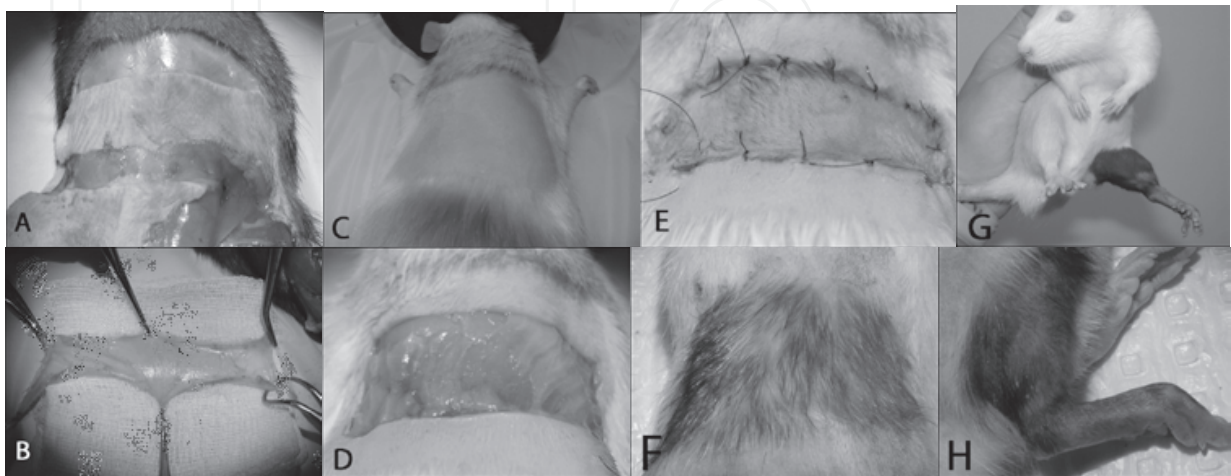


Fig. 1. Full thickness sentinel skin allograft and the hind limb transplantation

scapular region of LEW recipient rats. Special attention was given to preserve the panniculus carnosus and to apply the skin graft directly to this highly vascular tissue (**Fig 1**). **A-F** 4 x 5 cm full thickness skin graft harvested from the abdominal region of BN donor. DSSG transplanted to the inter-scapular region of LEW recipient rats. Special attention was given to preserve the **panniculus carnosus** (**D**) and to apply the skin graft on this highly vascular tissue. **G, H** The hind limb allotransplant

Immunosuppressive drug regime

All animals received standard immunosuppressive therapy, consisting of the triple drug combination with the first administration provided on the operative day. We used the standard regime consisting of FK506 (Prograf[®] Janssen-Cilag) 2 mg/kg/day; MMF (CellCept[®], Roche Products) 15 mg/kg/day and Prednisone (PredMix[®], oral liquid 5 mg/ml. Archpend) 0.5 mg/kg/day administered in 1 ml saline by oral gavage for 6 weeks. This time was sufficient to allow for complete healing of the skin graft and limb transplant, after which, all drugs were stopped. Salvage therapy was administered for early rejection episodes upon the first visual signs of rejection of the sentinel skin graft or of the transplanted limb skin. This consisted of FK506 10 mg/kg/day; MMF 30 mg/kg/day and Prednisone 0.5 mg/kg/day. Salvage therapy was administered for 3 days, followed by the optimal drug regime until signs of rejection were reversed.

Visual monitoring of rejection

The skin of transplanted limbs and skin allografts was monitored twice a day for any signs of rejection, including erythema, changes in texture of the skin, desquamation, epidermolysis, edema, exudation and skin necrosis. After the withdrawal of immunosuppression rejection was assessed based on a new clinical (visual) and histologic grading system that was focused to more accurately describes the very early signs of skin rejection. Rejection was assigned visually, based on changes in color and texture of the skin in most clinically affected skin area.

Histological evaluation of the rejection

Tissue specimens were taken after withdrawal of immunosuppressive therapy, at the first signs of skin graft or limb skin rejection. Skin biopsies were fixed in 10% Neutral Buffered Formalin before transfer to 70% ethyl alcohol. Tissue samples were embedded in paraffin for routine light histological examination. Sections were stained with hematoxylin and eosin. A pathologist (CAL) read all the slides in a blinded fashion and scored the sections based on a proprietary histologic grading system. Rejection was assigned histologically, based on changes in the most immunoreactive zone on the histological slides.

3. Results

One month post-operatively the skin grafts were well healed, with stable size and shape. To facilitate observation, hair from the skin graft and limb was removed with a depilatory cream at the end of the 6th postoperative week. This caused only a slight skin inflammation observed for one day in 3 rats.

Visual rejection episodes in controls

After the withdrawal of immunosuppression rejection was assessed based on a newly developed clinical (visual) and histologic grading system that was aimed to more accurately describes the very early signs of skin rejection. Rejection was assigned visually and histologically, based on changes in color and texture of the skin in most clinically affected

skin area and in the most immunoactive zone on the histological slides. The details of this visual scoring system are shown in (Table 1).

Grade 0 No rejection	Normal epidermal and dermal appearance without evidence of rejection
Grade 1 Indeterminate/ supposed rejection	Very early visual signs of rejection Focal (<25% of limb or DSSG surface) inconspicuous changes in the skin color (pink/pinkish or slight red/reddish spots) and/or in the texture of the skin (dryness, fine scaling of epidermis)
Grade 2 Mild rejection	Clear visual signs of rejection Diffuse (25-50 % of DSSG or limb skin surface) clear changes in color and texture of skin, sometimes with slight limb edema, thickening of the skin
Grade 3 Moderate rejection	Extensive (more than 50% of DSSG or limb skin surface) and advances alteration of skin quality – desquamation, scabs, skin crusts
Grade 4 Severe rejection	Destruction of epidermis with intact dermis or complete destruction of the skin

Table 1. Visual grading system for assessment of rejection

Three animals (20%) showed early rejection and salvage therapy was successful in all cases. One of rats developed a second rejection episode, successfully treated with salvage therapy. In two of these three rats skin damage after resolution of rejection prevented assessment of grades 1 and 2 rejection do to incomplete or deficient healing. The remaining 12 rats (80%) were free of rejection during the treatment period.

The average time for the onset of grade 1 rejection in limb skin after immunosuppression ceased was 6.75 ± 1.42 days (median day 6.5) and 8.75 ± 2.38 days (median day 8) for grade 2. The mean interval between the onset of grade 1 and the development of grade 2 rejection in limb skin was 2 ± 1.35 days for rats free of early rejection (n= 12).

Visual rejection episodes in group 2 (rats with limb transplant and DSSG)

During the first 6 weeks 28 rats (62%) were rejection free. Seventeen rats (38%) developed early rejection. Thirteen rats (29%) were excluded from the study due to the poor quality of skin due to incomplete or deficient healing after salvage therapy. In total, 32 rats, 28 without early rejection episodes and 4 rats with one episode of very early or early rejection, successfully reversed with salvage therapy, were evaluated after termination of immunosuppressive therapy (Fig 2).

The average onset grade 1 rejection was 5.06 days (median day 5) for DSSG, and 6.41 days (median day 6) for limb skin. The average interval between grade 1 rejection of the skin graft and grade 1 rejection of the limb skin was 1.35 days. Rats evaluated in group 2 displayed a strong statistic difference in the onset of grade 1 rejection of the skin graft and the limb skin ($p < 0.0005$).

The average onset grade 2 rejection was 8.28 days (median day 8) for DSSG, and day 9.21 7 (median day 9) for limb skin. The interval between grade 2 rejection of the skin graft and grade 2 rejection of the limb skin was 0.91 days. There was a small but statistically

significant difference between the first day with visual signs of grade 2 rejection of the skin graft and the limb skin ($p < 0.05$).

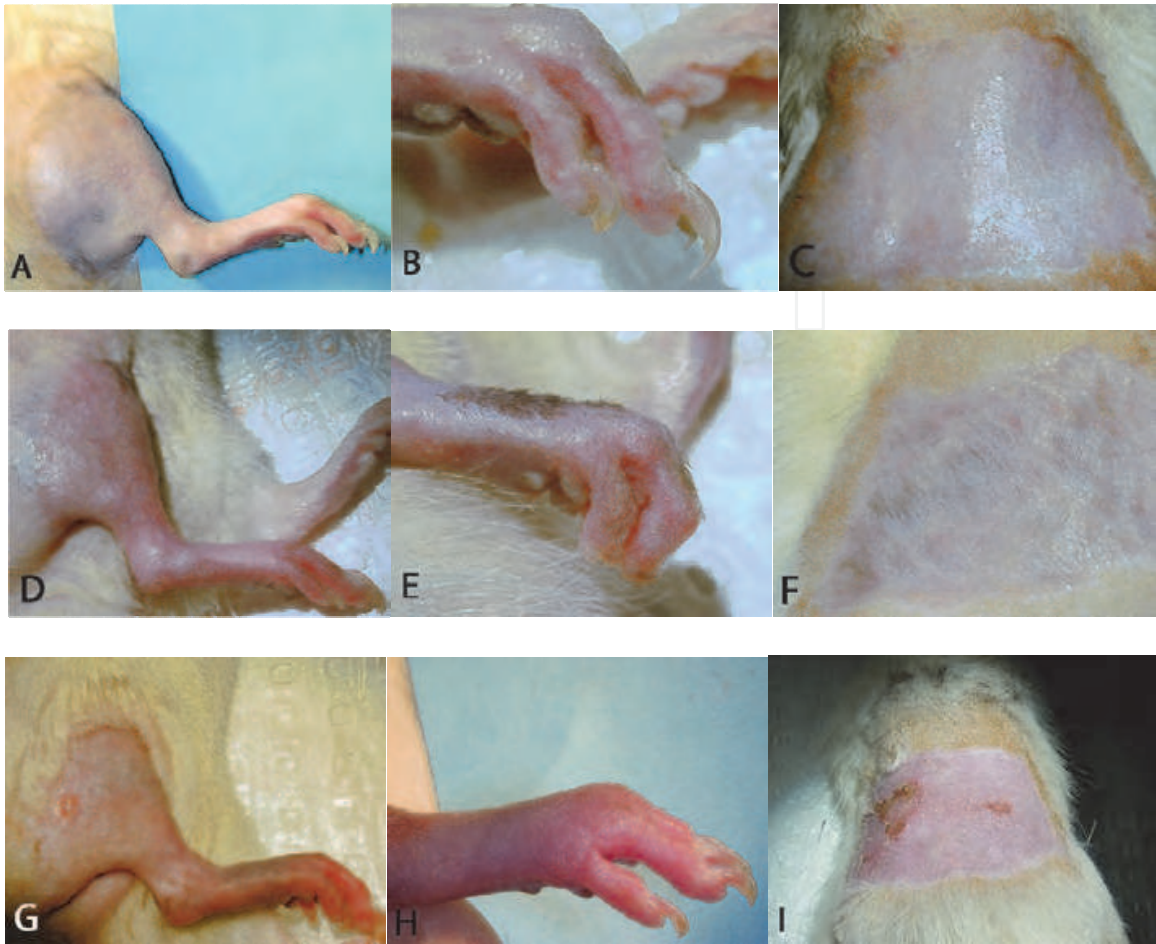


Fig. 2. Clinical (visual) aspect of rejection on the limb skin and on the DSSG in the earlier stages of rejection **A, B, C** *Grade 0 (No rejection)* - Normal epidermal and dermal appearance without evidence of rejection **D, E, F** *Grade 1 (Inconspicuous / indeterminate / supposed rejection)* - Very early visual signs of rejection; Focal (<25% of limb or DSSG surface) inconspicuous changes in the skin color (pink/pinkish or slight red/reddish spots) and/or in the texture of the skin (dryness, fine scaling of epidermis) **G, H, I** *Grade 2 (Mild rejection)* - Clear visual signs of rejection; Diffuse (25-50 % of DSSG or limb skin surface) clear changes in color and texture of skin, sometimes with slight limb edema, thickening of the skin

The time difference between the onset of grade 1 rejection and the development of grade 2 rejection was on average 3.4 days for DSSG and 2.9 days for limb skin. There was no significant difference between grades 1 or 2 rejection of the limb skin of control animals and rats with both a limb transplant and sentinel skin graft. As a result, we conclude that application of a skin allograft does not influence the rejection of a transplanted limb.

Histologic rejection results

161 biopsies from 45 animals were evaluated histologically for signs of rejection. Specimens were taken for suspected rejection or when the visual grade appeared to alter. Samples were

taken concurrently, from both the sentinel skin graft and limb allograft. Rejection was assigned histologically, based on changes in the most immunoactive zone on the histological slides. All slides were analyzed in a blinded fashion and scored based on a new histologic grading system. The new grading system was introduced to describe the very early changes in skin pathology observed during onset of rejection. The criteria used for histologic assessment of skin rejection are shown in (Table 2, Fig 3).

Grade 0	Normal epidermal and dermal appearance without evidence of rejection Dermal mononuclear cell infiltration < 10 cells / 500X optic field
Grade 1 Indeterminate rejection	Dermal mononuclear cell infiltration 10-20 cells / 500X optic field Epidermal (especially on epidermo-dermal junction) mononuclear cells infiltration 1-3 cells / 200X optic field
Grade 2 Mild rejection	Diffuse intercellular edema (spongiosis) on basal layer of epidermis with normal continuity of epidermo-dermal junction Dermal mononuclear cell infiltration 10-20 cells / 500X optic field Epidermal (especially on epidermo-dermal junction) mononuclear cells infiltration > 3 cells / 200X optic field
Grade 3 Moderate rejection	Discontinuity of epidermo-dermal junction Focal basal cells vacuolization Dermal mononuclear cell infiltration more than 20 cells / 500X optic field Epidermal (especially on epidermo-dermal junction) mononuclear cells infiltration > 3 cells / 200X optic field Intercellular edema on basal layer of epidermis (spongiosis) Dyskeratosis of squamous cells in the epidermis or hair follicle epithelium
Grade 4 Severe rejection	Complete separation at the epidermo dermal junction Complete epidermal degeneration and necrosis Dense inflammatory infiltration in the dermis > 20 cells / 500X optic field

Table 2. Histology grading and scoring system for assessment of rejection

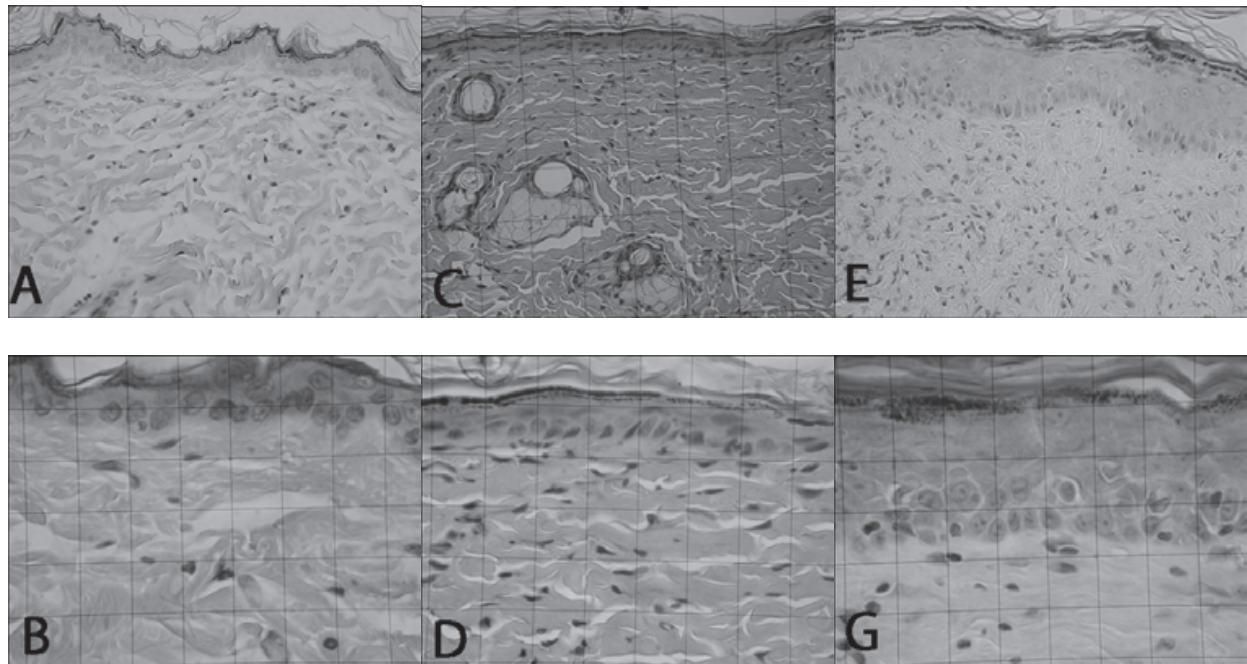


Fig. 3. Histological aspects of rejection in the earlier stages of skin rejection

A, B Grade 0 (H&E; 200x and 500x) Normal epidermal and dermal appearance without evidence of rejection - Dermal mononuclear cell infiltration < 10 cells / 500X optic field **C, D Grade 1** (H&E; 200x and 500x) Indeterminate rejection - Dermal mononuclear cell infiltration 10-20 cells / 500X optic field; Epidermal (especially on epidermo-dermal junction) mononuclear cells infiltration 1-3 cells / 200X optic field **E, G. Grade 2** (H&E; 200x and 500x) Mild rejection - Diffuse intercellular edema (spongiosis) on basal layer of epidermis with normal continuity of epidermo-dermal junction; Dermal mononuclear cell infiltration 10-20 cells / 500X optic field; Epidermal (especially on epidermo-dermal junction) mononuclear cells infiltration > 3 cells / 200X optic field

The average grade of limb rejection noted in 35 samples harvested from 13 control rats was 1.57. In group 2, 126 samples from 32 rats were analyzed. Analyzing the early stages of rejection (grade 0 - 2), for corresponding skin graft and limb skin samples, the average grade of rejection observed for limb skin was 1.08 compared with 1.46 for the skin grafts. The difference in severity of rejection was found to be significant using a paired t test at $p < 0.005$. The higher average grade of rejection seen in sentinel skin infers that rejection develops sooner at this site. This finding confirms the hypothesis that a distant sentinel skin graft rejects before limb skin.

There was no significant difference using an unpaired t-test (p value = 0.86) between the onset of limb skin rejection in groups 1 and 2. The mean rejection grade was 1.57 for group 1 and 1.42 for group 2. This result confirmed visual analysis, and demonstrated that the

sentinel skin graft did not influence the rejection of limb allografts when transplanted simultaneously.

4. Conclusions

In conclusion, these findings confirm a small, but significant delay in rejection of limb skin compared to a DSSG. Skin grafts transplanted simultaneously with a hind limb are thus a useful marker of rejection by providing advanced warning of an impending episode. This allows earlier intervention with salvage therapy and the consequent rapid initiation of therapy that is of benefit in a clinical setting. The DSSG can be placed on a site usually covered by clothing and may obviate the need for biopsies of the transplanted limb, with their associated scarring, functional and aesthetic consequences. The skin DSSG did not appear to significantly alter the incidence or severity of rejection and appear to be safe in this animal model. Modifications of the current visual and histopathological criteria for diagnosis of rejection were introduced to allow early detection.

The concept of DSSG is already applied in clinical settings. A series of three hand transplants performed where patients received an additional simultaneous full-thickness donor skin graft transplanted to the left hip area. This skin was used as a source for skin biopsies and as an additional area for monitoring rejection (distant sentinel skin graft, DSSG). The DSSG used in all three patients proved to be of benefit, allowing prediction of rejection of the hand by as much as 7 days. This allowed appropriate treatment to be started immediately. In one patient, salvage therapy (systemic and topical) was delayed until the hand showed the same clinical and histological signs of rejection. The skin changes resolved completely within 5 days at both locations. In the other two patients salvage therapy was started immediately DSSG showed the onset of rejection and rejection of the hand was not observed. However, the DSSG was of value only in the early postoperative phases. With time DSSG cells were replaced by "creeping substitution" of recipient skin and monitoring value was lost.

In our study, we found that the DSSG showed the first signs of rejection (grade 1), with a delay of 1.35 days before the limb skin detection. Sensitivity was reduced to 0.91 days for grade 2 rejection. The 7 days interval noted in Italian clinical cases, may be explained by a gradual taper of immunosuppressive therapy, rather than the complete withdrawal used in this study.

In the case of the first face transplantation a sentinel radial forearm flap harvested from the donor's left upper limb was transferred to the recipient's left submammary fold and suture end-to-end to the thoracodorsal vessels. This vascularized composite tissue flap, hidden under the hanging breast, was used to monitor indirectly the immunological behavior of the graft, aiming to avoid damage to the reconstructed face by repeated skin biopsies.

5. References

- Andrew Lee W. P., Yaremchuk M J, Pan YC, Randolph MA, Tan CM, Weiland AJ. Relative Antigenicity of Components of a Vascularized Limb Allograft. *Plast Reconstr Surgery*, March 1991, Volume 87, Issue 3

- Askenasy N Localized Bone Marrow Transplantation Leads to Skin Allograft Acceptance in Nonmyeloablated Recipients: Comparison of Intra-Bone Marrow and Isolated Limb Perfusion. *Stem Cells* 2002; 20: 86-93
- Black KS., Hewitt CW., Aniel M., Grisham GR., Caiozzo VJ., Achauer BM. Neuromuscular capabilities in long-term composite tissue allografts. *Transplant Proc* 1988;20:369
- Bos JD, Das PK, Kapsenberg ML. The skin immune system (SIS), 2nd Ed. Boca Raton: CRC Press, 1997
- Buttemeyer R., Jones NJ., Min Z., Rao U. Rejection of the Component Tissues of Limb Allografts in Rats Immunosuppressed with FK506 and Cyclosporine. *Plast Reconstr Surg* 1996;97:139
- Doi K. Homotransplantation of limbs in rats. A preliminary report on an experimental study with nonspecific immunosuppressive drugs. *Plast Reconstr Surgery* 1979 Nov;64(5):613-21
- Guzman-Stein A, Shons AR. Functional recovery in the rat limb transplant model: a preliminary study. *Transplant Proc.* 1987 Feb;19(1 Pt 2):1115-7.
- Hewitt CW, Black KS, Fraser LA, Howard EB, Martin DC, Achauer BM, Furnas DW. Composite tissue (limb) allografts in rats. I. Dose-dependent increase in survival with cyclosporine. *Transplantation.* 1985 Apr; 39(4):360-4.
- Hewitt CW, Black KS, Fraser LA, Howard EB, Martin DC, Achauer BM, Furnas DW. Composite tissue (limb) allografts in rats. I. Dose-dependent increase in survival with cyclosporine. *Transplantation.* 1985 Apr; 39(4):365-8.
- Hewitt CW., Black KS., Aguinaldo AMA., Lin SS., Howard EB. Pathologic alterations in the skin component of composite tissue and skin allografts treated with Cyclosporine. *Transplant Proc* 1988;20:1003
- Jones NF., Heberbraud D., Buttemeyer R., Zhao M., Benhaim P., Rao U. Comparison of Long-Term Immunosuppression for Limb Transplantation Using Cyclosporine, Tacrolimus and Mycophenolate Mofetil: Implications for Clinical Composite Tissue Transplantation. *Plast Reconstr Surg* 2001;107:777
- Kim SK, Aziz S, Oyer P, Hentz VR. Use of cyclosporine-A in allotransplantation of rat limbs. *Ann Plast Surg* 1984; 12: 249-255
- Lanzetta M, Dubernard JM. Hand Transplantation. Springer Milan 2007, 263-268
- Lanzetta M, Dubernard JM. Hand Transplantation. Springer Milan 2007, 425-433
- Llull R. An open proposal for clinical composite tissue allotransplantation. *Transplant Proc* Volume 30, Issue 6, September 1998, 2692-2696
- Press BHJ, Sibley RK, Shons AR. Limb allotransplantation in the rat: extended survival and return of nerve function with continuous cyclosporine/prednisone immunosuppression. *Ann Plast Surg* 1986 1986 Apr;16(4):313-21.
- Scott A. Gruber, Mansour V. Shirbacheh, Jon W. Jones, John H. Barker, Warren C. Breidenbach. Local drug delivery to composite tissue allografts (p 407-411). *Microsurgery* Volume 20 Issue 8 , 357 - 469 (2000)
- Shapiro RI, Cerra FB. A model for reimplantation and transplantation of a complex organ: the rat hind limb. *J Surg Res* 1978;24:501-506

- Zamfirescu DG, Owen E, Lascar I, Molitor M, Zegrea I, Popescu M, Bishop GA, Lauer CA, Simionescu M, Climov M, Lanzetta M., Sentinel skin allograft-a reliable marker for monitoring of composite tissue transplant rejection. *Transplant Proc.* 2009 Mar;41(2):503-8.
- Zdichavsky M, Jones J, Ustuner TE, Ren X, Edelstein J, Maldonado C, Breidenbach WC, Gruber SA, Ray M, Barker JH. Scoring of skin rejection in a swine composite tissue allograft model. *J Surg Res* 1999;85:1-8

IntechOpen

IntechOpen



Skin Grafts - Indications, Applications and Current Research

Edited by Dr. Marcia Spear

ISBN 978-953-307-509-9

Hard cover, 368 pages

Publisher InTech

Published online 29, August, 2011

Published in print edition August, 2011

The procedure of skin grafting has been performed since 3000BC and with the aid of modern technology has evolved through the years. While the development of new techniques and devices has significantly improved the functional as well as the aesthetic results from skin grafting, the fundamentals of skin grafting have remained the same, a healthy vascular granulating wound bed free of infection. Adherence to the recipient bed is the most important factor in skin graft survival and research continues introducing new techniques that promote this process. Biological and synthetic skin substitutes have also provided better treatment options as well as HLA tissue typing and the use of growth factors. Even today, skin grafts remain the most common and least invasive procedure for the closure of soft tissue defects but the quest for perfection continues.

How to reference

In order to correctly reference this scholarly work, feel free to copy and paste the following:

Zamfirescu DG, Lascar I and Lanzetta M (2011). Sentinel Skin Allograft for Monitoring of Composite Tissue Transplants Rejection, Skin Grafts - Indications, Applications and Current Research, Dr. Marcia Spear (Ed.), ISBN: 978-953-307-509-9, InTech, Available from: <http://www.intechopen.com/books/skin-grafts-indications-applications-and-current-research/sentinel-skin-allograft-for-monitoring-of-composite-tissue-transplants-rejection>

INTECH
open science | open minds

InTech Europe

University Campus STeP Ri
Slavka Krautzeka 83/A
51000 Rijeka, Croatia
Phone: +385 (51) 770 447
Fax: +385 (51) 686 166
www.intechopen.com

InTech China

Unit 405, Office Block, Hotel Equatorial Shanghai
No.65, Yan An Road (West), Shanghai, 200040, China
中国上海市延安西路65号上海国际贵都大饭店办公楼405单元
Phone: +86-21-62489820
Fax: +86-21-62489821

© 2011 The Author(s). Licensee IntechOpen. This chapter is distributed under the terms of the [Creative Commons Attribution-NonCommercial-ShareAlike-3.0 License](#), which permits use, distribution and reproduction for non-commercial purposes, provided the original is properly cited and derivative works building on this content are distributed under the same license.

IntechOpen

IntechOpen