Chapter

Deleterious Facial Effects Caused by Noninvasive Ventilation Mask Early Treatment, in Congenital Muscular Dystrophy

David Andrade, Maria-João Palha, Ana Norton, Viviana Macho, Rui Andrade, Miguel Palha, Sandra Bussadori, Lurdes Morais and Manuela Santos

Abstract

Neuromuscular disorders is a general term that encompasses a large number of diseases with different presentations. Progressive muscle weakness is the predominant condition of these disorders. Respiratory failure can occur in a significant number of diseases. The use of devices to assist ventilation is quite frequent in these types of patients. Noninvasive ventilation can be applied by various means, including nasal, oronasal, or facial masks. Masks, type bilevel positive airway pressure, continuous positive airway pressure, and similar are generally supported on the maxilla. Oral health in pediatric neuromuscular diseases has some peculiar aspects that we must consider in these patients' follow-up. Based on a clinical case, this chapter provides a better understanding of these patients. It will focus on the oral and maxillofacial morphological alterations and preventive measures and strategies for oral pathologies management in this population. Despite always aiming at esthetics, treating these patients should always prioritize the possibilities of improving the oral and general functions of the body.

Keywords: neuromuscular diseases, congenital muscular dystrophy, noninvasive ventilation, clinical case, adverse effects, palatal expansion technique, extraoral traction appliances, pediatric dentistry, maxillary retrusion, airway obstruction

1. Introduction

Neuromuscular disorders (NMD) is a general term that encompasses a large number of diseases with different presentations.

Progressive muscle weakness is the predominant condition of these disorders. Respiratory failure can occur in a significant number of diseases. The use of devices to assist ventilation is quite frequent in these types of patients. Noninvasive ventilation (NIV) can be applied by various means, including nasal, oronasal, or facial masks.

Masks, type bilevel positive airway pressure (BiPAP), continuous positive airway pressure (CPAP), and similar are generally supported on the maxilla.

Long-term noninvasive ventilation (LTNIV) has been increasingly used in children to manage chronic respiratory failure and airway obstruction. Interfaces are of paramount importance for NIV effectiveness and patient compliance. Factors such as the child's age, disease, craniofacial conformation, type of ventilator and ventilation mode, and children's and family's preferences should be considered when selecting the appropriate mask. Adverse events such as skin lesions, facial growth impairment, and leaks must be prevented and promptly corrected. Humidification is a controversial issue on NIV, but it may be helpful in certain circumstances. Regular cleaning and disinfection of interfaces and equipment must be addressed. During follow-up, educational programs, close supervision, and continuous support to children and families are crucial to the success of LTNIV therapy [1].

Oral health in pediatric neuromuscular diseases has some peculiar aspects that we must consider in these patients' follow-up. Based on a clinical case, this chapter provides a better understanding of these patients. It will focus on the oral and maxillofacial morphological alterations and preventive measures and strategies for oral pathologies management in this population. Despite always aiming at esthetics, treating these patients should always prioritize the possibilities of improving the oral and general functions of the body.

Also, future research on the oral health of patients will be discussed.

2. Neuromuscular disorders

Neuromuscular disorders (NMDs) include conditions affecting the anterior horn cell (e.g., Spinal muscular atrophy = SMA), the peripheral nerve (e.g., Charcot–Marie–Tooth disease = CMT), the neuromuscular junction (e.g., Congenital myasthenia), or the muscle itself (e.g., Duchenne muscular dystrophy = DMD). NMDs are progressive, impair motor function, and often reduce life expectancy and quality of life [2]. Progressive muscle weakness is the predominant condition of these disorders. All muscles may be involved, such as facial muscles (including orbicularis oris) and bulbar muscles. In some of the patients, congenital high arched palate and even temporomandibular arthrogryposis can be present. Feeding problems are common, with the need for a feeding tube or gastrostomy. Speech problems with anarthria or dysphonia with nasal speech can be present.

The terms "muscle disease," "myopathy," "neuromuscular conditions," and "neuromuscular disorders" all describe a group of conditions that affect either the muscles, those in the arms and legs or the heart and lungs, or the nerves which control the muscles [3].

3. Noninvasive ventilation

Positive airway pressure (PAP) may be invasive or not, depending on the techniques we use. Furthermore, it can be used in acute or chronic situations.

Noninvasive ventilation can be applied by various means, including nasal, oronasal, or facial mask, among others [4]. Masks, type BIPAP, CPAP, VPAP, and similar, are generally supported over the jaw. A nasal interface (or nasal cannula) is the preferred interface, and a nasobuccal interface can be used with caution in case of mouth breathing.

Positive Long-term NIV is a highly efficacious type of noninvasive respiratory support that has transformed the scope of chronic respiratory failure and severe sleep-disordered breathing in children with NMD by avoiding tracheotomies and allowing the child to live at home with a good quality of life for a child and his family. The tremendous heterogeneity of the disorders, ages, prognosis, and outcomes of the patients underlines the necessity of management by experienced, multidisciplinary pediatric centers, having technical competencies in pediatric NIV, and expertise in sleep studies and therapeutic education [5].

4. Major groups of risk

If we look to the population that uses NIV, we identify the significant groups of risk, where respiratory muscles are weakened, or the airway is obstructed:

1. Neuromuscular disorders,

2. Obstructive sleep apnea,

3. Cystic fibrosis,

4. Children with obesity and Down syndrome.

5. Facial side effects during noninvasive positive pressure ventilation in children

Retrognathia is a physical misalignment of the upper (maxilla) and lower (mandibular) jawbones in which either or both recede relative to the frontal plane of the forehead. In the maxilla, we use the term maxillary retrusion as synonymous [6].

Facial side effects during noninvasive positive pressure ventilation (NPPV) in children are not a new effect. Brigitte Faroux [7], in 2005, concluded about the use of nasal masks that global facial flattening was present in 68% of the patients, and a maxillary retrusion was present in 37% of patients. In that time, she suggested systematic maxillofacial follow-up so that these effects may be identified. Remedial measures could include the change of the interface or reducing the daily use of NPPV.

Continuous positive airway pressure (CPAP) is a type of positive airway pressure used to deliver a set pressure to the airways maintained throughout the respiratory cycle during inspiration and expiration [8].

Bariani, in 2020, reports that most of the studies demonstrated that long-term use of nasal positive airway pressure in childhood/adolescence is associated with midface hypoplasia [9].

Ma, in 2021, tries the fit and comfort evaluation of custom mask designs using a randomized fit test with a series of three-dimensional (3D) printed versus commercial standard masks. Results indicate that custom masks are more comfortable than conventional continuous positive airway pressure (CPAP) masks, particularly on fit, contact pressure, and comfort [10].

Martelly, in 2021, also makes 3D masks (BiPAP and CPAP) and reports that while the custom-fit mask did not reduce the average measured leakage for subjects, subjects reported experiencing less leakage. Overall, results suggest that the

custom-fit masks are more comfortable and tolerable than the provided off-the-shelf (OTS) mask option [11].

6. Case report—deleterious facial effects caused by noninvasive ventilation mask early treatment in congenital muscular dystrophy

With this clinical case, we want to familiarize professionals who work with these patients about the consequences that LTNIV may have in these children's face and oral functions and the importance of a pediatric dentist or an orthodontist in the team that treats these patients.

A 5-year-old child born with congenital muscular dystrophy type 1A (MDC1A) and total absence of merosin due to laminin α2 gene (*LAMA2*) mutation was referred by the pediatrician for the first time to the dentist. The child had a motor deficit, absence of gait, muscle hypotonia, feeding difficulty, breathing difficulties, sleep apnea, and normal intellectual development.

MDC1A is a rare autosomal recessive hereditary disease [12, 13] with severe consequences for its patients. It is characterized by motor deficits, muscle hypotonia, retractions, and progressive respiratory system impairment [14]. Affected individuals may show muscle hypertrophy [15]. The use of noninvasive ventilation devices is one of the strategies to manage the disease [16]. BiPAP and other similar units function as air compressor units and are used to treat respiratory insufficiencies [17], aiding ventilation with positive results in the pediatric population [18]. In this population, these devices are often used with a mask resting on the upper jaw.

Severe maxillary retrusion was diagnosed. Looking for the cause of such a severe facial deformity, it was hypothesized that force exerted by the noninvasive ventilation mask in this particular patient (with facial and bulbar weakness since birth) is one of the reasons for the deformity. The use of devices to assist ventilation is quite frequent in these patients. The use of these auxiliary ventilation devices, which are very important for the patient's well-being, must be carefully considered as they cause maxillary hypoplasia.

The retrusion of the middle floor of the face is maxillary hypoplasia or maxillary deficiency, which is an underdevelopment of the jawbones, with the greater concavity of the face and reduced nasolabial angle. This term represents underdevelopment of the maxilla (upper jaw) in length (decrease in the average height of the face) or depth (retrusion of the jaw) [19]. The maxillary retrusion resulting in non-development creates a pseudo-class III malocclusion resulting in esthetic disharmony, greater resistance of the nasal pathways [20, 21], narrowing of the pharyngeal airway, discomfort, and problems of eruption in mixed dentition [22, 23], with maxillary compression and crowding, in addition to pseudomacroglossia [24]. That is, the benefit obtained by the best oxygenation should always be equated with the relative anatomo-functional misfit that may result from prolonged use of the mask. Surveillance of the evolution of the maxilla development by pediatric dentists is necessary, and this professional should be part of the treatment and follow-up team.

The management of this disease and its comorbidity is predominant for the patient's quality of life, considering that there is no cure for it.

In this case, the use of the noninvasive ventilation device (BiPAP) occurred from the age of 15 months in the context of rest, nocturnal use (**Figure 1**). The device is used due to the child's ventilation difficulties, trying to compensate for the fragility of the respiratory muscles.

Figure 1.
At 15 months, the child started using noninvasive night ventilation with a nasal mask. So that there is a good adaptation of the nasal mask, without air escaping, a strap adapts the silicone to the face, anchored in the neck or nape, easily creating a retrusive force to the jaw.

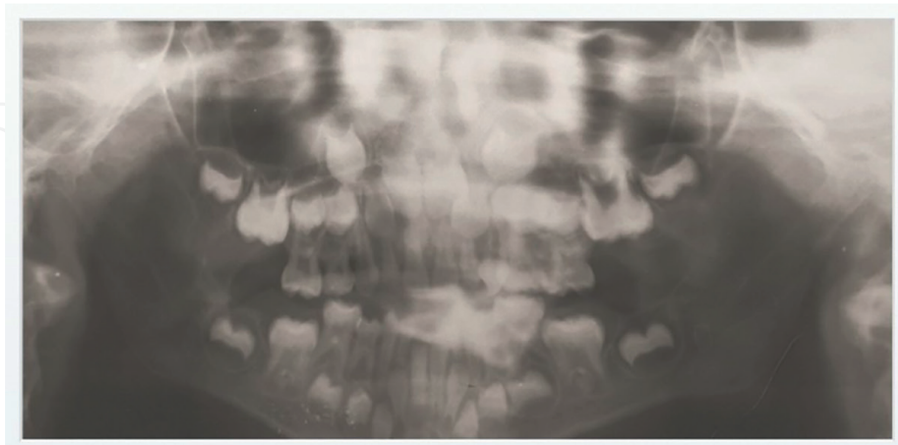

Figure 2.
The panoramic X-ray is the best exam to test the child and parent collaboration. For a child who does not walk and needs constant help from the mother to position himself, the radiograph is of sufficient quality and should not be repeated.

In our consultation, and despite the difficulties arising from age and the absence of gait that makes the child always dependent on the mother, good collaboration was achieved to perform a study [25], after obtaining additional diagnostic

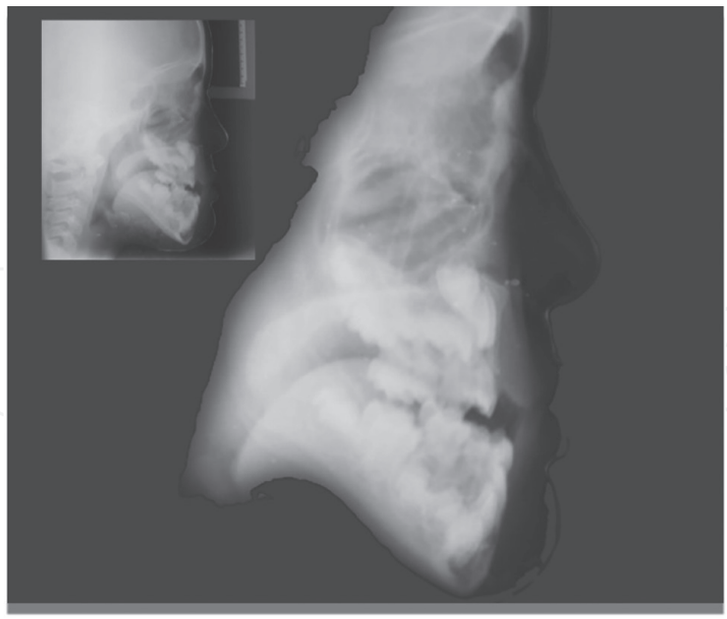

Figure 3.
Teleradiography - lateral radiography of the cranium from a 5-year-old female patient with Congenital Muscle Dystrophy. Severe maxillary retrusion, crossbite, open bite, and vertical growth of the mandible.

Figure 4.
Extra-oral photographs—as the child cannot hold herself standing, the photos were taken in the dental chair. The mother and child were very collaborative.

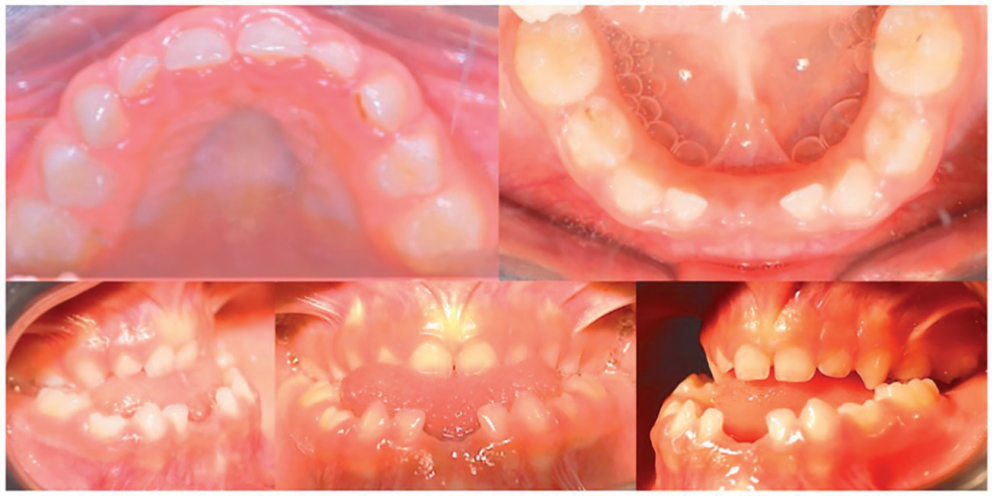

Figure 5.
Intra-oral photographs—the lips were previously moistened with a lip care balm to avoid the child's sensitivity and facilitate the placement of the lips and cheeks retractors.

Figure 6.
On 22/01/2017—the educator's photo shows retrognathic profile and lingual protrusion (Pseudomacroglossia).

elements: orthopantomography (**Figure 2**), teleradiography (**Figure 3**), extra-oral (**Figure 4**), and intra-oral photographs (**Figure 5**), and upper and lower molds of the child's mouth.

The child does not present dental problems, all teeth being healthy.

The study allowed to suggest starting the first phase of the correction of this problem, using an orthopedic maxillary therapy, with the placement of a rapid maxillary expansion appliance to widen the maxilla, followed by the simultaneous use of a facial mask for maxillary traction. At all times, the use of noninvasive ventilation was maintained.

The child must be regularly followed, and other therapeutical measures may have to be considered with the evolution of the treatment. At this moment, the focus is to recover as soon as possible the oral physiological functions.

Severe maxillary hypoplasia with progeny disharmony greater than 1 cm with a retracted appearance of the middle face is notorious. Retrusion, anterior and posterior crossbite, open bite, vertical growth of the mandible, and pseudomacroglossia (**Figures 2–6**).

Concavo profile and pseudomacroglossia (**Figure 6**) are visible in the resting position of the photo taken by the educators.

Further investigation of the facial features pre-use of NIV allowed us to conclude that the face was harmonic, without any hypoplasia or retrusion, as seen from the observation of several photographs and videos pre NIV (**Figures 7** and **8**). The profile was convex, with slight dystocclusion.

Figure 7.
Photo of the child on 17/11/2011, taken before using the noninvasive ventilation appliance; note the convex facial profile, without maxillary retrognathia problems.

Figure 8.
Child's photograph on 10/01/2012, also taken before using the noninvasive ventilation device; note the convex face profile, with a noticeable distal occlusion of the mandible and the middle third of the face well developed and proportional.

7. Discussion

Noninvasive mechanical ventilation (NIV) is defined as a ventilatory support that does not require an orotracheal tube or tracheostomy, used through an interface, with the objective of promoting adequate ventilation, reducing respiratory work, preventing respiratory muscle fatigue, increasing alveolar ventilation, and improving gas exchange, thus avoiding intubation and promoting, in some cases, early extubation [26, 27]. The use of NIV may also reduce complications associated with invasive mechanical ventilation and, consequently, morbidity and mortality rates related to this ventilatory support [28].

Currently, NIV is considered an alternative ventilatory support in the Pediatric Neuromuscular Outpatient Clinic. It has good acceptability and high success rates. It is indicated in the presence of acute or chronic respiratory disorders, neuromuscular diseases, central nervous system disorders, obstructive sleep apnea, neuromuscular diseases, central nervous system disorders, obstructive sleep apnea, postoperative, post-extubation period, and early extubation [29, 30].

A certain type of patient needs to use a ventilation aid for different reasons and at different ages, sometimes in the first years of life. The use of these noninvasive ventilation masks (BiPAP, CPAP, and the like) is sometimes maintained for years and a considerable period of daily use (more than eight or even 12 hours). The masks allow patients better oxygenation, but closure must be obtained around the place where the mask touches so that there is no air leakage. This peripheral closure of the mask on the face is obtained by the traction pressure of the mask against the tissues, and the mask can be nasal, nasal and oral, or facial.

The harmful effects caused using the mask will depend on the type of mask applied, the places where the forces are applied, the intensity of the forces, their direction, and the time of action of the forces in question. If this mask does not rely on solid structures of the face causes severe deformations in patients, especially if they are young and with the skeleton to form and easily moldable. Also, the substrate on which the forces act is important because a hard bone of an adult male does not deform in the same way as the soft bone of a baby or child.

Looking for the possible causes for maxillary retrusion and hypoplasia found, the feasible one that can be related is the use of noninvasive nasal mask ventilation in a child with facial and bulbar weakness. In this clinical case, everything indicates that the deformation found was iatrogenic, caused by the masks used in noninvasive ventilation. That is one of the main reasons for the deformity due to the mask.

Using this device from an early age (15 months) exerts an anchoring force in the skull (more difficult to deform) that causes an inhibition reaction of the growth of the maxilla and its retrusion since the predominant force was exerted in the cranial calotte. In this sense, the absence of well-distributed facial supports caused the applied forces to retort the entire anterior sector.

Given what was observed, it seemed that the alternative would be to counteract all this movement. So, we associate with the retrusive force of BiPAP a protrusive force, through a facial mask, complemented by the transverse expansion of the maxillary disjunction.

Maxillary reverse traction therapy is indicated for the solution of orthodontic cases as a non-surgical alternative for correcting malocclusion, allowing movement of the maxilla forward and down through the remodeling of the maxillary sutures. At the same time, the mandible shows a clockwise rotation, which corrects the concavity of the soft tissue profile. The technique may be associated with surgical procedures and rapid maxillary expansion orthopedical movements. Better results are obtained when therapy is used in young patients when compared to older patients [31].

The technique used allowed the child to continue to use BiPAP, necessary for his health and metabolism of development, but at the same time counteract the forces exerted by the NIV.

In this case, maxillary hypoplasia was reported in a child with congenital muscular dystrophy and a total absence of merosin. These children have severe breathing problems and ventilation difficulties.

The obstruction of the nasal airways is related to their volume [32, 33]. Some authors believe that rapid maxillary expansion may result in greater ventilatory capacity [34, 35] resulting from increased permeability and nasal volume [36, 37] as well as different tongue positioning [38, 39] and changes in voice [40].

The correct anatomy, good airways permeability, and positioning of the teeth and tongue permit better oral functions, such as chewing, drinking, speaking, breathing, and even earing [41].

This procedure allowed an increase of the entire nasal pyramid, resulting from the rapid expansion of the maxillary, which in the future will allow better ventilation, tongue positioning, and drainage of secretions in addition to closer anatomy of normal. It allows better development and a smaller number of hours lost by parents in medical consultations.

Despite the importance of this intervention for the child's current development, the treatment must have a second phase, pluridisciplinary, that may involve pediatric dentistry, orthodontics, physiotherapy, speech therapy, and maxillofacial surgery.

The fact that we later found other cases in which the same etiological hypothesis is possible made us write this text as a starting point for investigation and as a warning to colleagues who put on auxiliary ventilation masks such as BiPAP device, CPAP, and similar, for the treatment of apnea, sleep apnea, or situations that require prolonged use of NIV. It is intended that this text is a warning so that the placement of these masks is supported whenever possible in an extensive area and with the involvement of multiple less deformable bones, besides making it necessary to control the forces used so that these masks do not act like an orthodontic device of maxillary retrusion. Whenever possible, use only nose tubes, or helmet-like devices, to avoid jaw pressure at early ages.

In NIV a mask supported by the maxilla is used. Suppose we hypothesized that its use since the age of 15 months might have retracted the jaw or prevented its growth, functioning as an orthodontic appliance and with an unequal distribution of forces. In that case, we are faced with a method of disease management that may end up being harmful in the long term, preventing the natural formation of the sinus and the consequent ventilatory improvement. The use of this method of disease management is a "two-beak stick" because it allows an improvement in ventilatory capacity when using the device but seems to decrease the typical anatomical characteristics necessary for adequate ventilation. In this sense, noninvasive ventilation devices with an average force distribution and forces supported in more extensive areas and independent bones should be preferred to prevent retrusion. The most extensive support surface can prevent retrusion by what would be ideal the realization of masks tailored to each face.

8. Patient perspective

The mother left a testimony, translated to English, after removing names:

Sharing: I, mother and primary caregiver, hereby share this testimony, with the greatest satisfaction of what this device gave to my child's mouth, as she has severe congenital muscular dystrophy, a total absence of merosin (strength protein).

As soon as the appliance was placed in her mouth, within days, there was massive notoriety in her teeth spacing, mouth opening, and "ogival" palate alteration (widening and less depth), to the point where the teeth fit (aligned) correctly, "teeth with teeth."

Something that had not happened before and that made chewing less effective, such as lack of muscle strength, which was another situation that made the situation worse.

After this situation was successful, we moved on to the next stage with the traction device. It rectifies the bite, which was misaligned, due to the BiPAP respiratory device for sleep apnea at a very early age. Bipap had a beneficial effect on oxygenation while sleeping, but at the jaw level, projected it backward.

The process was slower but managed to exceed expectations to the extent of the severity noted. Through this long but very advantageous process, the changes were notorious at all levels:

- respiratory (with better breath)
- speech (diction)
- eat (chews more firmly and quickly) (crack some foods)
- drinking (faster)

However, this could not happen if I had not chosen as an Orthodontist Prof. Doctor Casimiro de Andrade and his team in this very complex process. In this, there was a development of delivery, trust, and humanity par excellence, to which I fully thank.

He was gradually doing the treatment according to the child's condition, in the different phases, so that this process would not be invasive under any circumstances.

Moreover, the entire multidisciplinary team was delighted to see my daughter evolve and progress throughout her treatment (Dr. Lurdes Morais (pulmonologist), Dr. Julia Eça de Guimarães (pediatrician), and Physiotherapist Ana Moreira and her team.

Mother of the child. Grateful for everything.!!! Thank you all.

9. Informed consent

The patient responsible agreed to use and publish the disease-related article with personal information to be excluded.

10. Conclusions

Whenever VNI use is prolonged and at an early age, exclusively maxillary support should be avoided, if possible discarded, preferring the use of a mask with multi-site facial support, or in some instances, total and better-distributed loads, if necessary tailored to measure.

Pediatric dentistry and orthodontics play a vital role in promoting health and development in children with neuromuscular disorders.

A pediatric dentist is a vital element in the medical team that follows these patients and should always identify, prevent, and intercept these problems to achieve proper development.

Acknowledgements

We thank the fantastic collaboration of all the therapeutic teams that followed the child.

We thank the mother's child as an example of care and attention to her child.

Conflict of interest

The authors supported this investigation.

The authors declare no conflict of interest.

David Casimiro de Andrade, Maria João Palha e José Rui Andrade: responsible for the conception and design.

David Casimiro de Andrade, Maria João Palha, Viviana Macho and Ana Norton were responsible for the data collection and manuscript redaction.

Ana Norton, Viviana Macho were responsible for the critical revision of its contents.

Sandra Kalil Bussadori, Miguel Palha, Lurdes Morais and Manuela Santos were responsible for the critical revision of its intellectual contents.

David Casimiro de Andrade was responsible for graphics and photos, the critical revision of its intellectual contents, and the final approval of the version to be published.

All authors declare that written informed consent was obtained from the patient (or other approved parties) to publish this research paper.

Author details

David Andrade[1*], Maria-João Palha[2], Ana Norton[1], Viviana Macho[3], Rui Andrade[5], Miguel Palha[4], Sandra Bussadori[6], Lurdes Morais[7] and Manuela Santos[8]

1 Pediatric Dentistry, Faculty of Dental Medicine, University of Porto, Porto, Portugal

2 Pediatrics, Santa Maria Hospital, Centro Hospitalar Universitário Lisboa Norte, Lisboa, Portugal

3 Pediatric Dentistry, Faculty of Health Sciences, University Fernando Pessoa, Porto, Portugal

4 Developmental Pediatrician, Child Development Centre Diferenças, Lisbon, Portugal

5 Nutritionism, Clínica Dentária de Espinho, Espinho, Portugal

6 Pediatric Dentistry, Uninove, Campus Vila Prudente, São Paulo, Brazil

7 Pediatric Pneumology, North Maternal and Child Centre from Centro Hospitalar do Porto, Porto, Portugal

8 Neuropediatrics, North Maternal and Child Centre from Centro Hospitalar do Porto, Porto, Portugal

*Address all correspondence to: dandrade@fmd.up.pt

References

[1] Ferreira R. Interfaces, Circuits and Humidifiers. Front Pediatr. 2020 Dec 7;8:557301. doi:10.3389/fped.2020.557301. PMID:33365289; PMCID: PMC7750325.

[2] Flotats-Bastardas M, Hahn A. New Therapeutics Options for Pediatric Neuromuscular Disorders. Vol. 8, Frontiers in Pediatrics. Frontiers Media S.A.; 2020.

[3] Potikanond S, Nimlamool W, Noordermeer J, Fradkin LG. Muscular dystrophy model. In: Advances in Experimental Medicine and Biology [Internet]. Springer New York LLC; 2018 [cited 2021 Jul 3]. p. 147-72. Available from: https://pubmed.ncbi.nlm.nih.gov/29951819/

[4] Long-term non-invasive ventilation therapies in children: A scoping review | Elsevier Enhanced Reader [Internet]. [cited 2021 Jul 8]. Available from: https://reader.elsevier.com/reader/sd/pii/S1087079217300461?token=84E22C08CBF74E237DBCDC07D19C37F8BB65BE820300BE021454B02493F85DE3095AF1D652CD7AD2E4D4D52B26C6E8C1&originRegion=eu-west-1&originCreation=20210708061359

[5] Fauroux B, Khirani S, Griffon L, Teng T, Lanzeray A, Amaddeo A. Non-invasive Ventilation in Children With Neuromuscular Disease. Front Pediatr. 2020 Nov 16;8:482. doi:10.3389/fped.2020.00482. PMID: 33330262; PMCID: PMC7717941.

[6] MeSH | Cochrane Library [Internet]. [cited 2021 Jul 3]. Available from: https://www.cochranelibrary.com/advanced-search/mesh

[7] Fauroux, B, Lavis, JF., Nicot, F et al. Facial side effects during noninvasive positive pressure ventilation in children. Intensive Care Med 31, 965-969 (2005). https://doi.org/10.1007/s00134-005-2669-2.

[8] Pinto VL, Sharma S. Continuous Positive Airway Pressure. 2021 May 7. In: StatPearls [Internet]. Treasure Island (FL): StatPearls Publishing; 2021 Jan–. PMID: 29489216.

[9] Bariani RC, Guimarães TM, Cappellette Junior M, Moreira G, Fujita RR. The impact of positive airway pressure on midface growth: a literature review. Braz J Otorhinolaryngol. 2020;86:647---53. Available from: https://doi.org/10.1016/j.bjorl.2020.05.010 1808-8694.

[10] Ma, Z., Hyde, P., Drinnan, M., and Munguia, J. (March 12, 2021). "Custom Three-Dimensional-Printed CPAP Mask Development, Preliminary Comfort and Fit Evaluation." ASME. J. Med. Devices. June 2021; 15(2): 024501. https://doi.org/10.1115/1.4050201.

[11] Martelly, E., Rana, S., and Shimada, K. (March 12, 2021). "Design and Fabrication of Custom-Fit BiPAP and CPAP Masks Using Three-Dimensional Imaging and Three-Dimensional Printing Techniques." ASME. J. Med. Devices. June 2021; 15(2): 024502. https://doi.org/10.1115/1.4049981.

[12] Lista de doenças raras e de sinónimos, por ordem alfabética», Série de Relatórios da Orphanet, coleção de Doenças Raras, Janeiro 2021, Available from: http://www.orpha.net/orphacom/cahiers/docs/PT/lista_de_doen-as_raras_por_ordem_alfabetica.pdf

[13] Leitão TGM (2014). Distrofia Muscular Congénita com Deficiência de

Merosina - a propósito de um caso clínico (Dissertação de mestrado, Universidade Beira Interior, Covilhã, Portugal).

[14] Butterfield RJ. Congenital Muscular Dystrophy and Congenital Myopathy. Contin Lifelong Learn Neurol. 2019;25(6):1640-1661.

[15] Oliveira, J., Freixo, J. P., Santos, M., & Coelho, T. (2020). LAMA2 Muscular Dystrophy. GeneReviews®. https://www.ncbi.nlm.nih.gov/books/NBK97333/

[16] Nguyen Q, Lim KRQ, Yokota T. Current understanding and treatment of cardiac and skeletal muscle pathology in laminin-α2 chain-deficient congenital muscular dystrophy. Appl Clin Genet. 2019;12:113-130.

[17] David-João PG, Guedes MH, Réa-Neto Á, Chaiben VB d. O, Baena CP. Noninvasive ventilation in acute hypoxemic respiratory failure: A systematic review and meta-analysis. J Crit Care [Internet]. 2019;49:84-91. Available from: https://doi.org/10.1016/j.jcrc.2018.10.012

[18] Abramo T, Williams A, Mushtaq S, Meredith M, Sepaule R, Crossman K, et al. Paediatric ED BiPAP continuous quality improvement programme with patient analysis: 2005-2013. BMJ Open. 2017;7(1):1-14.

[19] Midface Retrusion, National Human Genome Research Institute; [Internet]. [cited 2021 Jul 3]. Available from: https://elementsofmorphology.nih.gov/index.cgi?tid=5b7ad34ab35682b5#:~:text=Definition%3A,and%2For reduced nasolabial angle.

[20] G Ottaviano, P Maculan, G Borghetto, V Favero, B Galletti, E Savietto, B Scarpa, A Martini, E Stellini, C De Filippis L Favero, Nasal function before and after rapid maxillary expansion in children: A randomized, prospective, controlled study, International Journal of Pediatric Otorhinolaryngology (2018), doi: https://doi.org/10.1016/j.ijporl.2018.09.029.

[21] de Moura CP, Vales F, Andrade D, Cunha LM, Barros H, Pueschel SM, et al. Rapid maxillary expansion and nasal patency in children with Down syndrome. Rhinology. 2005;43(2):138-142.

[22] Ağlarcl C, Esenlik E, Flndlk Y. Comparison of short-term effects between face mask and skeletal anchorage therapy with intermaxillary elastics in patients with maxillary retrognathia. Eur J Orthod. 2016;38(3):313-323.

[23] Vidya VS, Sumathi FA. Rapid maxillary expansion as a standard treatment for obstructive sleep apnea syndrome: a systematic review. J Dental Med Sci. 2015;14:51-55.

[24] de Moura CP, Silveira H, Andrade D, Palha M, Clemente MP. Trissomia 21-Perspectiva Otorrinolaringológica. Arq Med. 2004;18(1/2):61-65.

[25] Macho V, Norton A, Areias C, Silva S, Silva CC, Macedo AP, Fraga C, Guedes-Pinto A, Andrade DC. A importância do Exame, Diagnóstico e Plano de Tratamento em Odontopediatria. In: Andrade DC, Guedes-Pinto AC. Textos Escolhidos de Odontopediatria. UP Editora, Porto, 2017. p.77- 102 p: il. color. e-ISBN: 978-989-746-138-5.

[26] Grande RAA, Fernandes GA, Andrade DP, Matsunaga NY, Oliveira T de, Almeida CCB, et al. Ventilação não invasiva em pacientes em uma Unidade de Terapia Intensiva Pediátrica: fatores associados à falha. J Bras Pneumol [Internet]. 2020 Aug 21 [cited 2021

Jul 8];46(6):1-8. Available from: http://www.scielo.br/j/jbpneu/a/ZsKwNhnPP6ddYtGyjhYTXrH/?lang=pt

[27] Viscusi CD, Pacheco GS. Pediatric Emergency Noninvasive Ventilation. Emerg Med Clin North Am. 2018 May 1;36(2):387-400.

[28] Ferreira S, Nogueira C, Conde S, Taveira N. Ventilação não invasiva. Rev Port Pneumol. 2009 Jul 1;15(4):655-667.

[29] Amaddeo A, Moreau J, Frapin A, Khirani S, Felix O, Fernandez-Bolanos M, et al. Long term continuous positive airway pressure (CPAP) and noninvasive ventilation (NIV) in children: initiation criteria in real life. Pediatr Pulmonol. 2016;51(9):968-974. http://dx.doi.org/10.1002/ppul.23416. PMid:27111113.

[30] Castro-Codesal ML, Dehaan K, Featherstone R, Bedi PK, Martinez Carrasco C, Katz SL, et al. Long-term non-invasive ventilation therapies in children: a scoping review. Sleep Med Rev. 2018;37:148-158. PMid:28410811.

[31] Primo, Bruno Tochetto et al. Terapia da tração reversa maxilar com máscara facial de Petit - relato de caso. RFO UPF [online]. 2010, vol.15, n.2, pp. 171-176. ISSN 1413-4012.

[32] G Ottaviano, P Maculan, G Borghetto, V Favero, B Galletti, E Savietto, B Scarpa, A Martini, E Stellini, C De Filippis L Favero, Nasal function before and after rapid maxillary expansion in children: A randomized, prospective, controlled study, International Journal of Pediatric Otorhinolaryngology (2018), doi: https://doi.org/10.1016/j.ijporl.2018.09.029.

[33] Andrade DC Macho V, Pinto M, Moura C., P. M., Andrade, C., Palha, M., Macho, V., Pinto, M., & Moura, C. (2009). Effects of Rapid Maxillary Expansion In Down Syndrome. O66 MH Abstracts and Proceedings Book of the 10th World Down Syndrome Congress. Dublin., O66 MH Abstracts and Proceedings book.

[34] Compadretti GC, Tasca I, Bonetti GA. Nasal airway measurements in children treated by rapid maxillary expansion. Am J Rhinol. 2006;20(4): 385-393.

[35] Moura, C., Vales, F., Andrade, D. J. C. de, Cunha, L., Barros, H., Pueschel, S., Pais-Clemente M. (2004). Rapid Maxillary Expansion and Nasal Permeability of a Down Syndrome Paediatric Population. Annual Meeting of American Academy of Otolaryngology, Head And Neck Surgery., 43(2), 138-142.

[36] De Felippe NLO, Da Silveira AC, Viana G, Kusnoto B, Smith B, Evans CA. Relationship between rapid maxillary expansion and nasal cavity size and airway resistance: short- and long-term effects. Am J Orthod Dentofacial Orthop 2008;134:370-382.

[37] Matsumoto MAN, Itikawa CE, Valera FCP, Faria G, Alnselmo-Lima WT. Long-term effects of rapid maxillary expansion on nasal area and nasal airway resistance. Am J Rhinol Allergy 2010;24:161-165.

[38] Areias C, Maia B, Macho V, Norton A, Macedo P, Andrade DC. Oral health in Down Syndrome, p. 45-68, 2015 in Health Problems in Down Syndrome. Intech open science|Open minds. Subrata Dey. 2015. ISBN 978-953-51-2154-1 DOI: 10.5772/60652 Available from: https://www.intechopen.com/books/health-problems-in-down-syndrome

[39] G Ottaviano, P Maculan, G Borghetto, V Favero, B Galletti, E Savietto, B Scarpa, A Martini, E

Stellini, C De Filippis L Favero, Nasal function before and after rapid maxillary expansion in children: A randomized, prospective, controlled study, International Journal of Pediatric Otorhinolaryngology (2018), doi: https://doi.org/10.1016/j.ijporl.2018.09.029.

[40] Moura C, Andrade DC, Cunha L, Cunha M, Vilarinho H, Barros H, Freitas D, Pais-Clemente M. Voice quality in Down syndrome children treated with rapid maxillary expansion. Interspeech. 6th 2005. (9th European conference on speech communication and technology) (5 vols); 1073-1076. Available from: www.isca-speech.org/archive/archive_papers/interspeech_2005/i05_1073.pdf

[41] de Moura, C. P., Andrade, D., Cunha, L. M., Tavares, M. J., Cunha, M. J., Vaz, P., Barros, H., Pueschel, S. M., & Pais Clemente, M. (2008). Down syndrome: Otolaryngological effects of rapid maxillary expansion. Journal of Laryngology and Otology, 122(12), 1318-1324. https://doi.org/10.1017/S002221510800279X.