

# We are IntechOpen, the world's leading publisher of Open Access books Built by scientists, for scientists

5,500

Open access books available

135,000

International authors and editors

165M

Downloads

Our authors are among the

154

Countries delivered to

TOP 1%

most cited scientists

12.2%

Contributors from top 500 universities



WEB OF SCIENCE™

Selection of our books indexed in the Book Citation Index  
in Web of Science™ Core Collection (BKCI)

Interested in publishing with us?  
Contact [book.department@intechopen.com](mailto:book.department@intechopen.com)

Numbers displayed above are based on latest data collected.  
For more information visit [www.intechopen.com](http://www.intechopen.com)



# Sino-Nasal Changes Associated with Midfacial Expansion: An Overview

*G. Dave Singh*

## Abstract

The concept of palatal expansion can be viewed as an anachronism since the delivery and scope of this clinical technique has changed dramatically over the past few decades. Indeed, since the palatal complex does not exist in isolation, clinicians ought to be cognizant of how palatal expansion affects contiguous midfacial structures. Because of this structural arrangement, surgical and non-surgical palatal expansion can have clinical consequences on the dentoalveolar structures, which are dependent on bony remodeling of the maxillo-palatine complex. In addition, it can also be suggested that morphologic alterations of the maxillary air sinus might lead to functional and clinical improvements of inflammatory changes associated with rhinosinusitis. Furthermore, enhancements in the nasal airway could affect a host of other conditions, including nasal breathing and obstructive sleep apnea, etc. Therefore, the aim of this chapter is to review the effects of midfacial expansion techniques on contiguous structures, including the paranasal sinuses.

**Keywords:** Maxillary sinus, nasal airway, sinusitis, palatal expansion, midfacial development

## 1. Introduction

The human air sinuses are enigmatic in that numerous functional attributes have been associated with them, including humidification, warming, and cleaning of inhaled air; biosynthesis, storage, and concentration of nitric oxide (NO); an anterior 'crumple zone' to withstand frontal trauma, and lightening of the skull, presumably for flight in extinct dinosaurs and extant birds. Recent evidence even goes on to suggest that the paranasal sinuses might be vestigial organs of breathing [1]. In any case, originally, clinical palatal expansion was pioneered as an orthodontic technique to widen the upper dental arch in attempt to improve jaw relations and/or tooth alignment. However, the maxillary air sinuses also lie above and lateral to the hard palate, while the dentoalveolar structures, such as the roots of the maxillary molars, can project into the sinus floor. Medially, the nasal airway communicates with the maxillary sinuses, including the ostio-meatal complex. Because of this diverse structural arrangement, non-surgical and surgical palatal expansion techniques might have clinical consequences on the maxillary air sinuses, which are dependent on bony remodeling and subsequent pneumatization of the maxillo-palatine complex. Therefore, an overview of various midfacial expansion

procedures that might induce anatomic alterations of the maxillary air sinus, that may in turn lead to functional and clinical changes, is warranted.

## **2. Sinus changes associated with non-surgical midfacial expansion**

Numerous studies have deployed 3D cone-beam computed tomography (CBCT) scans to quantify morphologic changes associated with rapid maxillary expansion (RME). For example, Lanteri et al. [2] evaluated midfacial changes after slow maxillary expansion and RME in 8 yr-old children. They found that the volumes of the nasal cavity and maxillary sinuses increased after treatment in both protocols. Conversely, Garrett et al. [3] had earlier reported that RME in 14 yr-olds was associated with an increase in nasal width but a decrease in maxillary sinus width, implying that the increase in nasal functional space was gained by displacing the maxillary air sinus volume, although clinical consequences of these changes were not noted. However, in a similar study on 13 yr-olds treated with banded and bonded maxillary expanders, Pangrazio-Kulbersh et al. [4] found that both appliances induced anterior and posterior skeletal widening of the hard palate via the midpalatal suture, and their study demonstrated increases in both nasal cavity volume and maxillary sinus volume. On the other hand, Almuzian et al. [5] provided further details of the RME approach in 13 yr-olds. Over a period of 2–3 weeks, an average palatal width-increase of 3.7 mm was noted in males and 2.8 mm in females. These linear changes were found to be correlated with maxillary sinus volume changes. Therefore, it can be surmised that anatomical differences in the outcome of RME might simply be explained by differences in the design, materials and protocols of the devices used.

A non-surgical variant of RME, maxillary protraction, deploys the use of facemasks (FM), particularly in cases of Class III malocclusion that exhibit a maxillary deficiency. Pamporakis et al. [6] assessed midfacial alterations, including the volume of the maxillary air sinuses in 10-yr-old children, associated with an RME-FM protocol for 10 days. Using this technique, they reported an overall increase in maxillary sinus volume post-treatment. However, the authors also noted that the RME-FM protocol did not affect all the maxillary sinuses, indicating that there may be a range of responses, presumably related to individual craniofacial morphology. In another variation of RME, alternate RME and constriction is sometimes deployed followed by FM. Onem-Ozbilen et al. [7] used this protocol on 10-yr-old children with a skeletal Class III phenotype, exhibiting maxillary retrognathia, over 10–12 months. It was found that the maxillary sinus volumes increased. Therefore, the authors concluded that different expansion devices and protocols can effect disparate changes in maxillary sinus volume. This deduction was borne out by the study of Erdur et al. [8] who used symmetric and asymmetric rapid maxillary expansion (ARME) treatments in patients aged 12–15 yrs. While maxillary sinus volume changes were greater in the RME group post-treatment, in the ARME group, no changes in sinus volume were found. Since bilateral symmetry is a feature of human development, these results are not perhaps surprising as the craniofacial system may regress to homeostasis once the devices are removed.

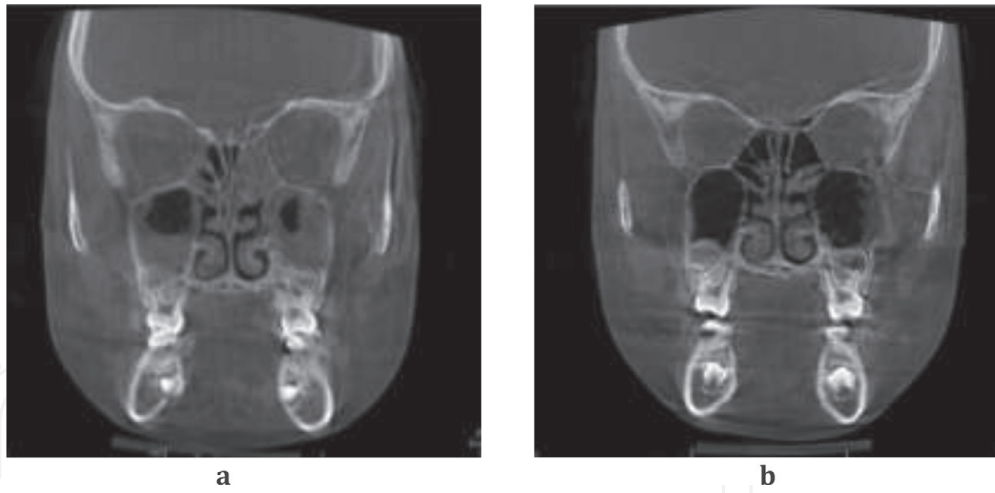
The age at which these various palatal expansion protocols are applied may also be pertinent. Most of these types of studies have been undertaken in pediatric populations but the efficacy of palatal expansion in older individuals is also worth considering. In fact, Machado-Júnior and Crespo [9] opine that maxillary expansion in adults requires further due diligence. In this regard, Kavand et al. [10] studied maxillary expansion with bone- and tooth-borne appliances in adolescents. They reported that both groups showed an increase in nasal cavity volume, but not

maxillary sinus volume, even though the maxillary bone width increased. This is an interesting finding because by age 15 yrs. the second maxillary molars are often fully erupted and root formation is typically completed, giving little or no room for continued pneumatization until the maxillary third molars evacuate the body of the maxilla, which is rare, since unerupted, impacted wisdom teeth is a common finding on radiographs. Thus, in adolescents, RME is unlikely to result in an increase in maxillary sinus volume. In contrast, Singh and Kim [11] found that a biomimetic approach to palatal expansion increased maxillary sinus volume by some 6.5% in adults (mean age approx. 25 yrs.) accompanied by a mean palatal width increase of approx. 3 mm, which is similar to that achieved in teenagers as noted above. Therefore, while morphologic differences in the outcome of non-surgical RME might be explained by disparate designs, materials and protocols of the devices used, if the laws of biologic control, such as sutural homeostasis and pneumatization, are not violated, enhancement of maxillary sinus morphology might be possible even in adults, perhaps leading to improved clinical outcomes.

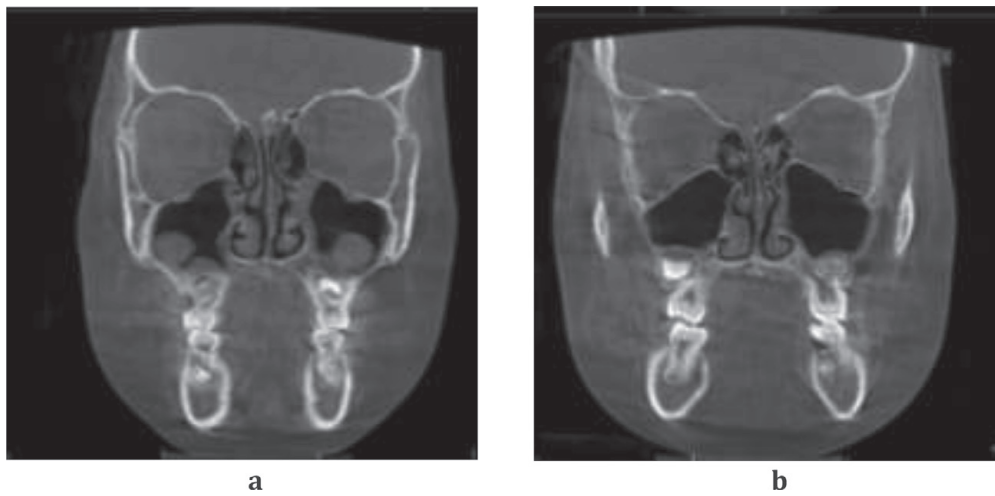
### **3. Functional sinus changes associated with non-surgical midfacial expansion**

One of the roles of the paranasal sinuses is the biosynthesis of nitric oxide (NO). It is known that NO plays important roles in a diverse range of physiologic and patho-physiologic processes, including antimicrobial activity, pulmonary vascular resistance, alveolar oxygen transfer, neurotransmission, respiration, as well as its anti-inflammatory activities [12, 13]. Lundberg et al. [14] were some of the first to report that NO originates from the paranasal sinuses and that NO synthase is expressed in healthy sinus pneumocytes. In addition, Andersson et al. [15] found extremely high concentrations of NO in the paranasal sinuses, suggesting that the antra may act as NO reservoirs. Furthermore, Runer et al. [16] noted that NO is likely to be a regulator of mucociliary activity in the nasal airway. In contrast to these healthy states, Deja et al. [17] found significantly reduced NO production in maxillary sinuses of patients with sinusitis diagnosed using radiologic methods. Similarly, Naraghi et al. [18] reported that NO metabolites are higher in patients with chronic sinusitis and concluded that NO metabolites may play an important role in the pathogenesis of rhinosinusitis. In view of these findings, Degano et al. [19] investigated changes in NO concentration during the treatment of maxillary sinusitis. Using a protocol that included drainage, daily lavage, etc., a significant increase in the levels of maxillary and nasal NO was noted. Therefore, morphologic and functional optimization of the paranasal sinuses using non-surgical palatal expansion might be beneficial in the management of some sinus diseases.

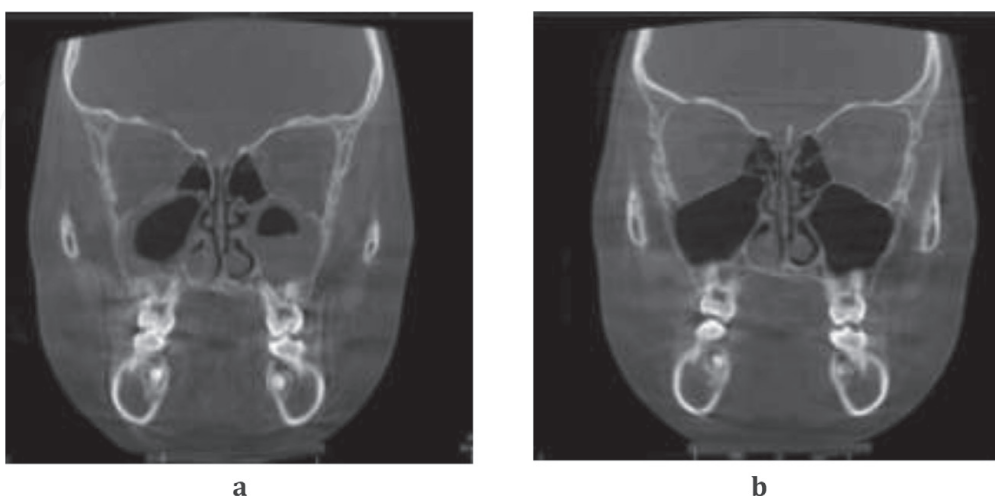
In pediatric rhinitis, Wen et al. [20] consider that NO is a useful biomarker for both nasal inflammation and sinus ostial patency. In their study, they determined that obstruction of NO sino-nasal flow is likely associated with rhinosinusitis since NO concentrations returned to normal levels following antibiotic therapy. On the other hand, in a case series, Hwang et al. [21] reported their findings on pediatric rhinosinusitis during biomimetic oral appliance therapy (BOAT). **Figures 1a–3b** summarize their findings. In 3 consecutive pediatric patients (mean age 9 yrs.), Hwang et al. [21] used 3D cone-beam CT scans to show inflammatory maxillary sinus disease with circumferential mucosal thickening, obstructed ostio-meatuses, and enlarged inferior turbinates (**Figures 1a, 2a and 3a**) prior to treatment. All 3 cases were treated using BOAT for approx. 10 months. Post-treatment, the sinuses were aerated without mucosal thickening; the sinus walls were intact, and the ostiomeatal units were patent (**Figures 1b, 2b and 3b**). Although enhancement



**Figure 1.**  
*a: Case 1: Pre-treatment nasal floor width is 17.7 mm; b: Post-treatment nasal floor width increased to 19.5 mm.*



**Figure 2.**  
*a: Case 2: Pre-treatment nasal floor width is 17.6 mm; b: Post-treatment nasal floor width increased to 19.3 mm.*



**Figure 3.**  
*a: Case 3: Pre-treatment width increased to 18.7 mm; b: Post-treatment nasal floor nasal floor width is 15.3 mm.*

of maxillary air sinus structure and function through non-surgical remodeling is presumed, there is no clear mechanism of how the sinuses improved during BOAT in these cases. It is possible that the sinusitis resolved through the natural immune

response, seasonal changes, through normal craniofacial growth or the placebo effect. However, enlargement of the ostium ( $>20 \text{ mm}^2$ ) is thought to decrease sinus NO concentration, as the size of the ostium shows correlation to NO levels [22]. Since the width of the nasal floor increased in these 3 cases (**Figures 1b, 2b and 3b**), the notion that BOAT involved remodeling of the ostia to within normal limits is yet to be determined.

#### **4. Surgical midfacial expansion**

Aside from non-surgical palatal expansion, a plethora of surgical maxillary expansion procedures has become available. One study [23] compared the effects of non-surgical RME with surgically assisted rapid maxillary expansion (SARME). Surprisingly perhaps, there were no differences between the two protocols since nasal cavity width and volume, as well as maxillary width, increased with a concomitant decrease in nasal airway resistance. If non-surgical and surgical techniques yield similar results, one of the questions that currently remains unanswered is, how to minimize or avoid (orthognathic) surgery? To address this subject, Lee et al. [24] described the use of orthodontic screws for mini-screw-assisted rapid maxillary expansion (MARME), since some mistakenly believe that non-surgical palatal expansion relies on unwanted dental tipping rather than actual skeletal expansion. Bearing this in mind, Carlson et al. [25] treated a 19-year-old using MARME. Post-treatment, they reported enlargement in the zygomatic regions and nasal bone regions in association with widening of the circum-maxillary sutures. Indeed, MARME utilizes forces to split the midpalatal suture, which precipitates a midline diastema, an unwanted dental effect. However, insufficient force application may render MARME unsuccessful. Therefore, Suzuki et al. [26] deployed cortical punctures along the midpalatal suture followed by mini-screw insertion to fracture the midpalatal suture by 3-4 mm in an adult patient.

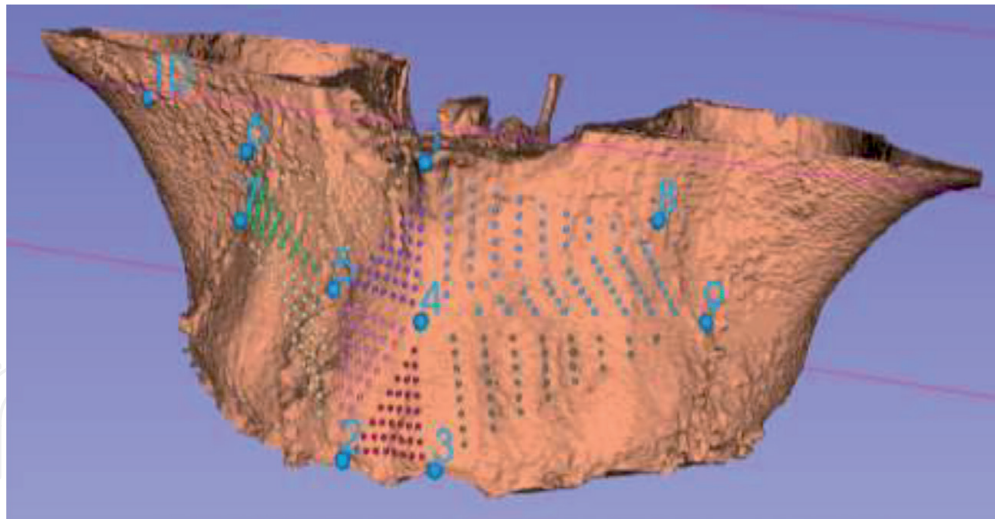
Despite the above variations, the impact of MARME on the upper airway and breathing is not clear. Recently, Abu-Arquub et al. [27] reviewed the effects of MARME on the upper airway in pediatric patients aged 10-17 yrs. They concluded that while short-term improvements were identifiable, no correlation was observed between upper airway morphology and functional parameters, such as nasal airflow and nasal resistance. Similarly, in older patients (mean age 20 yrs.), Yi et al. [28] found that although MARME produced both skeletal and dento-alveolar expansion, there were no changes in the oropharyngeal, palatopharyngeal, and glossopharyngeal regions and the total airway volume remained unaltered on 3D CBCT scans. In another study [29], it was reported that MARME produced an increase in nasal cavity and nasopharyngeal volumes, associated with bony expansion of the nasal floor and maxillary width in young adults (mean age 22.5 yrs.). Thus, when assessing changes on 3D CBCT scans after MARME, the association between skeletal changes and the upper airway remain unclear. Despite these assertions, Singh et al. [30] tested the hypothesis that the upper airway can be improved non-surgically in adults using BOAT. The mean treatment time was 16.5mos. and CBCT scan measurements were taken with no device in the patient's mouth. Their multivariate tests confirmed a significant treatment effect on the upper airway parameters ( $p = 0.012$ ), suggesting that both craniofacial architecture and upper airway morphology can be non-surgically enhanced even in adults. However, this novel approach remains overlooked although further evidence is emerging.

To enhance orthopedics effect induced by MARME, 4 mini-implants with palatal and nasal cortical engagement are sometimes positioned in the palate, when using the maxillary skeletal expander (MSE) technique. Cantarella et al. [31] investigated the effects of this particular protocol on the midpalatal and pterygopalatine

sutures in young adults (mean age 17 yrs.). Using CBCT scans, it was found that the midpalatal suture was split slightly asymmetrically, being wider anteriorly than posteriorly. Moreover, pterygopalatine disjunction was revealed in over half of the cases studied, as the pyramidal process of the palatine bone was dislocated from the pterygoid processes. In a similar later study, Cantarella et al. [32] assessed facial changes associated with MSE, again using CBCT scans. Here, it was reported that the zygomatico-maxillary complex showed centrifugal changes with a “center of rotation” located at the fronto-zygomatic suture. Consequently, the inter-zygomatic distances and the fronto-zygomatic angles increased using MSE, but no data on any associated nasopharyngeal airway changes were reported in these particular studies. However, to further locate the center of rotation for the zygomatico-maxillary complex associated with MSE, Cantarella et al. [33] reported that the center of rotation for the zygomatico-maxillary complex could be found more inferiorly, posteriorly and laterally (near the zygomatic process of the temporal bone) compared with their other study [32]. In contrast, Paredes et al. [34] concluded that the center of rotation for the zygomatico-maxillary complex is located at the most infero-lateral point of the zygomatic process of the frontal bone. This variation in the center of rotational displacement could be due to bone deformations that are thought to occur during MSE, which might also explain the occurrence of pterygopalatine dislocation. In fact, Colak et al. [35] evaluated pterygopalatine disarticulation patterns after MSE. The vast majority of cases (> 80%) exhibited pterygopalatine disjunction without direct surgical intervention at this site. The clinical consequences of this iatrogenic fracture, if any, remain undetermined, at least as yet.

Recently, in order to avoid the potential risk of damaging anatomical structures, Cantarella et al. [36] suggested that the deployment of 3D virtual surgical planning using digital data might be advantageous prior to undertaking MSE. Elkenawy et al. [37] were also interested in the biomechanics of MSE. In their study, they noted that over half of approx. 30 adult patients exhibited an asymmetric response following splitting of the midpalatal suture. This result is perhaps not surprising since the midline vomero-maxillary suture would presumably provide an impediment to a symmetric split based *a priori* on fluctuating asymmetry [38]. Indeed, Schwarz et al. [39] examined adult patients for the incidence of nasal septal deviation following SARME. Although no post-operative changes in nasal septal positioning were found, maxillary rotation was associated with an inferior ‘rotation’ of the palatal vault with a concomitant increase in nasal airway space, although these authors attributed the increases to a decreased thickening of the pre-operative inflamed nasal mucosa. Nonetheless, Abedini et al. [40] were also interested in the soft tissue facial changes induced by MSE. Using 3D stereophotogrammetry, they computed mean 3D soft tissue geometries using techniques similar to those first described by Singh et al. [41, 42] for craniofacial data (**Figure 4**), and were able to demonstrate changes in the paranasal, upper lip, and zygomatic regions of the face associated with MSE. Therefore, clinicians and patients ought to be cognizant of the facial effects associated with MSE prior to embarking upon a treatment plan that putatively targets upper airway inadequacy.

Distraction osteogenesis maxillary expansion (DOME) is another technique that aims to improve the nasal airway changes through widening of the maxilla. Using this approach, Kunkel et al. [43] were able to enlarge the nasal airway volume by 23% on average without pterygomaxillary disjunction being a part of the surgical procedure, which occurs in any case. Despite this drawback, DOME is currently viewed as a reliable procedure to widen the nasal floor in adults with OSA. Using this protocol, the mean apnea-hypopnea index (AHI) was improved, nasal airflow velocity decreased and the mean negative pressures in the nasal, retropalatal, oropharyngeal, and hypopharyngeal airway were reduced, which correlated with a



**Figure 4.** Using CBCT data, the maxillary complex has been rendered in 3D virtual space and dense correspondence of (colored) landmarks has been computed using the ten homologous landmarks (1–10).

reduction in the AHI, according to Iwasaki et al. [44]. These findings are, however, similar to the well-known results of non-surgical RME using fixed appliance in children. For example, in pediatric cases, Cozza et al. [45] reported that there was a reduction in nasal resistance with increased nasal airflow after RME. Indeed, RME is thought by some to be a comparatively non-invasive, economic treatment option to improve nasal respiration in patients up to at least 30 years of age. Gray [46] considers the medical indications for RME are a deficient nasal airway, septal deformity, recurrent ear infection, and allergic rhinitis, *inter alia*. In a series of over 300 consecutive selected cases, 80% changed their mode of oral breathing to nasal breathing. Thus, the advantages of MSE over RME in terms of nasal airway resistance and anatomical changes in the nasal cavity require further clarification.

## 5. Nasal airway space, resistance and breathing

In an early study, Warren et al. [47] assessed the effects of non-surgical RME and surgical expansion on nasal airway size. While both procedures improved the nasal airway, approx. 30% of subjects in both groups were unable to eliminate the need for mouth breathing, suggesting that neither RME nor surgical maxillary expansion is justified for nasal breathing purposes alone, likely due to individual variation in response. Bicakci et al. [48] were one of the first to assess the effect of RME on nasal cross-sectional area using acoustic rhinometry, confirming that the overall increase in the cross-sectional area was greater in the RME-treated groups when compared to controls. Around the same time, Ceroni-Compadretti et al. [49] also reported that RME increased both the width of the maxilla and the nasal volume, as measured with acoustic rhinometry. Furthermore, Compadretti et al. [50] deployed rhinomanometry and acoustic rhinometry to assess the function and size of the nasal cavities associated with RME in children. Compared to a control group, the RME treatment group showed an increase in nasal cross-sectional area and volume, as well as a decrease in nasal airway resistance, but the study was unable to confirm the clinical mode of breathing. Likewise, Palaisa et al. [51], using CT scanning, explored the relationship between morphologic changes in nasal area and volume following RME in young patients (8-15 yrs). They reported symmetric increases in both nasal cavity area and volume although the variance in response was again large. Similarly, Oliveira de Felipe et al. [52] concluded that



post-expansion, while nasal cross-sectional area increased when measured using acoustic rhinometry, and nasal cavity volume increased using 3D imaging, only 60% of subjects reported subjective improvement in nasal respiration. Therefore, Enoki et al. [53] correctly concluded that RME may lessen nasal resistance but subtle differences in nasal geometry, such as shape changes as opposed to size-changes, may influence success in switching from mouth breathing to nasal respiration.

Currently there is a lack of consensus on the reliability of RME-related procedures in improving nasal functional behaviors, such as changing mouth breathing to nasal breathing predominantly. Hershey et al. [54] noted that patients' subjective opinions on changes in the ability to breathe nasally are not correlated to reductions in treatment-induced nasal resistance, even though RME is effective in reducing nasal resistance to levels consistent with nasal respiration. For example, Doruk et al. [55] found that nearly 60% of 13-yr-olds considered their nasal breathing had improved following RME using subjective evaluation. Earlier, using rhinomanometry, Timms [56] measured nasal airway resistance prior to and after RME in patients aged 10 to 19.5 yrs. On average, a 36% reduction in nasal resistance was reported but this did not correlate with the transpalatal or trans-alar width increases post-expansion. Similarly, Hartgerink et al. [57] surmise that individual variation in nasal resistance values is considerable and that average response variability renders RME unpredictable in terms of decreasing nasal resistance despite evidence of expansion at the anterior nares. In this regard, White et al. [58] reported a mean reduction in nasal airway resistance of approx. 50% after about one-year post-RME. Moreover, they noted that the reduction in nasal airway resistance was correlated to the initial nasal resistance level prior to RME, and that individuals with greater resistance pre-expansion tended to have greater reductions post-treatment. This notion had earlier been investigated using a multidisciplinary approach [59]. Utilizing a combination of RME and oral myofunctional assessment using rhinomanometric measurements, two phenotypes were identified: first, predominantly mouth breathers, showing an average nasal airway resistance decrease of 34%; and second, predominantly nasal breathers with an average nasal airway resistance decrease of <5%. Notably, 75% of predominantly mouth breathers were converted to nasal breathing. Thus, it appears that maxillary deficiency allied with functional deficits needs a tailored approach to be adopted to address the mode of respiration.

It is thought that nasal surgery alone can fail to restore nasal breathing in various cases with maxillary restriction, which is associated with closure of the internal and external nasal valves. In addition, although some now generally agree that RME in both children and adults increases upper airway volume, it remains uncertain whether maxillary expansion improves nasal function. Thus, recently, Iwasaki et al. [60] investigated the efficacy of three RME appliances on nasal ventilation in 10-16 yr. old patients. They reported that RME reduced nasal pressure and nasal airflow velocity, which was accompanied by resolution of nasal obstruction. Nevertheless, Calvo-Henriquez et al. [61] undertook a systematic review on this subject, concluding that there is insufficient evidence to recommend maxillary expansion as a first-line therapy to improve nasal breathing. Despite this assertion, one aspect that remains under-investigated at this juncture is the role of nasal exercises. In the interpretation of numerous studies, it has simply been assumed that an increase or enhancement of anatomical form will result in the desired functional response. But, in their review, Levrini et al. [62] suggest that if RME is combined with functional rehabilitation, the chances of changing a mouth-breathing pattern to nasal respiration are increased. Therefore, the role of respiratory therapists and/or oral myofunctional therapists may need to be extended to include nasal breathing exercises perhaps allied with the use of capnography for biofeedback. In any case, Kiliç and Oktay [63] are of the opinion that while RME increases nasopharyngeal

airway dimensions and nasal respiration in pediatric patients exhibiting maxillary constriction and mouth breathing, RME could also be effective on naso-respiratory and sleep-disordered breathing problems in children.

Pirelli et al. [64] evaluated the effect of RME on nasal airway patency and pediatric OSA. On postero-anterior and occlusal radiographic assessment, widening of the midpalatal suture and nasal fossae were confirmed, and restoration of nasal airflow was associated with elimination of obstructive sleep disordered breathing. Therefore, changing the anatomic structure using RME produced significant functional improvement in pediatric patients diagnosed with OSA. On the other hand, Garcez et al. [65] demonstrated the effects of MSE on respiratory function and athletic performance. Using CBCT scans they reported a 6 mm widening of the midpalatal suture and nasomaxillary structures, while the nasal and pharyngeal airways also increased in volume by 30%. In addition, all respiratory indices improved after MSE. Thus, MSE can potentially have a positive influence on both respiratory functions and athletic performance. Recently, Singh et al. [30] also reported a 14% increase in nasal cavity volume achieved non-surgically in adults using a biomimetic oral appliance. Therefore, one of the research question that needs to be addressed now is: Which procedure best suits a particular patient's requirements both safely and effectively? Taking a cohort of cases that have had the same intervention, it should be possible to compute the mean, underlying transformation for a sample of cases. If this transformation can then be applied to a naïve subject, a predictive model can be achieved, assuming the new subject behaves in the same way that the sample did on average. Therefore, the use of mathematical modeling on 3D digital data provides a promising avenue of future research in terms of virtual treatment planning, perhaps incorporating the use of artificial intelligence to inform clinical decision-making.

## 6. Conclusion

Non-surgical and surgical midfacial expansion techniques are associated with functional sinus changes in the paranasal sinuses as well as changes in nasal airway space, nasal resistance and the mode of breathing. To address the question of which procedure best suits a particular patient's requirements both safely and effectively, the use of mathematical modeling provides a promising approach.

### Conflict of interest

Professor G. Dave Singh is Founder and Chief Medical Officer of Vivos Therapeutics, Inc., USA. He is currently collaborating with Stanford University in the development of a craniofacial facility.

IntechOpen

IntechOpen

### **Author details**


G. Dave Singh

Institute for Craniofacial Sleep Medicine, Highlands Ranch, USA

\*Address all correspondence to: [drsingh@drdavesingh.com](mailto:drsingh@drdavesingh.com)

### **IntechOpen**

---

© 2021 The Author(s). Licensee IntechOpen. This chapter is distributed under the terms of the Creative Commons Attribution License (<http://creativecommons.org/licenses/by/3.0>), which permits unrestricted use, distribution, and reproduction in any medium, provided the original work is properly cited. 

## References

- [1] Sereno PC, Martinez RN, Wilson JA, Varricchio DJ, Alcober OA, Larsson HC. Evidence for avian intrathoracic air sacs in a new predatory dinosaur from Argentina. *PLoS One*. 2008;3:e3303.
- [2] Lanteri V, Farronato M, Ugolini A, Cossellu G, Gaffuri F, Parisi FMR, Cavagnetto D, Abate A, Maspero C. Volumetric changes in the upper airways after rapid and slow maxillary expansion in growing patients: A case-control study. *Materials (Basel)*. 2020;13:2239.
- [3] Garrett BJ, Caruso JM, Rungcharassaeng K, Farrage JR, Kim JS, Taylor GD. Skeletal effects to the maxilla after rapid maxillary expansion assessed with cone-beam computed tomography. *Am J Orthod Dentofacial Orthop*. 2008;134:8-9.
- [4] Pangrazio-Kulbersh V, Wine P, Haughey M, Pajtas B, Kaczynski R. Cone beam computed tomography evaluation of changes in the naso-maxillary complex associated with two types of maxillary expanders. *Angle Orthod*. 2012;82:448-457.
- [5] Almuzian M, Ju X, Almkhtar A, Ayoub A, Al-Muzian L, McDonald JP. Does rapid maxillary expansion affect nasopharyngeal airway? A prospective Cone Beam Computerised Tomography (CBCT) based study. *Surgeon*. 2018;16:1-11.
- [6] Pamporakis P, Nevzatoğlu Ş, Küçükkeleş N. Three-dimensional alterations in pharyngeal airway and maxillary sinus volumes in Class III maxillary deficiency subjects undergoing orthopedic facemask treatment. *Angle Orthod*. 2014;84:701-707.
- [7] Onem-Ozbilen E, Yilmaz HN, Kucukkeles N. Comparison of the effects of rapid maxillary expansion and alternate rapid maxillary expansion and constriction protocols followed by facemask therapy. *Korean J Orthod*. 2019;49:49-58.
- [8] Erdur EA, Yildırım M, Karatas RMC, Akin M. Effects of symmetric and asymmetric rapid maxillary expansion treatments on pharyngeal airway and sinus volume. *Angle Orthod*. 2020;90:425-431.
- [9] Machado-Júnior AJ, Crespo AN. Expansion of the maxilla in adults with OSAS: myth or reality? *Sleep Med*. 2020;65:170-171.
- [10] Kavand G, Lagravère M, Kula K, Stewart K, Ghoneima A. Retrospective CBCT analysis of airway volume changes after bone-borne vs tooth-borne rapid maxillary expansion. *Angle Orthod*. 2019;89:566-574.
- [11] Singh GD, Kim HN. Changes in pneumatization of the maxillary air sinuses in Korean adults following biomimetic oral appliance therapy. *World J Otorhinolaryngol Head Neck Surg*. 2020 doi.org/10.1016/j.wjorl.2020.07.007.
- [12] Maniscalco M, Bianco A, Mazzarella G, Motta A. Recent Advances on Nitric Oxide in the Upper Airways. *Curr Med Chem*. 2016;23:2736-2745.
- [13] Jankowski R, Nguyen DT, Poussel M, Chenuel B, Gallet P, Rumeau C. Sinusology. *Eur Ann Otorhinolaryngol Head Neck Dis*. 2016;133:263-268.
- [14] Lundberg JO, Weitzberg E, Rinder J, Rudehill A, Jansson O, Wiklund NP, Lundberg JM, Alving K. Calcium-independent and steroid-resistant nitric oxide synthase activity in human paranasal sinus mucosa. *Eur Respir J*. 1996;9:1344-1347.

- [15] Andersson JA, Cervin A, Lindberg S, Uddman R, Cardell LO. The paranasal sinuses as reservoirs for nitric oxide. *Acta Otolaryngol.* 2002;122:861-865.
- [16] Runer T, Cervin A, Lindberg S, Uddman R. Nitric oxide is a regulator of mucociliary activity in the upper respiratory tract. *Otolaryngol Head Neck Surg.* 1998;119:278-287.
- [17] Deja M, Busch T, Bachmann S, Riskowski K, Campean V, Wiedmann B, Schwabe M, Hell B, Pfeilschifter J, Falke KJ, Lewandowski K. Reduced nitric oxide in sinus epithelium of patients with radiologic maxillary sinusitis and sepsis. *Am J Respir Crit Care Med.* 2003;168:281-286.
- [18] Naraghi M, Deroee AF, Ebrahimkhani M, Kiani S, Dehpour A. Nitric oxide: a new concept in chronic sinusitis pathogenesis. *Am J Otolaryngol.* 2007;28:334-337.
- [19] Degano B, Génestal M, Serrano E, Rami J, Arnal JF. Effect of treatment on maxillary sinus and nasal nitric oxide concentrations in patients with nosocomial maxillary sinusitis. *Chest* 2005;128:1699-1705.
- [20] Wen YS, Lin CY, Yang KD, Hung CH, Chang YJ, Tsai YG. Nasal nitric oxide is a useful biomarker for acute unilateral maxillary sinusitis in pediatric allergic rhinitis: A prospective observational cohort study. *World Allergy Organ J.* 2019;12:100027.
- [21] Hwang H, Hwang C, West J, Singh GD. Changes in pediatric paranasal sinuses following biomimetic oral appliance therapy: 3 case reports. *Cranio.* 2019;1-6.
- [22] Kirihene RK, Rees G, Wormald PJ. The influence of the size of the maxillary sinus ostium on the nasal and sinus nitric oxide levels. *Am J Rhinol.* 2002;16:261-264.
- [23] Basciftci FA, Mutlu N, Karaman AI, Malkoc S, Küçükkolbasi H. Does the timing and method of rapid maxillary expansion have an effect on the changes in nasal dimensions? *Angle Orthod.* 2002;72:118-123.
- [24] Lee KJ, Park YC, Park JY, Hwang WS. Miniscrew-assisted nonsurgical palatal expansion before orthognathic surgery for a patient with severe mandibular prognathism. *Am J Orthod Dentofacial Orthop.* 2010;137:830-839.
- [25] Carlson C, Sung J, McComb RW, Machado AW, Moon W. Microimplant-assisted rapid palatal expansion appliance to orthopedically correct transverse maxillary deficiency in an adult. *Am J Orthod Dentofacial Orthop.* 2016;149:716-728.
- [26] Suzuki SS, Braga LFS, Fujii DN, Moon W, Suzuki H. Corticopuncture Facilitated Microimplant-Assisted Rapid Palatal Expansion. *Case Rep Dent.* 2018;1392895.
- [27] Abu-Arquub S, Mehta S, Iverson MG, Yadav S, Upadhyay M, Almuzian M. Does Mini Screw Assisted Rapid Palatal Expansion (MARPE) have an influence on airway and breathing in middle-aged children and adolescents? A systematic review. *Int Orthod.* 2021;19:37-50.
- [28] Yi F, Liu S, Lei L, Liu O, Zhang L, Peng Q, Lu Y. Changes of the upper airway and bone in microimplant-assisted rapid palatal expansion: A cone-beam computed tomography (CBCT) study. *J Xray Sci Technol.* 2020;28:271-283.
- [29] Li Q, Tang H, Liu X, Luo Q, Jiang Z, Martin D, Guo J. Comparison of dimensions and volume of upper airway before and after mini-implant assisted rapid maxillary expansion. *Angle Orthod.* 2020;90:432-441.
- [30] Singh GD, Kim HN, Kim SH, Wang L. 3D craniofacial and upper

airway changes after biomimetic oral appliance therapy in Korean adults. *Otorhinolaryngol Head Neck Surg.* 2021;6:1-7.

[31] Cantarella D, Dominguez-Mompell R, Mallya SM, Moschik C, Pan HC, Miller J, Moon W. Changes in the midpalatal and pterygopalatine sutures induced by micro-implant-supported skeletal expander, analyzed with a novel 3D method based on CBCT imaging. *Prog Orthod.* 2017;18:34.

[32] Cantarella D, Dominguez-Mompell R, Moschik C, Mallya SM, Pan HC, Alkahtani MR, Elkenawy I, Moon W. Midfacial changes in the coronal plane induced by microimplant-supported skeletal expander, studied with cone-beam computed tomography images. *Am J Orthod Dentofacial Orthop.* 2018;154:337-345.

[33] Cantarella D, Dominguez-Mompell R, Moschik C, Sfogliano L, Elkenawy I, Pan HC, Mallya SM, Moon W. Zygomaticomaxillary modifications in the horizontal plane induced by micro-implant-supported skeletal expander, analyzed with CBCT images. *Prog Orthod.* 2018;19:41.

[34] Paredes, N., Colak, O., Sfogliano, L. et al. Differential assessment of skeletal, alveolar, and dental components induced by microimplant-supported midfacial skeletal expander (MSE), utilizing novel angular measurements from the fulcrum. *Prog Orthod.* 2020;21:18.

[35] Colak O, Paredes NA, Elkenawy I, Torres M, Bui J, Jahangiri S, Moon W. Tomographic assessment of palatal suture opening pattern and pterygopalatine suture disarticulation in the axial plane after midfacial skeletal expansion. *Prog Orthod.* 2020;21:21.

[36] Cantarella D, Savio G, Grigolato L, Zanata P, Berveglieri C, Lo Giudice A, Isola G, Del Fabbro M, Moon W. A New

Methodology for the Digital Planning of Micro-Implant-Supported Maxillary Skeletal Expansion. *Med Devices (Auckl).* 2020;13:93-106.

[37] Elkenawy I, Fijany L, Colak O, Paredes NA, Gargoum A, Abedini S, Cantarella D, Dominguez-Mompell R, Sfogliano L, Moon W. An assessment of the magnitude, parallelism, and asymmetry of micro-implant-assisted rapid maxillary expansion in non-growing patients. *Prog Orthod.* 2020;21:42.

[38] Auffray, J.C.; Debat, V.; Alibert, P. Shape asymmetry and developmental stability. In: Chaplain MAJ, Singh GD, McLachlan JC, editors. *On Growth and Form: Spatio-Temporal Pattern Formation in Biology.* Chichester: Wiley; 1999. p. 309-324.

[39] Schwarz GM, Thrash WJ, Byrd DL, Jacobs JD. Tomographic assessment of nasal septal changes following surgical-orthodontic rapid maxillary expansion. *Am J Orthod.* 1985;87:39-45. doi: 10.1016/0002-9416(85)90172-1.

[40] Abedini S, Elkenawy I, Kim E, Moon W. Three-dimensional soft tissue analysis of the face following micro-implant-supported maxillary skeletal expansion. *Prog Orthod.* 2018;19:46.

[41] Singh GD, McNamara JA Jr., Lozanoff S. Morphometry of the cranial base in subjects with Class III malocclusion. *J. Dent. Res.* 1997;76: 694-703.

[42] Singh GD, Levy-Bercowski D, Yañez MA, Santiago PE. Three-dimensional facial morphology following surgical repair of unilateral cleft lip and palate in patients after nasoalveolar molding. *Orthod Craniofac Res.* 2007;10: 161-166.

[43] Kunkel M, Ekert O, Wagner W. [Changes in the nasal airway by transverse distraction of the maxilla].

Mund Kiefer Gesichtschir. 1999;3:12-6.  
[Article in German]

[44] Iwasaki T, Yoon A, Guilleminault C, Yamasaki Y, Liu SY. How does distraction osteogenesis maxillary expansion (DOME) reduce severity of obstructive sleep apnea? *Sleep Breath.* 2020;24:287-296.

[45] Cozza P, Di Girolamo S, Ballanti F, Panfilio F. Orthodontist-otorhinolaryngologist: an interdisciplinary approach to solve otitis media. *Eur J Paediatr Dent.* 2007;8:83-88.

[46] Gray LP. Results of 310 cases of rapid maxillary expansion selected for medical reasons. *J Laryngol Otol.* 1975;89:601-614.

[47] Warren DW, Hershey HG, Turvey TA, Hinton VA, Hairfield WM. The nasal airway following maxillary expansion. *Am J Orthod Dentofacial Orthop.* 1987;91:111-116.

[48] Bicakci AA, Agar U, Sökücü O, Babacan H, Doruk C. Nasal airway changes due to rapid maxillary expansion timing. *Angle Orthod.* 2005;75:1-6.

[49] Ceroni Compadretti G, Tasca I, Alessandri-Bonetti G, Peri S, D'Addario A. Acoustic rhinometric measurements in children undergoing rapid maxillary expansion. *Int J Pediatr Otorhinolaryngol.* 2006;70:27-34.

[50] Compadretti GC, Tasca I, Bonetti GA. Nasal airway measurements in children treated by rapid maxillary expansion. *Am J Rhinol.* 2006;20:385-393.

[51] Palaisa J, Ngan P, Martin C, Razmus T. Use of conventional tomography to evaluate changes in the nasal cavity with rapid palatal expansion. *Am J Orthod Dentofacial Orthop.* 2007;132:458-466.

[52] Oliveira De Felippe NL, Da Silveira AC, Viana G, Kusnoto B, Smith B, Evans CA. Relationship between rapid maxillary expansion and nasal cavity size and airway resistance: short- and long-term effects. *Am J Orthod Dentofacial Orthop.* 2008;134:370-382.

[53] Enoki C, Valera FC, Lessa FC, Elias AM, Matsumoto MA, Anselmo-Lima WT. Effect of rapid maxillary expansion on the dimension of the nasal cavity and on nasal air resistance. *Int J Pediatr Otorhinolaryngol.* 2006;70:1225-1230.

[54] Hershey HG, Stewart BL, Warren DW. Changes in nasal airway resistance associated with rapid maxillary expansion. *Am J Orthod.* 1976;69:274-284.

[55] Doruk C, Sökücü O, Sezer H, Canbay EI. Evaluation of nasal airway resistance during rapid maxillary expansion using acoustic rhinometry. *Eur J Orthod.* 2004;26:397-401.

[56] Timms DJ. The effect of rapid maxillary expansion on nasal airway resistance. *Br J Orthod.* 1986;13:221-228.

[57] Hartgerink DV, Vig PS, Abbott DW. The effect of rapid maxillary expansion on nasal airway resistance. *Am J Orthod Dentofacial Orthop.* 1987;92:381-389.

[58] White BC, Woodside DG, Cole P. The effect of rapid maxillary expansion on nasal airway resistance. *J Otolaryngol.* 1989;18(4):137-143.

[59] Wollens AG, Goffart Y, Lismonde P, Limme M. [Therapeutic maxillary expansion]. *Rev Belge Med Dent* (1984) 1991;46:51-8. [Article in French]

[60] Iwasaki T, Papageorgiou SN, Yamasaki Y, Ali Darendeliler M, Papadopoulou AK. Nasal ventilation and rapid maxillary expansion (RME): a

randomized trial. *Eur J Orthod.* 2021  
Feb 10:cjab001.

[61] Calvo-Henriquez C, Megias-Barrera J, Chiesa-Estomba C, Lechien JR, Maldonado Alvarado B, Ibrahim B, Suarez-Quintanilla D, Kahn S, Capasso R. The impact of maxillary expansion on adults' nasal breathing: A systematic review and meta-analysis. *Am J Rhinol Allergy.* 2021;1945892421995350. doi: 10.1177/1945892421995350. Epub ahead of print.

[62] Levrini L, Lorusso P, Caprioglio A, Magnani A, Diaféria G, Bittencourt L, Bommarito S. Model of oronasal rehabilitation in children with obstructive sleep apnea syndrome undergoing rapid maxillary expansion: Research review. *Sleep Sci.* 2014;7:225-233.

[63] Kiliç N, Oktay H. Effects of rapid maxillary expansion on nasal breathing and some naso-respiratory and breathing problems in growing children: a literature review. *Int J Pediatr Otorhinolaryngol.* 2008;72:1595-1601.

[64] Pirelli P, Saponara M, Attanasio G. Obstructive Sleep Apnoea Syndrome (OSAS) and rhino-tuberc dysfunction in children: therapeutic effects of RME therapy. *Prog Orthod.* 2005;6:48-61.

[65] Garcez AS, Suzuki SS, Storto CJ, Cusmanich KG, Elkenawy I, Moon W. Effects of maxillary skeletal expansion on respiratory function and sport performance in a para-athlete – A case report. *Phys Ther Sport* 2019;36:70-77.