

# We are IntechOpen, the world's leading publisher of Open Access books Built by scientists, for scientists

5,500

Open access books available

135,000

International authors and editors

165M

Downloads

Our authors are among the

154

Countries delivered to

TOP 1%

most cited scientists

12.2%

Contributors from top 500 universities



WEB OF SCIENCE™

Selection of our books indexed in the Book Citation Index  
in Web of Science™ Core Collection (BKCI)

Interested in publishing with us?  
Contact [book.department@intechopen.com](mailto:book.department@intechopen.com)

Numbers displayed above are based on latest data collected.  
For more information visit [www.intechopen.com](http://www.intechopen.com)



# Impact of Sugar on Vision

*Grace Ogbonna, Rosemary Ehigbo and Ogbonna Hannah*

## Abstract

Sugar forms an integral part of the human body, and contributes to normal body function. However, sugar in high quantities can be detrimental to the body especially to the eye. In the normal concentration, sugar in the form of glucose is found in the aqueous humour, and tears, and serves to provide nourishment to the avascular cornea, and lens respectively. Sugar at this stage may also be used to determine the post mortem interval of a cadaver. However, when in excess as may be seen in patients with diabetes, sugar can cause oxidative stress to the cornea, lens, and retina resulting in cornea oedema, cataract, retinal aneurysm which can contribute significantly to the prevalence of low vision, and vision impairment.

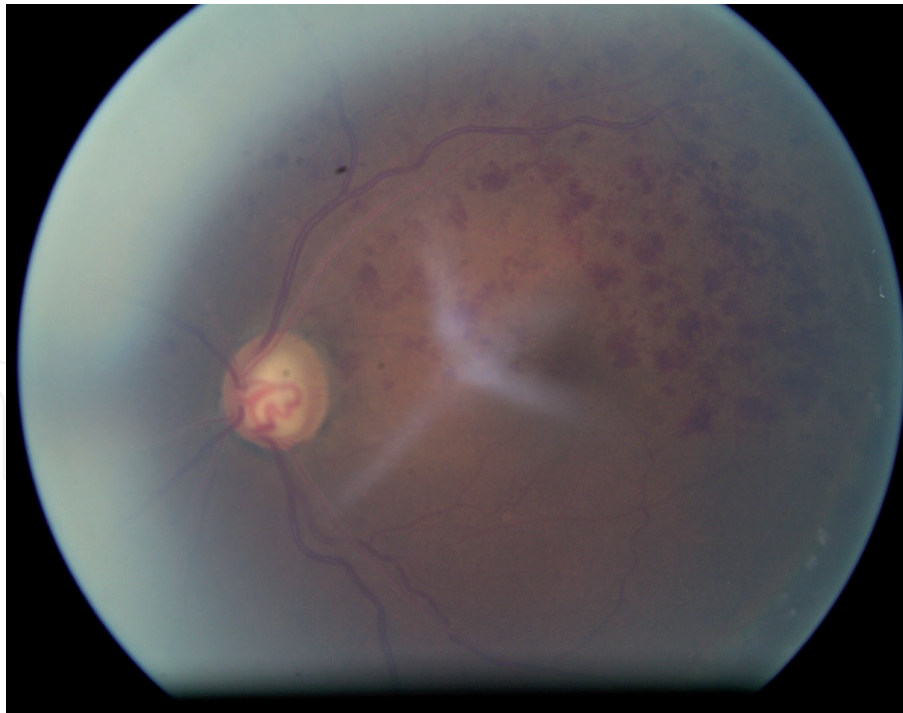
**Keywords:** sugar, cataract, oxidative stress, aneurysm

## 1. Introduction

Sugar forms an integral part of the human eye, and can be found in different parts of the eye including the tears, aqueous humour, and the lens. Its primary function in the eye includes; maintenance of the structural component of the eye, and the provision of nourishment to the surrounding structures of the eye wherein it is found. For instance, glucose found in the aqueous humour forms part of the required nourishment to the avascular lens, and cornea [1]. In the tears, sugar in the form of glucose forms part of the nutrients that supply the avascular cornea. The sugar in the vitreous is present as hyaluronic acid which is a molecular unit of glucuronite, and N-acetylglucosamine. Its function is to maintain the point of vitreous attachment to the retina. In general, sugar is important for the normal functioning of the human eye. In the lens, sugar is found as polysaccharides. Meyer *et al* [2] showed that there are at least three different polysaccharides in the cornea stroma - keratin sulfate, chondroitin-4-sulfate, and chondroitin, and may play a role in cornea healing.

Despite the role of sugar in maintaining the metabolic requirements of the human body, excessive sugar consumption can lead to high sugar concentration in blood circulation within the body system which can be detrimental to human health. Sustained high sugar level results in hyperglycaemia, and if left unchecked can result in Diabetes Mellitus. Diabetes mellitus is a group of metabolic diseases, characterized by chronic hyperglycaemia due to deficiency in the production, and/or usage of insulin. Diabetes mellitus can occur as either Type 1 (due to poor secretion of insulin) or Type 2 (due to poor usage of insulin for glucose metabolism).

Diabetes Mellitus presents with a myriad of ocular complications and has been identified as the leading cause of legal blindness globally. Complications secondary to diabetes affects almost every part of the eye and could result in diabetic retinopathy, cataracts, glaucoma, keratopathy, dry eye syndrome, and so many others (Figure 1).



**Figure 1.**  
*Fundus picture of a proliferative diabetic retinopathy.*

In recent years, diabetes mellitus has become a serious public health concern as the number of diabetic patients worldwide has more than doubled over the last three decades. In 2010, 286 million people were said to be diabetic, and this was projected to increase to 439 million by 2030 [3]. As the prevalence of DM, duration, and onset increases, the number of patients with ocular complications due to the condition is also expected to increase.

## **2. Mechanism of action of the effect of hyperglycaemic on the eyes**

The mechanism of action of hyperglycaemia on the eyes and the consequential damage to the eyes have been likened to that of the effect of ageing on the eye [4]. Various factors such as pro-inflammation, oxidative stress, glycosylated cross-linkages, the formation of advanced glycelated end-products (AGE), vascular permeability, vascular endothelial growth factor (VEGF), and epigenetic factors have been found to cause to ageing changes in the eye. Similarly, these factors have been implicated in the development of ocular complications secondary to sustained increased sugar levels in the body [5–7].

Further, Insulin resistance as may be seen in diabetic patients has been associated with the repression of a Sirtuin 1 (Sirt 1) [8], which is the gene responsible for the regulation of appetite in the geriatric population. Sirt 1 is also known as the anti-ageing gene due to its ability to alleviate oxidative stress [8–10]. Repression of Sirt 1 gene may lead to mitochondrial apoptosis, and in diabetic patients can also lead to diabetic retinopathy due to oxidative stress [8, 10, 11].

## **3. Sugar, and the lens: an overview**

The human crystalline lens is the structure directly behind the iris, and in front of the vitreous humour [1]. The lens thickness and curvature allows it to

contribute significantly to refraction [12]. It is also responsible for accommodation in non-presbyopic, and pre-presbyopic people. Its transparent nature allows for the passage of light to the retina. Physiologically, the lens contains 2/3 water, and 1/3 protein (water-soluble and water-insoluble proteins) [13]. Water-soluble proteins are responsible for maintaining the lens optical properties. On the other hand, water-insoluble protein maintains cellular structures, architectural arrangement, and alignment.

The lens lacks blood vessel supplies to it and is therefore regarded as avascular. Due to the lack of blood vessels in the lens, it acquires most of its nutrition from the aqueous humour, through the aerobic glycolysis, or through the pentose phosphate pathway (sorbitol pathway). The sorbitol pathway is believed to be a pathway through which glucose, and galactose from the aqueous humour is absorbed into the lens [14]. When glucose is absorbed, it is reduced to sorbitol by the aldose reductase enzyme. Further to this, sorbitol is metabolized by the sorbitol dehydrogenase, whereas galactitol remains in the lens nearly not metabolized for a prolonged period. In diabetes, the increased presence of sugar in the blood results in increased glucose level in the aqueous, therefore bringing about increased sugar inflow into the lens through the sorbitol pathway [15]. Unfortunately, the sorbitol is produced faster than it is converted to fructose by the sorbitol dehydrogenase. This, therefore, means an increased amount of sorbitol in the lens. The prolonged presence of sorbitol in the lens results in increased intracellular fluid as a response to increased osmotic pressure, therefore causing the swelling of the lens material. Further, because sorbitol is polar, it is hardly removed from the lens through simple diffusion.

### **3.1 Sugar, and cataract**

Sustained hyperglycaemia causes the inflow of sugar into the lens resulting in the swelling of the lens material. This also results in the loss of the lens structural arrangement (lens fibres), precipitation of the water-insoluble proteins, oxidation of the water-insoluble proteins, hardening of the lens fibres, formation of permanent bonds, and eventually cataract.

Sugar induced cataract is a common occurrence, and a significant cause of visual impairment among diabetic patients. According to the Framingham study findings, diabetic patients under 65 are four times more likely to develop cataracts than their normal age mates. The onset of cataract in diabetes is often associated with fluctuations in the sugar level of a sufferer, and the cataract progresses rapidly once initiated. Even though the process of cataract formation in a diabetic patient is known, however, there is no known mechanism to delay its formation in the presence of Hyperglycaemic [16]. Nevertheless, cataract surgery is a recommended, and effective way of managing diabetic cataracts.

Early cataract extraction in diabetic patients though recommended, should be approached with caution, and is advisable to be done with regulated blood sugar levels as healing may be delayed due to Hyperglycaemic [17, 18]. Although, a study in Nigeria reported no significant difference in the visual outcome of diabetic patients post-cataract when compared to age-matched nondiabetic controls, however, complications such as rubeosis, acceleration in the formation of retinopathy, post-operative inflammation,, and incidence of clinical, and angiographic cystoid oedema has been reported to occur more in diabetic patients following cataract extraction [19]. Given these complications, the preferred method of cataract extraction in diabetic patients is phacoemulsification as this has been associated with fewer complications, and better prognosis.

### **3.2 Sugar, and refractive error**

Refractive changes have been noted to occur in diabetic patients. A number of earlier clinical studies had reported an association between sustained hyperglycaemia, and refractive shift towards increased myopia [12, 19, 20]. Myopic shift occurs when a diabetic patient experiences more myopia than the regular refractive error status. This happens due to an increase in the inflow of sugar into the lens through the sorbitol pathway catalysed by the aldose reductase activity [21, 22]. People with diabetes have been observed to have a higher prevalence of myopia compared to those without diabetes [23]. In a study conducted by Jacobsen *et al* [24] it was determined that the prevalence of myopia (spherical equivalent 0.5 D) was 53.3% among 252 type 1 diabetic patient age 16–26 years old. The relative risk of a myopic shift was determined to be 1.7 in patients aged 16–21 years, and 1.6 in patients with HbA1c above 8.8%. Insulin dosage was not related to myopia. Klein *et al.* [21] showed that persons of similar age with T1D were likely to be more myopic than those with T2D. In general, myopia associated with diabetes reverses when sugar control is instituted.

Although past studies had reported a myopic shift in refractive status following an increase in sugar level, however, recent studies have also noted a hyperopic shift associated with glycaemic control [25, 26]. Hyperopic shift following hyperglycaemia control has been reported to occur when glucose levels fall a few days or weeks after the initiation of glycaemic control [12, 27]. This hyperopia was associated with increased lens thickness, and a decrease in anterior chamber depth [22]. Lin *et al* [12] reported the development of hyperopia in 4 men and 1 woman who was treated with insulin. According to their report, the hyperopia peaked at 11.7 days after initiation of glycaemic control and tapered off at 64.0 days after treatment initiation. From this it can be deduced that institution of treatment in diabetic patients is often followed by two refractive changes; one involving a rapid refractive change towards the direction of hyperopic, and the other is a gradual change to the patient's normal refractive status.

In general, both myopic, and hyperopic shifts are transient, and patients' refractive status gradually returns to the baseline values a few days or weeks after sugar stabilizes. Thus, it can be said that both myopic, and hyperopic shift may occur with changes in sugar levels in a hyperglycemic patient [25]. Hence, change in prescription glasses should be approached with caution as glasses prescribed during this time will only be durable during the said sugar fluctuations [28].

### **3.3 Sugar, and accommodation**

Several studies have reported on biometric changes such as lens thickening, increase in the lens surface curvature and a decrease in the refractive index secondary to diabetes [29]. According to Mathebula, and Makunyane “people with diabetes have accelerated age-related biometric ocular changes compared to people without diabetes” [4]. Elevated sugar levels in pre-presbyopic patients have been associated with a reduction in the amplitude of accommodation. According to Huntjens and O'Donnell, amplitude of accommodation is lower in people living with Type I patients than that of their non-diabetic age-matched, even in the absence of non-detectable retinal damage [25].

Amplitude of accommodation is important for maintaining images on the retina while doing near work. A reduction in amplitude of accommodation means that the near point becomes receded, and a patient will have difficulties reading things at near as seen in presbyopic patients. This has unfortunately been found in pre-presbyopic diabetic patients who show signs of presbyopia earlier than their age

match nondiabetic counterparts. The effect of hyperglycaemia on the accommodative system may be due to changes in lens glucose metabolism, ischemic hypoxia on the oculomotor nerve, and ciliary muscles. Some studies have noted that the longer the duration of diabetes, the more likely the reduction in the amplitude of accommodation.

#### **4. Sugar, and the cornea**

The cornea is a superficial organ most affected by high sugar levels [30]. The impact of sugar on the cornea varies with its level and duration, and may underpin specific systemic complications that may be associated with diabetes. At normal glycaemic levels, sugar serves as one of the dissolved nutrients in the tears, and aqueous humour that nourishes the cornea. Sugar is also found in the cornea stroma in the form of polysaccharides (glycosaminoglycan GAG) [31]. GAG reduces the effects of diffraction when light is directed towards the eye. Chondroitin sulphate an element that plays a role in cornea wound healing is also made from polysaccharides.

However, in diabetes, sugar promises to be detrimental to the anatomical and physiological wellbeing of the cornea. Structural components such as the epithelium, the nerves, immune cells, and the endothelium of the cornea are often negatively affected. Sustained hyperglycaemia reduces cornea sensitivity and innervation due to peripheral neuropathy. These nerve alterations occur all over the cornea including at the cornea scleral junction (limbal region) where new epithelial cells are formed [31]. When there is a reduction in corneal sensitivity, affected patients experiences various symptoms, and in most cases become susceptible to further damages to the eye. Reduction in corneal sensitivity has been identified as a predictor for the development of peripheral neuropathy in diabetic patients.

Other cornea complications such as corneal infections, ulcers, and oedema have been reported in diabetic patients with poorly controlled glycaemic levels. Sugar induced cornea swelling increases the fragility of the cornea epithelium and can result in stroma oedema [32]. This for unknown reasons affects the stromal collagen bundles and increases corneal autofluorescence level. The variation between the normal fluorescence level and increased autofluorescence in the corneal may be an indicator of changed corneal metabolism due to impaired corneal mitochondria metabolism. Corneal fluorescence may also be an indicator of a pathological breakdown of the blood-aqueous- barrier as may be seen in patients with proliferative diabetic retinopathy.

Sustained hyperglycaemic levels in the body also increases the chances of corneal erosions, persistent epithelial defects, corneal endothelial damage, and dry eye [6, 22, 32]. With Sustained hyperglycaemia the cornea faces difficulties with wound healing, and most times there is incomplete wound healing, thus small corneal erosions become persistent as wound healing is delayed. Delayed wound healing has been linked to a reduction in cornea epithelium regeneration secondary to a decrease in cornea sensitivity, which occurs as a result of peripheral neuropathy [6]. linked Further, because the ability of the cornea to ward off infections is reduced, infections like fungal keratitis occurs and remains recurrent [33].

#### **5. Sugar, and the lids, and conjunctiva**

The lids and conjunctiva are tissues in the body that protects the eye against external invaders. Sustained high blood sugar level increases the susceptibility

of the human system to bacterial infection. In the lid, this susceptibility leads to a recurrent bacterial infection which can lead to the formation of sty, and blepharitis.

High sugar and reduced insulin as is obtainable in diabetes pose damaging consequences to the meibomian gland. Like other sebaceous glands, insulin forms an essential component for the optimal functioning of the sebaceous glands and resistance or reduction in its absorption results in the dysfunction of the Meibomian gland. Similarly, sustained increase in sugar level brings about the lipolysis of adipocytes, this, therefore, means that sustained sugar levels in the Meibomian gland will reduce the quality of the meibum secreted in the eye. Meibum is the secretion responsible for ensuring the liquid part of the tears (aqueous) does not overflow or evaporate, hence reduction in the quality of meibum would allow for tear evaporation, bringing about dry eye effect in diabetic patients.

Similarly, the goblet cells found in the conjunctiva which are responsible for the production of the mucin layer of the tear film are often adversely affected with Hyperglycaemic. Diabetes also affects the conjunctival blood vessels in similar ways as it does to the retinal blood vessels [34]. In the conjunctiva, capillary loss, and microvascular dilatation had similarly been observed as a consequence of sustained hyperglycemia. Similarly, studies have reported on the tortuosity of conjunctival blood vessels.

## **6. Sugar, and dry eye**

Dry eye is a disorder of the tear film which results in symptoms such as pain, burning, itchiness, stinging, grittiness, foreign body sensation, tearing, and ocular fatigue. Due to the multifactorial nature of dry eye onset, it has been referred to as a disease of the lacrimal function unit (LFU). The lacrimal function unit is made up of the cornea, lid, conjunctiva, Meibomian gland, the sensory, and the motor nerves which all work as a unit to maintain the tear film layer. Dry eye is a common experience in diabetic patients.

The occurrence of dry eye in a diabetic patient may be as a result of the negative effect of hyperglycaemia on any part of the lacrimal function unit. For instance, insufficient production of tears due to reduced cornea sensitivity secondary to autonomic neuropathy has been blamed as part of the reason for dry eye development in diabetic patients [35]. Corneal sensitivity forms part of the neuronal loop feedback mechanism for reflex tear secretion. Autonomic neuropathy affects the nerves that control the lacrimal gland secretion, bringing about a reduction in tears secretion, due to reduced corneal sensitivity. For instance, damage to the microvasculature of the lacrimal gland accompanied by autonomic neuropathy in diabetic patients often impairs lacrimation, therefore, resulting in dry eye symptoms in such a patient. The reduction in tear secretion accounts for the low Schirmer test result as may be seen in diabetic patients. It is noteworthy that once corneal peripheral neuropathy sets in, corneal sensitivity starts and the magnitude of reflex tear secretion is affected.

Also, dry eye may result due to a reduction in the population density of the goblet cells secondary to the effect of diabetes on the cells on the goblet cell function [22]. The goblet cells are responsible for the secretion of mucin which is the first layer of the tear film. The mucin layer is responsible for maintaining the tear film layer on the cornea to avoid the drying out of the cornea and maintaining its lustre. Therefore, a reduction in the density of the goblet cells will bring about a decrease in the secretion of the mucin layer, resulting in the inability of the tear film to remain stable on the cornea. Also, alongside the reduction in goblet cell density,

there is an accompanying reduction in the ability of the mucin layer to “pick-up-up’ the cytology impression necessary to maintain the tear film spreading, and stability on the cornea. These two factors (goblet cell density, and mucin sensitivity), have been cited to partly be responsible for the reduction in the tear break-up time.

Some retinal changes, and procedures have similarly been linked with dry eye in patients with prolonged, and sustained hyperglycaemia. Reduction in total tear secretion has been reported in patients with non-proliferative diabetic retinopathy. This on the other hand is relatively small in people without retinopathy. Also, pan-retinal photocoagulation has been suggested to increase dry eye syndrome in patients.

Dry eye symptoms in diabetic patients are often associated with longer duration of the disease; it may also be associated with glycaemic level (HBA1c) [36]. Further, poorly controlled glycaemic level has been associated with more symptoms of dry eye. The most frequently encountered dry eye disease symptoms in diabetic patients include itching, burning, and foreign body sensation. Detection of dry eye in a diabetic patient can be achieved through conducting a comprehensive eye examination, which among others should measure the volume of tears, and determine the quality of the tears. This can be achieved by running specific diagnostic tests such as the Tear Film Break-Up Time (TFBUT), fluoresce test, Schirmer test, and rose Bengal. Management of dry eye in patients with diabetes strongly revolves around glycaemic control, and healthy lifestyle.

## **7. Sugar, and the iris**

Hyperglycaemia affects the iris in various ways. Morphologically, changes in the iris structure, vessels, pigment granules, and vacuolation of the pigment. The iris epithelium due to hyperglycaemia can experience depigmentation of the cells which often deposits on the corneal endothelium or is washed by the aqueous flow to the trabecular meshwork where it could block the outflow of aqueous from the meshwork, therefore resulting in the building of ocular tension (increased intraocular pressure). Also, Hyperglycaemic may cause rubeosis iridis (the formation abnormal blood vessels on the epithelial layer of the iris), a response that has been associated with ischaemia secondary to retinal capillary dropout.

Further, abnormal iris transillumination has been reported to occur in type 2 diabetes patients. This has been associated with short term retinopathy and is said to be an indicator or marker for rapidly progressive retinopathy in diabetes [37]. Similarly, ultrastructural changes have been reported in the regions of the sphincter, and dilator muscles of the iris, with more of the changes seen in the iris, this may explain why the pupil in diabetic patient’s experience miosis while in dark rooms.

## **8. Sugar, and the vitreous**

In the presence of hyperglycaemia, the vitreous gel and vitreous interface experiences alterations which are often predictors to the development of diabetic retinopathy. Changes in the vitreous gel due to diabetic mellitus may include; increased collagen fibril cross-linking, accumulation of advanced glycation end products, liquidation of the vitreous gels, vitreous haemorrhage and alteration in the concentration of various proteins present in the vitreous [38, 39]. In some cases, there may also be the development of new vessel on the vitreous surface, this can happen in response to retinal ischemia and can result in a structural change in



the vitreous [40, 41]. The presence of severe non-clearing vitreous haemorrhage may be an indicator for the.

## **9. Sugar, and the retina**

Sugar affects different layers of the retina, and in most cases is very detrimental, and can lead to blindness. Diabetic retinopathy is the most common cause of visual impairment in patients living with diabetes.

### **9.1 Sugar, and diabetic retinopathy**

Diabetic retinopathy is a microvascular complication of diabetes. It is said to occur to some degree in almost all type 1 diabetic patients and in nearly 77% of people living with type 2 diabetes for more than 2 decades [7]. Its formation has been linked to hyperglycaemic induced electrolyte imbalance secondary to high aldose reductase levels in the retina [39]. The electrolyte imbalance leads to the loss of retinal endothelial cells and loss of vascular pericytes which are responsible for regulating the retinal vascular tone. Loss of endothelial cells results in the breakdown of the blood-retinal-barrier resulting in an increase in the vascular permeability. On the other hand, the loss of the pericytes results in vasodilation and the thickening of the capillary basement membrane all of which leads to microaneurysm (formation of small outpouchings from blood vessel walls) [42], a primary indicator of early retinopathy changes in diabetes [43].

There are different stages of diabetic retinopathy: mild non-proliferative diabetic retinopathy, pre-proliferative diabetic retinopathy, and proliferative diabetic retinopathy. According to the findings of the Wisconsin study, the prevalence of retinopathy in patients with diabetes increases from 2% to 97.5% in people with diabetes less than 2 years, and 15 or more years respectively. Prevalence of proliferative retinopathy was notably at zero but increased with age to 4%, 25%, and 67% among diabetic patients who had lived with diabetes for 10 years, 15 years, and 35 years respectively. Proliferative diabetic retinopathy is the most complicated stage of diabetic retinopathy and is often associated with other complications such as vitreous haemorrhage, tractional retinal detachment, combined tractional rhegmatogenous retinal detachment, and severe fibrovascular proliferation.

Proliferative diabetic retinopathy is said to occur due to prolonged retinal ischemia secondary to Hyperglycaemic. Retinal ischemia leads to the production of angiogenic factors which are produced in an attempt for the retina to revascularize the hypoxic areas of the retina. Thus the release of angiogenic factors is the retinal way of seeking for a secondary means of transporting oxygen to the affected parts of the retina. After the formation of the angiogenic factor, there appears to be an interaction between the angiogenic factors, and the vascular endothelial growth factor (VEGF) thereby inducing the growth of new blood vessels (neovascularization). The new vessels are fragile, and can easily rupture, but they proliferate persistently. The proliferation of the new blood vessels is accompanied by varying degrees of fibrous tissue proliferation. Fibrous tissue proliferation into the vitreoretinal interface brings about the formation of fibrovascular membranes in the vitreoretinal interface.

The fibrovascular tissues attach themselves to the vitreoretinal interface focally (at a point) or broadly (at different points). The point of attachment of the fibrovascular tissue to the vitreoretina exerts tractional forces at these points, therefore, pulling on the retina, and resulting in tractional retinal detachment.

Although the duration and glycaemic control play a role in the development of retinopathy, genetics, and individual disparity contribute significantly to the development and degree of retinopathy. Diabetic retinopathy has been cited to occur more globally in Latin Americans, and South Asians [5]. Clustering of diabetic retinopathy among people of similar ethnicity suggests that genetics could play a significant role in its development. The role of familial genetics in the development of diabetic retinopathy was demonstrated by Leslie and Pyke who found that 95% of concordant type 2 diabetic twins versus 68% of concordant type 1 diabetic identical twins develop a similar degree of diabetic retinopathy. Also, siblings with diabetes have similar levels of diabetes when compared to other levels of retinopathies seen in non-family members. Familial clustering for the risk of developing severe retinopathy to increase among those who have diabetic relatives with positive retinopathy with an odds ratio of 5.4 compared to those whose relatives do not have the retinopathy [44].

Further, the genes responsible for encoding the aldose reductase (ALR), Angiotensin-1-converting enzyme, endothelial nitric oxide synthase (eNOS), a receptor for advanced glycation end products (RAGE), and Vascular Endothelial Growth Factor (VEGF), has been implicated in the development of Diabetic retinopathy [44]. Also, evidence exist which suggest that low-grade inflammatory responses underlies the resultant vascular complications seen in diabetes retinopathy. This, therefore, implies that diabetic retinopathy is an inflammatory disease that results due to elevated systemic cytokines like TNF- $\alpha$ , and IL-1 $\beta$ , and elevated numbers of activated leukocytes circulating in the retinal blood vessels.

The role of angiotensin II in the formation of diabetic retinopathy has been well studied with most studies promoting possible retardation of the proliferation process seen in diabetic retinopathy through the use of drugs that blocks the renin-angiotensin system. This is because angiotensin II which promotes vascular remodelling, and proliferation can cause an increase in the growth of capillaries, and cell permeability, and oxidative stress which is common in the formation of diabetic retinopathy.

The role of vasodilators like nitric oxide has rather been inconclusive, and a matter of debate. While some researchers believe that nitric oxide could lead to retinal damage and death, some others believe that nitric oxide enzyme may be protective in the development of diabetic retinopathy. Also, the actions of Glucagon-Like-Peptide-1 (GLP-1) a 30-amino acid, which is a hormone produced in the intestine, and helps in regulating blood glucose has been found to play a protective role on the retinal cells via the reduction of oxidative stress on the retina, which is protective in the development of diabetic retinopathy [11]. The action of GLP-1 is often activated by SIRT1 an anti-ageing gene.

## **10. Sugar and the optic disc, and nerve**

Sustained sugar level affects the optic nerve resulting in nerve abnormalities, for instance, the optic disc often experiences pronounced oxidative stress, ischaemia, and neurodegeneration which eventually results into loss of the retinal nerve fibre layer, and optic atrophy. Optic atrophy may occur due to the inability of the nerves to access nourishment secondary to hyperglycaemia. Optic atrophy secondary to hyperglycaemia is very common in diabetic patients who are in their fourth decade of life. Although this presents no symptoms, it requires constant monitoring as it may ensure to proliferative diabetic retinopathy.

Optic nerve atrophy may also occur as a result of damage following photocoagulation treatment. This often shows a characteristics appearance that is abnormal

which may or may not be similar to glaucomatous damage [45]. This is due to nerve damage that may be associated with the destruction of the axons of the retinal ganglion cells following pan-retinal photocoagulation. Other causes of optic atrophy may include previous diabetic papillopathy, nonarteritic ischemic neuropathy, and multiple nerve fibre layer infarcts.

Neovascularization at the optic disc head may also occur especially in the proliferative stage of diabetes. Although the formation of these vessels are mechanisms by which the eye seems to transport oxygen to areas without nourishment, however, the new vessels formed are both fragile, and vulnerable to rupture, hence presents a danger to the eye.

## **11. Diabetes induced maculopathy**

Diabetes induced maculopathy is a common occurrence in people with diabetic retinopathy [41]. Its prevalence is often determined by the type of diabetes, the severity of diabetic retinopathy, and duration of the disease. Type 1 diabetic patients are less likely to develop maculopathy, than type 2 diabetic patients [40]. Also, the occurrence of maculopathy in type 1 diabetic patients is highly dependent on the duration of the disease. Most of the patients with type 1 diabetes will rarely develop maculopathy before 8 years of the disease, with about 25–30% developing maculopathy after 20 years of the disease [41, 43]. About 3% of type 2 diabetic patients with non-proliferative retinopathy will have macular oedema, whereas between 40%, and 70% of those with moderate, and proliferative retinopathy respectively would end up developing macular oedema. Among this population, nearly half of them will experience fovea involvement of the macula oedema [43].

## **12. Pupil involvement in diabetes**

Pupillary involvement is a common occurrence in diabetic patients and has been suggested to be due to autonomic neuropathy secondary to degenerative changes at the nerve terminal. In the pupil, the autonomous nervous system regulates the sphincter, and dilator muscles which controls the pupillary response to light, accommodation, and drugs. Sustained high sugar level often results in autonomic neuropathy which meant that nerves lose their ability to respond or conduct sensations as they ought to. The occurrence of autonomic neuropathy results in partial denervation of mostly the dilator muscle of the pupil. This, therefore, implies different pupillary responses to normal pupillary stimulus diabetic patients will be affected. For instance, diabetic pupils have excessive miotic pupils in dim illumination, also diabetic pupils experience loss of light reflex, non-syphilitic-Argy Robertson pupil has been reported. Further, variations in response to topical mydriatic agents have similarly been noted.

## **13. Sugar, and glaucoma**

There are still conflicting opinions regarding the relationship between glaucoma and diabetes, however, the mechanism that leads to the autonomic dysfunction in the regulation of intraocular pressure, fluctuation of intraocular pressure, and the increased susceptibility of retinal ganglion cells to cell death can easily be rationalized [46]. According to Negi and Vernon [43], diabetic patients are at high risk

of developing higher intraocular pressures than their non-diabetic counterparts. Proliferative diabetes is one of the leading causes of neovascular glaucoma.

## **14. Sugar, and ophthalmoplegia**

Ophthalmoplegia is a rare adverse effect of diabetes mellitus. It is often associated with multiple cranial nerve palsies affecting nerve III, IV, and VI. Patients with ophthalmoplegia secondary to diabetes often make a full recovery after 12 weeks of the onset of the condition [47]. A study by Kahtani et al. [48] reported ophthalmoplegia to be more common in male than female diabetic patients. Medial squint and Ptosis have also been reported in patients with acute vasculitis due to diabetes mellitus.

## **15. Sugar, and low vision**

Complications secondary to diabetes mellitus is the leading cause of blindness in developed countries [6, 40]. According to global estimates, 5% of the 37 million cases of blindness occur secondary to diabetic retinopathy [7]. However, not all cases of diabetic retinopathy results in blindness, some others cause low vision in affected patients.

Low vision as defined by World Health Organization (WHO), is the visual acuity of less than 6/18 in the best-corrected eye of a patient. It can also be defined as the visual field of less than 10 degrees in a patient. There exists a strong relationship between complications resulting from sustained hyperglycaemia as seen in diabetes and low vision. Some of the complications resulting from hyperglycaemia brings about visual changes in sufferers which may eventually lead to low vision. Some visual changes that have been reported by hyperglycaemic patients include changes in Visual acuity, colour vision, contrast sensitivity, reduction in glare tolerance, and visual field all, of which affects a person's quality of life.

### **15.1 Sugar, and visual acuity**

Because visual acuity status is affected by the status of the retina, cornea, lens, and the anterior chamber, visual acuity is one of the visual functions that is heavily affected by hyperglycaemia at different stages of the disease. Visual acuity may be affected by the presence of Diabetic cataract, which reduces the clarity of the lens. Visual acuity may also be affected by the presence of retinopathy which results in irreversible damage in the visual threshold of the patient. Other causes of reduction in visual acuity in a diabetic patients patient may include macular oedema, corneal haze, variations in the refractive status of the eyes due to variations in glycaemic levels, and procedures such as photocoagulation for diabetic macular oedema [49].

### **15.2 Sugar, and colour vision**

Acquired dyschromatopsia has been reported to be common in people living with type 2 diabetes. The Okubo colour study, conducted among type diabetic patients showed that there is an-increased-adjusted-odds (5.89) for the development of colour vision impairment by type 2 diabetic compared with their age-matched normal glycaemic peers [2]. Some studies have reported an increase in the incidence of acquired, non-sex-linked blue-yellow colour vision deficit in diabetic patients. According to a study by Melisa et al., the blue-yellow colour deficit is more

pronounced as diabetic retinopathy progresses, and is worse among patients who may have undergone laser treatment. The association between colour vision deficit and diabetes may be because diabetes irrespective of stage gradually affects the optic nerve as well as the retina, therefore resulting in abnormalities. Tan et al. also showed that more than 6 duration of type two diabetes may predispose patients to develop colour vision impairment [50].

### **15.3 Sugar and contrast sensitivity**

Contrast sensitivity is a measure of the amount of contrast required to detect or recognize a visual target. It is a very important visual function in a person. Unfortunately, contrast sensitivity has been reported to decline with sustained hyperglycaemia. This has been attributed to retinal neurosensorial losses which may precede the occurrence of retinopathy in diabetic patients [51]. According to studies by Alberto et al. the occurrence of reduced contrast sensitivity is more in type 1 diabetic patients with retinopathy than with those without retinopathy [52]. Reduced contrast sensitivity can also be found in patients with type 2 diabetes. Safi *et al.* showed that contrast sensitivity decline was aggravated with the progression of retinopathy [53].

### **15.4 Sugar and visual field**

Visual field defects have been reported as one of the notable low vision abnormalities that can occur in diabetic patients. Patrick and Lavin reported the occurrence of reversible homonymous hemianopia caused by non-ketotic hyperglycaemia in four patients with type 2 diabetes mellitus. [54]. Their report also noted that among the patients, homonymous hemianopia was the first manifestation of diabetes mellitus type 2 in two of the patients. Other factors such cerebrovascular accident, coexisting glaucoma, and pan-retinal photocoagulation has been reported as reasons for visual field defects in diabetic patients [43].

Visual processing disorders may also be seen in diabetic patients following cerebrovascular accident. Processing defects such as visual neglect and extinction has been reported to be partially reversible in these patients following treatment, and interventions.

## **16. Role of vitreous sugar in the determination of post-mortal interval**

Sugar in the vitreous has found its usefulness in forensic medicine, where it can be used to determine the time of death and possible causes of death. The fact that there are biochemical changes in the blood glucose pathway after death makes the use of blood glucose in the biochemical analysis of the state of a cadaver difficult [55]. However, this difficulty can be overcome if the vitreous humor is used, given that, it is better preserved after death. Use of the concentration of sugar in the vitreous to determine the time of death has gradually gained some level of acceptance in forensic medicine and has been determined to have major advantages over other body fluids. Some of its advantages include its accessibility and the fact that after death it is often protected against putrefaction.

## **17. Effect of low sugar intake on vision**

Although most of the emphasis of the impact of sugar in the eye is often placed on high sugar level, however low sugar level can also be detrimental to the eye.

The impact of low sugar level includes blurred vision, reduced contrast sensitivity, and central scotomas [56, 57].

## 18. Conclusions

Sugar forms a component part of the eye. Its presence at normal concentration is very important for the normal visual function, however when low or high, sugar can have very negative impact on vision.

### Conflict of interest

The authors declare no conflict of interest.

### Author details

Grace Ogbonna<sup>1\*</sup>, Rosemary Ehigbo<sup>2</sup> and Ogbonna Hannah<sup>3</sup>

1 Mzuzu University, Mzuzu, Malawi

2 Specialist Hospital Umuahia, Umuahia, Abia State, Nigeria

3 Umudike College of Agriculture, Umuahia, Nigeria

\*Address all correspondence to: [ogbonnagrace19@gmail.com](mailto:ogbonnagrace19@gmail.com)

### IntechOpen

© 2021 The Author(s). Licensee IntechOpen. This chapter is distributed under the terms of the Creative Commons Attribution License (<http://creativecommons.org/licenses/by/3.0>), which permits unrestricted use, distribution, and reproduction in any medium, provided the original work is properly cited. 

## References

- [1] Chakrabarti A. Posterior capsular rent: Genesis and management. *Posterior Capsul Rent Genes Manag.* 2017;1-279.
- [2] Shoji T, Sakurai Y, Sato H, Chihara E, Takeuchi M. Do type 2 diabetes patients without diabetic retinopathy or subjects with impaired fasting glucose have impaired colour vision? The Okubo Color Study Report. *Diabet Med.* 2011;28(7):865-871.
- [3] Burda N. The Incidence of Dry Eye Disease Related to Long Term Diabetes Mellitus Tip 2. *Juniper Online J Case Stud.* 2017;1(5):5-8.
- [4] Mathebula SD, Makunyane PS. Amplitude of accommodation is reduced in pre-presbyopic diabetic patients. *J Endocrinol Metab Diabetes South Africa.* 2017;22(1):64-68.
- [5] Jeng-Miller KW, Baumal CR. Genetics of Diabetic Retinopathy. Current Management of Diabetic Retinopathy. Elsevier Inc.; 2018. 37-40 p.
- [6] Han SB, Yang HK, Hyon JY. Influence of diabetes mellitus on anterior segment of the eye. *Clin Interv Aging.* 2019;14:53-63.
- [7] Lee C, Adler AI. Epidemiologic Evidence on Antioxidant-related Micronutrients and Diabetic Retinopathy. *Diabetes: Oxidative Stress and Dietary Antioxidants.* Elsevier; 2013. 231-236 p.
- [8] Martins IJ. populations Current Updates in Gerontology Geriatric Medicine and Heat Shock Gene Therapy in Global Populations. 2016;1-5.
- [9] Martins IJ. Anti-Aging Genes Improve Appetite Regulation and Reverse Cell Senescence and Apoptosis in Global Populations. 2016;(January):9-26.
- [10] Zhou M, Luo J, Zhang H. Role of Sirtuin 1 in the pathogenesis of ocular disease ( Review ). 2018;13-20.
- [11] Karbasforooshan H, Karimi G. Biomedicine & Pharmacotherapy The role of SIRT1 in diabetic retinopathy. *Biomed Pharmacother.* 2018;97(October 2017):190-194.
- [12] Lin SF, Lin PK, Chang FL, Tsai RK. Transient hyperopia after intensive treatment of hyperglycemia in newly diagnosed diabetes. *Ophthalmologica.* 2009;223(1):68-71.
- [13] Lund AL, Smith JB, Smith DL. Modifications of the water-insoluble humans lens  $\alpha$ -crystallins. *Exp Eye Res.* 1996;63(6):661-672.
- [14] Pintor J. Sugars, the Crystalline Lens and the Development of Cataracts. *Biochem Pharmacol Open Access.* 2012;01(04):10-12.
- [15] Sorokanich S. Microscopic Findings .— The speci - Martin Wand , MD. 2015;2015.
- [16] Pollreisz A, Schmidt-Erfurth U. Diabetic Cataract—Pathogenesis, Epidemiology and Treatment. *J Ophthalmol.* 2010;2010:1-8.
- [17] Kumar CM, Seet E, Eke T, Dhatariya K, Joshi GP. Glycaemic control during cataract surgery under loco-regional anaesthesia: a growing problem and we are none the wiser. *Br J Anaesth.* 2016;117(6):687-691.
- [18] Onakpoya OH, Bekibele CO, Adegbehingbe SA. Control Study. 2009;16(2):88-92.
- [19] Balasopoulou A, Kokkinos P, Pagoulatos D, Plotas P, Makri OE, Georgakopoulos CD, et al. Symposium Recent advances and challenges in the management of retinoblastoma

Globe - saving Treatments. BMC Ophthalmol. 2017;17(1):1.

[20] Okamoto F, Sone H, Nonoyama T, Hommura S. Refractive changes in diabetic patients during intensive glycaemic control. Br J Ophthalmol. 2000;84(10):1097-1102.

[21] Klein BEK, Lee KE, Klein R. Refraction in adults with diabetes. Arch Ophthalmol. 2011;129(1):56-62.

[22] Calvo-Maroto AM, Perez-Cambrodí RJ, Albarán-Diego C, Pons A, Cerviño A. Optical quality of the diabetic eye: A review. Eye. 2014;28(11):1271-1280.

[23] Kaštelan S, Gverović-Antunica A, Pečić G, Gotovac M, Marković I, Kasun B. Refractive Changes Associated with Diabetes Mellitus. Semin Ophthalmol. 2018;33(7-8): 838-845.

[24] Jacobsen N, Jensen H, Lund-Andersen H, Goldschmidt E. Is poor glycaemic control in diabetic patients a risk factor of myopia? Acta Ophthalmol. 2008;86(5):510-514.

[25] Robinson et al. City Research Online City, University of London Institutional Repository. City Res Online. 2008;37(9):1591-1601.

[26] Neil Charman W, Atchison DA. Gradients of refractive index in the crystalline lens and transient changes in refraction among patients with diabetes. Biomed Opt Express. 2012;3(12):3033-30342.

[27] Neil Charman W, Atchison DA. Gradients of refractive index in the crystalline lens and transient changes in refraction among patients with diabetes. Biomed Opt Express. 2012;3(12):3033-3042.

[28] Valley SF, Bachelor H, Degree S, Therapy V, Ca P, Therapy V. Diabetes

and Visual Dysfunction ( OTHER ) Pre - VT Progress Eval. 2016;

[29] Bron AJ, Sparrow J, Brown NAP, Harding JJ, Blakytyn R. The lens in diabetes. Eye. 1993;7(2):260-275.

[30] Shih KC, Lam KL, Tong L. A systematic review on the impact of diabetes mellitus on the ocular surface. Nutr Diabetes. 2017;7(3):e251-e210.

[31] DelMonte DW, Kim T. Anatomy and physiology of the cornea. J Cataract Refract Surg. 2011;37(3):588-598.

[32] Ljubimov A V. Diabetic complications in the cornea. Vision Res. 2017;139:138-152.

[33] Wang B, Yang S, Zhai HL, Zhang YY, Cui CX, Wang JY, et al. A comparative study of risk factors for corneal infection in diabetic and non-diabetic patients. Int J Ophthalmol. 2018;11(1):43-47.

[34] Owen CG, Newsom RSB, Rudnicka AR, Barman SA, Woodward EG, Ellis TJ. Diabetes and the Tortuosity of Vessels of the Bulbar Conjunctiva. Ophthalmology. 2008;115(6):27-32.

[35] Achtsidis V, Eleftheriadou I, Kozanidou E, Voumvourakis KI, Stamboulis E, Theodosiadis PG, et al. Dry eye syndrome in subjects with diabetes and association with neuropathy. Diabetes Care. 2014;37(10):e210-e211.

[36] Zhang X, Zhao L, Deng S, Sun X, Wang N. Dry Eye Syndrome in Patients with Diabetes Mellitus: Prevalence, Etiology, and Clinical Characteristics. J Ophthalmol. 2016;2016:1-7.

[37] Voutilainen-Kaunisto R, Niskanen L, Uusitupa M, Teräsvirta M. Iris transluminance in type 2 diabetes. Acta Ophthalmol Scand. 2002;80(1):64-68.



- [38] Wiley HE, Ferris FL. Nonproliferative Diabetic Retinopathy and Diabetic Macular Edema. Fifth Edit. Vol. 2, Retina Fifth Edition. Elsevier Inc.; 2012. 940-968 p.
- [39] Ciulla TA, Amador AG, Zinman B. Diabetic retinopathy and diabetic macular edema: Pathophysiology, screening, and novel therapies. *Diabetes Care*. 2003;26(9):2653-2664.
- [40] Vieira-Potter VJ, Karamichos D, Lee DJ. Ocular Complications of Diabetes and Therapeutic Approaches. *Biomed Res Int*. 2016;2016.
- [41] Howells LH. Ocular complications of diabetes mellitus. *Br J Ophthalmol*. 1953;37(12):716-724.
- [42] Qian H, Ripps H. Neurovascular interaction and the pathophysiology of diabetic retinopathy. *Exp Diabetes Res*. 2011;2011.
- [43] Negi A, Vernon SA. An overview of the eye in diabetes. *J R Soc Med*. 2003;96(6):266-272.
- [44] Brownlee M, Aiello LP, Cooper ME, Vinik AI, Plutzky J, Boulton AJM. Complications of Diabetes Mellitus **BIOCHEMISTRY AND MOLECULAR CELL BIOLOGY**. Thirteenth. *Biochemistry and Molecular Cell Biology*. Elsevier Inc.; 2017. 1484-1581 p.
- [45] Su RF, Su C, Tan XB, Zhang L. Effect of panretinal photocoagulation on retinal nerve fiber layer thickness and visual field in diabetic retinopathy. *Int Eye Sci*. 2020;20(1):154-157.
- [46] Khan A, Petropoulos IN, Ponirakis G, Malik RA. Visual complications in diabetes mellitus: beyond retinopathy. *Diabet Med*. 2017;34(4):478-484.
- [47] Jabs DA, Miller NR, Green WR. Ischaemic optic neuropathy with painful ophthalmoplegia in diabetes mellitus. 1981;673-678.
- [48] Al Kahtani ES, Khandekar R, Al-Rubeaan K, Youssef AM, Ibrahim HM, Al-Sharqawi AH. Assessment of the prevalence and risk factors of ophthalmoplegia among diabetic patients in a large national diabetes registry cohort. *BMC Ophthalmol*. 2016;16(1):1-8.
- [49] Shrestha GS, Kaiti R. Visual functions and disability in diabetic retinopathy patients. *J Optom*. 2014;7(1):37-43.
- [50] Tan NC, Yip WF, Kallakuri S, Sankari U, Koh YLE. Factors associated with impaired color vision without retinopathy amongst people with type 2 diabetes mellitus: A cross-sectional study. *BMC Endocr Disord*. 2017;17(1):1-8.
- [51] Di Leo MAS, Caputo S, Falsini B, Porciatti V, Minnella A, Greco A V, et al. Nonselective loss of contrast sensitivity in visual system testing in early type I diabetes. *Diabetes Care*. 1992;15(5):620-625.
- [52] Verrotti A, Lobefalo L, Petitti MT, Mastropasqua L, Morgese G, Chiarelli F, et al. Relationship between contrast sensitivity and metabolic control in diabetics with and without retinopathy Relationship between contrast sensitivity and metabolic control in diabetics with and without retinopathy. 2009;3890.
- [53] Safi S, Rahimi A, Raeesi A, Safi H, Amiri MA, Malek M, et al. Contrast sensitivity to spatial gratings in moderate and dim light conditions in patients with diabetes in the absence of diabetic retinopathy. 2017;1-9.
- [54] Lavin PJM. hemianopia : A reversible complication of non-ketotic hyperglycemia. *Neurology*. 2005;65:616-619.

[55] Fors M. Some Considerations about Glucose Determination in Humor Vitreous to Estimate Post Mortem Interval. *Curr Res Diabetes Obes J.* 2018;7(4):3-5.

[56] Mhatre V. Ho and Kelsey C. Martin J-AL. Acute Hypoglycemia Decreases Central Retinal Function in the Human Eye. *Bone.* 2012;23(1):1-7.

[57] Sharma T, Kaur H, Weinstock RS. Visual Symptoms During Hypoglycemia: A Case Series. *AACE Clin Case Reports.* 2015;1(1):e32–e35.

IntechOpen