

# We are IntechOpen, the world's leading publisher of Open Access books Built by scientists, for scientists

5,500

Open access books available

135,000

International authors and editors

165M

Downloads

Our authors are among the

154

Countries delivered to

TOP 1%

most cited scientists

12.2%

Contributors from top 500 universities



WEB OF SCIENCE™

Selection of our books indexed in the Book Citation Index  
in Web of Science™ Core Collection (BKCI)

Interested in publishing with us?  
Contact [book.department@intechopen.com](mailto:book.department@intechopen.com)

Numbers displayed above are based on latest data collected.  
For more information visit [www.intechopen.com](http://www.intechopen.com)



# Movement-Related Cortical Potential Associated with Jaw-Biting Movement in the Patients with Oral Cancer after the Surgery

*Ichiro Nakajima, Mitsuyo Shinohara and Hiroiku Ohba*

## Abstract

Oral cancer is first treated with surgery for the patients. In most cases, it becomes difficult for these patients to perform smooth jaw movements postoperatively, causing masticatory dysfunctions, due to the mandible excision including muscles and peripheral nerves. However, it is still unknown whether the surgery affects the brain function for jaw movement in the patients. In this study, therefore, we investigated a significance of the movement-related cortical potential (MRCP) for jaw movements in the patients after the cancer surgery, to clarify the motor preparation process in the brain, as compared with healthy subjects. Eight normal subjects and seven patients with oral cancers were enrolled in the study. Experiment 1: The normal subjects were instructed to perform jaw-biting movement and hand movement, respectively. The MRCPs appeared bilaterally over the scalp approximately 1 to 2 s before the onset of muscle discharge in both movements. Experiment 2: The MRCPs appeared preoperatively in the jaw biting movement in all patients. However, the amplitudes of the MRCP decreased significantly after than before the surgery ( $p < 0.05$ ). Our data indicated the dysfunction of the motor preparation process for jaw movements in the patient after the surgery, suggesting impairment of feed-forward system in the maxillofacial area.

**Keywords:** oral cancer, mandibulectomy, movement-related cortical potential, jaw movement, feed-forward system

## 1. Introduction

According to the World Health Organization, there are an estimated 657,000 new cases of oral cavity and pharyngeal cancers each year, and more than 330,000 death [1]. In high-risk countries such as Sri Lanka, India, Pakistan and Bangladesh, oral cancer is the most common cancer in men, and may contribute up to 25% of all new cases of cancer [2].

Oral cancers can occur on the lip or in the oral cavity, nasopharynx, and pharynx. It belongs to a larger group of cancers called head and neck cancers. Usually, oral cancer is first treated with surgery. In most cases, surgery is followed by radiation therapy and chemotherapy [3–5].

During the jaw bone excision in oral cancer surgery, we commonly find that the adjacent masticatory muscle, tendon tissue, and peripheral nerves are known to be included in the disease field. However, oral cancer patients who underwent resection surgery can suffer from eating and swallowing dysfunctions, owing to the masticatory muscle's excision, even when bone grafts obtain a morphological recovery [6].

In the postoperative period, most patients complain of immobility at the onset of jaw movement.

We predict that one cause is a disorder associated with the preparatory stage of the onset of voluntary jaw movement in the patients, leading to difficulty masticating and swallowing.

Jaw motor dysfunctions may be related either to the mandibular bone and teeth' defects or some brain functions' modulation after surgery.

Movement-related cortical potential (MRCP) is a slow negative potential in an electroencephalographic recording that occurs about 2 s before voluntary body movement production in humans [7].

In general, MRCP consists of two main components: Bereitschaftspotential (BP) and negative slope. From extensive studies, the current model is that BP starts first in the SMA, including the pre-SMA, and then shortly after that in the lateral premotor cortices bilaterally [8, 9]. About 400 msec before the movement onset, NS' starts in M1 and the premotor cortex mainly. MRCPs are also generated from the cerebellum as subcortical structures [10].

This potential is well known to reflect the cortical processes involved in movement planning and movement preparation preceding voluntary limb and maxillofacial movements [11–16].

In this study, we observed changes in MRCP waveform components associated with jaw-biting movements in oral cancer patients before and after surgical excision of their lesions. The purpose of this study was to investigate whether brain activities, as measured by MRCP recordings, are affected by the loss of neurological tissue in patients with oral cancer after the surgery.

In this chapter, thus, we discuss the clinical importance of application of MRCP recording in the field of maxillofacial surgery.

## **2. Material and methods**

### **2.1 Research design**

We performed two experiments in this study, described below.

**Experiment 1:** The MRCP waveforms for jaw movement were compared with those for hand movement in healthy subjects, which served as the control, to confirm MRCP components' characteristics (BP and NS') preceding onset of jaw muscle activities.

**Experiment 2:** The MRCP waveforms for jaw movement were compared between the preoperative and postoperative periods in the oral cancer patients to confirm MRCP components' changing (BP and NS') preceding onset of jaw muscle activities.

### **2.2 Informed consent**

We obtained informed consent was obtained from all participants after explaining the procedure in detail. The Ethical Committee approved the protocol of Nihon University School of Dentistry.

## 2.3 Experiment 1

### 2.3.1 Subjects

Eight unaffected subjects, four males and four females were enrolled in this experiment. Each had a complete set of natural maxillary teeth, instead of mandibular teeth. The average age was between 25 and 32 years.

### 2.3.2 Motor tasks

#### 2.3.2.1 Jaw-biting task

The subjects were instructed to bite softly on a 3-cm-thick plastic block between their upper and lower molars on their habitual side (left or right) at their own pace.

#### 2.3.2.2 Wrist dorsiflexion task (control movement task)

The subjects were instructed to put their hands on the chair's arms and dorsiflex their right wrist.

The above movement was carried out 50 times rapidly, and three trials were carried out with a break between them. The MRCP waveform data obtained from both groups for the above movement tasks were compared with those obtained for the right wrist dorsiflexion movement task as the control task.

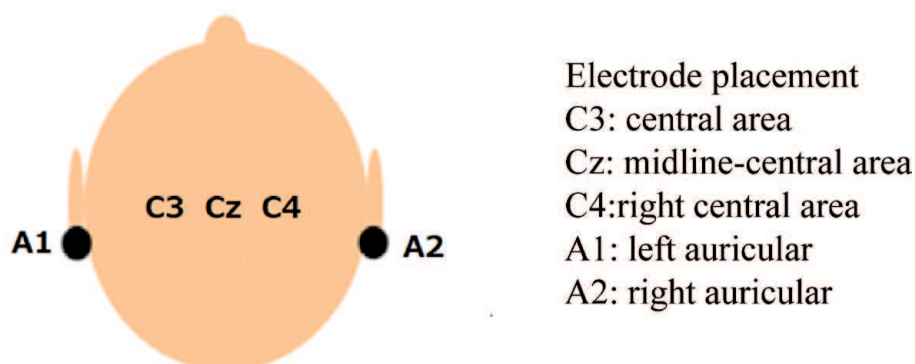
The subjects sat in an armchair with the FH plane nearly parallel to the floor in a relaxed manner. They were instructed not to move their jaw and tongue before doing each movement.

The subjects performed the movements 30–50 times rapidly and carried out the following two tasks with a break between them. The subjects were instructed to gaze at a mark positioned 1.5 m ahead at eye level lightly. The subjects were instructed not to blink for 6 s before beginning the specified movement and to relax, and then to perform the following movement tasks.

### 2.3.3 Recording conditions

#### 2.3.3.1 Electroencephalographic (EEG) recording

For electroencephalographic recording, Ag/AgCl electrodes were set at three sites, C3, Cz, and C4, stipulated under the international 10–20 system (**Figure 1**). The right and left earlobes (A1 and A2) were selected as the reference electrodes.



**Figure 1.**  
*Electroencephalographic recoding areas.*

Electroencephalography was performed using a monopolar lead with a time constant of 5.0 s, a 100 Hz high-frequency filter, and electric resistance of 5 k $\Omega$  or less.

### *2.3.3.2 Electrooculograms (EOG) recording*

Electrooculograms were recorded from electrodes above and below the right eye, to enable us to monitor for eye movement and blink artifacts.

### *2.3.3.3 Electromyogram (EMG) recording*

Surface electromyograms that served as a trigger for brain wave averaging were recorded from agonists shown below:

Jaw-biting task: Superficial part of the right masseter muscle.

Wrist movement task: Short radial extensor muscle of the right wrist (control movement task).

Surface electromyograms were recorded from each muscle group using a bipolar lead. The ocular movement was recorded during all the movement tasks, and electroencephalographic data contaminated with ocular movement artifacts were excluded from the analysis.

### *2.3.4 Data analysis conditions*

Signals obtained from electroencephalography, ocular movement, and muscle activity were amplified with an evoked potential measuring system (Neuropak-MEB-2200, Nihon Kohden Corporation). Electroencephalographic data without artifacts taken 50 times with the point of muscle discharge of the suprahyoid muscle group exceeding 2  $\mu$ V chosen as the threshold for the trigger were averaged.

## **2.4 Experiment 2**

### *2.4.1 Patients*

Seven oral cancer patients in whom the large area of the mandibular bone was excised during tumor resection were enrolled in this study (**Table 1**).

The patients ranged in age from 17 to 70 at the time of surgery. Additionally, they had upper and lower molars on the non-operative side (unaffected side). Their operation procedures were either segmental mandibulectomy or hemi-mandibulectomy (**Figure 2**).

### *2.4.2 Motor task*

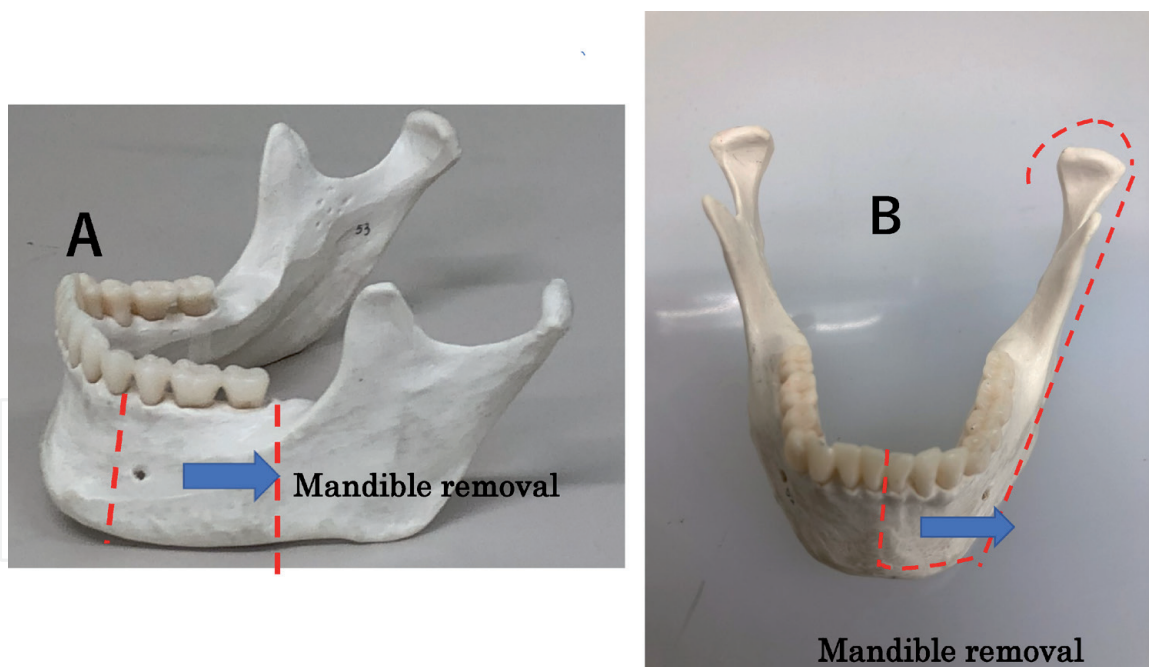
The patients were instructed to carry out the jaw-biting task on the unaffected side. They were instructed to bite softly on a 3-cm-thick plastic block between the upper and lower molars on the unaffected side at their own pace before undergoing tumor resection. The patients carried out the same specified movement postoperatively. One of the patients was instructed to perform the right wrist dorsiflexion movement postoperatively.

### *2.4.3 Recording conditions*

Experiment 2 was carried out according to the recording conditions of Experiment 1. Electroencephalography was done on five patients, according to the

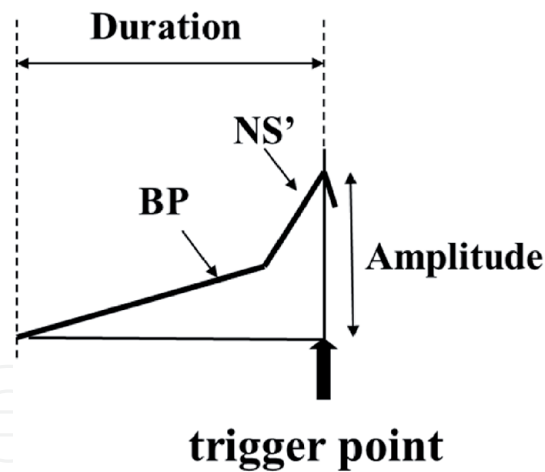
Case	Age	Diagnosis	Surgical procedure	Recorded month of MRCP before surgery	Recorded month of MRCP after operation
1	36Y	Fibrosarcoma	Left hemi-mandiblectomy	1 month within	12 month
2	60Y	Squamous cell carcinoma	Right segmental mandiblectomy		
3	63Y	Squamous cell carcinoma	Right segmental mandiblectomy		
4	70Y	Squamous cell carcinoma	Left segmental mandiblectomy		
5	17Y	Ameloblastoma	Left segmental mandiblectomy		
6	18Y	Ameloblastoma	Left segmental mandiblectomy		
7	70Y	Ameloblastoma	Left segmental mandiblectomy		

**Table 1.**  
 The list of patients participated in the research.



**Figure 2.**  
 Surgical areas of mandibulectomy in the patients. (A) Segmental mandibulectomy is a surgical procedure in which the mandible is partially resected continuously from the alveolus to the inferior border of the mandible, resulting in the disruption of its continuity. (B) Hemi-mandibulectomy is a surgical procedure involving resection of the hemi-mandible including its condyle. Between 1 to 3 years after the surgery, the mandibular bone was reconstructed with bone grafts from the ilium in these patients. The patients who participated in this study also complained of difficulty in jaw movement and mastication after surgery.

international 10–20 method, by placing sensors over the vertex (CZ). For electromyography, recordings were made using bipolar leads placed over the left and right masseter muscles. Simultaneously, electrooculography was done to monitor a mixture of eye-blinking potential with the electroencephalogram.



**Figure 3.**

*MRCP components. Bereitschaftspotential (BP): BP is a gradually increasing, bilaterally widespread surface negativity with the maximum over the midline vertex region regardless of the site of movement onset. Negative slope (NS'): NS' is a much steeper slope starting about 400 ms before the movement onset, and is characterized by a more localized negativity over the central and vertex regions contralateral to the movement. Trigger point indicates the onset of EMG for EEG averaging.*

#### 2.4.4 Measurement parameters

The measurement parameters for each movement task were maximum amplitude and duration determined by setting the baseline and rise time of MRCP under the following conditions (**Figure 3**). The average potential of a segment between 4 and 3 s before the start of muscle discharge was calculated to set the baseline.

#### 2.4.5 MRCP duration, maximum MRCP amplitude

##### 2.4.5.1 Maximum MRCP amplitude

The difference in potential between peak MRCP amplitude before muscle discharge initiation and the baseline (NS' amplitude) was determined as the maximum MRCP amplitude.

##### 2.4.5.2 MRCP duration

The difference in time between the starting point of the rise in MRCP from the baseline and muscle discharge initiation was determined as the MRCP duration.

### 2.5 Statistical analysis

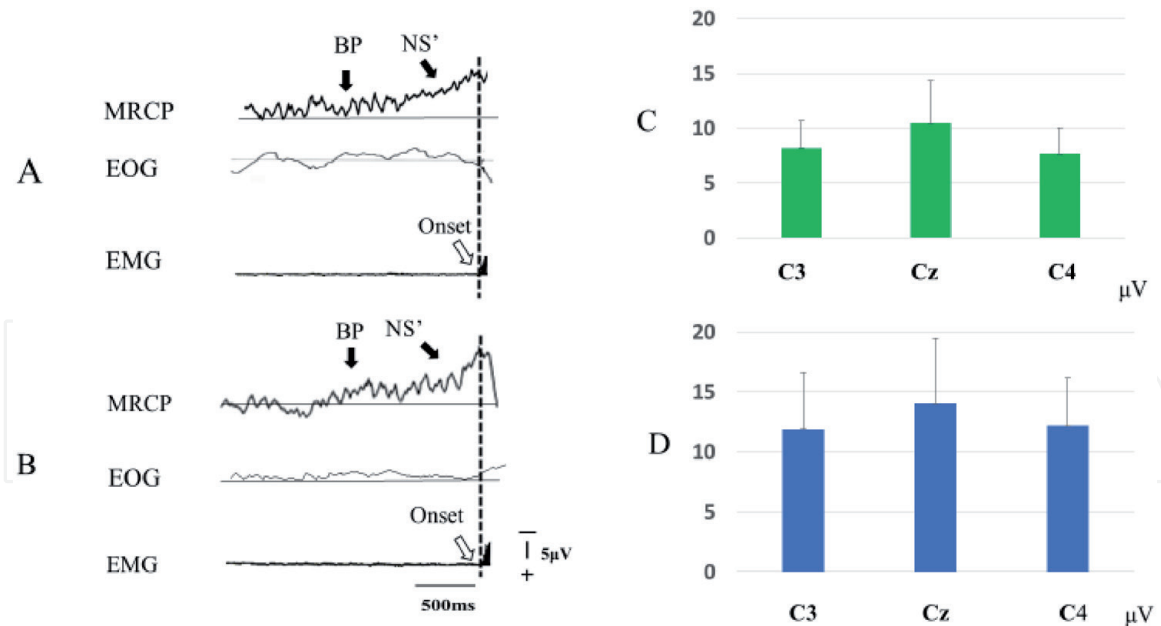
Differences of the amplitudes in the two different motor tasks were analyzed with a two-factor (recording site - task), repeated-measures analysis of variance (ANOVA). Statistical significance was considered when  $P < 0.05$ . A paired t-test was also used to compare the measured values (amplitude/duration) of two groups.

## 3. Results

### 3.1 Experiment 1

#### 3.1.1 MRCP waveform components in tasks

MRCP waveforms obtained in jaw-biting and wrist motor tasks were shown in Fi.4A and **Figure 4B**, respectively. Negative slow potential appeared bilaterally



**Figure 4.** Comparison of cortical potentials in jaw biting and wrist extension tasks in healthy subjects. (A) The grand averaged MRCPs for wrist extension task over all eight subjects. (B) The grand averaged MRCPs for jaw-biting task over all eight subjects. Both waveforms were obtained from vertex (Cz). The BP component and NS component can be confirmed in each waveform. "Onset" indicates onset of muscle discharge. Panel (C) and (D) indicate mean peak amplitudes values of the MRCPs for wrist extension and for jaw-biting tasks, respectively.

from electrodes at five sites on the scalp 1 or 2 s before muscle discharge initiation in each task. Each slow negative potential was divided into the BP component, which was of long duration centering on Cz, and the rapid NS' component appearing approximately 500 msec before muscle discharge initiation.

### 3.1.2 Maximum peak amplitudes (NS' amplitude) in each task

#### 3.1.2.1 Mean peak amplitudes of MRCPs

Maximum amplitudes in the wrist dorsiflexion movement task were  $8.18 \pm 2.46 \mu\text{V}$ ,  $10.48 \pm 3.84 \mu\text{V}$ ,  $7.64 \pm 2.41 \mu\text{V}$ , at C3, Cz, and C4, respectively (Figure 4C). On the other hand, the MRCP amplitudes in the jaw-biting task were  $12.80 \pm 5.22 \mu\text{V}$ ,  $15.09 \pm 5.98 \mu\text{V}$ ,  $12.91 \pm 4.32 \mu\text{V}$  at C3, Cz, and C4, respectively (Figure 4D).

In a two-way analysis of variance with each task and each recording site as two factors, a significant difference in MRCP amplitude was observed when the task was considered as the main effect [ $F(1,42) = 11.8$ ,  $p < 0.01$ ]. No significant difference was also observed between the recording sites [ $F(2,42) = 1.78$ ,  $p > 0.05$ ]. No interaction was observed [ $F(2,42) = 0.07$ ,  $p > 0.05$ ]. These results indicate that MRCP amplitude varied with the task. The MRCP amplitude was significantly higher in the jaw-biting task than in the wrist dorsiflexion movement task ( $p < 0.01$ ). The MRCP recorded at Cz tended to be a large amplitude in both tasks, and was clear to distinguish two main components (BP and NS').

#### 3.1.3 MRCP duration in tasks

The MRCP durations were  $1,704.37 \pm 743.03$  ms in the wrist dorsiflexion movement task,  $2,180.00 \pm 196.81$  ms in the jaw-biting task. No significant difference was observed in MRCP duration between the movement tasks (paired test,  $p > 0.05$ ).



## 3.2 Experiment 2

### 3.2.1 Changes in MRCP waveform components in oral cancer patients

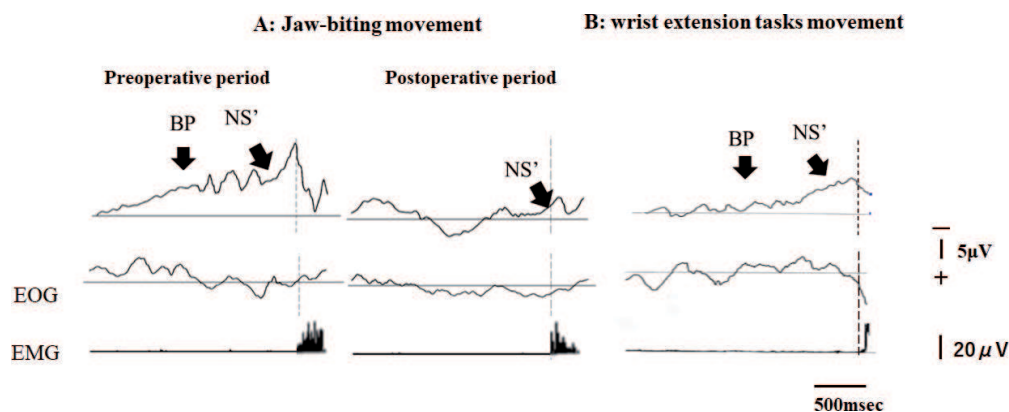
Regarding MRCP waveforms associated with the preoperative jaw-biting, negative potential appeared bilaterally 1.5 s before muscle discharge initiation. The precipitous negative potential appeared 500 msec before muscle discharge initiation in all five patients. Preoperative negative potential waveforms consisted of BP and NS' components.

However, BP and NS' appearance became unclear in four of all seven patients after the surgery. In only one case, BP and NS' components were observed at both pre and postoperative periods.

**Figure 5** shows a typical case with reduced waveform components. In this case, the BP component was confirmed 1.5 seconds before the onset of masseter muscle discharge, as in healthy adults, before the surgery (**Figure 5A**).

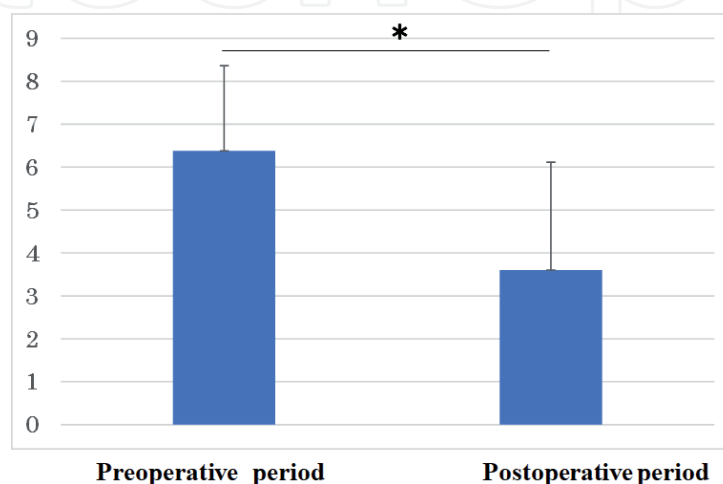
However, after surgery, the amplitudes of MRCPs were decreased so much that the BP component could not be confirmed (**Figure 5B**). The NS' component was barely confirmed in the waveforms. In addition, the BP and NS components could be observed in the MRCP waveforms when this patient was requested to perform wrist movement during the postoperative period (**Figure 5C**).

The MRCP amplitudes in the jaw-biting task at pre- and postoperative periods were  $6.80 \pm 1.442 \mu\text{V}$  and  $4.02 \pm 2.33 \mu\text{V}$ , respectively (**Figure 6**). The amplitudes



**Figure 5.**

A typical change in pre and postoperative MRCP waveforms in same patient. (A) Comparison between the MRCPs for jaw-biting in a patient at preoperative and postoperative periods. (B) The MRCPs for wrist extension in same patient at postoperative period.



**Figure 6.**

Comparison of mean peak amplitude values before and after surgery. Paired *t* test: \* indicates significant difference at  $p < 0.05$ .

of the MRCP decreased significantly in the patients after than before the surgery ( $p < 0.05$ ). Thus, it was clear that the cerebral potentials associated with jaw movement were affected in the patient after surgery.

## 4. Discussion

### 4.1 Experiment 1

Recently, the epidemiological data suggest a positive correlation between masticatory functions and cognitive functions in the elderly people [17, 18]. Thus, we feel it is essential to study the relationship between masticatory muscle movement and brain function in humans from many points of view.

That local cerebral function is related to various movements' execution has been documented recently using cerebral function imaging methods such as fMRI and positron-emission tomography [19–21]. These techniques have excellent spatial resolution and various applications, such as function localization in the cerebral cortex. These techniques can be used in jaw movement studies.

Because these methods' temporal resolutions, which are on the order of tens to hundred milliseconds, are low, it is impossible to record brain activity on a time series plot: before, at the start of, and during a movement. The methods provide information on brain activity during a movement but cannot clarify brain activity during a movement's preparation.

On the other hand, an MRCP is recorded from the scalp before voluntary movements. Hence, an index reflecting changes in brain potential, but MRCP reflects the supplementary motor area and sensorimotor cortex's activities appear before the start of voluntary movements. Its temporal resolution is on the order of 1/1000 seconds, allowing very high-resolution examination and enabling continuous monitoring of central nerve activity accompanying the movement.

Shibasaki (1980) divided MRCP recorded from the scalp into two components: the BP and the NS' components [8]. The BP component initiates approximately 1,000 to 2,000 ms before starting a movement with a mild gradient showing maximum amplitude. In contrast, the NS' component initiates at approximately 500 ms after the start of a movement with a steep gradient showing maximum amplitude on the side contralateral to the movement side. The NS' measurement is used clinically to diagnose movement disorder of central origin.

Therefore, we conducted this study by focusing on changes in the BP and NS' components of MRCP waveforms associated with jaw movements.

In this study, the BP component appeared bilaterally from the scalp 1 to 1.5 s ahead of muscle discharge initiation in the jaw-biting task, similarly to the wrist dorsiflexion movement task. However, the NS' amplitude tended to be higher in the jaw-biting task than in the wrist dorsiflexion movement task. Our data demonstrated the difference between jaw and limb movements in the peak amplitudes of MRCPs.

MRCP amplitude has been shown to have a more significant increase, particularly in the movement task coordinating the bilateral upper limbs than in the unilateral upper-limb movement task [21, 22]. This phenomenon is considered attributable to increased activity in the supplementary motor area. The difference in MRCP amplitude between the jaw movement and wrist movement tasks was considered to indicate the brain's more extensive activation in the jaw movement's preparatory process involving the bilateral muscles' coordination than for the unilateral wrist dorsiflexion movement.

Our results indicate that BP and NS' components can be considered a useful index for the jaw-biting movement's motor preparation, similar to limb

movements. In later experiments, we will investigate the relationship between these components and the brain's active sites for jaw-biting movement in patients with oral cancer.

## **4.2 Experiment 2**

In Experiment 1, our data indicated that BP and NS' were a useful index of MRCPs, suggesting the more complicated preparatory process for the jaw movement than for the limb movement. In Experiment 2, the influence of excision of the unilateral masticatory muscle in oral tumor resection on the BP and NS' components of the MRCPs for the jaw-biting was examined in the patients.

Chewing aims to crush, triturate, and mix food with saliva so that that food can be transported by deglutition down the digestive canal [23]. The masticatory muscle is an agonist of an actual jaw movement and a sensory organ involved in sensing the mandible position through stretch receptors [24].

Therefore, in this experiment, we predicted that a loss of oral sensory receptors such as muscle spindles due to oral cancer removal might affect brain function.

In this study, MRCP consisting of the BP and NS' components appeared initial onset of master muscle activities in all five patients at the preoperative period.

However, these MRCPs decreased in four of five subjects during the postoperative period in the patients. In particular, our results indicated the BP components more remarkably decreased.

The cerebellum receives signals from receptors on various parts of the body and the cerebrum [25, 26].

The cerebellum transmits movement-controlling signals based on the above signals to the medulla's vestibular nuclei oblongata and cerebellar nuclei. Various sensory input types are distributed fragmentarily in intracortical adjacent areas, and Purkinje cells, the only projection neurons, potentially integrate various sensory information at a single-cell level. It is considered that the plasticity of parallel fiber synapses determined by the interaction of two types of excitatory input received by Purkinje cells, climbing fiber inputs and parallel fiber inputs, plays an important role in sensory information processing and motor learning.

It is well known that the cerebellum drives MRCP generation. Ikeda et al. [27] have determined the cortical source of MRCPs by directly recording cortical potentials through chronically implanted subdural electrodes in patients with epilepsy as part of the presurgical evaluation [10]. Sasaki et al. [28] reported that in monkeys trained to perform spontaneous hand movements, MRCPs recorded before the movement's initiation disappear following cerebellum resection [28]. Ikeda et al. [27] reported that in cerebellar infarction patients performing an upper-limb movement task, no MRCP was recorded [27].

Naito et al. demonstrated that sensorimotor inputs from muscle spindles and tendon receptors through afferent nerves in humans are transmitted to the primary sensorimotor cortices, supplementary motor area (SMA) and cingulate motor area (CMA), by using emission tomography (PET) [29].

In this study, therefore, our data may suggest that the marked postoperative reduction in MRCP amplitude in the oral cancer patients was attributable to decreased activities of the cerebellum before the initiation of voluntary movements, leading to dysfunction of the feed-forward system of jaw movements.

As a further study, we will investigate the effect of postoperative rehabilitation for cancer patients using not only MRCP but fMRI analysis, in order to establish the effective dysphagia treatment.

## 5. Conclusion

The above findings support our hypothesis that the removal procedure of the oral cancer including masticatory muscles (muscle spindle, tendon receptor) may affect this information processing of brain for smooth jaw movement. We concluded that it is necessary to diagnose brain functions for the oral cancer patients before and after the surgery for postoperative rehabilitation of a jaw motor disorder.

### Conflict of interest

The authors declare no conflict of interest.

### Thanks

Authors would like to thank Prof. Mitsuhiko Matsumoto for his warm research support sincerely.

### Author details

Ichiro Nakajima<sup>1\*</sup>, Mitsuyo Shinohara<sup>2</sup> and Hiroiku Ohba<sup>3</sup>

1 Department of Community Dentistry, Nihon University School of Dentistry, Tokyo, Japan

2 Department of Oral and Maxillofacial Surgery, Faculty of Medicine, Juntendo University, Tokyo, Japan

3 Department of Dental and Oral Surgery, Tokyo Saiseikai Central Hospital, Tokyo, Japan

\*Address all correspondence to: [nakajima.ichirou@nihon-u.ac.jp](mailto:nakajima.ichirou@nihon-u.ac.jp)

### IntechOpen

© 2021 The Author(s). Licensee IntechOpen. This chapter is distributed under the terms of the Creative Commons Attribution License (<http://creativecommons.org/licenses/by/3.0>), which permits unrestricted use, distribution, and reproduction in any medium, provided the original work is properly cited. 

## References

- [1] WHO. Oral cancer. [Internet]. 2020. Available from <https://www.who.int/cancer/prevention/diagnosis-screening/oral-cancer/en/> [Accessed 2020-11-22]
- [2] Warnakulasuriya S : Global epidemiology of oral and oropharyngeal cancer. *Oral Oncology*. 2009;45(4-5):309-16. DOI:10.1016/j.oraloncology.2008.06.002
- [3] Montero H P, Patel G S: Cancer of the oral cavity. *Surgical Oncology Clinics of North America*. 2015; 24(3): 491-508. DOI: 10.1016/j.soc.2015.03.006.
- [4] Moroi H. H., Okimoto, K. , Terada, Y. :The effect of an oral prosthesis on the quality of life for head and neck cancer patients. *Journal of Oral Rehabilitation*. 1999; 26:265-273. DOI. org/10.1046/j.1365-2842.1999.00379.x
- [5] Specht L.: Oral complications in the head and neck radiation patient. *Support Care Cancer*. 2002; 10(1):36-39. DOI: 10.1007/s005200100283
- [6] Namaki S., Matsumoto M., Ohba H., Tanaka H., Koshikawa N. Shinohara M.:Masticatory efficiency before and after surgery in oral cancer patients: comparative study of glossectomy, marginal mandibulectomy and segmental mandibulectomy. *Journal of Oral Science*. 2004; 46 (2):113-117. DOI:10.2334 / josnurd.46.113
- [7] Kornhuber H. H., Deecke L.: Brain potential changes in voluntary and passive movements in humans: readiness potential and reafferent potentials. *Pflügers Archiv-European Journal of Physiology*. 2016; 468 (7): 1115-24. DOI:10.1007/s00424-016-1852-3
- [8] Shibasaki H., Barret G., Halliday E. : Components of the movement-related cortical potential and their scalp topography. *Electroencephalography Clinical Neurophysiology*. 2016; 49 (3-4): 213-226. DOI: org/10.1016/0013-4694(80)90216-3
- [9] Shibasaki H. :Human brain mapping: Hemodynamic response and electrophysiology. *Clinical Neurophysiology*. 2008; 119 (4): 731-743. DOI: 10.1016/j.clinph.2007.10.026
- [10] Ikeda A., Luders H.O., Burgess R. C., Shibasaki H. : Movement-related potentials recorded from supplementary motor area and primary motor area. Role of supplementary motor area in voluntary movements. *Brain*. 1992; 115 (4):1017-1043. DOI: 10.1093/brain/115.4.1017
- [11] Nakajima I., Tanaka Y., Uchida A., Sakai T., Akasaka M., Mori A., Sumino R.: Cortical potentials associated with voluntary biting movement in humans. *Neuroscience Research*. 1991; 10 (4): 285-289. DOI: 10.1016/0168-0102(91)90085-d
- [12] Nakajima I., Miyauchi M., Minowa K., Akasaka M., Uchida A. : Contingent negative variations associated with jaw opening in humans. *Somatosensory and motor research*. 1994; 11 (2): 149-152. DOI: org/10.3109/08990229409028867
- [13] Huckabee, M. L., Deecke L., Cannito M.P., Gould H. J. , Mayr, W. : Cortical control mechanisms in volitional swallowing: the Bereitschaftspotential. *Brain Topography*. 2003; 16 (1) :3-17. DOI: 10.1023/a:1025671914949.
- [14] Nonaka T., Yoshida M., Yamaguchi T., Uchida, A., Ohba, H., Oka S., Nakajima I. :Contingent negative variations associated with command swallowing in humans. *Clinical Neurophysiology*. 2009; 120 (10) :1845-1851. DOI: 10.1016/j.clinph.2009.06.029

- [15] Satow T., Ikeda A., Yamamoto J., Begum T., Thuy D. H. D., Matsushashi M., Mima T.; Nagamine T., Baba K., Mihara T., Inoue Y., Miyamoto S., Hashimoto N., Shibasaki H. :Role of primary sensorimotor cortex and supplementary motor area in volitional swallowing: a movement-related cortical potential study. *American journal of physiology. Gastrointestinal and Liver Physiology.* 2004; 287 (2) : 459-470. DOI: 10.1152/ajpgi.00323.2003
- [16] Yoshida K., Kaji R., Kohara N., Murase N., Ikeda A., Shibasaki H., Iizuka T. :Movement-related cortical potentials before jaw excursions in oromandibular dystonia. *Movement Disorders.* 2003; 18(1):94-100. DOI: 10.1002/mds.10296
- [17] Miura H., Yamasaki K., Kariyasu M., Miura K., Sumi Y. :Relationship between cognitive function and mastication in elderly females. *Journal of Oral Rehabilitation.* 2003; 30(8):808-811. DOI: 10.1046/j.1365-2842.2003.01124.x
- [18] Takeshita H., Ikebe K., Gondo Y., Inagaki H., Masui Y., Inomata C., Mihara Y., Uota M., Matsuda K., Kamide K., Takahashi R., Arai Y. Maeda Y. :Association of Occlusal Force with Cognition in Independent Older Japanese People. *JDR Clinical and Translational Research.* 2016; 1(1):69-76. DOI: 10.1177/2380084416636604.
- [19] Deiber P.M., Passingham E.R., Colebatch G.J., Friston J.K., Nixon D.P., R S Frackowiak S.R.: Cortical areas and the selection of movement: a study with positron emission tomography. *Experimental Brain Research.* 1991;84(2):393-402. DOI: 10.1007/BF00231461.
- [20] Nahab B.F., Hallet M.: Current Role of fMRI in diagnosis of movement disorders. *Neuroimaging Clinics of North America.* 2010; 20(1): 103-110. DOI:10.1016/j.nic.2009.08.001.
- [21] Onozuka M., Fujita M., Watanabe K., Hirano Y., Niwa, M., Nishiyama K., Saito S. : Mapping brain region activity during chewing: a functional magnetic resonance imaging study. *Journal of Dental Research.* 2002; 81(11): 743-746. DOI. org/10.1177/0810743
- [22] Kristeva R., Cheyne D., W.Lang W., Lindinger G., Deecke L.: Movement-related potentials accompanying unilateral and bilateral finger movements with different inertial loads. *Electroencephalography and Clinical Neurophysiology.*1990; 75(5): 410-418. DOI.org/10.1016/0013-4694(90)90086-Y
- [23] Lund P.J. : Mastication and its Control by the Brain Stem. *Critical Reviews in Oral Biology and Medicine.* 1991; 2(1):33-64. DOI.org/10.1177/10454411910020010401
- [24] Morimoto T., Hamada T., Kawamura Y. : Alteration in directional specificity of interdental dimension discrimination with the degree of mouth opening. *Journal of Oral Rehabilitation.*1983; 10(4): 335-342. DOI .org/10.1111/j.1365-2842.1983.tb00128.x
- [25] Marr D.:A theory of cerebellar cortex. *Journal of Physiology.* 202(2): 437-470.1. DOI: 10.1113/jphysiol.1969.sp008820
- [26] Yamazaki T., Lennon W.: Revisiting a theory of cerebellar cortex. *Neuroscience Research.* 2019; 148: 1-8. DOI.org/10.1016/j.neures.2019.03.001
- [27] Ikeda A., Shibasaki H., Nagamine T., Terada K., Kaji R., Fukuyama H., Kimura J.: Dissociation between contingent negative variation and Bereitschaftspotential in a patient with cerebellar efferent lesion. *Electroencephalography Clinical Neurophysiology.* 1994; 90 (5):359-364. DOI.org/10.1016/0013-4694(94)90051-5

[28] Sasaki K., Gemba H. , Hashimoto S.:  
Premovement slow cortical potentials  
on selfpaced hand movements and  
thalamocortical and corticocortical  
responses in the monkey. *Experimental  
Neurology*. 1981; 72(1): 41-50. DOI.  
org/10.1016/0014-4886(81)90125-4

[29] Naito E., EhrssonH.H.: Kinesthetic  
illusion of wrist movement  
activates motor-related areas. 2002;  
*Neuroreport* 12(17):3805-9. DOI:  
10.1097/00001756-200112040-00041

IntechOpen