

We are IntechOpen, the world's leading publisher of Open Access books Built by scientists, for scientists

5,100

Open access books available

126,000

International authors and editors

145M

Downloads

Our authors are among the

154

Countries delivered to

TOP 1%

most cited scientists

12.2%

Contributors from top 500 universities



WEB OF SCIENCE™

Selection of our books indexed in the Book Citation Index
in Web of Science™ Core Collection (BKCI)

Interested in publishing with us?
Contact book.department@intechopen.com

Numbers displayed above are based on latest data collected.
For more information visit www.intechopen.com



Standard Open Right Hepatectomy

Luis Cesar Bredt

Abstract

The evolution of hepatic resection from an imprecise removal of portions of the liver often associated with a mortality rate of up to 20% to a routine and controlled anatomic procedure with operative risk less than 5%, represents a major advance in modern surgery. This accomplishment has been made thanks to better understanding of the liver vascular and biliary anatomy, recognition of the functional reserve of the liver and the potential for regeneration, advances in surgical technique as well as anesthesia and perioperative care. These factors, along with the improvement of prolonged survival following hepatic resection for colorectal metastases, hepatocellular and cholangiocarcinoma have led to an expansion of liver surgery. In this chapter, we will give the evolution of the technique used for the standard open right hepatectomy. In addition, we will describe on detail our technique employed for right hepatectomy focusing on indications, preoperative preparation and specific technical aspects.

Keywords: hepatectomy, open right, liver resection

1. Introduction

The evolution of hepatic resection from an imprecise removal of portions of the liver often associated with a mortality rate of up to 20% to a routine and controlled anatomic procedure with operative risk less than 5%, represents a major advance in modern surgery. This accomplishment has been made thanks to better understanding of the liver vascular and biliary anatomy, recognition of the functional reserve of the liver and the potential for regeneration, advances in surgical technique as well as anesthesia and perioperative care. These factors, along with the improvement of prolonged survival following hepatic resection for colorectal metastases, hepatocellular and cholangiocarcinoma have led to an expansion of liver surgery.

In this chapter, we will give the evolution of the technique used for the standard open right hepatectomy. In addition, we will describe on detail our technique employed for right hepatectomy focusing on:

- Indications
- Preoperative preparation
- Specific technical aspects

2. Surgical anatomy

It was the work from our center conducted by Bismuth [1] which introduced to the English speaking world, the segmental approach to liver surgery, which in turn was based on the anatomical description of the liver by Couinaud [2]. The two liver lobes are divided into four segments with defined blood inflow and outflow as well as biliary drainage. The fibrous Glissonian sheath surrounds the branches of the segmental structures, whereas the hepatic veins lie between the pairs of the liver segments [3, 4].

For further details on liver anatomy of interest for surgeons performing liver surgery the reader is referred to the chapter on liver anatomy on this book.

3. Indications

Currently, hepatic and right liver resections may be required in a wide variety of conditions, including pathological processes which are limited to the respective right side of the liver. Partial right hepatectomy in the treatment of primary (benign or malignant) liver tumors, biliary tract tumors and secondary malignant tumors are the most common indications. Partial right hepatic resections may also be necessary in the management of complex cystic diseases, benign biliary stenoses, some hepatic trauma, and more recently in liver transplantation with live donors. Total hepatectomies are reserved for situations of liver uptake in cadaveric donors and hepatic replacement in the hepatic transplant recipient.

4. Different techniques of hepatectomy

The modern era of anatomic resection dates as far back as 1950s, when Lortat-Jacob [5] reported the technique of right hepatectomy by performing an initial dissection, ligation and division of the right hepatic artery, portal vein and right hepatic vein, followed by parenchyma transection with intrahepatic isolation of the vessels. Although, this technique is advantageous as it reduces the bleeding during the parenchyma transection in addition to displaying the demarcation line between healthy and ischemic parenchyma, it is associated with serious complications such as major bleeding and air embolism (if the right hepatic vein is injured during the dissection of its non-parenchymal route). For this reason, Lortat-Jacobs' original technique [5], was later modified by preceding the portal and hepatic vein dissection by supra- and infra-hepatic caval control. This technique has, however, two drawbacks: firstly, the already mentioned risk of trauma to the hepatic vein, and secondly, the possibility of devascularization of parts of remaining liver in cases of anatomical variations. In addition, during a right hepatectomy, the extrahepatic ligation of the right pedicle is associated with a risk of ligation of the biliary convergence situated anterior to the origin of the right portal branch.

In contrast, these complications are less frequent with the technique described by Tung and Quang [6] which entails an initial parenchymal dissection with intrahepatic control of the vessels.

Although, other techniques have been described, generally most liver surgeons use a combination of these techniques often applied in accordance to case specifics.

The technique we use, first described by Bismuth [7], consists of an initial hilar dissection to control the arterial and portal components without touching the biliary duct (**Figure 1**).



Figure 1.
Control of the arterial and portal components without touching the biliary duct.

The control of right hepatic vein can also be done at this stage, however, this is not essential and should be avoided if difficulties are anticipated. This technique has the advantage of preceding the parenchymal section by the selective control of the right arteriportal and right hepatic components (as in the technique described by Lortat-Jacob) [5] and tie the vessels in the hepatic parenchyma (as in the technique described by Ton That Tung) [6].

5. Preoperative evaluation

Before any decision to perform a major surgical procedure could be made there is a need for a thorough pre-operative evaluation of the patients focused on the general physical status as related to the requirements of the planned operative procedure. All factors needed for a proper evaluation of the risk and possible gain from the patient's point of view should be taken into account. In this aspect liver resection does not differ from any other major surgical resection. However, there are factors that are specific to liver resection: the risk for massive intraoperative hemorrhage and postoperative functional hepatic insufficiency. The preoperative evaluation of the functional capacity of the remaining liver is difficult and there are no strict and objective rules and specific knowledge and experience is required. In general, to determine the indications for surgery and the possible course of the prognosis following the surgical treatment, evaluation of liver cell integrity, excretory, and metabolic performance as well as the expected temporary ischemia and the effects of the anesthesia are all of importance [8]. Risk factors should be taken into account particularly fibrosis/cirrhosis or small future remnant volume and the question whether resection safety can be increased by portal vein embolization (PVE) should be examined preoperatively [9].

Also, the preoperative evaluation should aim at clarifying the following questions:

- The extent of the pathological lesions.
- Detailed evaluation of the pathological lesions within the hepatic parenchyma and the relationship with important structures such as vascular and biliary components.

In this regard, a three phase spiral computerized tomography (CT) and a magnetic resonance (MR) can be of a significant help. However, further information

and accuracy with great clinical benefit during the preoperative evaluation is obtained from 3D CT or MR reconstruction, vascular reconstruction as well liver volume measurements.

6. Operative procedure

6.1 Installation

The patient is placed on supine position. The right arm is placed along the body wrapped in a drape whose ends pass under the back of the patient. The left arm is stretched at 90°. For anesthesiological monitoring, central venous lines and an arterial pressure sensor are placed. A gastric tube may be used to decompress the stomach.

The surgical field usually extends from the lower half of the chest to the pubic symphysis. The patient's head is turned to the right and fixed on this position by Elastoplast® tape in order to expose the left jugular triangle. The site of the abdominal incision is marked and the entire operative field is then covered. For large tumors requiring a thoracoabdominal incision or median sternotomy, the entire chest is included in the surgical field.

6.2 Surgical incision

An optimal surgical approach is a prerequisite for safe, controlled liver resection. For right hepatic resection, we use almost exclusively an abdominal approach. This involves a median incision with right transverse extension (**Figure 2**).

Depending on the case, the incision usually can be extended cranial over the xiphoid process. A bicostal incision may provide a very good exposure suitable for almost all types of standard hepatectomies.

Extension of the incision into the chest is exceptional, however, in extreme cases the incision can be extended further by a partial sternotomy, giving an excellent exposure of the suprahepatic vena cava. Similarly, a thoraco-phreno-laparotomy is used rarely for very large tumors of the right lobe or the upper right lobe preventing the mobilization and control of the suprahepatic vena cava.

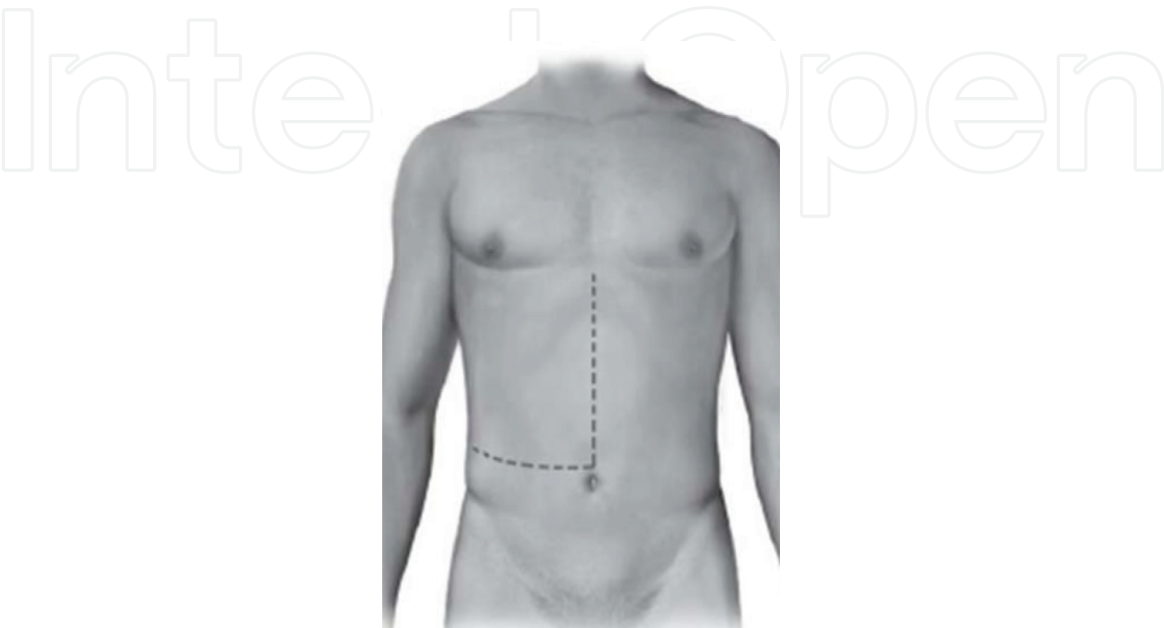


Figure 2.
Median incision with right transverse extension (modified Makuuchi incision).

6.3 Abdominal exploration

This step involves a complete exploration of the abdominal cavity paying special attention to the liver in order to identify possible undiagnosed lesions which could constitute a contraindication to liver resection. In general, it is possible to perform this step via a limited right subcostal incision. The first part of the exploration involves a manual palpation which is focused on the left liver, porta hepatis (in particular the lower posterior aspect) and the coeliac region. Division of the ligamentum teres and the falciform ligament along the anterior surface of the liver facilitates the exploration. The elevation of the ligamentum teres helps to expose the inferior surface of the liver and the area of the hilus as well as umbilical fissure. Performing this step (elevation of the ligamentum teres) helps to identify and better estimate lesions which can be potentially missed or underevaluated. Exploration should also include the inferior quadrants of the abdomen looking for adenopathy, peritoneal carcinomatosis or any lesion indicating colonic recurrence. Frozen section biopsies should be done for suspected lesions.

The second part of the exploration involves performing an ultrasound (US) examination of the liver. The US helps to identify previously undetected lesions and to clearly delineate anatomical landmarks in the relation to the tumor [10]. The intraoperative US is particularly beneficial for deep seated lesions <10 mm in diameter as identification of these lesions may influence the surgeon to change the strategy and/or tip the balance against a curative resection. In addition, US may identify anatomical variations that may make the resection more difficult, such as accessory hepatic veins or common origins of the portal pedicles [11]. Finally, ultrasound is an indispensable aid when the anatomy is altered by a previous hepatectomy. If the exploration (manual and by US) is negative, the incision is enlarged to start the mobilization of the liver.

6.4 Liver mobilization

Following the division of the ligamentum teres, the posterosuperior remaining part of the falciform ligament is incised and divided as far back as the suprahepatic IVC. The space between the right hepatic vein (RHV) and middle hepatic vein (MHV) is dissected 2 or 3 cm in the caudal direction. In a similar fashion, the perihepatic attachments (right and when required left coronary ligament) are divided. This begins from the right lateral side and continues to the inferior peritoneal reflection exposed by retracting the right lobe anterosuperiorly. During this stage it is important to stay in close contact to the liver surface so to avoid entering the retroperitoneum. Failure to do so may result on profuse bleeding from severed retroperitoneal veins, which at times can be very dilated, particularly in patients with portal hypertension. Similarly, after dividing the upper lamina of the coronary ligament, care should be taken not to enter the thickness of the diaphragm as it can cause bleeding which often requires a time consuming hemostasis. In addition, adhesions between liver and diaphragm when present should not be digitally dissected (especially with a cirrhotic liver) as this approach is associated with a real risk of liver decapsulation leading to massive bleeding.

Multiple short Spigelian veins between the IVC and posterior surface of the liver are ligated and divided as the liver is retracted anteriorly and laterally to the left. If an inferior right hepatic vein/s are present (>5 mm) it is crucial to ligate and divide them as they are a potential source of major bleeding. During this stage, one often encounters a band of ligamentous tissue extending from the liver to the right lateral aspect of the vena cava and in some patients this represents a small bridge of liver

parenchyma. Regardless the nature, this too requires ligation and division as most of the time this band contains one or two veins.

After the right liver is fully mobilized, the space between the RHV and the MHV in the anteromedian surface of the vena cava is carefully dissected using a right angle forceps through which a tape is passed around to control the root of the RHV. Having achieved this, laparotomy pads are placed behind the liver to enhance the exposure of the right lobe necessary for the parenchyma resection.

It is not unusual that during mobilization to find right lobe tumors attached to the diaphragm. The surgeon should either separate these attachments or in some cases resect a segment of the diaphragm which can be subsequently repaired. Tumor attachment/s to the diaphragm should not be considered as distal metastatic lesions and should not influence the surgeon to abandon the planned resection.

6.5 Hilar dissection

After cholecystectomy, the right lateral aspect of the hepatoduodenal ligament is incised longitudinally just posterior to the bile duct, followed by a hilar dissection to identify and achieve control of the right hepatic artery (RHA) and right portal vein (RPV). The right hepatic artery is identified during the cholecystectomy. Anomalies such as having a right hepatic artery originating from the superior mesenteric artery or posterior location in the hepatoduodenal ligament should always be kept in mind if injuries are to be prevented. Ideally, these possibilities should be excluded during the preoperative work-up by CT angiography imaging. The artery is traced to its left sufficiently to identify with certainty its junction with the proper hepatic artery after which the right branch is controlled.

The next step involves the exposure of the portal vein. Using gently a blunt right angle forceps, the trunk of portal vein is dissected anteriorly and posteriorly and a traction tape is passed around this vessel. Dissection is then continued into the hilum of the liver to expose the bifurcation of the portal vein, where the right branch is freed up and controlled by a vascular tape. During this step, one should be careful to avoid two possible complications. First, the left portal vein tends to pass directly away from the operator and care must be taken not to injure it. Second, the possibility of small tributaries from the right portal branch to the caudate lobe should always be kept in mind as failure to do so may lead to cumbersome bleeding from such very fine veins. Hilar dissection is completed by tracing the common bile duct into the hilum where the right and left branches are seen. Insertion of a small catheter through the cystic duct stump and up into the left and right ducts can be useful to identify these structures as a preparation step for eventual division (during the parenchyma transection).

An initial occlusion of RHA and RPV with bulldog clamps will reveal a demarcation line on the liver surface that corresponds to the transection plane, which is marked with electrocautery. The isolation and clamping of the right arterial and portal branches is advantageous as it allows selective clamping without inducing ischemia in the contralateral site of the liver [12–14].

One important point to remember is that at the end of this step the surgeon has two options. First, as described above to dissect and control the vascular components (right hepatic and portal branch) followed by parenchyma transection. Second, to dissect, ligate and divide the vascular components before commencing the parenchymal transection. The choice will depend on the case particulars and on the surgeons' preference.

6.6 Parenchymal transection

After selectively controlling the right lobe inflow and outflow, transection of the parenchyma is commenced along the marked line running from an anteroinferior to posterosuperior direction near the diaphragmatic hiatus of the IVC for early exposure of the middle hepatic vein. The transection is done using either a Kelly clamp or ultrasonic dissector with selective occlusion of the vascular inflow (RHA and RPV). While the ultrasonic dissector is highly effective for exposure of the periportal pedicles, care must be taken with this instrument when dissecting in close contact to the hepatic veins whose walls are extremely fragile. In addition, one should be always aware of the location of the tumor to achieve a negative histologic margin. When the resection is performed in a fibrous or cirrhotic liver, using a small Kelly clamp (kellyclasp) to carry out the transection may be preferable. As parenchymal division proceeds, pedicles including the larger branches originating from the hepatic veins are tied with silk 4.0. We do not use metal clips or absorbable material to achieve the hemostasis in transection surface of the remaining parenchyma. In our experience, the clips can easily be removed/dislodged during manipulations, by vigorous suction or when the liver becomes very congested or edematous leading to unnecessary bleeding and time delay to control it.

Care must be taken to preserve the middle hepatic vein by carefully ligating its branches to the anterosuperior and anteroinferior segments of the right lobe and by preserving the venous drainage of the medial segment of the left lobe. The parenchyma is divided in an anteroposterior direction until the anterior surface of the IVC is exposed. Before the specimen is removed it is necessary to divide the right portal pedicle and right hepatic vein. The right hepatic artery already controlled is double ligated with nonabsorbable suture (Cardionyl[®] 4.0), whereas the portal vein is sutured transversely with Cardionyl[®] 5.0 in order to prevent stricture of the remnant portal trunk. At this stage, the right biliary duct as the only remaining anatomical structure of the pedicle is in turn divided and closed with PDS 6.0. The right hepatic vein as the last structure holding the specimen, clearly exposed by a combined approach (extrahepatic dissection above the liver and laterally along the vena cava as well as medially by the parenchymal transection) is double clamped using DeBakey clamps and divided leaving sufficient length to perform a secure closure with Prolene[®] 4.0, or it may be divided using a vascular stapler. Alternatively, the right hepatic vein can be controlled and divided intrahepatically during the parenchyma transection. However, extrahepatic control reduces blood loss as the liver is divided and is very important maneuver for tumors close to the vena cava. Following the removal of the specimen, it is important to check for possible bile leaks by injecting methylene blue either via the cystic duct stump or the stump of the right bile duct before closing it. Bile leaks on the resection surface are easily visualized and selectively closed by using monofilament sutures. With the described technique for the parenchymal transection, the cut surface is usually dry, however, when required the hemostasis is achieved by gentle manual compression combined sometimes with application of biological fibrin glues.

Following resection, torsion of the mobilized left lobe may occur which can potentially lead to either kinking of the vessels in the hilum or the left hepatic vein. By refixing the falciform ligament this complication can be prevented. In addition, the diaphragmatic veins, vena cava, the surface of the parenchyma, hepatic artery and the integrity of the bile duct are checked before abdominal closure.

6.7 Technical variations

6.7.1 The liver hanging maneuver

In 2001 Belghiti described a technique termed the “liver hanging manoeuvre” (LHM). In this procedure, the liver is lifted by a tape passed between the anterior surface of the vena cava and the liver, thereby providing effective vascular control, in order to make the anterior approach safer and easier [15].

The classic technique was first described to facilitate right hepatectomy by the anterior approach. In this first variant of the procedure, the anterior aspect of the suprahepatic IVC is exposed and the space between the right hepatic vein (RHV) and the middle hepatic vein (MHV) is dissected along the IVC axis for 2–3 cm, and when the dissection is complete, the hepatic parenchyma is looped up with a tape.

During the parenchymal transection, continuous upwards traction is applied on the tape by holding both its ends together. The tape ensures the safety of the underlying major vascular structures during transaction in a manner akin to dissecting on the finger to protect an important underlying structure. The tape elevates the liver, making it easier to transect, and constantly guides the surgeon towards the correct plane, thereby enabling a vertical transaction along the shortest possible route. The traction on the tape can also be regulated to provide control in instances of venous bleeding to help identify the vessel.

In “up to down” technique, the classic technique is modified in order to increase its security that no major bleeding occurs during the maneuver [16]. The entire blind dissection of the RHIVC tunnel is performed in a craniocaudal direction in order to avoid the possible risk of RHV or MHV injury by the clamp inserted caudally. The maneuver is begun between the RHV and MHV, this space usually does not contain SHVs [17], and can be safely dissected for 3–4 cm downwards with a right-angled vascular clamp without any risk. The long axis of the RHIVC does not always represent a straight perpendicular line, but may take a straight-oblique or slightly curved course [17]. For this reason the dissection should be performed along a right oblique axis rather than in vertical direction to reduce the risk of injury to the caudate processus vein.

6.8 Drainage

Drainage is carried out by silicone drains. Two drains are brought out on the lower edge of the surgical incision, one placed on the right subdiaphragmatic space near the resected surface, whereas the second drain whose end lies in the foramen of Winslow is placed under the liver. In general, we believe that hepatectomies should be drained as this measure reduces the risk of postoperative hematoma formation or bile collection.

7. Immediate operative care

The patient is kept in ICU for a minimum of 12 h in order to begin monitoring potential postoperative complications (**Table 1**).

-
- Bleeding
 - Post-hepatectomy liver failure
 - Biliary fistula
 - Post-operative ascites
 - Surgical infection
 - Coagulation disorders
 - Pulmonary infection and respiratory disorders
 - Acute kidney injury
 - Hepatorenal syndrome
-

Table 1.
Potential postoperative complications of right hepatectomy.

8. Final considerations

The adoption of a specific technique for right hepatectomy is related to the preference of the surgeon and for each specific situation, however, it is desirable that surgeons are familiar with various techniques available to perform the operation. An obvious example is the resection of large tumors of the right lobe in these cases and it is desirable, but impossible, to maintain the conventional mode of hepatic resection with mobilization of the wolf right prior to transection. Another example is the ability to promptly apply occlusion of vascular influx, or even total vascular exclusion, in case of bleeding during hepatectomy.

The surgical risks associated with hepatic resection are now smaller, especially in specialized centers and high volume liver operations.

Author details

Luis Cesar Bredt

Surgical Oncology and Hepatobiliary Surgery, University Hospital of Western Paraná, State University of Western Paraná, Cascavel, Paraná, Brazil

*Address all correspondence to: lcbredt@gmail.com

IntechOpen

© 2018 The Author(s). Licensee IntechOpen. This chapter is distributed under the terms of the Creative Commons Attribution License (<http://creativecommons.org/licenses/by/3.0>), which permits unrestricted use, distribution, and reproduction in any medium, provided the original work is properly cited. 

References

- [1] Bismuth H. Les hépatectomies: Encycl méd.-Chir., Techniques Chirurgicales—Appareil Digestif. Paris: Editions Techniques Ed; 1968, 4.2.07, 40762
- [2] Couinaud C. Le foie. Etudes Anatomiques et Chirurgicales. Paris: Masson Ed; 1957
- [3] Goldsmith NA, Woodburne RI. Surgical anatomy pertaining to liver resection. *Surgery, Gynecology & Obstetrics*. 1957;**195**:310-318
- [4] Launois B, Jamieson GG. The importance of Glisson's capsule and its sheaths in the intrahepatic approach to resection of the liver. *Surgery, Gynecology & Obstetrics*. 1992;**174**:7-10
- [5] Lortat-Jacob JL, Robert HG, Henry C. Un cas d'hépatectomie droite réglée. *Mémoires. Académie de Chirurgie*. 1952; **78**:244-251
- [6] Tung TT, Quang ND. L'hépatectomie réglée par ligature vasculaire intra-parenchymateuse. *Presse Médicale*. 1965;**73**:3015-3017
- [7] Bismuth H, Castaing D, Garden OJ. Major hepatic resection under total vascular exclusion. *Annals of Surgery*. 1989;**210**:13-19
- [8] Bismuth H, Houssin D, Ornowski J, Meriggi F. Liver resection in cirrhotic patients: A western experience. *World Journal of Surgery*. 1986;**10**:311-317
- [9] Azoulay D, Raccuia JS, Castaing D, Bismuth H. Right portal vein embolization in preparation for major hepatic resection. *Journal of the American College of Surgeons*. 1995;**181**: 267-269
- [10] Bismuth H, Castaing D. Echographie per-opératoire du foie et des voies biliaires. Paris: Flammarion Médecine-Sciences Ed; 1985
- [11] Castaing D, Garden J, Bismuth H. Segmental liver resection using ultrasound-guided selective portal venous occlusion. *Annals of Surgery*. 1989;**210**:20-23
- [12] Shimamura Y, Gunven P, Takenaka Y, Shimizu H, Akimoto H, Shima Y, et al. Selective portal branch occlusion by balloon catheter during liver resection. *Surgery*. 1986;**100**:938-941
- [13] Gotoh M, Monden M, Sakon M, Kanai T, Umeshita K, Nagano H, et al. Hilar lobar vascular occlusion for hepatic resection. *Journal of the American College of Surgeons*. 1994; **178**:6-10
- [14] Hannoun L, Vaillant JC, Borie D, Delva E. Techniques de l'exclusion vasculaire du foie et des hépatectomies extrêmes (chirurgie «ex situ-ex vivo» et «in situ-ex vivo» du foie). *Encycl méd.-Chir., Techniques Chirurgicales - Appareil Digestif*. Vol. 40. Paris: Editions Techniques Ed; 1994. pp. 766-782
- [15] Belghiti J, Guevara OA, Noun R, Saldinger PF, Kianmanesh R. Liver hanging Manoeuvre : A safe approach to right hepatectomy without liver mobilization. *Journal of the American College of Surgeons*. 2001;**193**:109-111
- [16] Ogata S, Belghiti J, Varma D, Sommacale D, Maeda A, Dondero F, et al. Two hundred hanging manoeuvres for major hepatectomy: A single-centre experience. *Annals of Surgery*. 2007; **245**:31-35
- [17] Hirai I, Murakami G, Kimura W, Kanamura T, Sato I. How should we treat short hepatic veins and paracaval branches in anterior hepatectomy. *Clinical Anatomy*. 2003;**16**(3):224-232