

We are IntechOpen, the world's leading publisher of Open Access books Built by scientists, for scientists

5,300

Open access books available

130,000

International authors and editors

155M

Downloads

Our authors are among the

154

Countries delivered to

TOP 1%

most cited scientists

12.2%

Contributors from top 500 universities



WEB OF SCIENCE™

Selection of our books indexed in the Book Citation Index
in Web of Science™ Core Collection (BKCI)

Interested in publishing with us?
Contact book.department@intechopen.com

Numbers displayed above are based on latest data collected.
For more information visit www.intechopen.com



Chronic Endometritis

Attilio Di Spiezio Sardo, Federica Palma, Gloria Calagna, Brunella Zizolfi and Giuseppe Bifulco

Additional information is available at the end of the chapter

<http://dx.doi.org/10.5772/63023>

Abstract

Chronic endometritis is a persistent inflammation of the inner lining of the uterine cavity. Several studies have demonstrated that it is a condition frequently associated with repeated unexplained implantation failure at in vitro fertilization, recurrent miscarriage, as well as poor obstetric outcomes such as preterm labor.

The aim of this paper is to provide information about diagnosis and treatment of this condition to improve reproductive outcome. In fact, significantly higher rate of successful pregnancies was achieved in those patients in whom antibiotic treatment was able to normalize both hysteroscopic and histologic endometrial pattern compared with women who were not treated or with persistent disease. Hysteroscopy with endometrial biopsy is assumed to be the best method for the detection of chronic endometritis. So, we support the importance of hysteroscopy as a part of the diagnostic workup of infertile women.

Keywords: Infections, chronic endometritis, infertility, hysteroscopy, antibiotic therapy

1. Introduction

1.1. Definition and etiology

Endometritis is defined as inflammation of the endometrium, grouped in various typologies, depending on the underlying causality.

It may present in acute or chronic forms.

The acute form is principally a transitional phase of short duration generally arising due to the persistence of placental or abortive residues, or in combination with pelvic inflammatory disease, or with inflammatory conditions of bacterial/viral etiology elsewhere in the urogenital tract [1–4].

Chronic inflammation may follow the acute stage—which is the most frequently seen—or it may occur more subtly, as chronic inflammation ‘*ab initio*’, without passing through an acute stage.

Chronic endometritis can reveal a microbiological origin or a mechanical–chemical origin [5].

In the latter case, the most frequent causative agents are common pyogenic pathogens (streptococci, staphylococci, enterococci, *Escherichia coli*), as well as bacteria such as *Chlamydia trachomatis*, *Neisseria gonorrhoeae*, *Mycoplasma*, and *Ureaplasma urealyticum*. It has also been described in cases of postpartum endometritis secondary to herpes simplex virus (HSV) and cytomegalovirus (CMV) infections, particularly in patients with HIV [6–8].

However, although the etiology in most cases is polymicrobial, the results obtained by traditional culture tests are laboratory dependent, and often, given the use of endometrial sampling devices, vaginal and endocervical contamination cannot be excluded.

Also worth mentioning is tubercular endometritis, because in recent years there has been an increased incidence of tuberculosis in Western countries, owing to migration from countries with a high incidence of endemic tuberculosis.

Endometritis of chemical–mechanical origin, on the other hand, is generally caused by the presence of pessaries or intrauterine devices.

2. Clinical appearance

Chronic endometritis is often clinically silent. Therefore, it is impossible to accurately determine its true prevalence in the general population [5].

In some cases, however, it can be associated with *infertility* [9–11].

Endometrial inflammation seems to interfere with the physiological mechanisms of oocyte fertilization and embryonic implantation.

Repeated implantation failure (RIF) is defined as failure to conceive following two or three embryo transfer cycles or cumulative transfer of 10 good quality embryos [12,13].

In a retrospective study reported by Johnston-MacAnanny [14], women with a history of RIF after in vitro fertilization (IVF) were positively diagnosed with chronic endometritis in about 30% of cases and women diagnosed with chronic endometritis had lower implantation rates (11.5%) after IVF cycles.

In contrast, Kasius et al. [15] reported that the clinical implication of chronic endometritis seems minimal because they diagnosed this condition only in 2.8% of asymptomatic infertile patients with a normal transvaginal ultrasound examination (TVS). The same authors reported that the reproductive outcome at conventional In Vitro Fertilization (IVF) or Intra-cytoplasmic sperm injection (ICSI) cycles was not negatively affected by chronic endometritis, but they underlined that the low prevalence and unknown clinical significance of endometritis warrant further study [15, 16].

Cicinelli et al. [12], in a recent pilot research, demonstrated that chronic endometritis was a condition frequently associated with RIF (66.0%). It was about double compared with 30.3% reported by Johnston-MacAnanny et al. [14]. This discrepancy could be explained by the very strict selection criteria employed in this study (for example, in order to rule out any confounding factor and inflammatory conditions, they considered clinical or ultrasonographic evidence of ovarian endometrioma as an exclusion criterion) and by the expertise of their group in hysteroscopic and histological diagnosis of chronic endometritis. In this population study, the most prevalent infectious agents were common bacteria and mycoplasma. In addition, the normalization of the hysteroscopic endometrial pattern was associated with a significant improvement of the reproductive outcome of the IVF cycle performed after antibiotic treatment.

Chronic endometritis is also related to recurrent miscarriage (RM) [17].

RM, defined as three or more miscarriages before 20 weeks of pregnancy, affects about 3% of all couples [4, 18].

In a recent paper, it was demonstrated that in women with repeated abortions, chronic endometritis is a frequent finding (68.3%) and that women who received adequate antibiotic treatment had a significantly higher rate of successful pregnancies compared to women who were not treated or with persistent disease. Also in this population, the most prevalent infectious agents were common bacteria and *Mycoplasma* [12, 18].

In conclusion, untreated chronic endometritis seems to diminish the success rates of both spontaneous conception and IVF cycles, as well as to contribute to adverse obstetrical outcomes, as intrauterine infections, preterm delivery, and postpartum endometritis [2–4, 12, 16, 19–21]. Furthermore, all these results suggest that hysteroscopy should be a part of the diagnostic work-up of infertile women complaining of unexplained RM and with RIF [18, 22].

However, the exact mechanisms by which chronic endometritis can lead to a compromised fertility are not yet fully understood and are still the subject of numerous studies.

Very recently, it was shown that in the endometrial mucosa of infertile patients suffering from chronic endometritis, there is an altered distribution of natural killer cells. In particular, in chronic endometritis, there is a decrease in CD56 lymphocytes and an increase in CD16 lymphocytes, hence, an altered maternal immune tolerance towards the embryo, along with adverse effects on the mechanisms of implantation, and a defective trophoblastic invasion [23].

Other symptoms related to chronic endometritis are as follows [24]:

- *Abnormal uterine bleeding*: such a symptomatology can present in the form of intermenstrual spotting or metrorrhagia; however, to date, the relationship between abnormal uterine bleeding and chronic endometritis is not clear.
- *Dysmenorrhea*: the current hypothesis identifies, as a major cause of dysmenorrhea, the prostaglandins, which are released through the endometrial cell membranes damaged by the inflammatory process.
- *Dyspareunia*.

- *Leucorrhea and urinary symptoms*: occasionally, there is a malodorous, purulent vaginal discharge, with increased urinary frequency and/or symptoms similar to those of cystitis, along with concomitant bladder irritation.
- *Fever*: Elevated in the acute phase; in some cases, a mild fever in the chronic form.

Tubercular endometritis merits special mention; this type of chronic endometrial inflammation virtually always occurs secondary to respiratory or abdominal localization, with a clear predilection for adnexal localization. It is generally limited to young women of childbearing age, being rare in the menopause.

The symptomatology varies from overt forms, in which the inflammatory process has affected the appendages, to completely latent forms. In the presence of tubercular endometritis, changes in menstrual flow may occur, ranging from polymenorrhea to amenorrhea, accompanied by an almost universal history of sterility/infertility.

3. Prehysteroscopic diagnosis

The diagnosis of chronic endometritis by means of two-dimensional transvaginal sonography (TVS) is difficult due to the absence of pathognomonic signs associated with the condition [12].

Indirect sonography signs are as follows:

- hematometra;
- endometrium with hyperechogenic spots;
- intracavitary synechiae;
- increase in endometrial thickness, asynchronous with the phase of the menstrual cycle.

4. Hysteroscopic diagnosis

A hysteroscopy, performed in the proliferative phase of the menstrual cycle, allows to identify the signs of endometrial inflammation.

Under examination with CO₂, chronic endometritis typically presents with endometrial areas, which are bright red with white central dots, focally or diffusely distributed over the endometrial surface, assuming an appearance considered to resemble a 'strawberry' pattern, similar to the colposcopic pattern 'punctated with white spots'.

Other findings may be conspicuous due to the presence of friable, white patches that bleed easily on contact. These features are, however, very unspecific, as they may also be related to lesions of the vascular bed in reaction to the intracavitary CO₂ distension medium, or emerging due to immunological disorders, or hypertension, and they may yet be so mild as to evade diagnosis.

Uterine distension with saline has, among other advantages, that of causing no adverse side effects on endometrial microcirculation, thus facilitating the diagnosis of chronic endometritis [25].

The criteria proposed by Cicinelli et al. [26] to establish a hysteroscopic diagnosis of chronic endometritis are as follows (Figures 1–3):

- Hyperemia: The vascular network appears accentuated, especially at periglandular level.
- Stromal edema: The endometrium presents, in the proliferative phase, as both pale and thickened.
- Micropolyps: Manifesting with small pedunculated, vascularized protrusions of the uterine mucosa (<1 mm) covered by endometrium and characterized by an accumulation of inflammatory cells (lymphocytes, plasma cells, and eosinophils) intermingled with normal stromal cells.

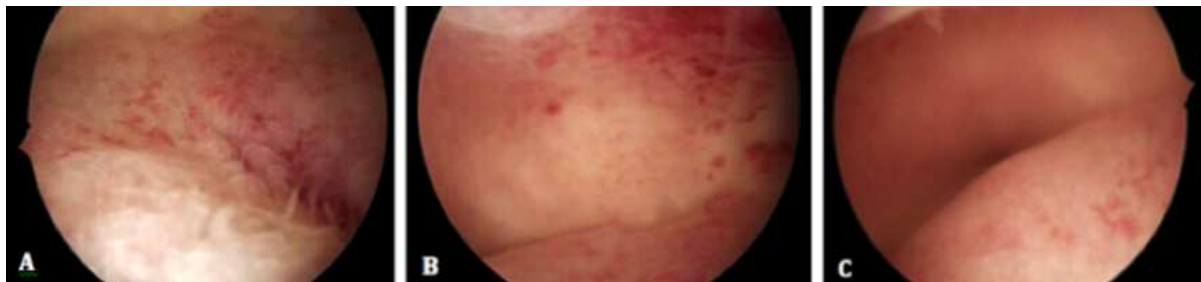

Figure 1. Hysteroscopic view of chronic endometritis in a 30-year-old infertile woman. Saline used as distension medium does not affect endometrial microcirculation, making it easier to identify the characteristic signs of chronic endometritis. Note the micropolyps, which appear as small pedunculated, vascularized protrusions (<1 mm) on the uterine mucosa (A). The close-up view clearly shows a marked accentuation of the vascular network at the level of the uterine fundus (B). To right, an overt stromal edema is evident (C), though the examination was carried out in the early proliferative phase.

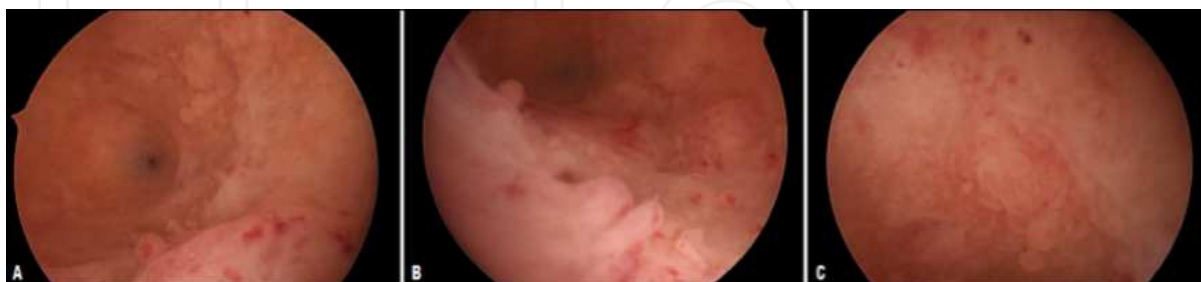


Figure 2. Hysteroscopic view of chronic endometritis in a 34-year-old woman with a positive anamnesis of three early spontaneous abortions (A–C). The stromal edema is clearly evident on the posterior wall (A) and micropolyps are detected on any of the uterine walls (A–C).

A study led by Cicinelli in 2005 [26] showed that the absence of stromal edema and hyperemia –detected at hysteroscopy – has a high negative predictive value (98.8%), i.e., the absence of

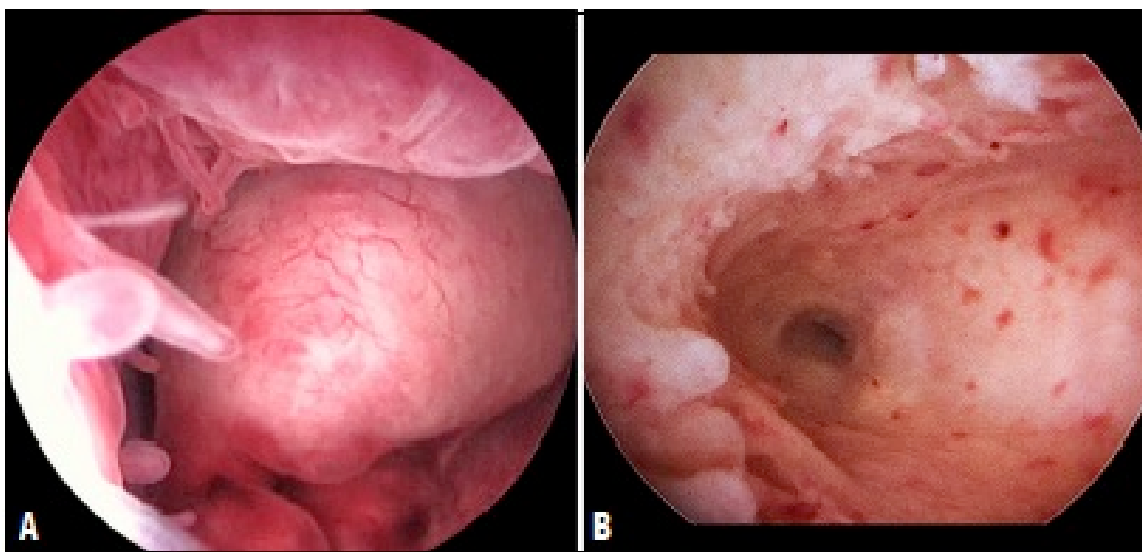


Figure 3. Detail of micropolyps under hysteroscopic examination using a liquid distension medium: the micropolyps, which appear with a varied morphology, are scattered over the uterine wall and may often be encountered with polyps (A) and/or pseudopolyps.

these findings allows the hysteroscopist to rule out, with reasonable certainty, the presence of endometrial inflammation.

Conversely, if micropolyps are found, which is almost always associated with hyperemia or stromal edema, this should be interpreted a reliable sign of inflammation, as corroborated by the high positive predictive value attributed to this finding (98.4%).

The presence of focal hyperemia with isolated micropolyps is associated, histologically, with a mild type of endometrial inflammation; conversely, the findings of generalized hyperemia, diffused micropolyps, or a thickened endometrium with polypoid diffusion are all associated with moderate-to-severe endometrial inflammation [27, 28].

In summary, the presence of hyperemia, edema, and stromal micropolyps has a demonstrated diagnostic accuracy of 93.4%.

The potential development of endometritis, if left untreated, leads to the formation of intrauterine synechiae.

Regarding tuberculous endometritis, certain hysteroscopic signs suggestive of disease have been described, such as the presence of a thin, uneven, and pale endometrium with irregular whitish spots scattered over the uterine walls [29].

It is not uncommon to observe intrauterine adhesions, while a much rarer finding is the presence of classic tubercles in the endometrial mucosa. Differential diagnosis should be established against the presence of granulomatous endometritis (sarcoidosis) and that of the fungal form [30]. Even CMV-related endometritis can manifest itself in the granulomatous form.

Finally, there is a rare form of endometritis that may mimic, at macroscopic level, an endometrial carcinoma [31]. This is xanthogranulomatous endometritis, whose etiology is still

under debate, and which occurs predominantly in elderly women with cervical stenosis and pyometra. Histologically, it is characterized by xanthogranuloma, consisting of lipid-rich histiocytes, giant cells, lymphocytes, neutrophils, and plasma cells.

5. Histological diagnosis

The histological diagnosis of chronic endometritis is based on the presence of a number of criteria that have been widely described in the literature: superficial stromal edema, increased stromal density, and inflammatory stromal infiltration, which is predominated by the presence of lymphocytes and plasma cells [32]. The presence of the latter is considered by some authors as a marker specific to endometritis; according to some, in particular, the presence of a few or even a single stromal level plasma cell is enough to settle the diagnosis on chronic endometritis [33].

However, the majority of authors agree upon a greater importance that an overall view of all histological aspects be established (the coexisting presence of several criteria suggestive of chronic endometritis—rather than focusing on a single diagnostic criterion).

An unusual distribution pattern of leukocytes in the endometrial mass and the presence of an increased number of B lymphocytes may contribute to the diagnosis because the B lymphocytes in the endometrium normally make up less than 1% of the leukocyte count.

6. Treatment

The therapy for chronic endometritis is pharmacological and is based on the administration of broad-spectrum antibiotics [34, 35].

Generally, the drug of choice is doxycycline, administered in doses of 100 mg every 12 hours for 14 days, or alternatively, the administration of cephalosporins, macrolides, or quinolones is possible. It is preferable for the partner to also undergo the same antibiotic treatment.

Where antibiotic therapy fails and/or where the presence of endometritis persists, an endometrial culture with a relative antibiogram should be considered and an appropriate antibiotic treatment must be prescribed.

In particular, according to the Centers for Disease Control guidelines, the therapies recommended are in case of [12]:

- positive for Gram-negative bacteria: Ciprofloxacin 500 mg twice a day for 10 days as first line therapy;
- Gram-positive bacteria: Amoxicillin+clavulanate 1 g twice a day for 8 days;
- *Mycoplasma* and *U. urealyticum* infections: Josamycin 1 g twice a day for 12 days; while, in case of persistence, minocycline 100 mg twice a day for 12 days;

- negative cultures: Ceftriaxone 250 mg IM in a single dose plus doxycycline 100 mg orally twice a day for 14 days with metronidazole 500 mg orally twice a day for 14 days.

In case of persistence of signs of chronic endometritis at subsequent hysteroscopy, the protocol can be repeated up to three times.

In the presence of confirmed tuberculous endometritis, the patient should be given a specific antibiotic therapy for tuberculosis (isoniazid, ethambutol, rifampicin, and pyrazinamide for 2 months, followed by isoniazid and rifampicin for another 4 months).

Author details

Attilio Di Spiezio Sardo^{1*}, Federica Palma², Gloria Calagna³, Brunella Zizolfi¹ and Giuseppe Bifulco²

*Address all correspondence to: cdispie@tin.it, attiliodispiezio@libero.it

1 Unit of Obstetrics and Gynecology, University of Federico II, Naples, Italy

2 Unit of Obstetrics and Gynecology, University of Modena and Reggio Emilia, Italy

3 Unit of Obstetrics and Gynecology, University of Palermo, Italy

References

- [1] Taylor S, Frydman R. Hysteroscopy and sperm infection. *Contracept Fertil Sex* 1996; 24: 549–51.
- [2] Gravett MG, Hitti J, Hess DL, Eschenbach DA. Intrauterine infection and preterm delivery: evidence for activation of the fetal hypothalamic pituitary-adrenal axis. *American Journal of Obstetrics and Gynecology* 2000; 182: 1404–13.
- [3] Eckert LO, Moore DE, Patton DL, Agnew KJ, Eschenbach DA. Relationship of vaginal bacteria and inflammation with conception and early pregnancy loss following in vitro fertilization. *Infectious Diseases in Obstetrics and Gynecology* 2003; 11: 11–7.
- [4] Romero R, Mazor M. Infection and preterm labor. *Clinical of Obstetrics and Gynecology* 1988; 31: 553–84.
- [5] Farooki MA. Epidemiology and pathology of chronic endometritis. *International Surgery* 1967; 48: 566–73.
- [6] Giraldo-Isaza MA, Jaspan D, Cohen AW. Postpartum endometritis caused by herpes and cytomegaloviruses. *Obstetrics and Gynecology* 2011; 117: 466–7.

- [7] Hollier LM, Laurie Scott L, Murphree SS, Wendel GD. Postpartum endometritis caused by herpes simplex virus. *Obstetrics and Gynecology* 1997; 89 (5): 836–8.
- [8] Remaldi S, Finci V, Ismail A, Zacharie S, Vassilakos P. Herpetic endometritis after pregnancy. *Pathology Research and Practice* 1995; 191: 31–4.
- [9] Kamiyama S, Teruya Y, Nohara M, Kanazawa K. Impact of detection of bacterial endotoxin in menstrual effluent on the pregnancy rate in in vitro fertilization and embryo transfer. *Fertility and Sterility* 2004; 82: 788–92.
- [10] Polisseni F, Bambirra EA, Camargos AF. Detection of chronic endometritis by diagnostic hysteroscopy in asymptomatic infertile patients. *Gynecologic and Obstetric Investigation* 2003; 55: 205–10.
- [11] Salim R, Ben-Shlomo I, Colodner R, Keness Y, Shalev E. Bacterial colonization of the uterine cervix and success rate in assisted reproduction: results of a prospective survey. *Human Reproduction* 2002; 17: 337–40.
- [12] Cicinelli E, Matteo M, Tinelli R, Lepera A, Alfonso R, Indraccolo U, Marrocchella S, et al. Prevalence of chronic endometritis in repeated unexplained implantation failure and the IVF success rate after antibiotic therapy. *Human Reproduction*. 2015; 30: 323–30.
- [13] El-Toukhy T, Taranissi M. Towards better quality research in recurrent implantation failure: standardizing its definition is the first step. *Reproductive Biomedicine Online* 2006;12:383–5.
- [14] Johnston-Mac-Ananny EB, Hartnett J, Engmann LL, Nulsen JC, Sanders MM, Benadiva CA. Chronic endometritis is a frequent finding in women with recurrent implantation failure after in vitro fertilization. *Fertility and Sterility* 2010; 93: 437–41.
- [15] Kasius JC, Fatemi HM, Bourgain C, Sie-Go DM, Eijkemans RJ, Fauser BC, Devroey P, et al. The impact of chronic endometritis on reproductive outcome. *Fertility and Sterility* 2011; 96(6): 1451–6.
- [16] Kasius JC, Broekmans FJM, Sie-Go DM, Bourgain C, Eijkemans MJC, Fauser BC, Devroey P, et al. The reliability of the histological diagnosis of endometritis in asymptomatic IVF cases: a multicenter observer study. *Human Reproduction* 2012; 27: 153–8.
- [17] Kitaya K. Prevalence of chronic endometritis in recurrent miscarriage. *Fertility and Sterility* 2011; 95: 1156–8.
- [18] Cicinelli E, Matteo M, Tinelli R, Pinto V, Marinaccio M, Indraccolo U, De Ziegler D, et al. Chronic endometritis due to common bacteria is prevalent in women with recurrent miscarriage as confirmed by improved pregnancy outcome after antibiotic treatment. *Reproductive Sciences*. 2014; 21: 640–7.

- [19] Feghali J, Bakar J, Mayenga JM, Segard L, Hamou J, Driguez P, Belaish-Allart J. Systematic hysteroscopy prior to in vitro fertilization. *Gynecol Obstet Fertil* 2003; 31: 127–31.
- [20] Espinoza J, Erez O, Romero R. Preconceptional antibiotic treatment to prevent preterm birth in women with a previous preterm delivery. *American Journal of Obstetrics and Gynecol* 2006; 194: 630–7.
- [21] Romero R, Espinoza J, Mazor M. Can endometrial infection/inflammation explain implantation failure, spontaneous abortion, and preterm birth after in vitro fertilization? *Fertility and Sterility* 2004; 82: 799–804.
- [22] Zolghardri J, Momthan M, Aminian K, Ghaffarpassand F, Tavana Z. The value of hysteroscopy in diagnosis of chronic endometritis in patients with unexplained recurrent spontaneous abortion. *European Journal of Obstetrics and Gynecology and Reproductive Biology* 2011; 217–20.
- [23] Matteo M, Cicinelli E, Greco P, Massenzio F, Baldini D, Falagario T, Rosenberg P, Castellana L, Specchia G, Liso A. Abnormal pattern of lymphocyte subpopulations in the endometrium of infertile women with chronic endometritis. *American Journal of Reproductive Immunology* 2009; 322–9.
- [24] Greenwood SM, Moran JJ. Chronic endometritis: morphologic and clinical observations. *Obstetrics and Gynecology* 1981; 58: 176–84.
- [25] Cicinelli E, Resta L, Nicoletti R, Tartagni M, Marinaccio M, Bulletti C, Tartagni M, Marinaccio M, Bulletti C, Colafiglio G. Detection of chronic endometritis at fluid hysteroscopy. *Journal of Minimally Invasive Gynecology* 2005; 12: 514–8.
- [26] Cicinelli E, Resta L, Nicoletti R, Zappimbulso V, Tartagni M, Saliani N. Endometrial micropolyps at fluid hysteroscopy suggest the existence of chronic endometritis. *Human Reproduction* 2005; 20: 1386–9.
- [27] Cicinelli E, De Ziegler D, Nicoletti R. Chronic endometritis: correlation among hysteroscopic, histologic and bacteriologic findings in a prospective trial with 2190 consecutive office hysteroscopies. *Fertility and Sterility* 2008; 89: 677–84.
- [28] Cicinelli E, Tinelli R, Lepera A, Pinto V, Fucci M, Resta L. Correspondence between hysteroscopic and histologic findings in women with chronic endometritis. *Acta ObstetGynecol Scand* 2010; 89: 1061–5.
- [29] Cicinelli E, Tinelli R, Colafiglio G, Saliani N, Pastore A. Tubercular endometritis: a rare condition reliably detectable with fluid hysteroscopy. *Journal of Minimally Invasive Gynecology* 2008; 15: 752–54.
- [30] Sharma JB Roy KK, Pushparaj M, Karmakar D, Kumar S, Singh N. Increased difficult and complications encountered during hysteroscopy in women with genital tuberculosis. *Journal of Minimally Invasive Gynecology* 2011; 18: 660–65.

- [31] Dogan-Ekici AI, Usubütün A, Küçükali T, Ayhan A. Xanthogranulomatous endometritis: a challenging imitator of endometrial carcinoma. *Infectious Diseases in Obstetrics and Gynecology* 2007; 347–63.
- [32] Smith M, Hagerty KA, Skipper B, Bocklage T. Chronic endometritis: a combined histopathologic and clinical review of cases from 2002 to 2007. *International Journal of Gynecologic Pathology* 2010; 29: 44–50.
- [33] Pitsos M, Sturnick J, Heller D. Association of pathologic diagnoses with clinical findings in chronic endometritis. *Journal of Reproductive Medicine* 2009; 54 (6): 373–7.
- [34] Andrews WW, Goldenberg RL, Hauth JC, Cliver SP, Cooper R, Conner M. Interconceptional antibiotics to prevent spontaneous preterm birth: a randomized clinical trial. *American Journal Obstetrics and Gynecology* 2006; 194: 617–23.
- [35] Cravello L, Porcu G, D'Ercole C, D'Ercole C, Roger V, Blanc B. Identification and treatment of endometritis. *ContraceptFertil Sex* 1997; 25: 585–6.

