

We are IntechOpen, the world's leading publisher of Open Access books Built by scientists, for scientists

5,900

Open access books available

146,000

International authors and editors

185M

Downloads

Our authors are among the

154

Countries delivered to

TOP 1%

most cited scientists

12.2%

Contributors from top 500 universities



WEB OF SCIENCE™

Selection of our books indexed in the Book Citation Index
in Web of Science™ Core Collection (BKCI)

Interested in publishing with us?
Contact book.department@intechopen.com

Numbers displayed above are based on latest data collected.
For more information visit www.intechopen.com



Clinical Manifestations of Sarcoidosis

Luis Jara-Palomares, Candela Caballero-Eraso,
Cesar Gutiérrez, Alvaro Donate and
Jose Antonio Rodríguez-Portal

Additional information is available at the end of the chapter

<http://dx.doi.org/10.5772/55556>

1. Introduction

Sarcoidosis is a systemic granulomatous disease of unknown etiology that is characterized from the point of view of pathology of the presence of noncaseating granulomas in affected organs. Typically affects young adults and is often present initially with one or more of the following conditions: 1) bilateral hilar lymphadenopathy, 2) pulmonary reticular pattern, 3) Involvement of the skin, joints and / or eyes.

In this chapter we are going to review and update the clinical features and sign of sarcoidosis.

2. Airway involvement

Patients with pulmonary sarcoidosis may have impaired upper and/or lower airway, and could be impossible or difficult to detect with routine imaging, but are recognized by alternative diagnostic tests (eg, bronchoscopy) [1]. Endobronchial disease exists in approximately 40% of patients with stage I disease, and approximately 70% of patients with stage II or III. Airway stenosis clinically significant is rare but can be unwieldy when severe [2, 3]. Table 1 summarize the airway involvement in sarcoidosis.

In the fibrotic stage of the disease can be observed thinning of the mucosa, pallor, and scarring can lead to a decrease in the light of the airways and the stenosis [4-6].

Type of involvement	Comments
Mucosal erythema and edema	Nonspecific finding*
Granular mucosa	Nonspecific*
Cobblestone mucosa	More common in lobar and segmental bronchi*
Mucosal plaques (yellowish)	Also occurs in other disorders*
Mucosal nodules (waxy yellow)	Characteristic feature*; may occlude bronchi
Bronchial stenosis	Lobar and segmental bronchi affected more frequently than central airways; mucosal biopsy may or may not show granulomas
Airway distortion	More likely in advanced parenchymal disease
Bronchiectasis	Traction bronchiectasis associated with advanced parenchymal disease; usually asymptomatic
Bronchiolitis	Uncommon; CT scan may suggest diagnosis*
Extrinsic compression	Uncommon; may occur with significant thoracic lymphadenopathy
Airway hyperreactivity	Occurs in up to 20% of sarcoid patients; endobronchial involvement increases the risk
Airflow limitation (FEV1/FVC ratio < 80)	Occurs in 60% of sarcoid patients; seen in any stage
Hemoptysis	Uncommon from airway involvement
Obstructive sleep apnea	Due to laryngeal involvement; more common in patients with lupus pernio
Supraglottic structures	Oral, nasal, and pharyngeal mucosal changes as noted above, hoarseness, dysphagia, laryngeal paralysis, and airway obstruction

*A biopsy required to document the presence of a noncaseous granuloma; in other types of involvement, a biopsy specimen may or may not demonstrate noncaseous granulomas.

Modified from Ref. 1

Table 1. Airway involvement in sarcoidosis

2.1. Supraglottic airways

Nasal passages, oropharynx, supraglottic structures, and the larynx develop sarcoid granulomas in approximately 6% of patients with sarcoidosis [7-10]. Debería sospecharse en todos los pacientes con sarcoidosis sistémica y síntomas de vía aérea superior [4, 5, 8, 11-12]. Sarcoid lesions can occur in nasal and oral mucosa, occasionally with ulceration; anosmia improves after steroid therapy [13]. A nasal examination may reveal granulomatous mass, yellow-white mucosal papules, and adhesions and crusting of septal and turbinate mucosa. Nodular sarcoidosis of supraglottic and glottic structures can lead to dyspnea, stridor, dysphonia, irritating cough with pharyngolaryngeal discomfort, dysphagia, retronasal obstruction, and/or hyponasal speech. Rhinopharyngolaryngeal endoscopy may reveal reddish or yellow granulomatous lesions (2-4 mm in diameter) [14]. Laryngoscopy may show epiglottic thickening and granularity, granulomatous mass and infiltrative sarcoid nodules of epiglottis, aryepiglottic folds, and false cords. These may cause respiratory distress, requiring tracheostomy [15]. Flow-volume curves and laryngeal examination are helpful in the diagnosis and management [16]. Obstructing polypoid sarcoid lesions have been managed with laryngoscopic resection, tracheostomy, or local injection of a corticosteroid [17].

Obstructive sleep apnea, which occurs in about 5% of the general population, seems to occur with increased frequency in patients with sarcoidosis, especially in patients with lupus pernio [18]. Sarcoidosis of the upper airways has been suggested as one of the possible mechanisms for sleep apnea in patients with sarcoidosis and lupus pernio, although the overwhelming majority of obstructive sleep apnea in sarcoidosis is most probably related to obesity from corticosteroids. Sarcoidosis of the supraglottic airways in children is rare [19].

2.2. Larynx

Laryngeal sarcoidosis often occurs as an isolated phenomenon and is usually attributed to asthma [20]. Occasionally, laryngeal sarcoid can lead to progressive life-threatening airway obstruction [15]. Laryngeal sarcoidosis is uncommon [21]. The incidence of laryngeal sarcoidosis is estimated to be about 1.2%. Laryngeal sarcoidosis could be treated with systemic and intralesional injections of a corticosteroid, surgical intervention, carbon dioxide laser ablation, and external beam radiation [22, 23].

Paralysis of the left vocal cord and hoarseness can occur from compression of the left recurrent laryngeal nerve by enlarged lymph nodes [24, 25]. Systemic corticosteroid therapy has resulted in resolution of the hoarseness [24].

2.3. Central airways

The trachea and main bronchi are less frequently affected than the lobar, segmental, subsegmental, and distal airways. Sarcoid granulomas of trachea, main carina, and major bronchi by themselves seldom produce significant obstructive symptoms or airway dysfunction [26, 27]. Cough is the main symptom. Symptoms, clinical examination, flow-volume curves, and bronchoscopy help in assessing the severity of the central airway stenosis [28].

Mainstem bronchial stenoses as well as segmental stenosis have been described in patients with sarcoidosis [29]. Disabling inspiratory and expiratory airflow limitation mimicking fixed upper airway obstruction has been reported [27]. Bronchoscopy may demonstrate other changes as: mucosal erythema, edema, friability, granularity, fine cobblestoning, and sarcoid nodules. The characteristic yellow waxy nodules typical of sarcoidosis are less likely to occur in the trachea and main bronchi, but when seen in these areas, they tend to be sparsely distributed.

Extrinsic compression of the central airways by the enlarged mediastinal and hilar lymph nodes is uncommon. Right middle lobe syndrome caused by extrinsic compression and intraluminal sarcoidosis has been described [30].

2.4. Distal airways

Sarcoidosis could affect lobar, segmental, subsegmental, and more distal bronchi as well as bronchioles, which is manifested as mucosal inflammation, endobronchial granulomas, stenosis, extrinsic compression, distortion, bronchiectasis, bronchiolitis, airway hyperreactivity, and streaky hemoptysis.

These can lead to airway dysfunction and respiratory symptoms. Sarcoid granulomas tend to develop along the bronchovascular bundle or in the vicinity of the airways. All of these changes are more likely to affect the airways in upper and mid-lung regions.

The various types of airway abnormalities encountered in patients with sarcoidosis are described in the following paragraphs.

a. Endobronchial Granulomas

The definitive diagnosis of endobronchial granulomata requires a biopsy of the airway mucosa because a normal-appearing airway mucosa does not exclude the presence of granulomas [31]. The mucosal abnormalities can be diffuse or patchy. These findings are nonspecific and may be seen in other disorders. Therefore, biopsies of the mucosa and submucosa are essential for making a histologic diagnosis. Segmental and lobar bronchial lumen can be compromised by extrinsic compression by an enlarged adjacent lymph node. Endobronchial characteristics of sarcoid granulomas are well documented [32]. The classic endobronchial sarcoidosis is characterized by mucosal islands of waxy yellow mucosal nodules, measuring 2 to 4 mm in diameter. These nodules appear dull gray or waxy yellow. The mucosal lesions tend to be diffuse but more profuse in the lobar and segmental bronchi. Bronchial luminal occlusion by sarcoid granulomas can mimic an obstructing malignant mass. Endobronchial granulomas produce cough, wheezing, and dyspnea. The mucosal nodules seldom ulcerate or bleed.

b. Bronchial Stenosis

Bronchial stenosis is reported to occur in up to 14% of patients with sarcoidosis [33]. Bronchoscopy is helpful in evaluating the location, types, and severity of bronchial stenosis. The stenoses can be solitary or multiple, lobar or segmental bronchial stenoses, with or without atelectasis, and they may occur at any stage of respiratory sarcoidosis [33-35]. Extensive and multiple stenotic lesions of larger bronchi may cause or contribute to pulmonary symptoms.

c. Bronchiolitis

Bronchiolar involvement from sarcoidosis can also occur in early sarcoidosis without pulmonary parenchymal involvement [36, 37]. Bronchiolitis obliterans organizing pneumonia, bronchiolar narrowing and occlusion, and sarcoidosis coexisting with asthma have been described [38, 39]. Airtrapping is a common feature in sarcoidosis and correlates with evidence of small airways disease on pulmonary function testing.

d. Airway Distortion

Airway distortion is common in later stages of sarcoidosis and is caused by granulomatous changes in and around the airways and the secondary traction bronchiectasis associated with pulmonary parenchymal fibrosis [40, 41].

e. Bronchiectasis

Traction bronchiectasis becomes evident as the parenchymal disease progresses [40]. Traction bronchiectasis has been reported in up to 40% of patients with fibrotic stages of sarcoid [41]. Localized bronchiectasis of the right middle lobe caused by obstructing sarcoid granuloma has

been described [42]. Traction bronchiectasis and bronchial distortion, as described earlier, seldom cause bronchiectatic symptoms [43].

f. Hemoptysis

Hemoptysis in patients with sarcoidosis is usually the result of a complication such as the development of an aspergilloma in advanced fibrotic and cavitary sarcoid [44-46]. Large pulmonary cystic lesions occur in advanced stages of sarcoidosis, and these could potentially become infected with *Aspergillus* and aspergilloma could develop. Fatal massive hemoptysis has been described in such patients [46]. Traction bronchiectasis is observed in patients with advanced sarcoidosis and endobronchial sarcoidosis rarely causes hemoptysis.

g. Airway Hyperreactivity

Airway hyperreactivity has been reported in up to 20% of patients with sarcoidosis, and, as a result, cough and wheezing may prompt patients to seek medical help [47, 48]. The airway hyperreactivity is also responsible for the cough, wheezing, and dyspnea and is independent of the airway involvement. Airway hyperreactivity in patients with sarcoidosis remains a difficult entity to define because of the airway involvement by sarcoidosis. The smaller baseline diameter of the diseased airway can potentially increase airway resistance and lead to a false-positive bronchoprovocation test result.

2.5. Bronchoscopy

Bronchoscopy plays a significant role in the diagnosis and management of airway sarcoidosis. The role of the technique in the retrieval of immune effector cells and infectious organisms by analyzing bronchoalveolar lavage (BAL) fluid, biopsy specimens of pulmonary parenchymal sarcoid, and needle aspiration/biopsy samples of enlarged lymph nodes in the mediastinum and hilar regions is well known [49]. These bronchoscopic techniques have an important role in the diagnosis of infectious diseases in sarcoid patients in whom complications such as aspergilloma and other infections develop. Bronchoscopy also helps in excluding disorders that may resemble sarcoidosis.

Bronchoscopic abnormalities have been observed in up to 60% of patients with sarcoidosis [48]. These include "retinalization" of mucosa from increased mucosal vascularity, mucosal coarseness, pallor, flat yellow mucosal plaques, wartlike excrescences, "bleb-like" formations, irregular mucosal thickening, ulceration, and atrophic mucosa. The three common findings were bronchial mucosal hyperemia or edema, distortion of the bronchial anatomy, and bronchial narrowing. The classic endobronchial sarcoidosis is mucosal islands of waxy yellow mucosal nodules, 2 to 4 mm in diameter. Bronchoscopy may reveal endobronchial occlusion by sarcoid granulomas in the submucosa or an endobronchial polyp caused by sarcoid granulomas [35].

Bronchoscopic biopsy of endobronchial lesions confirms the diagnosis of endobronchial sarcoidosis in up to 70% patients with the disease [48, 50, 51]. Patients with abnormal-appearing airways are much more likely to have positive results, with a diagnostic yield of 75% [48]. Even when the airway mucosa appears normal, mucosal biopsy specimens may

demonstrate mucosal or submucosal noncaseous granulomas in up to 50% of patients with sarcoidosis [48]. In typical cases, the identification of noncaseous granulomas on frozen section analysis may render lung biopsy unnecessary.

3. Lung disease

Sarcoidosis occurs in patients aged between 10-40 years in 70-90% of cases. In about half the cases the disease is detected incidentally by alterations in the chest radiograph. The organ most frequently affected is the lung. The most common symptoms are cough, dyspnea and chest pain. In patients in the eighth decade of life is more common than systemic symptoms such as fatigue and anorexia, although dyspnea is often present at the same time [52].

A pulmonary auscultation crackles or roncus uncommon to hear, but wheezing may be present.

3.1. Pulmonary imaging

Pulmonary involvement occurs in 90% of patients with sarcoidosis [10]. The typical chest radiograph shows bilateral hilar lymphadenopathy. This finding, however, may be absent, or if present may occur in combination with opacities in the parenchyma. Parenchymal opacities may be interstitial, alveolar or both. Pleural involvement is uncommon (<5%), but may occur as lymphocytic exudate in the pleural effusion, chylothorax, hemothorax, or pneumothorax [54-56].

a. Chest x-ray:

Stage of lung involvement is established based on chest radiography. Although the chest radiograph provides an anatomical guide of lung disease can not measure disease activity or functional damage assessment. The sarcoid nodule is defined as pulmonary nodules, bilateral and multiple in the chest radiograph, which may mimic metastatic disease. When viewed through the computerized tomography (CT) revealed a nodular consolidation with well defined borders [56]. Radiological stages are (Figure 1):

- Stage I: is defined as the presence of bilateral hilar lymphadenopathy, which are often accompanied with an increase in right paratracheal adenopathy. 50% of patients initially present as bilateral hilar lymphadenopathy. In 75% of cases, hilar lymphadenopathy return within the first through third year, while 10% will persist for 10 years or more.
- Stage II: Defined as bilateral hilar lymphadenopathy and reticular opacities (the latter occurs more often in the upper lobes). These findings are initially in 25% of patients. In two thirds of these cases the lesions regress spontaneously, while the rest can be progression of the disease or remain unchanged over time. Normally the stage II patients have mild or moderate. The most common symptoms are usually: cough, dyspnea, fever, and/or fatigue.
- Stage III: This is defined as reticular opacities without hilar lymphadenopathy. Reticular opacities are distributed predominantly in the upper lobes.

- Stage IV: Is characterized by reticular opacities with evidence of volume loss, chiefly distributed in the upper lobes. Can also be observed: adenopathic clusters with marked traction bronchiectasis, or extensive calcification, cavitation or cyst formation [57].

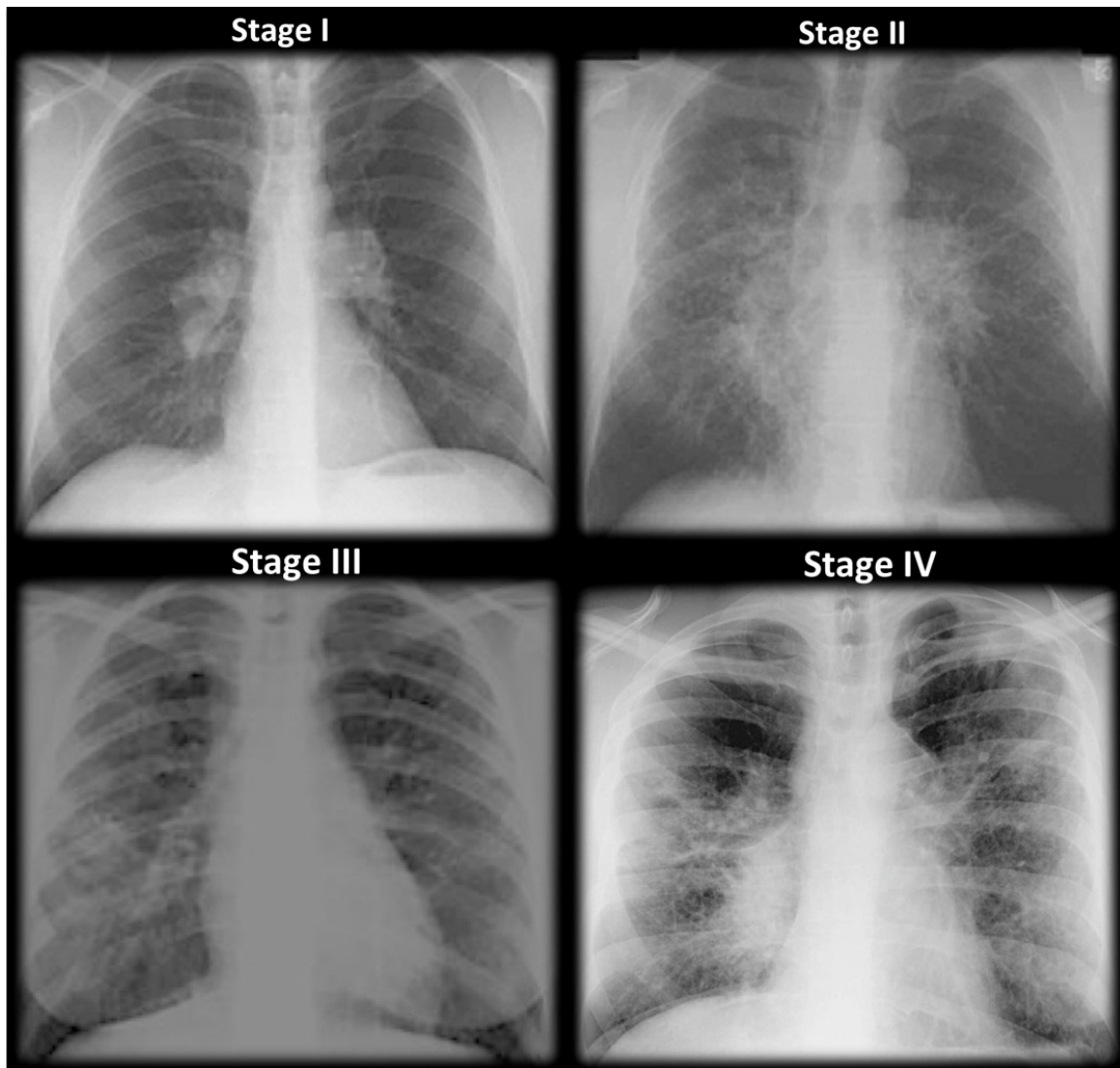


Figure 1. Staging of sarcoidosis on basis of chest radiographs

b. Computerized Axial Tomography (CT) scan:

Sarcoidosis patient can show a variety of abnormalities [58, 59]: Hilar and mediastinal lymphadenopathy, beaded or irregular thickening of the bronchovascular bundles, nodules along bronchi, vessels, and subpleural regions, bronchial wall thickening, ground glass opacification, parenchymal masses or consolidation, parenchymal bands, cysts, traction bronchiectasis, fibrosis with distortion of the lung architecture.

High-resolution CT has proved superior to conventional CT for assessing subtle parenchymal details and discriminating between inflammation and fibrosis in patients with pulmonary

sarcoidosis [58, 60]. The thin-section collimation (1- to 1.5- mm section thickness) and high-spatial-frequency reconstruction algorithms that are used to generate high-resolution CT images allow improved detection of nodular and reticular opacities, thickened interlobular septa, and faint ground-glass opacities, making the technique especially useful for identifying and managing sarcoidosis.

High-resolution CT may be particularly helpful for distinguishing active inflammation from irreversible fibrosis in selected patients with stage 2 or 3 sarcoidosis. Nodules, ground-glass opacities, and alveolar opacities are suggestive of granulomatous inflammation that may be reversed with therapy [61]. By contrast, honeycomb-like cysts, bullae, broad and coarse septal bands, architectural distortion, volume loss, and traction bronchiectasis are indicative of irreversible fibrosis [62]. High-resolution CT may be useful also for verifying specific diagnoses in patients with atypical clinical manifestations or unusual radiographic features [63].

In the appropriate clinical context, the observation of typical imaging features of sarcoidosis (eg, bilateral hilar lymph node enlargement with a perilymphatic micronodular pattern) and the anatomic distribution of those abnormalities (eg, upper lobe predominance) may point to a highly specific diagnosis. However, atypical manifestations may necessitate a broader differential diagnosis that includes tuberculosis and other granulomatous infections, silicosis, malignancies, and pneumoconiosis.

We are going to explain some typical patterns of sarcoidosis. Criado et al. [64] published an extensive review about typical and atypical patterns of sarcoidosis. Table 2 shows typical and atypical features of pulmonary sarcoidosis at high-resolution CT.

Typical features	Atypical features
Lymphadenopathy: hilar, mediastinal (right paratracheal), bilateral, symmetric, and well defined	Lymphadenopathy: unilateral, isolated, anterior and posterior mediastinal
Nodules: micronodules (2–4 mm in diameter; well defined, bilateral); macronodules (≥ 5 mm in diameter, coalescing)	Airspace consolidation: masslike opacities, conglomerate masses, solitary pulmonary nodules, confluent alveolar opacities (alveolar sarcoid pattern)
Lymphangitic spread: peribronchovascular, subpleural, interlobular septal	Linear opacities: interlobular septal thickening, intralobular linear opacities
Fibrotic changes: reticular opacities, architectural distortion, traction bronchiectasis, bronchiolectasis, volume loss	Fibrocystic changes: cysts, bullae, blebs, emphysema, honeycomb-like opacities with upper- and middle-zone predominance
Bilateral perihilar opacities	Ground-glass opacities
Predominant upper- and middle-zone locations of parenchymal abnormalities	Miliary opacities
	Airway involvement: mosaic attenuation pattern, tracheobronchial abnormalities, atelectasis
	Pleural disease: effusion, chylothorax, hemothorax, pneumothorax, pleural thickening, calcification
	Mycetoma, aspergilloma

Table 2. Typical and Atypical Features of Pulmonary Sarcoidosis at High-Resolution CT. Modified from ref. 64.

- Typical Patterns of Lymphadenopathy

The most common pattern is well-defined, bilateral, symmetric hilar and right paratracheal lymph node enlargement. Bilateral hilar lymph node enlargement, alone or in combination with mediastinal lymph node enlargement, occurs in an estimated 95% of patients affected with sarcoidosis [65, 66]. Middle mediastinal nodes (at the left paratracheal level, subcarinal level, and level of the aortopulmonary window), prevascular nodes, or both are involved in approximately 50% of patients [60].

Bilateral hilar lymph node enlargement may be a feature of infection (particularly fungal or mycobacterial infection) or malignancy (eg, lymphoma). However, in the absence of specific symptoms or signs, sarcoidosis is the most common cause of bilateral lymph node enlargement. Histologic confirmation is not required for a diagnosis of sarcoidosis in these patients. However, a biopsy should be performed if the chest radiographic findings worsen or specific signs and symptoms develop [67].

- Typical Parenchymal Manifestations

1. Micronodules with a Perilymphatic Distribution

A perilymphatic distribution of micronodular lesions is the most common parenchymal disease pattern seen in patients with pulmonary sarcoidosis (75%–90% of cases). High-resolution CT shows sharply defined, small (2–4 mm in diameter), rounded nodules, usually with a bilateral and symmetric distribution, predominantly but not invariably in the upper and middle zones. The nodules are found most often in the subpleural peribronchovascular interstitium and less often in the interlobular septa. Although sarcoid granulomas arise as micronodular lesions, they may coalesce over time, forming larger lesions (macronodules) [56, 58, 63].

Sarcoid granulomas frequently cause nodular or irregular thickening of the peribronchovascular interstitium. Extensive peribronchovascular nodularity on high-resolution CT images is strongly suggestive of sarcoidosis. However, interstitial thickening is not extensive in most patients with sarcoidosis.

2. Fibrotic Changes

In most patients, sarcoid granulomas resolve with time. However, in an estimated 20% of patients, fibrosis becomes more prominent over time, producing CT and radiographic findings of linear opacities, traction bronchiectasis, and architectural distortion (displacement of fissures and bronchovascular bundles). Fibrosis is seen predominantly in the upper and middle zones, in a patchy distribution [41].

Extensive interstitial fibrosis can cause pulmonary arterial hypertension and resultant right heart failure. Imaging findings that may be predictive of such an event include a prominent main pulmonary artery, enlarged right and left pulmonary arteries, right ventricular enlargement, and attenuation of peripheral vessels.

3. Bilateral Perihilar Opacities

Confluent nodular opacities that appear on high-resolution CT images as bilateral areas of lung consolidation with irregular edges and blurred margins, radiating from the hilum toward

the periphery, are often seen with or without air bronchograms. These areas of consolidation are less homogeneous peripherally and are usually accompanied by micronodules [41, 60].

c. Positron emission tomography (PET):

A PET fluorine-18-fluorodeoxyglucose (18F-FDG) can help identify occult lesions and potentially reversible granulomatous disease [69, 70]. This test does not differentiate sarcoidosis from malignant lesions, as 18F-FDG PET can be positive in both processes. However, in a small study of 24 sarcoidosis and 17 lung cancer, the combination of 18F-FDG and 18F-FMT (L-[3-18F]-methyltyrosine) PET scanning was able to differentiate sarcoidosis cancer. Sarcoid lesions were positive in 18 F-FDG PET but negative on 18 F-FMT PET, and both were positive for cancer patients [71]. More studies are needed to confirm these findings. Besides the latter tracer may not be available in all centers.

d. Radiotracer scanning - Gallium-67 lung scanning:

Is a noninvasive test for staging the "alveolitis" found in interstitial lung diseases. This compound located the site of inflammation of the lung [72-74]. The role of gallium-67 scanning in the diagnosis and management of sarcoidosis is currently controversial [75]. It has been suggested that there is a direct relationship between a visual index of gallium-67 uptake in the lung and the number of inflammatory cells (particularly macrophages) obtained from bronchoalveolar lavage in patients with sarcoidosis (and idiopathic pulmonary fibrosis). As a result the uptake of gallium-67 may be useful to determine the degree of alveolar inflammation, which will focus more lower alveolar macrophages and neutrophils [72-74].

Unfortunately there has not been adequate study to make any correlation of the gallium-67 level with the stage of swelling or how the level of radionuclide uptake may correspond to the stage of disease. Furthermore, studies in normal subjects demonstrate that there may be a small but significant uptake of gallium-67 in alveolar macrophages obtained by bronchoalveolar lavage despite negative imaging test [76].

As a result, actually is not recommended for routine evaluation with gallium-67 lung scanning in these patients because of the difficulty of interpretation, since it is not specific, and that a negative test does not exclude the disease.

Other types of radiotracer-based scanning may help in future diagnosis and clinical management of patients with sarcoidosis [77, 78]. As an example, one study of 22 patients with sarcoidosis scans performed after administration of technetium-labeled Depreotide, which binds to somatostatin receptors [77]. The scan was positive in 18 patients (81%) and in 4 of whom was negative had a normal chest radiograph. The features of this test are still unknown, and clinical use is experimental.

3.2. Pulmonary function test

Characteristically, pulmonary function tests show a restrictive pattern with reduced diffusing capacity for carbon monoxide. Yet we must bear in mind that pulmonary function tests may be normal [79]. Endobronchial sarcoidosis may show involvement of airflow obstruction and respiratory pattern.

The greatest value of pulmonary function tests is to verify the course of the disease individually by sequential measurements. Mean it will not detect pulmonary sarcoidosis or provide a reliable estimate of the extent of parenchymal disease. In addition, the clinician can not predict the natural course of lung disease or response to treatment based solely on these tests.

3.3. Bronchoalveolar Lavage (BAL)

BAL can be used as an adjuvant as to support the diagnosis of sarcoidosis, showing a reduced number of CD8 cells, an elevated CD4/CD8 ratio and an increase in activated T cells, CD4, immunoglobulins, and IgG-secreting cells [80-83]. BAL may also be useful to exclude infections as an alternative diagnosis.

Lymphocytosis in BAL is neither sensitive nor specific for the diagnosis of sarcoidosis. In addition, this test can be misinterpreted [80].

The D-dimer in BAL also supports the diagnosis of sarcoidosis. An observational study found that 8 of the 10 patients with sarcoidosis had detectable D-dimer in the BAL (defined as D-dimer > 78ng) Compared to none of 18 healthy controls [82]. Among patients with sarcoidosis are more likely to have a higher D-dimer black patients than whites [83].

3.4. Histopathology

The morphological feature of sarcoidosis is the noncaseating granuloma of the lung, which is most often found in the alveolar septa, the walls of the bronchi and pulmonary arteries and veins. Sarcoid granuloma formation probably is preceded by alveolitis which involves more than the interstitium and alveolar spaces is characterized by the accumulation of inflammatory cells, including monocytes, macrophages and lymphocytes [84, 85].

The sarcoid granuloma is a chronic inflammatory reaction and focal accumulation formed by epithelial cells, monocytes, lymphocytes, macrophages and fibroblasts. Multinucleated giant cells are frequently found between epithelial cells in the follicle of the granuloma and often have cytoplasmic inclusions such as asteroid bodies, Schaumann bodies and birefringent crystalline particles (calcium oxalate and other calcium salts) [86]. Most sarcoid granulomas gradually resolved and leave little or no residual manifestation of prior inflammation.

3.5. Allocation pulmonary vs. extrapulmonary

Health status is a subjective parameter that is being used more frequently to assess health interventions. Questionnaires have been developed, both generic and disease-specific, to assess health status. Differences in patients reported outcomes between sarcoidosis patients with isolated pulmonary involvement and those with extrapulmonary manifestations have not been well described. In this way, Gvozdenovic et al. [68] develop a study to assess the differences of the severity of fatigue and dyspnea symptoms, activities of daily living and health status between the patients with isolated pulmonary and those with pulmonary plus extrapulmonary sarcoidosis. This study concluded that patients with pulmonary and extrapulmonary sarcoidosis are more fatigued, have more dyspnea, are more limited in their

everyday physical activities, and have lower health status in comparison with those with isolated pulmonary involvement. They proposed several mechanisms to explain these differences, although remained conjectural and are potential fruitful areas for future research.

4. Pulmonary hypertension complicating sarcoidosis

Pulmonary hypertension (PH) is defined as the presence of a mean pulmonary artery pressure (mPAP) ≥ 25 mm Hg [87]. Although in most cases sarcoidosis is a disease with good prognosis, the presence of PH is a serious complication that occurs in cases with severe pulmonary involvement, although there have been cases of PH in any stages of the disease. An early diagnosis that may consider different treatment options is critical to improve the prognosis of these patients.

The prevalence of pulmonary hypertension (SAPH) associated to sarcoidosis is unknown. Prospective and retrospective studies describe prevalence from 5 to 28% [88] (see Table 3). This variability is mainly due to the use of different diagnostic methods, non-homogeneous patient populations and stages of the disease included in those studies. It has been described that in patients with mild lung disease in which PH is defined as that PAP ≥ 40 mm Hg measured by transthoracic echocardiography (TTE), the prevalence is 5.7% [89].

Author/reference	Population	Number	Method	Prevalence (%)
Handa (89)	Prospective study of unselected patients	212	TTE	5.7
Baughmann (88)	Subjects with dyspnea out of proportion	53	RHC	47
Sulica (98)	Retrospective study of TTE	106	TTE	51

Table 3. Ascertained prevalence of Sarcoidosis-associated pulmonary hypertension in several populations

A retrospective study of 53 patients with sarcoidosis and persistent dyspnea showed that in 47% of them had a mPAP ≥ 25 mm Hg. Only 69% of these cases had stage 3-4 of sarcoidosis [90].

4.1. Pathophysiology

According to Dana Point classification [91] of pulmonary hypertension, the group 3 includes cases of PH due to lung disease or hypoxia (including interstitial lung disease). The group 5 includes the cases where PH has not a clarified mechanism; group 5 also includes sarcoidosis because the pathogenesis of SAPH is associated with complex mechanisms.

a. Destruction of the distal capillary bed

Most patients with sarcoidosis and PH are in advanced stages, presenting a significant alteration of lung parenchyma with destruction of the capillary bed and leading of hypoxemia. However, there are cases of SAPH with minimal lung disorder (Stages 0-1) and hemodynamic measurements detected in the right heart catheterization (RHC) are not always correlated

directly with lung function or PaO₂ [92]. When comparing cases of idiopathic pulmonary fibrosis and sarcoidosis there are differences in mPAP of 9 mm Hg for an equivalent functional alteration, so this mechanism does not explain the development of PH in all the patients.

b. Increased vasoreactivity

Few years ago was found that production of endothelin 1 (ET-1) in the lung of patients with sarcoidosis is increased [93]. The ET-1 is a potent vasoconstrictor with mitogenic and inflammatory activity and one of the therapeutic targets for the treatment of PH, using receptor antagonists of ET-1. The synthesis and release of nitric oxide (NO) by endothelial cells causes vasodilatation, the decreased of NO production has been associated with PH. Has been suggested that the decrease of NO, found in some studies of patient with sarcoidosis, may participate in the development of SAPH and that could have therapeutic implications [94].

c. Extrinsic compression of pulmonary vessels

There is extrinsic compression of major pulmonary arteries by adenopathies up to 21.4% of patients with SAPH and pulmonary fibrosis [95]. This alteration is often seen in cases with mediastinal and bilateral hilar adenopathies. Compression of the pulmonary vasculature can also be found in cases of mediastinal fibrosis.

d. Vasculopathy

Granulomatous involvement of the pulmonary vessel occurs in 69-100% of the cases studied by lung biopsy specimens. Exits occlusive or destructive granulomas or the patient may develop a perivascular fibrosis. These findings are more frequent in small veins [96].

e. Post-capillary pulmonary hypertension

We mustn't forget that myocardial involvement in sarcoidosis occurs in up to 5% of cases and cause ventricular systolic or diastolic failure which contribute to the development of PH [97]. However, the symptomatic myocardial abnormality is lower than that found in necropsy studies. We can conclude that the mechanisms involved in the development of PH in sarcoidosis are multiple, involving various anatomical structures and with different therapeutic implications.

4.2. Clinical presentation

The diagnosis of PH in sarcoidosis is difficult because the most common symptom is dyspnea, and many times, this symptom is attributed to the presence of parenchymal involvement. The PH should be suspected in patients with sarcoidosis and dyspnea, hypoxemia, or clinical evidence of the presence of right heart failure, particularly, if these symptoms have not a proportional relationship to the degree of parenchymal involvement. Symptoms of right heart failure are independent predictors of increased pressure in the right cavities. However, these symptoms have low sensitivity, and are only manifested in 21% of patients with confirmed PH. The symptoms are: progressive dyspnea, cough, chest pain, palpitations or syncope [98]. Table 4 shows the distribution of the symptoms.

Sudden death caused by compression of large pulmonary arteries, occlusion of the pulmonary veins by a sarcoid involvement intravascular or combination of SAPH and portal hypertension is infrequent.

Symptoms	Frequency %
<i>Dyspnea on exertion</i>	85
<i>Cough</i>	36
<i>Chest pain</i>	10
<i>Palpitations</i>	10
<i>Asymptomatic</i>	8

Table 4. Presenting symptoms in Sarcoidosis-associated pulmonary hypertension

4.3. Diagnosis

Patients with SAPH usually present with restrictive dysfunction on pulmonary function tests, and decrease in carbón monoxide diffusion capacity (DLCO) out of proportion to the decrease in total lung capacity (TLC). Forced vital capacity (FVC), forced expiratory volumen in 1 second (FEV1) and DLCO have been reported to be significantly lower in patients with Sarcoidosis and PH when compared with patients without PH [99]. La hipoxemia esta frecuentemente presente en los pacientes con SAPH siendo este grupo uno de los que con probabilidad va a requerir oxígeno suplementario y por otra parte recorren menos metros en el 6-minute walking test cuando se comparan con pacientes que tienen Sarcoidosis en el mismo estadio radiológico pero sin PH [99].

Transthoracic echocardiography (TTE) represents a noninvasive screening method to evaluate the presence of PH in sarcoidosis. It is helpful to describe other potential cardiac abnormalities, such as left heart disease, presence of shunts or pericardial effusion, and to evaluate the right heart anatomically and functionally. Echocardiography may be used to estimate the right ventricular systolic pressure (RVSP) if a tricuspid regurgitation jet is present. Echocardiographically estimated RVSP had inadequate positive and negative predictive value in diagnosing PH in advanced lung disease, so it's a screening test that cannot supplant right heart catheterization (RHC) for the SAPH diagnosis.

RHC is the diagnostic gold standard for SAPH. TTE was unable to detect RVSP in 30% of the patients and 24% of the patients with elevated PAP had a pulmonary capillary wedge pressure (PCWP) in excess of 20 mm Hg, underscoring the importance of left ventricular disease in the pathogenesis of PH in some Sarcoidosis patients. RHC should be performed in all cases in which SAPH is suspected or when echocardiography is suggestive of right heart pathology.

5. Cardiac sarcoidosis

5.1. Epidemiology

The presence of cardiac sarcoidosis is influenced by race. Over 25% of Japanese sarcoidosis patients present cardiac disease, only 5% of patients in the United States and Europe are affected at this level. Although clinical evidence of myocardial involvement is present in 5% of patients, there are autopsy studies that indicate that subclinical cardiac disease is present in 20-30% of cases.

5.2. Clinical manifestations

Cardiac Sarcoidosis can be an incidental finding, has a benign course or being a life-threatening disorder. Clinicians should suspect this disease in young or middle-aged patients with cardiac symptoms and in any patients with a history of sarcoidosis who develop arrhythmias, conduction disturbances or other cardiac symptoms.

Clinical manifestations depend on the location and extent of granulomatous infiltration, being the most common cause of cardiac involvement secondary to infiltration of the myocardium. Usually, cardiac disease appears with any other organ involvement (lung, skin...). The most frequent manifestations of cardiac sarcoidosis are heart failure and arrhythmias, produced in both cases, by the infiltration of the myocardium.

5.3. Cardiac arrhythmias

The most common are ventricular arrhythmias, caused by infiltration of granulomas in the ventricular myocardium causing a focus for abnormal automaticity, or a disruption of ventricular activation and recover [100]. In patients with cardiac sarcoidosis, ventricular arrhythmias and sudden death, due to ventricular tachycardia, are common causes of death. Ventricular tachycardia is one of the most common manifestations of cardiac involvement, being the 24-h ambulatory monitoring the best way to detect them. Supraventricular arrhythmias are infrequent.

5.4. Conduction abnormalities

Caused by the granulomatous infiltration at the atrioventricular node or bundle of His leading to a first degree heart block. Initially, patients are usually asymptomatic but they can progress to complete heart block [101]. This can be detected by routine electrocardiography.

5.5. Heart failure

Caused by extensive granulomatous infiltration of the myocardium. May cause impairment of systolic or diastolic function. Diagnostic is difficult and many patients with heart failure due to sarcoidosis disease are diagnostic of idiopathic dilated cardiomyopathy.

5.6. Other clinical manifestations

- a. *Valvular dysfunction*: The most frequent is the involvement of the mitral valve caused by diastolic dysfunction and left ventricular dilatation or granulomatous involvement of the papillary muscle [102]. Less common is the tricuspid valve dysfunction.
- b. Aorta aneurysm: Although are infrequent, has been described descending thoracic and abdominal aorta aneurysm [103].
- c. Cor pulmonale: May occur secondary to pulmonary fibrosis.

6. Gastrointestinal and liver sarcoidosis

6.1. Liver disease

Occurs in 13% of patients with systemic sarcoidosis [104]. Isolated liver involvement is infrequent. In most cases there are no symptoms but can appear hepatosplenomegaly, elevated liver enzymes, cholestasis or portal hypertension. In addition, 60% of patients with liver disease have fever and / or concomitant arthralgia [104].

Although in most cases the granulomas in the liver are small and are located in the portal space, symptoms consistent with chronic cholestasis [105] portal hypertension or Bud-Chiari syndrome can appear [106] Intrahepatic cholestasis can resemble primary biliary cirrhosis or sclerosing cholangitis.

Usually liver function is normal, but the most common abnormality is an elevation of alkaline phosphatase level.

6.2. Gastrointestinal involvement

Affects less than 1% of patients with sarcoidosis, being the stomach the most affected organ of the digestive tract. The symptoms of patients with gastric involvement are inespecific: epigastric pain, heartburn, abdominal discomfort, nausea or vomiting, diarrhea and significant weight loss.

Involvement of the intestine is very infrequent and can occasionally coexist with Crohn's disease [107].

7. Neurosarcoidosis

Neurosarcoidosis is the neurologic manifestation of sarcoidosis, a system granulomatous disease. The most affected organ is the lung, but it can also affect eyes, liver and nervous system. It affects the 5-15% of patients with sarcoidosis. It can be manifested by a wide variety of symptoms: peripheral neuropathy, central symptoms, loss of memory and behavior changes. Psiquiatric manifestations include, but not exclusively, psychosis and delirium, with

20% prevalence in patients with neurosarcoidosis or 1% in those affected with sarcoidosis. The prevalence of neurosarcoidosis is similar to schizophrenia, between 0,50-1,46% of general population. Thus, a study shows that 2 of each 268 patients with a first schizophrenia episode, they had neurosarcoidosis.

Neurologic complications occur in approximately 5 percent of patients with sarcoidosis [108-112]. Neurosarcoidosis is a diagnostic consideration in patients with known sarcoidosis who develop neurologic complaints and in patients presenting de novo with a constellation of findings consistent with the disease [113, 114]. About 50 percent of patients with neurosarcoidosis present with neurologic difficulties at the time of the diagnosis. One-third of those with neurosarcoidosis has or develops more than one neurologic manifestation of their disease.

7.1. Clinical presentation

Any portion of the central or peripheral nervous system can be affected by sarcoidosis. Neuropsychiatric: seizures, amnesia, psychosis and disorientation. Cranial mononeuropathy. Peripheral facial nerve palsy develops in 25 to 50 percent of patients with neurosarcoidosis [111, 114, 115]. The facial nerve palsy can be unilateral or bilateral (simultaneous or sequential) and recurrent. Optic neuropathy and cranial nerve VIII dysfunction can lead to intermittent or progressive visual, auditory, or vestibular dysfunction. Neuroendocrine dysfunction typically occurs with hypothalamic inflammation, resulting in polyuria or disturbances in thirst, sleep, appetite, temperature, or libido. Hypothalamic or pituitary lesions may also cause thyroid, gonadal, or adrenal abnormalities [115, 117]. Polyuria can result from one or more factors in patients with sarcoidosis. Direct hypothalamic involvement can lead to central diabetes insipidus or primary polydipsia, while hyperkalemia (due to production of calcitriol by activated macrophages) can cause nephrogenic diabetes insipidus [117]. Thus, all patients with sarcoidosis and polyuria require a water restriction test to establish the correct diagnosis. Granulomatous inflammation in a perivascular distribution can involve the brain and produce partial or generalized seizures, or a restricted or generalized encephalopathy/vasculopathy [114, 115]. Patients can present with cognitive or behavioral problems and/or focal neurologic deficits referable to the anatomic area involved. In rare cases, this manifests as a focal cerebral infarction [118]. A myelopathy or radiculopathy can occur if granulomatous inflammation affects the spinal cord [114, 115, 119, 120]. The lesions are typically perivascular, they can be extra medullary or intramedullary, and can involve the caudal equine. Communicating or non communicating hydrocephalus may develop acutely or subacutely. Asymptomatic ventricular enlargement may be incidentally detected by imaging studies. Sudden death can rarely result from acute obstruction to CSF flow. Meningeal involvement can take the form of either acute aseptic meningitis or chronic meningitis. Meningeal mass lesions also can develop. Peripheral neuropathic presentations include a mononeuropathy, mononeuritis multiplex, and generalized sensory, small fiber sensory, sensorimotor, autonomic and motor polyneuropathies [122]. The symptoms can be acute, subacute, or chronic; electromyography usually reveals an axonal neuropathy. In addition, an acute generalized demyelinating motor neuropathy similar to the Guillain-Barré syndrome also has been described [123]. Carpal tunnel syndrome appears to be more common among patients with sarcoidosis than the general population [124-126].

Muscle involvement includes asymptomatic microscopic nodules, isolated palpable nodules, an acute or chronic proximal myopathy, and muscle atrophy [127].

In some series of patients affected with intracranial hypertension syndrome, whose manifestation is headache, the diagnosis is neurosarcoidosis. It is uncommon, however, it must be included in differential diagnosis [109].

Patients presenting with neurosarcoidosis may have no systemic features of the disease. In one case series, non-neurologic symptoms were present in less than one-fourth of patients and were most commonly anterior uveitis, cough and dyspnea, renal impairment, rash, and polyarthritis [114].

7.2. Diagnosis

Neurosarcoidosis is a diagnostic consideration in patients with known sarcoidosis who develop neurologic findings, although an intercurrent infection or malignancy must be excluded. Patients who develop a neurologic illness consistent with neurosarcoidosis but are not known to have sarcoidosis present a diagnostic challenge. Table 5 summarizes findings in patients with Neurosarcoidosis.

Findings in patients with Neurosarcoidosis	Frequency (%)
Findings in Chest Rx	24-68%
Cranial mononeuropathy	25-50%
MRI meningeal enhancement	40%
Psychiatric symptoms	20%
Findings in Cerebrospinal fluid	Frequency (%)
Elevated total protein	66%
Pleocytosis	50%
Elevated opening pressure	10%

Table 5. Findings in patients with Neurosarcoidosis

a. Clinical evaluation:

If neurosarcoidosis is suspected, the patient should be evaluated for evidence of extra neural disease because obtaining nerve tissue for diagnostic evaluation is often difficult. Corticosteroids can eliminate evidence of systemic inflammation, and the diagnostic evaluation should be pursued in a rapid fashion while withholding immunosuppressive therapy unless severe illness mandates its use.

The search for extra neural sarcoidosis should include a thorough evaluation of the skin, lymph nodes, and lungs. Other tests that may be useful are:

1. Ophthalmologic examination
2. Endoscopic nasal and sinus examination. A chest x-ray or computed tomographic scan of the chest to look for hilar adenopathy or parenchymal changes consistent with pulmonary sarcoidosis. Positive findings suggestive of sarcoidosis on chest imaging have been reported in 24 to 68 percent of individuals who present with neurologic sarcoidosis [114, 115].
3. Serum angiotensin converting enzyme (ACE) assay, which may be helpful if elevated; however, an elevated serum ACE is not specific for sarcoidosis, and the ACE concentration may not necessarily be elevated if the patient has isolated neurosarcoidosis
4. In occasional cases, a magnetic resonance, gallium, or fluorodeoxyglucose positron emission tomographic scan, may highlight otherwise occult areas of inflammation that might be amenable to biopsy

b. Neurodiagnostic testing:

Neurologic evaluation should proceed if no extra neural tissue is available for biopsy. Unfortunately, no neurodiagnostic tests are pathognomonic for neurosarcoidosis. However, neurodiagnostic tests help define the extent of disease and eliminate other diagnostic considerations, particularly infection and malignancy. Furthermore, a presumptive diagnosis of neurosarcoidosis is often made on the basis of MRI and lumbar puncture results in the appropriate clinical setting [128].

c. Neuroimaging:

The imaging procedure of choice for CNS disease is contrast-enhanced MRI [115, 116, 129]. Meningeal or parenchymal enhancement suggests active inflammation with disruption of the blood brain barrier, and parenchymal or meningeal masses and hydrocephalus are easily identified. Involvement of the optic nerve or other cranial nerves can be documented, and spinal cord and cauda equine inflammation is well seen on targeted images. Multiple parenchymal nodules may actually represent inflammation extending along the Virchow-Robin spaces deep into the brain or spinal cord. In one series of 29 patients with neurosarcoidosis, approximately 40 percent demonstrated meningeal enhancement and/or multiple white matter lesions on MRI [128].

d. Lumbar puncture:

Cerebrospinal fluid (CSF) abnormalities occur frequently in patients with CNS sarcoidosis [114, 115]: The CSF opening pressure is elevated in approximately 10 percent of patients, and the total protein is increased in two-thirds of patients, typically up to 250 mg/dL. A pleocytosis is present in approximately 50 percent of patients. Glucose can be normal or low, as can be seen in CNS infections or carcinomatous meningitis. A predominantly mononuclear cell pleocytosis is common. The IgG index can be elevated, and oligoclonal bands may be present.

The CSF ACE concentration is occasionally elevated, but reliable normal values are lacking and CSF ACE may also be increased with infection or carcinomatous meningitis.

Caution should be applied in performing a LP in patients with neurosarcoidosis if there is evidence of increased intracranial pressure. A fundoscopic examination to exclude papilledema and an MRI to exclude ventricular enlargement, cerebral edema, and a mass lesion should precede LP [130].

e. Other tests:

Other diagnostic tests, such as electroencephalography, evoked potentials, and angiography, are occasionally indicated to exclude other conditions. Nerve conduction studies (NCS) and electromyography (EMG) can help localize neuromuscular lesions, depending on the clinical syndrome.

Although false-positive reactions to the Kveim-Siltzbach test are reported to be rare; the test has limited utility [114]. The test is not standardized; it is not universally available; and there are concerns regarding the transmission of HIV and hepatitis.

f. Biopsy:

If the diagnosis remains in doubt, meningeal, brain, or spinal cord biopsy is occasionally indicated. Extra neural tissue biopsy from other clinically affected organs is generally preferable when possible, as it is less risky; skin, lymph node, and lung (trans bronchial) biopsies can be of high yield [114, 115]. Muscle and peripheral nerve biopsy, including an epidermal biopsy with quantitative nerve terminal analysis to document small fiber sensory neuropathy, can all be easily performed for the appropriate syndrome.

8. Cutaneous manifestations of sarcoidosis

Cutaneous lesions of sarcoidosis may present with variety of morphologies [131]. Although not life-threatening, the unsightly skin lesions of sarcoidosis can be emotionally devastating [132]. Given the wide variability of clinical manifestations, it is one of the "great imitators," making it necessary to consider clinical, epidemiological, radiographic, laboratory, and histopathological criteria to make the diagnosis [133]

Skin involvement is common (occurring in 25 to 35 % of patients with sarcoidosis). Cutaneous manifestation of sarcoidosis could be one of the two following: specific lesions, which demonstrate granuloma on biopsy; and nonspecific lesions that do not have granulomas but are inflammatory reactions [134].

Specific lesions are estimated to occur in 9 to 15 percent of patients with sarcoidosis. Although their histopathologic features are similar, the clinical manifestations of specific lesions vary widely [135]. Papules, nodules, plaques, and infiltrated scars are among the most common presentations; other manifestations also occur.

8.1. Specific eruptions

a. Papular sarcoidosis

Papular sarcoidosis is a common specific cutaneous manifestation of sarcoidosis. Papular sarcoidosis most frequently occurs on the face, with predilection for the eyelids and nasolabial

folds. Upon resolution, faintly discolored, occasionally atrophic macules may remain at previous sites of involvement [135, 136].

b. Nodular sarcoidosis

Nodular sarcoidosis is a relatively common form of cutaneous sarcoidosis that results from large collections of sarcoidal granulomas in the dermis or subcutaneous tissue [135]. Nodules tend to be between 1 and 2 cm in diameter and may be single or multiple. On the nose, nodular sarcoidosis can resemble rhinophyma [135, 137]-

c. Maculopapular sarcoidosis

Characteristically, lesions are asymptomatic or pruritic, and consist of slightly infiltrated, slightly hyperpigmented patches studded with slightly raised papules that are often around 1 mm in diameter [136]. Facial skin, especially the periorifial or eyelid area, is the most common site of involvement.

d. Plaque sarcoidosis

Presents with oval or annular, indurated, discrete plaques that are flesh – colored, erythematous, or brown. Frequent site of involvement include the shoulders and arms, back, and buttocks [131].

e. Lupus pernio

Lupus pernio is characterized by violaceous or erythematous indured papules, plaques, or nodules that are primarily distributed on the central face [138]. The alar rim of the nose is often affected. Lupus pernio is more common in women than in men and is associated with chronic disease and extrapulmonary involvement [138, 139]. Without treatment, the lesions progressively increase in thickness, size, and induration, eventually resulting in considerable cosmetic disfigurement.

The presence of lupus pernio appears to be associated with an increased risk for extra cutaneous disease, particularly sarcoidosis involving the respiratory tract [140]. When severe, granulomatous inflammation of the upper respiratory tract can result in airway obstruction [141].

8.2. Non-Specific eruptions

a. Erythema nodosum

Erythema nodosum develops in up to 25 percent of patients with sarcoidosis and is clinically and histologically identical to erythema nodosum secondary to other causes. García Porrúa et al in Spanish study of 106 biopsy proven cases of erythema nodosum, 20 percent of patients had sarcoidosis [142]. Arthritis, lower extremity edema, and low grade fever are the most common systemic symptoms associated with erythema nodosum.

The clinical feature of subcutaneous sarcoidosis can resemble erythema nodosum. Biopsy is useful for distinguishing between these disorders. Biopsy specimens of erythema nodosum

lesions show nonspecific septal panniculitis, which neither confirms nor negates the diagnosis of sarcoidosis [143].

b. Löfgren's syndrome

Löfgren's syndrome is an acute presentation of sarcoidosis characterized by the triad of hilar adenopathy, erythema nodosum, and polyarthralgia or arthritis, with or without parenchymal infiltrates or fever [132, 144]. The presence of bilateral hilar adenopathy and erythema nodosum is usually, but not always, caused by acute sarcoidosis. More recently, the definition has been expanded to include patients with hilar adenopathy and periarticular inflammation with or without erythema nodosum [145].

8.3. Management of cutaneous sarcoidosis

a. First line agents:

Formal studies of local therapies for cutaneous sarcoidosis are limited, and the widespread use of topical and intralesional corticosteroids for this disease primarily are based upon clinical experience.

Topical corticosteroids: Superpotent topical corticosteroids are widely used for the treatment of cutaneous sarcoidosis: Clobetasol, halobetasol.

Intralesional Corticosteroids: Generally accepted that intralesional injection of corticosteroids can lead to flattening or resolution of cutaneous lesions: Triamcinolone

b. Second line agents

Systematic glucocorticoids (prednisone 20 to 40 mg/day)

Antimalarials: Hydroxychloroquine and chloroquine.

Methotrexate (10 to 25mg/week)

c. Refractory disease:

Patients who fail to respond to conventional first – and second – line therapies may benefit from treatment with infliximab or thalidomide.

9. Sarcoid arthropathy

Arthritis is the most common musculoskeletal manifestation in sarcoidosis [146]. Approximately 25 percent of patients with sarcoidosis have an associated arthropathy [147]. Real incidence is unclear since the diagnosis may be difficult when a patient presents with articular complaints alone; in this setting, the presence of sarcoidosis is established only after more commonly involved organs, such as the eye or lung, become affected [148].

9.1. Acute arthritis

Acute sarcoid arthritis may present in isolation or as part of Löfgren's syndrome (association of arthritis, erythema nodosum and bilateral hilar lymphadenopathy). Joint effusion is discrete [149]. Rheumatoid factor and ANA may be positive, as in the general sarcoidosis [146]. The acute polyarthritis most commonly involves ankles (>90 percent), often bilaterally, followed by other larger joints of lower extremity and may be mistaken for a reactive arthritis. The arthritis is mostly oligoarticular (87%), and involvement is typically symmetrical (76%). Glennas et al, in a prospective study of 189 patients presenting with symptoms suggestive of reactive arthritis, 17 (9%) were eventually diagnosed with acute sarcoid arthritis. Ten had Löfgren's syndrome, and 17 had bilateral ankle involvement [150].

Löfgren's syndrome: The triad of hilar adenopathy, acute polyarthritis and erythema nodosum characterizes Löfgren's syndrome. Löfgren's syndrome is usually self-limiting. Erythema nodosum typically disappears in a few months [144]. Approximately one third of patients have persistent arthritis; rarely, the arthritis symptoms are recurrent. Hilar adenopathy tends to resolve over time up to 90 percent of patients. Erythema nodosum is more often seen in female compared with male patients presenting with Löfgren's syndrome [142].

Sarcoid arthritis can resemble rheumatic fever when the polyarthritis is migratory. It may resemble patients with juvenile idiopathic arthritis in young children presenting with both uveitis and arthritis [151].

9.2. Chronic arthritis

Patients presenting with chronic arthritis are typically older than patients with acute arthritis or Löfgren's syndrome [144]. The ankle, knees, hands, wrist, metacarpophalangeal and proximal interphalangeal joint are the joints most frequently involved; rarely, the sacroiliac and temporomandibular joints may also be affected [144]. Chronic arthritis is frequently associated with parenchymal lung disease and other extrapulmonary manifestations [144].

The correlation between extremely high serum of angiotensin converting enzyme levels and extrathoracic sarcoidosis, including chronic arthritis, probably reflects the high total body load of granulomas.

9.3. Diagnosis

Diagnosis of sarcoid arthropathy is based upon suggestive clinical, imaging, synovial fluid, and, in selected cases, synovial tissue biopsy. Classic Löfgren's syndrome can be diagnosed based upon clinical features alone [132].

9.4. Treatment

Sarcoid arthritis should be treated with nonsteroidal antiinflammatory agents. Corticosteroids and other immunosuppressive drugs as colchicine and hydroxychloroquine should be reserved for refractory cases. Biological therapies such as the anti-TNF α and the anti-CD20 were showed to be effective in some case reports of severe and refractory disease [152].

10. Ocular manifestations in sarcoidosis

The eye or adnexa are affected in 25 to 80% of the sarcoidosis patients. The disease can involve the orbit, lacrimal gland, anterior and posterior segments of the eye [153].

The disease can involve the orbit, lacrimal gland, anterior and posterior segments of the eye. Anterior uveitis is the most common manifestation, occurring in 65% of patients with ophthalmologic involvement [132]. Inflammation can affect the uveal tract leading to glaucoma, cataracts, and blindness. Typical sarcoid uveitis presents with bilateral mutton-fat keratic precipitates, cells, flare, iris nodules, anterior and posterior synechia, and increased ocular pressure. Posterior involvement includes vitreitis, vasculitis, choroidal lesions, and optic neuropathy. Long-term complications are common, and cystoid macular edema is the most important and sight-threatening consequence [153]. Acute uveitis presents with eye redness, cloudy vision, photophobia, and watering or can present asymptotically (with a "quiet eye").

The gold standard for the diagnosis of sarcoidosis should be obtained with histologic examination. However, an international workshop has recently established diagnostic criteria of "intraocular sarcoidosis" (sarcoidosis uveitis) on the basis of a combination of suggestive ophthalmological findings and laboratory tests, when biopsy is not performed or is negative. More recent techniques such as PET-scan and endoscopic ultrasound-guided fine-needle biopsy of intrathoracic nodes should be assessed in future prospective studies [154].

Chronic anterior uveitis, with insidious symptoms leading to glaucoma and vision loss, is more common than acute anterior uveitis. In about 10 to 15% of patients with uveitis, both the anterior and posterior segments are involved.

Lacrimal gland enlargement can cause dry eyes. Conjunctival follicles, dacryocystitis, keratoconjunctivitis sicca, and retinal vasculitis also occur. Optic neuritis is an ophthalmologic emergency that requires immediate systemic therapy as it can result in a rapid permanent loss of vision.

Papillitis, papilledema, and neovascularization are seen under funduscopic examination leading to optic atrophy. Other less common manifestations include periphlebitis retinae, retinal hemorrhage, retinitis proliferans, band keratopathy, proptosis, and exophthalmos [155, 156].

Routine evaluation for eye involvement should include a slit-lamp examination and funduscopic examination to evaluate the anterior and posterior uveal tract, respectively [132]. Fluorescence angiography may also be considered if a posterior uveitis is suspected [156].

Oral corticosteroids are the mainstay of treatment of sarcoidosis. Systemic cytotoxic agents like methotrexate, azathioprine, and chlorambucil may be used in refractory cases. The visual prognosis of sarcoidosis is usually good [153].

Patients should be warned that skin atrophy could occur if steroids come into contact with skin surfaces. Intraocular corticosteroid injections can provide the patient with longer control

of symptoms. Systemic steroids can be used if uveitis does not resolve with topical therapy or for cases where vision loss is possible. Alternative agents include tacrolimus, methotrexate, and photodynamic therapy [157].

Minocycline may be an option for patients with comorbidities that make steroids a less appealing option [158].

Interferon-alpha is commonly used to treat hepatitis C viral infection and has been reported to induce sarcoidosis and more recently ocular sarcoidosis with granulomatous panuveitis with choroidal granulomas.

In these cases topical steroids were used to treat ocular uveitis with systemic steroids for systemic findings.

Author details

Luis Jara-Palomares, Candela Caballero-Eraso, Cesar Gutiérrez, Alvaro Donate and Jose Antonio Rodríguez-Portal

*Address all correspondence to: luisoneumo@hotmail.com

Pneumologist, Medical-Surgical Unit of Respiratory Diseases. University Hospital Virgen del Rocío. Seville, Spain

References

- [1] Polychronopoulos VS, Prakash UB. Airway involvement in sarcoidosis. *Chest* 2009; 136:1371.
- [2] James JC, Simpson CB. Treatment of laryngeal sarcoidosis with CO₂ laser and mitomycin-C. *Otolaryngol Head Neck Surg* 2004; 130:262.
- [3] Fouty BW, Pomeranz M, Thigpen TP, Martin RJ. Dilatation of bronchial stenoses due to sarcoidosis using a flexible fiberoptic bronchoscope. *Chest* 1994; 106:677.
- [4] Baughman RP, Lower EE, Tami T. Upper airway. 4: Sarcoidosis of the upper respiratory tract (SURT). *Thorax* 2010; 65:181.
- [5] Reed J, deShazo RD, Houle TT, et al. Clinical features of sarcoid rhinosinusitis. *Am J Med* 2010; 123:856.
- [6] Aubart FC, Ouayoun M, Brauner M, et al. Sinonasal involvement in sarcoidosis: a case-control study of 20 patients. *Medicine (Baltimore)* 2006; 85:365.
- [7] Hunninghake GW, Costabel U, Ando M, et al. ATS/ERS/WASOG statement on sarcoidosis: American Thoracic Society/European Respiratory Society/World Associa-

- tion of Sarcoidosis and other Granulomatous Disorders. *Sarcoidosis Vasc Diffuse Lung Dis* 1999; 16:149–173
- [8] Rottoli P, Bargagli E, Chidichimo C, et al. Sarcoidosis with upper respiratory tract involvement. *Respir Med* 2006; 100:253–257
- [9] Rizzato G, Palmieri G, Agrati AM, et al. The organ-specific extrapulmonary presentation of sarcoidosis: a frequent occurrence but a challenge to an early diagnosis; a 3-year-long prospective observational study. *Sarcoidosis Vasc Diffuse Lung Dis* 2004; 21:119–126
- [10] Baughman RP, Teirstein AS, Judson MA, et al. Clinical characteristics of patients in a case control study of sarcoidosis. *Am J Respir Crit Care Med* 2001; 164:1885–1889
- [11] Fouty BW, Pomeranz M, Thigpen TP, Martin RJ. Dilatation of bronchial stenoses due to sarcoidosis using a flexible fiberoptic bronchoscope. *Chest* 1994; 106:677.
- [12] Long CM, Smith TL, Loehrl TA, et al. Sinonasal disease in patients with sarcoidosis. *Am J Rhinol* 2001; 15:211
- [13] Black JI. Sarcoidosis of the nose. *J Laryngol Otol* 1966; 80:1065–1068
- [14] Braun JJ, Imperiale A, Schultz P, et al. Pharyngolaryngeal sarcoidosis: report of 12 cases. *Otolaryngol Head Neck Surg* 2008; 139:463–465
- [15] Davis C, Girzadas DV Jr. Laryngeal sarcoidosis causing acute upper airway obstruction. *Am J Emerg Med* 2008; 26:e111–e113
- [16] Becker GL, Tenholder MF, Hunt KK. Obligate mouth breathing during exercise: nasal and laryngeal sarcoidosis. *Chest* 1990; 98:756–757
- [17] Carasso B. Sarcoidosis of the larynx causing airway obstruction. *Chest* 1974; 65:693–695
- [18] Turner GA, Lower EE, Corser BC, et al. Sleep apnea in sarcoidosis. *Sarcoidosis Vasc Diffuse Lung Dis* 1997; 14: 61–64
- [19] Roger G, Gallas D, Tashjian G, et al. Sarcoidosis of the upper respiratory tract in children. *Int J Pediatr Otorhinolaryngol* 1994; 30:233–240
- [20] Bower JS, Belen JE, Weg JG, et al. Manifestations and treatment of laryngeal sarcoidosis. *Am Rev Respir Dis* 1980; 122:325–332
- [21] Israel HL, Sones M. Sarcoidosis: clinical observation on one hundred sixty cases. *AMA Arch Intern Med* 1958; 102:766–776
- [22] Gerencer RZ, Keohane JD Jr, Russell L. Laryngeal sarcoidosis with airway obstruction. *J Otolaryngol* 1998; 27:90–93.
- [23] Fogel TD, Weissberg JB, Dobular K, et al. Radiotherapy in sarcoidosis of the larynx: case report and review of the literature. *Laryngoscope* 1984; 94:1223–1225

- [24] Chijimatsu Y, Tajima J, Washizaki M, et al. Hoarseness as an initial manifestation of sarcoidosis. *Chest* 1980; 78:779–781
- [25] Jaffe R, Bogomolski-Yahalom V, Kramer MR. Vocal cord paralysis as the presenting symptom of sarcoidosis. *Respir Med* 1994; 88:633–636.
- [26] Brandstetter RD, Messina MS, Sprince NL, et al. Tracheal stenosis due to sarcoidosis. *Chest* 1981; 80:656
- [27] Miller A, Brown LK, Teirstein AS. Stenosis of main bronchi mimicking fixed upper airway obstruction in sarcoidosis. *Chest* 1985; 88:244–248
- [28] Harrison BD, Shaylor JM, Stokes TC, et al. Airflow limitation in sarcoidosis: a study of pulmonary function in 107 patients with newly diagnosed disease. *Respir Med* 1991; 85:59–64
- [29] Murray ME, Stokes TC. Endobronchial sarcoidosis presenting as severe upper airways narrowing with normal chest radiograph. *Respir Med* 1991; 85:425–426
- [30] Mendelson DS, Norton K, Cohen BA, et al. Bronchial compression: an unusual manifestation of sarcoidosis. *J Comput Assist Tomogr* 1983; 7:892–894
- [31] Armstrong JR, Radke JR, Kvale PA, et al. Endoscopic findings in sarcoidosis: characteristics and correlations with radiographic staging and bronchial mucosal biopsy yield. *Ann Otol Rhinol Laryngol* 1981; 90:339–343
- [32] Yamada G, Aketa K, Takahashi H, et al. Endobronchial lesions of sarcoidosis. *Intern Med* 2005; 44:909–910
- [33] Olsson T, Bjornstad-Pettersen H, Stjernberg NL. Bronchostenosis due to sarcoidosis: a cause of atelectasis and airway obstruction simulating pulmonary neoplasm and chronic obstructive pulmonary disease. *Chest* 1979; 75:663–666
- [34] Westcott JL, Noehren TH. Bronchial stenosis in chronic sarcoidosis. *Chest* 1973; 63:893–897
- [35] Corsello BF, Lohaus GH, Funahashi A. Endobronchial mass lesion due to sarcoidosis: complete resolution with corticosteroids. *Thorax* 1983; 38:157–158
- [36] Chapman A, Rgyropoulou PK, Patakas DA, Louridas GE. Airway function in stage I and stage II pulmonary sarcoidosis. *Respiration* 1984; 46:17–25
- [37] Dutton RE, Renzi PM, Lopez-Majano V, et al. Airway function in sarcoidosis: smokers versus nonsmokers. *Respiration* 1982; 43:164–173
- [38] Rodriguez E, Lopez D, Buges J, et al. Sarcoidosis-associated bronchiolitis obliterans organizing pneumonia. *Arch Intern Med* 2001; 161:2148–2149
- [39] Carbonelli C, Roggeri A, Cavazza A, et al. Relapsing bronchiolitis obliterans organizing pneumonia and chronic sarcoidosis in an atopic asthmatic patient. *Monaldi Arch Chest Dis* 2008; 69:39–42

- [40] Akira M, Kozuka T, Inoue Y, et al. Long-term follow-up CT scan evaluation in patients with pulmonary sarcoidosis. *Chest* 2005; 127:185–191.
- [41] Abehsera M, Valeyre D, Grenier P, et al. Sarcoidosis with pulmonary fibrosis: CT patterns and correlation with pulmonary function. *AJR Am J Roentgenol* 2000; 174:1751–1757
- [42] Rockoff SD, Rohatgi PK. Unusual manifestations of thoracic sarcoidosis. *AJR Am J Roentgenol* 1985; 144:513–528
- [43] Lewis MM, Mortelliti MP, Yeager H Jr, et al. Clinical bronchiectasis complicating pulmonary sarcoidosis: case series of seven patients. *Sarcoidosis Vasc Diffuse Lung Dis* 2002; 19:154–159
- [44] Rubinstein I, Baum GL, Hiss Y, et al. Hemoptysis in sarcoidosis. *Eur J Respir Dis* 1985; 66:302–305
- [45] Rubinstein I, Solomon A, Baum GL, et al. Pulmonary sarcoidosis presenting with unusual roentgenographic manifestations. *Eur J Respir Dis* 1985; 67:335–340
- [46] Wollschlager C, Khan F. Aspergillomas complicating sarcoidosis: a prospective study in 100 patients. *Chest* 1984; 86:585–588
- [47] Marcias S, Ledda MA, Perra R, et al. Aspecific bronchial hyperreactivity in pulmonary sarcoidosis. *Sarcoidosis* 1994; 11:118–122
- [48] Shorr AF, Torrington KG, Hnatiuk OW. Endobronchial involvement and airway hyperreactivity in patients with sarcoidosis. *Chest* 2001; 120:881–886
- [49] Chapman JT, Mehta AC. Bronchoscopy in sarcoidosis: diagnostic and therapeutic interventions. *Curr Opin Pulm Med* 2003; 9:402–407
- [50] Mihailovic -Vucinic V, Jovanovic D. Pulmonary sarcoidosis. *Clin Chest Med* 2008; 29:459–473
- [51] Judson MA. The diagnosis of sarcoidosis. *Clin Chest Med* 2008; 29:415–427 fsd
- [52] Chevalet P, Clément R, Rodat O, et al. Sarcoidosis diagnosed in elderly subjects: retrospective study of 30 cases. *Chest* 2004; 126:1423.
- [53] Soskel NT, Sharma OP. Pleural involvement in sarcoidosis. *Curr Opin Pulm Med* 2000; 6:455.
- [54] Navaneethan SD, Venkatesh S, Shrivastava R, et al. Recurrent pleural and pericardial effusions due to sarcoidosis. *PLoS Med* 2005; 2:e63.
- [55] Huggins JT, Doelken P, Sahn SA, et al. Pleural effusions in a series of 181 outpatients with sarcoidosis. *Chest* 2006; 129:1599.
- [56] Koyama T, Ueda H, Togashi K, et al. Radiologic manifestations of sarcoidosis in various organs. *Radiographics* 2004; 24:87.

- [57] Hours S, Nunes H, Kambouchner M, et al. Pulmonary cavitary sarcoidosis: clinico-radiologic characteristics and natural history of a rare form of sarcoidosis. *Medicine (Baltimore)* 2008; 87:142.
- [58] Müller NL, Kullnig P, Miller RR. The CT findings of pulmonary sarcoidosis: analysis of 25 patients. *AJR Am J Roentgenol* 1989; 152:1179-1182.
- [59] Müller NL, Mawson JB, Mathieson JR, et al. Sarcoidosis: correlation of extent of disease at CT with clinical, functional, and radiographic findings. *Radiology* 1989; 171:613.
- [60] Brauner MW, Grenier P, Mompoin D, Lenoir S, de Crémoux H. Pulmonary sarcoidosis: evaluation with high-resolution CT. *Radiology* 1989;172(2): 467–471.
- [61] Müller NL, Miller RR. Ground-glass attenuation, nodules, alveolitis, and sarcoid granulomas. *Radiology* 1993;189(1):31–32.
- [62] Baughman RP, Winget DB, Bowen EH, Lower EE. Predicting respiratory failure in sarcoidosis patients. *Sarcoidosis Vasc Diffuse Lung Dis* 1997;14(2): 154–158.
- [63] Hamper UM, Fishman EK, Khouri NF, Johns CJ, Wang KP, Siegelman SS. Typical and atypical CT manifestations of pulmonary sarcoidosis. *J Comput Assist Tomogr* 1986;10(6):928–936.
- [64] Criado E, Sánchez M, Ramírez J, Arguis P, de Caralt TM, Perea RJ, Xaubet A. Pulmonary sarcoidosis: typical and atypical manifestations at high-resolution CT with pathologic correlation. *Radiographics*. 2010 Oct;30(6):1567-86. Review.
- [65] Henke CE, Henke G, Elveback LR, Beard CM, Ballard DJ, Kurland LT. The epidemiology of sarcoidosis in Rochester, Minnesota: a population-based study of incidence and survival. *Am J Epidemiol* 1986;123(5):840–845.
- [66] Lynch JP 3rd, Kazerooni EA, Gay SE. Pulmonary sarcoidosis. *Clin Chest Med* 1997;18(4):755–785.
- [67] Winterbauer RH, Belic N, Moores KD. Clinical interpretation of bilateral hilar adenopathy. *Ann Intern Med* 1973;78(1):65–71.
- [68] Gvozdenovic BS, Mihailovic-Vucinic V, Ilic-Dudvarski A, Zugic V, Judson MA. Differences in symptom severity and health status impairment between patients with pulmonary and pulmonary plus extrapulmonary sarcoidosis. *Respir Med*. 2008 Nov; 102(11):1636-42.
- [69] Teirstein AS, Machac J, Almeida O, et al. Results of 188 whole-body fluorodeoxyglucose positron emission tomography scans in 137 patients with sarcoidosis. *Chest* 2007; 132:1949.
- [70] de Prost N, Kerrou K, Sibony M, et al. Fluorine-18 fluorodeoxyglucose with positron emission tomography revealed bone marrow involvement in sarcoidosis patients with anaemia. *Respiration* 2010; 79:25.

- [71] Kaira K, Oriuchi N, Otani Y, et al. Diagnostic usefulness of fluorine-18-alpha-methyl-tyrosine positron emission tomography in combination with 18F-fluorodeoxyglucose in sarcoidosis patients. *Chest* 2007; 131:1019.
- [72] Line BR, Hunninghake GW, Keogh BA, et al. Gallium-67 scanning to stage the alveolitis of sarcoidosis: correlation with clinical studies, pulmonary function studies, and bronchoalveolar lavage. *Am Rev Respir Dis* 1981; 123:440.
- [73] Schoenberger CI, Line BR, Keogh BA, et al. Lung inflammation in sarcoidosis: comparison of serum angiotensin-converting enzyme levels with bronchoalveolar lavage and gallium-67 scanning assessment of the T lymphocyte alveolitis. *Thorax* 1982; 37:19.
- [74] Beaumont D, Herry JY, Sapene M, et al. Gallium-67 in the evaluation of sarcoidosis: correlations with serum angiotensin-converting enzyme and bronchoalveolar lavage. *Thorax* 1982; 37:11.
- [75] Baughman RP, Shipley R, Eisentrout CE. Predictive value of gallium scan, angiotensin-converting enzyme level, and bronchoalveolar lavage in two-year follow-up of pulmonary sarcoidosis. *Lung* 1987; 165:371.
- [76] Braude AC, Chamberlain DW, Rebeck AS. Pulmonary disposition of gallium-67 in humans: concise communication. *J Nucl Med* 1982; 23:574.
- [77] Shorr AF, Helman DL, Lettieri CJ, et al. Depreotide scanning in sarcoidosis: a pilot study. *Chest* 2004; 126:1337.
- [78] Lebtahi R, Crestani B, Belmatoug N, et al. Somatostatin receptor scintigraphy and gallium scintigraphy in patients with sarcoidosis. *J Nucl Med* 2001; 42:21.
- [79] Dunn TL, Watters LC, Hendrix C, et al. Gas exchange at a given degree of volume restriction is different in sarcoidosis and idiopathic pulmonary fibrosis. *Am J Med* 1988; 85:221.
- [80] Winterbauer RH, Lammert J, Selland M, et al. Bronchoalveolar lavage cell populations in the diagnosis of sarcoidosis. *Chest* 1993; 104:352.
- [81] Lin YH, Haslam PL, Turner-Warwick M. Chronic pulmonary sarcoidosis: relationship between lung lavage cell counts, chest radiograph, and results of standard lung function tests. *Thorax* 1985; 40:501.
- [82] Perez RL, Duncan A, Hunter RL, Staton GW Jr. Elevated D dimer in the lungs and blood of patients with sarcoidosis. *Chest* 1993; 103:1100.
- [83] Perez RL, Kimani AP, King TE Jr, et al. Bronchoalveolar lavage fluid D dimer levels are higher and more prevalent in black patients with pulmonary sarcoidosis. *Respiration* 2007; 74:297.

- [84] Keogh BA, Hunninghake GW, Line BR, Crystal RG. The alveolitis of pulmonary sarcoidosis. Evaluation of natural history and alveolitis-dependent changes in lung function. *Am Rev Respir Dis* 1983; 128:256.
- [85] Takemura T, Hiraga Y, Oomichi M, et al. Ultrastructural features of alveolitis in sarcoidosis. *Am J Respir Crit Care Med* 1995; 152:360.
- [86] Myers JL, Tazelaar HD. Challenges in pulmonary fibrosis: 6--Problematic granulomatous lung disease. *Thorax* 2008; 63:78.
- [87] Badesh DB, Champion HC, Sanchez MA et al. Diagnosis and assesment of pulmonary arterial hypertension. *J Am Coll Cardiol* 2009; 54(1. Suppl): S55-S66.
- [88] Baughman RP, Engel PJ, Meyer CA, Barret AB, Lower EE. Pulmonary hypertension in Sarcoidosis. *Sarcoidosis Vasc Diffuse Lung Dis* 2006; 23: 108-16.
- [89] Handa T, Nagai S, Miki S et al. Incidence of pulmonary hypertension and its clinical relevance in patients with Sarcoidosis . *Chest* 2006; 129: 1246
- [90] Días-Guzmán E, Farver C, Parambil J, Culver DA. Pulmonary hypertension caused by Sarcoidosis. *Clin Chest Med* 2008; 29 (3): 549-71.
- [91] Simonneau G, Robbins JM, Beghetti M et al. Update clinical classification of pulmonary hypertension. *J Am Coll Cardiol* 2009; 54: S43-S54
- [92] Baughman RP, Engel PJ, Meyer CA, Berret AB, Lower EE. Survival in Sarcoidosis associated pulmonary hypertension: the importance of hemodinamyc evaluation. *Chest* 2010;138(5): 1078-85.
- [93] Giaid A, Yanagisawa M, Langleben D et al. Expression of endotelin 1 in the lungs of patients with pulmonary hypertension. *N Eng J Med* 1993; 328:1732-39.
- [94] Preston IR, Klinger JR, Landzberg MJ, Houtchens J, Nelson D, Hill NS. Vasoresponsiveness of Sarcoidosis-associated pulmonary hypertension. *Chest* 2001; 120:866-72.
- [95] Nunes H, Humbert M, Capron F et al. Pulmonary hypertension associated with Sarcoidosis: mechanisms, haemodynamics and prognosis. *Thorax* 2006; 61: 68-74.
- [96] Palmero V, Sulica R. Sarcoidosis-associated pulmonary hypertension: assessment and management. *Semin Respir Crit Care Med* 2010; 31: 494-500
- [97] Nunes H, Freynet O, Naggara N et al. Cardiac Sarcoidosis. *Semin Respir Crit Care Med* 2010; 31: 428-41.
- [98] Sulica R, Teirstein AS, Kakarla S, Nemani N, Behnegar A, Padilla ML. Distinctive clinical, radiographic, and functional characteristics of patients with Sarcoidosis-associated pulmonary hypertension. *Chest* 2005;128:1483-89.
- [99] Shlobin OA, Nathan D. Management of end-stage Sarcoidosis: pulmonary hypertension and lung transplantation . *Eur Respi J* 2012; 39: 1520-33.

- [100] Sekiguchi M, Numao Y, Imai M, et al. Clinical and histopathological profile of sarcoidosis of the heart and acute idiopathic myocarditis. Concepts through a study employing endomyocardial biopsy. I. Sarcoidosis. *Jpn Circ J* 1980; 44:249
- [101] Yoshida Y, Morimoto S, Hiramitsu S, et al. Incidence of cardiac sarcoidosis in Japanese patients with high-degree atrioventricular block. *Am Heart J* 1997; 134:382.
- [102] Sato Y, Matsumoto N, Kunimasa T, et al. Multiple involvements of cardiac sarcoidosis in both left and right ventricles and papillary muscles detected by delayed-enhanced magnetic resonance imaging. *Int J Cardiol* 2008; 130:288.
- [103] Numata S, Kanda K, Hatta T, et al. Sarcoidosis with double saccular abdominal aortic aneurysms. *J Vasc Surg* 2005; 41:1065.
- [104] Mueller S, Boehme MW, Hofmann WJ, Stremmel W. Extrapulmonary sarcoidosis primarily diagnosed in the liver. *Scand J Gastroenterol* 2000; 35: 1003-1008
- [105] Dupas B, Gournay J, Frampas E, Leaute F, Le Borgne J. Anicteric cholestasis: imaging and diagnostic strategy. *J Radiol* 2006; 87: 441-459
- [106] Nataline MR, Goyette RE, Owensby LC, Rubin RN. The Budd-Chiari syndrome in sarcoidosis. *JAMA* 1978; 239: 2657-2657
- [107] Fries W, Grassi SA, Leone L, et al. Association between inflammatory bowel disease and sarcoidosis. Report of two cases and review of the literature. *Scand J Gastroenterol* 1995; 30:1221.
- [108] Burns TM. Neurosarcoidosis. *Arch Neurol* 2003; 60:1166.
- [109] Vargas DL, Stern BJ. Neurosarcoidosis: diagnosis and management. *Semin Respir Crit Care Med* 2010; 31(4): 419-27.
- [110] Titlic M, Bradic-Hammoud M, Miric L, Punda A. Clinical manifestations of neurosarcoidosis. *Bratisl Lek Listy* 2009; 110(9):576-9.
- [111] Stern BJ, Krumholz A, Johns C, et al. Sarcoidosis and its neurological manifestations. *Arch Neurol* 1985; 42:909.
- [112] Joseph FG, Scolding NJ. Sarcoidosis of the nervous system. *Pract Neurol* 2007; 7:234.
- [113] Scott TF. Neurosarcoidosis: progress and clinical aspects. *Neurology* 1993; 43:8.
- [114] Joseph FG, Scolding NJ. Neurosarcoidosis: a study of 30 new cases. *J Neurol Neurosurg Psychiatry* 2009; 80:297.
- [115] Pawate S, Moses H, Sriram S. Presentations and outcomes of neurosarcoidosis: a study of 54 cases. *QJM* 2009; 102:449.
- [116] Bihan H, Christozova V, Dumas JL, et al. Sarcoidosis: clinical, hormonal, and magnetic resonance imaging (MRI) manifestations of hypothalamic-pituitary disease in 9 patients and review of the literature. *Medicine (Baltimore)* 2007; 86:259.

- [117] Stuart CA, Neelon FA, Lebovitz HE. Disordered control of thirst in hypothalamic-pituitary sarcoidosis. *N Engl J Med* 1980; 303:1078.
- [118] Navi BB, DeAngelis LM. Sarcoidosis presenting as brainstem ischemic stroke. *Neurology* 2009; 72:1021.
- [119] Junger SS, Stern BJ, Levine SR, et al. Intramedullary spinal sarcoidosis: clinical and magnetic resonance imaging characteristics. *Neurology* 1993; 43:333.
- [120] Reda HM, Taylor SW, Klein CJ, Boes CJ. A case of sensory ataxia as the presenting manifestation of neurosarcoidosis. *Muscle Nerve* 2011; 43:900.
- [121] Brouwer MC, de Gans J, Willemsse RB, van de Beek D. Neurological picture. Sarcoidosis presenting with hydrocephalus. *J Neurol Neurosurg Psychiatry* 2009; 80:550.
- [122] Zuniga G, Ropper AH, Frank J. Sarcoid peripheral neuropathy. *Neurology* 1991; 41:1558.
- [123] Saifee TA, Reilly MM, Ako E, et al. Sarcoidosis presenting as acute inflammatory demyelinating polyradiculoneuropathy. *Muscle Nerve* 2011; 43:296.
- [124] Niemer GW, Bolster MB, Buxbaum L, Judson MA. Carpal tunnel syndrome in sarcoidosis. *Sarcoidosis Vasc Diffuse Lung Dis* 2001; 18:296.
- [125] Nakatani-Enomoto S, Aizawa H, Koyama S, et al. Transient swelling of peripheral nerves in a case of neurosarcoidosis. *Intern Med* 2004; 43:1078.
- [126] Shambaugh GE, Cirksena WJ, Newcomer KL. Carpal tunnel syndrome as manifestation of sarcoidosis. *Arch Intern Med* 1964; 114:830.
- [127] Ando DG, Lynch JP 3rd, Fantone JC 3rd. Sarcoid myopathy with elevated creatine phosphokinase. *Am Rev Respir Dis* 1985; 131:298.
- [128] Zajicek JP, Scolding NJ, Foster O, et al. Central nervous system sarcoidosis--diagnosis and management. *QJM* 1999; 92:103.
- [129] Sherman JL, Stern BJ. Sarcoidosis of the CNS: comparison of unenhanced and enhanced MR images. *AJNR Am J Neuroradiol* 1990; 11:915.
- [130] Scott TF. Cerebral herniation after lumbar puncture in sarcoid meningitis. *Clin Neurol Neurosurg* 2000; 102:26.
- [131] Lodha S, Sanchez M, Prystowsky S. Sarcoidosis of the skin: a review for the pulmonologist. *Chest* 2009; 136:583.
- [132] Iannuzzi MC, Rybicki BA. Sarcoidosis. *N Engl J Med* 2007; 357: 2153-65
- [133] Fernandez Fait E, MacDonnel J. Cutaneous sarcoidosis: differential diagnosis. *Clin Dermatol*. 2007 May-Jun; 25(3):276-87.
- [134] Holmes J, Lazarus A. Sarcoidosis extrathoracic manifestations. *Disease a month*. Vol 55 (11). Elsevier. Nov 1, 2009

- [135] Yanardag H, Pamuk ON, Karayel T. Cutaneous involvement in sarcoidosis: analysis of the features in 170 patients. *Respir Med* 2003; 97: 978.
- [136] Elgart ML. Cutaneous sarcoidosis: definitions and types of lesions. *Clin Dermatol* 1986; 4:35.
- [137] Ben Jennet S, Benmously R, Chaabane S, et al. Cutaneous sarcoidosis through a hospital series of 28 cases. *Tunis Med* 2008; 86: 447
- [138] Dumitrescu SM, Schwartz RA, Baredes S, et al. Mutilating facial sarcoidosis. *Dermatology* 1999; 199:265.
- [139] Young RJ, Gilson RT, Yanase D. Cutaneous sarcoidosis. *Int J Dermatol* 2001; 40:249.
- [140] Yanardag H, Pamuk ON, Pamuk GE. Lupus pernio in sarcoidosis: clinical features and treatment outcomes of 14 patients. *J Clin Rheumatol* 2003; 9: 72-6
- [141] Cardoso JC, Cravo M, Reis JP, Tellechea O. Cutaneous sarcoidosis: a histopathological study. *J Eur Acad Dermatol Venereol* 2009; 23:678.
- [142] García Porrúa C, Gonzalez-Gay MA, Vázquez-Caruncho M, et al. Erythema nodosum: etiologic and predictive factors in a defined population. *Arthritis Rheum* 2000; 100:183.
- [143] Okamoto H, Mizuno K, Imamura S, et al. Erythema nodosum like eruption in sarcoidosis. *Clin Exp Dermatol* 1994; 19:507.
- [144] Grunewald J, Eklund A. Sex-specific manifestations of Löfgren's syndrome. *Am J Respir Crit Care Med* 2007; 175:40.
- [145] Grunewald J, Eklund A. Löfgren's syndrome: human leukocyte antigen strongly influences the disease course. *Am J Respir Crit care Med* 2009; 179: 307.
- [146] Valverde García J, García Gómez C. Sarcoidosis. *Medicine* 2009, 10 (33): 2192-8
- [147] Abril A, Cohen MD. Rheumatologic manifestations of sarcoidosis. *Curr Opin Rheumatol* 2004; 16:51.
- [148] Siltzbach LE, Duberstein JL. Arthritis in sarcoidosis. *Clin Orthop Relat Res* 1968; 57:31.
- [149] Visser H, Vos K, Zanelli E, et al. Sarcoid arthritis: clinical characteristics, diagnostic aspects, and risk factors. *Ann Rheum Dis* 2001; 61:499.
- [150] Glennas A, Kvien TK, Melby K, et al. Acute sarcoid arthritis: occurrence. Seasonal onset, clinical features and outcome. *Br J Rheumatol* 1995; 34:45
- [151] Shetty AK, Gedalia A. Sarcoidosis: a pediatric prospective. *Clin Pediatr* 1998; 37:707.
- [152] Awada H, Abi-Karam G, Fayad F. Musculoskeletal and other extrapulmonary disorders in sarcoidosis. *Best Pract Res Clin Rheumatol* 2003; 17: 971.

- [153] Bonfioli AA, Orefice F. Sarcoidosis. *Sem Ophthalmol*. 2005 Jul – Sep; 20 (3): 177-82
- [154] Varron L, Abad S, Kodjikian L, Seve P. Sarcoid uveitis: Diagnostic and therapeutic update. *Rev Med Interne*. 2011 Feb; 32(2): 86 – 92. Epub 2010 Oct 20.
- [155] American Thoracic Society: Statement on sarcoidosis. *Am J Respir Crit Care Med* 1999;160:736-55.
- [156] Judson M. Extrapulmonary sarcoidosis. *Semin Respir Crit Care Med* 2007;28: 83-101
- [157] White ES, Lynch JP. Current and emerging strategies for the management of sarcoidosis. *Exp Opin Pharmacother* 2007;8:1293-311.
- [158] Park DJJ, Woog JJ, Pulido JS, et al. Minocycline for the treatment of ocular and ocular adnexal sarcoidosis. *Arch Ophthalmol* 2007;125:705-9.

IntechOpen

