

We are IntechOpen, the world's leading publisher of Open Access books Built by scientists, for scientists

4,300

Open access books available

117,000

International authors and editors

130M

Downloads

Our authors are among the

154

Countries delivered to

TOP 1%

most cited scientists

12.2%

Contributors from top 500 universities



WEB OF SCIENCE™

Selection of our books indexed in the Book Citation Index
in Web of Science™ Core Collection (BKCI)

Interested in publishing with us?
Contact book.department@intechopen.com

Numbers displayed above are based on latest data collected.
For more information visit www.intechopen.com



Macular Edema and Cataract Surgery

Miltiadis K Tsilimbaris, Chrysanthi Tsika,
Vasilios Diakonis, Aleksandra Karavitaki and Ioannis Pallikaris
*University of Crete Medical School, Department of Ophthalmology
Greece*

1. Introduction

Macular edema (macular oedema) is the accumulation of fluid within the retinal spaces, among the several layers of the tissue due to mechanical factors (anatomic failure, traction) or chemical factors (inflammation, drugs). The macular edema causes thickening of the retina and it may be diffuse or local. Cystoid macular edema (CME) also spelled as cystoid macular oedema (CMO) is the local form of the condition when it accumulates into cystic spaces mainly in the outer layers of the central retina (macula). CME is a painless condition. The effect on visual function depends on the severity of the condition and is usually associated with blurred or distorted vision. CME can be recognized by visual acuity reduction, characteristic appearance of the macula during fundoscopy, fluorescein angiography or ocular coherence tomography (OCT). It is important to distinguish the different varieties of CME that can range from fluorescein angiography findings only (angiographic CME) to symptomatic CME. Chronic cystoid macular edema refers to clinically significant CME that persist for more than six months (Gass & Norton, 1969; Berkow et al., 1997).

The cause of CME depends on the underlying disease process. It has been reported in association with local ocular conditions (epiretinal membrane, subretinal neovascularization), ocular or systemic vascular diseases (central and branch retinal vein obstruction, diabetic retinopathy), inflammatory conditions (pars planitis), conditions that lead to mechanical/tractional stress of the retina (vitreomacular traction syndrome), use of medications (epinephrine, latanoprost), and inherited diseases (retinitis pigmentosa). Rare causes of CME such as juvenile retinoschisis, Goldmann-Favre disease and nicotinic acid maculopathy are characterized by different pathogenesis, positive family history and different patterns in the fluorescein angiography.

Postoperative CME represents a well-known distinct entity associated with a variety of intraocular operations. Operations such as scleral buckling, pneumatic retinopexy or combined PKP and transscleral sutured posterior chamber IOL implantation can be complicated by postoperative CME (Notage et al., 2009; Van der Schaft et al, Tunc et al., 2007). CME following cataract surgery is currently the most commonly encountered postoperative CME. Post-cataract or Pseudophakic CME was initially described by Irvine SR in 1953 and Gass & Norton in 1966; this is why this entity is also known as Irvine-Gass syndrome (Irvine, 1953, 1976; Gass & Norton, 1966). Although most patients with CME after cataract surgery are visually asymptomatic, demonstrating only CME findings on

angiography and on OCT, clinically significant CME still occurs even after an uncomplicated cataract extraction using phacoemulsification.

2. Incidence, epidemiology, risk factors

CME is the most common cause for sub-optimal visual outcome after cataract extraction procedures and represents today the most common cause of unexpected visual loss after uneventful cataract surgery (Ray & D'Amico, 2002). CME may occur after both complicated and uncomplicated cataract surgery, with no significant gender or race predilection.

Angiographic CME is detected in fluorescein angiography as a capillary perifoveal leakage with a petaloid appearance while in clinical CME biomicroscopic findings together with significant visual impairment are also present. Older reports on angiographic CME after intracapsular cataract extraction (ICCE) mention rates as high as 50-70% while after extracapsular cataract extraction (ECCE) the rate has been reported to be close to 18% ranging from 16 to 40% (Ray & D'Amico, 2002, Nagpal et al., 2001). Ursell et al. (1999) investigated the existence of angiographic CME after phacoemulsification the 60th day after surgery; they reported 19% of angiographic CME in 103 eyes, with no development of clinical CME in any of these eyes.

The incidence of clinically significant CME has been reported to be from 1% to 12% depending on factors such as surgical technique, selection of IOL, intra-operative complications and post-operative management. In 1998, Flach performed fluorescein angiograms in all cases with VA lower than 20/40 after ECCE with PC-IOL implantation and revealed a 7% incidence of post-operative clinical CME. The lack of use of post-operative steroids may have contributed to that high rate in this particular study. Following an uncomplicated phacoemulsification with an intact posterior capsule, the rate for CME has been reported to be as low as 0-2%. (Mentes et al., 2003; Flach et al., 1998). Recently, Loewenstein & Zur (2010) reported a rate of 0.1-2.35% for clinical CME following modern cataract surgery techniques.

Risk factors responsible for the development of CME after cataract extraction include several intraoperative complications such as posterior capsular rupture, vitreous loss and vitreous incarceration into the incision site and anterior chamber. Advanced age has been also reported as a risk factor for the development of the syndrome (Rossetti & Autelitano, 2000). Percival (1998) studied the effect of different factors on CME development after lens implantation. He reported a 13% incidence of CME after ECCE with intact posterior capsule, while if the capsule was ruptured the rate increased to 27%. Moreover, vitreous in the anterior chamber resulted in the appearance of CME in 33% of cases. Other authors have also shown the relationship between posterior capsule rupture and postoperative CME (Nikica et al., 1992; Chambless et al., 1979). The same positive correlation with postoperative CME has been reported by several authors for vitreous loss (Ah-Fat et al., 1998; Iwao et al., 2008). In a 2000 review by Rosetti & Autelitano, vitreous loss was correlated with an overall increase in CME by 10-20%. The use of iris supported IOLs is also associated with increased incidence and late onset of CME, which has been attributed to the chronic irritation of the iris. Iris is a tissue that responds to injury with secretion of inflammatory mediators. Gulkilik et al. (2006) found the presence of CME in 70% of patients after iris trauma compared to 20,5% of patients without iris injury. In general, the incidence of CME in complicated cases of cataract extraction has been reported to range from 1.5% to 35.7%

(Nikica et al. 1992). The type of intraocular lens (IOL) implanted may also play some role in postoperative CME formation. Kraff et al. (1985) reported that the use of ultraviolet (UV)-filtering IOLs might reduce the formation of angiographic CME. Finally, Ferreri et al. (1999) reported an association between macular edema formation and the amount of energy during phacoemulsification; in their study, a higher incidence of CME was associated with energies that exceeded one joule. On the other hand several other factors do not seem to play any significant role. In a study performed by Gulkilik et al (2006) no correlation was found between postoperative CME and cataract type, iris colour or pseudoexfoliation; in the same study no correlation between phacoemulsification time and CME development was found.

The risk of visually significant CME has decreased with the development of advanced surgical techniques, such as modern phacoemulsification with micro-incisional techniques and foldable intraocular lenses (IOLs), when compared to older techniques, especially intracapsular cataract extraction (Wetzig et al, 1979; Sorr et al, 1979). If the diagnosis of visually significant ME is based on visual loss to the 20/40 level or worse, the incidence is 2 - 10% following ECCE or ICCE and 0 - 2% following phacoemulsification with an intact posterior capsule. However, in at least one large series comparing postoperative CME after ECCE and phacoemulsification in patients with no underlying systemic disease, no significant differences were found between the two techniques. Even though the angiographic CME was slightly higher for ECCE, the clinical incidence was similar (0-6% for phacoemulsification compared to 0-7.6% for ECCE) (Powe et al., 1994).

The risk of CME formation after cataract surgery may increase in the presence of several ocular or systemic diseases when compared with history free patients. In a review study by Rotsos et al it was suggested that cataract surgery in diabetic patients might accelerate pre-existing diabetic macular edema leading to poor visual outcome. Even in the absence of diabetic macular edema, diabetic patients tend to have a higher risk of developing CME after uncomplicated cataract extraction (Dowler et al., 1995, 2000; Dowler & Hykin, 2001; Schatz, 1994; Pollack, 1992). In addition to diabetes, uveitis is also a significant pre-operative condition predisposing to CME. The rates reported in the literature may reach 56% while in most case it is recurrent (Krishna et al., 1998; Estafanous et al., 2001).). For this reason a careful selection of patients with uveitis has been suggested as a way to decrease the frequency of postoperative CME development (Suresh et al., 2001). Preoperative steroids may be given, topically and/or systemically in uveitis patients. The presence of epiretinal membrane also predisposes to increase of macular thickness and macular edema after cataract extraction. Finally, patients under local therapy with prostaglandin analogues have been reported to have a higher incidence of CME after cataract extraction. Agange et al presented a case report of a glaucomatic patient who developed recurrent CME with three separate trials of three different prostaglandins after uncomplicated cataract surgery. Other studies have also reported same findings (Yeh & Ramanathan, 2002; Altintas et al., 2005; Panteleontidis et al., 2010).

In a study conducted in our institution, we prospectively examined macular thickness alterations after uncomplicated phacoemulsification in four different groups of patients. One group consisted of otherwise fit patients while the others included patients with diabetes, epiretinal membrane and glaucoma. We concluded that regardless of group, a statistically significant mean foveal thickness (MFT) increase occurs one month after surgery, while this increase regresses six months after surgery. Even though MFT regressed during the follow up period, in patients with diabetes mellitus and epiretinal membrane it

remained significantly higher even six months after cataract surgery. With regard to diabetic patients, these showed the greatest difference between postoperative and preoperative macular thickness, indicating that the underlying pathophysiology is influenced significantly by the cataract extraction process. Despite these macular alterations, visual acuity improved significantly after cataract surgery in all patients in this study, while none of the patients demonstrated clinical CME (M. Eleftheriadou et al., 2010).

3. Pathogenesis, pathophysiology

The formation of CME is due to leakage of perifoveal capillaries, which if severe enough, leads to pooling in the outer layers of the central retina. Cystoid spaces are formed in the foveal area, in the outer plexiform layer and Henle's layer while some fluid accumulates in the nerve fiber layer, inside thin-walled cysts (Gass & Norton, 1966). Recently, histological findings have proved that the cysts may form also in the inner plexiform layer. The rod and cone photoreceptors in the area under the cysts are consistently found to be decreased in number.

Although the exact pathogenesis of post cataract CME is unknown, the main mechanism involved is considered to be inflammation. Inflammation in the vitreous, as described by Gass, represents a consistent finding in eyes with postoperative CME. This has been also documented in specimens of vitreous aspiration, where inflammatory cells were identified (Tso et al., 1982; Flach et al., 1998). In general, intraocular surgery seems to trigger the accumulation of macrophages and neutrophils that are further activated by circulating inflammatory agents, including cyclooxygenase and lipooxygenase metabolites, proteolytic agents and more, leading to the appearance of clinical signs of inflammation (perilimbal injection and anterior chamber flare). Cytokines such as interferon- γ , interleukin-2 and tumor necrosis factor- α also participate in the process inducing the production of cyclooxygenase. (Wakefield & Lloyd, 1992; Miyake et al., 2000). Experimental studies of lens implantation in animal models have confirmed that trauma of the lens epithelial cells leads to the secretion of inflammatory mediators (Miyake et al., 1990). Other factors such as nitric oxide, complement and platelet-activating factor secreted by different cell types are believed to play important role in triggering inflammation postoperatively (Lightman & Chan, 1990). The induced inflammation has been also suggested to affect the function of Bito's pump, which is located in the ciliary epithelium and is responsible for the removal of inflammatory mediators from the eye (El-Harazi et al., 2001). Furthermore, the procedure of cataract surgery itself has been suggested recently to induce pro-inflammatory gene expression and protein secretion (Xu et al., 2011).

After a cataract operation, posterior diffusion of inflammatory factors is supposed to lead to blood-retina barrier (BRB) breakdown. The BRB is responsible for restricting movement of plasma constituents into the retina and in maintaining retinal homeostasis. A BRB breakdown leads to increased capillary permeability of the perifoveal network, and results in cyst formation and intraretinal fluid accumulation both intra- and extracellularly (Yanoff et al., 1984). Fluid accumulation disturbs cell function and retinal configuration. Müller cells are thought to act as metabolic pumps, which keep the macula dry. The accumulation of fluid in the outer plexiform layer is considered to be a late phenomenon following breakdown of the Müller cells. This produces the characteristic petaloid pattern of CME on fluorescein angiography (Figure 1).

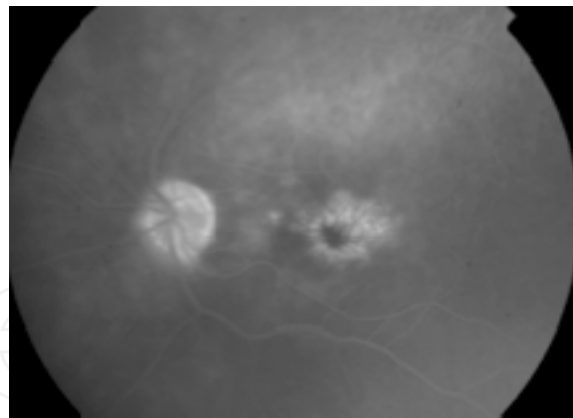


Fig. 1. Late phase of fluorescein angiography demonstrating the characteristic petaloid pattern of CME.

It is still not clear why the fluid that leaks from the perifoveal capillaries accumulates in the foveal region despite the massive production and distribution of the inflammatory agents throughout the retina. The relative avascularity of the avascular zone in combination with the high metabolic activity of the foveal area may explain in part the reduced reabsorption of leaking fluid in this area. Moreover, the thinner constitution of the inner limiting membrane (ILM) in the macula, may allow the diffusion of inflammatory agents in greater extent in this area than elsewhere. Even if all the aforementioned is crucial to the formation of CME, the fact that the majority of cases resolve spontaneously suggests that the more important question is what factors prolong its existence.

4. Clinical presentation, symptoms, diagnosis

4.1 Clinical presentaion & symptoms

Macular edema developing after cataract surgery does not necessarily imply a reduction of visual acuity. Thus, CME can appear either as an angiographic or tomographic entity without visual impairment or as a condition with significant visual impairment. Angiographic CME is reported to occur in 3% to 70 % of patients whereas clinically significant CME appears in 0.1% to 12%. This means that an important percentage of CME remains asymptomatic.

The definition of clinical CME is slightly different amongst authors but generally involves a visual acuity worse than 20/40 with a parallel biomicroscopic observation and angiographic documentation of perifoveal leakage. It usually occurs 3–12 weeks postoperatively (peak incidence 6–10 weeks), but in some instances its onset may be delayed for months or years after surgery (Mao & Holland, 1988). Unlike diabetic macular edema, which can be an important differential diagnosis, it does not usually occur less than two weeks after cataract surgery.

When visually significant, the CME can induce a reduction of visual acuity that ranges, down to 20/65 or 20/80 (Chan et al., 2010). It can also impair other visual functions such as contrast sensitivity (Ibanez et al. 1993). Metamorphopsia and micropsia may be reported by patients suffering from CME, while a hyperopic shift is often observed (Quillen & Blodi, 2002).

4.2 Diagnosis

Several diagnostic modalities provide important information about macular status and can assist ophthalmologists in diagnosing CME. The main diagnostic techniques used in everyday practice include biomicroscopy, fluorescein angiography and optical coherence tomography.

4.2.1 Slit-lamp biomicroscopy

In patients suffering from CME after cataract operation, anterior chamber findings may sometimes be present such as limbal ciliary flush, mild iritis and vitritis. The signs of surgical complications may also be observed such as a vitreous strand(s) to the iris or the wound, a dislocated IOL or a disrupted posterior capsule. Retinal biomicroscopy (Figure 2) reveals loss of the normal foveal reflection, thickening of the retina and multiple cystoid areas in the sensory retina that are better observed through a red free filter. A thorough biomicroscopic examination should always be performed in order to exclude other causes of post-operative loss of visual acuity such as macular holes, branch vascular occlusions and epiretinal membranes.

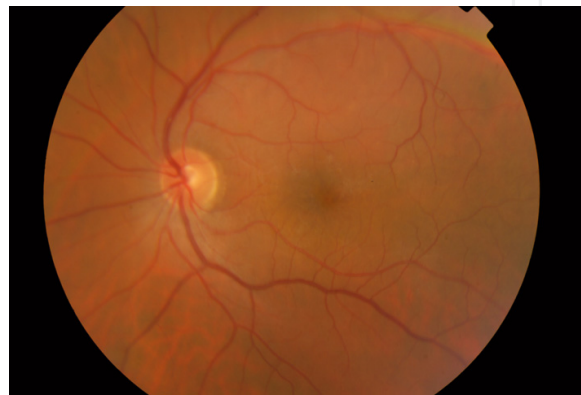


Fig. 2. Biomicroscopic appearance of a macula with cystoid macular edema. The findings may be minimal requiring careful observation and confirmation with imaging techniques such as OCT and fluorescein angiography

4.2.2 Fluorescein angiography

Fluorescein angiography (FA) is the gold standard for the diagnosis of macular edema (Figure 3). Macular edema is characterized by small hyperfluorescent spots (due to early leakage) in the arteriovenous phase and by the development of a 'flower petal' pattern ('petaloid') of hyperfluorescence in the late phase, caused by accumulation of fluorescein dye within the microcystic spaces in the outer plexiform layer of the retina, with a radial arrangement around the center of the foveola (corresponding to the arrangement of Henle's

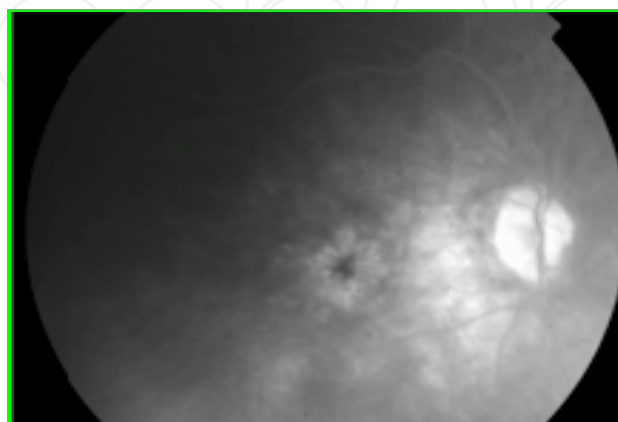


Fig. 3. Late phase of fluorescein angiography demonstrating the characteristic petaloid pattern of CME.

layer). Another common angiographic finding of cystoid macular edema, especially after cataract surgery, is the hyperfluorescence of the optic disc; this feature may predict a better response to anti-inflammatory medications.

It has been reported extensively that after cataract operation, patients will develop angiographic macular edema (fluorescein dye leakage), in a larger percentage when compared to the incidence of CME detected biomicroscopically. Nevertheless, both findings are not directly associated with visual acuity alterations.

4.2.3 Optical coherence tomography (OCT)

Since the introduction of OCT, the diagnosis and follow up of macular edema has been greatly facilitated (Figure 4). This modality offers a non-invasive imaging technique that provides high resolution cross sectional images of the macula. CME in OCT appears as a collection of hyporeflective spaces within the retina, with an overall macular thickening and loss of the foveal depression. OCT is as effective as FA at detecting ME, while it produces highly reproducible measurements so that serial examination may be used for follow up. A macular thickness change that is equal or more than 40 μm has been described as an index of OCT-significant macular edema (Wittpenn et al., 2008). The amount of macular thickening has not been well-correlated with visual loss. Small pachymetric macular changes seem not to influence visual acuity but when macular pachymetry alterations are in the 100 μm or more range, visual acuity may be influenced. (Kim & Bressler, 2007). This inability to directly correlate macular thickness and visual acuity is probably related to the fact that extracellular edema may cause mechanical stress on the retina, while the visual pathways remain intact. Finally, OCT is extremely valuable in following a patient's response to treatment and determining whether or not further treatment is necessary. There is no consensus yet on whether OCT should be done in all patients after cataract surgery to detect CME.

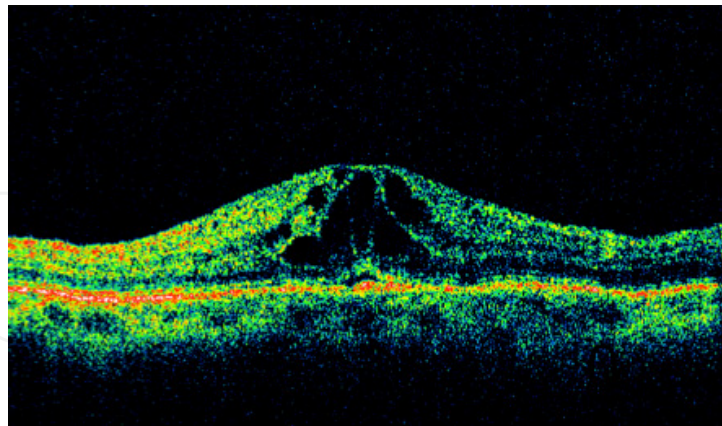


Fig. 4. Postoperative cystoid macular edema in OCT. Notice the collection of hyporeflective spaces within the retina, the increased macular thickness and the loss of the foveal depression.

5. Treatment

Most cases of pseudophakic CME, resolve spontaneously. This is why the value of prophylactic treatment remains doubtful. However, a large meta-analysis study that

reviewed 16 randomized Clinical Trials (RCTs) involving 2898 eyes, concluded that there is some prophylactic effect against both angiographic and clinical CME when using topical NSAIDs or steroids pre-operatively (Ross et al., 1998).

Today, there is no standard approach for treating CME occurring after cataract extraction. In addition to any pharmacological treatment, the overall confrontation should also include the correction of the underlying cause, if possible.

First-line treatment of postsurgical CME includes topical administration of anti-inflammatory agents, such as nonsteroidal anti-inflammatory drugs (NSAIDs) and corticosteroids. The ophthalmic NSAIDs are non-selective inhibitors of cyclooxygenase (COX) - ketorolac, nepafenac, diclofenac etc - which inhibit the formation of prostaglandins from arachidonic acid. The steroids (including prednisolone, dexamethasone etc) act by blocking prostaglandin activity through the inhibition of the formation of arachidonic acid. Both categories can be provided as eye drops immediately after the CME is diagnosed (clinically and/or angiographically) or after a short period of attendance due to the self-limiting character of the condition. The effectiveness of topically administered NSAIDs is proved by several studies (Miyake et al., 1980; Yannuzzi et al., 1981; Flach et al., 1991; Italian Diclofenac Study Group, 1997) and their use is suggested as alternative to steroids when possible (Warren & Fox, 2008) due to the well-known side effects after long-term administration of steroids (eg. elevation of IOP).

The combination of the two categories is also proposed in the literature. In 2000, Heier et al. investigated the use of ketorolac versus prednisolone versus their combination for treating acute post-operative CME. The combination was proved to be the most effective, while between monotherapies, ketorolac surpassed prednisolone. Furthermore, in the study of Henderson et al. in 2007, a faster resolution of the edema was noticed in patients that received NSAIDs plus steroids. Whitpenn et al. (2008) also reported a lower incidence of CME in a group of low-risk patients that received ketorolac plus prednisolone preoperatively and 4 weeks postoperatively versus patients that received prednisolone alone.

The postoperative CME seems to respond well to topical anti-inflammatory agents even when it becomes chronic. Weisz et al. in 1998, in a study concerning 10 eyes of 9 patients with CME lasting more than 24 months, administered topical ketorolac for at least three months. The CME improved or resolved during treatment but recurred after the interruption of the administration. As far as the relative effectiveness of the different NSAIDs is concerned, no significant evidence is provided by the literature to support superiority of any of them over the others (Rho, 2003; Maca, 2010).

Recently, there has been a discussion on the benefit of initiation of anti-inflammatory treatment immediately after surgery. It is suggested that in patients belonging in high-risk groups for developing CME (DR, RVO, ERM), the direct application of such agents can reduce the frequency of appearance to the levels of patients who are not in high risk (Henderson et al., 2007).

Many experts administer topical steroids intensively such as 2-hourly and non-steroidal anti-inflammatory agents 6-hourly and assess response after a trial period of two weeks. When the CME does not respond to topical therapy, systemic therapy may be considered by some authorities. Oral carbonic anhydrase inhibitors are the most usual agents administered complementary to the topical treatment - acetazolamide is the most frequent choice (Ismail et al., 2008). However their benefit in postoperative CME is still debated and they are not used by many authorities. The carbonic anhydrase inhibitors should be given with caution and not for a prolonged period, due to the loss of potassium that they cause and the

consequent systematic risks (Kaur et al., 2002). The systemic use of steroids is not indicated for postoperative CME, because of the disproportionate benefit compared to their systemic side effects. Recently, the oral administration of a COX-2 inhibitor (valdecoxib) has been suggested to have therapeutic effect on the post-operative CME (Reis et al., 2007). In this study, 10 patients with post-operative CME received 10mg/day of valdecoxib for 3 weeks. All but one increased the BCVA and remained stable for at least 15 months.

However, there are cases where the CME doesn't respond to any topical or systemic treatment or it regresses every time the treatment is ceased. In such cases, periocular or intraocular corticosteroids represent an option. The most commonly used steroid is triamcinolone, which is administered by injection either in the area of the orbital floor (periocularly) or as a posterior sub-Tenon's injection or, failing this with no improvement after a period of time (typically a further two weeks observation), intravitreally (Karacorlu et al., 2003; Boscia et al., 2005; Koutsandrea et al., 2007). Recently, the preference of intravitreal administration has increased considerably because it is much more effective with lesser dosage of the drug. It is important to note, however, that the intravitreal route is accompanied with some risk for complications such as endophthalmitis (Tao & Jonas, 2011). Moreover, elevation of IOP is always likely to occur after several repetitions of the intravitreal injection although, as with topical administration, the effect is often transient, even if it lasts longer (Sobrin & D'Amico, 2005; Tao & Jonas, 2011).

For the refractory cases some investigators have tried the use of anti-VEG agents intravitreally such as bevacizumab with encouraging results (Diaz-Llopis et al., 2007; Barone et al., 2008). The pathophysiological mechanism for this action of antiangiogenics is not clear but it is probably related to the stabilization of the BRB that they induce. The frequency of the injection repetition as well as the dosage, are only few of the questions regarding the intravitreal administration of anti-VEGFs in CME.

Since the mid 2000's a few studies have appeared concerning the intravitreal administration of NSAIDs in CME. Ketorolac and diclofenac have been administered intravitreally in CME of a variety of aetiologies including cases of postoperative persistent CME (Wafapoor & McCluskey, 2006; Tsilimbaris et al., 2008; Masoud et al., 2010). The results are contradictory but not discouraging for the consideration of the IVT use of the NSAIDs for certain indications. Last treatment options when all the aforementioned has failed, is the surgical treatment. Surgical intervention should be reserved for special indications. The iatrogenic induction of posterior vitreous detachment during standard pars plana vitrectomy (PPV) is believed to ameliorate the supply of oxygen to the affected retinal area and to relieve the macula from any possible traction that could contribute to the formation of the CME. A few studies have shown improvement after PPV alone (Pendergast et al., 1999), PPV combined with ILM peeling (Peyman et al., 2002) or PPV combined with IVT triamcinolone (Bencić et al., 2006). Likewise, in cases of vitreous incarceration in the anterior segment, anterior vitrectomy or YAG laser disruption of vitreous adhesions may have therapeutic effect. Finally, in rare cases it may be necessary to remove an anterior chamber IOL.

To conclude, the treatment of CME post cataract surgery is not always obvious. Even though the topical anti-inflammatory agents have in the majority of cases a reasonable effect especially if combined with topical steroids, there may be times that the CME is refractory to any treatment and persists resulting in low visual acuity and eventually in atrophy of the adjacent retinal structures. Intravitreal agents such as corticosteroids, anti-VEGFs and NSAIDs have been tried for refractory cases with various results. Surgical treatment is the last choice for nonresponsive cases of chronic and clinically significant pseudophakic CME.

6. Prognosis

Pseudophakic CME typically has a good prognosis. Spontaneous resolution with subsequent visual improvement may occur within 3–12 months in 80% of the patients (Bonnet, 1995). Similarly in 90% of eyes the edema resolves over a two years period (Benitah & Arroyo, 2010). Persistent macular edema or multiple remissions and exacerbations can result in foveolar photoreceptor damage with permanent impairment of vision. (Gass & Norton, 1969).

7. References

- Agange N. & Mosead S. (2010). Prostaglandin-induced cystoid macular edema following routine cataract extraction. *J Ophthalmol*, Vol. 2010, No. 690707 (published on line)
- Ah-Fat F.G., Sharma M.K., Majid M.A. & Yang Y.C. (1998). Vitreous loss during conversion from conventional extracapsular cataract extraction to phacoemulsification. *J Cataract Refract Surg*, Vol. 24, pp. (801–805).
- Altintas O., Yuksel N., Karabas V.L. & Demirci G. (2005). Cystoid macular edema associated with latanoprost after uncomplicated cataract surgery. *Eur J Ophthalmol*, Vol. 15, No. 1, pp. (158–161).
- Barone, A., Prascina, F., Russo, V., Iaculli, C., Primavera, V., Querques, G., Stella, A. & Delle Noci, N. (2008). Successful treatment of pseudophakic cystoid macular edema with intravitreal bevacizumab. *J Cataract Refract Surg*, Vol. 34, pp. (1210–1212).
- Bencić, G., Vataavuk, Z. & Mandić, Z. (2006). Pars plana vitrectomy and intravitreal triamcinolone for chronic pseudophakic cystoid macular edema. *Acta Med Croatica*, Vol. 60, No. 2, pp. (93–96).
- Benitah N.R. & Arroyo J.G. (2010). Pseudophakic cystoid macular edema. *Int Ophthalmol Clin*, Vol. 50, pp. (139–153).
- Berkow J.W., Flower R.W., Orth D.H. et al. *Fluorescein and Indocyanine Green Angiography: Technique and Interpretation*. 2nd ed. *Ophthalmology Monograph* 5. San Francisco: American Academy of Ophthalmology:1997: 117–8
- Bonnet S. (1995). Repercussions of cataract surgery on the development of cystoid macular edema in the diabetic patient. *Bull Soc Belge Ophtalmol*, Vol. 256, pp (127–129).
- Boscia F., Furino C., Dammacco R., Ferreri P., Sborgia L. & Sborgia C. (2005). Intravitreal triamcinolone acetate in refractory pseudophakic cystoid macular edema: functional and anatomic results. *Eur J Ophthalmol*, Vol.15, No. 1, pp (89–95).
- Chambless W.S. (1979). Phacoemulsification and the retina: cystoid macular edema. *Ophthalmology*, Vol. 86, pp. (2019–2022).
- Chan E., Mahroon O.A.R. & Spalton D.J. (2010). Complications of cataract surgery. *Clin Exp Optom*, Vol. 93, No. 6, pp. (379–389).
- Diaz-Llopis M., Amselem L., Cervera E., Garcia-Delpech S., Torralba C. & Montero J. (2007). Intravitreal injection of bevacizumab for pseudophakic cystoid macular edema resistant to steroids. *Arch Soc Esp Ophthalmol*, Vol. 82, pp. (447–450)
- Dowler J.G.F., Hykin P.G., Lightman S.L. & Hamilton A.M. (1995). Visual acuity following extracapsular cataract extraction in diabetes: a meta-analysis. *Eye*, Vol. 9, pp. (313–317).

- Dowler J.G., Hykin P.G. & Hamilton A.M. (2000). Phacoemulsification versus extracapsular cataract extraction in patients with diabetes. *Ophthalmol*, Vol. 107, pp. (457-462).
- Dowler J. & Hykin P.G. (2001). Cataract surgery in diabetes. *Curr Opin Ophthalmol*, Vol. 12, pp. (175-178).
- Eleftheriadou M., Fragiskou S., Kymionis G, Panteleontidis V, Papadaki T. & Tsilimbaris M.K. (2010). Cystoid Macular Edema and Macular Thickness Alterations After Cataract Surgery Determined by Optical Coherence Tomography (OCT). *Invest Ophthalmol Vis Sci*, Vol. 51: E-Abstract 4727
- El-Harazi S.M., Feldman R.M. (2001). Control of intra-ocular inflammation associated with cataract surgery. *Curr Opin Ophthalmol*, Vol. 12, pp. (4-8).
- Estafanous M.F., Lowder C.Y., Meisler D.M. & Chauhan R. (2001). Phacoemulsification cataract extraction and posterior chamber lens implantation in patients with uveitis. *Am J Ophthalmol*, Vol. 31, pp. (620-625).
- Ferrari M.T., Cavallo M., Minnino L., Cardascia N. (1999). Macular edema induced by phacoemulsification. *Doc Ophthalmol*, Vol. 97, pp. (325-327).
- Fishman G.A., Fishman M. & Maggiano J. (1977). Macular Lesions Associated With Retinitis Pigmentosa. *Arch Ophthalmol*, Vol. 95, No. 5, pp. (798-803).
- Flach A.J., Jampol L.M., Weinberg D., Kraff M.C., Yannuzzi L.A., Campo R.V., Neumann A.C., Cupples H.P. & Lefler W.H. (1991). Improvement in visual acuity in chronic aphakic and pseudophakic cystoid macular edema after treatment with topical 0.5% ketorolac tromethamine. *Am J Ophthalmol*, Vol. 112, pp. (514-519).
- Flach A.J. (1998). The incidence, pathogenesis and treatment of cystoid macular edema following cataract surgery. *Trans Am Ophthalmol Soc*, Vol. 96, pp. (557-634).
- Gass J.D., Norton E.W. (1966). Cystoid macular edema and papilledema following cataract extraction. A fluorescein fundoscopic and angiographic study. *Arch Ophthalmol*, Vol. 76, pp. (646-661).
- Gass J.D., Norton E.W. (1969). Follow-up study of cystoid macular edema following cataract extraction. *Trans Am Acad Ophthalmol Otolaryngol*, Vol. 73, No. 4, pp. (665-682).
- Gulkilik G., Kocabora S., Taskapili M. & Engin G. (2006). Cystoid macular edema after phacoemulsification: risk factors and effect on visual acuity. *Can J Optalmol*, Vol. 41, pp. (699-703).
- Heier, J.S., Topping, T.M., Baumann, W., Dirks, M.,S. & Chern, S. (2000). Ketorolac versus Prednisolone versus Combination Therapy in the Treatment of Acute Pseudophakic Cystoid Macular Edema. *Ophthalmology*, Vol. 107, pp. (2034 -2039).
- Henderson, B.A., Kim, J.Y., Ament, C.S., Ferrufino-Ponce, Z.K., Grabowska, A. & Cremers, S.L. (2007). Clinical pseudophakic cystoid macular edema Risk factors for development and duration after treatment. *J Cataract Refract Surg*, Vol. 33, pp. (1550-1558).
- Ibanez H.E., Leshner M.P., Singerman L.J., Rice T.A. & Keep G.F. (1993). Prospective Evaluation of the Effect of Pseudophakic Cystoid Macula Edema on Contrast Sensitivity. *Arch Ophthalmol*, Vol. 111, pp. (1635-1639).
- Irvine, S.R. (1953). A newly defined vitreous syndrome following cataract surgery. *Am J Ophthalmol*, Vol. 36, No. 5, pp. (499-619).
- Irvine A.R. (1976). Cystoid maculopathy. *Surv Ophthalmol*, Vol. 21, pp. (1-17).
- Ismail R.A., Sallam A. & Zambarakji H.J. (2008). Pseudophakic macular edema and oral acetazolamide: an optical coherence tomography measurable, dose-related response. *Eur J Ophthalmol*, Vol. 18, No. 6, pp. (1011-1013).

- Italian Diclofenac Study Group. (1997). Efficacy of diclofenac eye drops in preventing postoperative inflammation and long-term cystoid macular edema. *J Cataract Refract Surg*, Vol. 23, pp. (183-189).
- Karacorlu, M., Ozdemir, H. & Karacorlu, S. (2003). Intravitreal triamcinolone acetonide for the treatment of chronic pseudophakic cystoid macular oedema. *Acta Ophthalmol Scand*, Vol. 81, pp. (648-652).
- Kaur I.P., Smitha R., Aggarwal D., Kapil M. (2002). Acetazolamide: future perspective in topical glaucoma therapeutics. *Int J Pharm*, Vol. 248, No. 1-2, pp. (1-14).
- Kim SJ & Bressler NM. (2007). Analysis of macular edema after cataract surgery in patients with diabetes using optical coherence tomography. *Ophthalmol*, Vol. 114, No. 5, pp. (881-889).
- Koutsandrea, C.C., Moschos, M.M., Brouzas, D., Loukianou, E., Apostolopoulos M. & Moschos, M. (2007). Intraocular triamcinolone acetonide for cystoid macular edema. *Optical Coherence Tomography and multifocal electroretinography study. Retina*, Vol. 27, pp. (159 -164).
- Kraff M.C., Sanders D.R., Jampol L.M. & Lieberman H.L. (1985). Factors affecting pseudophakic cystoids macular edema: five randomized trials. *J Am Intraocular Implant Soc*, Vol. 11, pp. (380-385).
- Krishna R., Meisler D.M., Lowder C.Y., Estafanous M. & Foster R.E. (1998). Long-term follow-up of extracapsular cataract extraction and posterior chamber intraocular lens implantation in patients with uveitis. *Ophthalmology*, Vol. 105, pp. (1765-1769).
- Lightman S. & Chan C.C. (1990). Immune mechanisms in choroido-retinal inflammation in man. *Eye*, Vol. 4, pp. (345-353).
- Loewenstein A. & Zur D. (2010). Postsurgical Cystoid Macular Edema. *Dev Ophthalmol*, Vol. 47, pp. (148-159).
- Maca S.M., Amon M., Findl O., Kahraman G. & Barisani-Asenbauer T. (2010). Efficacy and tolerability of preservative-free and preserved diclofenac and preserved ketorolac eye drops after cataract surgery. *Am J Ophthalmol*, Vol. 149, No. 5, pp. (777-784).
- Mao L.K. & Holland P.M. (1988). "Very late onset" cystoid macular edema. *Ophthalmic Surg*, Vol. 19, pp. (633-635).
- Masoud S., Saeed K., Azireza R. & Peyman, G.A. (2010). Pilot study of intravitreal injection of diclofenac for treatment of macular edema of various etiologies. *Retina*, Vol. 30, No. 3, pp. (509-515).
- Mentes J., Erakgun T., Afrashi F. & Kerici G. (2003). Incidence of cystoid macular edema after uncomplicated phacoemulsification. *Ophthalmologica*, Vol. 217, pp. (408-412).
- Miyake K., Sakamura S. & Miura H. (1980). Long-term follow-up study on prevention of aphakic cystoid macular oedema by topical indomethacin. *Br J Ophthalmol*, Vol. 64, pp. (324-328).
- Miyake K., Mibu H., Horiguchi M. & Shirasawa E. (1990). Inflammatory mediators in postoperative aphakic and pseudophakic baboon eyes. *Arch Ophthalmol*, Vol. 108, pp. (1764-1767).
- Miyake K., Masuda K., Shirato S., Oshika T., Eguchi K., Hoshi H., Majima Y., Kimura W. & Hayashi F. (2000). Comparison of diclofenac and fluorometholone in preventing cystoid macular edema after small incision cataract surgery: a multicentered prospective trial. *Jpn J Ophthalmol*, Vol. 44, pp. (58-67).

- Miyake K., Sakamura S., Miura Iwao M., Inatani M., Iwao K. & Kawaji T. (2008). Cystoid macular edema caused by intraocular lens dislocation after trabeculectomy. *Can J Ophthalmol*, Vol. 43, No. 6, pp. (728-729).
- Nagpal M., Nagpal K. & Nagpal P.N. (2001). Postcataract cystoid macular edema. *Ophthalmol Clin North Am*, Vol. 14, pp. (651-659).
- Nikica G., Ljerka HP., Jelena P., Metez-Soldo K. & Mladen B. (1992). Cystoid macular edema in anterior chamber lens implantation following posterior capsule rupture. *Doc Ophthalmol*, Vol. 81, pp. (309-315).
- Nottage J.M., Bhasin V. & Nirankari V.S. (2009). Long-term safety and visual outcomes of transscleral sutured posterior chamber IOLs and penetrating keratoplasty combined with transscleral sutured posterior chamber IOLs. *Trans Am Ophthalmol Soc*, Vol. 107, pp. (242-250).
- Panteleontidis V., Detorakis E.T., Pallikaris I.G., Tsilimbaris M.K. (2010). Latanoprost-dependent cystoid macular edema following uncomplicated cataract surgery in pseudoexfoliative eyes. *Ophthalmic Surg Lasers Imaging*, Vol. 9, pp. (1-5).
- Pendergast S.D., Margherio R.R., Williams G.A. & Cox M.S. (1999). Vitrectomy for chronic pseudophakic cystoid macular edema unresponsive to medical treatment. *Am J Ophthalmol*, Vol. 128, pp. (317-323).
- Percival P. (1981). Clinical factors relating to cystoid macular edema after lens implantation. *J Am Intraocul Implant Soc*, Vol. 7, pp. (43-45).
- Peyman G.A., Canakis C., Livir-Rallatos C. & Conway M.D. (2002). The effect of internal limiting membrane peeling on chronic recalcitrant pseudophakic cystoid macular edema: a report of two cases Brief report. *Am J Ophthalmol*, Vol. 133, No. 4, pp. (571-572).
- Pollack A., Leiba H., Bukelman A. & Oliver M. (1992). Cystoid macular oedema following cataract extraction in patients with diabetes. *Br J Ophthalmol*, Vol. 76, pp. (221-224).
- Powe N.R., Schein O.D., Gieser S.C., Tielsch J.M., Luthra R., Javitt J. & Steinberg E.P. (1994). Synthesis of the literature on visual acuity and complications following cataract extraction with intraocular lens implantation. Cataract Patient Outcome Research Team. *Arch Ophthalmol*, Vol. 112, pp. (239-252).
- Quillen D.A. & Blodi B.A. (2002). *Clinical Retina*, AMA Press, ISBN 1-57947-284-2, USA.
- Ray S & D'Amico DJ. (2002). *Semin Ophthalmol*, Vol. 17, No. 3-4, pp. (167-180).
- Reis A., Birnbaum F., Hansen L.L. & Reinhard T. (2007). Successful treatment of cystoid macular edema with valdecoxib. *J Cataract Refract Surg*, Vol. 33, pp. (682-685).
- Rho, D.S. (2003). Treatment of acute pseudophakic cystoid macular edema: Diclofenac versus ketorolac. *J Cataract Refract Surg*, Vol. 29, pp. (2378-2384).
- Ross L., Chaudhwi J. & Dickersin K. (1998). Medical prophylaxis and treatment of cystoid macular edema after cataract surgery. The Results of a Meta-analysis. *Ophthalmol*, Vol. 105, No. 3, pp. (397-405).
- Rossetti L. & Autelitano A. (2000). Cystoid macular edema following cataract surgery. *Curr Opin Ophthalmol*, Vol. 11, pp. (65-72).
- Rotsos T.G. & Moschos M.M. (2008). Cystoid Macular Edema. *Clin Ophthalmol*, Vol. 2, No. 4, pp. (919-930).
- Schatz H., Atienza D., McDonald H.R. & Johnson R.N. (1994). Severe diabetic retinopathy after cataract surgery. *Am J Ophthalmol*, Vol. 117, pp. (314-321).
- Sobrin L. & D'Amico D.J. (2005). Controversies in Intravitreal Triamcinolone Acetonide Use. *Int Ophthalmol Clin*, Vol. 45, No. 4, pp. (133-141).

- Sorr E.M., Everett W.G., Hurite F.G. (1979). Incidence of fluorescein angiographic subclinical macular edema following phacoemulsification of senile cataracts. *Trans Am Acad Ophthalmol*, Vol. 86, pp. (2013-2018).
- Suresh P.S. & Jones N.P. (2001). Phacoemulsification with intraocular lens implantation in patients with uveitis. *Eye*, Vol. 15, pp. (621-628).
- Tao Y. & Jonas J.B. (2011). Intravitreal triamcinolone. *Ophthalmologica*, Vol. 225, No. 1, pp. (1-20).
- Thomas J.V., Gragoudas E.S., Blair N.P. & Lopus J.V. (1978). Correlation of epinephrine use and macular edema in aphakic glaucomatous eyes. *Arch Ophthalmol*, Vol. 96, pp. (625-628).
- Tsilimbaris MK, Panagiotoglou TD, Tsika C, Pandeledonidis V, Kymionis G. (2008). Intravitreal Injection of Ketorolac Tromethamine in Postoperative Cystoid Macular Edema. *Invest Ophthalmol Vis Sci*, 49: E-Abstract 2693
- Tso M.O. (1982). Pathology of cystoid macular edema. *Ophthalmol*, Vol. 89, pp. (902-915).
- Tunc M., Lahey J.M., Kearney J.J., Lewis J.M. & Francis R. (2007). Cystoid macular oedema following pneumatic retinopexy vs scleral buckling. *Eye*, Vol. 21, No. 6, pp. (831-834).
- Ursell P.G., Spalton D.J., Whitcup S.M. & Nussenblatt R.B. (1999). Cystoid macular edema after phacoemulsification: relationship to blood-aqueous barrier damage and visual acuity. *J Cataract Refract Surg*. Vol. 25, No. 11, pp. 1492-1497.
- Van der Schaft T.L., van Rij G., Renardel de Lavalette J.G. & Beekhuis W.H. (1989). Results of penetrating keratoplasty for pseudophakic bullous keratopathy with the exchange of an intraocular lens. *Br J Ophthalmol*, Vol. 73. No. 9, pp. (704-708).
- Wafapoor H. & McCluskey J. (2006). Intravitreal Ketorolac as a Treatment of Diabetic and Non-Diabetic Macular Edema. *Invest Ophthalmol Vis Sci*, Vol.47: E-Abstract 4252.
- Wakefield D. & Lloyd A. (1992). The role of cytokines in the pathogenesis of inflammatory eye disease. *Cytokine*, Vol. 4, pp. (1-5).
- Warren K.A. & Fox J.E. (2008). Topical Nepafenac as an alterant treatment for cystoid macular edema in steroid responsive patients. *Retina*, Vol. 28, pp. (1427-1434).
- Wetzig P.C., Thatcher D.B. & Christiansen J.M.(1979). The intracapsular versus the extracapsular cataract technique in relationship to retinal problems. *Trans Am Ophthalmol Soc*, Vol. 77, pp. (339-347).
- Weisz, J.M., Bressler, N.M., Bressler, S.B. & Schachat, A.P. (1999). Ketorolac treatment of pseudophakic cystoid macular edema identified more than 24 months after cataract extraction. *Ophthalmology*, Vol. 106, pp. (1656 -1659).
- Wittppenn J.R., Silverstein S., Heier J., Kenyon K.R., Hunkeler J.D. & Earl M., on behalf of the Acular LS for Cystoid Macular Edema (ACME) Study Group. (2008). A randomized, masked comparison of topical ketorolac 0.4 plus steroid vs steroid alone in low-risk cataract surgery patients. *Am J Ophthalmol*, Vol.146, pp. (554 -560).
- Xu H., Chen M., Forrester J.V. & Lois N. (2011). Cataract Surgery Induces Retinal Pro-inflammatory Gene Expression and Protein Secretion. *Invest Ophthalmol Vis Sci*, Vol. 52, pp. (249 -255).
- Yanoff M., Fine B.S., Brucker A.J. & Eagle R.C. Jr. (1984). Pathology of human cystoid macular edema. *Surv Ophthalmol*, Vol. 28(Suppl), pp. (505-511).
- Yannuzzi L.A., Landau A.N. & Turtz A.I. (1981). Incidence of aphakic cystoid macular edema with the use of topical indomethacin. *Ophthalmology*, Vol. 88 ,pp. (947-953).
- Yeh P.C. & Ramanathan S. (2002). Latanoprost and clinically significant cystoid macular edema after uneventful phacoemulsification with intraocular lens implantation. *J Cataract Refract Surg*, Vol. 28, No. 10, pp. (1814-1818).