

# We are IntechOpen, the world's leading publisher of Open Access books Built by scientists, for scientists

4,300

Open access books available

117,000

International authors and editors

130M

Downloads

Our authors are among the

154

Countries delivered to

TOP 1%

most cited scientists

12.2%

Contributors from top 500 universities



WEB OF SCIENCE™

Selection of our books indexed in the Book Citation Index  
in Web of Science™ Core Collection (BKCI)

Interested in publishing with us?  
Contact [book.department@intechopen.com](mailto:book.department@intechopen.com)

Numbers displayed above are based on latest data collected.  
For more information visit [www.intechopen.com](http://www.intechopen.com)



## Early Post-Operative Complications in Cataract Surgery

Emin Kurt<sup>1,\*</sup> and Hüseyin Mayalı<sup>2</sup>

<sup>1</sup>*Department of Ophthalmology, Celal Bayar University, Manisa,*

<sup>2</sup>*Eye Clinic, Buca Gynaecology and Paediatric Hospital, İzmir, Turkey*

### 1. Introduction

To date a number of techniques have been used for cataract surgery. However phacoemulsification is the most common method. Other methods such as intra- and extracapsular cataract extraction, mini-nuc, phacosection, sandwich and phacolit have also been used by many surgeons. Over the years, the techniques of cataract surgery have evolved into a safe and successful procedure for visual rehabilitation. The incidence of most complications has significantly decreased with better instrumentation and affordable high quality intraocular lens implants. Better pre-operative evaluation has helped. This has also reduced the number of poor results owing to the presence of other eye diseases in a patient. However some risk factors are intrinsic to the patient and, short of avoiding surgery altogether, very little can be done to eliminate them. In the event of surgery, high-risk cases should be operated on in an appropriate setting, by a surgeon who has the right level of experience. Although cataract surgery is safe for the majority of patients, some complications that involve the anterior and the posterior segment can occur. Cataract surgery complications can be divided into intraoperative complications, and postoperative complications. These complications are anaesthesia-related complications, posterior capsular rupture and vitreous loss, vitreous prolapse, expulsive haemorrhage, Descemet's membrane detachment, intraocular haemorrhage, wound malapposition, shallow anterior chamber, iris prolapse, infectious endophthalmitis, corneal oedema, dropped nucleus or retained nuclear fragments, suture-induced astigmatism, cystoid macular oedema, retinal detachment, posterior capsule opacification, and bullous keratopathy. The most important of these complications are often associated with posterior capsular rupture and infectious endophthalmitis. The incidence of posterior capsule tear during cataract surgery ranges from 0.2% to 16.0%. A higher incidence of posterior capsule tear and vitreous loss is associated with pseudoexfoliation, diabetes mellitus, trauma, hard or brunescient nuclei, and white cataract. Postoperative endophthalmitis remains a devastating outcome after cataract surgery, despite improved methods of prophylaxis, surgical technique, and treatment. This complication causes significant morbidity and distress and often severe visual impairment or blindness. The reported incidence of endophthalmitis after cataract surgery varies considerably around the world. Occurring about once every 500 operations worldwide, the relatively low incidence of endophthalmitis makes it

---

\* Corresponding Author

difficult to identify the risk factors clearly. If the posterior capsule tear causes occur vitreous loss and dropped fragments or nucleus drop it can lead to long-standing uveitis, vitritis, cystoid macular oedema, and secondary glaucoma. In the late period it is important to be vigilant in terms of posterior capsular opacification and retinal detachment. In this review, the diagnosis, treatment and prevention of early postoperative complications of cataract surgery are discussed. Early recognition and prompt treatment of these problems can minimize the risk of ocular morbidity.

## 2. Endophthalmitis

Infectious endophthalmitis following cataract surgery is still a devastating condition, despite major improvements in surgical techniques in the last decades. Most series report on an incidence rate ranging from 0.05% to 0.4% in different studies worldwide (Melo et al., 2010; Taban et al., 2005).

Infectious endophthalmitis is defined as infection causing severe inflammation involving both the anterior and posterior segments of the eye after intraocular surgery. It is a serious intraocular inflammatory condition that also results in infection of the vitreous cavity (Lemley & Han, 2007). Although it is rare, it has the potential to have a severe impact on vision and may even lead to a loss of the eye. Fortunately a number of factors including increased knowledge of the pathogenesis of the condition, improved surgical and diagnostic techniques, and a wider choice of management options have led to a decrease in the incidence of post-surgical cases.

Typically, postoperative endophthalmitis is caused by the peri-operative introduction of microbial organisms into the eye. The primary source of this intraocular infection is considered to be bacteria from the patient's ocular cornea, conjunctiva, lacrimal glands, blepharitis, and extraocular muscles (Maguire, 2008). However, contamination of sterilized instruments, disposable supplies, prepared solutions, the surgical field, or the intraocular lens, have been reported. Epidemic clusters of endophthalmitis have resulted from these types of external contaminations (Cruciani et al., 1998; Gibb et al., 2006).

The bacteria most frequently isolated are Gram-positive coagulase-negative cocci which account for 70% of culture-positive cases. Gram-negative bacteria account for just 6% of culture-positive cases; however, an infection with these bacteria, particularly with *Pseudomonas aeruginosa*, can lead to a devastating visual outcome (Eifring et al., 2003; Mamalis et al., 2002).

Once organisms gain access to the vitreous cavity, overwhelming inflammation is likely to occur, making rapid recognition, diagnosis and treatment critical in optimizing final outcomes. Although most cases of postoperative endophthalmitis occur within 6 weeks of surgery, infections seen in high-risk patients or infections caused by slow-growing organisms may occur months or years after the procedure (Cruciani et al., 1998; Eifrig et al., 2002; Taban et al., 2005).

The most common risk factors are posterior capsular rupture, retained lens material, the specific surgical procedure, wound leak and less experienced surgeons. Published studies have demonstrated an increased risk of endophthalmitis after placement of a secondary intraocular lens, possibly due to prolonged surgical time or ocular manipulation (Eifrig et al., 2002). Prolene haptic sutures have also been implicated as a possible risk factor. Other factors that are more controversial include increased patient age, corneal incision site and wound configuration (Chan et al., 2010).

Cataract patients with an acute postoperative form of infectious endophthalmitis may present as early as the day after surgery or up to two weeks later. Common clinical ocular associations include injection, conjunctival chemosis, purulent discharge, corneal oedema, anterior chamber cell and flare reaction, hypopyon, vitreous opacification, choroidal swelling, periphlebitis, and retinal haemorrhages. Adnexal swelling may also be present. Symptoms classically include pain and decreased vision (Kamalarajah et al., 2004; Kressloff et al., 1998; Lemley & Han, 2007; Mamalis et al., 2002). The inflammation seen is significantly greater than that otherwise expected post cataract surgery (Kamalarajah et al., 2004).

Taking appropriate measures to prevent endophthalmitis is crucial. Many different factors in cataract surgery have been investigated extensively for their role as a risk factor for endophthalmitis. Currently, the three most accepted methods of reducing the risk are to use an appropriate antiseptic solution (povidone-iodine), adequate draping of the surgical field to exclude the eyelashes and the use of intracameral antibiotics, such as cefuroxime at the conclusion of surgery (Chan et al., 2010).

A definitive approach to treatment of postoperative endophthalmitis is not uniformly agreed upon by many vitreoretinal surgeons. Therapeutics generally involves administration of intravitreal broad spectrum antibiotics with associated vitreous tap/biopsy (VTB) or pars plana vitrectomy (PPV). The choice of topical, peri-ocular, and even systemic antibiotics is increasingly controversial compared with 10 years ago (Maguire, 2008).

Most cases are caused by Gram-positive and Gram-negative micro-organisms. The antibiotics selected should cover the broad range of Gram-positive and Gram-negative organisms causing clinical endophthalmitis. Antibiotics can be delivered into the eye by several routes, including direct intraocular injection, systemic administration, peri-ocular injection, and topical application (Table 1). Out of all the available antimicrobial agents evaluated for intraocular injection only a few are used regularly in clinical practice. Intraocular vancomycin in combination with an aminoglycoside has been a commonly used regimen for the initial empiric treatment of presumed bacterial endophthalmitis (Flynn et al., 1991).

An alternative to the aminoglycosides for coverage of Gram-negative organisms is the use of intraocular ceftazidime, a third-generation cephalosporin (Campochiaro & Green, 1992; Jay et al., 1987; Stonecipher et al., 1991). These antibiotic combinations will theoretically provide broad coverage for nearly all of the organisms causing bacterial endophthalmitis (Stonecipher et al., 1991).

Intravitreal administration is used in order to deliver a high concentration of antibiotic directly in the eye. However, repetitive injections of intraocular antibiotics may cause significant retinal toxicity. In a rabbit model, eyes treated with a second or third intraocular vancomycin/aminoglycoside injection at 48-hour intervals showed progressive toxicity (Oum et al., 1989). Topical and subconjunctival antibiotics are often prescribed in addition to intravitreal antibiotics in order to increase the concentration of antibiotics within the anterior segment of the eye. Aqueous and vitreous solution samples are usually taken and sent to the laboratory for cultures. Vitreous samples are more likely to yield positive cultures. A smear placed on a glass slide and stained with a variety of chemicals provides a rapid result but it is not as sensitive or specific as results obtained from culture growth on different types of media. However, the latter can take up to a fortnight and therefore broad spectrum treatment must be provided until this is done (Barza et al., 1997).

Owing to concern as to whether intraocular antibiotics with or without vitrectomy are sufficient to treat infectious endophthalmitis, local ocular therapy is commonly supplemented with systemic antibiotics. Intraocular inflammation and/or performing a PPV alter the blood-retina barrier in a manner that allows better intravitreal penetration of systemically administered antibiotics (Meredith, 1993).

PPV may be necessary depending on level of vision. As a result of the EVS it is generally felt that in patients with light perception only or worse vision, PPV should be performed as the results of the study showed that these patients had a significantly better outcome compared with other modes of treatment (Endophthalmitis Vitrectomy Study Group [EVSG], 1995). The question arises whether PPV should be applied more frequently to patients presenting with vision of hand movements (HM) or better (Altan et al., 2009). The advantage of this procedure is that it enables the removal of a significant amount of the infecting organism, exo- and endotoxins, inflammatory agents, and any opacities and vitreous membranes that could result in retinal detachment (EVSG, 1995; Lemley & Han, 2007; Maguire, 2008).

Detractors of this approach have pointed to potential complications of surgery in severely inflamed eyes with poor visibility, a more rapid turnover of intravitreal antibiotics and the risks of delayed therapy (Maguire, 2008). Vitreal samples can easily be taken at the same time and subsequent intravitreal antibiotic distribution is greatly improved. However, significant inflammation may make visualisation difficult when performing the vitrectomy. Patients may also require multiple PPV procedures (Lemley & Han, 2007).

Intravenous Abs		
	Ceftazidime	2 g q 8 h (ciprofloxacin 750 p.o. bid) <sup>a</sup>
	Amikacin	6.0 mg/kg 12 h
Intravitreal Abs		
	Vancomycin	1.0 mg
	Amikacin	0.4 mg
Subconjunctival Abs		
	Vancomycin	25mg in 0.5 cc
	Ceftazidime	100mg in 0.5 cc
	Dexamethasone	6.0mg
Topical Abs		
	Vancomycin	50 mg/ml gtts q h
	Amikacin	20 mg/ml gtts q h
Steroids		
	Prednisone	30mg BID for 5–10 days

Abbreviations: Abs, antibiotics; bid, twice a day.

<sup>a</sup>In penicillin allergic patients.

Table 1. Standard pharmacological agents utilized in the Endophthalmitis Vitrectomy Study

### 3. Dropped nucleus

Loss of nuclear material into the vitreous cavity carries a major risk of loss of sight. This complicates 0.1% to 1% of cases of cataract extractions (Figure 1.) (Hoeve & Stilma, 2010). It



can happen in even experienced hands, and can be a worry as corrective action requires intervention in the posterior segment (Lu et al., 1999). Removing a dropped nucleus or even nuclear fragments is essential as it can either lead to long-standing uveitis, vitritis, cystoid macular oedema, and secondary glaucoma (Kaputsa et al., 1996; Lu et al., 1999).

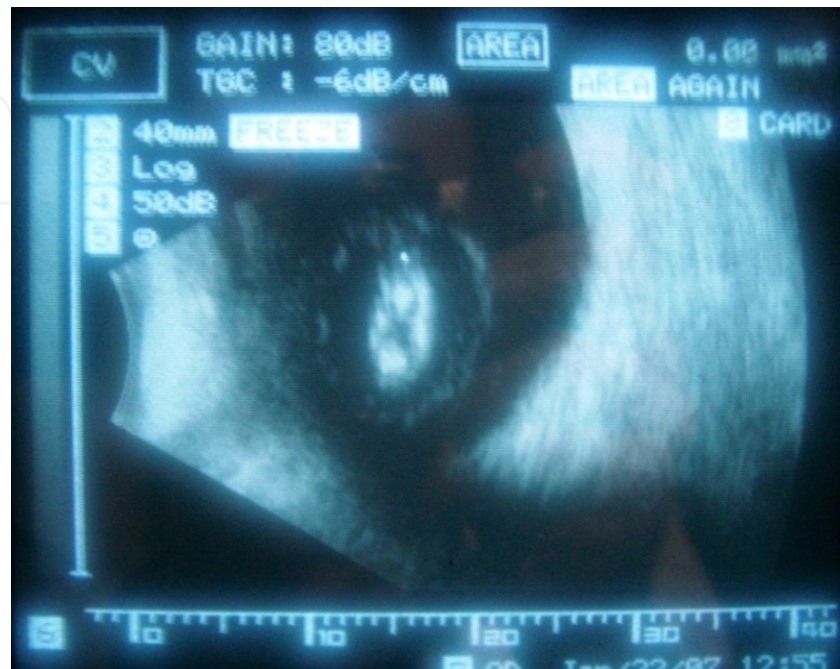

Fig. 1. Dropped nucleus

Clinical studies implicate posterior extension of breaks in the capsulorrhexis as a common cause of this complication. Congenital posterior polar cataract, which predisposes to posterior capsular dehiscence, is another risk factor for dropped nucleus (Kim & Miller, 2002). A higher incidence of posterior capsule tear and vitreous loss is associated with pseudoexfoliation, diabetes mellitus, trauma, hard or brunescent nuclei, and white cataract (Browning & Cobo, 1985; Guzek et al., 1987).

Management of these tears is especially difficult when the nucleus begins to drop into the vitreous. Rapid intervention is crucial to prevent the nucleus from dropping completely into the posterior vitreous. Manoeuvres performed through the anterior segment to retrieve the nuclear fragments can worsen the situation. Vitreous will prolapse through the surgical incision and, as a consequence, the partially dropped nuclear fragments might sink further back. Moreover, these manoeuvres can lead to serious late posterior segment complications and the risk for peripheral tears and retinal detachment (Gilliland et al., 1992; Lambrou & Stewart, 1992).

A dropped nucleus can lead to various problems that require additional treatment (Horiguchi et al., 2003). The surgeon should be familiar with the option of temporary aphakia or a sulcus lens and might also consider views of local surgeons performing PPV. Outcomes are typically excellent when there is minimal vitreous manipulation and traction and the residual lens material is removed in a controlled fashion by three-port PPV with phacofragmentation. It is recommended that PPV be performed within one to two weeks after cataract extraction (Hoeve & Stilma, 2010).

#### 4. Raised intraocular pressure

Elevated intraocular pressure is a common problem following cataract surgery. An increase in intraocular pressure frequently occurs after otherwise uneventful phacoemulsification cataract surgery. The exact mechanism responsible for the acute rise in intraocular pressure after phacoemulsification is not known but is probably multifactorial (Unal & Yücel, 2008). The first report of ocular hypertension one day after cataract surgery was documented by Gormaz in 1962 (Gormaz, 1962).

In most patients, postoperative increase in intraocular pressure following cataract surgery is transient and benign (Tranos et al., 2004). Nearly all patients' pressures returned to baseline with or without treatment. Some individuals, however, may experience pain, corneal oedema, glaucomatous nerve damage, or anterior ischemic optic neuropathy (Ermis et al., 2005).

Elevated pressure is the most frequent postoperative complication demanding treatment following phacoemulsification (Hildebrand et al., 2003). As many as 18% to 45% of patients may experience an intraocular pressure greater than 28 mm Hg following phacoemulsification, but most pressures will return to normal by 24 hours postoperatively (Tranos et al., 2004). The peaks most commonly occur 8 to 12 hours after surgery, and only 1.3% to 10.0% of cases record an intraocular pressure higher than 30 mm Hg 24 hours postoperatively. After uneventful phacoemulsification in eyes without glaucoma, however, intraocular pressure spikes may reach 68 mm Hg (Hildebrand et al., 2003). The causes of the elevated intraocular pressure are likely multifactorial (Table 2). Causes of elevated intraocular pressure are numerous (Bomer et al., 1995; Hildebrand et al., 2003; Tanaka et al., 1997; Thorofare & Slack, 2007).

Retained lens debris
Retained viscoelastic
Hyphaema or red blood cells
Watertight wound closure
Use of corneoscleral sutures vs. non-sutured incision
Steroid response (3 to 6 weeks after surgery)
Iris pigment release
Pre-existing glaucoma
Degree of surgical trauma
Secluded/occluded pupil with iris bombe
Uveitis or inflammatory cells
Expulsive haemorrhage
Aqueous misdirection
Epithelial down growth

Table 2. Causes of increased intraocular pressure following cataract surgery

It is well accepted that retained viscoelastic material inhibits aqueous outflow through the trabecular meshwork resulting in a higher incidence and degree of postoperative increase in intraocular pressure (Tanaka et al., 1997). Higher molecular weight viscoelastics have been shown to result in a higher rise in post-operative intraocular pressure (Borazan et al., 2007).

When considering the various causes of pressure elevation, topical steroids are often suspected. However, steroids in the immediate postoperative period are rarely a cause of pressure rise. Typically, a steroid-induced glaucoma requires 3 to 6 weeks of continuous use to elicit an intraocular pressure response (Thorofare & Slack, 2007).

The rise in intraocular pressure in the latter group will settle after discontinuation of topical steroids but those in the former group will often require anti-glaucoma medication or even surgery in more extreme cases (Chan et al., 2010). Surgical trauma, watertight wound closure, retained lenticular debris, the release of iris pigment, hyphaema, and inflammation are also thought to contribute to elevations in intraocular pressure (Hildebrand et al., 2003).

Patients at risk for a known increase in intraocular pressure and vision loss should be pretreated. There are several classes of drugs used to treat postoperative increases in intraocular pressure including: oral and topical carbonic anhydrase inhibitors (acetazolamide, brinzolamide, dorzolamide, and methazolamide), prostaglandin analogues (latanoprost, bimatoprost, and travoprost), alpha agonists (apraclonidine and brimonidine), beta blockers (timolol and levobunolol), and miotics (intracameral carbachol, pilocarpine, and intracameral acetylcholine). Although several drugs lower intraocular pressure after cataract surgery, none of them consistently prevents pressure increases from occurring (Browning et al., 2002; Byrd & Singh, 1998).

## 5. Iris prolapse

Iris prolapse can result from inadequate wound closure, accidental trauma, or raised intraocular pressure. Iris prolapse is extremely rare following small incision surgery but may occur after extracapsular cataract extraction (Figure 2) (Reddy, 1995). Complications include defective wound healing, chronic anterior uveitis, excessive astigmatism, endophthalmitis, cystoid macular oedema and epithelial ingrowth (Wright et al., 1988). Peribulbar or retrobulbar anaesthesia is necessary for iris manipulation. Treatment depends on the time interval between cataract surgery and identification of the prolapse. In cases of iris prolapse of less than 48 hours duration, the iris tissue can be repositioned. If however, the prolapse is of longer duration, the risk of infection mandates that the prolapsed section of iris is excised (Byrd & Singh, 1998).

## 6. Corneal oedema

Postoperative corneal oedema can be localized or diffuse. Postoperative localized stromal and/or epithelial oedema (Figure 3), especially in the half of the cornea near the main section indicates intraoperative trauma. Factors that predispose to corneal oedema following cataract surgery include the following: intraoperative mechanical endothelial trauma, prior endothelial disease or cell loss, excessive postoperative inflammation, and prolonged postoperative elevation of intraocular pressure (Reddy, 1995).

Raised intraocular pressure manifests as diffuse microcystic epithelial oedema, which is best visualized by retro-illumination. Postoperative corneal stromal oedema could also indicate pre-existing endothelial pathology as in Fuchs' endothelial dystrophy. Pre-operatively patients should be carefully examined for evidence of Fuchs' dystrophy or other conditions that produce a low endothelial cell count (Reddy, 1995; Wright et al., 1988; Yanoff & Duker, 2004).



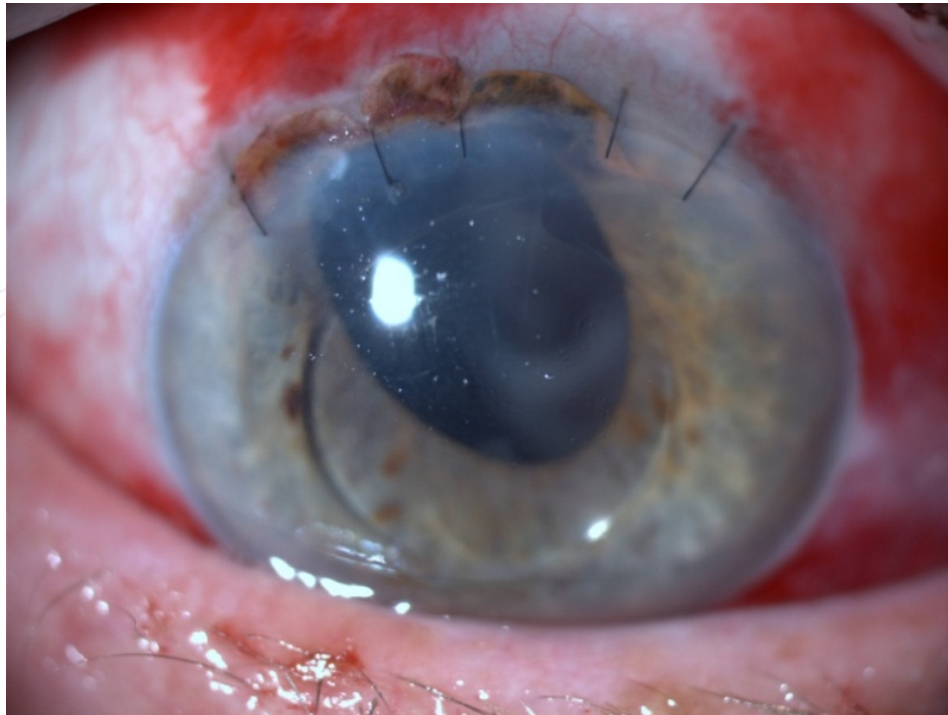

Fig. 2. Iris Prolapse (courtesy of Mehmet Baykara, Uludağ University, Bursa)

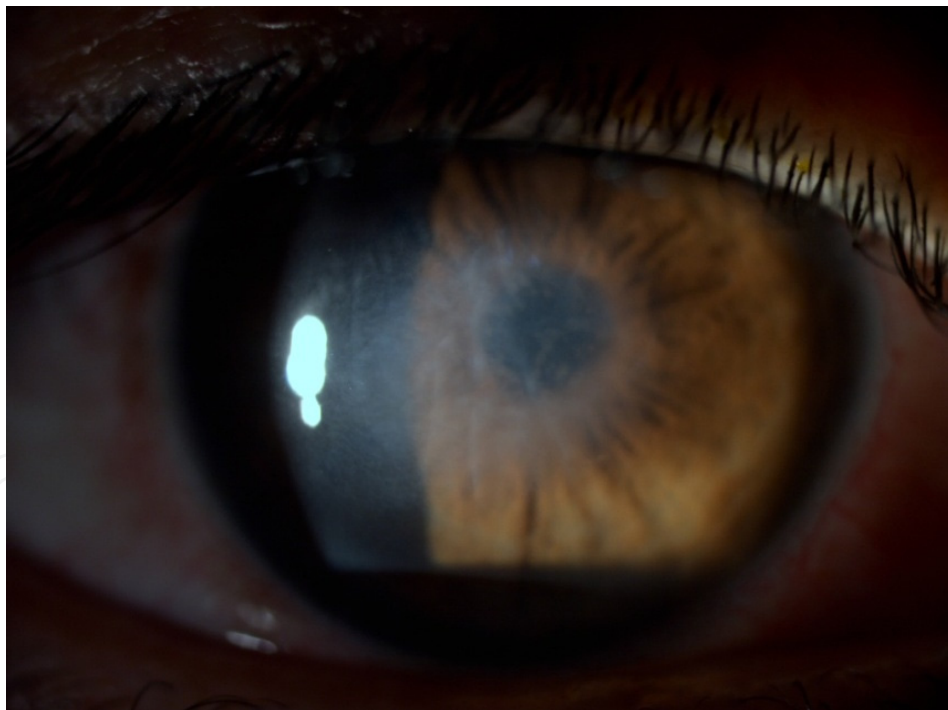


Fig. 3. Corneal Oedema

Previous studies have found that at birth the corneal endothelial cell density is approximately 5,000 cells/mm<sup>2</sup> and until the age of 20 years there is a significant decline in this number. Subsequently this decrease plateaus to a rate of 0.6% per year. In normal circumstances the reserves of endothelial cells mean that there are enough to last a lifetime (Edelhauser, 2000). The role of the corneal endothelium is to maintain the correct level of

corneal hydration. It forms a physical barrier between the corneal stroma and aqueous humour and acts as an ion pump. Injury of a significant number of cells results in significant decrease in endothelial cell density and this can impair the ability of the endothelium to maintain corneal clarity, resulting in irreversible corneal oedema. The patient will experience permanent blurring in their vision and ocular pain. There are a number of factors that could lead to endothelial damage during phacoemulsification (Takahashi, 2005).

Localised temperature increases associated with the phacoemulsification probe can lead to thermal damage to adjacent corneal tissue. Some types of phaco probes are now available with cooling functions to counteract this effect. High irrigation or aspiration rates can result in turbulent flow and air bubbles or lens particles connecting with and causing damage to the endothelium. It may be possible to adjust irrigation and aspiration flow rates to minimise this. Excessive duration of phacoemulsification may also result in endothelial cell damage. The ultrasound energy utilised in phacoemulsification is also associated with the production of free radicals (Holst et al., 1993). Free radicals are reactive species with one or more unpaired electrons in their outer orbits. Such chemicals can cause damage to the corneal endothelium known as oxidative stress (Yanoff & Duker, 2004).

Pseudophakic bullous keratopathy describes the irreversible oedema and endothelial cell damage that occurs after cataract surgery. The advent of phacoemulsification techniques and the use of IOLs and ophthalmic viscosurgical devices have helped to reduce the number of cases of pseudophakic bullous keratopathy following cataract surgery (Kang et al., 2005). The most common cause of corneal endothelial decompensation is surgical trauma (Narayanan et al., 2006).

Postoperatively corneal oedema and inflammation should be aggressively treated with topical corticosteroids, and intraocular pressure should be controlled below 20 mmHg. In patients with diffuse epithelial oedema, tonometry should be performed and if intraocular pressure is raised, the condition should be treated with topical and/or systemic anti-glaucoma medication. Reduction of intraocular pressure is important for reducing the corneal oedema because increased intraocular pressure can compromise endothelial cell function, lead to epithelial oedema, and cause further endothelial damage (Narayanan et al., 2006; Yanoff & Duker, 2004).

Therapy for pseudophakic corneal oedema and aphakic corneal oedema is aimed at reducing discomfort and/or increase visual acuity. The corneal oedema associated with phacoemulsification is chronic and usually non-inflammatory. Several medical treatment options are available. Epithelial oedema can often be managed with topical hypertonic agents such as sodium chloride (5%) ointment or drops. Hypertonic eye ointment at night is particularly useful because the oedema tends to be more severe on waking in the morning because of lack of evaporation during the night when the eyes are closed (Narayanan et al., 2006).

## 7. Toxic anterior segment syndrome

Toxic anterior segment syndrome is an acute, sterile, anterior segment inflammation that can occur after any anterior segment surgery. Early and intense postoperative inflammation after anterior segment surgery accompanied by minimal or no pain, fibrin formation, corneal oedema and the absence of vitreous involvement are the diagnostic criteria for toxic anterior segment syndrome. It almost always occurs as a complication of uneventful cataract surgery or anterior segment surgery and can result in damage to the intraocular tissues (Huang et al., 2010).

Toxic anterior segment syndrome most commonly occurs acutely following anterior segment surgery, typically 12-72 h after cataract extraction. Anterior segment inflammation is usually quite severe with hypopyon. Endothelial cell damage is common, resulting in diffuse corneal oedema. Most patients are asymptomatic with the exception of blurred vision; others may complain of mild discomfort. No bacterium is isolated from ocular samples. The causes of toxic anterior segment syndrome are numerous and difficult to isolate (Cornut & Chiquet, 2011).

The primary differential diagnosis is infectious endophthalmitis (Table 3). Development of new techniques such as polymerase chain reaction may prove more useful in the differentiation of sterile endophthalmitis and early infectious endophthalmitis (Holland et al., 2007; Van Gelder, 2001). Fibrinous uveitis of its own does not usually cause corneal clouding but can also enter the differential diagnosis.

Characteristics	Infectious endophthalmitis	Toxic anterior segment syndrome
Onset	3-7 days	1-3 days
Symptoms	Pain, blurred vision	Blurred vision
Cornea	Oedema 2 +	Oedema 1 +
Anterior chamber	Cells 3 +, Fibrin variable, Hypopyon 3 +	Cells 1-3 +, Fibrin 1-3 +, Hypopyon 1 +
Vitreous	Vitritis	Clear
Response to steroids	Negative	Positive

Table 3. Diagnosis: infectious endophthalmitis versus toxic anterior segment syndrome

Anterior segment findings include fibrin formation with occasional hypopyon and, in later stages, inflammatory membranes that can cause pupil distortion and glaucoma. Severe disease can lead to permanent endothelial damage, profound cystoid macular oedema, a permanently dilated pupil, and even permanent damage to the trabecular meshwork leading to resistant glaucoma that requires multiple operations (Holland et al., 2007; Parikh & Edelhauser, 2003).

Toxic anterior segment syndrome has numerous causes, and most cases are attributed to 1) contaminants on surgical instruments, resulting from improper or insufficient cleaning; 2) products introduced into the eye during surgery, such as irrigating solutions or ophthalmic medications; or 3) other substances that enter the eye during or after surgery, such as topical ointments or talc from surgical gloves (Mamalis et al., 2006).

Gram-negative bacteria may proliferate if the water reservoir in the phaco machine or inside the autoclave is not replaced on a regular basis. Gram-negative bacteria are typically destroyed during the autoclaving procedure; however, heat-stable lipopolysaccharide endotoxin may remain behind. Endotoxin deposits are removed only by acetone or alcohol if operating instruments are dry. If heat-stable lipopolysaccharide endotoxin gets into the eye during the operation, it may cause severe anterior segment inflammation. Prevention of Toxic anterior segment syndrome primarily depends on using appropriate protocols for cleaning and sterilizing surgical equipment and paying careful attention to all solutions, medications and ophthalmic devices used during anterior segment surgery (Avisar & Weinberger, 2010; Mamalis et al., 2006).

Management of toxic anterior segment syndrome involves use of topical steroids every hour and non-steroidal anti-inflammatory drugs (NSAIDs) every 6 hours. Milder cases will resolve from within a few days to 1 to 3 weeks, but if persisting for more than 6 weeks more dire consequences are likely (Parikh & Edelhauser, 2003).

## 8. References

- Altan T, Acar N, Kapran Z, Unver YB, Yurttaser S, Küçüksümer Y, & Eser I. Acute-onset endophthalmitis after cataract surgery: success of initial therapy, visual outcomes, and related factors. *Retina*, vol. 29, pp. 606-612, 2009.
- Avisar R, & Weinberger D. Corneal endothelial morphologic features in toxic anterior segment syndrome. *Cornea*, vol. 29, pp. 251-3, 2010.
- Barza M, Pavan PR, Doft BH, Wisniewski SR, Wilson LA, Han DP, & Kelsey SF. Evaluation of microbiological diagnostic techniques in postoperative endophthalmitis in the Endophthalmitis Vitrectomy Study. *Archives of Ophthalmology* vol. 115, pp. 1142-1150, 1997.
- Bomer TG, Lagreze W-DA, & Funk J. Intraocular pressure rise after phacoemulsification with posterior chamber lens implantation: effect of prophylactic medication, wound closure, and surgeon's experience. *British Journal of Ophthalmology*, vol. 79, pp.809-813. 1995.
- Borazan M, Karalezli A, Akman A, & Akova YA. Effect of antiglaucoma agents on postoperative intraocular pressure after cataract surgery with Viscoat. *Journal of Cataract and Refractive Surgery*, vol. 33, pp. 1941-1945, 2007.
- Browning DJ, & Cobo LM. Early experience in extracapsular cataract surgery by residents, *Ophthalmology*, vol. 92, pp. 1647-1653, 1985.
- Browning AC, Alwitry A, Hamilton R, Rotchford A, Bhan A, & Amoaku WM. Role of intraocular pressure measurement on the day of phacoemulsification cataract surgery. *Journal of Cataract and Refractive Surgery*, vol. 28, pp. 1601-1606, 2002.
- Byrd S, & Singh K. Medical control of intraocular pressure after cataract surgery. *Journal of Cataract and Refractive Surgery*, vol. 24, pp. 1493-1497, 1998.
- Campochiaro PA, & Green WR. Toxicity of intravitreal ceftazidime in primate retina. *Archives of Ophthalmology*, vol. 110, pp. 1625-1629, 1992.
- Chan E, Mahroo AR, & Spalton DJ. Complications of cataract surgery. *Clinical & Experimental Optometry* vol. 93, pp. 379-389, 2010.
- Cornut PL, & Chiquet C. Toxic anterior segment syndrome. *Journal de Français d'Ophthalmologie*, vol. 34, pp. 58-62, 2011.
- Cruciani M, Malena M, Amalfitano G, Monti P, & Bonomi L. Molecular epidemiology in a cluster of cases of postoperative *Pseudomonas aeruginosa* endophthalmitis. *Clinical Infectious Disease*, vol. 26, pp. 330-333, 1998.
- Edelhauser HF. The Resiliency of the Corneal Endothelium to Refractive and Intraocular Surgery. *Cornea*, vol. 19, pp. 263-273, 2000.
- Eifrig CW, Flynn HW Jr, Scott IU, & Newton J. Acute-onset postoperative endophthalmitis: review of incidence and visual outcomes (1995-2001). *Ophthalmic Surgery and Lasers*, vol. 33, 373-378, 2002.
- Eifrig CWG, Scott IU, Flynn HW Jr, & Miller D. Endophthalmitis caused by *Pseudomonas aeruginosa*. *Ophthalmology* vol. 110, pp. 1714-1717, 2003.



- Endophthalmitis Vitrectomy Study Group. Results of the endophthalmitis vitrectomy study (1995) a randomized trial of immediate vitrectomy and of intravenous antibiotics for the treatment of postoperative bacterial endophthalmitis. *Archives of Ophthalmology*, vol. 113, pp. 1479-1496, 1995.
- Ermis SS, Ozturk F, & Inan UU. Comparing the effects of travoprost and brinzolamide on intraocular pressure after phacoemulsification. *Eye*, vol. 19, pp. 303-307, 2005.
- Flynn HW Jr, Pulido JS, Pflugfelder SC, Davis JL, Culbertson WW, Roussel TJ, & Miller D. Endophthalmitis therapy: changing antibiotic sensitivity patterns and current therapeutic recommendations. *Archives of Ophthalmology*, vol. 109, pp. 175-176, 1991.
- Gibb AP, Fleck BW, & Kempton-Smith L. A cluster of deep bacterial infections following eye surgery associated with construction dust. *The Journal of Hospital Infection*, vol. 63, pp. 197-200, 2006.
- Gilliland GD, Hutton WL, & Fuller DG. Retained intravitreal lens fragments after cataract surgery. *Ophthalmology*, vol. 99, pp. 1263-1267, 1992.
- Gormaz A. Ocular tension after cataract surgery. *American Journal of Ophthalmology*, vol. 53, pp. 832-841, 1962.
- Guzek JP, Holm M, Cotter JB, Cameron JA, Rademaker WJ, Wissinger DH, Tonjum AM, & Sleeper LA. Risk factors for intraoperative complications in 1000 extracapsular cataract cases. *Ophthalmology*, vol. 94, pp. 461-466, 1987.
- Hildebrand GD, Wickremasinghe SS, Tranos PG, Harris ML, & Little BC. Efficacy of anterior chamber in controlling early intraocular pressure spikes after uneventful phacoemulsification. *Journal of Cataract and Refractive Surgery*, vol. 29, pp. 1087-1092, 2003.
- Hoeve M, & Stilma J. Dropped nucleus' on cataract extraction. *Nederlands Tijdschrift voor Geneeskunde*, vol. 154, pp.154, A1797, 2010.
- Holland SP, Morck DW, & Lee TL. Update on toxic anterior segment syndrome. *Current Opinion in Ophthalmology*, vol. 18, pp. 4-8, 2007.
- Holst A, Rolfsen W, Svensson B, Ilinger K, & Lundgren B. Formation of free radicals during phacoemulsification. *Current Eye Research*, vol. 12, pp. 359-365, 1993.
- Horiguchi M, Kojima Y & Shimada Y. Removal of lens material dropped into the vitreous cavity during cataract surgery using an optical fiber-free intravitreal surgery system. *Journal of Cataract and Refractive Surgery*, vol. 29, pp. 1256-1259, 2003.
- Huang Y, Dai Y, Wu X, Lan J, & Xie L. Toxic anterior segment syndrome after pediatric cataract surgery. *Journal of American Association for Pediatric Ophthalmology and Strabismus*, vol. 14, pp. 444-446, 2010.
- Jay WM, Fishman P, Aziz M, & Shockley RK. Intravitreal ceftazidime in a rabbit model: Dose- and time-dependent toxicity and pharmacokinetic analysis. *Journal of Ocular Pharmacology*, vol. 3, pp. 257-262, 1987.
- Kamalarajah S, Silvestri G, Sharma N, Khan A, Foot B, Ling R, Cran G, & Best RM. Surveillance of endophthalmitis following cataract surgery in the UK. *Eye*, vol. 18, pp. 580-587, 2004.
- Kang PC, Klintworth GK, Kim T, Carlson AN, Adelman R, Stinnett S, & Afshari NA. Trends in the indications for penetrating keratoplasty, 1980-2001. *Cornea*, vol. 24, pp. 801-803, 2005.



- Kapusta MA, Chen JC & Lam WC. Outcomes of dropped nucleus during phacoemulsification, *Ophthalmology*, vol. 103, pp. 1184-1187, 1996.
- Kim IK & Miller JW. Management of dislocated lens material. *Seminars in Ophthalmology*, vol. 17, pp 162-166, 2002.
- Kressloff MS, Castellarin A, & Zarbin MA. Endophthalmitis. *Survey of Ophthalmology*, vol. 43, pp. 193-224, 1998.
- Lambrou FH, & Stewart MW. Management of dislocated lens fragments during phacoemulsification, *Ophthalmology*, vol. 99, pp. 1260-1262, 1992.
- Lemley C A, Han, D P. Endophthalmitis A Review of Current Evaluation and Management. *Retina*, vol. 27, pp. 662-680, 2007.
- Lewis RA. What is the best way to prevent and manage postoperative intraocular pressure spikes? In: Chang DF (ed). *Curbside Consultation in Cataract Surgery*. Thorofare, NJ, Slack, 2007; 187-189.
- Lu H, Jiang YR, & Grabow HB. Managing a dropped nucleus during the phacoemulsification learning curve, *Journal of Cataract and Refractive Surgery*, vo. 25, pp. 447-450, 1999.
- Maguire JI. Postoperative endophthalmitis: optimal management and the role and timing of vitrectomy surgery. *Eye*, vol. 22, pp 1290-3000, 2008.
- Mamalis N, Kearsley L, & Brinton E. Postoperative endophthalmitis. *Current Opinion in Ophthalmology*, vol. 13, pp. 14-18, 2002.
- Mamalis N, Edelhauser HF, Dawson DG, Chew J, LeBoyer RM, & Werner L. Toxic anterior segment syndrome. *Journal of Cataract and Refractive Surgery*, vol. 32, pp. 324-333, 2006.
- Melo GB, Bispo PJ, Regatieri CV, Yu MC, Pignatari AC, & Höfling-Lima AL. Incidence of endophthalmitis after cataract surgery (2002-2008) at a Brazilian university-hospital. *Arquivos Brasileiros de Oftalmologia*, vol. 73, pp. 505-507, 2010.
- Meredith TA. Antimicrobial pharmacokinetics in endophthalmitis treatment: Studies of ceftazidime. *Transactions of the American Ophthalmological Society*, vol. 91, pp. 653-699, 1993.
- Narayanan R, Gaster RN, & Kenney MC. Pseudophakic corneal edema: A review of mechanisms and treatments. *Cornea*, vol. 25; pp. 993-1004, 2006.
- Oum BS, D'Amico DJ, & Wong KW. Intravitreal antibiotic therapy with vancomycin and aminoglycoside: An experimental study of combination and repetitive injections. *Archives of Ophthalmology*, vol. 107, pp. 1055-1060, 1989.
- Parikh CH, & Edelhauser HF. Ocular surgical pharmacology: corneal endothelial safety and toxicity. *Current Opinion in Ophthalmology*, vol. 14, pp. 178-185, 2003.
- Reddy MK. Complications of cataract surgery. *Indian Journal of Ophthalmology*, vol. 43, pp. 201-209, 1995.
- Stonecipher KG, Parmley VC, Jensen H, & Rowsey JJ. Infectious endophthalmitis following sutureless cataract surgery. *Archives of Ophthalmology*, vol. 109, pp. 1562-1563, 1991.
- Taban M, Behrens A, Newcomb RL, Nobe MY, Saedi G, Sweet PM, & McDonnell PJ. Acute endophthalmitis following cataract surgery: a systematic review of the literature. *Archives of Ophthalmology*, vol. 123, pp. 613-620, 2005.
- Takahashi H. Free Radical Development in Phacoemulsification. *Cataract Surgery Journal of Nippon Medical School*, vol. 72, pp. 4-12, 2005.

- Tanaka T, Inoue H, Kudo S, & Ogawa T. Relationship between postoperative intraocular pressure elevation and residual sodium hyaluronate following phacoemulsification and aspiration. *Journal of Cataract and Refractive Surgery*, vol. 23, pp. 284-288, 1997.
- Tranos P, Bhar G, & Little B. Postoperative intraocular pressure spikes: the need to treat. *Eye*, vol. 18, pp. 673-679, 2004.
- Unal M, Yücel I. Effect of bimatoprost on intraocular pressure after cataract surgery. *Canadian Journal of Ophthalmology*, vol. 43, pp. 712-716, 2008.
- Van Gelder RN. Applications of the polymerase chain reaction to diagnosis of ophthalmic disease. *Survey of Ophthalmology*, vol. 45, pp. 248-258, 2001.
- Wright PL, Wilkinson CP, Balyeat HD, Popham J, & Reinke M. Angiographic cystoid macular edema after posterior chamber lens implantation. *Archives of Ophthalmology*, vol. 106, pp. 740-744, 1988.
- Yanoff M, & Duker J. *Complications of Cataract Surgery*. 2nd ed. St. Louis: Mosby, 2004, pp. 381-390.