

We are IntechOpen, the world's leading publisher of Open Access books Built by scientists, for scientists

6,900

Open access books available

186,000

International authors and editors

200M

Downloads

Our authors are among the

154

Countries delivered to

TOP 1%

most cited scientists

12.2%

Contributors from top 500 universities



WEB OF SCIENCE™

Selection of our books indexed in the Book Citation Index
in Web of Science™ Core Collection (BKCI)

Interested in publishing with us?
Contact book.department@intechopen.com

Numbers displayed above are based on latest data collected.
For more information visit www.intechopen.com



Navigated Brain Stimulation (NBS) for Pre-Surgical Planning of Brain Lesion in Critical Areas: Basic Principles and Early Experience

Concetta Alafaci, Alfredo Conti and
Francesco Tomasello

Additional information is available at the end of the chapter

<http://dx.doi.org/10.5772/53216>

1. Introduction

Modern neurosurgery attempts to get the difficult goal of combining an "aggressive" resection of brain tumors with the fundamental purpose of preserving brain functions and best possible quality of life.

One of the most important evolutions of neurosurgical therapies is the opportunity to provide a customized surgical intervention by using modern methods to "map" the eloquent areas of the brain. This allows the identification of brain functional areas to be preserved from possible inadvertent intraoperative damage.

Direct cortical stimulation (DCS) is an intraoperative technique that uses electrodes placed directly on the exposed cortical surface of the brain to stimulate activity of functional areas by simultaneously recording the evoked responses peripherally. DCS is very precise and reliable and can be considered the gold standard in brain mapping and intraoperative functional monitoring. Nevertheless, the neurosurgeon discovers the spatial relationship between the disease and eloquent cortical surfaces only after having completed a craniotomy and dural opening.

A pre-surgical mapping method would give the opportunity to plan the treatment of brain diseases optimizing many aspects of the surgical treatment, including patient positioning, type of anesthesia, size of craniotomy, and extent of resection. Moreover, pre-surgical mapping would allow more precise prediction of the efficacy and risks of treatments that can be discussed with the patient and influence the therapeutic strategy.

New techniques have been proposed in an attempt to provide a reliable method for the functional study that can be, however, exploited pre-operatively. The most recent of these methods of mapping cortical activities is navigated brain stimulation (NBS), which is based on the neurophysiological technique of transcranial magnetic stimulation (TMS) of the cerebral cortex combined with the conventional neuronavigation. Basic principles of NBS will be here discussed together with our preliminary experience using this technique in different neurosurgical diseases.

2. Navigated Brain Stimulation for mapping the motor system

Navigated brain stimulation is a technique for mapping the motor cortex using a transcranial magnetic stimulation (TMS) of brain areas. In NBS, conventional TMS is combined with a sophisticated neuronavigation software that allows the navigation of each single “stimulated” point in the cortex. The electromagnetic stimulus delivered by the TMS coil overcomes the activation threshold of the underlying motor neurons, so that the impulse may propagate to the corticospinal tract determining a muscle contraction. Muscles responses to electric field (motor evoked potential, MEP) are recorded using EMG channels (Figure 1).

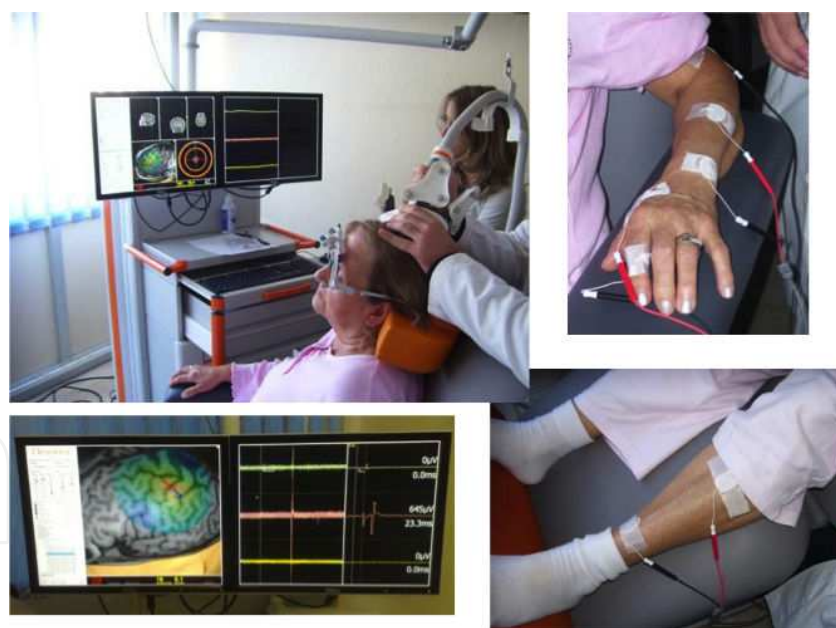

Figure 1. The navigated brain stimulation system Nexstim (Nexstim Ltd., Helsinki, Finland). With NBS, conventional transcranial magnetic stimulation is combined with a neuronavigation system that allows precise identification of each single “stimulated” point in the cortex on three-dimensional imaging study of the patient brain. Muscles responses to electric field (motor evoked potential, MEP) are recorded using EMG channels. The motor map obtained can be used for pre-surgical planning and integrated in the neuronavigation during surgical procedures.

This technique, that has been very recently developed [14], has several exciting clinical and research applications including:

Mapping motor areas for surgical oncology and epilepsy

Checking the integrity of post-stroke motor system

Mapping the motor response in post-traumatic spinal cord injury

Mapping of the areas that control language

Guiding the implantation of stimulating electrodes in the motor cortex

Stimulating the brain plasticity

Treating pain, tinnitus, depression

The first studies on NBS confirmed the safety and tolerability of this technique with no adverse events including pain and seizures, despite the majority of patients in the series had a history of epilepsy. Few patients may have a slight discomfort, and even fewer, a transient headache [14-16].

2.1. Transcranial Magnetic Stimulation

Transcranial magnetic stimulation is a noninvasive technique that allows a focal cortical stimulation. TMS uses electromagnetic induction to produce weak electric currents using a rapidly changing magnetic field. A plastic-enclosed coil of wire is held next to the skull and when activated, it produces a magnetic field oriented orthogonally to the plane of the coil. The magnetic field passes unimpeded through the skin and skull, inducing an oppositely directed current in the brain that activates nearby nerve cells in much the same way as currents applied directly to the cortical surface. The magnetic cortical stimulation is, therefore, a tool to drive in the brain an electrical stimulus generated outside of the head.

The method has, however, an inherent limitation: using a single coil the stimulus that results is not particularly focal and the magnetic field does not penetrate very deeply into the brain. This limitation has been solved through the use of "figure eight" or "butterfly" coils that make the area of overlap of the stimulus significantly more focal and increase the depth of the effect. A single stimulus generated by means of TMS lasts less than 1 ms; despite its brevity it has sufficient power to trigger the activation of many neurons below the coil and a consequent physiological complex chain reaction in the brain tissue that lasts for 50 - 100 ms. In fact, if initially only the neurons immediately below the coil reach the action potential, then it propagates through the synapses also to the adjacent neurons so that the neural response results amplified. This activation of neurons can then be followed by an inhibitory postsynaptic potential and by a period of electrical silence [17].

2.2. Electromyography

The NBS system records motor evoked potentials (MEP) produced by TMS through an electromyography system. Cortical representation of each muscle is a function of its level of innervation, being this latter an index of the degree of fineness of the movements that each muscle can accomplish. The muscles of the face, hand and leg have an extensive somatotopic cortical representation, and recording EMG activity of these muscles allow an almost com-

plete map of the primary motor cortex. It is possible to simultaneously map up to 6 muscles using the 6 EMG channels available in the NBS system.

Muscles of the thenar eminence are usually chosen in the group of muscles of the hand for their wide cortical representation (Figure 1). The mental muscle, being simple to relax for the patient, is frequently used for the group of facial muscles. The tibialis muscle is commonly used for leg function mapping [6].

It is possible to characterize the motor cortex on the basis of the amplitude of the MEP of each stimulated point. A map of colored dots, built on the basis of EMG recordings, provides the accurate localization of the motor cortex at end of the procedure (Figure 2).

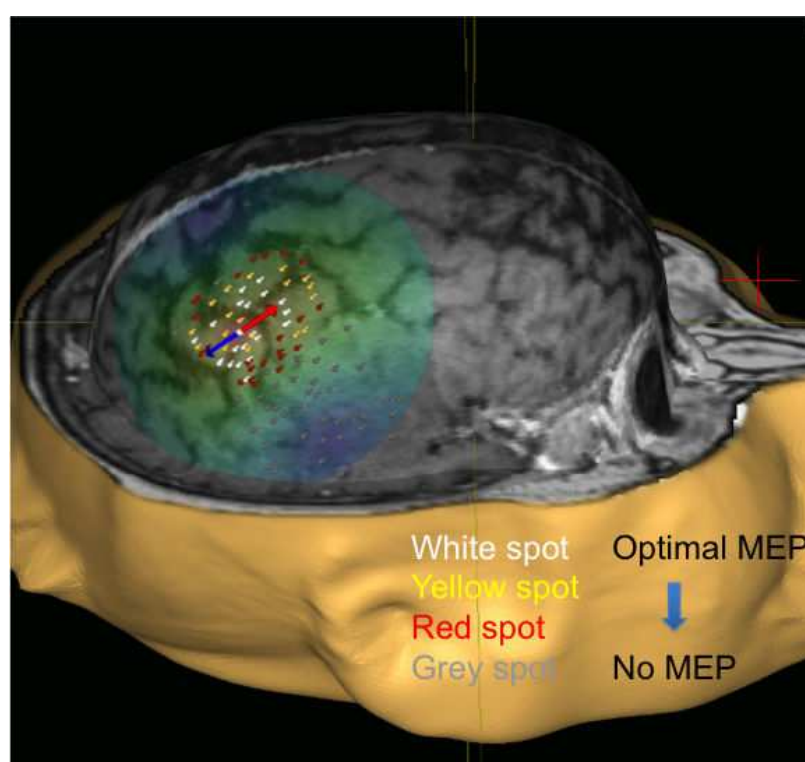


Figure 2. The NBS System uniquely determines the actual location of the stimulating electric field (E-field) in the cortex. Moving the transcranial magnetic stimulation coil over the patient's head, it is always possible to see, in real-time, the stimulation location, strength and direction in the 3-D intracranial rendering. During the mapping, the areas in the cortex with maximal EMG responses are automatically highlighted with different colors.

2.3. Neuronavigation

The NBS can accurately display, in a 3D rendering of the individual patient's magnetic resonance image (MRI), the induced electric field generated by TMS (Figure 3). A standard volumetric MRI is uploaded in the NBS System to obtain a detailed 3D rendering of the head and intracranial structures. Visualization of the brain cortex can be obtained by a tool that allow a layer-by-layer peeling of the skin, bone and dura mater to view the 3D rendering of the

brain at any desired intracranial depth. Overlay fMRI, DTI or PET data on the 3D rendering is needed can be registered as well.

With the patient wearing a head tracker (eye-frame), a pointer registers 12 scalp points and computer-aided landmark identification ensures accurate alignment to the MRI data (Figure 3).

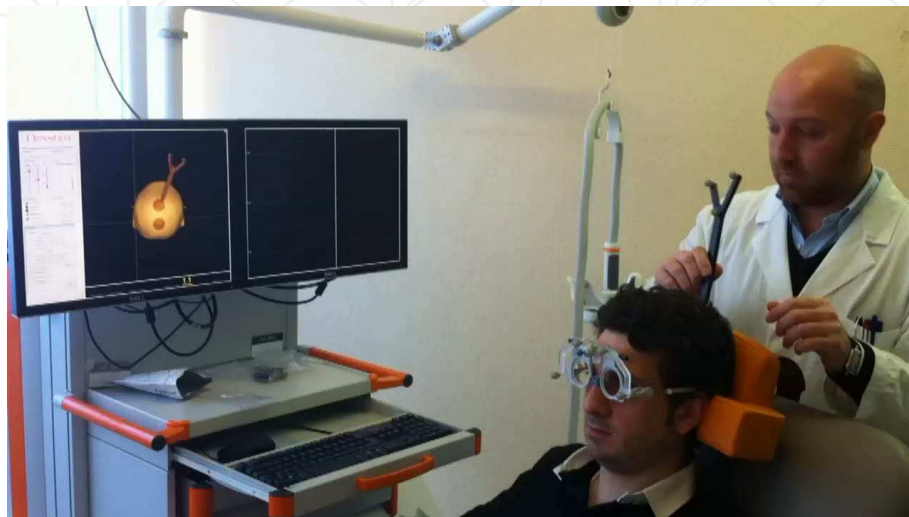


Figure 3. With the patient wearing a head tracker (eyeframe), computer-aided landmark identification ensures accurate alignment of the patient to the MRI data.

Therefore, the NBS system determines the actual location of the stimulating electric field in the cortex, taking into account the size and shape of the individual patient's head, as well as the TMS coil and stimulator parameters. Moving the TMS coil over the patient's head, it is possible to always see, in real-time, the electric field location, strength and direction in the 3-D intracranial rendering. As the session proceeds, a map of the cortical somatotopy, can be created and a post-hoc analysis can be performed offline.

3. Other potential clinical applications of NBS

3.1. Mapping the language

The identification of cortical areas controlling the language can be performed by direct cortical stimulation. The cortical area responsible for the motor function of language can be localized by the so-called "speech arrest" caused by its electrical stimulation. Prerequisite of this type of mapping is that the patient must be awake and cooperative. Nevertheless, these conditions cannot be always achieved, especially when patients are children or poorly cooperative adults. In these patients, therefore, it is imperative to find a method of tracking and monitoring the language during a surgery performed under general anesthesia.

In a recent study, navigated TMS was used in combination with video recording of the patient involved in an objects naming task [10]. A repetitive TMS (rTMS) must be used to this purpose. A train of five consecutive TMS pulses was delivered at repetition rate of 5 Hz [4] and with intensity range 80–110% of the motor threshold (MT). The induced electric field ranged between 45 and 80 V/m. To cover speech-related activity and make the possible speech arrest more clear, the train started 300 ms after the presentation of the picture.

Video recording was used for post-hoc review of "errors" caused by repetitive navigated TMS. During stimulation of cortical areas in proximity of the Brodmann 44 area, complete anomia and semantic errors have been recorded. In some patients, the stimulation of the right cortex produced similar errors.

Three different cortical areas in the frontal cortex have been identified as responsible for the arrest of speech: primary motor areas negative (NMA), opercular portion of Broca's area (Brodmann area 44) and area of primary motor cortex (M1). M1 cortex is responsible for controlling muscle movements necessary for vocalization, whereas the pars opercularis of Broca's area is responsible for phonological tasks. The responses of the laryngeal muscles can be clearly distinguished by their different latencies to stimulation: stimulation of the M1 produces a short latency response (SLR), whereas stimulation of the part opercularis of the Broca's area produces a long latency response (LLR) [3].

3.2. Therapeutic use of navigated TMS

Repetitive TMS (rTMS) has a potential therapeutic effect in several psychiatric and neurological diseases as well as in stroke and pain. In October 2008, the FDA approved rTMS in the USA for the treatment of major depressive disorders in adults who have failed at least one antidepressant medication.

With rTMS, one challenge is finding the optimal location and dose. In fact, despite multiple successful investigations showing positive effects of rTMS in depression, recent reports have indicated that non-responders may have received rTMS to suboptimal locations [6]. Navigation can help the identification of the optimal brain structure for targeting rTMS, but solving this problem still leaves the question of dose optimization. While specific pulse train parameters have been extensively reviewed in the literature, there is little knowledge of the intracranial strength of applied stimulation and dose-response behavior.

With regard to stroke, MEPs may have an important role in quantifying the remaining capacity of the motor cortex and the corticospinal tract to generate muscular activity [13]. Navigated TMS may show the development of post-stroke neuronal plasticity with shifting of the primary representation areas. This advances our prognostic evaluation and offers insights for innovative therapeutic strategies [11].

The stimulation of the motor cortex through surgically implanted epidural electrodes is a safe and effective technique to treat chronic neuropathic pain. About ten years ago, it was demonstrated that repetitive TMS of the motor cortex could also produce analgesic effects in patients with neuropathic pain resistant to drugs. Since rTMS is not invasive, the technique is particularly suited to the study of the mechanisms involved in the modulation induced by

cortical stimulation. Furthermore, the use of a navigated repetitive TMS may increase accuracy and reliability of the procedure. It exploits the ability to view "hot spots" of cortical stimulation, provided by the maximum amplitude of motor evoked potentials in the muscles of the painful body area, directly on the three-dimensional reconstruction of magnetic resonance imaging of the brain of each individual patient.

There is a critical frequency of stimulation to achieve the analgesic effect of rTMS. Repetitive TMS of the motor cortex has been proven of relieving pain when applied high frequency ($> 5\text{Hz}$), but not at low frequency ($<1\text{ Hz}$). The high frequencies are used to enhance synaptic transmission, without regard to time of stimulation, while the low frequency would be inhibitory. Unlike the frequency, increasing the intensity does not potentiate the analgesic effect of the stimulation. This is because the increased intensity only leads to recruitment of fibers placed in the deepest portion of the cortex, while the pain relief is achieved by activating neural circuitry in the upper layers of the cortex. The peak of analgesic effect of repetitive TMS due to synaptic plasticity, is reported from about 2-3 days after a single session of rTMS and can last for a week. The use in daily sessions of rTMS for several weeks may increase the degree and duration of pain reduction, beyond the time of stimulation. To date, however, the long-term relief, can only be achieved by implanting epidural motor cortex stimulation.

It has also been shown that the analgesic effect of rTMS depends on the precise location of the site of stimulation on the precentral gyrus contralateral to the site of pain. Conventionally, TMS relies solely on the skull anatomy. Using navigated TMS, it is possible to directly visualize the target area. For the hand, the target is located at the knee of the median motor gyrus, which is easily identifiable in 90% of cases, in the front portion of the central sulcus. If the hand knob cannot be accurately identified, the target can be set at the level of the apparent interruption of the central sulcus corresponding to the motor representation of the muscles of the hand. In rare cases where neither the joint nor the apparent interruption of the motor central sulcus can be identified (3% of cases), the target can be identified on the front arm of the central sulcus at the level of the superior frontal sulcus. The effectiveness of repetitive TMS depends also on the orientation of the coil. Analgesia is usually obtained when the coil has an antero-posterior orientation in the precentral gyrus. Repetitive TMS may modulate affective and emotional components of pain, perhaps connected with the effects of stimulation on limbic structures. A positive response to rTMS could be used to identify patients responding to epidural stimulation surgery, even though a negative response is not an exclusion criterion for the implant [1].

4. Materials and methods

All patients admitted to our clinic from November 2011 to May 2012 with lesions (primary brain tumors, brain metastases, vascular malformations) in the motor area underwent pre-operative mapping by NBS (Nexstim system 4, Nexstim Ltd., Helsinki, Finland).

Ten patients (5 women and 5 men), aged between 27 and 82 years (mean age = 54 years) underwent NBS. Four patients underwent also preoperative DTI tractography. Seven patients had a lesion of the left cerebral hemisphere.

Neuroimaging was performed using a 1.5-T MRI unit acquiring high-resolution T1 weighted (T1-w) isotropic volumetric data set with a 3D-magnetization prepared rapid gradient echo (3D-MPRAGE) sequence with 1 x 1 x 1 mm voxel size. During the same session DTI was performed. Patients were imaged with parallel imaging technique (IPAT GRAPPA implementation with acceleration factor of 2) and a 4-channel coil with different parameters of the same diffusion-weighted echo-planar sequence with a diffusion-weighted single-shot spin echo, echoplanar sequence with isotropic voxel of 2.3 x 2.3 x 2.3 mm.

Diffusion tensor images were transferred to a personal computer, converted in analyze format and then initially corrected for the effects of eddy-current-induced distortion using FSL modules. After returning them to the DICOM format the images were then processed with the Diffusion Toolkit software (Martinos Center for Biomedical Imaging, Massachusetts General Hospital, Boston, MA, USA) to calculate voxel-based fractional anisotropy maps. Fiber tracking was then performed with the same software using the interpolated streamline propagation algorithm.

The NBS study was performed using a "figure-eight" coil applied perpendicular to the sagittal line of the patient head, with an inclination of 45° and with a posterior-to-anterior flow of direct current.

The procedure was performed according to the following steps:

1. the patient's brain MRI was uploaded in the NBS system so that it can to elaborate a three-dimensional reconstruction; layer-by-layer peeling of superficial cortical structures was performed.
2. the electrodes for recording of electromyographic activity were placed on the surface of the muscles to be activated. Amplitude and latency of evoked potentials engines from 6 EMG channels will be automatically calculated and recorded.
3. The patient wore a special eye-frame for the "head tracking". The operator then tracked the head of the patient with a pointer. The NBS system aligned the points virtually drawn on the patient's head with their corresponding coordinates on the 3D magnetic resonance.
4. The TMS was then performed. Once the brain area for the target muscle was found, the NBS System found the patient's individual motor threshold (MT). With the stimulator output now set to the optimal mapping intensity, the NBS System automatically and reliably measured MEPs – enabling the high spatial resolution needed for accurate mapping.
5. Before NBS mapping, the resting motor threshold of each individual patient (resting motor threshold = minimal intensity of stimulation that can elicit at least 5 of 10 PEM, with an amplitude of 50 mV) was determined. The cortex of patients was thus activated with a stimulation intensity of 20-30% higher than the resting motor threshold.

6. A cortical somatotopic map was generated by stimulating different parts of the cortex, and identifying those in which the motor response was more intense.
7. The whole data set including the volumetric MRI and a co-registered functional map were exported and uploaded into the operative neuronavigation system.

The motor area has been mapped, on average, twice for each patient: the first mapping was usually carried out one week before surgery. The second determination was obtained the day before surgery.

In one patient, rTMS was performed in order to map language areas. This was done at a frequency of 5 Hz with trains of 7 stimuli (because the area of language is placed in a deepest portion of the cortex than the area motor) and a very low intensity (close to the motor threshold) to minimize the risk of seizures.

Motor evoked potentials of the following muscles were recorded: first interosseous, for the group of muscles of the hand; the tibialis anterior, for the group of muscles of the leg; mental muscle, for the group of muscles of the face.

The software classified the recorded MEP intensities using a chromatic scale of four colors: white, yellow, red, gray. Adjoining white spots (maximum cortical representation of the muscle activated by TMS) with yellow and red spots (MEPs of intermediate intensity, and excluding the grey points (no muscle activation following stimulation of that point = no cortical representation of the muscle at that point), the profile of the motor cortex was so elaborated offline (Figure 4).

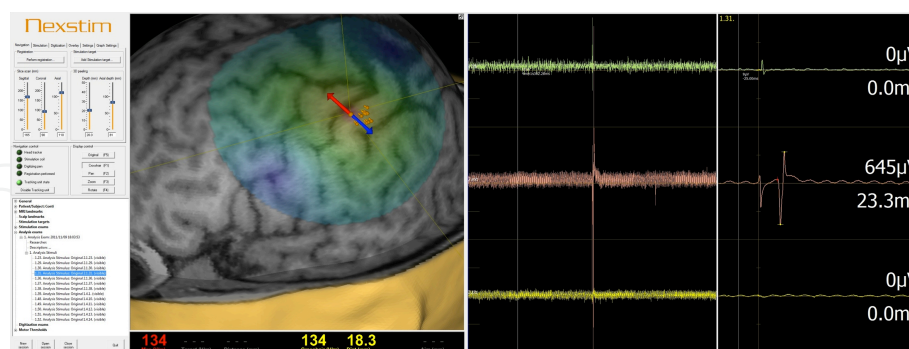


Figure 4. Once the representation area for the target muscle has been found, the NBS System finds the patient's individual motor threshold (MT). With the stimulator output now set to the optimal mapping intensity, the NBS System automatically and reliably measures MEPs enabling the high spatial resolution needed for accurate mapping.

The data obtained were exported and uploaded on a neuronavigation system Stealthstation 7 (Medtronic, Louisville, CO) and used in the operating room during surgery (Figure 5).

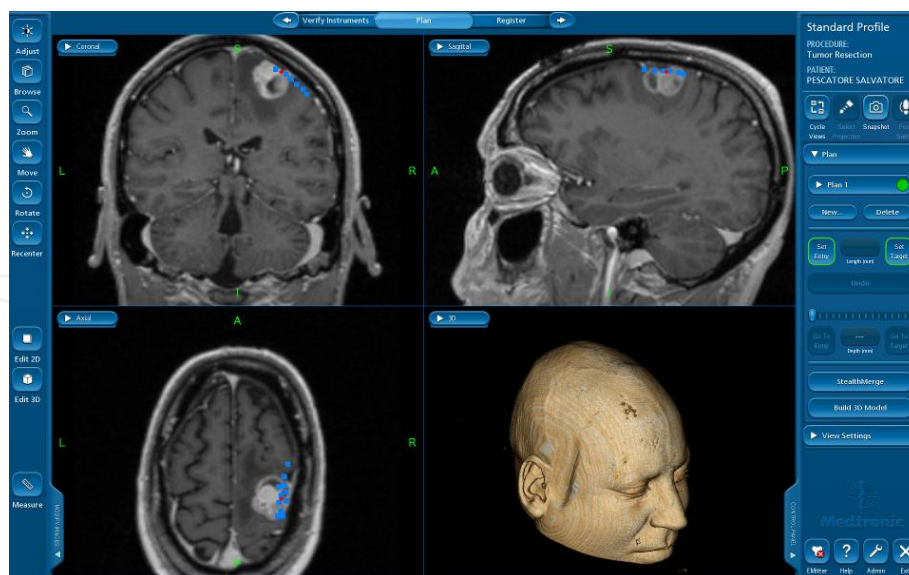


Figure 5. Once the mapping has been completed it is possible exporting images in DICOM format to the neuronavigator. In the operating room, NBS cortical maps may facilitate the optimal placement of direct cortical stimulation electrodes and facilitate surgical guidance.

5. Results and Discussion

All patients underwent gross total resection of tumors or vascular malformations. Post-operatively, only 1 out of 10 patients presented a right facial paresis of the central type associated to motor aphasia; both recovered within 48 hours. In 5 of the patients neurological examination showed no changes as compared to the pre-operative status. Finally, 4 patients had an improvement of neurologic status (Figure 6).

With regard to the tolerability of NBS, we did not record any discomfort for the patients, nor side effects or seizures due to the cortical stimulation, despite the majority of patients had a history of epilepsy (9 of 10 patients).

In this our preliminary experience, albeit the limitation of a small number of cases, NBS met the expectations with successful clinical results. Up to now, functional magnetic resonance imaging (fMRI) was the only non-invasive and readily available method to study brain functions, cognitive activities and potential functional circuitry. fMRI technique uses BOLD (blood oxygenation level dependent) sequences, namely a sequence able to detect increased level of cerebral blood flow and oxygen consumption of brain areas that are activated by appropriate stimulation tests. Although it is less available, positron emission tomography (PET) is the alternative technique that measures the oxygen or glucose consumption of activated brain areas. Both fMRI and PET have a sufficient spatial resolution, but a low temporal resolution. Moreover, the growth of brain tumors may transform local vascularization and cell metabolism, for which a method sensitive to hemodynamic or metabolic changes, may be less accurate.

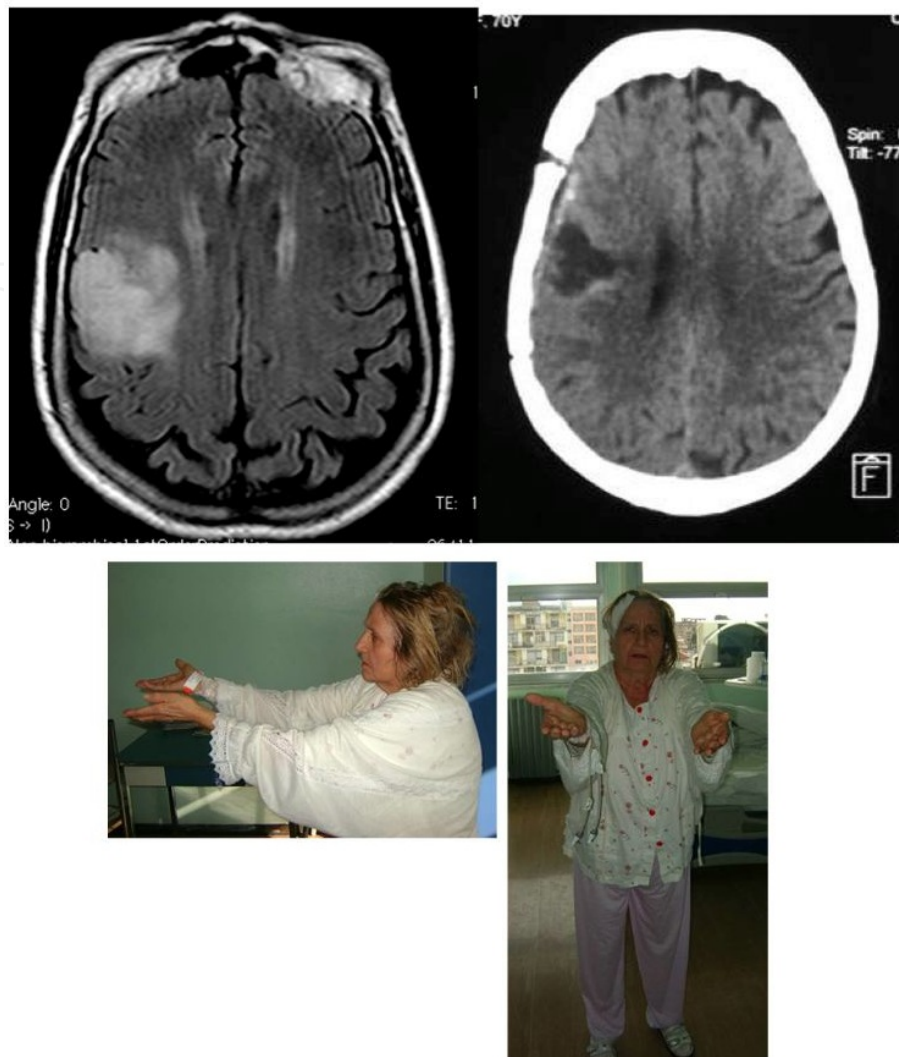


Figure 6. Preoperative MRI (upper left) and post-operative CT (upper right) imaging of a patient with a low grade gliomas of the right pre-rolandic area. The day after surgery the patient present no motor deficits.

Finally, these examinations could be cumbersome, or even not feasible in children and in patients with severe neurological impairments.

Navigated brain stimulation, among the methods of pre-operative brain mapping, has a number of potential advantages. Actually, NBS possesses a very high temporal resolution, since the muscle response to the stimulus electromagnetic is immediate, just as for the DCS. The spatial resolution is extremely high since we can record difference of cortical response within few millimeters. Furthermore, it does not passively record brain activity during voluntary patient movements, but detect an electromyographic response evoked by the TMS.

The identification of the relationships between the lesion and the motor area was possible in all our patients, whereas conventional MRI studies had only provided information on the location of the lesion and its possible relationship with the anatomical structures (e.g. precentral gyrus), but no information on their functional relevance. The peculiarity of the NBS, with

respect to the DCS, resides in the possibility of obtaining the cortical mapping preoperatively. Therefore, the surgeon gains the ability to make an accurate surgical plan before the patient arrives in the operating room. This allows a more accurate definition of the craniotomy site and its size, selection of extent of surgical resection prior to surgery, and last but not least, the possibility to predict neurological outcome of treatment and to provide a more accurate information to the patient. In our series, for instance, the indication for surgery was primarily determined on the basis of histology presumed by imaging studies and/or medical history, the location and the size of the lesion, its relation with the cerebral vessels, taking also into account patient age and the risks of comorbidity. Nevertheless, the information obtained with NBS influenced the overall surgical strategy with a planned treatment of extensive resection of noneloquent areas with maximal preservation of the motor area.

NBS functional maps were then “navigated” during surgical resection of the lesion and combined with DCS. The NBS and DCS share similarities, so that the combined use is reliable and can be of great utility. The pre-operative plan, obtained on the basis of NBS, can be applied intraoperatively with the support of DCS. The spatial deviation between DCS and NBS data ranges within the calculated accuracy of the nTMS system, which is 5.73 mm [18]. Such precision has been documented in previous reports on nTMS accuracy, indicating that a spatial resolution of 5 mm is obtainable [2,7,8].

Furthermore, it should be noticed that for lower extremity mapping, nTMS was possible more frequently than DCS, most likely because of the comparatively large stimulated cortical volume, which was calculated to be 1–2 cm³ for the figure-8 coil used [9].

NBS can also map the cortical areas involved in the control of language. We attempted the use of repetitive transcranial magnetic stimulation (rTMS), with trains of stimuli (between 5 and 10), in that the areas to be mapped are positioned deeper than the area motor of the hand or leg, and the stimulation is made almost at “threshold” level. The use of the repetitive stimulation increases the depth of the stimulus but the low intensity prevents the onset of epileptic seizures. The localization is done by displaying, on the 3D reconstruction of the image of magnetic resonance imaging of the patient, the “hot spot” corresponding to the “speech arrest”, i.e. from the errors generated in the naming of objects that are shown, on a screen, to the patient in the course of stimulation. The moments of speech arrest are filmed by a video camera and subsequently analyzed. The method is very promising for the presurgical planning, but also in the neurophysiological study of neuronal networks underlying the function of language. In fact, previous studies have suggested a revision of the current view, perhaps too simplistic, that Broca's and Wernicke's areas were the only ones involved in the control of language. Already fMRI showed that cortico-cortical connections are much more complex [12]. However, studies in patients with intracranial lesions were found to be more reliable when performed by nTMS; this method, in fact, does not possess the “limit” of relying on cerebral blood flow or metabolism, which could be altered in the presence of brain pathologies. Moreover, fMRI shows the entire cortical network underlying a specific activity, such as aspects of language. The combination with NBS may identify the hierarchy that exists between the different functional areas.

A further opportunity of NBS is the possibility to be integrated in the treatment planning of stereotactic radiosurgery. Radiosurgery is an ablative procedure, but it lacks the possibility of intraoperative brain function mapping and monitoring. NBS is a very good candidate.

Author details

Concetta Alafaci*, Alfredo Conti and Francesco Tomasello

*Address all correspondence to: calafaci@unime.it

Department of Neurosurgery, University of Messina, Messina, Italy

References

- [1] Ahdab, R., & Lefaucheur, J. P. (2010). Repetitive transcranial magnetic stimulation and implanted cortical stimulation in the treatment of neuropathic pain. *Proceedings 2nd International Workshop on Navigated Brain Stimulation in Neurosurgery, Berlin, Germany, October 08-09*.
- [2] Brasil-Neto, J. P., Cohen, L. G., Panizza, M., Nilsson, J., Roth, B. J., & Hallett, M. (1992). Optimal focal transcranial magnetic activation of the human motor cortex: effects of coil orientation, shape of the induced current pulse, and stimulus intensity. *J Clin Neurophysiol*, 9, 132-136.
- [3] Deletis, V., & Rogić, M. (2010). Neurophysiologic markers generated by motor speech-related cortical areas. *Proceedings 2nd International Workshop on Navigated Brain Stimulation in Neurosurgery, Berlin, Germany, October 08-09*.
- [4] Epstein, C. M., Lah, J. J., Meador, K., Weissman, JD, Gaitan, L. E., & Dihenia, B. (1996). Optimum stimulus parameters for lateralized suppression of speech with magnetic brain stimulation. *Neurology*, 47, 1590-1593.
- [5] Herbsman, T., Avery, D., Ramsey, D., Holtzheimer, P., Wadjik, C., Hardaway, F., et al. (2009). More lateral and anterior prefrontal coil location is associated with better repetitive transcranial magnetic stimulation antidepressant response. *Biol Psychiatry*, 66, 509-515.
- [6] Julkunen, P., & Jääskeläinen, J. E. (2010). Transfer of NBS motor mapping data through neuronavigator into optic field of operating microscope. *Proceedings 2nd International Workshop on Navigated Brain Stimulation in Neurosurgery, Berlin, Germany, October 08-09*.
- [7] Krieg, S. M., Shiban, E., Buchmann, N., Gempt, J., Foerschler, A., Meyer, B., & Ringel, F. (2012). Utility of presurgical navigated transcranial magnetic brain stimulation for the resection of tumors in eloquent motor areas. *J Neurosurg*, 116(5), 994-1001.

- [8] Krings, T., Buchbinder, B. R., Butler, W. E., Chiappa, K. H., Jiang, H. J., Rosen, B. R., et al. (1997). Stereotactic transcranial magnetic stimulation: correlation with direct electrical cortical stimulation. *Neurosurgery*, 41, 1319-1326.
- [9] Levy, W. J., Amassian, V. E., Schmid, U. D., & Jungreis, C. (1991). Mapping of motor cortex gyral sites non-invasively by transcranial magnetic stimulation in normal subjects and patients. *Electroencephalogr Clin Neurophysiol*, 43, 51-75.
- [10] Lioumis, P., Zhdanov, A., Mäkelä, N., Lehtinen, H., Wilenius, J., Neuvonen, T., Hannula, H., Deletis, V., Picht, T., & Mäkelä, J. P. (2012). A novel approach for documenting naming errors induced by navigated transcranial magnetic stimulation. *J Neurosci Methods*, 204, 349-54.
- [11] Mäkelä, J. P., Vitikainen, A. M., Lioumis, P., Paetau, R., Ahtola, E., Kuusela, L., Valanne, L., Blomstedt, G., & Gaily, E. (2012). Functional plasticity of the motor cortical structures demonstrated by navigated TMS in two patients with epilepsy. *Brain Stimul*. May 23. [Epub ahead of print].
- [12] Ojemann, G., & Mateer, C. (1979). Human language cortex: localization of memory, syntax, and sequential motor-phoneme identification systems. *Science*, 205(4413), 1401-1403.
- [13] Peurala, S. H., Tarkka, I. M., Juhakoski, M., Könönen, M., Karhu, J., Jäkälä, P., et al. (2008). Restoration of normal cortical excitability and gait ability in acute stroke after intensive rehabilitation. *Cerebrovasc Dis*, 26, 208-209.
- [14] Picht, T., Mularski, S., Kuehn, B., Vajkoczy, P., Kombos, T., & Suess, O. (2009). Navigated transcranial magnetic stimulation for preoperative functional diagnostics in brain tumor surgery. *Neurosurgery*, 93-98.
- [15] Picht, T., Mularski, S., Kuehn, B., Vajkoczy, P., Kombos, T., & Suess, O. (2009). Navigated transcranial magnetic stimulation for preoperative functional diagnostics in brain tumor surgery. *Neurosurgery*, 65, 93-98.
- [16] Picht, T., Schulz, J., Hanna, M., Schmidt, S., Suess, O., & Vajkoczy, P. (2012). Assessment of the influence of navigated transcranial magnetic stimulation on surgical planning for tumors in or near the motor cortex. *Neurosurgery*, 70(5), 1248-1256.
- [17] Rothwell, J. (2010). TMS principles. *Proceedings 2nd International Workshop on Navigated Brain Stimulation in Neurosurgery, Berlin, Germany, October 08-09*.
- [18] Ruohonen, J., & Karhu, J. (2010). Navigated transcranial magnetic stimulation. *Neurophysiol Clin*, 40, 7-17.