

We are IntechOpen, the world's leading publisher of Open Access books Built by scientists, for scientists

6,300

Open access books available

171,000

International authors and editors

190M

Downloads

Our authors are among the

154

Countries delivered to

TOP 1%

most cited scientists

12.2%

Contributors from top 500 universities



WEB OF SCIENCE™

Selection of our books indexed in the Book Citation Index
in Web of Science™ Core Collection (BKCI)

Interested in publishing with us?
Contact book.department@intechopen.com

Numbers displayed above are based on latest data collected.
For more information visit www.intechopen.com



Obstructive and Non-Obstructive Azoospermia

Antonio Luigi Pastore^{1,2*}, Giovanni Palleschi^{1,2}, Luigi Silvestri¹,
Antonino Leto¹ and Antonio Carbone^{1,2}

¹*Sapienza University of Rome, Faculty of Pharmacy and Medicine,
Department of Medico-Surgical Sciences and Biotechnologies,
Urology Unit, S. Maria Goretti Hospital Latina*

²*Uroresearch Association®[®], Latina
Italy*

1. Introduction

Azoospermia is defined as the complete absence of spermatozoa upon examination of the semen [including capillary tube centrifugation (CTC), strictly confirmed by the absence of spermatozoa issued in urine after ejaculation]. The presence of rare spermatozoa (<500.000/ml) in seminal fluid after centrifugation is called "cryptozoospermia". The complete absence of spermatozoa should be confirmed with repeat testing after a long time, because many external factors (e.g., febrile episodes and some therapies) may cause transient azoospermia. Azoospermia is present in approximately 1% of all men, and in approximately 15% of infertile men. Azoospermia may result from a lack of spermatozoa production in the testes (secretory or Non-Obstructive Azoospermia, NOA), or from an inability of produced spermatozoa to reach the emitted semen (excretory or Obstructive Azoospermia, OA); however, in clinical practice both components are sometimes present in a single patient (mixed genesis azoospermia). The initial diagnosis of azoospermia is made when no spermatozoa can be detected on high-powered microscopic examination of centrifuged seminal fluid on at least two occasions. *The World Health Organization (WHO) Laboratory Manual for the Examination of Human Semen and Semen-Cervical Mucus Interactions* recommends that the seminal fluid be centrifuged for 15 minutes, preferably at a centrifugation speed of $\geq 3000 \times g$.

The evaluation of a patient with azoospermia is performed to determine the etiology of the patient's condition. The numerous etiologies for azoospermia fall into three principal categories: pre-testicular, testicular, and post-testicular.

1. pre-testicular azoospermia affects approximately 2% of men with azoospermia, and is due to a hypothalamic or pituitary abnormality diagnosed with hypogonadotropic hypogonadism;
2. testicular failure or non-obstructive azoospermia is estimated to affect from 49% to 93% of azoospermic men. While the term testicular failure would seem to indicate a complete absence of spermatogenesis, men with testicular failure actually have either

* Corresponding Author

- reduced spermatogenesis [hypospermatogenesis], maturation arrest at an early or late stage of spermatogenesis, or a complete failure of spermatogenesis (noted with Sertoli-cell only syndrome);
3. post-testicular obstruction or retrograde ejaculation are estimated to affect from 7% to 51% of azoospermic men. In these cases, spermatogenesis is normal even though the semen lacks spermatozoa.

Diagnosis

The minimum initial evaluation of an azoospermic patient should include a complete medical history, physical examination, and hormone level measurements. Relevant history should investigate prior fertility; childhood illnesses such as orchitis or cryptorchidism; genital trauma or prior pelvic/inguinal surgery; infections; gonadotoxin exposure, such as prior radiation therapy/chemotherapy and current medical therapy; and a familial history of birth defects, mental retardation, reproductive failure, or cystic fibrosis. Physical examination includes: testis size and consistency; consistency of the epididymides; secondary sex characteristics; presence and consistency of the vasa deferentia; presence of a varicocele; and masses upon digital rectal examination. The initial hormonal evaluation should include measurement of serum testosterone (T) and follicle stimulating hormone (FSH) levels.

History and initial investigations for men with azoospermia

Cryptorchidism: the bilateral form is almost always associated with azoospermia and irreversible gonadal secretory dysfunction. The age at which surgical intervention is practiced and subsequent gonadal development may sometimes affect the prognosis. In addition, not infrequently, germinal malformations are also associated with atrophy of the epididymus and sometimes with iatrogenic damage to the vas deferens. In unilateral cryptorchidism, azoospermia is less frequent; azoospermia in a patient with unilateral cryptorchidism is likely the result of concurrent secretory dysfunction (dysgenesis) or other pathology of the contralateral testis.

Reduced volume of ejaculate: occurs progressively in the post-inflammatory obstruction of the ejaculatory ducts (ED), with a concomitant reduction of seminal fructose and lowering of pH. Ejaculate volume is normally reduced in cases of vas deferens agenesis or in the presence of large seminal cysts (Müllerian or Wolffian). The same phenomenon is present in primary hypogonadism. Partial retrograde ejaculation is present in patients with systemic neuropathy (e.g., juvenile diabetes and multiple sclerosis), and is a possible outcome of endoscopic urological surgery for bladder neck sclerosis.

Urological symptoms and signs: the clinician must always pay close attention to symptoms, even prior symptoms that may previously have had no apparent significance, such as episodes of hemospermia, burning urination, urinary frequency, and urethral catheterization after surgery. All of these symptoms should raise the suspicion that the proximal or distal seminal tract may be obstructed (Silber, 1981). The presence of hypospadias may be associated with urinary abnormalities, hypogonadism, cryptorchidism, and the presence of residues in the Müllerian duct of the prostate (utricle cysts). These cysts can be responsible for extrinsic compression of the ED.

Surgery: Inguinal hernioplasty interventions (often performed during infancy) may have damaged the tubes, and then create a condition of seminal tract obstruction. Resection of the funicular vessels may result in hypotrophy of the gonad.

Family history: Clinicians should be attentive to the concomitant presence of infertility in the patient's male relatives (as a result of chromosomal abnormalities, genetic conditions, tuberculosis, etc.). Scrotal traumas are often responsible for complete or incomplete epididymis obstruction, as well as trophic changes of the gonad.

Prior chemotherapy and radiotherapy: Drug and radiation treatments for tumors usually cause irreversible damage to spermatogenesis. Even high-dose hormone therapy; antibiotic therapy with tetracyclines, nitrofurans, and sulfasalazine; or other drug therapies often temporarily alter spermatogenesis.

Chronic obstructive pulmonary diseases are frequently associated with obstruction of the epididymis (11-21%). This condition is often the result of primary ciliary dyskinesia (also known as Kartagener Syndrome) or cystic fibrosis, the latter often characterized by agenesis of the distal epididymis, vas deferens, and seminal vesicles. The most common cause of congenital bilateral absence of the vas deferens (CBAVD) is a mutation of the cystic fibrosis trans-membrane conductance regulator (CFTR) gene. Almost all males with clinical cystic fibrosis have CBAVD, and approximately 70% of men with CBAVD and no clinical evidence of cystic fibrosis have an identifiable abnormality of the CFTR gene.

The CFTR gene is extremely large and known mutations in the gene are extremely numerous. Clinical laboratories typically test for the 30–50 most common mutations found in patients with clinical cystic fibrosis. However, the mutations associated with CBAVD may be different. Because over 1,300 different mutations have been identified in this gene, this type of limited analysis is only informative if a mutation is found. A negative test result only indicates that the CBAVD patient does not have the most common mutations causing cystic fibrosis. Testing for abnormalities in the CFTR should include, at minimum, a panel of common point mutations and the 5T allele. There is currently no consensus on the minimum number of mutations that should be tested.

Bilateral testicular atrophy may be caused by either primary or secondary testicular failure. Elevated serum FSH associated with either normal or low serum testosterone is consistent with primary testicular failure. All patients with these findings should be offered genetic testing for chromosomal abnormalities and Y-chromosome microdeletions. Low serum FSH associated with bilaterally small testes and low serum testosterone is consistent with hypogonadotropic hypogonadism (secondary testicular failure). These patients usually also have low serum luteinizing hormone (LH) levels. Hypogonadotropic hypogonadism can be caused by hypothalamic disorders (e.g., functioning and non-functioning pituitary tumors). Therefore, these patients should undergo further evaluation, including serum prolactin measurement and imaging of the pituitary gland.

When the vasa deferentia and testes are palpably normal, semen volume and serum FSH are key factors in determining the etiology of azoospermia. Azoospermic patients with normal ejaculate volume may have reproductive system obstruction or spermatogenesis abnormalities. Azoospermic patients with low semen volume and normal-sized testes may have ejaculatory dysfunction or ejaculatory duct obstruction (EDO).

Normal semen volume

The serum FSH level of a patient with normal semen volume is a critical factor with which to establish whether a diagnostic testicular biopsy is needed to investigate spermatogenesis. Although a diagnostic testicular biopsy will determine whether spermatogenesis is impaired, it does not provide accurate prognostic information regarding whether or not sperm will be found on future sperm retrieval attempts for patients with NOA. Therefore, a testicular biopsy is not necessary to establish the diagnosis or to provide clinically useful prognostic information for patients with consistent clinical findings for the diagnosis of NOA (e.g., testicular atrophy or markedly elevated FSH). Conversely, patients who have a normal serum FSH should undergo a diagnostic testicular biopsy, because normal or borderline elevated serum FSH levels may suggest either obstruction or abnormal spermatogenesis. If the testicular biopsy is normal, an obstruction in the reproductive system must be found. Most men with OA, palpable vasa deferentia, and no history of iatrogenic vasal injury present with bilateral epididymal obstruction. Epididymal obstruction can be identified only by surgical exploration. Vasography may be utilized to determine whether there is an obstruction in the vas deferens or ED.

Reduced semen volume

Low ejaculate volume (< 1.0 ml) that is not caused by hypogonadism or CBAVD may be caused by ejaculatory dysfunction, but is most likely caused by EDO. Ejaculatory dysfunction rarely causes low ejaculate volume with azoospermia, although it is a well-known cause of aspermia or low ejaculate volume with oligozoospermia. Additional seminal parameters that may be helpful in determining the presence of EDO are seminal pH and fructose, since the seminal vesicle secretions are alkaline and contain fructose. EDO is detected by transrectal ultrasonography (TRUS). The finding of midline cysts, dilated ED, and/or dilated seminal vesicles (>1.5 cm in antero-posterior diameter) on TRUS is suggestive, but not diagnostic, of EDO. Therefore, seminal vesicle aspiration (SVA) and seminal vesiculography may be performed under TRUS guidance to make a more definitive diagnosis of EDO. The presence of large numbers of sperm in the seminal vesicle of an azoospermic patient is highly suggestive of EDO. Seminal vesiculography performed contemporary with SVA can localize the site of obstruction. EDO is detected by TRUS, and is usually accompanied by dilation of the seminal vesicles (typically >1.5 cm).

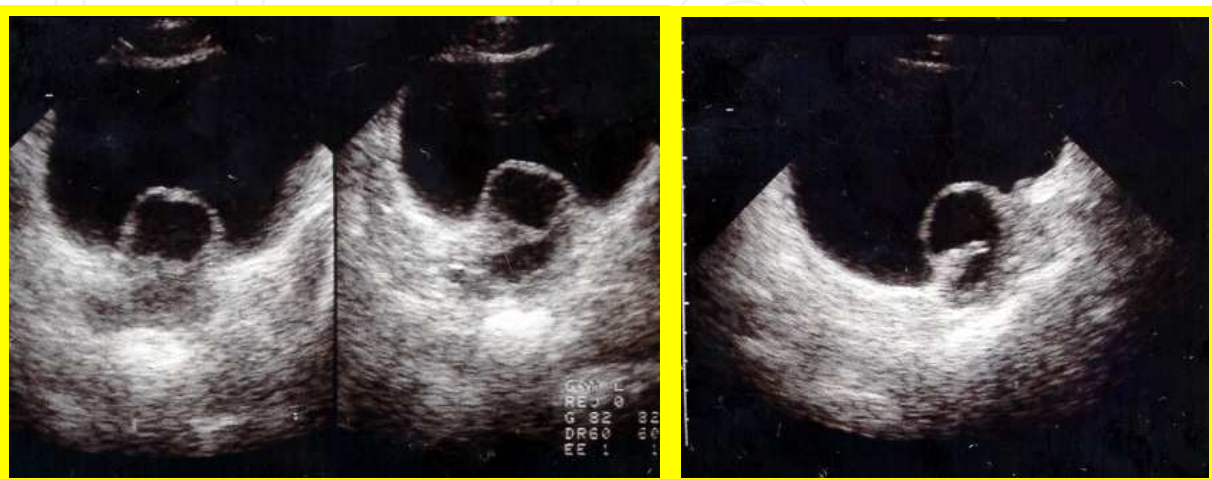


Fig. 1. Ultrasonography Investigation: Intraprostatic cyst with ejaculatory duct obstruction

Genetic investigations for men with azoospermia

All men with hypogonadotropic hypogonadism should be referred for genetics counseling, as almost all of the congenital abnormalities of the hypothalamus are due to a genetic alteration.

If a genetic alteration is identified, then genetic counseling is suggested (Level of evidence 2, Grade B recommendation). In addition to mutations in the CFTR gene that give rise to CBAVD, genetic factors may play a role in NOA. The two most common categories of genetic factors are chromosomal abnormalities resulting in impaired testicular function, and Y-chromosome microdeletions leading to isolated spermatogenic impairment.

Chromosomal abnormalities account for approximately 6% of all male infertility, and the prevalence increases with increased spermatogenic impairment (severe oligospermia and NOA).

Approximately 13% of men with NOA or severe oligospermia may have an underlying Y-chromosome microdeletion. Y chromosome microdeletions responsible for infertility – azoospermia factor (AZF) regions a, b, or c – are detected using sequence-tagged sites (STS) and polymerase chain reaction (PCR) analysis. Y chromosome microdeletions carry both prognostic significance for finding sperm, and consequences for offspring if these sperm are utilized. Although successful testicular sperm extraction has not been reported in infertile men with large deletions involving AZFa or AZFb regions, the total number of reports is limited. However, up to 80% of men with AZFc deletions may have retrievable sperm for intracytoplasmic sperm injection (ICSI).

Treatments for azoospermia

Obstructive azoospermia

Instrumental and surgical treatments designed to restore natural fertility

1. Microsurgical recanalization of the proximal seminal tract
 - a. Obstruction of the epididymis: epididymal tubal vasostomy (vasoepididymostomy)
 - b. Obstruction of the vas deferens: vasovasostomy
2. Recanalization of the distal seminal tract
 - a. Transurethral resection of the ejaculatory ducts (TURED)
 - b. Transrectal ultrasound-guided by unblocking (TRUC)
 - c. Seminal tract washout treatment
3. Surgical or instrumental sperm collection for artificial reproductive treatment
 - Testis
 - a. Testicular sperm extraction (TESE)
 - b. Testicular sperm aspiration (TESA)
 - c. Testicular fine needle aspiration (TEFNA)
 - Epididymis
 - a. Microsurgical epididymal sperm aspiration (MESA)
 - b. Percutaneous epididymal sperm aspiration (PESA)
 - c. Epididymal sperm extraction (ESE)
 - Vas deferens and distal seminal tract
 - a. Microscopic vasal sperm aspiration (MVSA)

- b. Distal seminal tract aspiration (DISTA)
- c. Transrectal ultrasound-guided aspiration of sperm from intraprostatic cysts communicating with the ED
- d. Seminal tract washout designed to recover sperm for in vitro fertilization (IVF)

Secretory azoospermia

- a. Medical treatment
- b. The varicocele in azoospermia
- c. Surgical removal of sperm from the testicle or instrument for artificial insemination
 1. Testicular sperm extraction (TESE)
 2. Testicular sperm aspiration (TESA) and Testicular fine needle aspiration (TEFNA)

Retrograde ejaculation

- a. Pharmacotherapy
- b. Recovery of sperm from the urine as an aid to artificial insemination

Anejaculation

- a. Etiologic treatments
- b. Treatment aimed to recover sperm for assisted reproductive technology (ART)
 1. Vibratory ED massage
 2. Electroejaculation
 3. Seminal tract washout designed to recover sperm for IVF or cryopreservation of testicular sperm

Obstructive azoospermia

The aim of treating obstructive azoospermia is to restore the patency of the seminal tract and spontaneous fertility. Treatment choice depends on the localization and characteristics of the obstructing lesion. When it is not possible to restore the patency of the seminal tract, the next step is to proceed to surgical sperm recovery (to be used fresh or after cryopreservation for ART).

2. Microsurgery: Reconstruction of the proximal seminal tract

The correct implementation and results of microsurgical reconstruction of the proximal seminal tract depend upon the use of special instruments (surgical microscope), non-reactive suture materials, and the technical skill of the operator. The surgical microscope is essential to evaluate the quantity and quality of sperm during seminal fluid aspiration. This determination dictates the choice of reconstructive surgery.

Surgery is indicated in the following cases:

- Azoospermia confirmed by at least two recent seminal examinations
- Preservation of spermatogenesis on at least one side
- Absence of retrograde ejaculation
- Absence of seminal tract infection

The reconstruction of the seminal tract is still subject to its proximal distal patency, which is demonstrated in the phase immediately preceding reconstructive surgery through

cannulation of the deferent (butterfly needle 23-25 Gauge) and injection of at least 10 ml of saline solution.

Epididymal obstructions: Vasoepididymostomy

Vasoepididymostomy is performed to treat congenital, infectious, post-vasectomy or idiopathic obstruction of the epididymis. The rate of restoration of patency varies between 60% and 87%, and spontaneous pregnancies vary between 10% and 43%.⁵⁻⁸ Accuracy of microsurgical technique affects the outcome of reconstructive procedures on the male reproductive system. The best results are achieved by surgeons with training and ongoing experience in microsurgery. To maximize successful outcomes, surgeons performing vasectomy reversal should be comfortable with anastomoses involving extremely small luminal diameters, and must be competent with both vasovasostomy and vasoepididymostomy, because the latter may be unexpectedly necessary in many cases.

Before vasoepididymostomy, or when anastomosis is not feasible, sperm aspiration and cryopreservation should be performed for future use for ICSI, in case of failure of the anastomosis. In some cases, the reappearance of sperm in the seminal liquid happens more than one year after surgery. Stricture of the anastomosis has been observed after some time, at rates varying between 10% and 21%. The absence of sperm in the epididymal tubule or the presence of diffuse fibrosis of the organ are two negative prognostic factors that indicate the presence of a secretory testicular pathology. The presence of ultrasound abnormalities of the distal seminal tract have recently been reported as adverse prognostic factors for the success rates of recanalization. Vasoepididymostomy in patients with obstruction secondary to vasectomy is more advantageous in terms of costs compared with MESA with ICSI pregnancies.

Technical notes

The epididymis is opened where there is a clear tubular dilation due to the obstacle; however, the opening should be as caudal as possible. The liquid that issues from the epididymis is immediately examined to assess the presence and motility of sperm. If the determination is negative, a more proximal tubule will be opened. If the goal is to make an end-to-end vasostomy, after transverse incision of the epididymis tunica vaginalis, the section of the seminal tubules containing sperm should be chosen to perform the anastomosis with the deferent to reduce the possibility of developing strictures in the future. A latero-terminal vasostomy appears to avoid this eventuality without additional effort. Under optical magnification of the field (40×) (the center of a window previously prepared in the tunica vaginalis of the epididymis), a loop is opened longitudinally and the tubulus is anastomosed to deferent with two stitches (8-0 Prolene). To prevent leakage of seminal fluid and the resulting formation of granulomas, the stitches should be as superficial as possible and at the end it is recommended that fibrin glue be placed on the anastomosis.

Obstructions of the vas deferens: Vasovasostomy

The obstruction of the vas deferens that results from vasectomy or, more rarely, from an incorrect vesiculodeferentography, can usually be successfully treated. By contrast, in

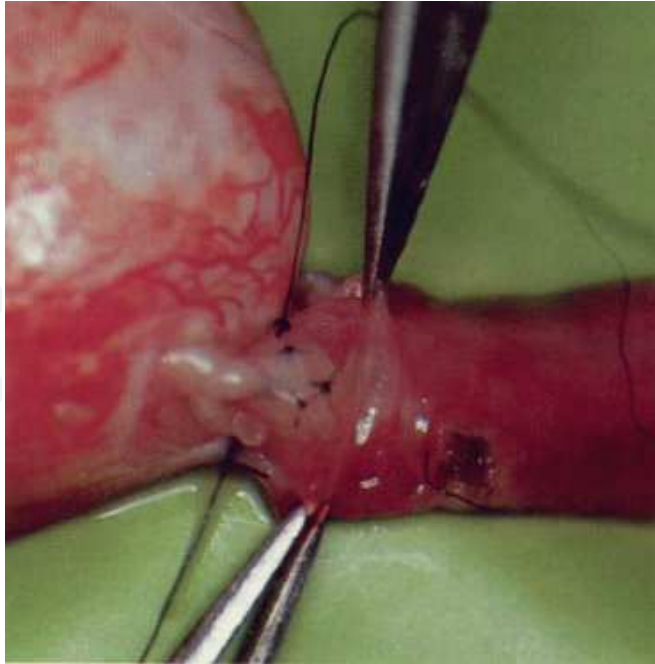


Fig. 2. Vasoepididymostomy

lesions of the distal vas deferens, usually resulting in bilateral herniorrhaphy, the stumps of the vas deferens are often poorly identified in the context of scar tissue. It is therefore necessary to resort to a wide mobilization of the stumps to perform both proximal and distal anastomosis. The outer diameter of the duct remains constant as a result of obstruction, while the inner testicular slope expands approximately 2-4 times. Distal stump sclerosis may progress to scarring. Factors that will influence the success of the anastomosis are:

- The use of a surgical microscope
- The quality of the tissues involved in the anastomosis
- The presence and characteristics of the fluid that is released from the proximal stump of the ductus
- Distal patency of the seminal vesicle
- The duration of obstruction

The recanalization rates extrapolated from the main series (a total of 2385 cases treated) vary between 86% and 93%, while the cumulative spontaneous pregnancy rates range between 52% and 82%. The duration of the obstruction appreciably affect the success rate of vasovasostomy. When the interval between obstruction and recanalization is shorter than 3 years, patency and spontaneous pregnancies are obtained, respectively, in 97% and 76% of cases, compared with 88% and 53% when the interval is between 3 and 8 years, and 71% and 30% when the interval is between 9 and 14 years. Deferential distal obstructions are often incorrigible. In these cases, the aspiration of sperm from the proximal deferential stump may be used or, if there is a concomitant epididymal obstruction, MESA or TESE may be employed (see related chapters).

Technical Notes

Reconstruction of the deferent can be performed in "double layer" or "single layer". In two-layer vasovasostomy, the mucous layer and inner muscle of the two stumps are sutured

with 6 sutures (preferably non-absorbable or slow resorption 9/0-10/0); then, the outer muscular and serosal layers are secured with 6 sutures 8/0-9/0, interspersed with the first. However, the sutures pass through the wall of the deferent at ≥ 6 points, possibly full-thickness.

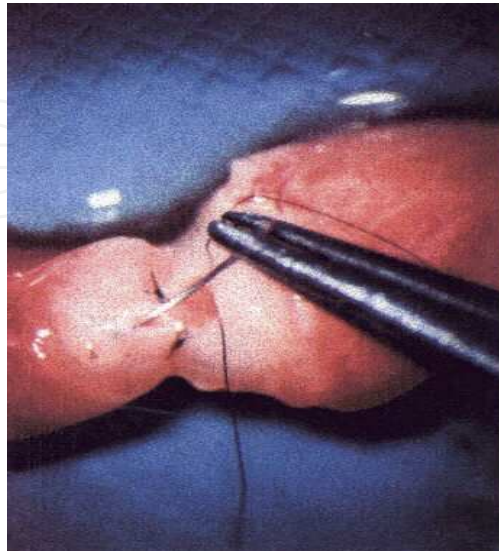


Fig. 3. Vaso-vasostomia

3. Recanalization of the distal seminal tract

Transurethral resection of the ejaculatory ducts (TURED)

Transurethral resection of the ejaculatory ducts (TURED) was proposed in 1973 by Farley and Barnes for the resolution of (EDO). Since then, several studies have documented its effectiveness. The term also includes the endoscopic resection of the ED obstructing prostatic cysts, even if improperly, because in this case the ED are not properly resected, but only the anterior wall of the cyst, making it widely communicate with the prostatic urethra. The indications for TURED are represented by a complete or incomplete congenital or acquired obstruction of the distal seminal tract, caused by atresia, strictures, or scarring; or in the presence of gallstones of ED; or subsequent prostatic cysts, whether or not they communicate with the seminal tract. Only issues relating to the use of TURED in cases of azoospermia will be taken into account.

Until a few years ago, TURED was the only therapeutic option in cases of obstruction of ED. Recently, successful sperm retrieval techniques for assisted reproduction (e.g., ICSI) and the introduction of new techniques (ultrasound-guided sclerotherapy of prostatic cysts, Seminal Tract Wash-out) have reduced its use. Nevertheless, TURED must still be considered an effective therapeutic method that allows patients to obtain natural pregnancies in a significant percentage of cases of obstructive azoospermia. A recent review of 164 cases reported in the literature documented a recanalization rate of 36% and a pregnancy rate of 26%. Regarding cystic obstruction of the ED, TURED could be used in the seminal cysts communicating with the seminal tract. In the presence of non-communicating cysts (Müllerian or median), transrectal ultrasound-guided or percutaneous sclerotherapy are first indicated, and only in case of their failure should TURED be performed.

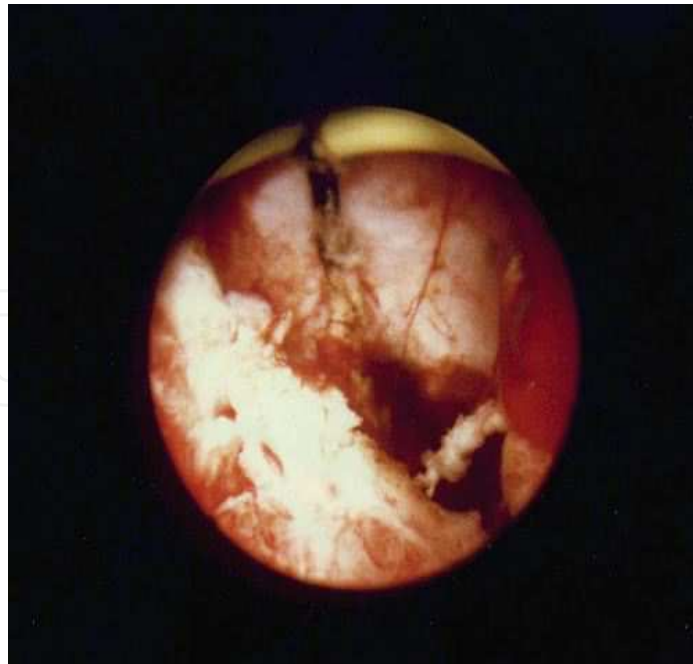


Fig. 4. TURED

Transrectal ultrasonically guided aspiration (TRUCA) of the seminal distal tract

Transrectal ultrasonically guided cyst aspiration (TRUCA) is a minimally invasive technique, suitable to evacuate intraprostatic cysts that are making an extrinsic compression on the ED. The above are of Müllerian cysts that do not communicate with the ED and do not contain sperm. The aspiration of the cyst temporarily or permanently restores normal patency of the ED. This procedure is used as an alternative to endoscopic transurethral incision of the Müllerian cysts.

Technical notes

A transrectal probe of 6.5-7.5 MHz biplanar is used to perform this technique, with a 20-22 G Chiba needle guide connected to a 5 ml syringe for suction. The treatment is conducted with the patient placed on his left side, after oral antibiotic coverage. The aspiration is performed with after the patient had abstained from sex from 4 to 5 days to determine the chemical-physical characteristics of the aspirated fluid and the presence of sperm. Shortly after aspiration, the patient is requested to provide a semen sample for analysis. Immediately after, the clinician should recheck the cyst to assess its possible immediate filling (in this case, the cyst is communicating with the seminal tract, and therefore should not be inflexible). For sclerotherapy, an antibiotic (tetracycline) is instilled into the cyst at a rate of one-tenth of the previously aspirated volume. This procedure allows recovery of patency of the distal seminal tract in 75% of patients.

Seminal tract washout therapy aims to restore the patency of the ejaculatory ducts

Seminal Tract Washout (STW) therapy is indicated in azoospermic patients in whom an ultrasound of the distal seminal tract (controlled before and after ejaculation) documents obstruction of the orifices of the ED.¹ This framework is characterized by an expansion of products that are associated with dilation of the seminal vesicles throughout their course,

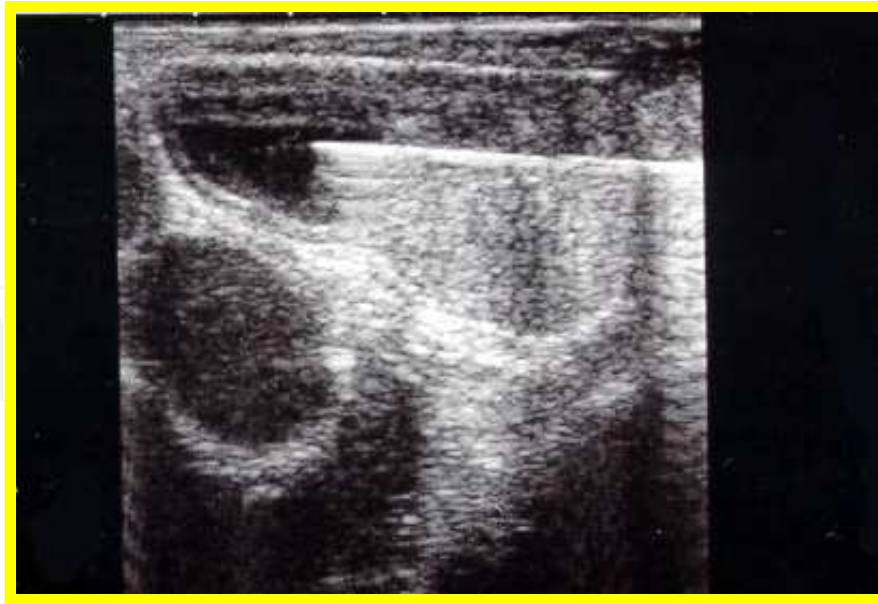


Fig. 5. TRUCA

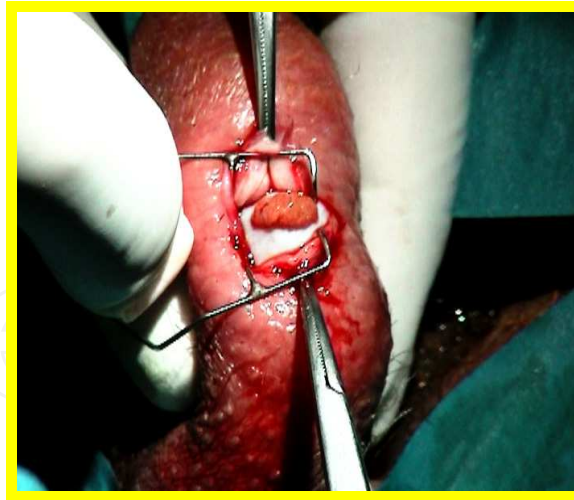possibly with seminal calcifications within them. STW is not indicated in patients with a transrectal ultrasound examination that clearly shows a post-inflammatory obstruction of the ED. The STW runs with the same methods described for the STW designed to retrieve sperm for use in assisted reproduction. The unblocking of the orifice of the ED does not rule out the option of recovering and cryopreserving the sperm present in the seminal tract obstruction.

4. Surgical or instrumental sperm collection for artificial insemination

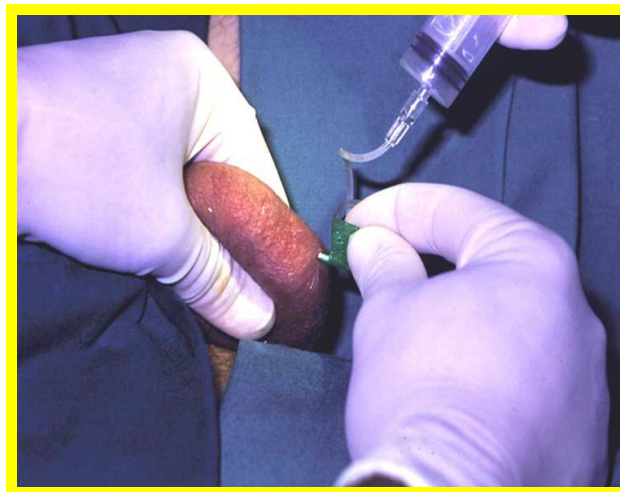Testicular Sperm Extraction (TESE)

TESE is the extraction of sperm from testicular parenchymal fragments obtained from single or multiple surgical biopsies. TESE was initially introduced by Silber et al. in 1995, as a method of sperm retrieval for ICSI in cases of azoospermia.

TESE is one of several options for sperm retrieval in cases of OA, with directions more or less similar to other techniques. As a testicular removal, it has the advantage over epididymal sperm extraction (ESE) of not obstructing the patency of the epididymis tubule. This advantage can be especially important in cases of potentially reconstructible proximal obstructions (which remain the only curative option in reconstructive surgery), particularly those involving cases of distal ejaculation or anejaculation. Compared with epididymal microsurgical sperm aspiration (MESA), TESE permits the recovery of sperm, and is definitely easier because it does not require the use of a surgical microscope. TESE could be considered the ideal solution to retrieve sperm in those rare cases in which obstructive MESA fails, during the same surgical procedure. TESE is slightly more invasive and complex than the percutaneous techniques; however, in comparison TESE allows the recovery of a more appropriate number of sperm (almost always enough to freeze and use in subsequent cycles of ICSI). Several authors have proposed using TESE directly with cryopreservation in the course of diagnostic testicular biopsy.



(a)



(b)

Fig. 6. (a) TESE, (b) TESA

Epididymal Microsurgical Sperm Aspiration (MESA)

MESA was the first sperm retrieval technique used for ART (Silber, 1987). While it was initially associated with IVF, since 1994 MESA has usually been associated with ICSI, even though the use of IVF may still be justified when sperm of good quality and quantity is recovered. MESA allows better recovery in terms of quantity and quality of sperm. Thanks to microsurgical techniques, it is possible to minimize blood contamination and choose the tubules with the best features for good sperm recovery.¹³ The chances of sperm retrieval with MESA are >95%, and it is almost always possible to freeze a sufficient number of sperm for any subsequent cycles of ICSI. Therefore, the male partner is usually subjected to a single intervention. The disadvantages of MESA arise because it is a complex technique that requires a manual microsurgical, as well as the availability of an operating microscope and proper instrumentation. The time and costs of MESA intervention are therefore higher than other techniques. MESA is now performed under local anesthesia with the patient's

immediate resignation. Normally it is sufficient to intervention only in cases of unilateral and insufficient sperm retrieval.

Technical notes

Traditional technique: General anesthesia, or local infiltration of the umbilical cord and the scrotal skin with any anesthesia care or sedation. A median scrotal incision is made with the opening of the tunica vaginalis and externalization of the testis. Under 20-30× magnification, a slot is removed from the head of the epididymis tunica albuginea and hemostasis is ensured with a bipolar forceps jeweler. The clinician then opens the tubule with microscissors and aspirates the liquid with a 22 or 23 G cannula mounted on an insulin syringe. Slight pressure on the testis and epididymis promotes the release of sperm. The extraction is continued with several syringes until leakage occurs, or until the biologist who monitors the sample finds it sufficient for freezing. Closure of the tubule with a 10/0 stitch is optional. In the variant proposed by Schlegel, instead of opening the tubule with microscissors, the tubule is pricked with a specially prepared, sharp glass micropipette connected to a suction system. This alternative saves time spent searching for the area with better sperm quality and minimizes blood contamination.

Mini-MESA: In this variation of the technique, an incision is made approximately 1 cm from the window as a diagnostic testicular biopsy. Instead of exteriorizing the testicle, only the head of the epididymis is dislocated from the incision and secured with a stitch on the edge of the same. The technique then continues in the same way as the traditional technique, using a surgical microscope for subsequent phases of sperm aspiration from the epididymal tubules. Advantages of this alternative technique include the lack of externalization of the testis, reduction of pain experienced by the patient, and a minimized possibility of postoperative surgical adhesions.

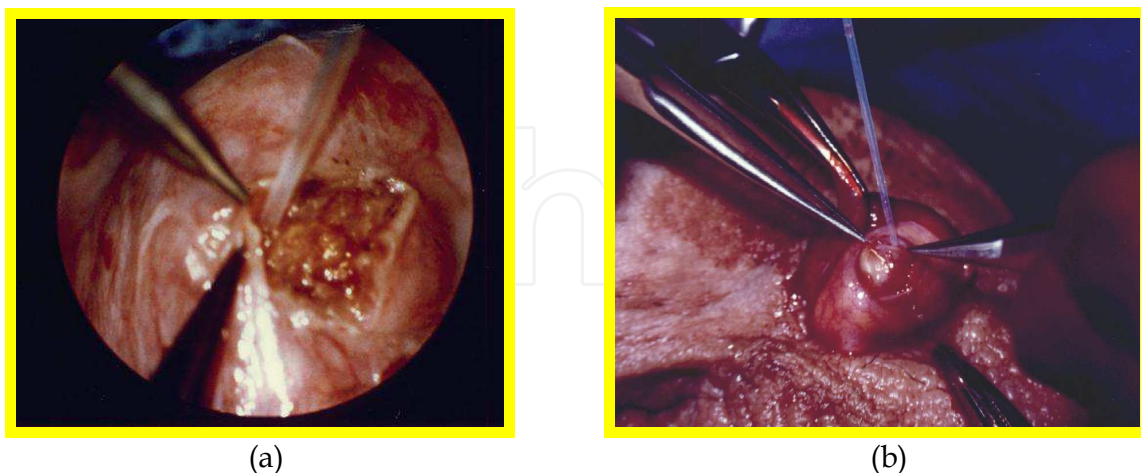


Fig. 7. (a) MESA, (b) Mini MESA

Epididymal Percutaneous Sperm Aspiration (PESA)

Introduced by Craft in 1995, PESA represented the first "economic" alternative to MESA in patients with OA. Like TESA, PESA has the advantages of being easily implemented,

economical, and minimally invasive. The main limitation of PESA is its lower efficacy compared with MESA sperm retrieval. In several studies, PESA seems to allow sperm recovery in approximately 60-70% of OA cases, compared with a 90-95% sperm recovery rate by MESA. The lower sperm recovery rate of PESA is presumably a consequence of the particular anatomic situation of the tubules of the head of the epididymis, which, when obstructed, are not uniformly dilated and do not contain the same amount or quality of sperm. If in the course of MESA is possible to drive on the intake and more dilated tubules with more chance of recovering motile sperm, PESA may just sting tubules without sperm or with sperm of poorer quality. Because PESA results in aspirated sperm of lower quantity and poorer quality, the possibility of freezing sperm for subsequent ICSI cycles is significantly lower with PESA than with MESA. By contrast, compared with TESA, PESA may allow better sperm retrieval, with less contamination from blood or other parenchymal cells. However, PESA involves an increased risk of scrotal hematoma than TESA, caused by the greater vascularity of the area of the head of the epididymis. PESA represents the technique of choice in cases of obstruction or congenital or acquired spermatocele in the epididymis. In this situation, PESA allows easy retrieval of a large amount of sperm with minimal invasiveness, and can be performed without any anesthesia.

Technical Notes

Regarding the need for anesthesia, the same considerations apply to PESA as to TESA. When aspirating, it is best to use a butterfly needle (21 or 22 G) connected to a 20-ml or 50-ml syringe. Aspiration should be applied to only the head of the epididymis, not to the body or tail. The clinician should immobilize the head of the epididymis by holding it between thumb and forefinger, and insert the needle into it. With the syringe, and always under slight suction, advance or retract the needle millimeter-wise until a small amount of clear liquid is observed in the connecting pipe. Continue suction until the flow stops. In most cases, this technique will result in a small quantity of well-aspirated sperm. The aspirated fluid is then diluted in culture medium and examined for sperm. If no sperm is recovered, the clinician should proceed to other aspirations, trying to puncture different parts of the head of the epididymis. It may help to exert pressure on the head of the epididymis for a few minutes, and to keep a bag of ice on the scrotum to minimize the risk of bleeding.

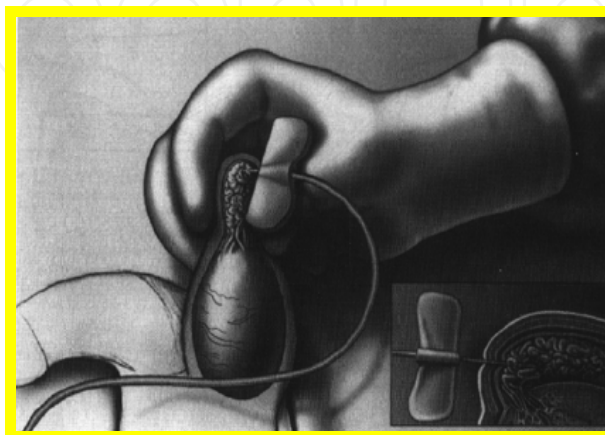


Fig. 8. PESA

5. Epididymis

Epididymal Sperm Extraction (ESE)

ESE is the surgical removal (no need for microsurgical techniques) of more or less substantial portions of the head of the epididymis for sperm extraction. ESE was described for the first time by Kim, although it had already been used sporadically by many clinicians. The extraction technique is identical to TESE. ESE has the advantage of being very fast, does not require the use of a surgical microscope, often provides excellent recoveries that are almost always sufficient to freeze sperm, and is associated with fertilization and pregnancy rates similar to those associated with other techniques. Its main disadvantages are that it is more invasive; the removal or parts of the epididymis is less repeatable (to be performed only in intractable situations of obstruction, such as CBAVD or congenital bilateral agenesis of the vasa deferentia); a higher risk of vascular damage to the testis; and increased blood contamination of the fragment to be treated. ESE is a viable option, and is therefore often used in the course of MESA, when it is not possible to retrieve sperm microaspirates from any of the epididymal sites.

Technical Notes

ESE can be performed under regional anesthesia or sedation. A medial scrotal incision is made, through which the testicle (or simply the head of the epididymis) is exteriorized. With scissors, the surgeon separates it from the testis to approximately 5 mm, dissecting some of the efferent vessels. The surgeon then uses scissors or a scalpel to cut a portion of the epididymis, and the entire head is immersed in a cell culture dish. Next, the biologist will perform the fragmentation of the piece first with scissors or scalpel and then slides with two sterile insulin needles.

Surgical or instrumental collection of sperm for assisted fertilization:

The vas deferens and distal seminal tract

Microscopic Vasal Sperm Aspiration (MVSA)

MVSA consists of the microsurgical aspiration of sperm from the lumen of the deferent. It is indicated in cases of distal deferential obstruction without any possibility of surgical reconstruction (e.g., iatrogenic damage from pelvic surgery or hernioplasty); cases of EDO; cases in which TURED or other techniques cannot be used to harvest sperm (e.g., DISTA); in cases of retrograde ejaculation with insufficient sperm retrieval from the post-orgasm urine; in cases of anejaculation due to different causes; or when vibrostimulation or electroejaculation fail. Finally, MVSA is indicated in selected cases of necrozoospermia or pronounced oligoastenozoospermia in the presence of structural or functional disorders of the emptying of the distal seminal tract that result in prolonged stagnation of the sperm. In these patients, sperm can be obtained from the deferent with good motility and vitality. The recovery of sperm cells that almost always exhibit very good motility makes it possible to opt for less invasive ART techniques (e.g., IVF, intrauterine insemination), as well as freezing. The main disadvantage of MVSA is that the procedure must be performed using microsurgical technique, which is essential for the closure of the rubble of the deferent because of the risk of iatrogenic obstruction.

Technical Notes

MVSA is performed under local anesthesia by infiltration of the scrotal skin. A small incision is made in the scrotum to isolate the deferent and exteriorize it through the surgical access. The vas deferens is cut with a scalpel at the level of a straight portion. With a 23 or 24 G cannula mounted on an insulin syringe or other suction system,³ it is then possible to proceed to the suction of seminal liquid from the lumen of the proximal stump of the deferent. The lumen must be closed with a microsurgical suture (Nylon 10/0), preferably in a double layer (2-3 and 5-6 inside-out stitches).

Distal Seminal Tract Aspiration (DISTA)

Designed as a diagnostic technique, DISTA was subsequently proposed as a treatment to support ART, particularly in cases of azoospermia secondary to an EDO. DISTA involves ultrasound-guided transperineal or transrectal fine needle aspiration of the liquid contained in the seminal vesicles, ED, or cysts of the seminal carrefour in patients with an obstruction of the seminal distal end, thereby achieving sperm retrieval for ART.

The advantage of this technique is that it is minimally invasive compared with TURED; DISTA can be performed under local anesthesia and is easily repeatable. Furthermore, DISTA does not present any of the complications that may arise after TURED, such as the contamination of semen and the reflux of urine into the seminal tract due to the alteration of the antireflux mechanism of the ED. Compared with the techniques used to retrieve sperm from the more proximal seminal tract (deferens: MVSA; epididymis: MESA-PESA; the testis: TESE-TESA), DISTA has the advantages of avoiding the risk of secondary iatrogenic obstructions in these locations; of being quicker and simpler to perform; of being less costly compared with MVSA, MESA, and TESE; and of allowing sperm retrieval that is usually better than TESA, TESE, or PESA. DISTA almost always results in semen that can be frozen for future use in simple ART techniques.

Its disadvantages include the persistent need of an ART technique and its dependence on the availability of an ultrasound machine, as well as even the possibility (albeit negligible) of ascending infections of the seminal tract.

The primary indication for DISTA is cystic duct obstruction (where TURED is not indicated because of high risk); its secondary indication is prostatic cysts communicating with the seminal tract, or intraprostatic cysts in the ED with no obstructions.

Technical Notes

It is advisable to ejaculate the patient immediately before the procedure to increase the number of spermatozoa present in the distal seminal tract. The patient is placed in the lithotomic position or right lateral decubitus. After the administration of systemic antibiotics and enemas (in the case of transrectal puncture), the procedure requires a (preferably linear) transrectal ultrasound probe. The transperineal puncture is performed with local anesthesia. A 20-22 G Chiba type needle is guided by ultrasound to reach the dilated tract (seminal vesicle, ED, prostatic cyst communicating). The liquid content is then aspirated and sent to the laboratory for search and treatment of spermatozoa (swim-up, Percoll, mini-Percoll) to be used for ART.

Transrectal ultrasonically guided sperm cyst aspiration (TRUSCA) can be used to retrieve sperm from Müllerian cysts or the urogenital sinus communicating with one or both ED.

The semen from the aspirated cysts may be suitable for cryopreservation and for subsequent use in ICSI. It may be useful to repeat the procedure a few hours later and immediately after an ejaculation, to increase the likelihood of getting recent sperm flow at the suction site.

Seminal Tract Washout designed to recover sperm for assisted fertilization

Seminal Tract Washout (STW) is an anterograde seminal tract cleaning that pushes spermatozoa from the tails of the epididymis into the bladder, recovering the latter spermatozoa from the bladder by catheterization. The spermatozoa are then cryopreserved or used fresh for ART.

STW is a minimally invasive surgical procedure, applicable in azoospermic (or cryptozoospermic) patients with functional impairment of emptying of the distal seminal tract or a congenital or acquired incomplete anatomic obstruction of the ED. Even in patients with neurogenic anejaculation (an outcome of spinal cord injury of traumatic or iatrogenic origin, juvenile diabetes, or retroperitoneal lymph node dissection for unilateral testicular cancer) and in those with psychogenic anejaculation, sperm retrieval for IVF is satisfactory.

Technical Notes

STW is performed in the outpatient clinic. After the insertion of a Foley Ch 16-18 catheter into the bladder, T6 medium or Ham's F10 is used to wash the bladder and bring the pH to values appropriate to the maintenance of spermatozoa. Twenty milliliters of the same medium are left inside the bladder. Under local funicular anesthesia, the vas deferens is exteriorized with an Allis clamp and loaded between two vascular tapes to insert a 9.5 mm, 25 G butterfly needle.

A 2.5 ml syringe is needed to fill in anterograde direction 20 ml of T6 medium or Ham's F10 for each side. The liquid is immediately recovered from the bladder through the previously inserted catheter and centrifuged (10 min, 600 g), and the pellet is treated with the mini-Percoll technique. The obtained sperm can be used for artificial insemination in vivo or in vitro, or cryopreserved and subsequently used for ICSI.

The full-term pregnancy rates of assisted reproductive technology ART with sperm retrieved using STW are high,⁴ and comparable to those obtained with testicular sperm from obstructive azoospermic subjects.

STW is simple and inexpensive, and does not require microsurgical sutures or paramedical personnel. Compared with TESE and TEFNA, STW allows recovery of a much higher number of sperm, and obtains biological preparations suitable for assisted reproduction techniques in vivo, often without ICSI.

STW is as invasive as a single sample pulp with TESE, and certainly less invasive than multiple TESE withdrawals. It does not require the opening of the tunica vaginalis, the externalization of the gonad, or the suture of the albuginea, and therefore does not carry a risk of bleeding.

6. References


- Bhasin S. Approach to the infertile man. *J Clin Endocrinol Metab.* 2007;92(6):1995-2004.
Campbell AJ, Irvine DS. Male infertility and intracytoplasmic sperm injection (ICSI). *Br Med Bull.* 2000;56(3):616-29.

- Choe JH, Kim JW, Lee JS, Seo JT. Routine screening for classical azoospermia factor deletions of the Y chromosome in azoospermic patients with Klinefelter syndrome. *Asian J Androl*. 2007 Nov;9(6):815-20. PubMed PMID: 17968468.
- Colpi GM, Negri L, Scropo FI, Grugnetti C, Patrizio P. Seminal Tract Washout: a new diagnostic tool in complicated cases of male infertility. *J Androl* 15 (Supplement):17S-22S, 1994.
- Dixit R, Dixit K, Jindal S, Shah KV. An unusual presentation of immotile-cilia syndrome with azoospermia: Case report and literature review. *Lung India*. 2009;26(4):142-5. PubMed PMID: 20532000; PubMed Central PMCID: PMC2876703.
- Donkol RH. Imaging in male-factor obstructive infertility. *World J Radiol* 2010;2(5):172-9.
- Donoso P, Tournaye H, Devroey P. Which is the best sperm retrieval technique for non-obstructive azoospermia? A systematic review. *Hum Reprod Update*. 2007 Nov-Dec;13(6):539-49.
- Esteves SC, Agarwal A. Novel concepts in male infertility. *Int Braz J Urol*.2011;37(1):5-15.
- Everaert K, De Croo I, Kerckhaert W, Dekuyper P, Dhont M, Van der Elst J, De Sutter P, Comhaire F, Mahmoud A, Lumen N. Long term effects of micro-surgical testicular sperm extraction on androgen status in patients with non obstructive azoospermia. *BMC Urol*. 2006 Mar 20;6:9.
- Ezeh UI. Beyond the clinical classification of azoospermia: opinion. *Hum Reprod*. 2000 Nov;15(11):2356-9.
- Foresta C, Moro E, Ferlin A. Y chromosome microdeletions and alterations of spermatogenesis. *Endocr Rev*. 2001 Apr;22(2):226-39.
- Fullerton G, Hamilton M, Maheshwari A. Should non-mosaic Klinefelter syndrome men be labelled as infertile in 2009? *Hum Reprod*. 2010 Mar;25(3):588-97.
- Garg T, LaRosa C, Strawn E, Robb P, Sandlow JI. Outcomes after testicular aspiration and testicular tissue cryopreservation for obstructive azoospermia and ejaculatory dysfunction. *J Urol*. 2008 Dec;180(6):2577-80.
- Gerris J. Methods of semen collection not based on masturbation or surgical sperm retrieval. *Hum Reprod Update*. 1999 May-Jun;5(3):211-5.
- Ho KL, Wong MH, Tam PC. Microsurgical vasoepididymostomy for obstructive azoospermia. *Hong Kong Med J*. 2009 Dec;15(6):452-7.
- Ichijo S, Sigg C, Nagasawa M, Sirawa Y. Vasoseminal vesiculography before and after ejaculation. *Urol. Intern* 36:35, 1981
- Jarow JP. Seminal vesicle aspiration of fertile men. *J Urol* 156(3):1005-1007, 1997.
- Jarzabek K, Zbucka M, Pepiński W, Szamatowicz J, Domitrz J, Janica J, Wołczyński S, Szamatowicz M. Cystic fibrosis as a cause of infertility. *Reprod Biol*. 2004;4(2):119-29.
- Jee SH, Hong YK. One-layer vasovasostomy: microsurgical versus loupe-assisted. *Fertil Steril*. 2010 Nov;94(6):2308-11.
- Kamal A, Fahmy I, Mansour R, Serour G, Aboulghar M, Ramos L, Kremer J. Does the outcome of ICSI in cases of obstructive azoospermia depend on the origin of the retrieved spermatozoa or the cause of obstruction? A comparative analysis. *Fertil Steril*. 2010 Nov;94(6):2135-40.
- La Marca A, Sighinolfi G, Radi D, Argento C, Baraldi E, Artenisio AC, Stabile G, Volpe A. Anti-Mullerian hormone (AMH) as a predictive marker in assisted reproductive technology (ART). *Hum Reprod Update*. 2010 Mar-Apr;16(2):113-30.

- Lee R, Li PS, Goldstein M, Tanrikut C, Schattman G, Schlegel PN. A decision analysis of treatments for obstructive azoospermia. *Hum Reprod*. 2008 Sep;23(9):2043-9.
- Lee R, Li PS, Schlegel PN, Goldstein M. Reassessing reconstruction in the management of obstructive azoospermia: reconstruction or sperm acquisition? *Urol Clin North Am*. 2008; 35(2):289-301
- Marmar JL. The emergence of specialized procedures for the acquisition, processing, and cryopreservation of epididymal and testicular sperm in connection with intracytoplasmic sperm injection. *J Androl*. 1998 Sep-Oct;19(5):517-26.
- McLachlan RI, O'Bryan MK. Clinical Review#: State of the art for genetic testing of infertile men. *J Clin Endocrinol Metab*. 2010 Mar;95(3):1013-24.
- Merchant R, Gandhi G, Allahbadia GN. In vitro fertilization/intracytoplasmic sperm injection for male infertility. *Indian J Urol*. 2011;27(1):121-32.
- Moon MH, Kim SH, Cho JY, Seo JT, Chun YK. Scrotal US for evaluation of infertile men with azoospermia. *Radiology*. 2006 Apr;239(1):168-73.
- Navarro-Costa P, Gonçalves J, Plancha CE. The AZFc region of the Y chromosome: at the crossroads between genetic diversity and male infertility. *Hum Reprod Update*. 2010 Sep-Oct;16(5):525-42.
- Navarro-Costa P, Plancha CE, Gonçalves J. Genetic dissection of the AZF regions of the human Y chromosome: thriller or filler for male (in)fertility? *J Biomed Biotechnol*. 2010;2010:936569.
- Paz G, Gamzu R, Yavetz H. Diagnosis of nonobstructive azoospermia: the laboratory perspective. *J Androl*. 2003 Mar-Apr;24(2):167-9.
- Poongothai J, Gopenath TS, Manonayaki S. Genetics of human male infertility. *Singapore Med J*. 2009 Apr;50(4):336-47.
- Practice Committee of American Society for Reproductive Medicine in collaboration with Society for Male Reproduction and Urology. The management of infertility due to obstructive azoospermia. *Fertil Steril*. 2008 Nov;90(5 Suppl):S121-4.
- Practice Committee of American Society for Reproductive Medicine. Sperm retrieval for obstructive azoospermia. *Fertil Steril*. 2008 Nov;90(5 Suppl):S213-8. Review.
- Sadeghi-Nejad H, Farrokhi F. Genetics of azoospermia: current knowledge, clinical implications, and future directions. Part I. *Urol J*. 2006 Fall;3(4):193-203.
- Sadeghi-Nejad H, Farrokhi F. Genetics of azoospermia: current knowledge, clinical implications, and future directions. Part II: Y chromosome microdeletions. *Urol J*. 2007 Fall;4(4):192-206
- Schlegel PN, Girardi SK. Clinical review 87: In vitro fertilization for male factor infertility. *J Clin Endocrinol Metab*. 1997 Mar;82(3):709-16.
- Semião-Francisco L, Braga DP, Figueira Rde C, Madaschi C, Pasqualotto FF, Iaconelli A Jr, Borges E Jr. Assisted reproductive technology outcomes in azoospermic men: 10 years of experience with surgical sperm retrieval. *Aging Male*. 2010 Mar;13(1):44-50.
- Sertić J, Cvitković P, Myers A, Saiki RK, Stavljenić Rukavina A. Genetic markers of male infertility: Y chromosome microdeletions and cystic fibrosis transmembrane conductance gene mutations. *Croat Med J*. 2001 Aug;42(4):416-20.
- Shah R. Surgical sperm retrieval: Techniques and their indications. *Indian J Urol*. 2011; 27(1):102-9.

- Sharif K. Reclassification of azoospermia: the time has come? *Hum Reprod* 2000 Feb;15(2):237-8.
- Shridharani A, Sandlow JI. Vasectomy reversal versus IVF with sperm retrieval: which is better? *Curr Opin Urol*. 2010 Nov;20(6):503-9.
- Tanrikut C, Goldstein M. Obstructive azoospermia: a microsurgical success story. *Semin Reprod Med*. 2009 Mar;27(2):159-64.
- Tournaye H. Update on surgical sperm recovery--the European view. *Hum Fertil (Camb)*. 2010 Dec;13(4):242-6.
- Van Peperstraten A, Proctor ML, Johnson NP, Philipson G. Techniques for surgical retrieval of sperm prior to intra-cytoplasmic sperm injection (ICSI) for azoospermia. *Cochrane Database Syst Rev*. 2008 Apr 16;(2):CD002807
- Visser L, Westerveld GH, Korver CM, van Daalen SK, Hovingh SE, Rozen S, van der Veen F, Repping S. Y chromosome gr/gr deletions are a risk factor for low semen quality. *Hum Reprod*. 2009 Oct;24(10):2667-73. Epub 2009 Jul 14. PubMed PMID: 19602516.
- Woldringh GH, Besselink DE, Tillema AH, Hendriks JC, Kremer JA. Karyotyping, congenital anomalies and follow-up of children after intracytoplasmic sperm injection with non-ejaculated sperm: a systematic review. *Hum Reprod Update*. 2010 Jan-Feb;16(1):12-9.
- Wood S, Sephton V, Searle T, Thomas K, Schnauffer K, Troup S, Kingsland C, Lewis-Jones I. Effect on clinical outcome of the interval between collection of epididymal and testicular spermatozoa and intracytoplasmic sperm injection in obstructive azoospermia. *J Androl*. 2003 Jan-Feb;24(1):67-72.
- Yamaguchi K, Ishikawa T, Nakano Y, Kondo Y, Shiotani M, Fujisawa M. Rapidly progressing, late-onset obstructive azoospermia linked to herniorrhaphy with mesh. *Fertil Steril*. 2008;90(5):2018.e5-7.
- Zielenski J. Genotype and phenotype in cystic fibrosis. *Respiration*. 2000;67(2):117-33.

IntechOpen



Male Infertility

Edited by Dr. Anu Bashamboo

ISBN 978-953-51-0562-6

Hard cover, 194 pages

Publisher InTech

Published online 20, April, 2012

Published in print edition April, 2012

Male infertility is a multifaceted disease where genetic, epigenetic and environmental factors all contribute to the development of the phenotype. In recent years, there has been an increasing concern about a decline in reproductive health, paralleled by an increase in demand for infertility treatments. This calls for a detailed and thorough understanding of normal and aberrant testicular function and the environmental influences on the establishment and integrity of the male germ cell. This is crucial for understanding the complex pathophysiology of male infertility and eventual success of Assisted Reproductive Technologies.

How to reference

In order to correctly reference this scholarly work, feel free to copy and paste the following:

Antonio Luigi Pastore, Giovanni Palleschi, Luigi Silvestri, Antonino Leto and Antonio Carbone (2012). Obstructive and Non-Obstructive Azoospermia, Male Infertility, Dr. Anu Bashamboo (Ed.), ISBN: 978-953-51-0562-6, InTech, Available from: <http://www.intechopen.com/books/male-infertility/obstructive-and-non-obstructive-azoospermia>

INTECH
open science | open minds

InTech Europe

University Campus STeP Ri
Slavka Krautzeka 83/A
51000 Rijeka, Croatia
Phone: +385 (51) 770 447
Fax: +385 (51) 686 166
www.intechopen.com

InTech China

Unit 405, Office Block, Hotel Equatorial Shanghai
No.65, Yan An Road (West), Shanghai, 200040, China
中国上海市延安西路65号上海国际贵都大饭店办公楼405单元
Phone: +86-21-62489820
Fax: +86-21-62489821

© 2012 The Author(s). Licensee IntechOpen. This is an open access article distributed under the terms of the [Creative Commons Attribution 3.0 License](#), which permits unrestricted use, distribution, and reproduction in any medium, provided the original work is properly cited.

IntechOpen

IntechOpen