

# We are IntechOpen, the world's leading publisher of Open Access books Built by scientists, for scientists

7,300

Open access books available

192,000

International authors and editors

210M

Downloads

Our authors are among the

154

Countries delivered to

TOP 1%

most cited scientists

14%

Contributors from top 500 universities



WEB OF SCIENCE™

Selection of our books indexed in the Book Citation Index  
in Web of Science™ Core Collection (BKCI)

Interested in publishing with us?  
Contact [book.department@intechopen.com](mailto:book.department@intechopen.com)

Numbers displayed above are based on latest data collected.  
For more information visit [www.intechopen.com](http://www.intechopen.com)



# Know-How of the Hormonal Therapy and the Effect of the Male Hormone on Uterus in the Female to Male Transsexuals

Seok Kwun Kim<sup>1</sup> and Myoungseok Han<sup>2</sup>

<sup>1</sup>*Department of Plastic and Reconstructive Surgery,*

<sup>2</sup>*Department of Obstetrics and Gynecology,*

*Dong-A University School of Medicine,*

*South Korea*

## 1. Introduction

Management of the patient with gender identity disorder involves many different aspects of medical care. Transsexualism is a multidimensional phenomenon that requires a multidisciplinary approach in both the diagnostic and treatment phases. Endocrinologists have to work together with mental health professionals and surgeons to provide full counselling, confirm the diagnosis and avoid mistakes or regrets. Hormonal therapy not only has a therapeutic role but also an important diagnostic tool.

Trends in Europe are toward treatment of patients at early age if the diagnosis is appropriately established. This may begin with blocking agents that temporarily suppress pubertal transformation. Secondary sexual trait suppression allows much more successful gender transformation.

Hormonal therapy is used to suppress secondary sexual characteristic of the biological sex, to induce the secondary sex characteristics of the new sex. This therapy should continue lifelong[1].

## 2. Masculinizing effect in female to male hormonal therapy

Endocrinologic masculinization is achieved by the use of testosterone to induce male physical characteristics. Testosterone works primarily by direct stimulation of receptors in target tissues. It elevates serum testosterone level to a male reference range rather than a decrease in serum estradiol[2]. Testosterone also has antigonadotropic action in high doses.

Rapidity and degree of change from testosterone therapy depends on the agents used, dosage, and the patient's responsiveness to endocrine therapy. Typically, within the first 1-3 months patients experience oilier skin and acne, increased libido, increased muscle mass and upper body strength, and redistribution of the fat to a more masculine pattern[3, 12].

The voice changes to crack and deepen within the first 3-6 months, but it can take a year or more for the voice pitch to fully drop [13].

In 75% FTMs testosterone will cause voice pitch to drop to a level sufficient for passability as male even on the telephone [4].

The clitoral enlargement begins within the first few months of testosterone initiation and typically plateaus within the first year [14, 15]. The degree of enlargement is variable with studies reporting a range of 3.5 – 6 cm maximal when stretched [14, 15, 16]. Clitoral growth dose not appear to be enhanced by topical application of testosterone to the clitoris.

Long-term testosterone use causes vaginal and cervical atrophy [3, 17], with decreased vaginal secretion and difficult penetration [12].

In most cases, menses stop within 1 – 6 months [5-8, 14-16, 18, 19]. If after three months menses have not stopped, the dosage of testosterone may be increased until serum free testosterone is within upper quartile of the normal male range or menses stop. Despite endometrial atrophy, cessation of menses, and reduced fertility there is evidence of ovulation even after several years of testosterone administration [17].

There is gradual increased growth, coarseness, and thickness of hair on the torso and extremities in the first year [3, 4, 6, 7, 16]. Facial hair increases more slowly, typically taking 1 - 4 years to reach full growth. Some patients experience male pattern baldness during this later stage of masculinization [4, 6-8, 11, 20].

Voice change, facial hair growth and male pattern baldness are not reversible, which other changes are reversible if hormone is stopped. Clitoral growth and sterility may or may not reversible(Table 1).

Effect	Onset (months)	Maximum (yr)
Skin oiliness/acne	1-6	1-2
Facial/body hair growth	6-12	4-5
Scalp hair loss	6-12	
Increased muscle mass/strength	6-12	2-5
Fat redistribution	1-6	2-5
Cessation of menses	2-6	
Clitoral enlargement	3-6	1-2
Vaginal atrophy	3-6	1-2
Deepening of voice	6-12	1-2

Table 1. Masculinizing effects in FTM transsexual persons

### 3. Recommended masculinizing male hormone regimen

Most commonly used preparations are injectable testosterone esters (Jenatestosterone®) administration intramuscularly in dose 200 - 250 mg every two weeks [21]. Sometimes, masculinization effect is low or when patient wants to bring rapid masculinization testosterone esters administrated intramuscularly in dose 200 - 250 mg every week. Serum testosterone level is checked every 3 months for first year and then 1 - 2 times per year afterward for appropriate signs of feminization and for development of adverse reaction. Serum testosterone level should be maintained <55 ng/dl.

At least 12 months of treatment of testosterone can achieve the masculinization. After oophorectomy or achievement of masculinization, administration of testosterone will be reduced to every three or four weeks. Serum testosterone level should be needed to keep within the middle or lower-middle end of the male range. Long acting testosterone undecanoate 1000 mg is available and injections may leave a space at 10 - 12 weeks [22], but masculinizing effect is not certain. Transdermal gel and transdermal patch can be used and also provide good, steady-state testosterone level. AndroGel® is applied 5 - 10 g qd. Androderm® patch is also applied 5 - 10 g daily [23].

To preserve bone density following oophorectomy, testosterone supplementation should be maintained throughout life, and calcium and vitamine D supplementation is recommended [23].

### 4. Recommended monitoring following initial testosterone therapy

At minimum, patients should be seen every month after initiating treatment or while adjusting medication dosages, then every 3 months for the first year, then every six months thereafter. The primary focus of monitoring cross-sex hormone use is to assess the degree of masculinization and the possible presence of adverse effects of medication. However, as with monitoring of any long-term medication, monitoring should take place in the context of comprehensive care of all health concerns.

Masculinization takes place gradually over a period of years. Observed changes to male pattern hair growth and voice should be noted, and the patient should be asked about changes to menstrual pattern, mood, clitoral growth, libido, and sexual function. Other changes should also be noted. To avoid a supraphysiological dose of testosterone, serum free testosterone should be checked 2 - 4 weeks after the starting dose or after a dose adjustment, and every 6 - 12 months thereafter.

All exams should include assessment of weight, cardiovascular risk, diabetes risk, and blood pressure. There are case reports of destabilization of bipolar disorder, schizophrenia, and schizoaffective disorder in non-transgender men with the use of testosterone. Mental health should be monitored carefully in FTMs with these condition for the duration of testosterone therapy.

At minimum, laboratory tests should include fasting blood glucose, hemoglobin, lipid profile, and liver enzymes. The fasting blood glucose should be checked 3 and 6 months after starting testosterone or after a dose adjustment, then annually increase frequency and

monitor A1c if elevated lipids, significant weight gain, elevated fasting glucose levels, personal history of glucose intolerance, or family history of diabetes. Hemoglobin should be checked 3 and 6 months after starting testosterone or after a dose adjustment, then annually. Lipid profile is needed to evaluate 3 and 6 months after starting testosterone or after a dose adjustment, then annually. Liver enzymes also should be checked 3 and 6 months after starting testosterone or after dose increase, then annually.

## 5. Effect of the long-term treatment of testosterone on health

The goal of treatment in the FTM is to induce virilization, deepening of the voice, production of male-pattern body hair growth, and physical contours, and cessation of menses.

The principal hormonal treatment used to accomplish these goals is testosterone preparation. After reassignment surgery, which includes oophorectomy and hysterectomy, hormonal therapy must be continued. It is reasonable to assume that the principles of treatment are very similar to a person without their own gonadal hormone secretion.

An unresolved question is whether in the long term all functions of sex steroids of a subject are adequately covered by cross-sex hormones and whether the administration of cross-sex hormones is appropriate safe. Nearly all hormone related biochemical processes can be sex reversed by administration of cross-sex hormone.

The complication of cross-sex hormone therapy is underreported. Although complications occurring in the long term are seen in general practice, and these complication are only occasionally reported in the scientific literature.

Polycythemia and erythrocytosis were observed in testosterone administration as a rare complication[24, 25]. Relative contraindication (e.g. persons who smoke, have diabetes, have liver diseases, etc) to therapy have been published and should have an in-depth discussion with their physician to balance the risk and benefit of therapy[26]. The worrisome complication of water and sodium retention increased body weight, decreased insulin sensitivity, obstructive sleep apnea, acne, poor lipid profile, and an increase in hematocrit have raised the concern for cardiac and thromboembolytic events.

Cerebral vascular accidents have been reported for individuals with supraphysiological level of testosterone[27, 28]. Polycystic ovarian disease is a risk factor for endometrial cancer[27]. As the association between polycystic ovarian disease and risk of endometrial and ovarian malignancy are not entirely clear and seen in greater numbers in transsexual people before androgen therapy than in the general population[28, 29]. Mild endometrial hyperplasia has been appreciated on removal of the uterus[30]. A case reported in 2 transsexuals with ovarian cancer[31]. Recommendation for hysterectomy and bilateral salpingo-oophorectomy, generally carried out around 15 months after the start of testosterone treatment in the male to female transsexuals, has yet to be fully justified, at least on the grounds of enhanced risk of malignancy.

Total hysterectomy after 2 years of testosterone therapy, followed by 50% reduction in hormone man be a way to avoid these risks[32, 33](Table 2).

- 
1. Water and sodium retention
  2. Increased erythropoiesis
  3. Decreased carbohydrate tolerance
  4. Decreased serum high-density lipoprotein (HDL) cholesterol
  5. Elevated liver enzymes
  6. Weight increase >10%
  7. Emotional or psychiatric problems
  8. Sleep apnea
  9. Acne
  10. Endometrial hyperplasia
  11. Aggression and hypersexuality
  12. Decreased insulin sensitivity
  13. Increased IGF
  14. Decreased bone mineral density after gonadectomy
  15. Ovarian cancer
- 

Table 2. Side Effects of Androgen Therapy in F-T-M Transsexuals

**6. The effect of the testosterone on uterus and ovary**

Human endometrium is a steroid-hormone-dependent tissue whose growth and remodeling respond to estrogen and progesterone secreted from ovary. Increasing circulating estradiol (E2) levels, a consequence of ovarian follicular growth named as ‘follicular’ phase of the cycle, promote endometrial cellular proliferation and tissue thickness, from approximately 2 mm after the postmenstrual repair phase, to 10–12 mm in the periovulatory period. [34] Although myometrial tissues are also influenced by estrogen stimulation for the growth and remodeling, they do not show such dramatic change as much as endometrium.

Testosterone treatments to the female to male transsexuals are a usual method to induce masculinization. Testosterone is one of the potent circulating androgens which are produced from testis and ovary. Ovary and adrenal gland in women produce not only female sex hormones and mineralcorticoid, but also androgens, such as testosterone, androstenedione and dehydroepiandrosterone or its sulfate. Several studies have shown that high plasma androgen levels are associated with adverse reproductive outcome, including infertility and increased incidence of miscarriage.[35, 36] Those clinical features imply that androgens have a potency to affect the endometrial cellular function and promote histological changes.



Polycystic ovary syndrome (PCOS), which is characterized by high circulating testosterone and androstenedione level, expresses different endometrial pattern, such as endometrial hyperplasia or cancer, compared to women with normal androgen level.[37] Those pathologic changes in PCOS patients are attributed to estrogen stimulation to the endometrium, which is aromatized from circulating androgens. Hyperandrogenic symptoms like acne or hirsutism are found in some PCOS patients.

However, it is rarely reported what effect on the uterus would be observed after long term exogenous testosterone treatment among FTM patients. Although it is easily acceptable that there are no definite gross changes of uterus and ovary, interesting histological features are expressed in a few articles. In 1986, Miller et al. reported histologic characteristics of uterus extirpated from FTMs. In the study, severe atrophied uterine cervix was found and variable degrees of atrophic change of endometrium were observed as well.[38] Such changes have been also observed in our previous histologic study on the extirpated uterus from 16 FTMs.(Fig.1, Fig.2) These changes are comparable with proliferative change of endometrium in PCOS. This means that androgen action on endometrium in FTMs is much higher than that of PCOS patients. Meanwhile, we also found that ovarian histologic changes in FTMs were polycystic appearance similar to those of PCOS.[39](Fig. 3) It is thought that the polycystic change of ovary might be due to multiple follicle recruitment action caused by androgen, which is thought to be the pathophysiologic theory about PCOS.

Finally, it is concluded that the histologic changes of endometrium and ovary are atrophic and polycystic appearance according to the duration of testosterone treatments. Molecular mechanisms on those changes would be clarified in the future.

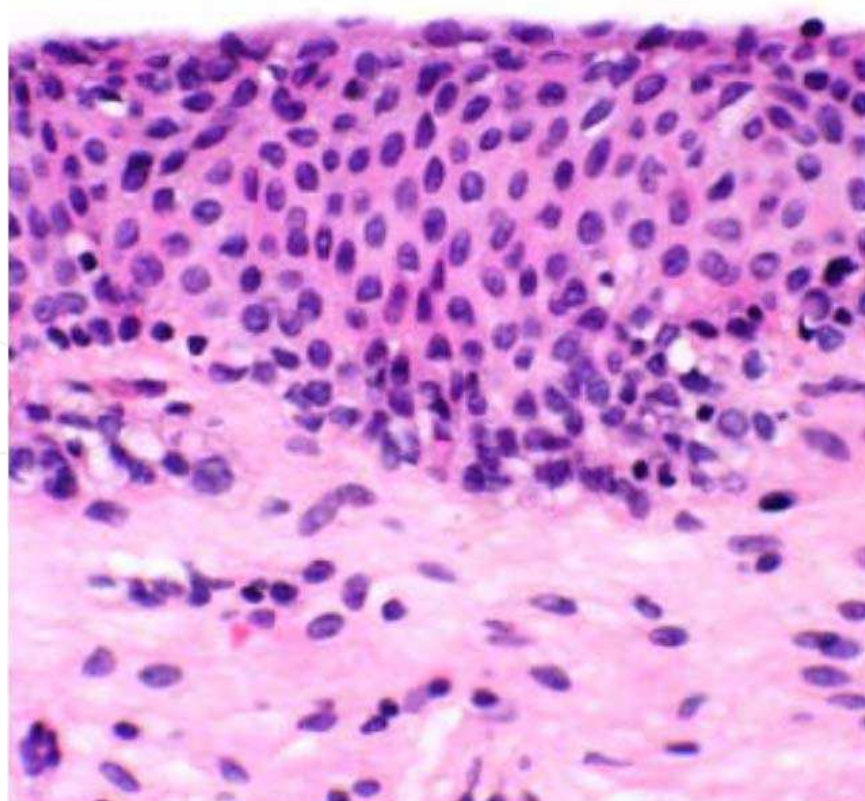


Fig. 1. Atrophied epithelium of exocervix (H-E, X400) (Kor J Fertil Steril 2005;32:325-330)

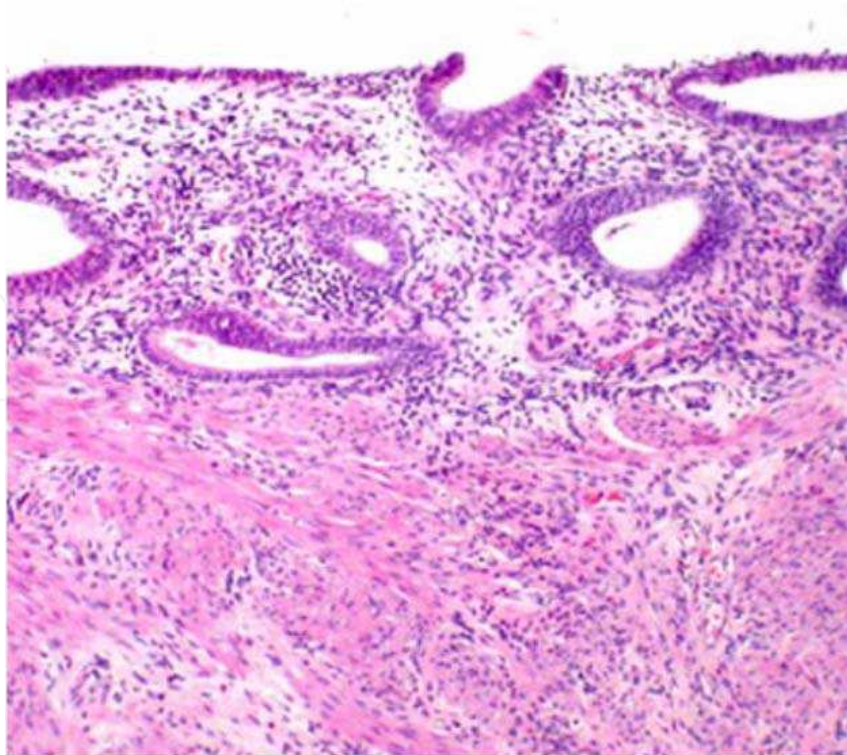


Fig. 2. Atrophy of endometrium (H-E, x200). (Kor J Fertil Steril 2005;32:325-330)

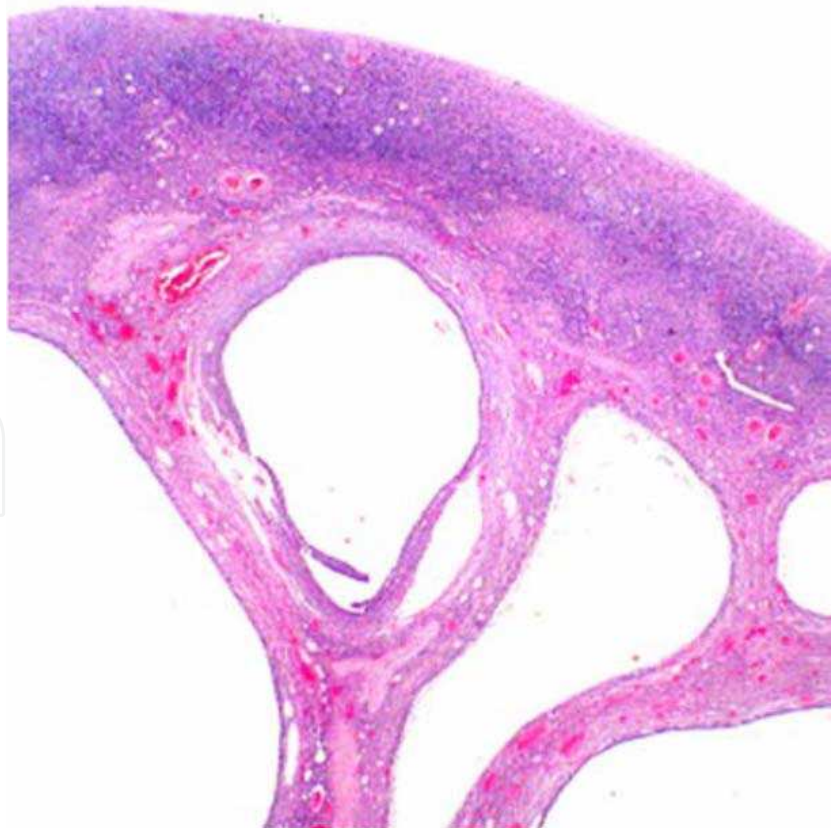


Fig. 3. Multiple cystic follicles in the ovarian cortex (H-E, X10) (Kor J Fertil Steril 2005;32:325-330)



## 7. Conclusions

The use of hormonal therapy in transsexualism is associated with appropriate physical change. Side effects in carefully monitored patients are usually few but are more likely to cause serious complications when therapy is too aggressive. This is particularly true in the FTM transsexual patients who are likely candidates for complications of dyslipoproteinemia which include premature atherogenesis, diabetes mellitus, hypertension, increased insulin resistance, and obesity. Investigators propose that initial treatment with androgen therapy which must be supraphysiological to suppress gonadotropins and virilize the patient should be kept to maximum of no more than 2 years. Following sex reassignment surgery, the dosage should be reduced by half in most patients.

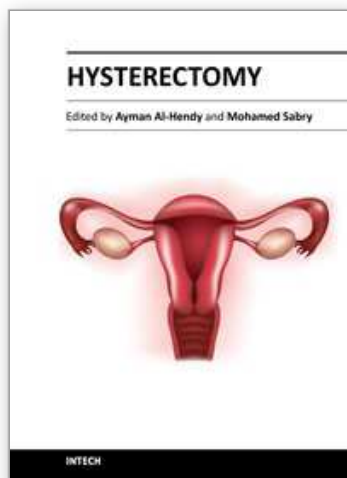
It is likely to reduce not only the duration of large dosage androgen therapy but also the potential risk of endometrial hyperplasia and uterine carcinoma. The role of the concerned physician is to be fully aware of potential risk of this therapy so as to adjust treatment and minimize potential complications.

## 8. References

- [1] Kaufman, D., & Maasdam, J. V. (2006). Surgery for gender identity disorder, Plastic surgery, 2nd ed. Philadelphia, PA: Saunders., 1305-1316.
- [2] Moore, E., Wisniewski, A., & Dobs, A. (2003). Endocrine treatment of transsexual people: a review of treatment regimens, outcomes, and adverse effects. *Journal of Clinical Endocrinology & Metabolism*, 88, 3467-3473.
- [3] Schlatterer, K., von Werder, K., & Stalla, G. K. (1996). Multistep treatment concept of transsexual patients. *Experimental and Clinical Endocrinology and Diabetes*, 104, 413-9.
- [4] Kirk, S., & Rothblatt, M. (1995). Medical, legal and workplace issues for the transsexual. Watertown, MA: Together Lifeworks.
- [5] Steinbeck, A. (1997). Hormonal medication for transsexuals. *Venereology: Interdisciplinary, International Journal of Sexual Health*, 10, 175-177.
- [6] Tangpricha, V., Ducharme, S. H., Barber, T. W., & Chipkin, S. R. (2003). Endocrinologic treatment of gender identity disorders. *Endocrine Practice*, 9, 12-21.
- [7] Bromham, D. & Pearson, R. (1996). The pharmacological treatment of transsexuals. *British Journal of Sexual Medicine*, 23(5) [no page numbers in file copy].
- [8] Flaherty, C., Franicevich, J., Freeman, M., Klein, P., Kohler, L., Lusardi, C., Martinez, L., Monihan, M., Vormohr, J., & Zevin, B. (2001). Protocols for hormonal reassignment of gender. San Francisco: San Francisco Department of Public Health. Retrieved January 1, 2005, from <http://www.dph.sf.ca.us/chn/HlthCtrs/HlthCtrDocs/TransGendprotocols.pdf>
- [9] Elbers, J. M. H., Asscheman, H., Seidell, J. C., & Gooren, L. J. G. (1999). Effects of sex steroid hormones on regional fat depots as assessed by magnetic resonance imaging in transsexuals. *American Journal of Physiology*, 276, E317-E325.
- [10] Slabbekoorn, D., Van Goozen, S. H. M., Gooren, L. J. G., & Cohen-Kettenis, P. T. (2001). Effects of cross-sex hormone treatment on emotionality in transsexuals. *International Journal of Transgenderism*, 5. Retrieved January 1, 2005, from [http://www.symposion.com/ijt/ijtvo05no03\\_02.htm](http://www.symposion.com/ijt/ijtvo05no03_02.htm)

- [11] Dimensions (2003). Informed consent for testosterone therapy for female-to-male transition. San Francisco, CA: Castro-Mission Health Center, San Francisco Department of Public Health. Retrieved January 1, 2005, from <http://tghealth-critiques.tripod.com/consen2.htm>
- [12] The Gender Centre Inc. (2001). Testosterone hormone information II. Sydney, Australia: The Gender Centre Inc. Retrieved January 1, 2005, from [http://www.gendercentre.org.au/testosterone\\_2.htm](http://www.gendercentre.org.au/testosterone_2.htm)
- [13] Van Borsel, J., De Cuypere, G., Rubens, R., & Destaerke, B. (2000). Voice problems in female-to-male transsexuals. *International Journal of Language & Communication Disorders*, 35, 427-442.
- [14] Gooren, L. J. G. (n.d.). Transsexualism: Introduction and general aspects of treatment. Retrieved January 1, 2005, from <http://www.xs4all.nl/~txtbreed/gender/gooren.html>
- [15] Meyer, W. J., III, Webb, A., Stuart, C. A., Finkelstein, J. W., Lawrence, B., & Walker, P. A. (1986). Physical and hormonal evaluation of transsexual patients: a longitudinal study. *Archives of Sexual Behavior*, 15, 121-138.
- [16] Meyer, W. J., III, Finkelstein, J. W., Stuart, C. A., Webb, A., Smith, E. R., Payer, A. F., & Walker, P. A. (1981). Physical and hormonal evaluation of transsexual patients during hormonal therapy. *Archives of Sexual Behavior*, 10, 347-56.
- [17] Miller, N., Bedard, Y. C., Cooter, N. B., & Shaul, D. L. (1986). Histological changes in the genital tract in transsexual women following androgen therapy. *Histopathology*, 10, 661-669.
- [18] Futterweit, W. (1998). Endocrine therapy of transsexualism and potential complications of long-term treatment. *Archives of Sexual Behavior*, 27, 209-226.
- [19] Israel, G. E., & Tarver, D. E. I. (1997). *Transgender care: Recommended guidelines, practical information, and personal accounts*. Philadelphia, PA: Temple University Press.
- [20] Feldman, J. & Bockting, W. O. (2003). Transgender health. *Minnesota Medicine*, 86, 25-32.
- [21] Louis, J. G., Erik J. G., & Mathijs, C. B. (2008). Long-Term Treatment of Transsexuals with Cross-Sex Hormones: Extensive Personal Experience. *J Clin Endocrinol Metab*, 93, 19-25.
- [22] Louis, G. (2005). Hormone Treatment of the Adult Transsexual Patient. *Horm Res*, 64(2), 31-36
- [23] Vancouver Coastal Health, Transcend Transgender Support & Education Society, and the Canadian Rainbow Health Coalition. (2006). Endocrine therapy for transgender adults in British Columbia: Suggested guidelines. from <http://transhealth.vch.ca>
- [24] Wilson, J., & Griffin, J. (1980). The use and misuse of androgens. *Metabolism*, 29, 1278-1295.
- [25] Ammus, S. (1989) The role of androgens in the treatment of hematologic disorders. *Adv Intern Med*, 34, 191-208
- [26] Nagelberg, S., Laue, L., Loriaux, L., Liu, L., & Sherins, R. (1986) Cerebrovascular accident associated with testosterone therapy in a 21-year-old hypogonadal man. *N Engl J Med*, 314, 649-650
- [27] Futterweit, W. (1984) Clinical features of polycystic ovarian disease. In: *Polycystic ovarian disease*. New York: Springer-Verlag; 83-95

- [28] Futterweit, W., Weiss, R., & Fagerstrom. (1986) Endocrine evaluation of forty female-to-male transsexual people: increased frequency of polycystic ovarian disease in female transsexualism. *Arch Sex Behav*, 15, 69–78.
- [29] Balen. A., Schachter. M., Montgomery, D., Reid, R., & Jacobs, H. (1993) Polycystic ovaries are a common finding in untreated female to male transsexual people. *Clin Endocrinol (Oxf)* 38, 325–329.
- [30] Futterweit. W., & Deligdisch, L. (1986) Histopathological effects of exogenously administered testosterone in 19 female to male transsexual people. *J Clin Endocrinol Metab*, 62, 16–21.
- [31] Hage, J., Dekker, J., Karim. R., Verheijen, R., & Bloemena, Em. (2000) Ovarian cancer in female-to-male transsexual people: report of two cases. *Gynecol Oncology*, 76, 413–415.
- [32] Michel, A., Mormont, C., & Legros, J. (2001). A psycho-endocrinological overview of transsexualism. *Eur J Endocrinol*, 145, 365–376.
- [33] Leiter, E., Futterweit, W., & Brown, G. (1993). In: Webster G, Kirby R, King L, Goldwasser B, eds. *Reconstructive urology*. Boston: Blackwell Scientific Publications; 23, 921–932
- [34] Giudice LC. Elucidating endometrial function in the post-genomic era. *Human Reproduction Update* 2003;9: 223–235.
- [35] Okon MA, Laird SM, Tuckerman EM, Li TC. Serum androgen levels in women who suffer recurrent miscarriage and their correlation with markers of endometrial function. *Fertil Steril* 1998;69:682–90.
- [36] Tulppala M, Stenman UH, Cacciatore B, Ylikorkala O. Polycystic ovaries and levels of gonadotrophins and androgens in recurrent miscarriage: prospective study in 50 women. *Br J Obstet Gynaecol* 1993;100:348 –52.
- [37] Cheung AP. Ultrasound and menstrual history in predicting endometrial hyperplasia in polycystic ovary syndrome. *Obstetrics and Gynecology* 2001; 98: 325–331.
- [38] Miller N, Bedard YC, Cooter NB, Shaul DL. Histological changes in the genital tract in transsexual women following androgen therapy. *Histopathology* 1986; 10: 661–9.
- [39] Byun JC, Kwak BG, Shin JH, Cha MS, Han MS, Rha SH, Kim SK. The Histologic Features of the Uterus and Adnexa Extirpated from Gender Identity Disorder Patients with Depot Androgen Injection. *Kor J Fertil Steril* 2005;32:325–330.



## **Hysterectomy**

Edited by Dr. Ayman Al-Hendy

ISBN 978-953-51-0434-6

Hard cover, 426 pages

**Publisher** InTech

**Published online** 20, April, 2012

**Published in print edition** April, 2012

This book is intended for the general and family practitioners, as well as for gynecologists, specialists in gynecological surgery, general surgeons, urologists and all other surgical specialists that perform procedures in or around the female pelvis, in addition to intensives and all other specialties and health care professionals who care for women before, during or after hysterectomy. The aim of this book is to review the recent achievements of the research community regarding the field of gynecologic surgery and hysterectomy as well as highlight future directions and where this field is heading. While no single volume can adequately cover the diversity of issues and facets in relation to such a common and important procedure such as hysterectomy, this book will attempt to address the pivotal topics especially in regards to safety, risk management as well as pre- and post-operative care.

### **How to reference**

In order to correctly reference this scholarly work, feel free to copy and paste the following:

Seok Kwun Kim and Myoungseok Han (2012). Know-How of the Hormonal Therapy and the Effect of the Male Hormone on Uterus in the Female to Male Transsexuals, Hysterectomy, Dr. Ayman Al-Hendy (Ed.), ISBN: 978-953-51-0434-6, InTech, Available from: <http://www.intechopen.com/books/hysterectomy/know-how-of-the-hormonal-therapy-and-the-effect-of-the-male-hormone-on-uterus-in-the-female-to-male->

**INTECH**  
open science | open minds

#### **InTech Europe**

University Campus STeP Ri  
Slavka Krautzeka 83/A  
51000 Rijeka, Croatia  
Phone: +385 (51) 770 447  
Fax: +385 (51) 686 166  
[www.intechopen.com](http://www.intechopen.com)

#### **InTech China**

Unit 405, Office Block, Hotel Equatorial Shanghai  
No.65, Yan An Road (West), Shanghai, 200040, China  
中国上海市延安西路65号上海国际贵都大饭店办公楼405单元  
Phone: +86-21-62489820  
Fax: +86-21-62489821

© 2012 The Author(s). Licensee IntechOpen. This is an open access article distributed under the terms of the [Creative Commons Attribution 3.0 License](https://creativecommons.org/licenses/by/3.0/), which permits unrestricted use, distribution, and reproduction in any medium, provided the original work is properly cited.

IntechOpen

IntechOpen