

We are IntechOpen, the world's leading publisher of Open Access books Built by scientists, for scientists

4,400

Open access books available

117,000

International authors and editors

130M

Downloads

Our authors are among the

154

Countries delivered to

TOP 1%

most cited scientists

12.2%

Contributors from top 500 universities



WEB OF SCIENCE™

Selection of our books indexed in the Book Citation Index
in Web of Science™ Core Collection (BKCI)

Interested in publishing with us?
Contact book.department@intechopen.com

Numbers displayed above are based on latest data collected.
For more information visit www.intechopen.com



Hallux Valgus Correction in Young Patients with Minimally Invasive Technique

Salvatore Moscadini¹ and Giuseppe Moscadini²

¹Division of Orthopaedics and Traumatology, University of Palermo,

²Pediatric Orthopaedic Division,

“Ospedali Riuniti Villa Sofia-Cervello” Hospital, Palermo,
Italy

1. Introduction

Hallux valgus is a common foot problem which in its early stages will affect just the first metatarsophalangeal joint.

Although hallux valgus has been described for over 100 years (Hueter, 1871, as cited in Kelikian, 1965), the etiology and the definitive treatment remain uncertain.

The term hallux valgus was introduced into the literature in 1871 when Hueter (Hueter, 1871, as cited in Kelikian, 1965) defined the deformity as an abduction contracture in which the great toe is turned away from the mid-line of the body (fig. 1). The adjective valgus implies a static deformity and should not be used interchangeably with abductus which refers to movement caused by muscle function.

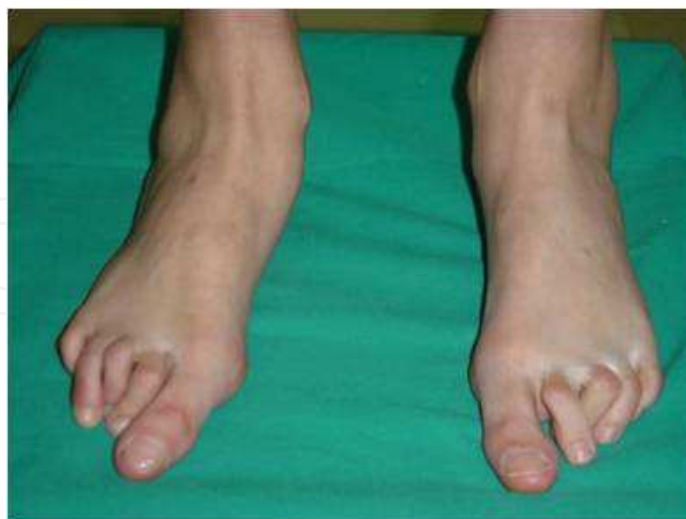

Fig. 1. Bilateral hallux valgus deformity

It is now recognized, particularly in juvenile patients, that a hallux valgus deformity can originate due to lateral deviation of the articular surface of the metatarsal head without subluxation of the first MTP joint.

Bunion is another term, derived from the Latin word *bunio* (meaning turnip), which is commonly used to describe the hallux valgus deformity and it can refer both to the inflammation of the bursa overlying the MTP joint and to the bony medial eminence which becomes apparent at quite an early stage in the development of hallux valgus.

The dividing line between a normal and a hallux valgus foot is contentious.

It is likely that hallux valgus is not a yes or no phenomenon but rather represents a continuum of variable severity. It can also be associated with abnormal foot mechanics, such as a contracted Achilles tendon, severe pes planus, generalized neuromuscular disease such as cerebral palsy or a cerebrovascular accident, or an acquired deformity of the hindfoot secondary to rupture of the posterior tibial tendon. It can likewise be associated with various inflammatory arthritic conditions, such as rheumatoid arthritis.

2. Anatomy

The articulation of the first MTP joint of the great toe differs from that of the lesser toes in that it has a sesamoid mechanism. The head of the first metatarsal articulates with the somewhat smaller, concave elliptical base of the proximal phalanx. A fan-shaped ligamentous band originates from the medial and lateral metatarsal epicondyles and constitutes the collateral ligaments of the MTP joint, that interdigitate with ligaments of the sesamoids.

The two tendons of the flexor hallucis brevis, the abductor and adductor hallucis, the plantar aponeurosis, and the joint capsule condense on the plantar aspect of the MTP joint to form the plantar plate.

A sesamoid bone is contained in each tendon of the flexor hallucis brevis and articulates by means of cartilage-covered convex facets on its superior surface, with the corresponding longitudinal grooves on the inferior surface of the first metatarsal head. Distally, the two sesamoids are attached by the sesamoid-phalangeal ligament to the base of the proximal phalanx.

The tendons and muscles that move the great toe are arranged around the MTP joint in four groups. Dorsal group: long and short extensor tendons; plantar group: long and short flexor tendons; the last two groups are composed of abductor (medially) and adductor (laterally) hallucis, both pass much nearer the plantar surface than the dorsal surface.

The adductor hallucis, arising from the lesser metatarsal shafts, is made up of two segments, the transverse and the oblique heads, which insert on the plantar lateral aspect of the base of the proximal phalanx and also blend with the plantar plate and the sesamoid complex. The adductor hallucis balances the abductor forces of the abductor hallucis. Acting in the line parallel to this bone and using the head of the first metatarsal as a fulcrum, the abductor hallucis pushes the first metatarsal toward the second metatarsal.

The base of the first metatarsal has a mildly sinusoidal articular surface that articulates with the distal articular surface of the first cuneiform. The orientation of the MTC joint may determine the amount of the metatarsus primus varus, and the shape of the articulation may affect metatarsal mobility. A medial inclination of up to 8 degrees at the MTC joint is normal. The axis of motion of the tarsometatarsal articulation is quite stable in the central

portion because of interlocking of the central metatarsals and cuneiforms. Stability of first and fifth metatarsal, instead, is determined also by the surrounding capsular structures. Therefore, when ligamentous laxity is present, the first metatarsal may deviate medially and the fifth metatarsal laterally in the development of a splay foot deformity.

3. Pathophysiology

The target of a proper treatment of the hallux valgus must include the identification and control of its causes, especially in cases of juvenile hallux valgus. For this reason, it is important understanding which biomechanical dynamics are responsible of the deformity. First of all, we can indentify two foot morphotypes, according to the relationship on the transverse plane between the different sections in which foot can be split (rear tarsus, front tarsus, metatarsus and toes): rectus foot type and adductus foot type. (Root et al.,1977)

In the first one, longitudinal axes of metatarsus and hindfoot tend to be parallel, instead in the adducted forefoot, the metatarsus is angled in adduction respect to the hindfoot.

Regardless of the type of foot, the longitudinal axis of fingers tend to be parallel to the axis of the hindfoot. This allows, in fact, a greater efficiency to the fingers in walking. So, larger is the angle of adduction of the forefoot over the heel, greater is the angle of abduction of the fingers over the metatarsals. This is due to a potential imbalance between the adductors and abductors forces that are exerted on the fingers, with a prevalence of second ones on first ones.

The hallux and the first MTP joint play a significant role in the transfer of weight-bearing forces during locomotion and certain pathologic conditions diminish this ability of the first MTP joint.

Several pathogenetic factors have an important role in the establishment of the deformity.

The excessive pronation of the foot is recognized since long time as a cause of hallux valgus.

In 1965 Kelikian suggested that collapse of the inner border of the midfoot, depressed the base of the first metatarsal downwards, while tilting the metatarsal head upwards. The medial capsule of the first metatarsophalangeal joint offered less resistance than the base of the proximal phalanx and the metatarsal head then subluxed medially.

Pronation of the subtalar joint, in fact, during the push-off phase of gait results in eversion of the foot; it increases the contact area to the ground of the first metatarsal head and causes dorsiflexion of the first metatarsal ray; it, also, hinders the stabilization of the forefoot on the hindfoot and also the stabilization of the cuboid, reflection point of the peroneus longus. Under these conditions, the contraction of the peroneus longus causes lifting of the lateral border of the foot and thus accentuates the pronation of the subtalar joint, instead of inducing plantarflexion and stabilization of the first metatarsal ray (Fig. 2). It determines, then, the unfolding of the long peroneal tendon in its plantar portion, resulting in loss of stabilizing and plantarflexion function on the 1st metatarsal ray (Root et al.,1977).

Once the first MTP become destabilized, it doesn't permit anymore a correct carrying of the weight from the first metatarsus to the great toe.

The loss of stability of the hallux does not allow to the transverse head of the Adductor hallucis to perform its normal function. It stabilizes the foot to the ground, acting on the

great toe. Its contraction is necessary to prevent the fan shaped enlargement of metatarsals. If there is a loss of stability of the hallux, the transverse head of the Adductor hallucis acts as an abductor, causing a progressive increase in the MTP angle (hallux abductus), representing a decisive factor in launching the deformity on the transverse plane. The contraction of flexor muscles, longus and brevis, makes the great toe adhering to the ground, trying ineffectually to stabilize the finger even in the case of a first ray hypermobility.

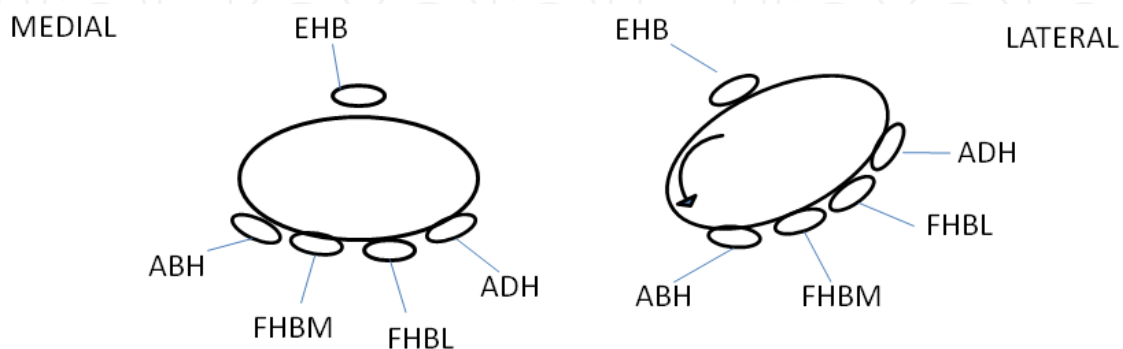


Fig. 2. Representation of tendons around the first metatarsal head. Left: articulation in a balanced state; right: position of the tendons in hallux valgus deformity. ABH, abductor hallucis; ADH, adductor hallucis; EHB, extensor hallucis brevis; FHBL, flexor hallucis brevis lateral head; FHBM, flexor hallucis brevis medial head.

In addition to dorsiflexion, pronation of the foot imposes a longitudinal rotation of the first ray (metatarsal and phalanges), enhanced by weight bearing, that places the axis of the MTP joint in an oblique plane relative to the floor. As under normal conditions, the first MTP joint has not range of motion along the frontal plane, it results in a deformity of the first metatarsal to the lateral direction, and an alteration in valgus of the great toe (Fig. 3). This is the mechanism that initiates the deformity along the frontal plane.

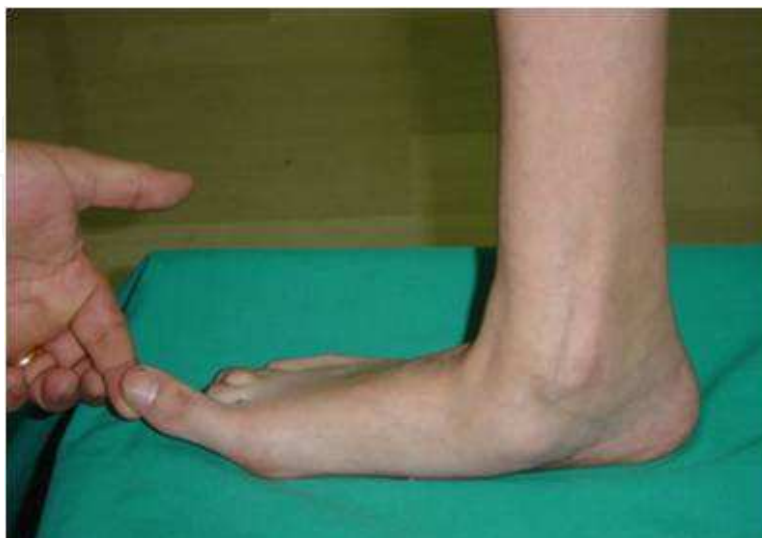

Fig. 3. Pronated foot associated with hallux valgus deformity. Pronation imposes a longitudinal rotation of the first ray that results in a lateral deformity of the first metatarsal, and a valgus great toe.

As the hallux valgus deformity progresses, the soft tissues on the lateral aspect of the MTP joint become contracted, and those on the medial aspect become attenuated. The metatarsal head is pushed in a medial direction by the lateral deviation of the proximal phalanx, thereby progressively exposing the sesamoids, which are anchored in place by the transverse metatarsal ligament and the adductor hallucis muscle. As the sesamoid sling slides beneath the first metatarsal head, the hallux gradually pronates. As this dynamic joint deformity occurs the medial eminence often becomes more prominent. Root, Orien and Weed (Root et al., 1977) proposed also that the inverted and dorsiflexed position of the hypermobile first metatarsal, led to articulation of the tibial sesamoid with the osseous intersesamoidal ridge. Erosion of the ridge followed, further destabilising the first metatarsophalangeal joint. Once the hallux had deviated so far laterally that it lay in contact with the second toe, a retrograde force was directed back across the first metatarsophalangeal joint which forced the first metatarsal into metatarsus primus varus, or metatarsus primus adductus as it was called by Root et al. (Root et al., 1977)

4. Etiology

Hallux valgus is certainly a multifactorial disease where extrinsic and intrinsic factors play different roles.

4.1 Extrinsic factors

It is not yet completely clear the relationship between footwear and hallux valgus. Although high-fashion footwear has been implicated in the progression of hallux valgus deformities in adults, some studies have suggested that in most cases a juvenile hallux valgus deformity does not appear to be influenced by a history of constricting footwear. But a study conducted on 858 pre-school children (Roddy et al., 2008), has shown that 61% of children wore indoor shoes 2 sizes too short and it was associated with an increase of 37% for the risk of a hallux angle of 4 degrees or more. Furthermore, the risk of a greater hallux angle for children wearing poorly-fitting indoor shoes was markedly higher than for children wearing poorly-fitting outdoor shoes, with a significant relationship between the lengthwise fit of the shoes and the hallux angle: shorter the shoe, higher the value of the hallux angle. Anyway, as the deformity does not develop in many people who wear fashionable or insufficient length footwear, some intrinsic predisposing factors must make some feet more vulnerable to the effect of footwear and likewise predispose some unshod feet to the development of hallux valgus. (Mann & Coughlin, 2010)

4.2 Intrinsic factors

4.2.1 Heredity

The notion that a hallux valgus deformity is inherited has been indeed suggested by many authors. (Mann & Coughlin, 2010) Juvenile hallux valgus deformities have been characterized by their familial tendency and in past different authors proposed that this trait was autosomal dominant with incomplete penetrance (Johnston, 1956) or with maternal transmission. (Coughlin, 1995) However, this trait can also be associated with x-linked dominant transmission or polygenic transmission (Mann & Coughlin, 2010).

4.2.2 Pes planus

The association of pes planus with the development of a hallux valgus deformity is controversial. A more than double increased incidence of pes planus has been demonstrated in a adult group with a hallux valgus than in a control group, without evidence of correlation between the hallux valgus angle and pes planus or between pes planus and first ray mobility. (Grebing & Coughlin, 2004) An association was observed, instead, between the hallux valgus angle and both Meary's line and the AP talonavicular coverage angle in those patients with pes planus (King & Toolan, 2004) (Fig. 4). Much more interesting, from a biomechanical point of view, is the observation that a hallux valgus deformity tends to develop in a pronated foot.

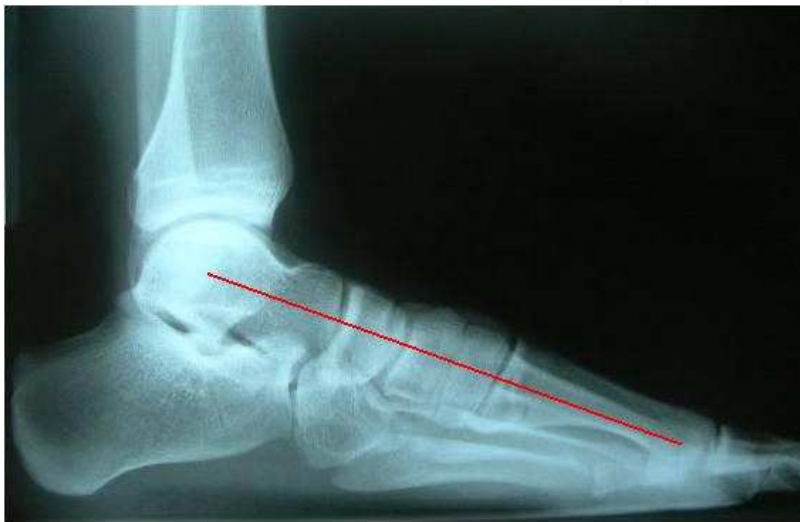

Fig. 4. Normal Meary's angle. The long axis of the talus intersects that of 1st metatarsal. In pes planus, the long axis of the talus is angled plantarward in relation to 1st metatarsal.

Already Jordan and Brodsky in 1951 wrote "We regard the majority of cases of hallux valgus as acquired deformities resulting from pronation of the foot. The role of footwear is secondary, serving to aggravate in mild deformity or produce manifest deformity where only potential hallux valgus previously existed as a result of foot pronation". (Jordan & Brodsky, 1951) Anyway, it is reasonable to think that a hallux valgus deformity will progress more rapid in a patient with pes planus because the foot appears to be less able to withstand the deforming pressures exerted on it by either shoes or weight bearing (Mann & Coughlin 2010).

4.2.3 Hypermobility of the metatarsocuneiform joint

An association between increased mobility of the first MTC joint and hallux valgus was suggested by Lapidus already in 50s. (Lapidus, 1934,1956,1960) Along the years, many authors tried to refine methods to accurately measure first ray mobility, finding a greater flexibility at the MTC joint in patients with hallux valgus. But Grebing and Coughlin showed how the position of the ankle substantially influences the perceived first ray mobility: if the ankle is placed in 30 degrees of plantar flexion, in fact, the rate of hallux valgus considered hypermobile is much higher compared to that with the ankle placed in 5 degrees of dorsiflexion (Grebing & Coughlin, 2004).

Having determined a relationship between hypermobility of the MTC joint and hallux valgus, it's important to understand if the hypermobility is an effect of the deformity or the cause. A follow-up prospective study in which an operative repair to correct hallux valgus deformity was performed on 122 feet, concluded that first ray mobility is an effect of the hallux valgus deformity rather than a cause in most cases. (Coughlin & Jones, 2005) First ray stability is probably a function of first ray alignment and the effectiveness of the intrinsic and extrinsic muscles and the plantar aponeurosis and not an intrinsic characteristic of the first MTC joint.

4.2.4 Ligamentous laxity

Although the findings of ligamentous laxity is probably uncommon in the typical adult patient with hallux valgus, it is instead quite frequently in young patients. In a report on juveniles, Clark et al, noted that 69% of patients in their series had generalized laxity on physical examination. (Clark et al, 1987) Attention should be addressed to ligamentous laxity in any evaluation before correction of hallux valgus. Especially in patients affected by genetic diseases involving mesenchymal tissues, like Marfan or Ehlers-Danlos's syndrome, generalized ligamentous laxity and Down syndrome, the specific laxity and the impairment of the capsuloligamentous structures play a key role about the onset of the disease and the tendency to relapse.

4.2.5 Neurological diseases

Neurological diseases such as spastic paralysis induce the appearance of a hallux valgus deformity by a serious and persistent subtalar pronation, to compensate for muscular equinism. The deformity develops, in these cases too, through a biomechanical impairment, but the different cause justifies their separate classification.

Anyway, in order to find the main cause of the deformity, a complete and accurate biomechanical examination of the lower limbs is important to identify the structural and/or functional defects responsible of the abnormal subtalar pronation of the foot. Causes could concern alterations of the foot, like forefoot varus, not rigid forefoot valgus, osseous ankle equinus, or structural defects over the foot, like tibial and genu varum, tibial and femoral torsional modifications and genu valgum. Also functional defects linked to muscular alterations could have a role in the occurrence of the deformity.

5. Epidemiology

Estimates of the community prevalence of hallux valgus vary widely, ranging from 2%–70% in epidemiologic studies. (Myerson, 2000; Benvenuti et al., 1995; Dunn et al., 2004; Elton & Sanderson, 1986; White & Mulley, 1989; Leveille et al., 1998) This variation is attributable, in part, to different study populations and definitions of hallux valgus used, in particular confusion of the terms hallux valgus and bunion.

In a study on a primary care population of 3868 people, Roddy et al. reported a prevalence of hallux valgus of 31%: bilateral hallux valgus was reported by 16.9% of subjects compared with subjects with unilateral hallux valgus (6.0% in the left foot only, 7.0% in the right foot only).(Roddy et al., 2008) In children, Klein et al. reported only 23.9% of children's feet with

a straight position of the great toe; in all the rest, the position of the great toe varied between a hallux angle of 1 degree up to 19 degrees valgus position (14.2% with a valgus deviation of equal to or greater than 10 degrees). (Klein et al., 2009)

A female preponderance of 2:1 was reported in a study of schoolchildren's feet (Wilkins, 1941); the ratio increases up to 3:1 in military recruits (Hewitt, 1953; Marwil & Brantingham, 1943), until to reach approximately the ratio of 15:1 in adult patients (Hardy & Clapham, 1951). Therefore, the prevalence in women increased as patient age increased, also probably due to the use of fashionable female shoes. The reported incidence of females in the juvenile population undergoing surgical correction for hallux valgus deformities varies from 84% to 100%. (Clark et al., 1987; Thompson, 1996)

About the age of onset, most of studies reported that a percentage of 40%-57% of bunion deformities occurred during adolescent year, anyway before the age of 20 (Piggott, 1960; Coughlin, 1995). But, as patients recognize a hallux valgus deformity just when they "feel" the deformity, the symptoms, and the magnitude of the deformity, it's right to think that the development of the hallux valgus probably occurs much earlier than has previously been appreciated.

Of importance is the fact that the late development after skeletal maturity occurs in a foot that at one point most likely had a normal structure, whereas an early onset in the juvenile years occurs before maturation in a foot that most likely "never had a normal structure". (Mann & Coughlin 2010)

6. Anatomic and radiographic consideration

Radiographic examination of the foot has no absolute value and, although crucial, it is not to be separated by a thorough clinical and biomechanics examination of the foot, which must be confirmation and completion at the same time. Only by correlating the results of various radiographic measurements to a correct clinical diagnosis, it's possible choosing the most appropriate surgical technique.

It's interesting to underline that a statistical study found that there was a highly significant difference between the radiographic and the intraoperative assessment of MTP joint congruity (Armanek et al., 1986).

Anyway, during a preoperative evaluation, the following radiographic parameters will always be evaluated (Bartolozzi et al., 2011):

- Hallux valgus angle
- 1-2 intermetatarsal angle
- Proximal Articular Set Angle (P.A.S.A.) or Distal Metatarsal Articular Angle (DMAA)
- Distal Articular Set Angle (D.A.S.A.)
- Joint Congruity
- Relative Metatarsal Protrusion
- First Metatarsocuneiform Joint
- Osteoarthritis
- Rotation of hallux about its long axis

6.1 Hallux valgus angle

On an AP weight-bearing radiograph, hallux valgus angle is created by the intersection of axes drawn on the first metatarsal and proximal phalanx, the first was obtained bisecting the shaft of the metatarsal at two levels, joining the points of bisection and extending the line in both directions; the second was obtained by a line applied by visual estimation, because the irregular outline of the phalanx did not allow of geometrical division at two levels (Fig. 5). While not entirely predictive, Hardy and Clapham's "artificial dividing line" of 15° about hallux valgus angle (Hardy & Clapham, 1951), appears to be supported by the epidemiological studies reviewed. Therefore, a normal angle is less than 15 degrees, mild deformity is less than 20 degrees, moderate deformity is 20 to 40 degrees, and severe deformity is greater than 40 degrees (Coughlin, 1996).

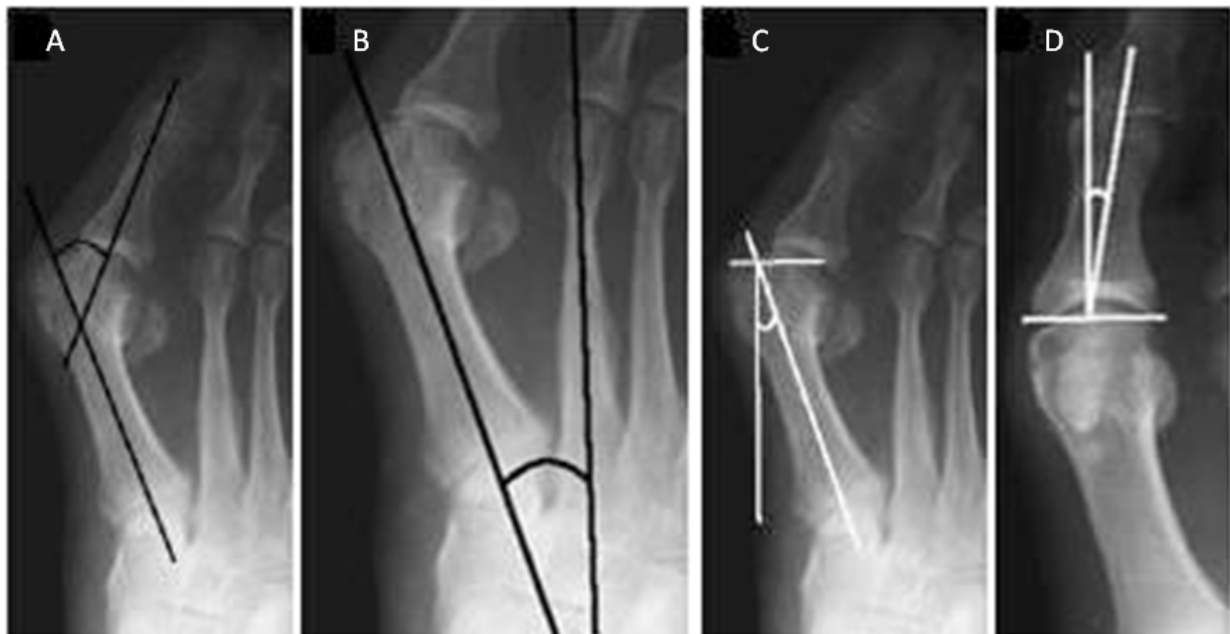


Fig. 5. A, Hallux Valgus Angle; B, Intermetatarsal Angle; C, Proximal Articular Set Angle (P.A.S.A.); D, Distal Articular Set Angle (D.A.S.A.).

6.2 1-2 intermetatarsal angle

On an AP weight-bearing radiograph, this angle is obtained by measuring the angle between the axis of the first and second metatarsals (fig. 5). Normal is less than 9 degrees (Hardy & Clapham, 1951), mild deformity is 11 degrees or less, moderate deformity is greater than 11 and less than 16 degrees, and severe deformity is greater than 16 degrees (Coughlin 1996).

6.3 Proximal Articular Set Angle (P.A.S.A.) or Distal Metatarsal Articular Angle (DMAA)

On an AP weight-bearing radiograph, it is formed by the intersection of the perpendicular line to the line passing through the two medial and lateral end points of the articular surface of the head of the first metatarsal and the longitudinal axis of the first metatarsal (Fig. 5). The measurement of this angle is extremely important when evaluating a patient with a hallux valgus deformity because it will in part determine what type of operative procedure

should be performed. Normal angle is regarded as 8 degrees or less of lateral sloping, even if Coughlin observed that in juvenile patients younger than 10 years with hallux valgus, the DMAA was 15 degrees, and in those older than 10 years, it averaged 9 degrees (Coughlin, 1995).

6.4 Distal Articular Set Angle (D.A.S.A.)

On an AP weight-bearing radiograph, defines the orientation of the proximal phalangeal articular surface in relation to the long axis of the proximal phalanx. Normal is less than 8 degrees, 5 degrees on average (Balding, 1985) (Fig. 5).

6.5 Joint congruity

Congruity is the term used to describe the relationship of the metatarsal and phalangeal articular surfaces. A congruent hallux valgus deformity occurs when the corresponding articular surfaces of the metatarsal and phalanx are concentrically aligned (Coughlin, 1995).

Piggott separated a normal from a hallux valgus foot on the basis of the congruence of the first metatarsophalangeal joint (Piggott, 1960).

In a physiological foot, the first metatarsophalangeal joint remained congruent with the articular surface of the first metatarsal head, and the proximal phalanx of the hallux lying adjacent to one another. Hallux valgus is a deviated joint where the proximal phalanx is moved laterally on the first metatarsal head, leaving the medial side of the metatarsal head exposed. Three groups are identified referred to congruous, deviated and subluxated patterns. In the first, the surfaces are completely congruous as in the normal foot, their central points lying opposite each other. In the second, the distal articular surface is deviated laterally on the proximal articular surface, leaving the medial end of the latter exposed. In the third, the base of the proximal phalanx is subluxated laterally off the metatarsal head.

According to this classification, Piggott considered Hardy and Clapham's dividing line somewhat artificial as he found a number of congruous joints with first metatarsophalangeal joint angles in excess of 15° (Piggott, 1960).

He suggested that mild subluxation of the first MTP joint can progress to significant subluxation and leave the medial metatarsal articular surface uncovered. According to the author, a congruous joint was typically stable and the hallux valgus did not appear to increase with time.

Anyway, a significant hallux valgus that needs surgical intervention, can occur in a patient with a symptomatic deformity and a congruent MTP joint; in some cases, an intraarticular MTP joint realignment could create an incongruent joint, predisposing the patient to a recurrent hallux valgus deformity or to the development of postoperative degenerative joint disease (Coughlin, 1990).

In juveniles, MTP joint congruity is believed to be a significant predisposing factor in the hallux valgus deformity (Coughlin, 1990; Funk & Wells, 1972; Coughlin, 1987; Goldner & Gaines, 1976; Piggott, 1960). Coughlin demonstrated that 47% of juveniles with hallux valgus were noted to have a congruent joint with a laterally sloping DMAA. For those with a subluxated first MTP joint, the average the DMAA was 8 degrees. For congruent joints, the

average lateral slope or DMAA was 15 degrees. The DMAA was noted to be significantly higher in patients with a positive family history, in those with early onset of hallux valgus (younger than 10 years), and in those with a long first metatarsal. The DMAA was not affected by the presence of metatarsus adductus. An increased DMAA is the defining characteristic of many juvenile hallux valgus deformities (Coughlin, 1995).

6.6 Relative metatarsal protrusion

The difference of length between first and second metatarsal linked to a possible association with hallux valgus is controversial. It is a somewhat vexed question because definition of terms is difficult and, even when defined, the relevance and interpretation of them are obscure.

The axes of the first and second metatarsal are drawn along their long axis; a transverse tarsal line is drawn so as to touch the posterior articular surface of the cuboid and the posterior aspect of the tuberosity of the navicular. At the point of intersection of this line with the axis of the second metatarsal one point of a pair of dividers is placed; arcs were then drawn with the other so as to touch the articular surfaces of the heads of the first and second metatarsal. The radial distance (in millimeters) between the arcs is taken as the measure of relative metatarsal protrusion. Conventionally, the distance between the arcs is preceded by a sign: a positive sign indicates that the first is greater than the second, and a negative sign that the second is greater than the first.

Morton's method using transverse lines is another technique to size the first metatarsal length but is influenced by varying angular deformities (Morton, 1935).

Also measurements in juveniles show short first metatarsals in 28%, first and second metatarsals of equal length in 42%, and long first metatarsals in 30% (Coughlin 1995). According to these data, a short first metatarsal is rarely associated to a hallux valgus deformity.

6.7 First metatarsocuneiform joint

The first MTC joint has a key role in the development both of an enlarged 1-2 intermetatarsal angle and an increased hallux valgus angle. The orientation and flexibility of the MTC joint play an important role in development of the deformity at the MTP joint. On an AP radiograph, the angle formed by the intersection of the longitudinal axes of the first and second metatarsals defines the 1-2 intermetatarsal angle. The normal value is 5-10 degrees (La Porta et al., 1974; Weissman, 1989). If it exceeds 25 degrees, an osteotomy of the first metatarsal base or an arthrodesis of the first MTC joint may be proposed (Lapidus, 1960).

Normally the first MTC joint is deviated medially, but in some cases it may have a marked degree of medial inclination, which is believed to result in joint instability. After anatomic dissection (Haines & Mc Dougall, 1954; Brage et al., 1994) of the MTC joint, it was demonstrated being an association between hallux valgus deformity and an oblique orientation of the first MTC joint. Therefore it's possible to hypothesize (Haines & Mc Dougall, 1954) that an abnormality in the first metatarsal base leads to a metatarsus primus varus deformity and that the first MTC joint is the major actor associated with an increased magnitude of the 1-2 intermetatarsal angle.

DuVries stated that in juveniles, the increased 1-2 intermetatarsal angle was responsible for the development of hallux valgus, whereas in adults, the increased 1-2 intermetatarsal angle was a secondary change following first MTP joint subluxation (DuVries, 1959). It confirms that in juveniles an increased 1-2 intermetatarsal angle is a primary deformity and the hallux valgus deformity is a secondary or acquired deformity.

6.8 Osteoarthritis

Degenerative arthritis of the first MTP joint is rarely associated with a juvenile hallux valgus deformity but is more often associated with an adult bunion.

The altered mechanics of the first MTP joint over time can cause development of arthrosis phenomena.

The first metatarsophalangeal joint is a target joint for osteoarthritis and it was included in Kellgren and Moore's seminal description of generalized osteoarthritis (Kellgren & Moore, 1952). More recently, radiographic evidence of osteoarthritis at the first metatarsophalangeal joint has been shown to be associated with radiographic evidence of osteoarthritis at the knee and hand (Wilder, 2005).

It is therefore interesting that hallux valgus, like an osteoarthritis consequence, was more frequently found to be a bilateral phenomenon with little difference between the right or left foot. Other components of generalized osteoarthritis (e.g., radiographic knee and interphalangeal joint osteoarthritis) have been found to be asymmetrical with a predominance of disease on the right side (Acheson, 1970; Neame et al., 2004).

This finding has been interpreted in the hands as evidence of the role of biomechanic factors in the development of osteoarthritis. Hence, 2 possible explanations for the symmetry of hallux valgus exist. First, the development of osteoarthritis may relate to constitutional or genetic factors or alternatively, biomechanic factors may apply equally to both feet, in contrast with the hand where use of the dominant side is favored (Roddy et al., 2008).

7. Symptoms

The main symptom is the pain, which occurs initially to the prominence of the metatarsal head because of the conflict with the upper part of the shoe, and it later may be complicated by the appearance of a serious inflammation of the bursa (bursitis). The deviation of the great toe causes a functional failure of the first ray, which causes a shift of weight on the central metatarsal heads with subsequent onset of pain and calluses at this level (metatarsalgia).

The functional overload of central rays leads to a muscular imbalance of the small fingers resulting in the appearance of the *griffe* deformity, sometimes associated to a dorsal subluxation or dislocation of the corresponding MTP joints. Deformities of the small fingers too can lead to pain and callus at the proximal interphalangeal joints, due to the mechanical conflict with the upper part of the shoe. Because of the inadequacy of the first ray, the transfer of the weight may also determine the appearance of Civinini-Morton's neuroma, most often on the third intermetatarsal space.

Besides biomechanical alterations and pain, caused by friction between foot and shoe in a deformed foot, it's important to take account of the tendency to progressive worsening of the deformity with functional and aesthetic impairment.

8. Classification

The main purpose of a classification of hallux valgus deformities is to facilitate the decision-making process on how to treat the deformity. Classification should be used only as a general guide.

In general, hallux valgus deformity is divided into three degrees of severity (Coughlin, 1996):

- **Mild**, if the hallux valgus angle is less than 20 degrees.
- **Moderate**, the hallux valgus angular deformity is 20 to 40 degrees.
- **Severe**, with a hallux valgus deformity greater than 40 degrees of lateral deviation of the hallux

9. Treatment

There are two main modes of treatment: conservative and surgical.

9.1 Conservative treatment

Conservative care is adequate only to relieve symptoms. A custom or prefabricated orthotic device may assist in the treatment of a flexible flatfoot deformity or in a patient with ligamentous laxity and hallux valgus associated with pes planus. A soft leather shoe with a wide toe box and preferably a soft sole may give significant relief of symptoms. The use of bunion pads, night splints, bunion posts, and other commercial appliances may also help in relieving symptoms.

The use of prefabricated or custom orthotics is controversial in the treatment of a patient with hallux valgus. It has not been demonstrated that orthotic devices prevent progression of the deformity. An orthotic device may be uncomfortable for a patient because it occupies space within the shoe. It may place increased pressure against the medial eminence and result in increased symptoms rather than relief of pressure on the first metatarsal head. According to this theory, Kilmartin et al(1991) found that the hallux valgus angle increased more in patients who used orthotics and concluded that orthoses did not prevent progression of a hallux valgus deformity.

Nonsurgical care should also be considered in patients with hyperelasticity, ligamentous laxity, or neuromuscular disorders because of the high recurrence rate.

9.2 Surgical treatment

About surgical treatment, several correction techniques performed on soft tissue and / or bone have been described and the most appropriate method should consider the already described clinical and radiographic factors.

Basically, the corrective actions can be divided as follows:

1. Soft tissues;
2. Arthroplasties
3. First metatarsal osteotomies:
 - a. Distal osteotomies
 - b. Proximal osteotomies
 - c. Metadiaphyseal osteotomies
4. First phalangeal osteotomies
5. Arthrodesises

These techniques, which can be variously combined, aim to correct all the deformities even through the use of fixation devices that may be metallic or absorbable, they may be internal (screws, staples) or external (K-wire) . The internal fixation devices are usually intended to remain, while those outside are removed several weeks after surgery.

In addition to traditional open surgery, which requires large incisions to perform osteotomies and soft-tissue releases, recently the minimally invasive surgery has emerged.

Minimally invasive surgery (MIS) is defined as surgery performed through the smallest incision necessary to perform correctly the surgical technique and with minimal involvement of bony structures, joints, tendons and skin.

For the treatment of hallux valgus deformity with MIS technique, in literature are described Bosch (et al., 1990) technique, the PDO (Percutaneous Distal Osteotomy) (Magnan et al.,1997) and SERI (Simple, Effective, Rapid, Inexpensive) (Giannini et al., 2003); the first two with punctiform percutaneous surgical access, the third with a minimally invasive approach through an incision of 7-10 mm. These three techniques perform essentially a similar distal osteotomy of the first metatarsal with lateral displacement of the epiphyseal fragment of the metatarsal head and stabilization of the correction with a single K-wire located extraperiosteally on the big toe and on the distal epiphyseal fragment, intramedullary the first metatarsal.

As the osteotomy site is fixed temporarily by a K-wire, the relative mobility of fragments allows the consolidation of the osteotomy in the best position under the guidance of the weight bearing. The osteotomy site consolidates in several months as a stress fracture, initially with exuberant callus and with subsequent remodeling of the metatarsal.

These techniques meet the biomechanical principles of traditional distal osteotomies performed with open technique, without requiring any time to release the soft tissues on the lateral side of joint.

Historically distal metatarsal osteotomies have been indicated in cases of mild to moderate deformity with an intermetatarsal angle equal to 15-20°. Distal osteotomies may also be used to correct deformities characterized by deviation of the distal metatarsal articular angle (DMAA) or to address concomitant stiffness.

Many authors over a year described techniques for distal osteotomies, some of them performed percutaneously, and each of them characterized by different approaches, osteotomy and fixation designs. Furthermore, several studies over the years reported more than 80% good results with the use of these techniques.

The MIS technique is indicated to correct mild to moderate reducible deformity when the Hallux Valgus Angle is up to 40° and the Intermetatarsal Angle is up to 20° (Giannini et al., 2003).

The operation is indicated if the MTP joint is either incongruent or congruent or with modification of DMAA, and if mild degenerative arthritis is present. Advantages of these techniques are short operating time required, decreased postoperative discomfort, immediate weight bearing, improvement in postoperative MTP joint motion, fewer local complications and minimal soft-tissue damage.

Regardless of the technique, the indications for surgical treatment are represented by:

1. Pain from conflicts with the use of shoes that does not allow the use of normal shoes;
2. Metatarsalgia;
3. Preventing the aggravation of the deformities in young patients, also asymptomatic, to prevent the development of arthritic degeneration of the first MTP joint;
4. Correction of deformities for cosmetic purposes in selected cases (after appropriate counseling);

The most reliable algorithm of choice of treatment is that proposed by the **American Orthopaedic Foot & Ankle Society (AOFAS)** and by the **European Foot & Ankle Society (EFAS)**, modified by the Italian Society of Foot Surgery (SICP) (Fig.6).

10. Our experience and preferred technique by the authors

10.1 Materials and methods

Since 2000 up to now, we treated through S.E.R.I. technique 55 patients (3 males, 52 females; mean age 14,5 years in a range of 13-16 years) with a juvenile hallux valgus deformity always associated with valgus flat foot treated with calcaneo-stop technique.

The surgery for the correction of the hallux valgus deformity was proposed at least two years later calcaneo stop procedure and anyway after the removal of the screw.

All patients were asymptomatic at the moment of the surgery, and the indications for surgical procedure were preventing the aggravation of the deformity and the development of arthritic degeneration of the first MTP joint.

During the preoperative evaluation has been checked all the radiographic parameters above indicated, and in particular the Hallux valgus angle, the 1-2 intermetatarsal angle, the Proximal Articular Set Angle (P.A.S.A.) and the Distal Articular Set Angle (D.A.S.A.).

Target of the surgery was the correction of clinical and radiological parameters which include the right realignment of the great toe, the relocation of sesamoids, the recovery of the inadequacy of 1st radius and the improvement of the valgus angle, the intermetatarsal angle, the proximal articular set angle, and the distal articular set angle.

10.2 Surgical technique

In young patients it is preferable to perform the surgery under general anesthesia, in adults also under local anaesthetic or local anaesthetic with oral sedation.

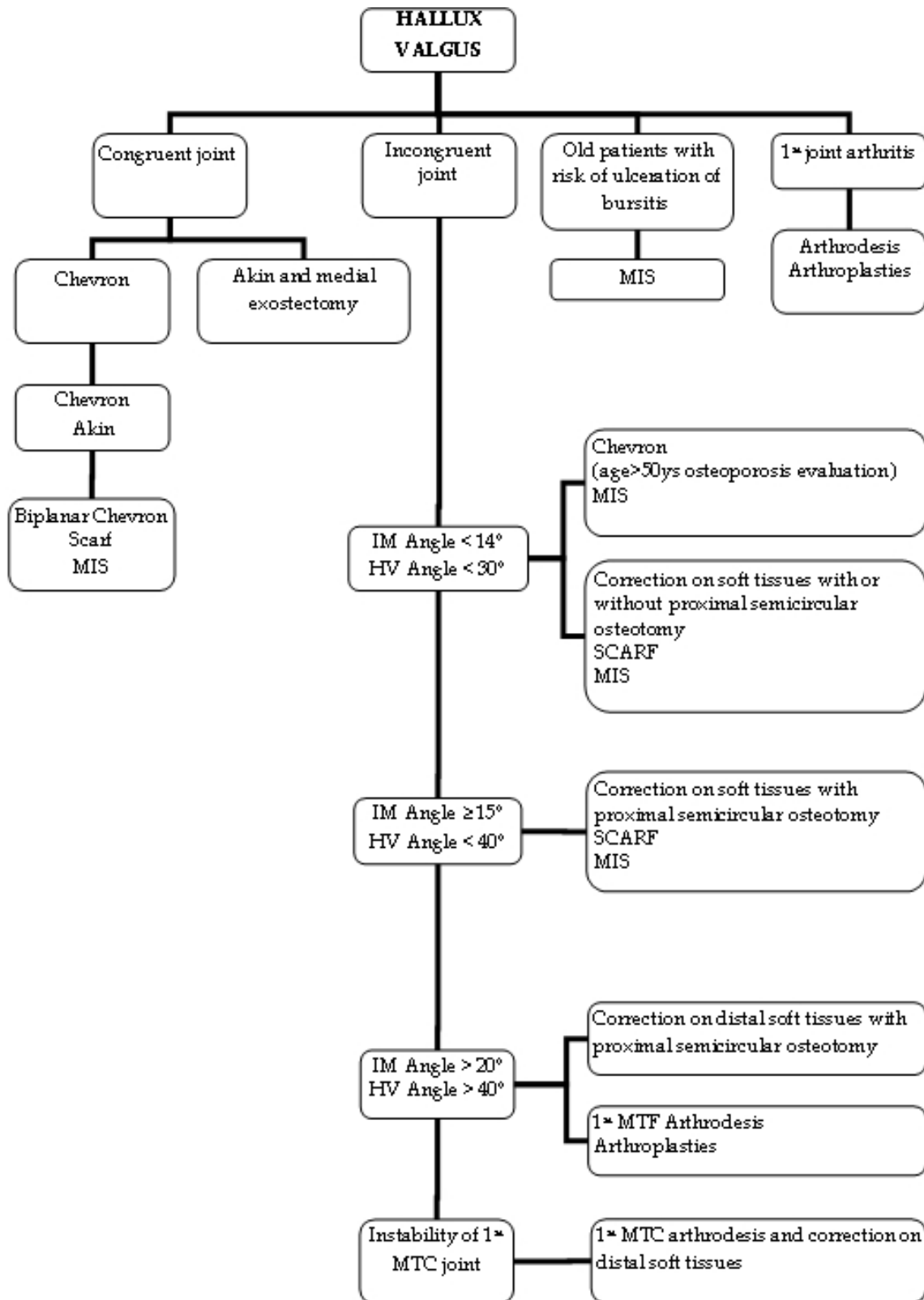


Fig. 6. Algorithm for the hallux valgus deformity treatment proposed by the American Orthopaedic Foot & Ankle Society (AOFAS) and by the European Foot & Ankle Society (EFAS), and modified by the Italian Society of Foot Surgery (SICP). MIS could be used for several types of deformities.

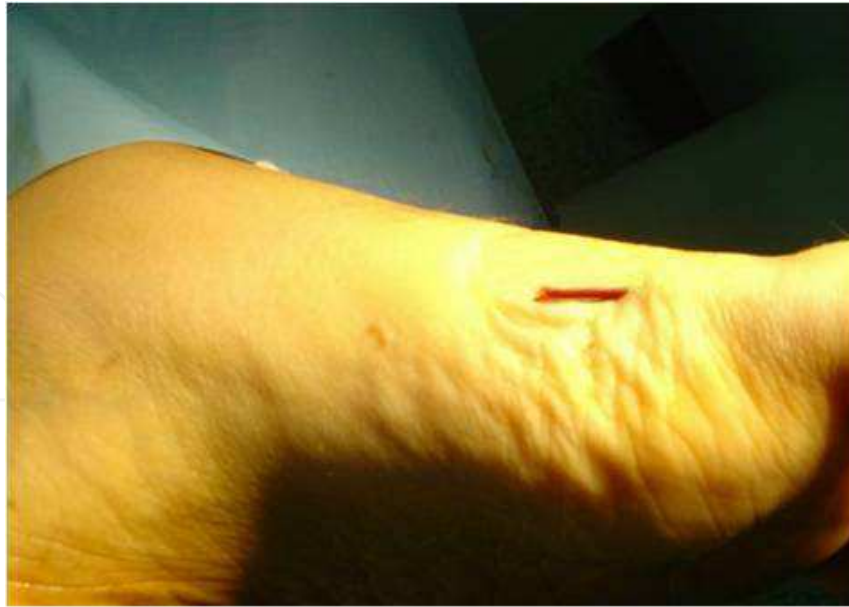

Fig. 7. Surgical incision

A 2 cm incision is made at the subcapital region of the first metatarsal, equidistant between the dorsal and plantar aspects of the bone (Fig. 7). The periosteum is detached dorsally and plantarly with a small elevator, preserving its continuity to protect the soft tissues during the osteotomy.

The transverse osteotomy is made in the first metatarsal subcapital region under fluoroscopic control, using an end cutting burr. The osteotomy is performed perpendicular to the metatarsal shaft in the sagittal plane. In the frontal plane, the mediolateral obliquity of the osteotomy can be varied to shorten or lengthen the first metatarsal according to the preoperative plan. Furthermore, the metatarsal head can be rotated in the axial plane to correct rotational components of the deformity. Once the osteotomy is finished, mobility at the osteotomy site is checked under fluoroscopy.

Through the incision, a 2 mm K-wire is introduced according to a proximal-distal direction until the medial side of the great toe, approximately 5 mm plantar to the proximal edge of the nail; the K-wire must be placed subcutaneously and extraperiosteally to perform the metatarsal head displacement at the osteotomy site. Once the wire has popped up near the nail of the great toe, it was taken from the drill and retracted until it reaches the proximal end of the line of osteotomy.

Next, a bent grooved guide is placed through the proximal incision into the proximal metatarsal bone fragment. The K-wire tip is placed in the concavity of the guide. Using the guide and K-wire as a lever, the metatarsal head lateral displacement and rotation is achieved and maintained during the wire progression into the medullary canal. While holding the hallux in a varus position, the wire is driven with smooth blows of the mallet to the base of the metatarsal. Fluoroscopy is used to confirm the lateral displacement of the head, and overlap of the proximal and distal fragments (Fig. 9). The probe is taken out and the wire is cut, leaving 1 cm outside the skin .

The incision is sutured and a short leg cast is packed. The weight-bearing is allowed with “walking” cast after 10 days.

Through this technique, the release of soft tissue is not required because their detensioning is obtained with the lateral displacement of the metatarsal head. However, it is advisable to perform a manual stretching of the adductor hallucis, forcing the great toe in varus.

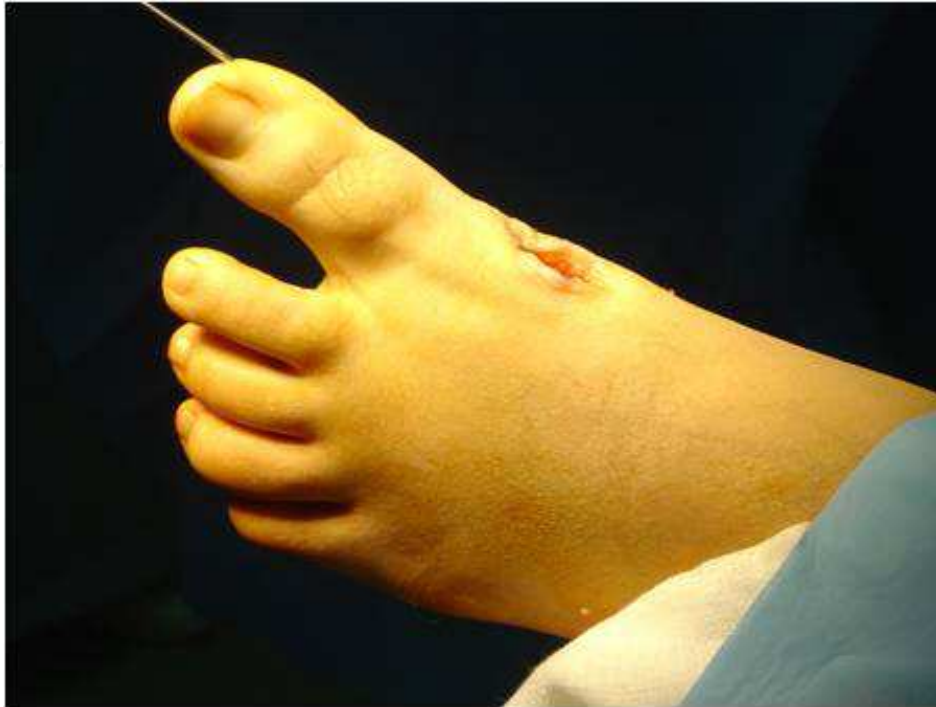

Fig. 8. Through the incision, the K-wire is introduced until the medial side of the great toe.

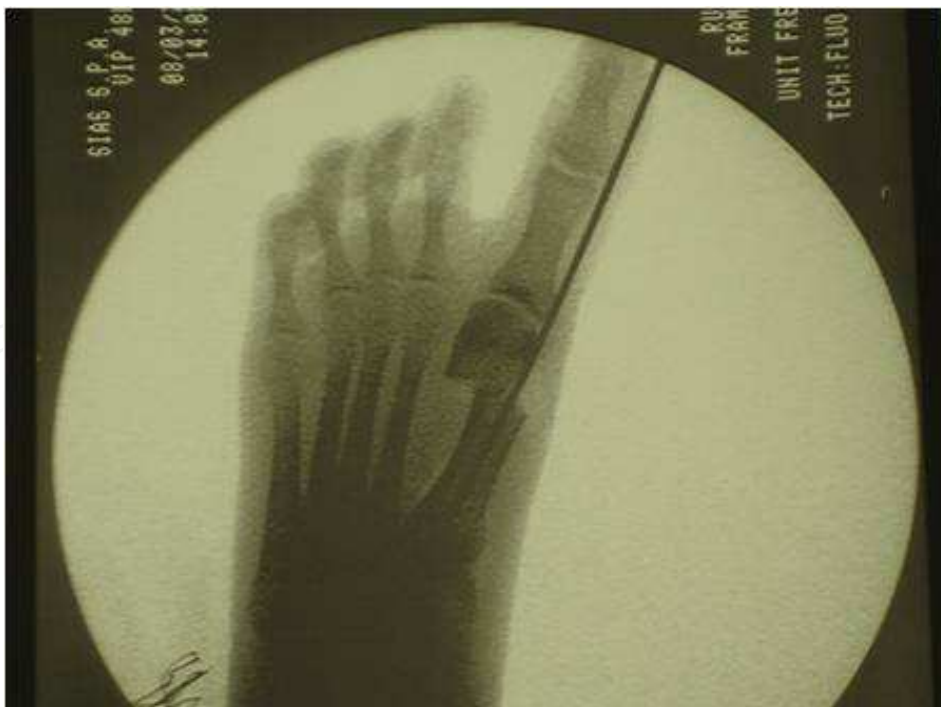

Fig. 9. Using a bent grooved guide the guide into the proximal metatarsal bone fragment and K-wire as a lever, the metatarsal head lateral displacement and rotation is achieved and maintained during the wire progression into the medullary canal.

The choice of the quadrant, according to the transverse direction (inferior-medial or superior-medial), of the first ray for the insertion and progress of the K-wire along the phalanx and the distal epiphysis of metatarsal is very important. The choice affects the subsequent positioning of the osteotomized epiphysis compared to the diaphysis. The wire is inserted into the superior-medial quadrant determining thus a plantar displacement of the head of the metatarsal (Fig. 10). An insertion of the wire into the inferior-medial quadrant should be avoided because it determines dorsal displacement of the great toe.

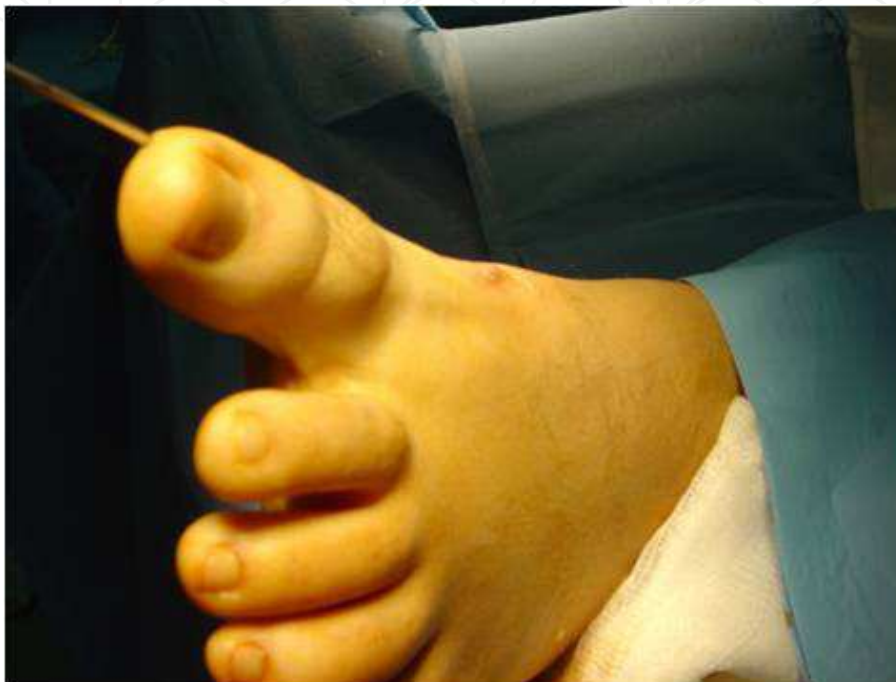

Fig. 10. The wire is inserted into the superior-medial quadrant determining a plantar displacement of the head of the metatarsal.

10.3 Post-operative care

The wire and the cast are kept for 30 days. After their removal, the patient can wear a "talus" shoe that distributes the weight-bearing on the hindfoot. Clinical and radiographic controls were performed at 1, 3, 6 and 12 months.

11. Results

There were no intraoperative complications. At a mean follow-up of 3 years (min. 1, max 5), radiographic parameters were evaluated and all showed values within normal range.

The radiographic follow-up showed a complete consolidation of the osteotomy and a great metatarsal bone remodeling. Clinical results showed an excellent aesthetic and multiplanar correction of the deformity. The translocation of the metatarsal head causes a normalization of the intermetatarsal angle and a realignment of sesamoids, extensor and flexor apparatus of the great toe. Only in 3 patients a varus osteotomy of the base of the proximal phalanx of the finger (Akin) was necessary due to a severe alteration of the phalangeal axis. All patients were satisfied according to the obtained aesthetic and functional results.

There were no cases of avascular necrosis of the metatarsal head or nonunion of the osteotomy. In the indicated follow up period, we have not observed loss of correction and no foot has developed hallux varus (Fig. 11-12).

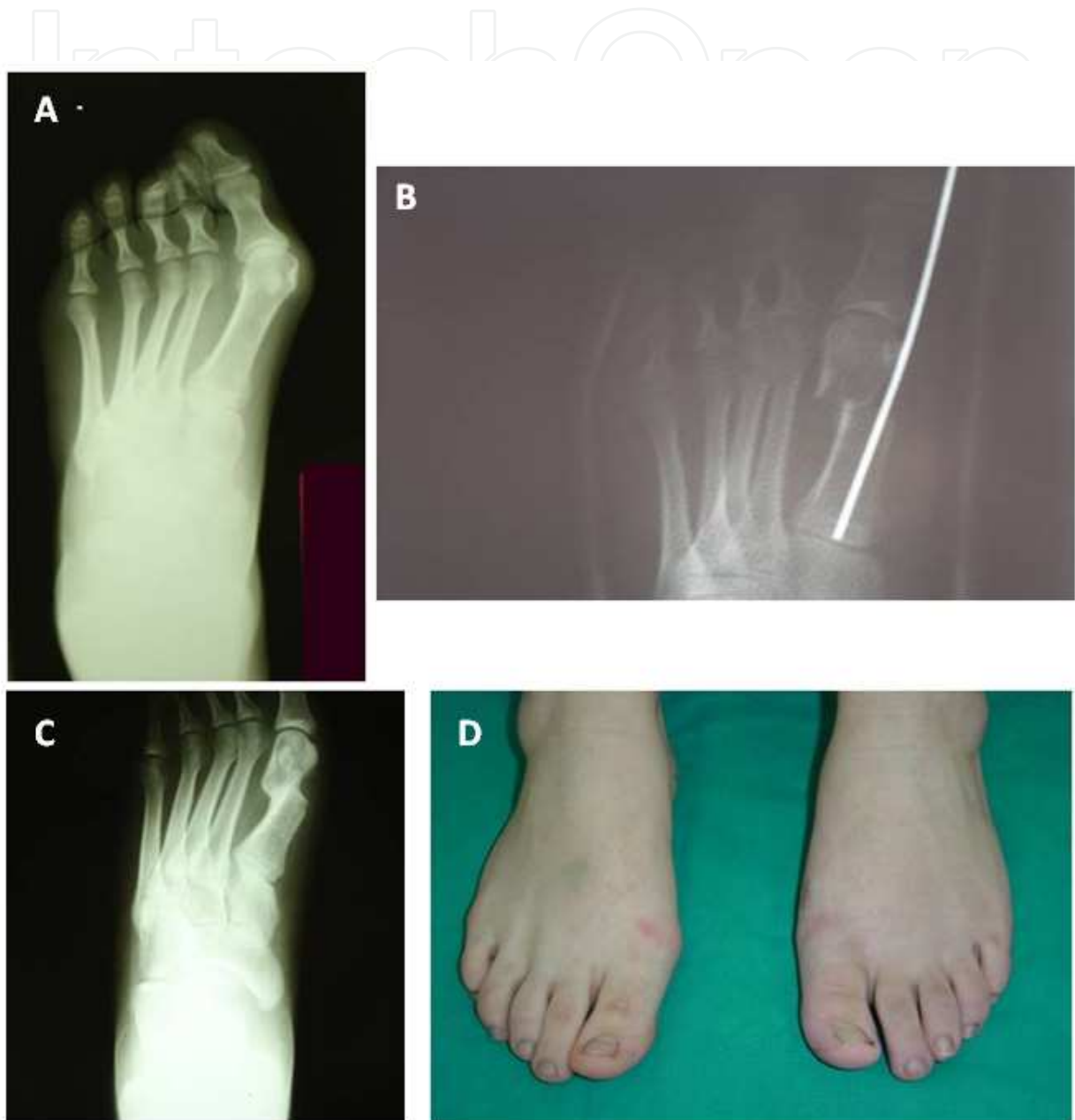

Fig. 11. 13 years old female with hallux valgus deformity of the left foot. The patient had been treated for flatfoot 2 years before. A, preoperative X-ray; B, Postoperative X-ray; C -D, X-ray and Clinical Control after 1 year.

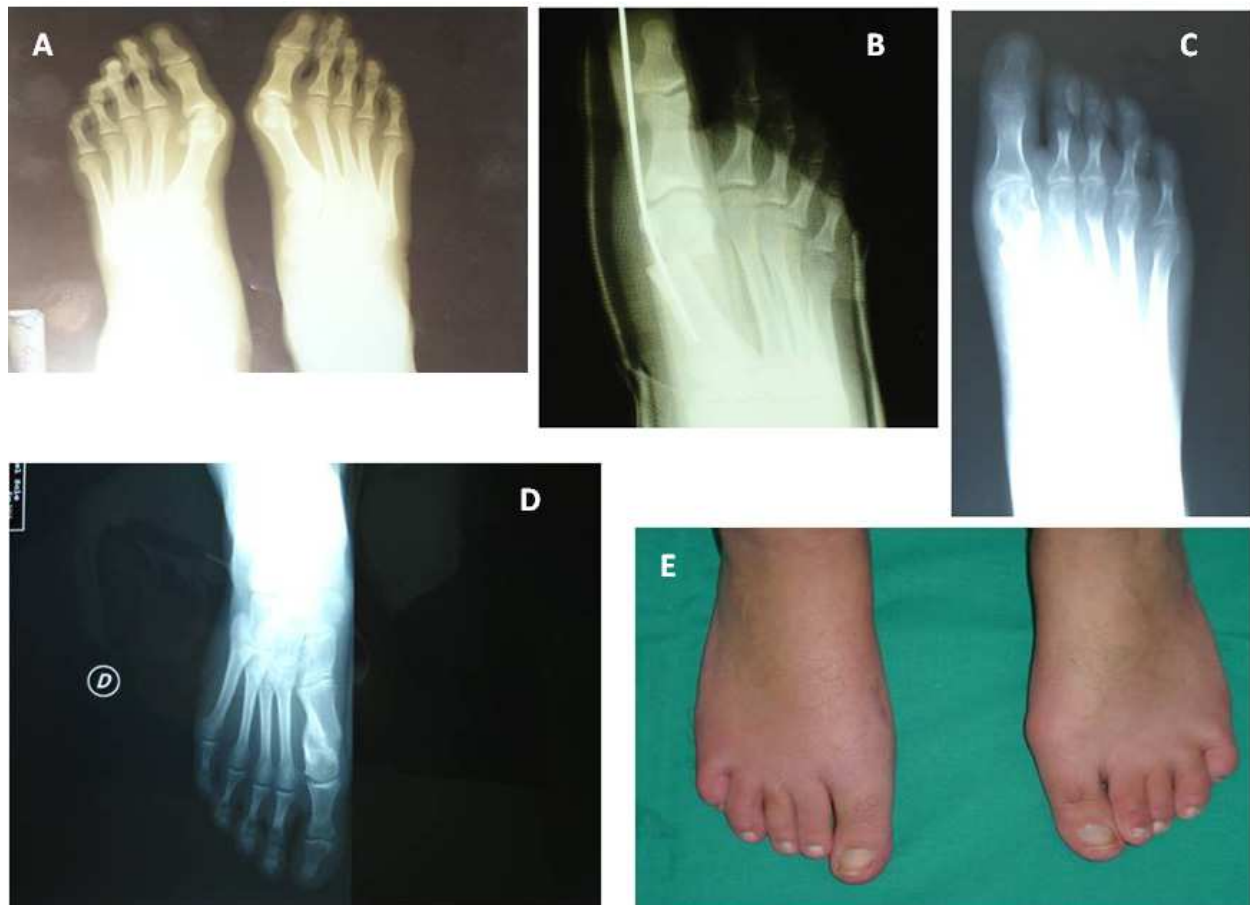

Fig. 12. 14 years old female with bilateral hallux valgus deformity. The patient had been already treated for flatfoot. A, preoperative X-ray; B, Postoperative X-ray; C, X-ray control 4 weeks later; D-E, X-ray and Clinical Control after 1 year.

12. Discussion

Minimally invasive surgical technique (MIS) for the treatment of the hallux valgus deformity has been described for the first time by Bosch in 1990 with his "distal linear osteotomy with temporary fixation with a single Kirschner wire". Bartolozzi and Magnan in 1997 described, then, the P.D.O. (Percutaneous Distal Osteotomy) and Giannini in 2003 the "S.E.R.I." (Simple, Effective, Rapid, Inexpensive).

These three techniques involve a distal first metatarsal osteotomy with a minimally invasive access and stabilization with K-wire. They differ only in surgical times and in the K-wire direction. Bosh technique involves incision, osteotomy and stabilization with a K-wire applied according to a distal-proximal direction; in the PDO, the application of the wire according to a distal-proximal direction comes before the incision and the osteotomy; SERI proposed by Giannini, consists of incision, osteotomy and K-wire according to proximal-distal direction through the skin incision already made.

Authors that have proposed surgical techniques for distal osteotomy with internal fixation, indicated like limit of a medium lateral shift of the metatarsal epiphysis 30-50% of the transverse diameter of the metatarsus, to allow an optimum stability of the synthesis.

Whereas potentially the correction of a distal osteotomy is about 1° per each mm of lateral displacement (Johnson 1994), traditional protocols provide like indication as an upper limit of a distal metatarsal osteotomy, a varus deformity of the first metatarsal not greater than 15-18 degrees of the intermetatarsal angle.

The minimally invasive technique with K-wire fixation, allows a lateral shift up to 90% of the transverse diameter of the metatarsal ("cortex on cortex") with a correction of the deformity which can be up, potentially, to 10-12 degrees, also including some cases in which traditional protocols would have opted for different techniques, as a proximal metatarsal osteotomy (Magnan et al., 1998).

All osteotomies reached radiographic consolidation within 6 months with abundant periosteal callus. This needed time could be considered entirely physiological for the healing of a metatarsal osteotomy, especially with a elastic type stabilization, with an evolution like to a "stress" fracture (Magnan et al., 1998). Although 1% of nonunion in osteotomies treated with a K-wire is reported in literature (Bosch, 1990), we did not observe nonunions in our experience.

Even if in literature the association of pes planus with the development of a juvenile hallux valgus deformity is controversial, in our experience and in the series we described there is a 100% association between hallux valgus and pes planus valgus, so with a pronated foot. Therefore, we can conclude that especially in the etiology and pathophysiology of hallux valgus, a defect in pronation of the foot plays a key role in the development of a metatarsus varus and therefore of a bunion, as described by Jordan and Brodsky in 1951. In addition, many of these young patients are overweight and this could affect the structural and biomechanical changes of the foot.

So if the pronation of the foot is a predisposing condition for the hallux valgus deformity, it is essential first of all to correct the valgus flat foot, especially to avoid recurrences that a wrong weight transfer on the forefoot could cause.

95% of young patients with hallux valgus deformity in the described series were females. This suggests a natural predisposition of women to this type of deformity, not influenced by the use of deforming fashionable women's shoes.

As younger patients poorly tolerate pain during the first postoperative days and, considering the age, they are not careful to protect the forefoot, we prefer not to allow the weight-bearing for about 7 days after surgery and immediately apply a short leg cast that allows walking, but protecting the osteotomy and synthesis site.

13. Conclusions

Since 2000, we treated 55 young patients with juvenile hallux valgus deformity always associated with valgus flat foot, performing a transverse osteotomy below the head of 1st metatarsal with minimally invasive surgical technique (S.E.R.I.). In our experience, it is a condition more common in young girls and it's often associated to valgus flat foot.

Surgery was indicated to restore the correct aesthetic and functional anatomy of the foot. It's important correcting it before deformity is structured, using the repair capability of the bone during adolescence, to prevent morphological more serious alterations in future and difficulty in walking.

As also indicated by the algorithm suggested by AOFAS, minimally invasive technique for the correction of the hallux valgus deformity allows to correct about 80% - 90% of all deformities without the need to remove the medial prominence or to run lateral release, but doing just the manipulation of the great toe with good or excellent results.

With this technique, we can obtain a plantar displacement of the first metatarsal head and a redistribution of weight on the other metatarsal heads, thereby reducing metatarsalgia.

The complete avoidance of surgical procedures on soft tissue, eliminates risks linked to this type of surgery, responsible sometimes of overcorrection.

Anyway, it's necessary for a correct timing surgery, an accurate clinical and radiological evaluation of the foot on weight-bearing with the analysis of the radiological angles linked to the hallux valgus deformity.

In all treated cases, correction of the hallux valgus deformity was performed about 2 years later the calcaneo stop surgical treatment for the flatfoot.

This technique can be applied safely in children. But, first of all, it is very important to correct the biomechanical imbalance in pronation of the foot predisposing the formation of the hallux valgus deformity.

For this reason it is advisable to carry out the surgery only when the pronation of the foot is corrected to obtain a right transmission of the weight on the metatarsals and to avoid recurrences in the growth phase.

Moreover, especially in children, the osteotomy area must be prevented from trauma and post-operative pain may be poorly tolerated by juveniles much more than adults. This is why we recommend to deny the weight-bearing for the first week and apply a short leg cast for 4 weeks.

In all cases, the treated metatarsals showed a remodeling even in case of significant displacement of the osteotomy with only few millimeters of bone contact. The consolidation of the osteotomy and the metatarsal bone remodeling capacity are not related to the displacement of the osteotomy, although an even minimal contact between the two bone fragments is necessary.

X-rays performed postoperatively, appear to be sufficient for proper clinical evaluation only after 3 months. In fact, this is the minimum period in order to obtain significant information regarding the healing of a metatarsal osteotomy. X-rays performed before that period, reassure the surgeon about the relationship of bone segments, but give no information about the clinical course.

Compared with conventional osteotomy (Scarf) (Mafulli et al., 2009), the minimally invasive technique has demonstrated comparable efficacy and a reduction in surgical time and hospital stay. Moreover it is inexpensive because it does not require any special tools, but only a K-wire for the stabilization, and has a minimal incidence of complications.

14. Acknowledgment

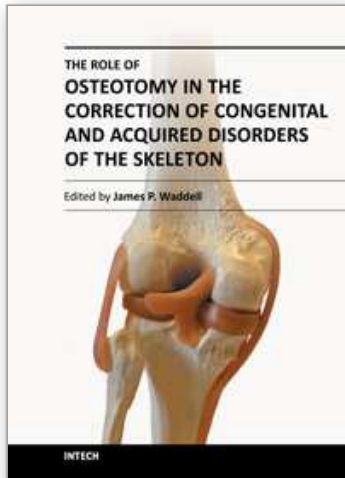
We gratefully acknowledge the assistance of Dr. Letizia Averna, University of Palermo.

15. References

- Acheson RM, Chan YK, Clemett AR. (1970). New Haven Survey of joint diseases. Distribution and symptoms of osteoarthritis in the hand with reference to handedness. *Ann Rheum Dis*; Vol,12. No,29. Pp.275-285.
- Amarnek DL, Jacobs AM, Oloff LM. (1985). Adolescent hallux valgus: an etiology and surgical management. *J Foot Surg* No,24. Pp.54-61.
- Amarnek DL, Mollica A, Jacobs A, Oloff LA. (1986). A statistical analysis on the reliability of the proximal articular set angle; *J. Foot Surgery*. No,25. Pp.39-43.
- Balding MG, Sorto LA jr. (1985). Distal Articular Set Angle. Etiology and X-Ray Evaluation; *J.A.P.M.A.* No,75. Pp.648-652.
- Bamel F, Canovas F, poiree G, Dusserre F, Vergnes C. (1999). Radiological results of scarf osteotomy for allux valgus related to distal metatarsal articular angle. *Rev Chir Orthop Reparatrice App Mot.* No,85. Pp.381-386.
- Bartolozzi P. et al. (2011). Chirurgia mininvasiva dell'alluce valgo; *GIOT*. No,37. Pp.92-112.
- Bartolozzi P., Magnan B. (2000). *L'osteotomia distale percutanea nella chirurgia dell'alluce valgo.* (Timeo). Bologna.
- Benvenuti F, Ferrucci L, Guralnik JM, Gangemi S, Baroni A. (1995). Foot pain and disability in older persons: an epidemiologic survey. *J Am Geriatr Soc.* No,43. Pp.479-84.
- Bosch P., Markowski H., Rannicher V. (1990). Technik und erste ergebnisse der subkutanen distalen metatarsale - I - osteotomie. *Orthopaedische Praxis*. No,26. Pp.51-6.
- Bosch P., Wanke S., Legenstein R. (2000). Hallux valgus correction by the method of Bosch: a new technique with a seven-to-ten-year follow-up. *Foot and Ankle Clinics*. Vol.5, No.3, pp.485-98.
- Brage ME, Holmes JR, Sangeorzan BJ. (1994). The influence of x-ray orientation of the first metatarsocuneiform joint angle. *Foot Ankle Int.* No.15, pp.495-497.
- Clark HR., Veith RG. & Hansen STJr.(1987). Adolescent bunions treated by the modified Lapidus procedure. *Bull HospJt Dis Orthop Inst.* No.47, pp.109-122.
- Coughlin MJ, Jones CP: Hallux valgus. (2005). Demographics, radiographic assessment and clinical outcomes. A prospective study, *Proceedings of 21st annual summer meeting of the American Orthopedic Foot and Ankle Society*, July 17, 2005.
- Coughlin MJ. & Mann RA. (1987). The pathophysiology of the juvenile bunion. *Instr Course Lect.* No.36, pp.123-136.
- Coughlin MJ. (1990). President's Forum:evaluation and treatment of juvenile hallux valgus. *Contemp Ortoph.* No.21, pp.169-203.
- Coughlin MJ. (1996). Hallux valgus. *J Boone Joint Surg Am.* No.78, pp.932-966.
- Coughlin MJ: Roger A. Mann Award. (1995). Juvenile hallux valgus: Etiology and treatment. *Foot Ankle Int.* No.16, pp.682-697.
- Dunn JE, Link CL, Felson DT, Crincoli MG, Keysor JJ, Mc-Kinlay JB. (2004). Prevalence of foot and ankle conditions in a multiethnic community sample of older adults. *Am J Epidemiol.* No.159, pp.491-498.
- DuVries H (Ed.). (1959). *Surgery of the foot.* CVmosby St. Louis. pp. 346-442.
- Elton PJ, Sanderson SP. (1986). A chiropodial survey of elderly persons over 65 years in the community. *Public Health* No.100, pp.219-222.
- Funk FJ Jr, Wells RE. (1972).Bunionectomy-with distal osteotomy. *Clin Orthop* No.85, pp.71-74.
- Giannini S, Ceccarelli F, Bevoni R, et al. (2003). Hallux valgus surgery: the minimally invasive bunion correction. *Tech Foot Ankle Surg.* No.2, pp.11-20.

- Giannini S, Vannini F, Faldini C, Bevoni R, Nanni M, Leoneni D. (2007). The minimally invasive hallux valgus correction (S.E.R.I.). *Interact Surg.* No.2, pp.17-23.
- Glasoe WM, Alen MK, Saltzman CL. (2001). First ray dorsal mobility in relation to hallux valgus deformity and first intermetatarsal angle. *Foot Ankle Int.* No.22, pp.98-101.
- Goldner JL. & Gaines RW. (1976). Adult and juvenile hallux valgus: analysis and treatment. *Orthop Clin North Am.* No.7, pp.863-887.
- Grebing BR, Coughlin MJ. (2004). The effect of ankle position on the exam for first ray mobility. *Foot Ankle Int.* No.25, pp.467-475.
- Grebing BR. & Coughlin MJ. (2004). Evaluation of Morton's Theory of second metatarsal hypertrophy. *J Bone Joint Surg Am.* No.86, pp.1375-1386.
- Haines RW. & Mc Dougall AM. (1954). The anatomy of hallux valgus. *J Bone Joint Surg Br.* No.36, pp.272-293.
- Hardy RH, Clapham JCR. (1951). Observations on hallux valgus; based on a controlled series J. *Bone Joint Surgery.* No.33B, pp.376-391.
- Hardy RH. & Clapham JC. (1952). Hallux valgus; predisposing anatomical causes. *Lancet.* No.1, pp. 1180-1183.
- Hohmann G. (1925). Der Hallux valgus und die uebrigen Zehenverkrueemmungen. *Egerb Chir Orthop* No.18, pp.308-348.
- Hueter C. in Kelikian H. (1965). Hallux valgus. Allied deformities of the forefoot and metatarsalgia; *Philadelphia & London.* pp. 10.
- Johnson KA. (1994). Master techniques in orthopaedics surgery, in: *the foot and the ankle*, No.4, pp.31-48.
- Johnston O. (1956). Further studies of the inheritance of hand and foot anomalies. *Clin Orthop.* Vol.8, pp. 146-160.
- Jones A. (1948). Hallux valgus in the adolescent. *Proc R Soc Med.* No.41, pp.392-393.
- Jordan HH, Brodsky AE. (1951). Keller operation for hallux valgus and hallux rigidus; *A.M.A. Arch Surg.*No.62, pp.586-596.
- Kelikian H. (1965). Hallux valgus. Allied deformities of the forefoot and metatarsalgia; *Philadelphia and London: Saunders Company.*
- Kellgren JH, Moore R. (1952). Generalised osteoarthritis and Heberden's nodes. *Br Med J.* No.1, pp.181-187.
- Kilmartin TE. (1994). The Orthotic Treatment of Juvenile Hallux Valgus. *Submitted to the University of Nottingham for the Degree of Doctor of Philosophy.*
- King DM & Toolan BC. (2004). Associated deformities and hypermobility in hallux valgus: an investigation with weightbearing radiographs. *Foot Ankle Int.* Vol. 25, pp. 251-255.
- Klaue K, Hansen ST, Masquelet AC. (1994). Clinical, quantitative assessment of first tarsometatarsal mobility in the sagittal plane and its relation to hallux valgus deformity. *Foot Ankle Int.* No.15, pp.9-13.
- Klein C, Groll-Knapp E, Kundi M, Kinz W. (2009). Increased hallux angle in children and its association with insufficient length of footwear: A community based cross-sectional study. *BMC Musculoskeletal Disorders.* No.10, p.159.
- La Porta G, Melillo T, Olinsky D. (1974). X-Ray evaluation of hallux abducto valgus deformity. *J.A.P.A.* Vol.64, No.8, pp.544-566.
- Lapidus PW. (1934). Operative correction of metatarsus varus primus in hallux valgus. *Surg Gynecol Obstet.* No.58, pp.183-191.
- Lapidus PW. (1956). A quarter of a century of experience with the operative correction of the metatarsus varus primus in hallux valgus. *Bull Hosp Jt Dis.* No.17, pp.404-421.
- Lapidus PW. (1960). The author's bunion operation from 1931 to 1959. *Clin Orthop.* No.16, pp.119-135.

- Leveille SG, Guralnik JM, Ferrucci L, Hirsch R, Simonsick E, Hochberg MC. (1998). Foot pain and disability in older women. *Am J Epidemiol*, No.148, pp.657-665.
- Mafulli N, Longo UG, Oliva F, et al. (2009). Bosch osteotomy and scarf osteotomy for hallux valgus correction. *Orthop Clin North Am*, No.40, pp. 515-524.
- Magnan B, Montanari M, Bragantini A, Fieschi S, Bartolozzi P. (1997). Trattamento dell'alluce valgo con tecnica "mini-invasiva" percutanea (P.D.O.: Percutaneous Distal Osteotomy). *Progressi in Chirurgia del Piede*, No.6, pp.91-104.
- Magnan B. Et al. (1998). Trattamento chirurgico dell'alluce valgo con osteotomia distale percutanea del primo metatarsale. Note di tecnica. G.I.O.T., Vol.XXIV, No.4, (dicembre 1998), pp.473-487.
- Mann RA, Coughlin MJ. (2010). Hallux Valgus. In Coughlin M, Mann RA, Saltzman CL (eds.): *Surgery of the foot and ankle*, 8th edition. Philadelphia, Elsevier, No7, pp. 184-354.
- McHale K, McKay D. (1986). Bunions in a child: Conservative versus surgical management. *J Musculoskel Med*, No.3, pp.56-62.
- Myerson MS. (2000). Hallux Valgus, in: *Foot and ankle disorders*. Saunders WB, Philadelphia, pp. 213-289.
- Neame R, Zhang W, Deighton C, Doherty M, Doherty S, Lanyon P, et al. (2004). Distribution of radiographic osteoarthritis between right and left hands, hips, and knees. *Arthritis Rheum*, No.50, pp.1487-1494.
- Piggot H. (1960). The natural history of hallux valgus in adolescence and early adult life. *J Bone Joint Surgery*; No.42-B, pp. 749-760.
- Roddy E, Zhang W, Doherty M. (2008). Prevalence and Associations of Hallux Valgus in a Primary Care Population. *Arthritis & Rheumatism (Arthritis Care & Research)* Vol. 59, No. 6, pp.857-862.
- Root ML, Orien WP, Weed JR. (1971). Biomechanical Examination of the foot; Clinical Biomechanics Corp. Los Angeles.
- Root ML, Orien WP, Weed JR. (1977). Normal and abnormal function of the foot. Vol II Clinical Biomechanics Corp. Los Angeles.
- Scranton PE Jr (1982). Adolescent bunions: Diagnosis and management. *Pediatr Ann*, No.11,.
- Sim-Fook L, Hodgson AR. (1958). A comparison of foot forms among the non-shoe and shoe-wearing Chinese population. *J Bone Joint Surg Am*, No.40, pp.1058-1062.
- Thompson GH. (1996). Bunions and deformities of the toes in children and adolescents. *Instr Course Lect*. No.45, pp.355-367.
- Weissman SD. (1989). *Radiology of the foot - 2nd Ed.*, Wiliam and Wilkins, Baltimore.
- White EG, Mulley GP. (1989). Footcare for very elderly people: a community survey. *Age Ageing*, No.18, pp.276-278.
- Wilder FV, Barrett JP, Farina EJ. (2005). The association of radiographic foot osteoarthritis and radiographic osteoarthritis at other sites. *Osteoarthritis Cartilage*, No.13, pp.211-215.



The Role of Osteotomy in the Correction of Congenital and Acquired Disorders of the Skeleton

Edited by Prof. James Waddell

ISBN 978-953-51-0495-7

Hard cover, 294 pages

Publisher InTech

Published online 11, April, 2012

Published in print edition April, 2012

This book demonstrates specific osteotomy techniques from the skull to the hallux. The role of osteotomy in the correction of deformity is under appreciated in part because of the ubiquitous nature of joint replacement surgery. It should be remembered, however, that osteotomy has a role to play in the correction of deformity in the growing child, the active young adult, and patients of any age with post-traumatic deformity limiting function and enjoyment of life. In this text we bring you a number of papers defining specific problems for which osteotomy is found to be an effective and lasting solution. I hope you find it useful.

How to reference

In order to correctly reference this scholarly work, feel free to copy and paste the following:

Salvatore Moscadini and Giuseppe Moscadini (2012). Hallux Valgus Correction in Young Patients with Minimally Invasive Technique, *The Role of Osteotomy in the Correction of Congenital and Acquired Disorders of the Skeleton*, Prof. James Waddell (Ed.), ISBN: 978-953-51-0495-7, InTech, Available from: <http://www.intechopen.com/books/the-role-of-osteotomy-in-the-correction-of-congenital-and-acquired-disorders-of-the-skeleton/hallux-valgus-correction-in-young-patients-with-minimally-invasive-technique>

INTECH
open science | open minds

InTech Europe

University Campus STeP Ri
Slavka Krautzeka 83/A
51000 Rijeka, Croatia
Phone: +385 (51) 770 447
Fax: +385 (51) 686 166
www.intechopen.com

InTech China

Unit 405, Office Block, Hotel Equatorial Shanghai
No.65, Yan An Road (West), Shanghai, 200040, China
中国上海市延安西路65号上海国际贵都大饭店办公楼405单元
Phone: +86-21-62489820
Fax: +86-21-62489821

© 2012 The Author(s). Licensee IntechOpen. This is an open access article distributed under the terms of the [Creative Commons Attribution 3.0 License](#), which permits unrestricted use, distribution, and reproduction in any medium, provided the original work is properly cited.

IntechOpen

IntechOpen