

We are IntechOpen, the world's leading publisher of Open Access books Built by scientists, for scientists

5,400

Open access books available

133,000

International authors and editors

165M

Downloads

Our authors are among the

154

Countries delivered to

TOP 1%

most cited scientists

12.2%

Contributors from top 500 universities



WEB OF SCIENCE™

Selection of our books indexed in the Book Citation Index
in Web of Science™ Core Collection (BKCI)

Interested in publishing with us?
Contact book.department@intechopen.com

Numbers displayed above are based on latest data collected.
For more information visit www.intechopen.com



Collapsing Glomerulopathy: The Expanding Etiologic Spectrum of a Shrinking Glomerular Lesion

Muhammed Mubarak and Javed I. Kazi

*Histopathology Department, Sindh Institute of Urology and Transplantation, Karachi
Pakistan*

1. Introduction

Collapsing glomerulopathy (CG) is a relatively recently described pattern of renal parenchymal injury that is being increasingly recognized as a common cause of end-stage renal disease (ESRD) throughout the world (Albaqumi et al., 2006). Although, it is currently classified officially as one of the pathological variants of focal segmental glomerulosclerosis (FSGS), its defining morphological alterations are in marked contrast to those observed in other variants of FSGS. During the initial stages of the disease, the lesion is characterized morphologically by an implosive, segmental and/or global wrinkling and retraction of the glomerular capillary tufts, pronounced hypertrophy and proliferation of the visceral epithelial cells (VECs) or podocytes, and severe tubulointerstitial damage. With disease progression, segmental and/or global glomerulosclerosis is also observed in addition to the pathognomonic collapsing lesions. Often, both the active and chronic lesions (collapsing and sclerotic) co-exist at the time of pathologic diagnosis, hence its classification as a variant of FSGS (Albaqumi et al., 2006; Albaqumi & Barisoni, 2006). The exact cause of this mysterious lesion is still not known, but a growing list of both genetic and acquired diseases/conditions is being reported in association with this morphologic pattern of renal parenchymal injury (Albaqumi et al., 2006). The pathogenesis of CG is also still incompletely understood, but many advances have been made during the past two to three decades, especially in the development and study of animal models of the disease and the discovery of genetic abnormalities leading to CG. Various triggering agents typically cause discreet epithelial cell injury in different anatomical compartments of the renal parenchyma leading to cell cycle dysregulation and a proliferative cellular phenotype (Albaqumi et al., 2006; Albaqumi & Barisoni, 2006; Schwimmer et al., 2003). Clinically, CG is characterized by its black racial predilection, a high incidence and severity of nephrotic syndrome (NS), a poor response to the currently used empirical therapy, and a rapid downhill course to ESRD (Albaqumi & Barisoni, 2006; Schwimmer et al., 2003). Although most of the early studies were reported in the native kidneys, the disease has also been found more recently to afflict the transplanted kidneys, either as a recurrent or de novo disease, frequently leading to loss of the allograft (Schwimmer et al., 2003; Canaud et al., 2010; Gupta et al., 2011; Nadasday et al., 2002; Stokes et al., 1996; Swaminathan et al., 2006). Most of the cases have been reported from the western countries, but the lesion is also being increasingly recognized in the tropical regions

(Kazi & Mubarak, 2007; Mubarak & Kazi, 2010; Nada et al., 2009). The recent increase in the reporting of CG partly reflects a genuine increase in the incidence of the disease and partly a detection bias resulting from heightened recognition by the pathologists (Albaqumi et al., 2006). There is no specific treatment for the disorder at present. Newer insights into the pathogenesis may pave the pathway for the development of targeted and specific therapy in not too distant future (Albaqumi et al., 2006; Albaqumi & Barisoni, 2006). This chapter discusses the nomenclature and historical background, epidemiology, etiology, pathogenesis, pathology, clinical manifestations, treatment and the prognosis of the condition.

2. The changing nomenclature of the lesion and the historical background

The nomenclature of CG has undergone interesting metamorphosis over the time and is still controversial. Although, the lesion was first recognized as a distinct clinicopathological entity (with a question mark!) in 1986, cases with similar morphology and clinical course in the literature trace back to early 1970's, when they were described as "malignant FSGS" (Albaqumi & Barisoni, 2006). During late 1980s and early 1990s, the term CG, was popular for this lesion (Weis et al., 1986). However, during mid to late 1990s reports started appearing in the literature linking this lesion to the expanding spectrum of FSGS; the main reason for this was the clinical presentation and concurrence of sclerotic lesions along with collapsing lesions on renal biopsies at the time of pathologic diagnosis (Detwiler et al., 1994; Valeri et al., 1996). Indeed, it has been suggested that the morphological lesions of CG may represent an early stage in the evolution that eventually are converted into the discrete segmental scars typical of FSGS (Detwiler et al., 1994). Another term, "cellular lesion," was also used for this lesion in 1980s (Schwartz & Lewis, 1985). The Columbia classification of FSGS officially classified this lesion as a subtype of FSGS (D'Agati et al., 2004). The Columbia classification also suggests using "cellular lesion" for a variant of FSGS characterized by expansion of the glomerular capillaries by intracapillary hypercellularity, in contrast to the intracapillary hypocellularity and collapse of CG. More recent studies suggest that the lesion may be distinct from FSGS and merits classification as a separate nosologic entity (Meyrier, 1999). Indeed, Barisoni et al. in a recently proposed classification of the podocytopathies have categorized CG separately from FSGS and further subdivided it into three major subtypes: idiopathic, genetic, and secondary or reactive (Barisoni et al., 2007). Further studies are needed to clarify this nosologic puzzle.

3. The magnitude of the problem and the epidemiology

Although the first report of CG included only six patients, this was soon followed by a series of fairly large studies from different centers mostly from United States, and subsequently from Europe and more recently from the developing countries (Agarwal et al., 2008; Bariety et al., 1998; Deegans et al., 2008; Detwiler et al., 1994; Grcevska & Polenakovik, 1999; Kazi & Mubarak, 2007; Laurinavicious et al., 1999; Meyrier, 1999; Mubarak & Kazi, 2010; Nada et al., 2009; Valeri et al., 1996; Weis et al., 1986). However, a wide variation is noted in the reported frequency of the lesion among all cases of FSGS. The disease thus has a cosmopolitan distribution and the wide geographical disparity in the reporting of CG appears to be mostly due to detection bias rather than true difference in the prevalence of the disorder, as more recently, rates of its diagnosis in both the native and the transplanted

kidneys approaching the western studies have been reported (Gupta et al., 2011; Mubarak, 2011). The increasing reporting of CG in the literature from both the western and the developing countries reflects both a true increase in the incidence of the lesion and the diagnostic bias (Albaqumi et al., 2006). The increase in the incidence of this lesion has been clearly shown in studies from United States and Europe. This lesion constituted 11% of all idiopathic FSGS at Columbia Presbyterian Medical Center from 1979 to 1985, 20% from 1986 to 1989, and 24% from 1990 to 1993 (Valeri et al., 1996). It is interesting to note their first case with the typical morphological features of CG was identified in 1979 on retrospective review of the renal biopsies, well before the formal recognition of this lesion, and represents the first documented case of idiopathic CG in the literature. Even more importantly, this lesion comprised 11% of all cases of idiopathic FSGS diagnosed on renal biopsies in pre-recognition era of CG in their report during the study period from 1979 to 1985 (Valeri et al., 1996). Another retrospective study by Haas et al. (1995), also from United States, from 1974 to 1993, identified their first case of CG after 1980, and during the time period of 1980 to 1993, CG represented 5.3% of cases of idiopathic FSGS in their series. A follow up study by the same authors from 1995 to 1997 identified CG in 9% of patients with idiopathic FSGS (Haas et al., 1997). Although less common than in the United States, Europe has also not lagged behind in the reporting of CG (Meyrier, 1999). The exact cause for the increase in the incidence of CG is not known, but may be due to a possible change in the exposure to certain infective organisms, chemical agents, or other environmental factors. Similarly, high rates of detection have been reported both in native and transplanted kidneys from developing countries, but no formal upward trend analysis of CG has been reported from developing countries till date (Gupta et al., 2011; Kazi & Mubarak, 2007; Mubarak & Kazi, 2010; Nada et al., 2009).

4. The etiology and the associated conditions

The most common form of CG is the primary or idiopathic one and the exact cause of this, as is evident from the name, is still not known. What is apparent from the increased reporting of CG is, however, that it is not a single disease but rather a unique pattern of renal parenchymal injury, which may result from a multitude of causes (Albaqumi et al., 2006; Amoura et al. 2006). Indeed, one outcome from the growing awareness of the lesion has been the exponential increase in reporting its association with disorders other than human immunodeficiency virus (HIV)-1 infection or idiopathic. There are many reports of secondary or reactive and genetic causes of this lesion and these provide an insight into the widening etiopathogenetic pathways of the condition (Table 1).

When broadly categorized, these associated disorders fall into seven classes: infections, drug toxicity, autoimmune diseases, malignant tumors, genetic diseases, ischemic causes, and during the posttransplant period. Among all the known causes/associations, HIV-1 infection is the most common cause and the disease caused by HIV-1 infection is called HIV associated nephropathy (HIVAN) (D'Agati & Appel, 1998). Other infectious agents and immunologic derangements are next common reported associations (Albaqumi et al., 2006). The list of the associated conditions/etiologic agents is growing day by day. As alluded to earlier, this wide heterogeneity of the underlying causes/associated conditions clearly shows that CG is not a single disease entity, but rather a common final pathway resulting from these various insults, all sharing the similar morphologic appearance on renal biopsy.

One peculiar scenario for the development of CG is the posttransplant period, where the disease can occur as recurrent, or more commonly, as de novo disease (Canaud et al., 2010; Gupta et al., 2011; Nadasday et al., 2002; Stokes et al., 1996; Swaminathan et al., 2006).

Infections

Human Immunodeficiency Virus-1 infection
 Parvovirus B19
 Cytomegalovirus infection
 Human T cell Lymphotropic Virus-1
 Hepatitis C Virus
 Pulmonary tuberculosis
 Leishmaniasis
 Febrile illness

Autoimmune diseases

Systemic lupus erythematosus
 Adult Still's disease
 Mixed connective tissue disorder
 Giant cell arteritis
 Lupus-like syndrome

Malignant tumors

Multiple myeloma
 Acute monoblastic leukemia
 Hemophagocytic syndrome

Genetic disorders

Action myoclonus-renal failure syndrome
 Mitochondrial cytopathy
 Familial
 Sickle cell anemia

Drugs/chemotherapeutic agents

Interferon- α
 Pamidronate
 Cyclosporin A

Post renal and other solid organ transplantation

Recurrent
 De novo
 Hyaline arteriolopathy
 Acute vascular rejection
 Thrombotic microangiopathy

Table 1. List of known etiologic factors/clinical conditions associated with collapsing FSGS in humans.

However, the etiological and clinical associations of CG following kidney transplantation are still not fully known. Recent studies have implicated ischemia and drug toxicity as major predisposing factors in the development of posttransplant CG (Swaminathan et al., 2006). Recurrent CG provides a unique opportunity to study the evolution of the lesions of CG by sequential biopsies with no interference of the confounding secondary causes (Bariety et al., 2001).

5. Pathogenetic mechanisms

Given the wide range of etiologic associations, a variety of hypotheses for the pathogenesis of CG have been proposed over the years, but till date no one definable pathogenic trigger has emerged clearly from studying these disparate disorders as a group. However, significant advances have been made during past two to three decades in unraveling many of the pathways leading to the final common manifestation of the disease. As discussed previously in the etiology of the condition, the discovery of secondary and genetic causes of CG had been very instrumental in understanding the pathogenesis of the disorder. Similarly, the discovery of a number of susceptibility genes for CG in mice and humans, and the development of more than a dozen independent mouse models of the disease in different centers of the world, represent landmark achievements for studying the disease process both *in vivo* and in a wider perspective (Albaqumi et al., 2006). The mouse models can be broadly categorized in to four types based on the nature of the triggering agents. In marked contrast to human disease, the pathogenic triggers in each of the four types of mouse models of CG are known. These include; HIV-1 gene products, immunoglobulins (Ig), oxidative stress, and the disturbance of podocyte paracrine/autocrine regulatory loop (Albaqumi et al., 2006). How these different triggering agents lead to the stereotyped morphological appearance is still not known. However, a hypothetical “best-fit” model has been proposed to explain the final common expression of the disease caused by such seemingly divergent initiating stimuli. According to this model, the initiating event consists of discreet epithelial cell injury caused by either intrinsic or extrinsic agents involving different compartments of renal parenchyma, *i.e.*, both the podocytes and the renal tubular epithelium. The injured epithelial cells undergo either apoptosis or necrosis, and relay signals to the surrounding un-injured epithelial cells and resident immune cells, principally the dendritic cells. Conditioned by the genetic and other environmental factors, the surrounding uninjured epithelial cells, subsequently respond to the injury, not by the normal repair or regeneration, but in a perverted manner, by the processes of dedifferentiation, proliferation and transdifferentiation of, for example, podocytes to the macrophage-like phenotype in the glomerular compartment (Albaqumi et al., 2006). These phenotypic changes are accompanied by changes in the behavior of these cells and their immunophenotypic profile. The immunophenotypic markers of maturity are lost, and the markers of immature phenotype, proliferation and macrophage lineage are expressed, the latter phenomenon being known as transdifferentiation (Bariety et al., 1998) (Table 2).

The podocytes become cuboidal to epithelioid cell like, lose primary foot processes, and detach from the glomerular basement membrane (GBM) and proliferate to form pseudo-crescents. Many of these detached podocytes are also passed into the tubules. These phenotypic changes result in marked alterations in the normal structure-function relationships of the different compartments of the nephron with consequent drastic changes in the function, so

characteristic of this disease. The luminal factors and the preexisting disturbance in the immune system, coupled with genetic susceptibility, likely contribute to the above sequence of events (Albaqumi et al., 2006). Similar changes in tubular epithelium give rise to both acute and chronic damage of the tubules, with microcystic transformation of the tubules in many forms of CG, especially that induced by HIV-1 infection (Fig. 1). Although this hypothetical “best-fit” model has not been studied directly in humans, but preliminary studies to characterize the earliest changes in the development of CG in some mouse models have shown that necrosis or apoptosis of epithelial cells occurs before the aberrant proliferation of the surviving epithelium. This podocytopenia is transient, short-lived, and not often seen on renal biopsies in human CG, and is in contrast with the prominent and pathogenetic podocytopenia in non-collapsing FSGS. We have observed this phenomenon in some of our sequential renal allograft biopsies done for the investigation of posttransplant proteinuria (unpublished observations) (Fig. 1). Indeed, renal allograft represents one of the best models to study the evolution and natural history of CG in humans.

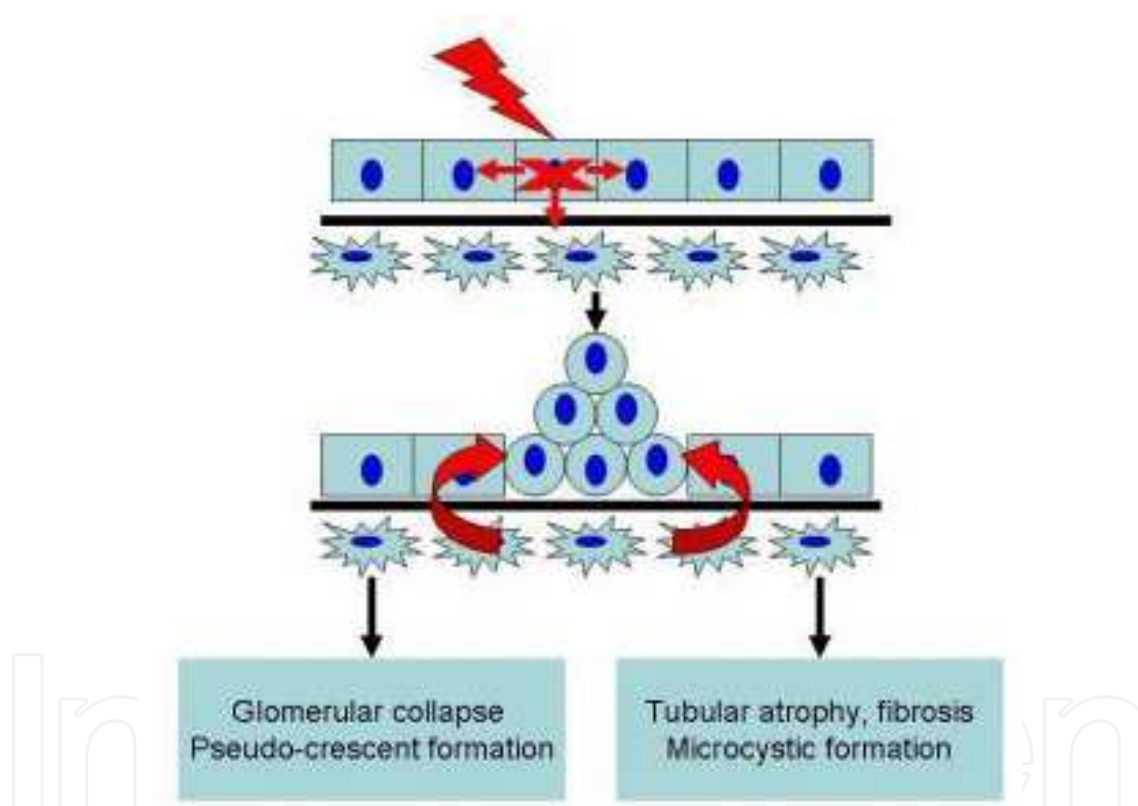


Fig. 1. Schematic diagram showing a hypothetical “best-fit” model for the pathogenesis of collapsing glomerulopathy. According to this model, an intrinsic or extrinsic injurious agent discreetly damages some epithelial cells. These cells undergo either apoptosis or necrosis and send signals to neighboring epithelial cells and dendritic and other innate immune cells. These cells, instead of inducing normal repair or cell cycle arrest upon contact with adjacent epithelial cells, cause aberrant hyperplasia of surrounding epithelial cells. These ultimately manifest in the form of glomerular collapse and pseudocrescent formation in the glomeruli, and in tubular atrophy, microcystic formation in the tubular compartment with interstitial inflammation and fibrosis. These structural alterations result in profound disturbances in the functions of respective elements of the renal parenchyma.

Underexpressed markers	Overexpressed markers
CD10	Cyclin D1
Glomerular epithelial protein 1	Cyclin E
Podocalyxin	Cyclin A
Synaptopodin	Ki-67
Wilms' tumor-1	Desmin
p27	Cytokeratin
p57	CD68

Table 2. The main immunohistochemical (IHC) markers of the aberrant podocyte phenotype observed in collapsing glomerulopathy.

Two major common pathways have been proposed to explain the stereotyped response of the renal parenchyma to a wide variety of conditions in CG: activation of the immune system and the dysregulation of the mitochondrial function ((Albaqumi et al., 2006)) (Fig. 2). Many of the diseases associated with CG involve a disturbance of immune homeostasis, suggesting at least some role for immune activation in the development of CG. The precise immunologic mechanisms are still not completely clear, but studies show that many involve T helper type 1 lymphocyte responses, an immune perturbation that already is known to aggravate and accelerate other proliferative parenchymal renal diseases, particularly crescentic glomerulonephritis (CresGN), the disease that CG mimics most closely on renal biopsies.

The second major common pathway involves some form of acute ischemic insult to the kidney such as that resulting from thrombotic microangiopathy (TMA), cyclosporine A (CsA) toxicity and severe hyaline arteriopathy ((Albaqumi et al., 2006)). This phenomenon has been particularly observed in transplanted kidneys. Recently, three cases of CG have been reported in renal allografts on allograft biopsies in association with areas of frank segmental infarction (Canaud et al., 2010). We have also observed similar phenomenon on renal biopsies from patients with acute cortical necrosis in native kidneys (Kazi & Mubarak, 2011). Thus, ischemic injury to the glomeruli does have a role in the development of CG. This may be mediated by dysregulation of the mitochondrial function and/or altered autocrine/paracrine interaction of podocytes, endothelial cells, and/or parietal epithelial cells ((Albaqumi et al., 2006)).

6. Diagnosis and histopathology

Although the diagnosis of CG may be suspected on clinical grounds, it can only be confirmed on the invasive test of renal biopsy. It is diagnosed pathologically by its characteristic morphological features in the glomeruli on light microscopy (LM) of renal biopsy (Albaqumi et al., 2006; Schwimmer et al., 2003). These consist of focal to diffuse, segmental to global, implosive collapse of the glomerular capillary tufts associated with marked proliferation and swelling of overlying podocytes (Fig. 3-7). These proliferating podocytes form a number of cell layers and fill the Bowman's space caused by collapsed tufts, resulting in the formation of pseudo-crescents, which differ from the true crescents of CresGN by their visceral location, the presence of a cleft like space between the pseudo-crescents and the parietal epithelium, the epithelioid appearance of the cells forming the pseudo-crescents, and the absence of fibrin in the pseudo-crescents (Fig. 5, 6). These

extracapillary cells lack the spindle cell appearance or pericellular matrix with collagen fibers typically noted in true crescents. Another distinguishing feature is that Bowman's capsule itself is intact, without the ruptures typical of cellular crescents of the inflammatory type. The proliferating podocytes also exhibit marked cytoplasmic vacuolization and prominent, hyaline, protein resorption droplets (Figure 5). There is usually also concurrent segmental and/or global glomerulosclerosis at the time of pathologic diagnosis of CG (Fig. 7). The distribution of lesions may be segmental or global, focal or diffuse and may involve any number of the glomeruli (Fig. 4). Due primarily to its poor prognosis among all the other variants of FSGS, even a single glomerulus with the characteristic collapsing lesion is sufficient for the diagnosis of CG on the biopsy. Although, CG is defined on the basis of glomerular lesions, the tubulointerstitial disease is an equally important component of the condition and often appears out of proportion to the degree of glomerular sclerosis.

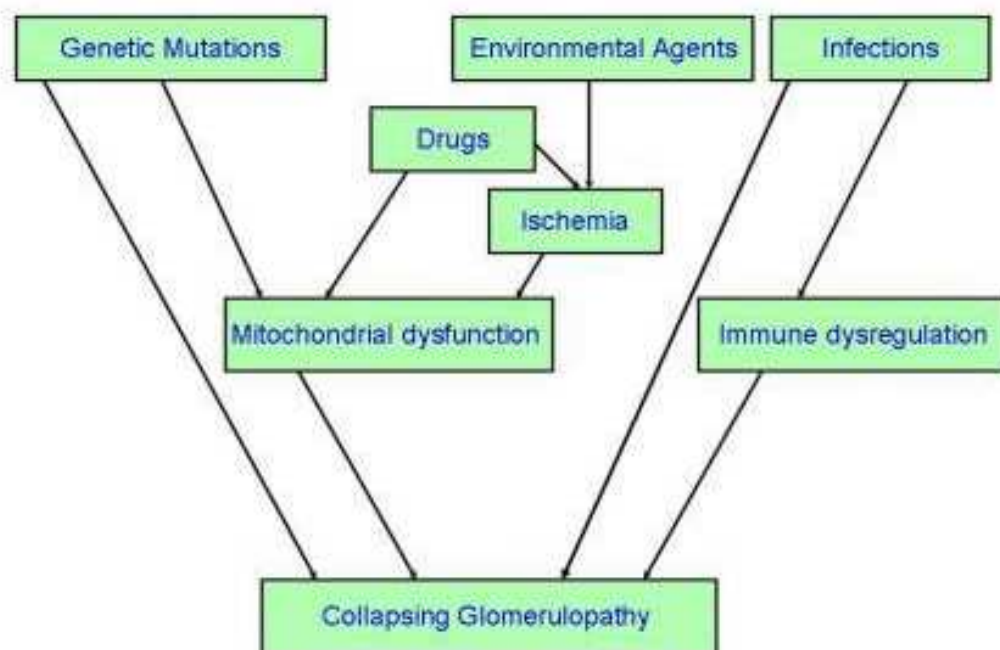


Fig. 2. Schematic diagram showing the pathogenesis of collapsing glomerulopathy. As is evident from this diagram, several mechanisms are involved in the pathogenesis of CG. A variety of triggering agents act through two major common pathways: dysregulation of the immune system and mitochondrial dysfunction. Some factors, eg. Infections, can directly lead to CG, while others produce lesions of CG by the disturbances in mitochondrial activity and immune function.

It has been suggested that the poor prognosis of the condition results from tubulointerstitial pathology rather than glomerular lesions (Meyrier, 1999). The tubulointerstitial component shows both acute and chronic changes. These include variable degrees of tubular atrophy, interstitial fibrosis, edema, and inflammation, associated with widespread degenerative and regenerative changes of the tubular epithelium, including microcyst formation, as shown in Fig. 8 and 9. The later are filled with hyaline casts with scalloped margins, as shown in Fig. 9. It has been proposed that the extent of tubulointerstitial involvement varies depending on the etiology of CG and may help in the differential diagnosis of different causes of CG (Albaqumi & Barisoni, 2006).

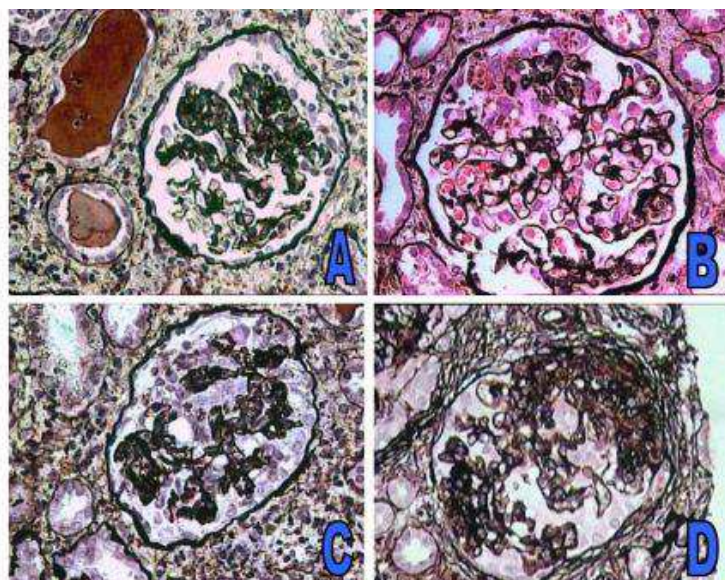


Fig. 3. The morphologic evolution of the lesions of collapsing glomerulopathy. A. Medium-power view showing segmental collapse of capillary tufts. The overlying podocytes have not yet markedly proliferated or hypertrophied. They are forming a cobblestone structure directly overlying the collapsed tufts. B. Medium-power view showing mild hypertrophy and hyperplasia of podocytes overlying the segment of capillary collapse. The hypertrophied podocytes are forming a focal crescent-like structure. Many hypertrophied podocytes contain protein resorption droplets in their cytoplasm. C. Medium-power view showing marked hypertrophy and hyperplasia of podocytes forming a cellular crescent-like structure, known as pseudo-crescent. An irregular cleft like space separates the viscally located pseudo-crescent from the Bowman's capsule. D. Advanced stages of collapsing glomerulopathy showing the evolution of collapsed tufts to areas of segmental scar formation and adhesion with Bowman's capsule. Areas of capillary collapse and mild hypertrophy of podocytes are still visible.

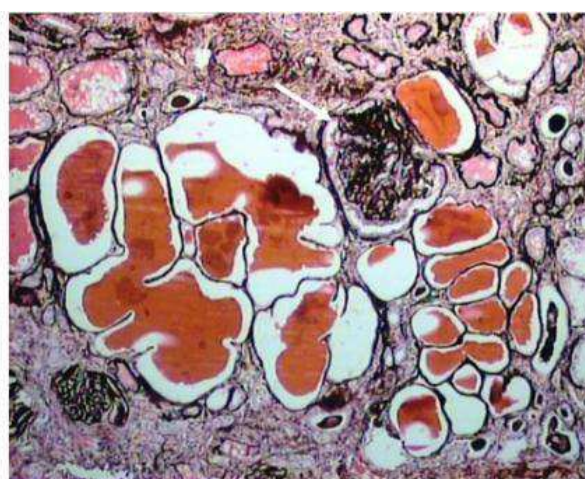


Fig. 4. Low-power photomicrograph showing one glomerulus with global retraction of the capillary tufts associated with prominent podocytes arranged as cobblestone-like collar on the surface of collapsed capillary tufts. These podocytes have not yet proliferated profusely. There is also marked tubulointerstitial involvement with tubular atrophy, microcystic dilatation and protein casts in dilated tubules. (Jones' methenamine silver, $\times 200$)

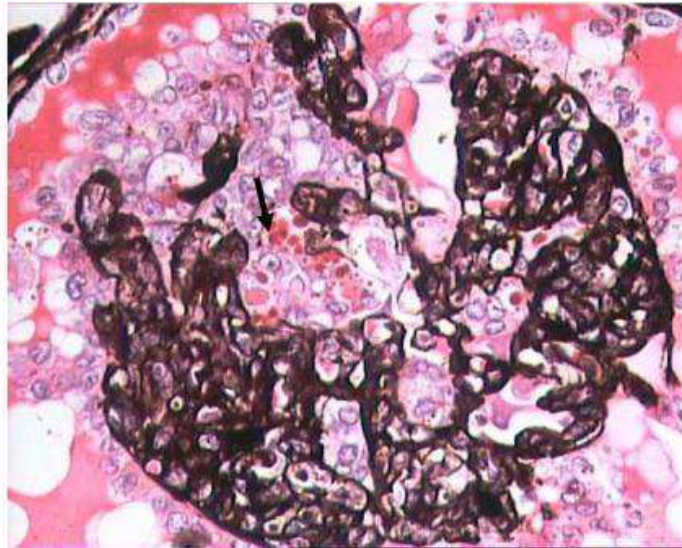


Fig. 5. High power photomicrograph showing global collapse of capillary tufts associated with marked hyperplasia and hypertrophy of podocytes. These show prominent cytoplasmic vacuolization and numerous hyaline, round to oval, protein resorption droplets (arrow). (Jones' methenamine silver, $\times 400$)

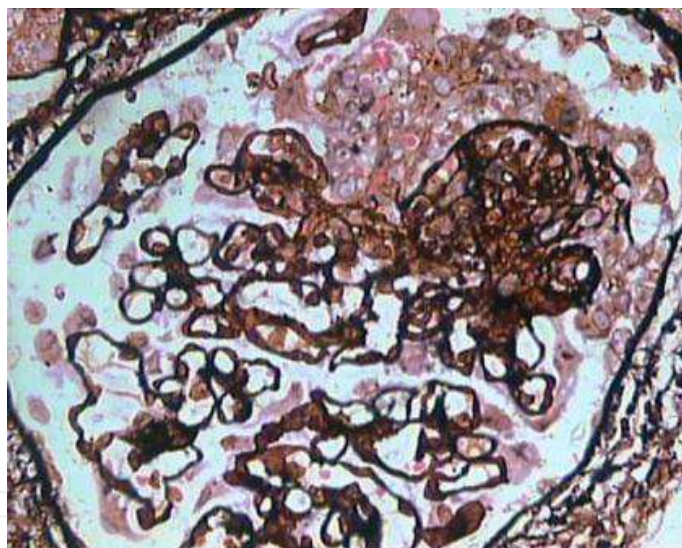


Fig. 6. High-power view showing segmental collapse of the capillary tufts associated with marked proliferation of the podocytes, forming a pseudo-crescent. The pseudo-crescent is separated from the Bowman's capsule by a cleft like space. There is no fibrinoid necrosis of the tuft, which distinguishes it from focal necrotizing lesion. (Jones' methenamine silver, $\times 400$)

As is evident from the above discussion of pathology, the biopsy diagnosis of CG is based almost solely on LM study. Immunofluorescence microscopy (IF) for renal panel immunoglobulins and complement components is usually negative (Table 3) or shows only focal segmental positivity of IgM, C3, and occasionally C1q, in collapsed segments of the glomeruli in some cases (Fig. 10). The intensity of staining is usually mild, ranging from trace positivity to 1+ but may be up to 2+ on a scale of 0 to 3+.

Light microscopic changes

Glomeruli

Collapse: segmental or global wrinkling and folding of the GBM with occlusion or sub-occlusion of the capillary lumena

Pseudo-crescent formation: podocyte proliferation leading to multiple layers of cells located over collapsed tufts

Swollen podocytes with occasional large nuclei, the later usually in viral causes of CG

Protein reabsorption droplets and vacuolization in the cytoplasm of podocytes

In advanced stages: segmental and/or global sclerosis

Tubulo-Interstitial compartment

Acute changes:

Interstitial edema

Interstitial inflammation

Acute tubular injury: flattening of the tubular epithelium, large epithelial cells, large, occasionally atypical, nuclei with prominent nucleoli

Chronic changes:

Tubular atrophy

Interstitial fibrosis

Microcysts: dilated, often angulated, tubules with flat epithelium containing eosinophilic proteinaceous casts with peripheral scalloping

Vessels

Nonspecific changes except for CG cases associated with vasculopathy such as thrombotic microangiopathy

Immunofluorescence

Nonspecific segmental positivity of IgM and C3 in areas of collapse and/or sclerosis

Electron microscopy

Large cuboidal podocytes with pale cytoplasm

Retraction of primary processes

Diffuse and severe foot process effacement

Loss of detectable actin-based cytoskeleton

Electron dense protein resorption droplets in podocyte cytoplasm

Detachment of podocytes from underlying GBM and deposition of newly formed extracellular matrix in between GBM and podocytes

Absence of tubulo-reticular inclusions in idiopathic CG.

Table 3. The characteristic morphologic features of CG observed on renal biopsy examination by light microscopy, immunofluorescence, and electron microscopy.

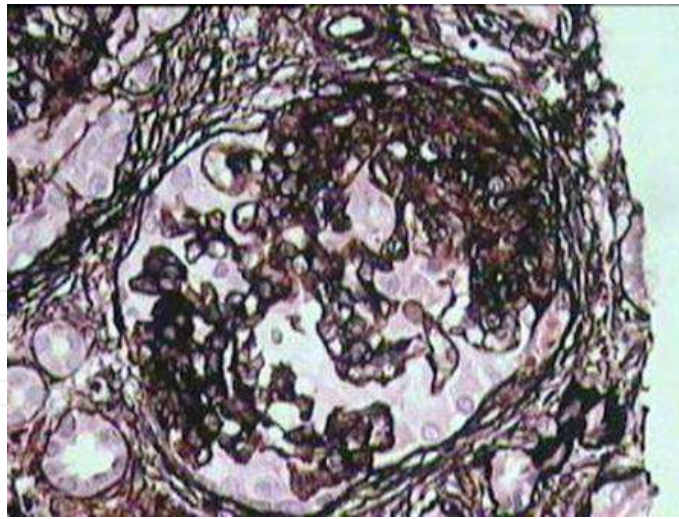


Fig. 7. High-power view showing a glomerulus exhibiting an admixture of segmental collapse on the left side and segmental scarring with adhesion formation with Bowman's capsule on the right, a not infrequent finding on renal biopsies at the time of primary diagnosis. Indeed, this concurrence of sclerotic and collapsing lesions has led the investigators to categorize the collapsing glomerulopathy as a variant of focal segmental glomerulosclerosis. (Jones' methenamine silver, $\times 400$)

The main purpose of IF study is to rule out the secondary causes of CG. Similar to IF, electron microscopic (EM) features are also non-specific and consist of wrinkling and collapse of GBM in areas of collapse with little or no thickening of GBM. The overlying podocytes are greatly hypertrophied with diffuse foot process effacement with focal areas of separation from the underlying GBM. No electron dense deposits are observed. EM study also helps in excluding secondary causes of CG, such as HIVAN, which reveal characteristic tubuloreticular inclusions (D'Agati & Appel, 1998).

7. Differential diagnosis

The lesions of full-blown CG are so characteristic that they are rarely mistaken for any other renal glomerular diseases. Furthermore, there are very few histopathological lesions on renal biopsies which simulate CG and come in the differential diagnosis. These include other variants of FSGS as well as other forms of glomerular disease, most notably CresGN. Among the variants of FSGS, the closest differential diagnosis of CG is the cellular FSGS. Indeed, during 1980s, the term of "cellular lesion" was also used to denote some cases of typical CG (Schwartz & Lewis, 1985). Both the collapsing and cellular variants are characterized by marked hyperplasia and hypertrophy of podocytes. The discriminating features that separate the two variants are the implosive wrinkling and retraction of the GBM seen in CG associated with endocapillary hypocellularity as opposed to the expansile lesions of endocapillary hypercellularity seen in the cellular FSGS. All other variants of FSGS display segmental increase in mesangial matrix with consolidation and the obliteration of capillaries (segmental scars), hyalinosis, intracapillary foam cells, and adhesion formation with Bowman's capsule, lesions rarely seen in early stages of CG. Advanced cases of CG, however, may display segmental and/or global glomerulosclerosis. In many cases of CG, the podocyte proliferation may be so florid as to form a cellular

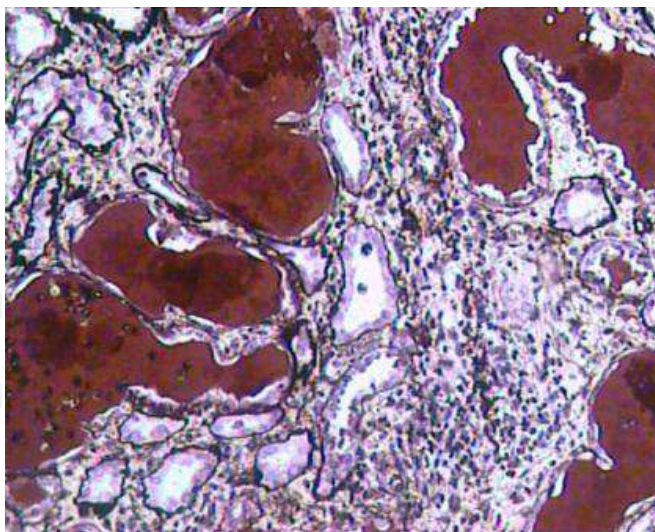


Fig. 8. Medium-power view showing moderate degree of tubular atrophy characterized by thickening and wrinkling of the tubular basement membranes, interstitial mononuclear inflammatory cell infiltration, and widespread microcystic transformation of tubules, the later filled with proteinaceous casts. The walls of many of the cystically dilated tubules are lined by flattened epithelium, which has resulted from degenerative changes. The changes in the tubulointerstitial compartment vary from case to case and some authors argue that these may be of differential diagnostic value regarding the underlying etiologic condition. It is suggested that these tubulointerstitial alterations are more important than the glomerular changes of collapsing glomerulopathy from poor prognostic point of view. (Jones' methenamine silver, $\times 200$)

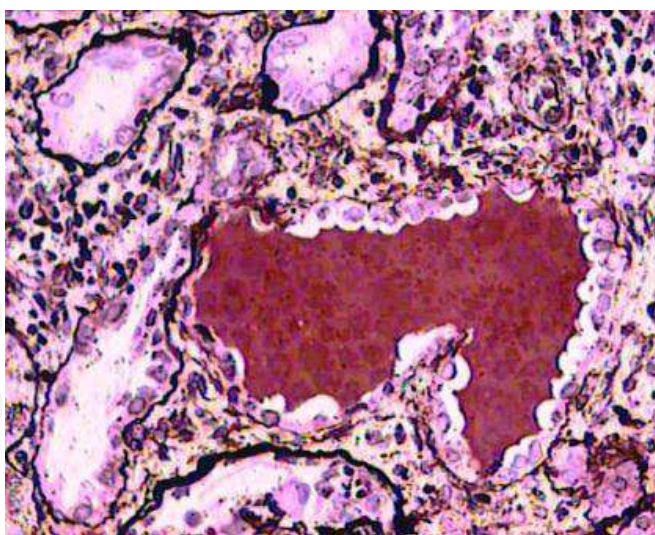


Fig. 9. High-power view showing marked tubular atrophy with irregular thickening and wrinkling of the tubular basement membranes and reduction in the diameter of the tubules. There is also patchy interstitial mononuclear inflammatory cell infiltration, and one tubule, which is cystically dilated and filled with proteinaceous cast with scalloped margins. This finding is highly characteristic of some forms of collapsing glomerulopathy. There are also marked degenerative changes in some of the tubular epithelial cells with shedding of cytoplasm and flattening of the cells (Jones' methenamine silver, $\times 400$)

crescent like structure, known as pseudo-crescent, to differentiate it from true crescents. In such cases, the biopsy findings may be misdiagnosed as CresGN. A closer scrutiny of the lesions with special attention to the features described previously in pseudo-crescents, along with appropriate integration of the clinical history and LM, IF, and EM findings will aid in this differential diagnosis (Albaqumi et al., 2006; Schwimmer et al., 2003).

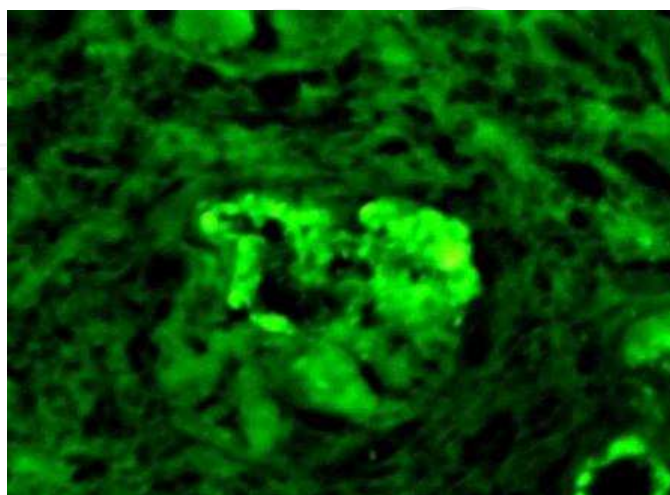


Fig. 10. Immunofluorescence on snap-frozen tissue showing segmental positivity of immunoglobulin M (IgM) in areas of segmental collapse. C3 also commonly accompanies IgM, whereas rest of the renal panel is usually negative. (Fluorescein isothiocyanate (FITC)-conjugated IgM, , ×200)

8. The clinical manifestations

The clinical spectrum of CG is also expanding with the expanding list of associated conditions and reflects to some extent the underlying causes. In general, the demographic, clinical and laboratory parameters resemble those observed in non-collapsing FSGS, but the disease is usually more severe. Idiopathic CG is typically a disease of young adults, with a median age of patients being 30 to 40 years, but a wide range of ages have been reported, with patients as young as 1.5 years and as old as 82 years. There are very few reports of CG in children (Singh et al., 2000; Gulati et al., 2008). Regarding gender distribution, most studies have reported a male predominance, although in one study, females predominated over males. CG is also notorious for its black racial predilection. Since Weiss et al's original report (1986), in which all six patients with CG were black, a predominance of black patients in the United States has been noted (Detwiler et al., 1994; Valeri et al., 1996). A study of eight patients in France by Bariety et al. also noted a predominance of black patients (1998). A review of all published series on CG has shown that, around 50% of the reported cases in the literature belong to black race (Albaqumi & Barisoni, 2006).

On presentation, a majority (>80%) of patients with CG have nephrotic range proteinuria, and studies have documented a significantly greater frequency of nephrotic syndrome (NS) and higher levels of proteinuria in patients with CG compared with patients with non-collapsing FSGS. There is also significantly greater renal functional impairment in patients with CG at presentation than patients with non-collapsing FSGS (Schwimmer et al., 2003). Other severe manifestations of NS are frequent, including hypoalbuminaemia,

hypercholesterolemia, and edema, but these manifestations are not significantly different from patients with non-collapsing FSGS. Most patients are hypertensive on presentation. Once a diagnosis of CG is rendered, the possibility of HIVAN must be ruled out, usually by negative HIV serological tests, corroborated by the absence of endothelial tubuloreticular inclusions on ultrastructural examination (Mubarak & Kazi, 2010).

9. Current and future therapeutic approaches

Currently, there is no specific treatment available for CG, and there are no prospective treatment trials of CG (Schwimmer et al., 2003). The therapeutic approaches used at present are empirical, and analogous to those used for non-collapsing FSGS, i.e., use of steroids or immunosuppressive agents (Albaqumi et al., 2006; Schwimmer et al., 2003). The particular therapeutic agents, their dosages, duration, and the definition of response vary among different studies, contributing to variable results in different studies. Recent studies in patients with non-collapsing FSGS using steroids, cyclosporine, and other immunosuppressive agents have shown that remissions were obtained in over 67% of cases, resulting in prolonged renal survival (Stirling et al., 2005; Stirling, 2006). In contrast, data from retrospective studies of CG suggest that the disease is relatively resistant to most immunosuppressive agents (Detwiler et al., 1994; Valeri et al., 1996). Although, variable rates of success have been reported, the overall results are poor, with a complete remission of 9.6% and a partial remission of 15.2% been reported (Schwimmer et al., 2003). A more specific approach involves the use of highly active anti-retroviral therapy (HAART) in cases of CG in HIV-1 positive patients. This has been shown to decrease the rate of progression of the disease to ESRD by 38% (Albaqumi et al., 2006).

In view of the present lack of effective therapeutic agents and the uniformly poor prognosis of the disease, there is an urgent need for the development of highly effective and targeted agents, based on the knowledge of the pathogenetic pathways of CG. Indeed, some progress has been made in this regard in animal models. The administration of small molecule inhibitors of cyclin-dependent kinases (CDKs) in small animals in preclinical trials has been shown to prevent the development, and retard the progression, of experimental lesions of CG. In addition, the use of differentiating agents such as retinoic acid derivatives, to inhibit the proliferation of podocytes and induce their differentiation to a mature, resting phenotype, has also been shown to ameliorate the lesions of experimental CG. Promising results have also been obtained in improving renal function in experimental forms of CG by the use of small molecule inhibitors of inflammatory pathways controlled by NF- κ B and cyclooxygenase-2. These findings underscore the multiplicity of pathogenetic pathways for the proliferative phenotype of podocytes in CG, and signify the emergence of rational approaches to therapy for CG based on the understanding of pathogenesis in the near future (Albaqumi et al., 2006).

10. Natural history and prognosis

Due primarily to the relatively scant data and the retrospective nature of most studies on CG, only generalizations can be made about the natural history of the disease and its prognosis. Patients with CG are at high risk of progressing to ESRD. Even with the currently available treatment, the incidence of ESRD is 50% to 100% in most series (Agarwal et al., 2008; Deegans et al., 2008; Detwiler et al., 1994; Grcevska & Polenakovik, 1999; Kazi &

Mubarak, 2007; Laurinavicius et al., 1999; Meyrier, 1999; Mubarak & Kazi, 2010; Nada et al., 2009; Valeri et al., 1996; Weis et al., 1986). In all comparative studies, the renal survival of patients with CG was significantly worse than patients with non-collapsing FSGS. Multiple studies have explored the possible prognostic features in CG. Valeri et al. (1996) found that progression to ESRD was predicted by serum creatinine concentration at the time of biopsy ($P < 0.05$) and lack of remission of proteinuria ($P < 0.025$), but did not find a correlation between severity of proteinuria or other features of NS with the outcome. The rate of progression of renal failure in the collapsing FSGS group correlated highly with the severity of tubular degenerative and regenerative changes ($P < 0.02$) but not with any other parameter of tubulointerstitial or glomerular change. The rate of progression of renal failure correlated strongly with male sex. Laurinavicius et al. (1999) reviewed retrospectively the data from 42 patients with CG and 18 patients with HIVAN to determine the predictors of serum creatinine level, proteinuria, and progression of renal disease. In their multivariate model, the risk for ESRD was increased significantly by interstitial fibrosis of $>20\%$, creatinine level > 2.0 mg/dL, proteinuria >8 g/d, glomeruli with collapsing lesions $>20\%$, and HIV infection ($P < 0.0001$). Similar to its ominous prognosis in native kidneys, the disease also leads to rapidly progressive graft failure, usually within two years of diagnosis.

11. Conclusion

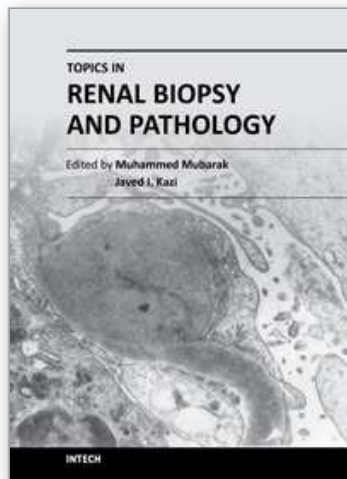
In conclusion, with increasing awareness and research, significant advances have been made in understanding the etiopathogenetic mechanisms underlying this mysterious renal disease. This is likely to open up the avenues for the development of rational and targeted therapy for this uniformly resistant form of disease. The success of preclinical testing of the novel therapeutic strategies based on the knowledge of pathogenetic pathways obtained from studies in humans and animal models holds promise that the presently poor prognosis of CG is likely to improve in the near future.

12. References

- Agrawal V, Vinod PB, Krishnani N, & Sharma RK. (2008). A case of collapsing glomerulopathy associated with febrile illness. *Indian J Pathol Microbiol*, Vol. 51, No. 4, pp. 509-11.
- Albaqumi M, Soos TJ, Barisoni L, & Nelson PJ. (2006). Collapsing glomerulopathy. *J Am Soc Nephrol*, Vol. 17, No. 10, pp. 2854-63.
- Albaqumi M, & Barisoni L. (2006). Current views on collapsing glomerulopathy. *J Am Soc Nephrol*, Vol. 19, No. 7, pp. 1276-81.
- Amoura Z, Georgin-Lavialle S, Haroche J, Merrien D, Brocheriou I, Beaufils H, & Piette J-C. (2006). Collapsing glomerulopathy in systemic autoimmune disorders: a case occurring in the course of full blown systemic lupus erythematosus. *Ann Rheum Dis*, Vol. 65, No. 2, pp. 277-8.
- Bariety J, Nochy D, Mandet C, Jacquot C, Glotz D, & Meyrier A. (1998). Podocytes undergo phenotypic changes and express macrophagic-associated markers in idiopathic collapsing glomerulopathy. *Kidney Int*, Vol. 53, No. 4, pp. 918-25.
- Barisoni L, Kriz W, Mundel P, & D'Agati V. (1999). The dysregulated podocyte phenotype: a novel concept in the pathogenesis of collapsing idiopathic focal segmental

- glomerulosclerosis and HIV-associated nephropathy. *J Am Soc Nephrol*, Vol.10, No. 1, pp. 51-61.
- Barisoni L, Schnaper HW, & Kopp JB. (2007). A proposed taxonomy for the podocytopathies: a reassessment of the primary nephrotic diseases. *Clin J Am Soc Nephrol*, Vol. 2, No. 3, pp. 529-42.
- Canaud G, Bruneval P, Noel L-H, Correas J-M, Audard V, Zafrani L, Rabant M, Timsit MO, Martinez F, Anglicheau D, Thervet E, Patey N, Legendre C, & Zuber J. (2010). Glomerular collapse associated with subtotal renal infarction in kidney transplant recipients with multiple renal arteries. *Am J Kidney Dis*, Vol. 55, No. 3, pp. 558-65.
- D'Agati V, & Appel GB. (1998). Renal pathology of human immunodeficiency virus infection. *Semin Nephrol*, Vol. 18, No. 4, pp. 406-21.
- D'Agati VD, Fogo AB, Bruijn JA, & Jennette JC. (2004). Pathologic classification of focal segmental glomerulosclerosis. A working proposal. *Am J Kidney Dis*, Vol. 43, No. 2, pp. 368-82.
- Deegans JKF, Steenbergen EJ, Borm GF, & Wetzels JFM. (2008). Pathological variants of focal segmental glomerulosclerosis in an adult Dutch population-epidemiology and outcome. *Nephrol Dial Transplant*, Vol. 23, No.1, pp.186-92.
- Detwiler RK, Falk RJ, Hogan SL, & Jennette JC. (1994). Collapsing glomerulopathy: a clinically and pathologically distinct variant of focal segmental glomerulosclerosis. *Kidney Int*, Vol. 45, No. 5, pp. 1416-24.
- Grcevska L, & Polenakovik M. (1999). Collapsing glomerulopathy: clinical characteristics and follow-up. *Am J Kidney Dis*, Vol. 33, No. 4, pp. 652-7.
- Gupta R, Sharma A, Agarwal SK, & Dinda AK. (2011). Collapsing glomerulopathy in renal allograft biopsies: a study of nine cases. *Indian J Nephrol*, Vol. 21, No. 1, pp. 10-3.
- Haas M, & Spargo BH, Coventry S. (1995). Increasing incidence of focal segmental glomerulosclerosis among adult nephropathies: A 20-years renal biopsy study. *Am J Kidney Dis*, Vol. 26, No. 5, pp. 740-50.
- Haas M, Meehan SM, Karrison TG, & Spargo BH. (1997). Changing etiologies of unexplained adult nephrotic syndrome: A comparison of renal biopsy findings from 1976-1979 and 1995-1997. *Am J Kidney Dis*, Vol. 30, No. 5, pp. 621-31.
- Kazi JI, & Mubarak M. (2009). Collapsing FSGS: a need of awareness. *J Pak Med Assoc*, Vol. 59, No. 8, pp. 583.
- Kazi JI & Mubarak M. (2011). Collapsing glomerulopathy: A novel association with patchy acute cortical necrosis secondary to postpartum hemorrhage in native kidneys. *NDT Plus* (in press).
- Laurinavicius A, Hurwitz S, & Rennke HG. (1999). Collapsing glomerulopathy in HIV and non-HIV patients: a clinicopathological and follow-up study. *Kidney Int*, Vol. 56, No. 6, pp. 2203-13.
- Laurinavicius A, & Rennke HG. (2002). Collapsing glomerulopathy: a new pattern of renal injury. *Semin Diagn Pathol*, Vol. 19, No. 3, pp. 106-15.
- Meehan SM, Pascual M, Williams WW, Tolckoff-Rubin N, Delmonico FL, Cosimi AB, & Colvin RB. (1998). De novo collapsing glomerulopathy in renal allografts. *Transplantation*, Vol. 65, No. 9, pp. 1192-7.
- Meyrier AY. (1999). Collapsing glomerulopathy: expanding interest in a shrinking tuft. *Am J Kidney Dis*, Vol. 33, No. 4, pp. 801-3.

- Mubarak M, & Kazi JI. (2011). Collapsing focal segmental glomerulosclerosis: a morphological lesion in search of identity. *Nephrol Urol Mon* (in press).
- Mubarak M, & Kazi JI. (2010). Collapsing FSGS: a clinicopathologic study of 10 cases from Pakistan. *Clin Exp Nephrol*, Vol. 14, No. 3, pp. 222-7.
- Mubarak M. (2011). Collapsing glomerulopathy in renal allograft biopsies: a study of nine cases. *Indian J Nephrol* (in press).
- Nada R, Kharbanda JK, Bhatti A, Minz RW, Sakhuja V, & Joshi K. (2009). Primary focal segmental glomerulosclerosis in adults: is the Indian cohort different? *Nephrol Dial Transplant*, Vol. 24, No. 12, pp. 3701-7.
- Nadasdy T, Allen C, & Zand MS. (2002). Zonal distribution of glomerular collapse in renal allografts: possible role of vascular changes. *Hum Pathol*, Vol. 33, No. 4, pp. 437-41.
- Schwimmer JA, Markowitz GS, Valeri A, & Appel GB. (2003). Collapsing glomerulopathy. *Sem Nephrol*, Vol. 23, No. 2, pp. 209-18.
- Stirling CM, Mathieson P, Boulton-Jones JM, Feehally J, Jayne D, Murray HM, & Adu D. (2005). Treatment and outcome of adult patients with primary focal segmental glomerulosclerosis in five UK renal units. *Q J Med*, Vol. 98, No. 6, pp. 443-9.
- Stirling CM. (2006). Focal segmental glomerulosclerosis-does treatment work? *Nephron Clin Pract*, Vol. 104, No. 2, pp. c83-84.
- Stokes MB, Davis CL, & Alpers CE. (1999). Collapsing glomerulopathy in renal allografts: a morphological pattern with diverse clinicopathologic associations. *Am J Kidney Dis*, Vol. 33, No. 4, pp. 658-66.
- Swaminathan S, Lager DJ, Qian X, Stegall MD, Larson TS, & Griffin MD. (2006). Collapsing and non-collapsing focal segmental glomerulosclerosis in kidney transplants. *Nephrol Dial Transplant*, Vol. 21, No. 9, pp. 2607-14.
- Thadhani R, Pascual M, Tolkoff-Rubin N, Nickleit V, & Colvin R. (1996). Preliminary description of focal segmental glomerulosclerosis in patients with renovascular disease. *Lancet*, Vol. 347, No. 8996, pp. 231-3.
- Valeri A, Barisoni L, Appel GB, Seigle R, & D'Agati V. (1996). Idiopathic collapsing focal segmental glomerulosclerosis: a clinicopathologic study. *Kidney Int*, Vol. 50, No. 5, pp. 1734-46.
- Weiss MA, Daquiaoag E, Margolin EG, & Pollak VE. (1986). Nephrotic syndrome, progressive irreversible renal failure, and glomerular "collapse." A new clinicopathologic entity? *Am J Kidney Dis*, Vol. 7, No. 1, pp. 20-8.



Topics in Renal Biopsy and Pathology

Edited by Dr. Muhammed Mubarak

ISBN 978-953-51-0477-3

Hard cover, 284 pages

Publisher InTech

Published online 04, April, 2012

Published in print edition April, 2012

There is no dearth of high-quality books on renal biopsy and pathology in the market. These are either single author or multi-author books, written by world authorities in their respective areas, mostly from the developed world. The vast scholarly potential of authors in the developing countries remains underutilized. Most of the books share the classical monotony of the topics or subjects covered in the book. The current book is a unique adventure in that it bears a truly international outlook and incorporates a variety of topics, which make the book a very interesting project. The authors of the present book hail not only from the developed world, but also many developing countries. The authors belong not only to US but also to Europe as well as to Pakistan and Japan. The scientific content of the book is equally varied, spanning the spectrum of technical issues of biopsy procurement, to pathological examination, to individual disease entities, renal graft pathology, pathophysiology of renal disorders, to practice guidelines.

How to reference

In order to correctly reference this scholarly work, feel free to copy and paste the following:

Muhammed Mubarak and Javed I. Kazi (2012). Collapsing Glomerulopathy: The Expanding Etiologic Spectrum of a Shrinking Glomerular Lesion, Topics in Renal Biopsy and Pathology, Dr. Muhammed Mubarak (Ed.), ISBN: 978-953-51-0477-3, InTech, Available from: <http://www.intechopen.com/books/topics-in-renal-biopsy-and-pathology/collapsing-glomerulopathy-the-expanding-etiological-spectrum-of-a-shrinking-glomerular-lesion>

INTECH
open science | open minds

InTech Europe

University Campus STeP Ri
Slavka Krautzeka 83/A
51000 Rijeka, Croatia
Phone: +385 (51) 770 447
Fax: +385 (51) 686 166
www.intechopen.com

InTech China

Unit 405, Office Block, Hotel Equatorial Shanghai
No.65, Yan An Road (West), Shanghai, 200040, China
中国上海市延安西路65号上海国际贵都大饭店办公楼405单元
Phone: +86-21-62489820
Fax: +86-21-62489821

© 2012 The Author(s). Licensee IntechOpen. This is an open access article distributed under the terms of the [Creative Commons Attribution 3.0 License](#), which permits unrestricted use, distribution, and reproduction in any medium, provided the original work is properly cited.

IntechOpen

IntechOpen