

We are IntechOpen, the world's leading publisher of Open Access books Built by scientists, for scientists

5,600

Open access books available

138,000

International authors and editors

175M

Downloads

Our authors are among the

154

Countries delivered to

TOP 1%

most cited scientists

12.2%

Contributors from top 500 universities



WEB OF SCIENCE™

Selection of our books indexed in the Book Citation Index
in Web of Science™ Core Collection (BKCI)

Interested in publishing with us?
Contact book.department@intechopen.com

Numbers displayed above are based on latest data collected.
For more information visit www.intechopen.com



Application of Radiofrequency in Low Back Pain Treatment

Hsi-Kai Tsou and Ting-Hsien Kao

Department of Neurosurgery, Taichung Veterans General Hospital, Taichung, Taiwan, Republic of China

1. Introduction

Chronic low back pain (LBP) has become a main cause of absenteeism and disability in industrialized societies and is a major health problem with enormous economic and costs (Andersson, 1999). As many as 80% of adults experience at least one episode of LBP during their lifetime. Only 5% of patients suffering from chronic LBP can find a specific cause such as disc herniation, spondylolisthesis, discitis or spondylitis. No definite evident causes were found in 95% patients with low back pain (Schwarze et al., 1995a, 1995b).

At present, the treatment of low back pain consists of therapies, both conservative and invasive, that are aimed at symptomatic relief. As the evidence-based medicine developed over the years, there are now much more accumulated data that inform us how to treat patients with chronic LBP. Unfortunately, many of the treatments used today are not strongly effective (Carragee 2005).

1.1 Application of radiofrequency in medicine

Radiofrequency (RF) is a minimally invasive, target-selective technique that has been in clinical use for more than decades and has been demonstrated to be successful for treating cardiac arrhythmias (Baszko et al., 2002), dysplasia (Shahee et al., 2009) and reducing pain in several chronic pain conditions including trigeminal neuralgia, chronic LBP, postherpetic neuralgia, complex regional pain syndrome, ischemic pain, cervicobrachialgia, postthoracotomy pain, occipital neuralgia, and cervical or lumbar radicular pain (Chao et al., 2008; Navani et al., 2006; Racz & Ruiz-Lopez 2006; Zhang et al., 2011). Focusing on pain management, RF can not only reach directly to the source of pain but also modulate the pain signal transmission.

1.2 Principles and mechanisms of radiofrequency

There are two major mechanisms of radiofrequency (RF) treatment: thermal (continuous) RF and non-thermal (pulsed) RF (PRF). Thermal RF caused by continuous current within frequencies between 300 Hz and 300 GHz generates both current and heat on exposed tissues. Since temperatures above 45°C result in nonselective destruction of both myelinated and nonmyelinated nerve fibers (Smith et al., 1981), the thermal RF procedure has limited applications and caused some adverse effects. Unlike continuous RF, PRF generates

intermittent pulsed current which lowers the target tissue temperature to below 45°C and causes different neurobiological effects (Cahana et al., 2003).

For example, a marker for neuronal activity in the dorsal horn, c-Fos, has been reported to be expressed immediately and up to 7 days after PRF treatment in rat models (Higuchi et al., 2002; Van Zundert et al., 2005). The long lasting effect of c-Fos expression was caused by non thermal RF but inhibition of excitatory C-fiber responses was seen in long-term depression (Richebé et al., 2005). Continuous RF creates a longer blockade of synaptic transmission than PRF in an in vitro model even under similar temperature. Both RF and PRF treatments induce distance dependent tissue destruction under the stimulating needle, but the effect was more pronounced in the RF group (Cahana et al., 2003). Moreover, morphological study showed no pathological findings in the control and sham-operated groups, minimal morphological changes in the PRF group, and neuro-destruction in the continuous RF group (Erdine et al., 2005). All these findings together indicate that the use of PRF promises to be a safer, reversible and nondestructive approach to various chronic pain conditions.

2. Application of radiofrequency treatment in low back pain from different origins and mechanisms

Low back pain can originate from several sources, such as discs, ligaments, muscles, and sacroiliac joints, and another cause can be lumbar facet joint degeneration (Deyo & Weinstein 2001). Since all the pain signals were transmitted by nerves, applying treatment targeting the neuronal transmission pathway can reasonably relieve the pain. Here we review the anatomy, possible biomechanical mechanisms, clinical presentation and physical examination findings of different sources of low back pain. The diagnostic tools and image findings are discussed as well.

2.1 Discogenic low back pain

Considering the diagnosis of LBP, pure discogenic pain is thought to be less than 10% (Deyo & Weinstein 2001). However, in chronic persistent LBP patients, intervertebral disc (IVD) degeneration seemed to be the initial step and played the most important role (Carragee 2005). After IVD degeneration, the biomechanical status of the vertebral column changes, and the possibility of facet joint degeneration, spondylosis, spondylolisthesis and spinal stenosis increases as well.

2.1.1 Anatomy and pathogenesis of disc and its degeneration

The IVD is composed of a tough outer ring, the annular fibrosus (AF), a gelatinous inner core, the nucleus pulposus (NP), and the adjacent vertebral endplate (VE). The axial loading force of IVD was support by posterior two facet joints. The healthy IVD is avascular and its nutritional supply depends on diffusion via the AF and VE. Symptomatic degeneration of the IVD is thought to be the leading causes of chronic back pain.

In a normal disc, the NP is devoid of nerve fibers, while the outer AF and VE contain nerve fibers. The nerve supply of the IVD is from branches of sympathetic trunk and sinuvertebral nerves (Fig. 1). The sinuvertebral nerves run ventral to the nerve root, back to the spinal

canal and divide the posterior longitudinal ligament and ventral dural branches. The anterior part of IVD was supplied by branches through the anterior longitudinal ligament which is from the sympathetic trunk. The lateral and ventral aspects of IVD are supplied by branches of rami communicantes (Fig. 1).

Because the IVD was supply by the sympathetic trunk, somatosensory nerves and their communicating network through multiple segments, discogenic back pain is always hard to localize and seemed to be a visceral pain (Bogduk et al., 1981) and RF applying to the target nerves of IVD is much more complicated than other parts of the spinal column (Bogduk et al., 1981; Brown et al., 1997; Edgar 2007).

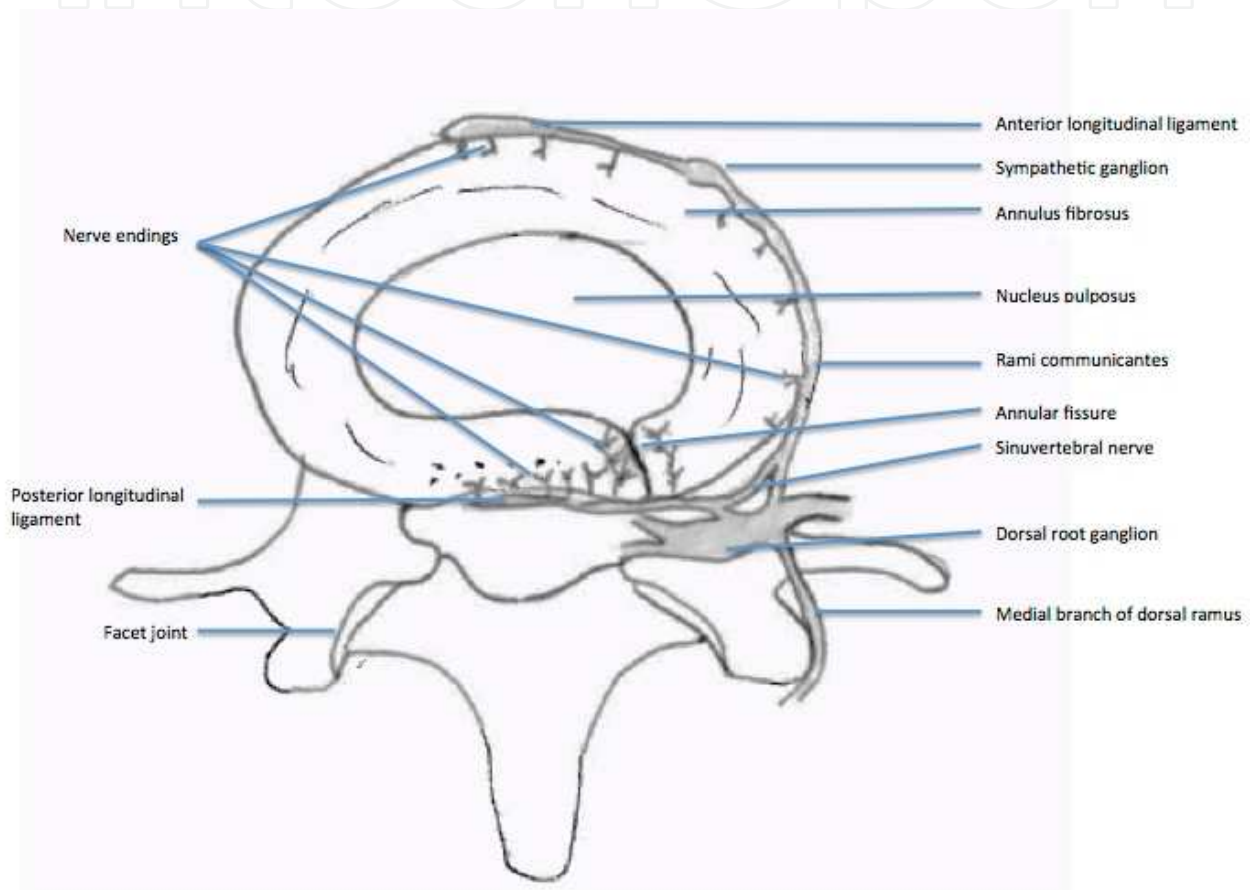


Fig. 1. Schematic illustration of the lumbosacral intervertebral disc innervation.

During IVD degeneration, increase neuronal activity is found in inner NP which is the possible mechanism of painful disc (Freemont et al., 1997; Coppes et al., 1997; Hurri & Karppinen 2004; Peng et al., 2006; Peng et al., 2009; Freemont et al., 2002; Freemont 2009). Nociceptive neuropeptides just like calcitonin gene-related peptide and substance P, which are present within the nerve fibers in the outer AF and dorsal root ganglion (DRG), may likely play a role in discogenic pain transmission (Brown et al., 1997; Ohtori et al., 2002). It is believed that most afferent fibers from the low lumbar discs travel in the sinuvertebral nerve, pass through the ramus communicantes and lumbar sympathetic chain, and finally enter the spinal cord through the L2 ramus communicantes and L2 spinal nerve roots (Nakamura et al., 1996a; 1996b).

Since most nerve fibers that innervate the disc emanate from the sympathetic nervous system (Bogduk et al., 1981; Nakamura et al., 1996a; 1996b), RF targeting discogenic low back pain can reasonably apply through two locations. One is thermal RF lesioning causing nerve fiber destruction within the inner disc and the other is sensory modulation targeting the DRG of L2, the level at which the sympathetic nerve fibers leave the spinal cord.

2.1.2 Clinical presentation, physical examination

There are no typical physical examination findings of painful IVD and most of the findings appear in other types of LBP. Diagnosis of discogenic LBP is based on these non-specific past histories and physical examinations as well as the image study. Generally speaking, most of the discogenic back pain is not localized. It seemed to be visceral pain because of its characteristics and nerve supply (Bogduk et al., 1981). Most patients experience typical features including persistent nociceptive low back (more than six months), groin with or without leg pain which worsens with axial loading or flexion of painful segment, and pain relief when lying down. Moreover, there are nerve roots lying just posteriorly to the disc margin. So some patients with discogenic LBP experience some referred pain. For example, painful IVDs for upper lumbar segment typically cause referred pain to the anterior aspect of thigh and lower lumbar segments and sometimes cause referred pain down to the posterior thigh and leg (Ohnmeiss et al, 1999a; 1999b)

2.1.3 Image diagnosis and discography

Before the development of computed tomography (CT) and magnetic resonance imaging (MRI), discography had been used to diagnose possible disc pathology (Lindblom, 1951). However, it was thought to be obsolete because of its complications and efficacy for diagnosis after the invention of CT and MRI (Walsh et al., 1990). There are many benefits of CT and MRI for disc pathology diagnosis. They provide clear three dimensional images of the spinal column and can be reconstructed to view different aspects. Moreover, some unusual pathology can be found during CT and MRI study combined with contrast enhancement (Maus, 2010).

Considering radiation exposure, MRI seems better than CT except for bony structure evaluation and determination of pre-existing metal material inside the body. T2-weighted sequence MRI can provide detailed information of disc pathology included disc height and morphology change, herniation of nucleus pulposus, spinal canal or neuroforamen stenosis, hydration of disc and with gadolinium enhancement, some inflammation pathology or neogrowth can be detected (Maus, 2010).

However, the clinical symptoms and outcome of disc degeneration cannot be predicted even if MRI can identify signal changes in the discs themselves and surrounding soft tissues (Keller et al., 2011). Moreover, MRI also provides adjacent vertebrae end plate signal change and annular tear which is thought to be strongly associated with discogenic LBP (Carragee & Hannibal 2004; Zhou & Abdi 2006).

Because painful IVD was found to increase neuronal activity in its inner layer (Freemont et al., 1997; Coppes et al., 1997; Freemont et al., 2002), a direct increase in intradiscal pressure may cause more pain. Besides, during degeneration or trauma, the tough annular ring AF

becomes weaker and then tears as fissure formation. When the intradiscal pressure increases, the force is transferred to the outer area of AF through the fissure which is always located in the posterior part of the disc and causes pain; so, provocative discography is thought to be useful to find the “exact” pain source. In summary, discography provokes pain through the following mechanisms: 1) Increase in intradiscal pressure during the injection of contrast material. Mechanical stretching of the annular fibers of the painful disc may stimulate the overgrowth of nerve endings. 2) Chemical irritation of the surrounding nerve endings within the disc.

The interpretation of discogram findings includes the degree of pain generation during the procedure in each disc, and the appearance of contrast medium in the disc. Sachs et al. described the Dallas grading system using the CT discogram appearance (Sachs et al., 1987). The 'Modified Dallas Discogram Description' was finalized in the 1990's and is the 'Gold Standard' for the CT classification of annular tears (Fig. 2). Based on their article, they divided the CT discogram finding into six degrees: Grade 0: the contrast medium within the inner NP margin. Grade 1 to grade 3 indicates the contrast medium leaking to inner, middle, or outer layer of AF. Grade 4 indicates the circumferential spread greater than 30 degrees. Grade 5 tear describes either a grade 3 or grade 4 radial tear that has completely ruptured the outer layers of the disc and is 'leaking' contrast medium from the disc into the epidural space (Fig. 2).

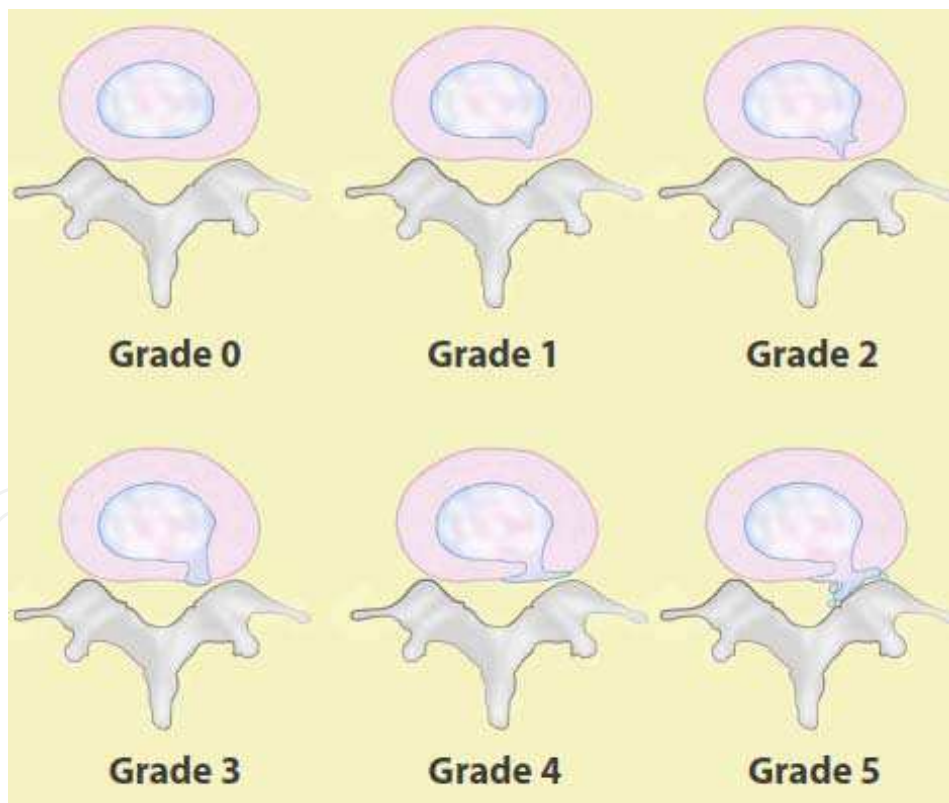


Fig. 2. The Modified Dallas Discogram

The degree of pain mainly depends on the Numeric Rating Scale (NRS), the reproduction of concordant pain and comparison of normal adjacent discs. According to the guidelines of the International Association for the Study of Pain (IASP) and the International Spine

Intervention Society (ISIS), they suggest at least two adjacent levels should be tested as controls during the provocative discography procedures. The criteria of discogenic pain is listed in table 1 (Kallewaard et al., 2010). However, because the discography is done without direct visualization of the disc structure and multiple combined pathologies of the lower back in most of the patients suffering from chronic LBP, the diagnosis made by provocative discography is controversial (Wichman, 2007). Wichman summarized three reasons causing controversy about discography for the diagnosis of discogenic LBP, namely, techniques, the disc pathology itself and symptom interpretation (Wichman, 2007).

Diagnosis	Diagnostic criteria
Absolute discogenic pain	Reproduce concordant pain in diseased level during procedures NRS at least 7 The pain develops less than 15 psi above the opening pressure Stimulation of the two adjacent discs is not painful
Highly probable discogenic pain	Reproduce concordant pain in diseased level during procedures NRS at least 7 The pain develops less than 15 psi above the opening pressure Stimulation of the one of the adjacent discs is not painful
Discogenic pain	Reproduce concordant pain in diseased level during procedures NRS at least 7 The pain develops less than 50 psi above the opening pressure Stimulation of the two adjacent discs is not painful
Possible discogenic pain	Reproduce concordant pain in diseased level during procedures NRS at least 7 The pain develops less than 50 psi above the opening pressure Stimulation of the one of the adjacent discs is not painful, and stimulation of another disc is painful at a pressure greater than 50 psi above the opening pressure, and the pain is discordant

(summary from the article by Kallewaard et al., 2010)

Table 1. Diagnostic criteria of discogenic pain by discography

2.1.4 Treatment choices of radiofrequency applying to discogenic low back pain

RF applying to the disc itself included transdiscal biacuplasty (Baylis Medical Inc., Montreal, Canada), intradiscal electrothermal therapy (IDET) with spinecath (OratecInterventions, Inc., Menlo Park, CA) and discrode (Radionics RFG-3C,Valleylab, Tyco Healthcare Group LP 5920 Longbow Drive, Boulder, Colorado 80301-3299 USA) (Karasek & Bogduk 2000; Saal JA & Saal JS, 2000, 2002; Davis et al., 2004; Kapural & Mekhail 2006; Andersson et al., 2006; Kvarstein et al., 2009; Tsou et al., 2010). The spinecath and discrode are flexible catheters with a distal thermocoil. When it is introduced into the annulus, the distal part should ideally be along the internal aspect of the posterior annulus. Local denervation effect is caused by heating of the distal portion of the catheter. The other two major mechanisms of IDET are intradiscal pressure reduction and enhancement of the annular healing process (Saal JA & Saal JS, 2000). However, two prospective studies have shown the opposite efficacy results using IDET for discogenic LBP patients (Pauza et al., 2004; Freeman et al., 2005). There are limited prospective studies mentioning transdiscal RF annuloplasty and their effects are uncertain (Helm et al., 2009).

The other choice of the RF target for discogenic LBP is the L2 DRG, which is based on the natural history of discogenic LBP and was not easily confirmed. With regard to discogenic pain, Nakamura et al. proposed that the main afferent pathway of pain from the lower intervertebral discs is through the L2 spinal nerve root, presumably via sympathetic afferents from the sinuvertebral nerve (Helm et al., 2009). Therefore, discogenic pain should be regarded as visceral pain due to its neural pathway. Nakamura et al. believe that the nerve fibers in the sinuvertebral nerve originate from the rami communicans of the sympathetic nerves (Nakamura et al., 1996b). RF lesioning to cervical DRG has been proved effective in a select group of patients with cervical brachialgia (van Kleef et al., 1996; Van Boxem et al., 2011). However, because of the side effects and possible complications of neuropathic pain, PRF was applied to cervical DRG treatment. In contrast, DRG lesioning for lumbosacral radicular pain was thought to be less effective (Geurts et al., 2003). Since the DRG of L2 was thought to be the main trunk of the lower back sensory afferent pathway, some clinical retrospective studies of PRF showed effectiveness for chronic LBP with highly suspect disc origins or unspecific LBP with or without radicular pain (Tsou et al., 2010; Nagda et al., 2011).

2.2 Neurogenic low back pain

Spinal nerves are protected in the spinal canal before they penetrate out of the neuroforamen. However, during the degeneration and aging process, the bony structure and soft tissue such as ligaments surrounding the nerves see hypertrophic change which possibly compromises the neuronal structure including nerve roots and their low back branches. Most patients with spondylosis, spinal stenosis and spondylolisthesis with or without radicular symptoms suffer from symptoms of back pain (Singh et al., 2005). Before the radicular symptoms are displayed, the narrowing canals compress the nerves and more or less cause local inflammatory and mechanical mechanism of back pain. Singh et al. divided two groups of patients with spinal stenosis; one group was congenital and young, while the other was degenerated and elderly. Since the pain is possibly from inflammation or mechanical stress directed to the nerves, neuronal modulation or temporary blocks are suitable for those without severe spinal stenosis or not suitable for surgical intervention. The clinical presentation of neurogenic LBP always combined both low back symptoms and neurogenic claudication with or without radicular pain (Singh et al., 2005). Diagnosis of neurogenic LBP depends on clinical presentation and dynamic lateral lumbar X ray imaging. Pedicle width narrowing and neuroforamen compromise can be seen on CT or MRI. The treatment choices for neurogenic pain before shifting to surgery includes epidural neuroforamen steroid injection (Benny & Azari 2011) selective nerve block (Thackeray et al., 2010) and RF for adjacent DRG (Van Boxem et al., 2011).

2.3 Low back pain from facet joint arthritis or degeneration (anatomy and biomechanics, clinical presentation and physical examination, diagnostic imaging)

2.3.1 Anatomy and pathogenesis of facet joints pain

Each vertebra has two sets of facet joints. One pair faces upward (superior articular facet) and one downward (inferior articular facet). The joint surfaces are coated with cartilage allowing joints to move smoothly against each other. These joints allow flexion (bend forward), extension (bend backward), and twisting motion. Since these joints are just like

other joints in the whole body, and they share axial loading with IVD, they can be affected by degeneration and arthritis. Facet joints have been implicated as a cause of chronic spinal pain in 15% to 40% of patients with chronic low back pain (Schwarzer et al., 1995a; 1995b). They are innervated by medial branches of dorsal rami from the spinal nerves (Fig. 3) and theoretically, facet joint pain can be treated by denervation of the medial branches of the dorsal rami, which supply the sensory innervation of the joints (Shealy, 1976; Bogduk & Long, 1980; Dreyfuss et al., 2000).

The lumbar facet syndrome was first described by Ghormley in 1933 (Ghormley, 1933). After detailed anatomical study of the lumbar zygapophysial nerve supply by Bogduk and Long in 1979 (Bogduk & Long 1979), several control studies showed initial benefits for pain relief by radiofrequency medial branch neurotomy (Dreyfuss et al., 2000; van Kleef et al., 1999). There are several diseases that contribute to facet joint disease, including degeneration, synovial cysts, ankylosing spondylitis, and trauma. A controlled trial has shown that RF medial branch neurectomy is not a placebo (van Kleef et al., 1999) and an observational study has shown that, provided patients are carefully selected using controlled diagnostic blocks, and provided a correct surgical technique is used, some 60% of patients can expect at least 80% relief of their pain at 12 months, and 80% of patients can expect at least 60% relief (Dreyfuss et al., 2000).

The nerve supply of the facet joint originates from two levels (Fig. 3); one branch of the primary ramus arises from the nerve root at the same level as the joint and another branch from the level above. Therefore therapeutic injection of the facet joint should include the joint above the suspected level (Lynch & Taylor 1986). In the lumbar region, the medial branch of the posterior ramus lies in a groove on the base of the superior articular facet, where it lies in direct contact with the base of the superior surface of the transverse process, passing between the mammillary and accessory processes. The nerve actually passes under the mamilloaccessory ligament, and this is the most reliable site for locating the nerve in

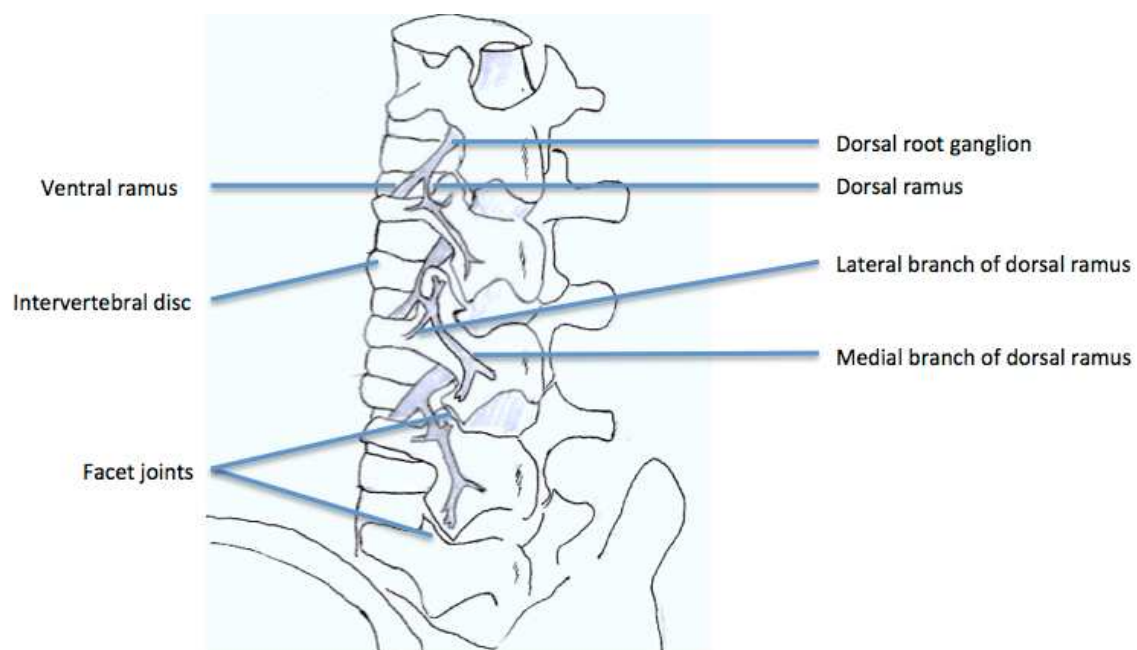


Fig. 3. The branches of lumbar roots

the lumbar spine. Studies support the idea that RF denervation is a treatment of choice for initial pain relief; however, it does not produce permanent pain relief because the nerve eventually regenerates, usually within 12-18 months (North et al., 1994). Lord et al. found the median time of return to 50% of pre-procedure pain was 263 days (Lord et al., 1996). Dreyfuss et al. found that pain relief may last for about 12 months (Dreyfuss et al., 2000). So, repeated treatment may be necessary in some patients.

2.3.2 Clinical presentation and physical examination of lumbar facet syndrome

Like other types of LBP, pain from facet joint arthritis or degeneration is always related to other pathologies. So there is no specific clinical presentation or physical examination finding for lumbar facet syndrome. Because the lumbar facet joints are like other synovial joints, the pain related to arthritis causes local tenderness of affected joints. All of the lumbar facet joints are capable of producing some referred pain. Pain emanating from the upper facet joints tends to extend into the flank, hip, and upper lateral thigh, whereas pain from the lower facet joints is likely to penetrate deeper into the thigh, usually laterally and/or posteriorly. Infrequently, the L4-L5 and L5-S1 facet joints can provoke pain extending into the lower lateral leg and, in rare instances, even the foot (Cohen & Raja 2007).

2.3.3 Image diagnosis and diagnostic block

Lumbar facets hypertrophy, joint interface widening, adjacent neuroforamen and spinal canal narrowing are easily seen in CT and MRI studies. However, the clinical symptoms and image findings often show no correlation (van Kleef et al., 2010). Diagnostic blocks using local anesthetics are performed either in the joint space or medial branch nerve region. However, both are associated with significant false-positive and false-negative rates (Cohen & Raja 2007). Technically, half way between the upper edge of the transverse process and the ligamentum mammilloaccessorium was suggested by Dreyfuss et al. because the infiltration of the anesthetic agent will influence the proximal segmental nerves and caused false-positive results (Dreyfuss et al., 1997). Because the double block causes a high false-negative rate, it was not recommended for use right now (Bogduk & Holmes 2000).

2.4 Sacroiliac joint pain (anatomy and biomechanics, clinical presentation and physical examination, diagnostic imaging, intraarticular diagnostic block)

Sacroiliac joint (SIJ) pain was believed one of the causes of chronic LBP and single anesthetic and steroid injection has proved 35% effectiveness in patients who underwent failed fusion surgery (van Kleef et al., 2010). The prevalence of SIJ pain is from 16-44% depending on different diagnostic tools (Cohen 2005). Since this kind of pathology can be treated as a single block or minimally invasive procedure, data for SIJ pain have accumulated in recent years. RF applying to SIJ is to block the nerve fibers to the SIJ. The treatment efficacy, possible mechanisms and techniques will be discussed later.

2.4.1 Anatomy and biomechanics

The SIJ is one of the origins of chronic low back pain that has always been neglected (Maigne & Planchon 2005). It is the largest axial joint in the body, with an average surface

area of 17.5 cm² (Cohen 2005). The anterior third of the intersurface between the sacrum and the ilium is the true synovial joint and the rest of the junction is comprised of a strong and complicated ligamentous network. The ligamentous network of women is weaker which allows motility for parturition. Like other true synovial joints, age-related change, degeneration or arthritis developed on the cartilage surface of the SIJ. Each SIJ is composed of the true synovial joint and part of the ligamentous network.

The pain sources from SIJ can be divided into two parts, one is intra-articular and the other is extra-articular. The intra-articular SIJ pain may be due to the degenerative process of the articular cartilage and chronic arthritis, or autoimmune arthritis. Cohen reviewed the SIJ pathology and summarized some risk factors, including leg length discrepancy, gait abnormality, prolonged vigorous exercise, scoliosis, and spinal fusion to sacrum. (Cohen 2005) The other pain origin of SIJ is extra-articular structures such as ligaments weakening and muscle trauma and inflammation and hypermobility of SIJ caused by iatrogenic trauma. The innervation of the SIJ is divided into two parts, anterior and posterior. The posterior nerve supply to the SIJ comes from the lateral branches of the L4-S3 dorsal rami and the anterior innervation of SIJ is from the ventral rami of L4-S2 (Cohen 2005).

2.4.2 Clinical presentation, physical examination and diagnostic imaging

Since SIJ pain could be caused by either intra-articular or extra-articular structures, the diagnosis of SIJ pain is more complicated. Except for the risk factors in the medical history, physical examinations which involve the distraction of these joints can be helpful; for example, Patrick's test and Gaenslen's test. However, inconsistent predictable values were found in both physical examinations and medical history. Radiological studies showed the diagnosis of SIJ pathology is not correlated to the clinical presentation.

2.4.3 Diagnostic block of sacroiliac joint pain

Intraarticular anesthetics injection (diagnostic block) of SIJ can reasonably relieve the pain from SIJs. However, there are limited data supporting the diagnostic tool that strongly reflects the real pathology. Besides, the SIJ is technically difficult to approach even by a good experienced pain physician. The local anesthetics leakage to surrounding structures may cause false-positive results. Even with the CT-guided injection method, there is less than a 30% accomplishment rate for adequate injection (Rosenberg et al., 2000). According to these findings, diagnostic SIJ block is not reliable to diagnose true SIJ pain.

2.5 Low back pain combined with radicular pain (anatomy and biomechanics, clinical presentation and physical examination, diagnostic imaging, epidural nerve block)

Before the development of PRF (non-thermal), RF has been used directly targeting neural tissue, including movement disorders (Carr 1971; Cala et al., 1976), cardiac arrhythmias (Baszko et al., 2002), trigeminal neuralgia, and cervical and lumbar radicular pain, and the treatment target is the reflecting DRG (van Kleef et al., 1996). After PRF was developed, it was used more and more because of a lower complication rate (Chua et al., 2010). Although lacking good randomized control studies, RF or PRF applying to adjacent DRG of low back or radicular pain can still be used for selected patients before moving to surgical treatment.

2.5.1 Anatomy and biomechanics

The mechanisms of lumbosacral radicular (LSR) pain can be mainly divided into two possibilities. The first one is mechanical compromise and the other is chemical irritation of adjacent nerve roots. It is difficult to make a clear distinction between them. The mechanical compromise of nerve roots can cause local inflammatory cytokines up-regulation and the chemical irritation of nerve structure can cause nerve swelling and further compromise (Yang et al., 2011). Sometimes, either decompression or epidural steroid injection alone fails to relieve the clinical symptoms of LBP and LSR pain. Blocking or modulation of nerve transmission after inflammation and mechanical vicious circle calm down seems like an alternative treatment.

2.5.2 Clinical presentation and physical examination

LBP with LSR pain are common combined situations in clinical practice. There are two reasons which could explain this. First, the lumbosacral plexus is complicated and the branches from the surrounding structure of the spinal column often cause multiple segments pathology of the lower lumbar and sacral spine. Second, the mechanical compression of the spinal canal also frequently compromises the adjacent DRG or nerve roots which cause the dual symptoms. The clinical presentation of these patients is not easy to differentiate from other pathologies. Generally speaking, compromise of the neuronal structure causes neurologic dermatomes sensory impairment, motor weakness and neurogenic claudication. Physical examinations should be carefully taken, including neurologic signs.

2.5.3 Epidural steroid injection and diagnostic imaging

X-ray studies should be taken in chronic LBP and LSR pain patients including standard anteroposterior and lateral aspects. Dynamic flexion extension lateral film is required to differentiate the possibilities of spondylolisthesis, congenital lumbar stenosis, scoliosis and some unusual osteolytic lesions. A three dimensional view can be seen in CT and MRI studies. CT has benefits of more clear bony structures, including neuroforamens. MRI provides clear information of the spinal canal, nerve roots and disc herniation as well as unusual neogrowth or infectious diseases.

Selective adjacent epidural steroid injection calms down the inflammation process and nerve swelling in both mechanical and chemical irritation. Benny reviewed the efficacy of epidural injection and concluded that there was strong evidence for transforaminal injections in the treatment of LSR pain for both short term and long term relief (Benny & Azari 2011). Once the epidural injection works for pain relief of these patients, repeated injection was suggested if it recurs. Injection at least three times was suggested before shifting to more invasive procedures. RF or PRF for selective DRG treatment should be considered if the result of epidural injection is only temporary.

3. Procedures

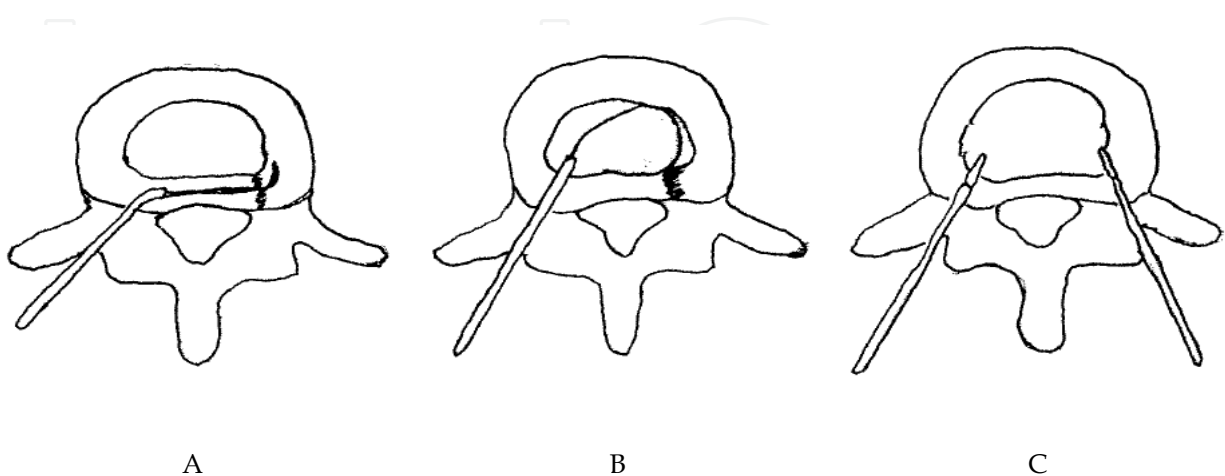
3.1 Radiofrequency for intradiscal thermotherapy (evidence of hypothesis, indication, effect of procedure)

The intradiscal electrothermal therapy (IDET) is based on the mechanisms of AF tear healing and could be enhanced by thermal effect. The intradiscal volume and pressure decrease as

well. Biologic study showed there are several types of radiofrequency intradiscal thermoplasty including spinecath (Oratec Interventions, Inc., Menlo Park, CA), discrode, transdiscal biacuplasty (Fig. 4). The IDET procedures of spinecath and discrode use a navigable intradiscal catheter with a thermal resistive coil. The procedure was performed under local anesthesia with lidocaine. All catheter placements are under fluoroscopy guidance. Preoperative administration of intravenous antibiotics two hours before the procedure is suggested.

In spinecath, the operator uses a 30-cm catheter with a 5-cm active electrothermal tip inserted anteriorly into the annulus or nucleus via a 17-gauge introducer. The active tip was advanced anterior-laterally inside the nuclear tissue and directed circuitously to return posteriorly, providing an ideal position to heat the entire posterior annulus. Once a satisfactory position was obtained in the anteroposterior, lateral views, the catheter was connected to a lead and passed to an independent technician. In all cases, the catheter tips were within 5 mm of the posterior vertebral margin upon review of saved fluoroscopic films. The discrode was designed with a different approach which let the catheter directly pass through the posterior part of AF. The temperature during IDET begins at 65°C and was increased incrementally by 1°C every 30 seconds to achieve a final temperature of 90°C. The final temperature was maintained for 4 minutes, giving a total treatment time of 16.5 minutes.

The procedures of transdiscal biacuplasty include two RF electrodes. The symptomatic disc was reached in oblique position after cutaneous-subcutaneous anesthesia using lidocaine 1%. To facilitate the intervention, first both posterolateral parts of the disc were bilaterally accessed by 17 G introducer needle (Baylis Medical Inc., Montreal, Canada). Then, two RF probes (Baylis Medical Inc., Montreal, Canada) specially designed for cooled RF practice, wherein closed circuit sterile water circulates, were fitted into the disc after they were passed through the introducers. To ensure that the probe tip was at optimal depth in the posterior annulus, the location of the probe in the tissue was controlled in the lateral and AP positions, with the radiopaque band at its tip taken as reference. The temperature = 45°C, Ramp Rate = 2.0°C/min, Time = 15 minutes.



A: Discrode; B: Spinecath; C: Transdiscal biacuplasty

Fig. 4. Different approach for RF intradiscal thermotherapy

3.2 Pulsed radiofrequency for L2 dorsal root ganglion for discogenic low back pain and other lumbar dorsal root ganglion for neurogenic low back pain

The PRF application procedure for L2 DRG was carried out with the patient in the prone position. The skin over the operative area was sterilized and then infiltrated with 2%

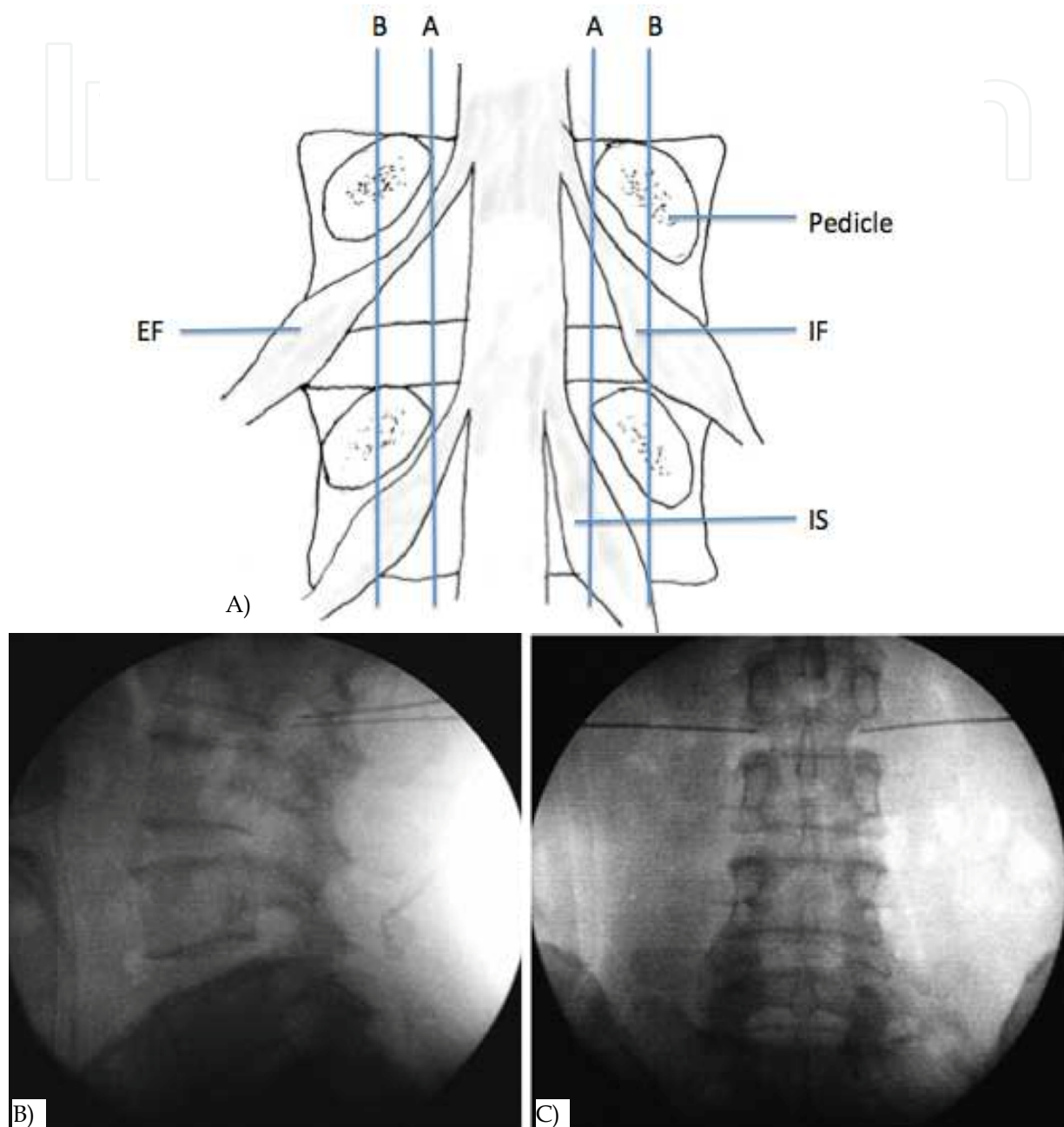


Fig. 5. DRG anatomy and ideal RF needle tips position landmark on fluoroscopy
 A: Positions of dorsal root ganglia (DRG) were determined by two schematic lines and classified into three types. Line A: aligning the medial borders of L4 and L5 pedicles, Line B: aligning the centers of L4 and L5 pedicles, Intraspinous type (IS) : DRG located proximal to line A, Intraforaminal type (IF) : DRG located between line A and B, Extraforaminal type (EF) : DRG located distal to line B. B & C: Lateral (B) and anteroposterior (C) radiographs showing ideal RF needle tips position of L2 DRG.

lidocaine solution. Under C-arm fluoroscopic guidance, a 10-cm 22-gauge carved tip cannula with a 1-cm active tip electrode was placed toward the DRG near the intervertebral foramen. A RF generator was used. The RF electrode was positioned when sensory stimulation (50 Hz) reproduced the patient's pain at less than 0.5 V, which indicated the location of the ganglion. The aim was to produce a tingling sensation in the dermatomal distribution of the nerve in question (Tsou et al., 2010).

Because the DRG location has been studied, the authors divided three types of location according to the DRG and pedicle relationship (Moon et al., 2010) (Fig. 5A). The needle was advanced deeper into the intervertebral foramen until the patient felt a tingling sensation (Tsou et al., 2010) (Fig. 5B & 5C). Then 2-Hz PRF waves were applied for 120 seconds at 45 V while making sure that the electrode tip temperature did not exceed 42°C. The DRG near the intervertebral foramen of L2 root was targeted for discogenic LBP and other levels according to the radicular pain or evidence of compression noted on MRI. Motor function testing is usually not necessary with PRF because there is no risk of motor root damage with this procedure.

3.3 Radiofrequency in medial branch block for facet joint pain

The patient is placed in prone position on the radiolucent table. The anatomical landmarks of the spinal structures reflected on the skin are marked under fluoroscopic guidance including midline and facet joints and transverse processes. The skin is then sterilized in the standard fashion. Local anesthesia with 2% lidocaine was injected into the subcutaneous tissue but not extended. Then a 10-cm, 22-gauge cannula with a 5-mm exposed tip was introduced percutaneously under fluoroscopic guidance to the medial branch of the distal portion of the spinal posterior rami nerve. The tip depth and site were adjusted according to the sensation similar to the clinical presentation. The point is the most sensitive area of soreness, numbness, heaviness and distention using the techniques of twirling, rotating the tip around the lesions. Then stimulation at 5 Hz with 0.5 msec pulse duration was used to confirm the nerve position. The temperature of the electrode tip was then raised to 80°C for 90 seconds.

The nerve supply of the facet joint originates from two levels. One branch of the primary ramus arises from the nerve root at the same level as the joint and another branch from the level above. Therefore therapeutic injection of the facet joint should include the joint above the suspected level (Lynch and Taylor, 1986). For example, the facet joint between the L4 and L5 vertebral bodies is innervated by the medial branch nerves from the L3 and L4 nerve roots. In the lumbar region, the medial branch of the posterior ramus lies in a groove on the base of the superior articular facet, where it lies in direct contact with the base of the superior surface of transverse process, passing between the mammillary and accessory processes. The nerve actually passes under mammilloaccessory ligament, and this is the most reliable site for locating the nerve in lumbar spine. The L5-S1 facet joint is innervated by three nerves, L4, L5, and S1.

3.4 Radiofrequency for sacroiliac joint pain

RF for sacroiliac joint (SIJ) pain is to lesion the possible afferent nerve from SIJs. All procedures can be done in an outpatient setting using local anesthesia. Inclusion criteria

includes axial low back or buttock pain ≥ 6 months in duration with tenderness overlying the SIJ(s); failure to respond to conservative therapy (e.g. physical therapy and pharmacotherapy), including long-term (>2 months) pain relief with SIJ corticosteroid injections; and $\geq 75\%$ pain relief as calculated from a 6-hour post-block pain diary following a single diagnostic SIJ injection (Cohen & Abdi 2003; Cohen et al., 2008). At each level, placement of the electrode in close proximity to the nerve was confirmed using electrostimulation at 50 Hz, with concordant sensation achieved at ≤ 0.5 V. Prior to lesioning, the absence of leg contractions was verified with stimulation at 2 Hz up to 2 V. After satisfactory electrode placement, 0.5 ml of lidocaine 2% was injected through each cannula to reduce thermal pain and ensure blinding. The RF probe was then reinserted and a 90-second, 80°C lesion was made using a RF generator set to the lowest audible volume to blend in with ambient noise. For S1-3 lateral branch procedures, the RF needle targeting points illustrated on Fig. 6. To ensure that anesthetic spread to adjacent foramina did not impede sensory testing, electrodes were placed and stimulated at contiguous levels before denervation commenced. Once the needles were properly positioned, monopolar electrodes were sequentially inserted into the cannulae and 2.5-minute lesions were made using a water-cooled RF heating system (Pain Management Sinergy System, Baylis Medical) and generator (PMG-115-TD, V2.0A, Baylis Medical). Using cooling-probe technology, the tissue temperature immediately adjacent to the cooled electrode was maintained at 60°C , while the target tissue was heated to 75°C , resulting in a lesion diameter ranging between 8 and 10 mm (Fig. 6). For safety reasons, this aggressive lesioning precludes using cooling probe technology for lumbar primary dorsal rami.

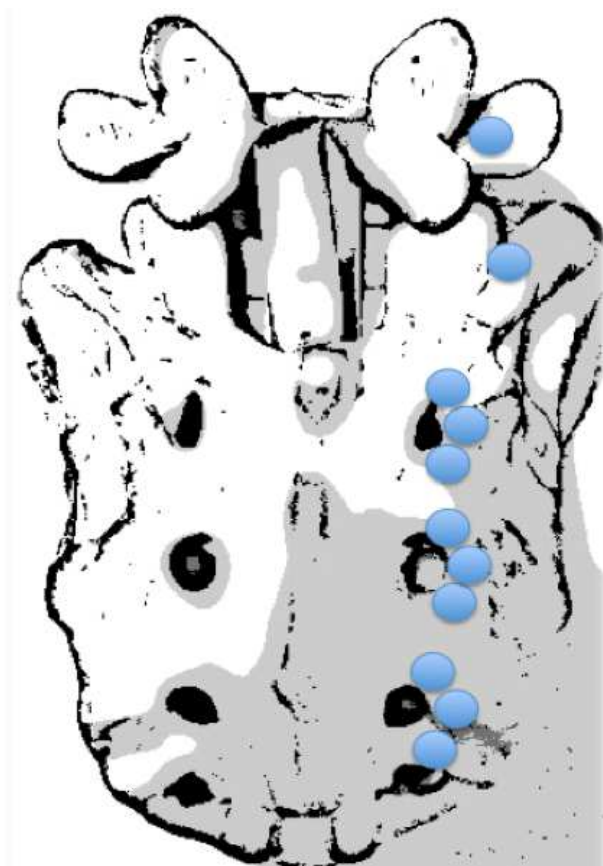


Fig. 6. The RF needle targeting points for sacroiliac joint pain

4. Evidence base medicine of radiofrequency application for low back pain

4.1 Intradiscal radiofrequency annuloplasty for discogenic low back pain

Among three major intradiscal RF annuloplasty procedures, IDET with spinecath was most commonly used and well-studied (Freeman et al., 2005; Pauza et al., 2004). Although the first results showed 50-70% efficacy, however, different opinions were noted in two randomized control trials and various positive and negative studies. In fact, no one will argue that the outcome is worse in severe degenerative disc disease and multi-segment degeneration. The evidence of transdiscal biacuplasty and discrode is lacking. Both need prospective control trials to prove their efficacy.

4.2 Medial branches radiofrequency for low back pain from facet joints

Van Boxem et al. reviewed five recent randomized trials on the efficacy of RF facet denervation for chronic LBP. Three of them are positive, one is negative and one is equivocal (van Boxem et al., 2008). Among all the applications of RF and PRF, cervical facet and lumbar facet syndrome are most evidently effective. Although most of the symptom relief period is limited, these minimal invasive and safe procedures are worth using to treat selected patients with LBP from facet origins.

4.3 Radiofrequency for low back pain from sacroiliac joints

The diagnosis of SIJ-related LBP is difficult and there are still limited clinical studies supporting the efficacy of RF procedures in the treatment of SIJ pain. The treatment of SIJ intraarticular steroid injection is promising. Before a good prospective controlled study proves its efficacy, RF procedure applying to SIJ pain should be used as a second line procedure (Cohen 2005).

4.4 Radiofrequency for lumbar dorsal root ganglion in low back pain combined with or without lumbosacral radicular pain

Most prospective controlled trials for RF applying to DRGs are small or limited by inadequate study design or relative short term follow up (Malik & Benzon 2008). However, the best evidence trial of RF for DRG in treatment of LSR pain showed negative results (Geurts et al., 2003) Even if there are some retrospective studies with positive efficacy, a well-designed, randomized controlled trial is necessary.

5. Complication and management

The possible complications of RF denervation include bleeding, infection, nerve damage, broken electrodes and post-denervation neuritis. However, the complication rate is relatively lower than other more invasive procedures. And even though there are some case reports which mention permanent nerve damage (Abbott et al., 2007), the incidence decreases with the use of PRF, which is a less destructive procedure.

There are different considerations of IDET procedures even the complications are infrequent. One retrospective study review the complications of 1675 IDET procedures, six nerve injuries and six post-IDET disc herniation were reported. Other complications

includes catheter breakage, temporary bladder dysfunction. Furthermore, the intradiscal heat may cause endplate injury and accelerate disc degeneration (Derby et al., 2008).

6. Conclusion

Chronic low back pain is a complicated situation that influences most members of the population at sometime during their lifetime. There are numerous of treatment modalities developed according to the diagnosis of different pathologies including non-invasive treatment and surgical intervention. Because chronic low back pain diagnosis is difficult, and the cause is multi-factorial, most treatment results for chronic LBP are unexpected. RF is a less invasive procedure that targets the pain transmission route. It can be applied reasonably to all pain problems. The evidence for the efficacy of RF for different kinds of etiologies causing chronic LBP is accumulating. Although there are some negative results and weak evidence of its efficacy, RF is still a treatment of choice because of low risk.

7. References

- Abbott, Z., Smuck, M., Haig, A., & Sagher, O. (2007). Irreversible spinal nerve injury from dorsal ramus radiofrequency neurotomy: a case report. *Archives of Physical Medicine and Rehabilitation*, Vol. 88, No. 10, pp. 1350-1352. ISSN 0003-9993
- Andersson, G. B. (1999). Epidemiological features of chronic low-back pain. *Lancet*, Vol. 354, No. 9178, pp. 581-585. ISSN 0410-6736
- Andersson, G. B. , Mekhail, N. A., & Block, J. E. (2006). A randomized, double-blind, controlled trial: intradiscal electrothermal therapy versus placebo for the treatment of chronic discogenic low back pain. *Spine*, Vol. 31, No. 14, pp 1637-1638. ISSN 1528-1159
- Baszko, A., Rinaldi, C. A., Simon, R. D. B., & Gill, J. S. (2002). Atrial fibrillation current and future treatments: radiofrequency ablation and novel pacing techniques. *International Journal of Clinical Practice*, Vol. 56, No 5., pp. 370-376. ISSN 1368-5031
- Benny, B., & Azari, P. (2011). The efficacy of lumbosacral transforaminal epidural steroid injections: a comprehensive literature review. *Journal of Back and Musculoskeletal Rehabilitation*, Vol. 24, No. 2, pp. 67-76. ISSN 1878-6324
- Bogduk, N, & Holmes, S. (2000). Controlled zygapophysial joint blocks: the travesty of cost-effectiveness. *Pain Medicine*, Vol. 1, No. 1, pp. 24-34. ISSN 1526-2375
- Bogduk, N, & Long, D. M. (1979). The anatomy of the so-called "articular nerves" and their relationship to facet denervation in the treatment of low-back pain. *Journal of Neurosurgery*, Vol. 51, No. 2, pp. 172-177. ISSN 0022-3085
- Bogduk, N, & Long, D. M. (1980). Percutaneous lumbar medial branch neurotomy: a modification of facet denervation. *Spine*, Vol. 5, No. 2, pp. 193-200. ISSN 0362-2436
- Bogduk, N, Tynan, W., & Wilson, A. S. (1981). The nerve supply to the human lumbar intervertebral discs. *Journal of Anatomy*, Vol. 132, No. 1, 39-56. ISSN 0021-8782
- Brown, M. F., Hukkanen, M. V., McCarthy, I. D., Redfern, D. R., Batten, J. J., Crock, H. V., Hughes, S. P. F., Polak, J. M., (1997). Sensory and sympathetic innervation of the vertebral endplate in patients with degenerative disc disease. *The Journal of Bone and Joint Surgery British*, Vol. 79, No.1, pp. 147-153. ISSN 0301-620X
- Cahana, A., Vutskits, L., & Muller, D. (2003). Acute differential modulation of synaptic transmission and cell survival during exposure to pulsed and continuous


- radiofrequency energy. *The Journal of Pain*, Vol. 4, No. 4, pp. 197-202. ISSN 1526-5900
- Cala, L. A., Mastaglia, F. L., & Vaughan, R. J. (1976). Localisation of stereotactic radiofrequency thalamic lesions by computerised axial tomography. *Lancet*, Vol. 2, No. 7995, pp. 1133-1134. ISSN 0140-6736
- Carr, E. M. (1971). Chronically implantable radiofrequency electrode for lesion production. Technical note. *Journal of Neurosurgery*, Vol. 35, No. 4, pp. 495-497. ISSN 0022-3085
- Carragee, E. J. (2005). Clinical practice. Persistent low back pain. *The New England Journal of Medicine*, Vol. 352, No. 18, pp. 1891-1898. ISSN 1533-4406
- Carragee, E. J., & Hannibal, M. (2004). Diagnostic evaluation of low back pain. *The Orthopedic Clinics of North America*, Vol. 35, No. 1, pp. 7-16. ISSN 0030-5898
- Chao, S.-C., Lee, H.-T., Kao, T.-H., Yang, M.-Y., Tsuei, Y.-S., Shen, C.-C., & Tsou, H.-K. (2008). Percutaneous pulsed radiofrequency in the treatment of cervical and lumbar radicular pain. *Surgical Neurology*, Vol. 70, No. 1, pp. 59-65. ISSN 0090-3019
- Chua, N. H. L., Vissers, K. C., & Sluiter, M. E. (2010). Pulsed radiofrequency treatment in interventional pain management: mechanisms and potential indications – a review. *Acta Neurochirurgica*, Vol. 153, No. 4, pp. 763-771. ISSN 0942-0940
- Cohen, S. P. (2005). Sacroiliac joint pain: a comprehensive review of anatomy, diagnosis, and treatment. *Anesthesia and Analgesia*, Vol. 101, No. 5, pp. 1440-1453. ISSN 0003-2999
- Cohen, S. P., & Abdi, S. (2003). Lateral branch blocks as a treatment for sacroiliac joint pain: A pilot study. *Regional Anesthesia and Pain Medicine*, Vol. 28, No. 2, pp. 113-119. ISSN 1098-7339
- Cohen, S. P., & Raja, S. N. (2007). Pathogenesis, diagnosis, and treatment of lumbar zygapophysial (facet) joint pain. *Anesthesiology*, Vol. 106, No. 3, pp. 591-614. ISSN 0003-3022
- Cohen, S. P., Hurley, R. W., Buckenmaier, C. C., Kurihara, C., Morlando, B., & Dragovich, A. (2008). Randomized Placebo-Controlled Study Evaluating Lateral Branch Radiofrequency Denervation for Sacroiliac Joint Pain. *Anesthesiology*, Vol. 109, No. 2, pp. 279-288. ISSN 1528-1175
- Coppes, M. H., Marani, E., Thomeer, R. T., & Groen, G. J. (1997). Innervation of “painful” lumbar discs. *Spine*, Vol. 22, No. 20, pp. 2342-2349; discussion 2349-2350. ISSN 0362-2436
- Davis, T. T., Delamarter, R. B., Sra, P., & Goldstein, T. B. (2004). The IDET procedure for chronic discogenic low back pain. *Spine*, Vol. 29, No. 7, pp. 752-756. ISSN 1528-1159
- Derby R, Baker RM, Lee CH, Anderson PA.(2008) Evidence-informed management of chronic low back pain with intradiscal electrothermal therapy. *The Spine Journal*, Vol. 8, No.1, pp. 80-95. ISSN 1529-9430
- Deyo, R. A., & Weinstein, J. N. (2001). Low back pain. *The New England Journal of Medicine*, Vol. 344, No. 5, pp. 363-370. ISSN 0028-4793
- Dreyfuss, P, Halbrook, B., Pauza, K., Joshi, A., McLarty, J., & Bogduk, N. (2000). Efficacy and validity of radiofrequency neurotomy for chronic lumbar zygapophysial joint pain. *Spine*, Vol. 25, No. 10, pp.1270-1277. ISSN 0362-2436
- Dreyfuss, P, Schwarzer, A. C., Lau, P., & Bogduk, N. (1997). Specificity of lumbar medial branch and L5 dorsal ramus blocks. A computed tomography study. *Spine*, Vol. 22, No. 8, pp. 895-902. ISSN 0362-2436
- Edgar, M. A. (2007). The nerve supply of the lumbar intervertebral disc. *The Journal of Bone and Joint Surgery British* Vol. 89, No. 9, pp. 1135-1139. ISSN 0301-620X

- Erdine, S., Yucel, A., Cimen, A., Aydin, S., Sav, A., & Bilir, A. (2005). Effects of pulsed versus conventional radiofrequency current on rabbit dorsal root ganglion morphology. *European Journal of Pain*, Vol. 9, No. 3, pp. 251-256. ISSN 1090-3801
- Freeman, B. J. C., Fraser, R. D., Cain, C. M. J., Hall, D. J., & Chapple, D. C. L. (2005). A randomized, double-blind, controlled trial: intradiscal electrothermal therapy versus placebo for the treatment of chronic discogenic low back pain. *Spine*, Vol. 30, No. 21, pp. 2369-2377; discussion 2378. ISSN 1528-1159
- Freemont, A. J. (2009). The cellular pathobiology of the degenerate intervertebral disc and discogenic back pain. *Rheumatology*, Vol. 48, No. 1, pp. 5-10. ISSN 1462-0332
- Freemont, A. J., Peacock, T. E., Goupille, P., Hoyland, J. A., O'Brien, J., & Jayson, M. I. (1997). Nerve ingrowth into diseased intervertebral disc in chronic back pain. *Lancet*, Vol. 350, No. 9072, pp. 178-181. ISSN 0140-6736
- Freemont, A. J., Watkins, A., Le Maitre, C., Baird, P., Jeziorska, M., Knight, M. T. N., Ross, E. R. S., O'Brien, J. P., Hoyland, J. A. (2002). Nerve growth factor expression and innervation of the painful intervertebral disc. *The Journal of Pathology*, Vol. 197, No. 3, pp. 286-292. ISSN 0022-3417
- Geurts, J. W. M., van Wijk, R. M. A. W., Wynne, H. J., Hammink, E., Buskens, E., Lousberg, R., Knape, J. T. A., Groen, G. J. (2003). Radiofrequency lesioning of dorsal root ganglia for chronic lumbosacral radicular pain: a randomised, double-blind, controlled trial. *Lancet*, Vol. 361, No. 9351, pp. 21-26. ISSN 0140-6736
- Ghormley, R. K. (1933). Low back pain. With special reference to the articular facets, with presentation of an operative procedure. *Journal of the American Medical Association*, Vol. 101, No. 23, pp. 1773-1777.
- Helm, S., Hayek, S. M., Benyamin, R. M., & Manchikanti, L. (2009). Systematic review of the effectiveness of thermal annular procedures in treating discogenic low back pain. *Pain Physician*, Vol. 12, No. 1, pp. 207-232. ISSN 1533-3159
- Higuchi, Y., Nashold, B. S., Jr, Sluijter, M., Cosman, E., & Pearlstein, R. D. (2002). Exposure of the dorsal root ganglion in rats to pulsed radiofrequency currents activates dorsal horn lamina I and II neurons. *Neurosurgery*, Vol. 50, No. 4, pp. 850-855; discussion 856. ISSN 0148-396X
- Hurri, H., & Karppinen, J. (2004). Discogenic pain. *Pain*, Vol. 112, No. 3, pp. 225-228. ISSN 0304-3959
- Kapural, L., & Mekhail, N. (2006). A randomized, double-blind, controlled trial: intradiscal electrothermal therapy versus placebo for the treatment of chronic discogenic low back pain. *Spine*, Vol. 31, No. 14, pp. 1636; author reply 1636-1637. ISSN 1528-1159
- Karasek, M., & Bogduk, N. (2000). Twelve-month follow-up of a controlled trial of intradiscal thermal anuloplasty for back pain due to internal disc disruption. *Spine*, Vol. 25, No. 20, pp. 2601-2607. ISSN 0362-2436
- Kallewaard, J. M., Terheggen, M. A. M. B., Groen G. J., Sluijter, M. E., Derby, R., Kapural, L., Mekhail, N., van Kleef, M. (2010). Discogenic low back pain. *Pain Medicine*, Vol. 10, No. 6, pp. 560-579. ISSN 1533-2500
- Keller, A., Boyle, E., Skog, T. A., Cassidy, J. D., & Bautz-Holter, E. (2011 in press). Are Modic changes prognostic for recovery in a cohort of patients with non-specific low back pain? *European Spine Journal* ISSN 1432-0932
- Kvarstein, G., Måwe, L., Indahl, A., Hol, P. K., Tennøe, B., Digernes, R., Stubhaug, A., Tønnessen, T. I., Beivik, H. (2009). A randomized double-blind controlled trial of intra-annular radiofrequency thermal disc therapy--a 12-month follow-up. *Pain*, Vol. 145, No. 3, pp. 279-286. ISSN 1872-6623

- Lindblom, K. (1951). Technique and results of diagnostic disc puncture and injection (discography) in the lumbar region. *Acta Orthopaedica Scandinavica*, Vol. 20, No. 4, pp. 315-326. ISSN 0001-6470
- Lord, S. M., Barnsley, L., Wallis, B. J., McDonald, G. J., & Bogduk, N. (1996). Percutaneous radio-frequency neurotomy for chronic cervical zygapophyseal-joint pain. *The New England Journal of Medicine*, Vol. 335, No. 23, pp. 1721-1726. ISSN 0028-4793
- Lynch, M. C., & Taylor, J. F. (1986). Facet joint injection for low back pain. A clinical study. *The Journal of Bone and Joint Surgery British*, Vol. 68, No. 1, pp. 138-141. ISSN 0301-620X
- Maigne, J. Y., & Planchon, C. A. (2005). Sacroiliac joint pain after lumbar fusion. A study with anesthetic blocks. *European Spine Journal*, Vol. 14, No. 7, pp. 654-658. ISSN 0940-6719
- Malik, K., & Benzon, H. T. (2008). Radiofrequency applications to dorsal root ganglia: a literature review. *Anesthesiology*, Vol. 109, No. 3, pp. 527-542. ISSN 1528-1175
- Maus, T. (2010). Imaging the Back Pain Patient. *Physical Medicine and Rehabilitation Clinics of North America*, Vol. 21, No. 4, pp. 725-766. ISSN 1558-1381
- Moon, H. S., Kim, Y. D., Song, B. H., Cha, Y. D., Song, J. H., & Lee, M. H. (2010). Position of dorsal root ganglia in the lumbosacral region in patients with radiculopathy. *Korean Journal of Anesthesiology*, Vol. 59, No. 6, pp. 398. ISSN 2005-7563
- Nagda, J. V., Davis, C. W., Bajwa, Z. H., & Simopoulos, T. T. (2011). Retrospective review of the efficacy and safety of repeated pulsed and continuous radiofrequency lesioning of the dorsal root ganglion/segmental nerve for lumbar radicular pain. *Pain Physician*, Vol. 14, No. 4, pp. 371-376. ISSN 2150-1149
- Nakamura, S., Takahashi, K., Takahashi, Y., Yamagata, M., & Moriya, H. (1996). The afferent pathways of discogenic low-back pain. Evaluation of L2 spinal nerve infiltration. *The Journal of Bone and Joint Surgery British*, Vol. 78, No. 4, pp. 606-612. ISSN 0301-620X
- Nakamura, S., Takahashi, K., Takahashi, Y., Morinaga, T., Shimada, Y., & Moriya, H. (1996). Origin of nerves supplying the posterior portion of lumbar intervertebral discs in rats. *Spine*, Vol. 21, No. 8, pp. 917-924. ISSN 0362-2436
- Navani, A., Mahajan, G., Kreis, P., & Fishman, S. M. (2006). A case of pulsed radiofrequency lesioning for occipital neuralgia. *Pain Medicine*, Vol. 7, No. 5, pp. 453-456. ISSN 1526-2375
- North, R. B., Han, M., Zahurak, M., & Kidd, D. H. (1994). Radiofrequency lumbar facet denervation: analysis of prognostic factors. *Pain*, Vol. 57, No. 1, pp. 77-83. ISSN 0304-3959
- Ohnmeiss, D. D., Vanharanta, H., & Ekholm, J. (1999). Relationship of pain drawings to invasive tests assessing intervertebral disc pathology. *European Spine Journal*, Vol. 8, No. 2, pp. 126-131. ISSN 0940-6719
- Ohnmeiss, D. D., Vanharanta, H., & Ekholm, J. (1999). Relation between pain location and disc pathology: a study of pain drawings and CT/discography. *The Clinical Journal of Pain*, Vol. 15, No. 3, pp. 210-217. ISSN 0749-8047
- Ohtori, S., Takahashi, K., Chiba, T., Yamagata, M., Sameda, H., & Moriya, H. (2002). Substance P and calcitonin gene-related peptide immunoreactive sensory DRG neurons innervating the lumbar intervertebral discs in rats. *Annals of Anatomy*. Vol. 184, No. 3, pp. 235-240. ISSN 0940-9602
- Pauza, K. J., Howell, S., Dreyfuss, P., Pelozo, J. H., Dawson, K., & Bogduk, N. (2004). A randomized, placebo-controlled trial of intradiscal electrothermal therapy for the

- treatment of discogenic low back pain. *The Spine Journal*, Vol. 4, No. 1, pp. 27-35. ISSN 1529-9430
- Peng, B., Chen, J., Kuang, Z., Li, D., Pang, X., & Zhang, X. (2009). Expression and role of connective tissue growth factor in painful disc fibrosis and degeneration. *Spine*, Vol. 34, No. 5, pp. E178-182. ISSN 1528-1159
- Peng, B., Hao, J., Hou, S., Wu, W., Jiang, D., Fu, X., & Yang, Y. (2006). Possible pathogenesis of painful intervertebral disc degeneration. *Spine*, Vol. 31, No. 5, pp. 560-566. ISSN 1528-1159
- Racz, G. B., & Ruiz-Lopez, R. (2006). Radiofrequency procedures. *Pain Practice*, Vol. 6, No. 1, pp. 46-50. ISSN 1533-2500
- Richebé, P., Rathmell, J. P., & Brennan, T. J. (2005). Immediate early genes after pulsed radiofrequency treatment: neurobiology in need of clinical trials. *Anesthesiology*, Vol. 102, No. 1, pp. 1-3. ISSN 0003-3022
- Rosenberg, J. M., Quint, T. J., & de Rosayro, A. M. (2000). Computerized tomographic localization of clinically-guided sacroiliac joint injections. *The Clinical Journal of Pain*, Vol. 16, No. 1, pp. 18-21. ISSN 0749-8047
- Saal, J A, & Saal, J. S. (2000). Intradiscal electrothermal treatment for chronic discogenic low back pain: a prospective outcome study with minimum 1-year follow-up. *Spine*, Vol. 25, No. 20, pp. 2622-2627. ISSN 0362-2436
- Saal, Jeffrey A, & Saal, J. S. (2002). Intradiscal electrothermal treatment for chronic discogenic low back pain: prospective outcome study with a minimum 2-year follow-up. *Spine*, Vol. 27, No. 9, pp. 966-973; discussion 973-974. ISSN 1528-1159
- Sachs, B. L., Vanharanta, H., Spivey, M. A., Guyer, R. D., Videman, T., Rashbaum, R. F., Johnson, R. G., Hochschuler, S. H., Mooney, V. (1987). Dallas discogram description. A new classification of CT/discography in low-back disorders. *Spine*, Vol. 12, No. 3, pp. 287-294. ISSN 0362-2436
- Schwarzer, A. C., Aprill, C. N., Derby, R., Fortin, J., Kine, G., & Bogduk, N. (1995a). The prevalence and clinical features of internal disc disruption in patients with chronic low back pain. *Spine*, Vol. 20, No. 17, pp. 1878-1883. ISSN 0362-2436
- Schwarzer, A. C., Wang, S. C., Bogduk, N., McNaught, P. J., & Laurent, R. (1995b). Prevalence and clinical features of lumbar zygapophysial joint pain: a study in an Australian population with chronic low back pain. *Annals of the Rheumatic Diseases*, Vol. 54, No. 2, pp. 100-106. ISSN 0003-4967
- Shaheen, N. J., Sharma, P., Overholt, B. F., Wolfsen, H. C., Sampliner, R. E., Wang, K. K., Galanko, J. A., et al. (2009). Radiofrequency ablation in Barrett's esophagus with dysplasia. *The New England Journal of Medicine*, Vol. 360, No. 22, pp. 2277-2288. ISSN 1533-4406
- Shealy, C. N. (1976). Facet denervation in the management of back and sciatic pain. *Clinical Orthopaedics and Related Research*, Vol. Mar-Apr., No.115, pp. 157-164. ISSN 0009-921X
- Singh, K., Samartzis, D., Vaccaro, A. R., Nassr, A., Andersson, G. B., Yoon, S. T., Phillips, F. M., et al. (2005). Congenital lumbar spinal stenosis: a prospective, control-matched, cohort radiographic analysis. *The Spine Journal*, Vol. 5, No. 6, pp. 615-622. ISSN 1529-9430
- Smith, H. P., McWhorter, J. M., & Challa, V. R. (1981). Radiofrequency neurolysis in a clinical model. Neuropathological correlation. *Journal of Neurosurgery*, Vol. 55, No. 2, pp. 246-253. ISSN 0022-3085

- Thackeray, A., Fritz, J. M., Brennan, G. P., Zaman, F. M., & Willick, S. E. (2010). A pilot study examining the effectiveness of physical therapy as an adjunct to selective nerve root block in the treatment of lumbar radicular pain from disk herniation: a randomized controlled trial. *Physical Therapy*, Vol. 90, No. 12, pp. 1717-1729. ISSN 1538-6724
- Tsou, H.-K., Chao, S.-C., Wang, C.-J., Chen, H.-T., Shen, C.-C., Lee, H.-T., & Tsuei, Y.-S. (2010). Percutaneous pulsed radiofrequency applied to the L-2 dorsal root ganglion for treatment of chronic low-back pain: 3-year experience. *Journal of Neurosurgery. Spine*, Vol. 12, No. 2, pp. 190-196. ISSN 1547-5646
- Tsou, H.-K., Chao, S.-C., Kao, T.-H., Yiin, J.-J., Hsu, H.-C., Shen, C.-C., & Chen, H.-T. (2010). Intradiscal electrothermal therapy in the treatment of chronic low back pain: Experience with 93 patients. *Surgical Neurology International*. Vol. 1. pp. 37. ISSN 2229-5097
- Van Boxem, K., van Bilsen, J., de Meij, N., Herrler, A., Kessels, F., Van Zundert, J., & van Kleef, M. (2011). Pulsed Radiofrequency Treatment Adjacent to the Lumbar Dorsal Root Ganglion for the Management of Lumbosacral Radicular Syndrome: A Clinical Audit. *Pain Medicine*. Vol. 12, No. 9, pp. 1322-1330. ISSN 1526-4637
- Van Boxem, K., van Eerd, M., Brinkhuizen, T., Brinkhuize, T., Patijn, J., van Kleef, M., & van Zundert, J. (2008). Radiofrequency and pulsed radiofrequency treatment of chronic pain syndromes: the available evidence. *Pain Practice*, Vol. 8, No. 5, pp. 385-393. ISSN 1533-2500
- Van Kleef, M, Barendse, G. A., Kessels, A., Voets, H. M., Weber, W. E., & de Lange, S. (1999). Randomized trial of radiofrequency lumbar facet denervation for chronic low back pain. *Spine*, Vol. 24, No. 18, pp. 1937-1942. ISSN 0362-2436
- Van Kleef, M, Liem, L., Lousberg, R., Barendse, G., Kessels, F., & Sluijter, M. (1996). Radiofrequency lesion adjacent to the dorsal root ganglion for cervicobrachial pain: a prospective double blind randomized study. *Neurosurgery*, Vol. 38, No. 6, pp. 1127-1131; discussion 1131-1132. ISSN 0148-396X
- Van Kleef, Maarten, Vanelder, P., Cohen, S. P., Lataster, A., Van Zundert, J., & Mekhail, N. (2010). Pain originating from the lumbar facet joints. *Pain Practice*, Vol. 10, No. 5, pp. 459-469. ISSN 1533-2500
- Van Zundert, J., de Louw, A. J. A., Joosten, E. A. J., Kessels, A. G. H., Honig, W., Dederen, P. J. W. C., Veening, J. G., et al. (2005). Pulsed and continuous radiofrequency current adjacent to the cervical dorsal root ganglion of the rat induces late cellular activity in the dorsal horn. *Anesthesiology*, Vol. 102, No. 1, pp. 125-131. ISSN 0003-3022
- Walsh, T. R., Weinstein, J. N., Spratt, K. F., Lehmann, T. R., Aprill, C., & Sayre, H. (1990). Lumbar discography in normal subjects. A controlled, prospective study. *The Journal of Bone and Joint Surgery, American*, Vol. 72, No. 7, pp. 1081-1088. ISSN 0021-9355
- Wichman, H. J. (2007). Discography: over 50 years of controversy. *Wisconsin medical journal*, Vol. 106, No. 1, pp. 27-29. ISSN 1098-1861
- Yang, G., Marras, W. S., & Best, T. M. (2011). The biochemical response to biomechanical tissue loading on the low back during physical work exposure. *Clinical Biomechanics*, Vol. 26, No. 5, pp. 431-437. ISSN 1879-1271
- Zhang, J., Shi, D.-S., & Wang, R. (2011 in press). Pulsed radiofrequency of the second cervical ganglion (C2) for the treatment of cervicogenic headache. *The Journal of Headache and Pain*. ISSN 1129-2377
- Zhou, Y., & Abdi, S. (2006). Diagnosis and minimally invasive treatment of lumbar discogenic pain--a review of the literature. *The Clinical Journal of Pain*, Vol. 22, No. 5, pp. 468-481. ISSN 0749-8047



Low Back Pain Pathogenesis and Treatment

Edited by Dr. Yoshihito Sakai

ISBN 978-953-51-0338-7

Hard cover, 244 pages

Publisher InTech

Published online 14, March, 2012

Published in print edition March, 2012

Low back pain is a common disorder which affects the lumbar spine, and is associated with substantial morbidity for about 80% of the general population at some stages during their lives. Although low back pain usually is a self-limiting disorder that improves spontaneously over time, the etiology of low back pain is generally unknown and the diagnostic label, "non-specific low back pain", is frequently given. This book contains reviews and original articles with emphasis on pathogenesis and treatment of low back pain except for the rehabilitative aspect. Consisting of three sections, the first section of the book has a focus on pathogenesis of low back pain, while the second and third sections are on the treatment including conservative and surgical procedure, respectively.

How to reference

In order to correctly reference this scholarly work, feel free to copy and paste the following:

Hsi-Kai Tsou and Ting-Hsien Kao (2012). Application of Radiofrequency in Low Back Pain Treatment, Low Back Pain Pathogenesis and Treatment, Dr. Yoshihito Sakai (Ed.), ISBN: 978-953-51-0338-7, InTech, Available from: <http://www.intechopen.com/books/low-back-pain-pathogenesis-and-treatment/application-of-radiofrequency-in-low-back-pain-treatment>

INTECH
open science | open minds

InTech Europe

University Campus STeP Ri
Slavka Krautzeka 83/A
51000 Rijeka, Croatia
Phone: +385 (51) 770 447
Fax: +385 (51) 686 166
www.intechopen.com

InTech China

Unit 405, Office Block, Hotel Equatorial Shanghai
No.65, Yan An Road (West), Shanghai, 200040, China
中国上海市延安西路65号上海国际贵都大饭店办公楼405单元
Phone: +86-21-62489820
Fax: +86-21-62489821

© 2012 The Author(s). Licensee IntechOpen. This is an open access article distributed under the terms of the [Creative Commons Attribution 3.0 License](#), which permits unrestricted use, distribution, and reproduction in any medium, provided the original work is properly cited.

IntechOpen

IntechOpen