

# We are IntechOpen, the world's leading publisher of Open Access books Built by scientists, for scientists

5,200

Open access books available

129,000

International authors and editors

155M

Downloads

Our authors are among the

154

Countries delivered to

TOP 1%

most cited scientists

12.2%

Contributors from top 500 universities



WEB OF SCIENCE™

Selection of our books indexed in the Book Citation Index  
in Web of Science™ Core Collection (BKCI)

Interested in publishing with us?  
Contact [book.department@intechopen.com](mailto:book.department@intechopen.com)

Numbers displayed above are based on latest data collected.  
For more information visit [www.intechopen.com](http://www.intechopen.com)



# Review on Ovarian Cryopreservation in Large Animals and Non-Human Primates

Milan Milenkovic, Cesar Díaz-Garcia and Mats Brännström  
*Department of Obstetrics and Gynecology, Sahlgrenska Academy  
 University of Gothenburg  
 Sweden*

## 1. Introduction

The ultimate aim of ovarian cryopreservation research is naturally to increase the effectiveness of this fertility preservation procedure in female cancer victims and much of this research on whole ovary cryopreservation, ovarian cortex cryopreservation and transplantation has been performed in animal models. However, ovarian cryopreservation could also be used in the future in programs with the purpose to rescue endangered species (Santos et al., 2010) and certain specific strains of animals (Dorsch et al., 2004). Due to the ethical barriers in the research on human tissue and the shortage of human premenopausal ovarian tissue for research purposes, there is a need to find animal models that are reasonably analogous to the human. As a general rule, animal models have to be comparable in biochemical, physiological and anatomical characteristics to the human so that the results can be applicable to human conditions (VandeBerg, 2004). Regarding research of ovarian cryopreservation for human fertility preservation, a similar tissue architecture and size of the ovary (Table 1) as well as being a mono-ovulatory species with the primordial follicles located superficially in the cortex would be of advantage (Gerritse et al., 2008). The previous research on ovarian cryopreservation using bovine, porcine, sheep and non-human primate models will be presented in this chapter.

Species	Ovarian volume	Tissue architecture	Ovulation pattern	Cycle length (days)
Cow	14.3 (+/- 5.7) cm <sup>3</sup> (Gerritse et al. 2008)	Similar to the human	Mono, di-ovulatory	21
Pig	7.3 (+/- 2.2) cm <sup>3</sup> (Gerritse et al. 2008)	Less fibrous than the human ovary	Multi ovulatory	18-24
Sheep	1.0 (+/- 0.4) cm <sup>3</sup> (Gerritse et al. 2008)	Similar to the human	Mono, tri-ovulatory	16-17 (Seasonal)
Non-human primate (cynomolgus macaque)	0.258 (+/- 0.159) cm <sup>3</sup> (Jones, 2011)	Similar to the human	Mono-ovulatory	28-32

Table 1. Ovarian characteristics of different large animal models

## 2. Cow

Cow ovaries may be used in research on ovarian cryopreservation. They are much larger ( $14.3 \pm 5.7 \text{ cm}^3$ ) (Gerritse et al., 2008) as compared to the human, but on the other hand the tissue architecture is similar. The function (Yang&Fortune, 2006) and the structure (Rodgers&Irving-Rodgers, 2010) of the bovine ovary has been extensively studied. Also, the granulosa cells and the extracellular matrix of bovine follicles of various developmental stages are well described (Lavranos et al., 1994; Irving-Rodgers et al., 2006).

There exist one report of avascular ovarian transplantation in the cow after cryopreservation by vitrification using a solution consisting of 20% ethylene glycol (EG) and 20% dimethylsulphoxide (DMSO) in TCM-199 medium (Kagawa et al., 2009). In this study, vitrification was performed using the Cryotissue method (Kagawa et al., 2007), where the ovarian cortex was positioned on a thin metal strip that was plunged into liquid nitrogen (LN) and inserted into a protective container for storage in LN. Rapid post-thaw warming was done with immersion of the metal strip into TCM-199, supplemented with sucrose at  $40^\circ\text{C}$  followed by washing in the identical solution but with decreasing sucrose concentration. After warming, the tissue was grafted subcutaneously to the neck or orthotopically to oophorectomized cows, and resumed cyclicity was seen in both groups within two months. Histological analysis of grafted tissue showed normal morphological appearance and about 80% viability among preantral follicles, as demonstrated by fluorescent staining. These results may be regarded as encouraging towards clinical application of the vitrification procedure for ovarian cortex cryopreservation.

In another study, aimed towards *in vitro* follicle maturation of bovine follicles, slow-frozen bovine ovarian cortical pieces were incubated after thawing for durations between 1 and 48 h (Paynter et al., 1999). The major finding was that the thawed tissue had a capacity to recover from damage during the subsequent incubation period. This idea was further utilized in later research, where bovine ovarian cortical pieces were cultured for six days followed by isolation of secondary follicles and culture in the presence of inhibin (McLaughlin&Telfer, 2010) showing significant estradiol (E2) secretion and oocytes growth up to a diameter  $> 100 \mu\text{m}$ .

The notion that antioxidants may enhance survival of frozen-thawed tissue was studied using bovine ovarian cortex (Kim et al., 2004). After cryopreservation by slow freezing with 1.5 M DMSO, bovine ovarian cortex was *in vitro* cultured for periods up to 48 h in minimal essential medium (MEM) with or without ascorbic acid. Interestingly, there was no difference between the two groups in apoptosis rate evaluated by terminal deoxynucleotidyl transferase dUTP nick end labelling test (TUNEL) or deoxyribonucleic acid laddering. Nevertheless, protective effects by ascorbic acid were seen in stromal cells that were cultured for 24 h. In addition, this study also demonstrated that stromal cells are more susceptible to damage mechanisms than primordial follicles, which is a finding also observed in frozen-thawed human ovarian tissue (Gook et al., 1999; Hreinsson et al., 2003). The model of supplementation of antioxidant agents to the cryoprotectant (CPA) should be investigated further.

The toxic effect of various concentrations and types of CPAs that are frequently used for slow freezing was compared using bovine ovarian cortical strips (Lucci et al., 2004; Celestino et al., 2008). Among other CPAs, DMSO at 1.5 M and 3 M were evaluated in both studies.

While the study by Celestino and colleagues (Celestino et al., 2008) showed increased toxicity with rising concentration of DMSO, the other study (Lucci et al., 2004) showed slightly higher proportion of normal follicles in the 3 M DMSO group when assessed by conventional histology. However, ultrastructural analysis by transmission electron microscopy (TEM) revealed some irregularities in the cytoplasm of granulosa cells when 3 M DMSO was applied (Lucci et al., 2004).

There is one study on bovine ovarian cortical strips comparing slow freezing with vitrification and this study demonstrated higher efficiency of slow-freezing (Gandolfi et al., 2006). Furthermore, another study also demonstrated advantages of the slow-freezing method as compared to vitrification, when bovine ovarian cortical pieces were used, but on the other hand an advantage of the vitrification method was seen when whole ovaries with vasculature were used as the model system (Zhang et al., 2011). In the latter study, the effectiveness of the different cryo techniques was evaluated by Trypan blue test, histology as well as E2 and progesterone levels obtained from supernatant after *in vitro* culture of the tissue. The same research group (Zhang et al., 2011) performed controlled-rate slow freezing with DMSO of whole bovine ovary and compared different cooling rates and ice seeding temperatures. The cooling rate of 0.2°C/min and ice seeding temperature of -5°C showed superiority in comparison to different combinations of the cooling rates of 2°C/min and 0.1°C/min and the ice-seeding temperatures of -2°C, -5°C and -8°C.

Additionally, one study on bovine ovarian tissue was designed to evaluate the effect of the thickness of the ovarian cortex strip on follicular morphology after incubation for 20 min and slow freezing with 1.5 M propylene glycol (PROH) (Ferreira et al., 2010). Ovarian cortex pieces of 10 x 3 mm, with a thickness of either 2 or 4 mm, were compared and considerably higher proportion of normal follicles were found in the 2 mm group compared to the 4 mm in both fresh and cryopreserved tissue. This result may be explained by superior tissue impregnation with CPA in the 2 mm group, but the exact mechanisms remain to be clarified.

### 3. Pig

The pig is a species that has been used in biomedical research, particularly regarding development and training of surgical techniques for later use in the human. The reproductive cycle of the pig lasts for 18-24 days and generally 8-15 oocytes are released from each ovary at ovulation (Soede et al., 2011). The size of the pig ovary is about 7.3 (+/- 2.2) cm<sup>3</sup> (Gerritse et al., 2008), which is comparable to the human ovarian size of 6.5 (+/- 2.9) cm<sup>3</sup> (Munn et al., 1986). The equal ovarian size of the sow and human female, as well as the possibility to get fresh pig ovaries from slaughterhouses, renders the pig as a good model for ovarian cryopreservation research. Nevertheless, a fairly low number of studies in this area with the pig ovary as an experimental model have been performed, as shown below.

One recent study on pig ovarian tissue evaluated whether the size of ovarian cortical pieces is important for the cryopreservation outcome (Jeremias et al., 2003). Cortical strips were all of 1 mm thickness but either 1x1 mm or 5x1 mm in surface area. The pieces were cryopreserved by slow freezing in 1.5 M DMSO and after rapid thawing the size of the surviving primordial follicle pool, was compared to fresh tissue (1x1 mm) (Jeremias et al., 2003). The freezing method was uncontrolled-rate freezing with the cryovials containing

ovarian tissue were placed in a freezer at  $-20^{\circ}\text{C}$  for 30 min followed by plunging in LN vapor for 30 min and then stored in LN. The results of the experiment showed similar density of primordial follicles of the 5x1x1 mm group as compared to the fresh tissue, while lower number of primordial follicles was observed in the small (1x1 mm) frozen-thawed pieces. It was not further discussed why the larger pieces were more resistant to cryoinjury.

In one study, using porcine ovarian cortex samples, programmed slow-freezing was performed with four different CPAs (glycerol (GLY)-10%; DMSO-1.5 M, EG-1.5 M, PROH-1.5 M) (Borges et al., 2009). The ovarian cortex pieces were incubated after thawing, and histological analysis, including light microscopy and TEM, demonstrated that the follicular viability was decreased after freezing with better results obtained by DMSO and EG as compared to PROH and GLY. This result correlates to that pregnancies in the human so far only have been demonstrated after ovarian cryopreservation in either DMSO or EG as CPAs (Donnez et al., 2004; Andersen et al., 2008). However, it should be emphasized that species differences exist in this regard, as demonstrated in a comparative study between ovarian cortex of human, bovine and porcine ovarian tissue (Gandolfi et al., 2006). In that study, Gandolfi and colleagues study showed that DMSO and PROH were equally effective to protect primordial and primary follicles of the pig ovary to cryoinjury and the pig ovarian tissue was also more resistant to cryoinjury as compared to the bovine and the human ovarian tissue.

The pig model was also used to study vitrification procedures (Gandolfi et al., 2006; Moniruzzaman et al., 2009). In one study, ovarian strips from 15-day old pigs, were vitrified using 15% EG, 15% DMSO and 20% fetal calf serum with addition of either 0 M, 0.25 M or 0.5 M sucrose (Moniruzzaman et al., 2009). Histological evaluation after warming showed higher percentage of healthy primordial follicles when CPA solution with 0.25 M sucrose was applied as compared to 0 M and 0.5 M solution. Moreover, the higher oocyte shrinkage was observed with the sucrose supplementation of 0.5 M and these results can be explained by unsatisfactory cell dehydration without sucrose as well as to excessive dehydration at 0.5 M sucrose. In one study, xenografting of vitrified ovarian tissues under the kidney capsule of nude mice was performed (Moniruzzaman et al., 2009). Histological evaluation, two months after grafting, revealed decrease of the primordial follicle density by around 20% in both fresh and vitrified grafts, but in the vitrified grafts, the follicles did not developed beyond the secondary stage. Hence, it may be that follicular development is disturbed after vitrification or that a follicular stage dependant developmental blockage is incurred by cryoinjury. Another study using pig ovarian cortex demonstrated low survival rate of primordial follicles with either EG or a combination of EG and DMSO as CPA (Gandolfi et al., 2006)

The pig ovary has been used in one study of whole ovary cryopreservation (Imhof et al., 2004). The ovary was perfused through the ovarian artery with 1.5 M DMSO and cryopreserved with a slow freezing protocol. Light microscopy evaluation after thawing at  $25^{\circ}\text{C}$  demonstrated a lower proportion of viable primordial follicles in the frozen-thawed ovaries (84%) as compared to fresh controls (98%). Furthermore, about 20% of healthy primordial follicles were seen when the ovaries were positioned directly into LN without previously perfusion with CPA. Noteworthy is that TEM did not demonstrate any major cellular difference between the fresh and frozen-thawed tissue.



#### 4. Sheep

A variety of *in vivo* and *in vitro* sheep models have been used in research on both ovarian cortex cryopreservation and whole ovary cryopreservation, most probably due to the large knowledge about the physiology of the sheep ovary. In addition, the sheep ovary has, similarly to the human ovary, a collagen-dense outer stroma containing the pool of primordial follicles (Arav et al., 2005). Nevertheless, the size of the sheep ovary is only around 20% of the human premenopausal ovary (Munn et al., 1986; Gerritse et al., 2008) and this fact has to be taken into consideration, particularly in comparative studies concerning whole ovary cryopreservation.

The pioneering study in ovarian cryopreservation was published in 1994 by the Edinburgh group (Gosden et al., 1994), where live births (Table 2), after ovarian cortex cryopreservation and transplantation in a large experimental animal, were reported for the first time. In fact, this study opened up the field for future clinical fertility preservation and this is also accentuated in its conclusion by stating "that frozen storage and replacement of a patient's own ovarian tissue might be practicable when fertility potential is threatened by chemotherapy/radiotherapy". The cryopreservation protocol applied in that study has subsequently been widely used in research and clinical practice, often with minor modifications. It should be emphasized that this slow freezing-thawing protocol was adapted from a study on cryopreservation of mouse primordial follicles (Carroll&Gosden, 1993) and the authors also wrote that they "have no evidence whether it is optimal". In the Gosden study, ovarian cortex pieces were positioned in cryovials with Leibowitz L-15 solution containing donor serum and 1.5 M DMSO and the cryovials were held on ice for 15 min. The ovarian cortex strips were then considered equilibrated in the CPA and cooled in a programmable freezer at a rate of 2°C/min to -7°C and maintained at -7°C for 10 min before seeding. Freezing was performed further by reducing the temperature at a rate by 0.3°C/min to -40°C following by 10°C/min until -140°C before plunging into LN. Thawing was performed by exposure of frozen tissue to air temperature for 2 min and then placed in a water bath at room temperature for an unspecified time. The frozen-thawed slices were attached adjacent to the left ovarian pedicle at the second laparoscopy of the sheep. High progesterone level four months later indicated reestablished normal cyclicity. Eight months after grafting, one sheep gave birth and one more lamb was delivered by Cesarean section at gestational age of about 144 days.

In a follow up study the authors reported that the longevity of the transplants was at least 22 months, but at that time very few primordial follicles were found in the graft (Baird et al., 1999). The levels of follicle-stimulating hormone (FSH) and luteinizing hormone (LH) in animals which had received grafts were higher as compared to controls. However, all grafted animals demonstrated normal cyclical pattern. These findings were corroborated by the lower levels of inhibin, indicating reduced number of inhibin-producing small antral follicles. In the second part of the study Baird and colleagues grafted both fresh and frozen-thawed ovarian pieces under the kidney capsule of nude mice to assess whether the freezing-thawing procedure per se or if the warm ischemic time post transplantation was the main reason for loss of the follicle pool already within two years. A follicular depletion of about 65% was seen after grafting of fresh tissue as compared to fresh non-grafted ovarian tissue. Additionally 7% was lost after transplantation of frozen-thawed pieces. Thus,

this study demonstrated that ischemia rather than cryopreservation is the main cause of follicle depletion.

Reference	Ovarian tissue	Cryopreservation	Cryoprotectant	Transplantation	Results
Gosden et al. 1994.	Cortical pieces	Slow freezing	1.5 M DMSO in Leibovitz L-15 with 10% donor calf serum	Avascular, orthotopic	2 live births out of 6 transplants 11 live births (of which 3 sheep delivered twins) out of 6 transplants;
Salle et al. 2002, Salle et al. 2003.	Hemi-ovarian cortex	Slow freezing	2 M DMSO in BM1 medium with 10% fetal cord serum	Avascular, orthotopic	2 sheep delivered for the second time
Bordes et al. 2005.	Hemi-ovarian cortex	Vitrification	2.62 M DMSO +2.6 M acetamide+1.3M propylene glycol+0.0075 M polyethylene glycol in BM1 medium	Avascular, orthotopic	4 live births (1 twins) out of 6 transplants
Imhof et al. 2006.	Whole ovary	Slow freezing	1.5 M DMSO in RPMI 1640 with 10% autologous sheep blood serum	Vascular, orthotopic	1 live birth out of 8 transplants

DMSO- dimethylsulphoxide; RPMI-Roswell Park Memorial Institute medium.

Table 2. Live-births after transplantation of cryopreserved ovarian tissue in large animal models

Depletion of the major follicular pool during the ischemic post grafting period was also demonstrated in a recent study in the sheep, where fresh and frozen ovarian cortical tissue were grafted either subcutaneously in the anterior abdominal wall or the uterine horn (Aubard et al., 1999). The cryopreservation procedure was a slight modification of the original Gosden method (Gosden et al., 1994). About 5% of primordial follicles survived grafting at evaluation after seven months. No pregnancy was demonstrated, but mature oocytes were retrieved after gonadotropin stimulation. In addition, poor fertilization rate and cleavage arrest at 4 cells were recorded in oocytes from both fresh and frozen ovarian tissue. These results open up the issue of about cytoplasmatic maturation as well as quality of the oocytes from grafted and frozen-thawed tissue.

In other studies, a larger part of sheep ovaries, containing also parts of the medulla, were evaluated regarding viability after cryopreservation and avascular transplantation (Salle et al., 1998). In that study, the ovarian tissue was cryopreserved using the slow freezing technique published by Gosden (Gosden et al., 1994). Transplantation was performed to the ovarian hilus. At evaluation after six months, well preserved morphology with follicles of all stages was demonstrated (Salle et al., 1998) and progesterone secretion was reestablished (Salle et al., 1999). The same research group reported live births (Table 2) after cryopreservation and avascular transplantation of hemi-ovarian cortex (Salle et al., 2002). However, the cryoprotocol had been slightly modified using higher concentration (2 M) of DMSO and the temperature was decreased by a rate of 2°C/min to -35°C followed by 25°C/min to -140°C. Semiautomatic seeding was initiated at -11°C. Orthotopic transplantation was performed. Four out of six ewes achieved pregnancy of which two delivered twins. The remaining four ewes were observed further for two years (Salle et al., 2003). All animals became pregnant (Table 2) and delivered lambs of which two sheep gave birth for a second time. Noteworthy is that considerable loss of follicles was seen in all grafts. The results of this study also emphasizes that the avascular transplantation per se induces major damage to the tissue.

In one study, vitrification of sheep hemi-ovaries was performed with the VS1 CPA solution, containing 2.62 M DMSO, 2.60 M acetamide, 1.31 M PROH and 0.0075 M polyethylene glycol in BM1 medium (Bordes et al., 2005). The ovarian tissue was equilibrated in increasing concentration of VS1 (12.5%, 25%, 50% and 100%) and then placed in cryovials containing 100% of VS1 followed by direct plunging into LN. The vitrified tissue was warmed in water at 37°C for 10 min. Notably, regained cyclicity was shown four months to one year after grafting and 3/6 sheep delivered offspring (Table 2). However, histological evaluation of the graft after delivery revealed very few follicles (6-58 follicles per graft).

A group from the Cleveland Clinic performed microvascular fresh ovary transplantation in the sheep (Jeremias et al., 2002) and soon after published their results after autotransplantation of the whole cryopreserved ovary applying the identical surgical technique (Bedaiwy et al., 2003) with comparison of the outcome to avascular grafting of frozen-thawed cortical pieces (frozen with Gosdens protocol). The whole ovaries were flushed by a solution consisting of Leibowitz L-15 medium, 10% fetal calf serum and 1.5 M DMSO and then allocated to controlled-rate freezing. The temperature was reduced at 2°C/min until seeding temperature of -7°C. Further reduction of temperature was done at 2°C/min until -35°C followed at by 25°C/min until -140°C when cryovials were positioned into LN. At thawing, the cryovials were placed in a water bath at 37°C. After that, the ovaries were flushed with Leibovitz L15 medium containing 10% fetal calf serum for 20 min followed by end-to-end anastomosis between the ovarian and the inferior epigastric vessels. Immediate vascular patency was showed in all grafts, but only 27% of the whole ovary transplants showed patent blood vessels eight to ten days after transplantation. Histological evaluation demonstrated large necrotic areas in the grafts of the non-patent anastomosis group and the primordial follicle pool was severely reduced in that group as compared to the patent group. Also, severe injuries with focal transmural necrosis of intraovarian vessels may be regarded as a cryoinjury of the vasculature. The follicular viability, evaluated by Trypan blue test, was around 80%, in the cortical avascular transplantation and the patent whole ovary transplantation group, with a slightly higher rate of apoptotic cells in the whole



ovary group. It should be emphasized that this study evaluated only short-term (8-10 days) results.

The long-term outcome, using the same microsurgical technique as described above, was assessed in a study of ovarian viability approximately five months after transplantation of frozen-thawed ovaries (Grazul-Bilska et al., 2008). A similar cryoprotocol was applied as in the earlier experiments (Bedaiwy et al., 2003) and the only difference was that the temperature from the seeding point was decreased by the rate 0.3°C/min until -40°C in contrast to 2°C/min until -35°C in the previous study. Histological evaluation revealed normal follicular development in only 25% of the transplanted ovaries. Furthermore, oocytes (n=3) from the larger follicles could be matured, but fertilization was not achieved. The vessels of the patent grafts appeared normal, with expression of marker proteins such as factor VIII, vascular endothelial growth factor (VEGF) and smooth muscle cell actin (SMCA). In view of the fact that the normal follicular development was seen in only 25% of the transplanted ovaries, and that mature oocytes did not fertilize, the study points to that major improvements in the fields of whole ovary cryopreservation and retransplantation are needed.

Main advances in the whole ovary cryopreservation field may be to optimize the freezing technique and also to improve the anastomosis technique as evaluated by an Israeli research group (Revel et al., 2004). After perfusion via the ovarian artery with 1.4 M DMSO in University of Wisconsin (UW) solution for 3 min, the sheep ovary was cryopreserved by the directional freezing technology. This technique provides identical cooling rate through the whole organ and allows constant cooling rate. The temperature was decreased by a rate of 0.6°C/min until seeding and 0.3°C/min to the temperature of -30°C before placement in LN. Rapid thawing was accomplished by placement of the cryovials into a water bath at 68°C for 20 s and 37°C for 2 min. The ovary was transplanted by microvascular anastomosis to an orthotopic site by end-to-end anastomosis to the remaining parts of the ovarian vessels. Cyclicity was demonstrated in three out of eight animals at around six months after the procedure. At laparotomy eight weeks after surgery, adhesions were seen in only one animal. In a follow up study, presenting long-term outcome of this technique (Arav et al., 2005), three animals demonstrated cyclicity two to three years after transplantation. Oocytes obtained from these animals could be parthenogenically activated with divisions until the 8-cell stage. In an extensive long-term follow up study (6 years) of the three whole ovary transplanted sheep (Arav et al., 2010) two of the ovaries responded to gonadotropin stimulation and these ovaries were normal at post mortem histological evaluation. The third sheep did not respond to FSH stimulation and histology revealed a fibrotic ovary and absence of follicles. The importance of this study is that cryopreserved whole ovary can survive for a long time and indicates beneficial effect of directional slow-freezing method. Nevertheless, it should be pointed out that the ultimate end point of healthy offspring has not been demonstrated by the use of this cryopreservation technique.

There is only one report on live-birth after whole ovary cryopreservation and vascular transplantation in sheep (Imhof et al., 2006). In that study, the ovaries were cryopreserved using the protocol of Gosden and coworkers (Gosden et al., 1994), but naturally the ovaries were cannulated and perfused with CPA before controlled-rate slow-freezing. Thawing was done by exposure of the frozen ovaries in air for two minutes followed by placement in a

water bath at 25°C for seven minutes and perfusion by Roswell Park Memorial Institute medium (RPMI) to remove CPA. Transplantation was performed after removal of the contralateral ovary and the frozen-thawed ovary was orthotopically transplanted using microvascular (9-0 sutures) anastomosis to the ovarian vessels which is a comparable technique to that described by the Israeli group (Arav et al., 2005). Cyclicity was reported in four out of nine transplanted sheep. Importantly, one pregnancy occurred in this resulted in delivery of a healthy lamb around 1.5 years after grafting. At histological examination of ovaries 18-19 months after transplantation, the size of the primordial follicle pool was only 2-8% of that in non transplanted control ovaries. The authors discussed that the major follicular loss occurred during the freezing-thawing procedure. However, this suggestion relied on results of histological assessment, which is probably an unreliable method to evaluate viability and should be combined with other methods. Nevertheless, this single large animal species live-birth after whole ovary cryopreservation is a proof of the concept, which should encourage further research in this area.

It is of considerable importance to recognize the mechanisms behind the low success rate of whole ovary cryopreservation and also to understand what cell compartments are affected by the cryopreservation and thawing procedures. It seems that the follicular survival and the ovarian function are directly correlated to the vascular patency, as demonstrated in one elegant study of heterotopic autotransplantation of the frozen-thawed whole ovary (Onions et al., 2009). The CPA and freezing protocols were similar to the traditional Gosden protocol (Gosden et al., 1994) and the microvascular anastomosis was by aortic patch and utero-ovarian vein to carotid artery and jugular vein, as developed more than 40 years ago (Goding et al., 1967). The control group was the animals which received non-frozen heterotopic transplants. Eight months after transplantation, 7/8 cryopreserved transplants and 3/4 fresh ovarian transplants demonstrated patency. However, regardless of vascular patency, 5/7 frozen-thawed ovaries with vascular patency did not regain cyclicity and eight months after transplantation, a follicular loss of about 90% was seen in both the fresh and frozen group. A possible damage of endothelial cells during cannulation was discussed as one detrimental factor.

In vitro studies of vitrification of the whole sheep ovary preceded the trials in vivo. It was demonstrated in an elaborate study that the whole sheep ovary could be vitrified and that the VS4 cryoprotectant solution (mixture of 2.75 M DMSO, 2.76 M formamide and 1.97 M PROH) was superior to the VS1 solution (mixture of 2.62 M DMSO, 2.60 M acetamide, 1.31 M PROH and 0.0075 M polyethylene-glycol) (Courbiere et al., 2005). After thawing, the higher primordial follicular density (50% vs 23%) as well as proportion of histologically normal primordial follicles (53% vs 25%) was demonstrated in the VS4 group. However, it should be underlined that endothelial damage of the vascular pedicle was more evident in the VS4 group.

In a subsequent study by the same research group, the thermodynamic properties of VS4 in RPS-1 medium were studied (Courbiere et al., 2006). Evaluation of the cooling rate was done by differential scanning calorimeter by connection of the thermocouples to the ovarian cortex, the medulla and the CPA solution. The rate of cooling was above 300°C/min, with the measured cooling rate of the cortex being slightly higher than that of the medulla. Furthermore, the cooling rate of the CPA solution was higher in comparison to the ovarian

medulla and cortex. This finding may be explained by differences in tissue architecture and vascularity of the ovary that leads to uneven distribution of the CPA. Results of this study also pointed out that it is not likely that the ovarian tissue can be completely vitrified at the end of the procedure. Ice crystallization during warming was also observed, indicating that the warming rate did not exceed the critical warming rate. Nevertheless, in contrast to the former study (Courbiere et al., 2005), injury of the endothelial layer of the ovarian vasculature was not demonstrated which possibly may be the result of the two-step-warming procedure to avoid ice crystallization (Pegg et al., 1997) as used in this study (Courbiere et al., 2006).

The same research group demonstrated in a subsequent study that the warming rate of the cortex was slightly higher than the medulla (Baudot et al., 2007). This corroborates the irregular distribution of CPA as well as complexity of the ovarian tissue. As in the previous study (Courbiere et al., 2005), a primordial follicle survival rate of about 50% was demonstrated after warming. In addition, ice crystals were observed during the cooling and the authors discussed that maybe limited ice crystallization can be acceptable for clinical application of this procedure.

Subsequent to the *in vitro* research on whole ovary vitrification, as described above (Courbiere et al., 2005; Courbiere et al., 2006), the efficiency of this method *in vivo* was assessed. In one study only one out of five vitrified-warmed ovaries resumed endocrine function (Courbiere et al., 2009) after orthotopic vascular transplantation. Vitrification was obtained using VS4 solution (2.75 M DMSO, 2.76 M formamide and 1.97 M PROH) in RPS-1 medium and the ovaries were perfused by gradually increasing concentrations of CPA. At warming, the ovaries were kept in LN vapor following by placement in a water bath at 45°C. The rationale behind this two-step warming was to attempt to avoid fractures of the vessels during the glassy state (Pegg et al., 1997). A total follicular loss in the vitrified group was demonstrated one year after transplantation. Vascular thrombosis occurred in three out of four vitrified ovaries, with patent vessels seen in the fresh group. One possible explanation may be that the warm ischemic time was longer in the vitrified group (median 287 min) in comparison to the control group (median 129 min) although it is more likely that major injuries occurred during the cryopreservation procedures.

It is obvious from the results presented above that there is a need for more systematic studies on the different stages of cryopreservation/transplantation procedures to get better results. As it relates to whole ovary cryopreservation, the viability and ovarian function should be evaluated after each stage of the procedure.

The effect of diverse cryoprotocols with accent of CPA toxicity was studied using the sheep hemiovary model (Demirci et al., 2001). The hemiovaries were incubated for 10 minutes in various concentrations (2-10 M) of DMSO and PROH and evaluated before and after slow-freezing-thawing (1, 1.5 and 2 M CPAs) concerning primordial follicle survival (Trypan blue test and histology). The follicular survival after incubation was higher at decreasing concentration of the CPA regardless of the type of CPA.

*In vitro* ovarian perfusion methodology, which was initially developed for evaluation of ovarian physiology (Brannstrom et al., 1987), may be used for evaluation of frozen-thawed ovaries (Fig. 1). The *in vitro* perfusion system highly mimics the physiological *in vivo* situation, and has shown that a complex processes, such as ovulation, occur during *in vitro*

perfusion (Lofman et al., 1989). Recently, *in vitro* ovarian perfusion was used together with live-dead assay, histology and cell culture to assess the viability of frozen-thawed whole sheep ovaries (Wallin et al., 2009). The ovaries were frozen by slow uncontrolled-rate freezing (Martinez-Madrid et al., 2004) using PROH, stored in LN and then thawed in a water bath at 37°C. The *in vitro* perfusion results demonstrated compromised ovarian function of the ovary after cryopreservation in PROH, when compared to fresh controls.

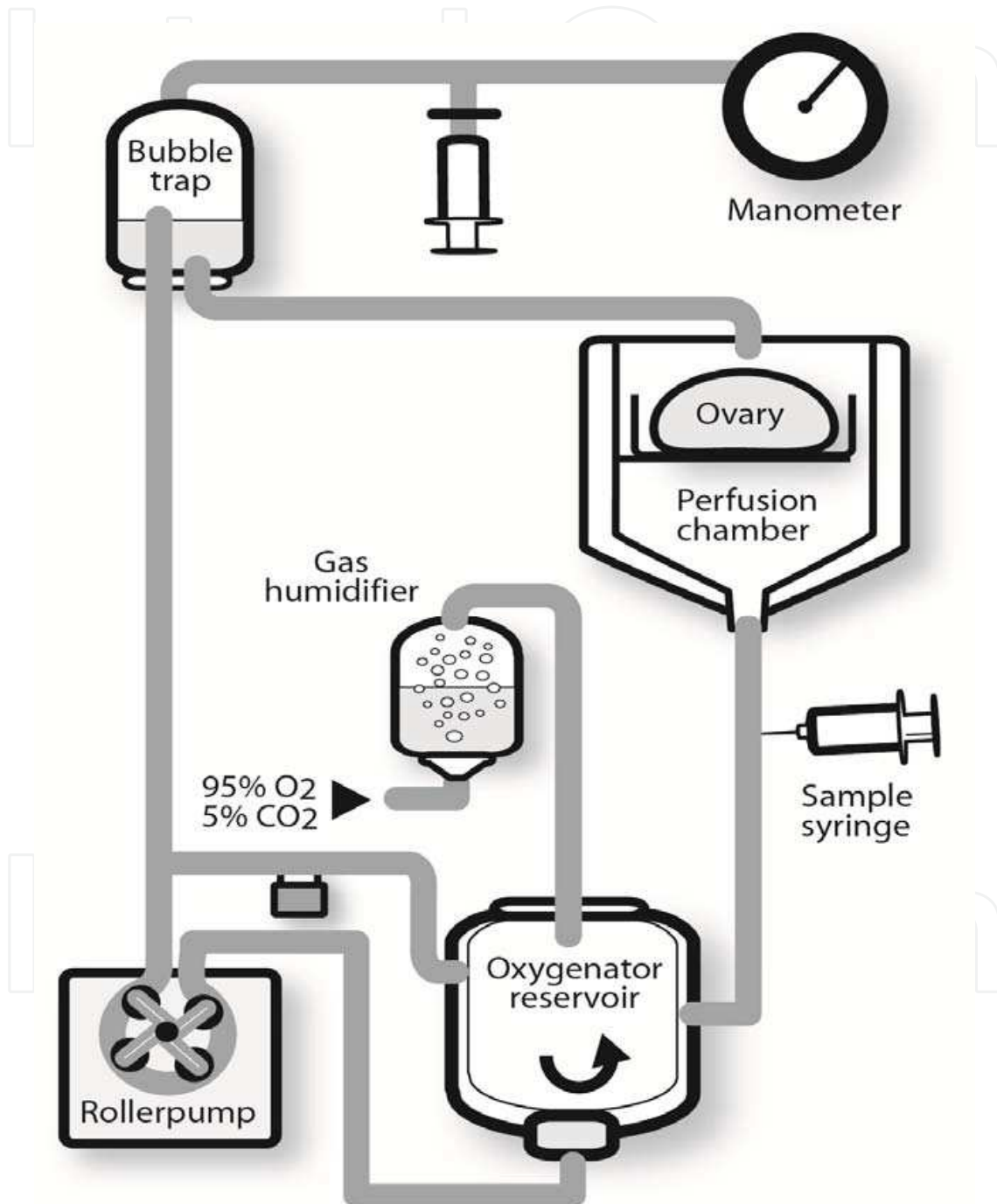


Fig. 1. Schematic drawing of the *in vitro* perfusion system

In another study of the same research group, the sheep ovaries were cryopreserved using the same uncontrolled-rate slow freezing with DMSO (Milenkovic et al., 2011). The ovaries



in control group were frozen without CPA. Interestingly, steroid production after *in vitro* perfusion (Fig. 2) and cell culture was also demonstrated in control group which can be explained by adequate equilibration between cell dehydration and extracellular ice formation. However, a clear benefit of DMSO presence was seen.




Fig. 2. Photograph of the *in vitro* perfusion apparatus

As discussed above, cryopreservation injury may not only occur within the follicles but also in the vascular bed of the ovary or in the large vessels. It was hypothesized that perfusion with the anti-apoptotic agent sphingosine-1-phosphate (S-1-P) before cryopreservation-perfusion by 1.5 M DMSO (Onions et al., 2008) may protect the tissue and diminish the cryoinjury. Histological examination after thawing showed arterial endothelial disruption of the vascular pedicle tissue in the cryopreserved ovaries, with the most extensive injury in the area where the cannula had been placed, followed by the hilus region and with less extensive injury on the venous side. No protective effect of the addition of sphingosine-1-phosphate could be demonstrated. In summary, this study was able to demonstrate the vulnerable state of the vasculature in whole ovary cryopreservation especially on the arterial side. It was also shown by proliferation and apoptosis markers that granulosa cells of antral follicles remain viable after cryopreservation.

## 5. Non-human primates

A number of non-human primate species have been used in research involving reproductive physiology and development of methods later used clinically in reproductive medicine. The benefit of these experimental animals is that the physiology and anatomy are similar to the human (Stevens, 1997; Weinbauer et al., 2008), although the ovarian size of the most studied cynomolgus monkey is considerably smaller ( $0.258 \pm 0.159 \text{ cm}^3$ ) (Jones et al., 2010) as compared to the human. Even if a lot of procedures are introduced in the human without



appropriate tests in non-human primate species, it is advisable to include these animal models in preclinical research.

There is one study on non-human primate that has assessed the function of cryopreserved ovarian cortex tissue *in vivo*. The ovarian pieces were cryopreserved by controlled-rate freezing with 1.5 M DMSO and both fresh and frozen-thawed strips were grafted subcutaneously to the upper arm of cynomolgus macaque monkeys (Schnorr et al., 2002). Regained menstrual cycle and ovarian steroidogenesis were demonstrated in 80% of the animals after fresh ovarian cortex transplantation and in 50% of the animals after cryopreserved transplants, demonstrating that the cryopreservation technique may have damaging effect on the tissue. Additionally, only one mature oocyte was aspirated from subcutaneous ovarian tissue after gonadotropin stimulation performed in four animals. In the other part of this study (Schnorr et al., 2002) an attempt to enhance angiogenesis was performed by local administration of VEGF for two weeks after grafting, but no beneficial effect could be demonstrated.

There is one study on ovarian cortex from macaques when vitrification (3.4 M GLY, 4.5 M EG) and slow freezing (1.5 M EG) were compared and evaluated whether post-thawing co-culture on feeder cells (mouse fetal fibroblast monolayer) with addition of follicle stimulating hormone, insulin, transferrin and selenium, would increase viability (Yeoman et al., 2005). The post-thaw viability, as assessed by live-dead fluorescent staining, was comparable (around 70%) in the two groups, which was only marginally lower than the follicular viability of the fresh tissue (76%). Interestingly, follicular viability was increased after post-thawing co-culture, indicating rescue of partly damaged follicles and possible beneficial effect of co-culture.

In another study on ovarian cortex tissue of rhesus macaques, controlled-rate slow-freezing with 1.5 M EG was done and expressions of activin subunits as well as the phosphorylated form of the signalling protein were investigated (Jin et al., 2010). Activin subunits and the phosphorylated form of the signalling protein are markers for early follicular development. Immunohistochemistry revealed that these proteins were regularly distributed in primordial and primary follicles of both cryopreserved and fresh cortex. One interesting finding was that a higher rate of post thawing apoptosis was found in the stromal cells as compared to oocytes and granulosa cells. Another recently published study was able to demonstrate follicular development after *in vitro* three dimensional culture of cryopreserved secondary follicles from rhesus macaque (Ting et al., 2011). The ovarian cortex from rhesus macaque was cryopreserved by slow freezing (1.5 M EG) and vitrification (3 M GLY and 4.5 M EG). After thawing, the secondary follicles were mechanically isolated, encapsulated in 0.25% alginate and cultured for five weeks in MEM at 37°C. The development of antral follicles, although delayed and functionally compromised as compared to fresh tissue was demonstrated after both cryopreservation methods with slightly better results obtained after vitrification in comparison to slow freezing protocol. This observation again supports the need for further improvement of cryopreservation techniques.

## 6. Conclusions

Regardless pioneering success and reporting pregnancies after cryopreservation and avascular transplantation of ovarian tissue in human (Donnez et al., 2011) the future course regarding cryopreservation of ovarian tissue should be focused on further research using

animal models. The size of ovarian cortex pieces, whole ovary freezing or not, choice and exposure time to CPA, stepwise or direct addition of CPA are some of the unresolved questions. The difference between species, complexity of ovarian tissue and uneven distribution of primordial follicles should be taken into consideration when creating an optimal study design. Vitrification seems promising, but differences between the protocols used make the interpretation of the data difficult. However, further research on animal models should lead to better understanding and improvement of cryopreservation techniques and then to higher efficiency, when used as a clinical procedure.

## 7. References

- Andersen, C. Y., M. Rosendahl, A. G. Byskov, A. Loft, C. Ottosen, M. Dueholm, K. L. Schmidt, A. N. Andersen & E. Ernst. (2008). Two successful pregnancies following autotransplantation of frozen/thawed ovarian tissue. *Hum Reprod*, 23, 2266-2272, 1460-2350 (Electronic)
- Arav, A., Z. Gavish, A. Elami, Y. Natan, A. Revel, S. Silber, R. G. Gosden & P. Patrizio. (2010). Ovarian function 6 years after cryopreservation and transplantation of whole sheep ovaries. *Reprod Biomed Online*, 20, 48-52, 1472-6491 (Electronic) 1472-6483 (Linking)
- Arav, A., A. Revel, Y. Nathan, A. Bor, H. Gacitua, S. Yavin, Z. Gavish, M. Uri & A. Elami. (2005). Oocyte recovery, embryo development and ovarian function after cryopreservation and transplantation of whole sheep ovary. *Hum Reprod*, 20, 3554-3559, 0268-1161 (Print)
- Aubard, Y., P. Piver, Y. Cogni, V. Fermeaux, N. Poulin & M. A. Driancourt. (1999). Orthotopic and heterotopic autografts of frozen-thawed ovarian cortex in sheep. *Hum Reprod*, 14, 2149-2154, 0268-1161 (Print) 0268-1161 (Linking)
- Baird, D. T., R. Webb, B. K. Campbell, L. M. Harkness & R. G. Gosden. (1999). Long-term ovarian function in sheep after ovariectomy and transplantation of autografts stored at -196 C. *Endocrinology*, 140, 462-471, 0013-7227 (Print)
- Baudot, A., B. Courbiere, V. Odagescu, B. Salle, C. Mazoyer, J. Massardier & J. Lornage. (2007). Towards whole sheep ovary cryopreservation. *Cryobiology*, 55, 236-248, 1090-2392 (Electronic)
- Bedaiwy, M. A., E. Jeremias, R. Gurunluoglu, M. R. Hussein, M. Siemianow, C. Biscotti & T. Falcone. (2003). Restoration of ovarian function after autotransplantation of intact frozen-thawed sheep ovaries with microvascular anastomosis. *Fertil Steril*, 79, 594-602, 0015-0282 (Print)
- Bordes, A., J. Lornage, B. Demirci, M. Franck, B. Courbiere, J. F. Guerin & B. Salle. (2005). Normal gestations and live births after orthotopic autograft of vitrified-warmed hemi-ovaries into ewes. *Hum Reprod*, 20, 2745-2748, 0268-1161 (Print)
- Borges, E. N., R. C. Silva, D. O. Futino, C. M. Rocha-Junior, C. A. Amorim, S. N. Bao & C. M. Lucci. (2009). Cryopreservation of swine ovarian tissue: effect of different cryoprotectants on the structural preservation of preantral follicle oocytes. *Cryobiology*, 59, 195-200, 1090-2392 (Electronic) 0011-2240 (Linking)
- Brannstrom, M., B. M. Johansson, J. Sogn & P. O. Janson. (1987). Characterization of an in vitro perfused rat ovary model: ovulation rate, oocyte maturation, steroidogenesis and influence of PMSG priming. *Acta Physiol Scand*, 130, 107-114, 0001-6772 (Print)
- Carroll, J. & R. G. Gosden. (1993). Transplantation of frozen-thawed mouse primordial follicles. *Hum Reprod*, 8, 1163-1167, 0268-1161 (Print) 0268-1161 (Linking)

- Celestino, J. J., R. R. Dos Santos, C. A. Lopes, F. S. Martins, M. H. Matos, M. A. Melo, S. N. Bao, A. P. Rodrigues, J. R. Silva & J. R. De Figueiredo. (2008). Preservation of bovine preantral follicle viability and ultra-structure after cooling and freezing of ovarian tissue. *Anim Reprod Sci*, 108, 309-318, 1873-2232 (Electronic) 0378-4320 (Linking)
- Courbiere, B., L. Caquant, C. Mazoyer, M. Franck, J. Lornage & B. Salle. (2009). Difficulties improving ovarian functional recovery by microvascular transplantation and whole ovary vitrification. *Fertil Steril*, 91, 2697-2706, 1556-5653 (Electronic) 0015-0282 (Linking)
- Courbiere, B., J. Massardier, B. Salle, C. Mazoyer, J. F. Guerin & J. Lornage. (2005). Follicular viability and histological assessment after cryopreservation of whole sheep ovaries with vascular pedicle by vitrification. *Fertil Steril*, 84 Suppl 2, 1065-1071, 1556-5653 (Electronic)
- Courbiere, B., V. Odagescu, A. Baudot, J. Massardier, C. Mazoyer, B. Salle & J. Lornage. (2006). Cryopreservation of the ovary by vitrification as an alternative to slow-cooling protocols. *Fertil Steril*, 86, 1243-1251, 1556-5653 (Electronic)
- Demirci, B., J. Lornage, B. Salle, L. Frappart, M. Franck & J. F. Guerin. (2001). Follicular viability and morphology of sheep ovaries after exposure to cryoprotectant and cryopreservation with different freezing protocols. *Fertil Steril*, 75, 754-762, 0015-0282 (Print) 0015-0282 (Linking)
- Donnez, J., M. M. Dolmans, D. Demylle, P. Jadoul, C. Pirard, J. Squifflet, B. Martinez-Madrid & A. Van Langendonck. (2004). Livebirth after orthotopic transplantation of cryopreserved ovarian tissue. *Lancet*, 364, 1405-1410, 1474-547X (Electronic)
- Donnez, J., S. Silber, C. Y. Andersen, I. Demeestere, P. Piver, D. Meirow, A. Pellicer & M. M. Dolmans. (2011). Children born after autotransplantation of cryopreserved ovarian tissue. a review of 13 live births. *Ann Med*, 43, 437-450, 1365-2060 (Electronic) 0785-3890 (Linking)
- Dorsch, M., D. Wedekind, K. Kamino & H. J. Hedrich. (2004). Orthotopic transplantation of rat ovaries as a tool for strain rescue. *Lab Anim*, 38, 307-312, 0023-6772 (Print) 0023-6772 (Linking)
- Ferreira, M., A. Bos-Mikich, N. Frantz, J. L. Rodrigues, A. L. Brunetto & G. Schwartzmann. (2010). The effects of sample size on the outcome of ovarian tissue cryopreservation. *Reprod Domest Anim*, 45, 99-102, 1439-0531 (Electronic) 0936-6768 (Linking)
- Gandolfi, F., A. Paffoni, E. Papasso Brambilla, S. Bonetti, T. A. Brevini & G. Ragni. (2006). Efficiency of equilibrium cooling and vitrification procedures for the cryopreservation of ovarian tissue: comparative analysis between human and animal models. *Fertil Steril*, 85 Suppl 1, 1150-1156, 1556-5653 (Electronic)
- Gerritse, R., C. C. Beerendonk, M. S. Tjink, A. Heetkamp, J. A. Kremer, D. D. Braat & J. R. Westphal. (2008). Optimal perfusion of an intact ovary as a prerequisite for successful ovarian cryopreservation. *Hum Reprod*, 23, 329-335, 1460-2350 (Electronic)
- Goding, J. R., J. A. Mccracken & D. T. Baird. (1967). The study of ovarian function in the ewe by means of a vascular autotransplantation technique. *J Endocrinol*, 39, 37-52, 0022-0795 (Print)
- Gook, D. A., D. H. Edgar & C. Stern. (1999). Effect of cooling rate and dehydration regimen on the histological appearance of human ovarian cortex following cryopreservation in 1, 2-propanediol. *Hum Reprod*, 14, 2061-2068, 0268-1161 (Print)


- Gosden, R. G., D. T. Baird, J. C. Wade & R. Webb. (1994). Restoration of fertility to oophorectomized sheep by ovarian autografts stored at -196 degrees C. *Hum Reprod*, 9, 597-603, 0268-1161 (Print)
- Grazul-Bilska, A. T., J. Banerjee, I. Yazici, E. Borowczyk, J. J. Bilski, R. K. Sharma, M. Siemionov & T. Falcone. (2008). Morphology and function of cryopreserved whole ovine ovaries after heterotopic autotransplantation. *Reprod Biol Endocrinol*, 6, 16, 1477-7827 (Electronic)
- Hreinsson, J., P. Zhang, M. L. Swahn, K. Hultenby & O. Hovatta. (2003). Cryopreservation of follicles in human ovarian cortical tissue. Comparison of serum and human serum albumin in the cryoprotectant solutions. *Hum Reprod*, 18, 2420-2428, 0268-1161 (Print)
- Imhof, M., H. Bergmeister, M. Lipovac, M. Rudas, G. Hofstetter & J. Huber. (2006). Orthotopic microvascular reanastomosis of whole cryopreserved ovine ovaries resulting in pregnancy and live birth. *Fertil Steril*, 85 Suppl 1, 1208-1215, 1556-5653 (Electronic)
- Imhof, M., G. Hofstetter, H. Bergmeister, M. Rudas, R. Kain, M. Lipovac & J. Huber. (2004). Cryopreservation of a whole ovary as a strategy for restoring ovarian function. *J Assist Reprod Genet*, 21, 459-465, 1058-0468 (Print)
- Irving-Rodgers, H. F., K. D. Catanzariti, W. J. Aspden, M. J. D'occhio & R. J. Rodgers. (2006). Remodeling of extracellular matrix at ovulation of the bovine ovarian follicle. *Mol Reprod Dev*, 73, 1292-1302, 1040-452X (Print) 1040-452X (Linking)
- Jeremias, E., M. A. Bedaiwy, R. Gurunluoglu, C. V. Biscotti, M. Siemionow & T. Falcone. (2002). Heterotopic autotransplantation of the ovary with microvascular anastomosis: a novel surgical technique. *Fertil Steril*, 77, 1278-1282, 0015-0282 (Print)
- Jeremias, E., M. A. Bedaiwy, D. Nelson, C. V. Biscotti & T. Falcone. (2003). Assessment of tissue injury in cryopreserved ovarian tissue. *Fertil Steril*, 79, 651-653, 0015-0282 (Print)
- Jin, S., L. Lei, L. D. Shea, M. B. Zelinski, R. L. Stouffer & T. K. Woodruff. (2010). Markers of growth and development in primate primordial follicles are preserved after slow cryopreservation. *Fertil Steril*, 93, 2627-2632, 1556-5653 (Electronic) 0015-0282 (Linking)
- Jones, J. C., S. E. Appt, S. R. Werre, J. C. Tan & J. R. Kaplan. (2010). Validation of multi-detector computed tomography as a non-invasive method for measuring ovarian volume in macaques (*Macaca fascicularis*). *Am J Primatol*, 72, 530-538, 1098-2345 (Electronic) 0275-2565 (Linking)
- Kagawa, N., M. Kuwayama, K. Nakata, G. Vajta, S. Silber, N. Manabe & O. Kato. (2007). Production of the first offspring from oocytes derived from fresh and cryopreserved pre-antral follicles of adult mice. *Reprod Biomed Online*, 14, 693-699, 1472-6483 (Print) 1472-6483 (Linking)
- Kagawa, N., S. Silber & M. Kuwayama. (2009). Successful vitrification of bovine and human ovarian tissue. *Reprod Biomed Online*, 18, 568-577, 1472-6491 (Electronic)
- Kim, S. S., H. W. Yang, H. G. Kang, H. H. Lee, H. C. Lee, D. S. Ko & R. G. Gosden. (2004). Quantitative assessment of ischemic tissue damage in ovarian cortical tissue with or without antioxidant (ascorbic acid) treatment. *Fertil Steril*, 82, 679-685, 0015-0282 (Print)
- Lavranos, T. C., H. F. Rodgers, I. Bertonecello & R. J. Rodgers. (1994). Anchorage-independent culture of bovine granulosa cells: the effects of basic fibroblast growth factor and



- dibutyryl cAMP on cell division and differentiation. *Exp Cell Res*, 211, 245-251, 0014-4827 (Print) 0014-4827 (Linking)
- Lofman, C. O., M. Brannstrom, P. V. Holmes&P. O. Janson. (1989). Ovulation in the isolated perfused rat ovary as documented by intravital microscopy. *Steroids*, 54, 481-490, 0039-128X (Print) 0039-128X (Linking)
- Lucci, C. M., M. A. Kacinskis, L. H. Lopes, R. Rumpf&S. N. Bao. (2004). Effect of different cryoprotectants on the structural preservation of follicles in frozen zebu bovine (*Bos indicus*) ovarian tissue. *Theriogenology*, 61, 1101-1114, 0093-691X (Print) 0093-691X (Linking)
- Martinez-Madrid, B., M. M. Dolmans, A. Van Langendonck, S. Defrere&J. Donnez. (2004). Freeze-thawing intact human ovary with its vascular pedicle with a passive cooling device. *Fertil Steril*, 82, 1390-1394, 0015-0282 (Print)
- Mclaughlin, M.&E. E. Telfer. (2010). Oocyte development in bovine primordial follicles is promoted by activin and FSH within a two-step serum-free culture system. *Reproduction*, 139, 971-978, 1741-7899 (Electronic) 1470-1626 (Linking)
- Milenkovic, M., A. Wallin, M. Ghahremani&M. Brannstrom. (2011). Whole sheep ovary cryopreservation: evaluation of a slow freezing protocol with dimethylsulphoxide. *J Assist Reprod Genet*, 28, 7-14, 1573-7330 (Electronic) 1058-0468 (Linking)
- Moniruzzaman, M., R. M. Bao, H. Taketsuru&T. Miyano. (2009). Development of vitrified porcine primordial follicles in xenografts. *Theriogenology*, 72, 280-288, 1879-3231 (Electronic) 0093-691X (Linking)
- Munn, C. S., L. C. Kiser, S. M. Wetzner&J. E. Baer. (1986). Ovary volume in young and premenopausal adults: US determination. Work in progress. *Radiology*, 159, 731-732, 0033-8419 (Print)
- Onions, V. J., M. R. Mitchell, B. K. Campbell&R. Webb. (2008). Ovarian tissue viability following whole ovine ovary cryopreservation: assessing the effects of sphingosine-1-phosphate inclusion. *Hum Reprod*, 23, 606-618, 1460-2350 (Electronic)
- Onions, V. J., R. Webb, A. S. Mcneilly&B. K. Campbell. (2009). Ovarian endocrine profile and long-term vascular patency following heterotopic autotransplantation of cryopreserved whole ovine ovaries. *Hum Reprod*, 24, 2845-2855, 1460-2350 (Electronic)
- Paynter, S. J., A. Cooper, B. J. Fuller&R. W. Shaw. (1999). Cryopreservation of bovine ovarian tissue: structural normality of follicles after thawing and culture in vitro. *Cryobiology*, 38, 301-309, 0011-2240 (Print) 0011-2240 (Linking)
- Pegg, D. E., M. C. Wusteman&S. Boylan. (1997). Fractures in cryopreserved elastic arteries. *Cryobiology*, 34, 183-192, 0011-2240 (Print) 0011-2240 (Linking)
- Revel, A., A. Elami, A. Bor, S. Yavin, Y. Natan&A. Arav. (2004). Whole sheep ovary cryopreservation and transplantation. *Fertil Steril*, 82, 1714-1715, 0015-0282 (Print)
- Rodgers, R. J.&H. F. Irving-Rodgers. (2010). Morphological classification of bovine ovarian follicles. *Reproduction*, 139, 309-318, 1741-7899 (Electronic) 1470-1626 (Linking)
- Salle, B., B. Demirci, M. Franck, C. Berthollet&J. Lornage. (2003). Long-term follow-up of cryopreserved hemi-ovary autografts in ewes: pregnancies, births, and histologic assessment. *Fertil Steril*, 80, 172-177, 0015-0282 (Print) 0015-0282 (Linking)
- Salle, B., B. Demirci, M. Franck, R. C. Rudigoz, J. F. Guerin&J. Lornage. (2002). Normal pregnancies and live births after autograft of frozen-thawed hemi-ovaries into ewes. *Fertil Steril*, 77, 403-408, 0015-0282 (Print)



- Salle, B., J. Lornage, B. Demirci, F. Vaudoyer, M. T. Poirel, M. Franck, R. C. Rudigoz & J. F. Guerin. (1999). Restoration of ovarian steroid secretion and histologic assessment after freezing, thawing, and autograft of a hemi-ovary in sheep. *Fertil Steril*, 72, 366-370, 0015-0282 (Print)
- Salle, B., J. Lornage, M. Franck, L. Isoard, R. C. Rudigoz & J. F. Guerin. (1998). Freezing, thawing, and autograft of ovarian fragments in sheep: preliminary experiments and histologic assessment. *Fertil Steril*, 70, 124-128, 0015-0282 (Print) 0015-0282 (Linking)
- Santos, R. R., C. Amorim, S. Cecconi, M. Fassbender, M. Imhof, J. Lornage, M. Paris, V. Schoenfeldt & B. Martinez-Madrid. (2010). Cryopreservation of ovarian tissue: an emerging technology for female germline preservation of endangered species and breeds. *Anim Reprod Sci*, 122, 151-163, 1873-2232 (Electronic) 0378-4320 (Linking)
- Schnorr, J., S. Oehninger, J. Toner, J. Hsiu, S. Lanzendorf, R. Williams & G. Hodgen. (2002). Functional studies of subcutaneous ovarian transplants in non-human primates: steroidogenesis, endometrial development, ovulation, menstrual patterns and gamete morphology. *Hum Reprod*, 17, 612-619, 0268-1161 (Print)
- Soede, N. M., P. Langendijk & B. Kemp. (2011). Reproductive cycles in pigs. *Anim Reprod Sci*, 124, 251-258, 1873-2232 (Electronic) 0378-4320 (Linking)
- Stevens, V. C. (1997). Some reproductive studies in the baboon. *Hum Reprod Update*, 3, 533-540, 1355-4786 (Print) 1355-4786 (Linking) Ting, A. Y., R. R. Yeoman, M. S. Lawson & M. B. Zelinski. (2011). In vitro development of secondary follicles from cryopreserved rhesus macaque ovarian tissue after slow-rate freeze or vitrification. *Hum Reprod*, 26, 2461-2472, 1460-2350 (Electronic) 0268-1161 (Linking) Vandeberg, J. L. (2004). Need for primate models in biomedical research. *Gynecol Obstet Invest*, 57, 6-8, 0378-7346 (Print) 0378-7346 (Linking) Wallin, A., M. Ghahremani, P. Dahm-Kahler & M. Brannstrom. (2009). Viability and function of the cryopreserved whole ovary: in vitro studies in the sheep. *Hum Reprod*, 24, 1684-1694, 1460-2350 (Electronic) 0268-1161 (Linking)
- Weinbauer, G. F., M. Niehoff, M. Niehaus, S. Srivastav, A. Fuchs, E. Van Esch & J. M. Cline. (2008). Physiology and Endocrinology of the Ovarian Cycle in Macaques. *Toxicol Pathol*, 36, 7S-23S, 1533-1601 (Electronic) 0192-6233 (Linking)
- Yang, M. Y. & J. E. Fortune. (2006). Testosterone stimulates the primary to secondary follicle transition in bovine follicles in vitro. *Biol Reprod*, 75, 924-932, 0006-3363 (Print) 0006-3363 (Linking)
- Yeoman, R. R., D. P. Wolf & D. M. Lee. (2005). Coculture of monkey ovarian tissue increases survival after vitrification and slow-rate freezing. *Fertil Steril*, 83 Suppl 1, 1248-1254, 0015-0282 (Print)
- Zhang, J. M., Y. Sheng, Y. Z. Cao, H. Y. Wang & Z. J. Chen. (2011). Cryopreservation of whole ovaries with vascular pedicles: vitrification or conventional freezing? *J Assist Reprod Genet*, 28, 445-452, 1573-7330 (Electronic) 1058-0468 (Linking)
- Zhang, J. M., Y. Sheng, Y. Z. Cao, H. Y. Wang & Z. J. Chen. (2011). Effects of cooling rates and ice-seeding temperatures on the cryopreservation of whole ovaries. *J Assist Reprod Genet*, 28, 627-633, 1573-7330 (Electronic) 1058-0468 (Linking)



## **Current Frontiers in Cryopreservation**

Edited by Prof. Igor Katkov

ISBN 978-953-51-0302-8

Hard cover, 462 pages

**Publisher** InTech

**Published online** 14, March, 2012

**Published in print edition** March, 2012

Almost a decade has passed since the last textbook on the science of cryobiology, *Life in the Frozen State*, was published. Recently, there have been some serious tectonic shifts in cryobiology which were perhaps not seen on the surface but will have a profound effect on both the future of cryobiology and the development of new cryopreservation methods. We feel that it is time to revise the previous paradigms and dogmas, discuss the conceptually new cryobiological ideas, and introduce the recently emerged practical protocols for cryopreservation. The present books, "Current Frontiers in Cryobiology" and "Current Frontiers in Cryopreservation" will serve the purpose. This is a global effort by scientists from 27 countries from all continents and we hope it will be interesting to a wide audience.

### **How to reference**

In order to correctly reference this scholarly work, feel free to copy and paste the following:

Milan Milenkovic, Cesar Díaz-Garcia and Mats Brännström (2012). Review on Ovarian Cryopreservation in Large Animals and Non-Human Primates, *Current Frontiers in Cryopreservation*, Prof. Igor Katkov (Ed.), ISBN: 978-953-51-0302-8, InTech, Available from: <http://www.intechopen.com/books/current-frontiers-in-cryopreservation/research-on-ovarian-cryopreservation-in-large-animals-and-non-human-primates>

**INTECH**  
open science | open minds

### **InTech Europe**

University Campus STeP Ri  
Slavka Krautzeka 83/A  
51000 Rijeka, Croatia  
Phone: +385 (51) 770 447  
Fax: +385 (51) 686 166  
[www.intechopen.com](http://www.intechopen.com)

### **InTech China**

Unit 405, Office Block, Hotel Equatorial Shanghai  
No.65, Yan An Road (West), Shanghai, 200040, China  
中国上海市延安西路65号上海国际贵都大饭店办公楼405单元  
Phone: +86-21-62489820  
Fax: +86-21-62489821

© 2012 The Author(s). Licensee IntechOpen. This is an open access article distributed under the terms of the [Creative Commons Attribution 3.0 License](#), which permits unrestricted use, distribution, and reproduction in any medium, provided the original work is properly cited.

IntechOpen

IntechOpen