

We are IntechOpen, the world's leading publisher of Open Access books Built by scientists, for scientists

5,200

Open access books available

129,000

International authors and editors

150M

Downloads

Our authors are among the

154

Countries delivered to

TOP 1%

most cited scientists

12.2%

Contributors from top 500 universities



WEB OF SCIENCE™

Selection of our books indexed in the Book Citation Index
in Web of Science™ Core Collection (BKCI)

Interested in publishing with us?
Contact book.department@intechopen.com

Numbers displayed above are based on latest data collected.
For more information visit www.intechopen.com



Electrocardiogram in an MRI Environment: Clinical Needs, Practical Considerations, Safety Implications, Technical Solutions and Future Directions

Thoralf Niendorf, Lukas Winter and Tobias Frauenrath
*Berlin Ultrahigh Field Facility (B.U.F.F.)
Max Delbrueck Center for Molecular Medicine, Berlin,
Germany*

1. Introduction

Magnetic Resonance Imaging (MRI) has been listed as the single most important medical innovation, on par with CT scanning (Fuchs & Sox 2001). In current clinical MRI ECG is being used for three major purposes. Firstly, heart motion, blood flow and blood pulsation are commonly dealt with using electrocardiogram (ECG) for synchronization of MR data acquisition with the cardiac cycle (Lanzer et.al. 1984) to address or compensate for cardiac activity related motion artifacts which is of paramount importance for an ever growing portfolio of cardiovascular MR (CMR) and neurovascular MR (NVMR) applications (Assomull et.al. 2007, Kelle et.al. 2008, Kramer et.al. 2008, Kwong & Korlakunta 2008, Niendorf et.al. 2006, Niendorf & Sodickson 2008, Niendorf & Sodickson 2006, Niendorf et.al. 2010, Pennell et.al. 2004, Schwitter 2008). Secondly, ECG is widely used to simultaneously register cardiac activity with MRI; for example to eliminate physiological fluctuations from brain activation maps derived from functional MRI studies (Purdon & Weisskoff 1998). Thirdly, there are an increasing number of clinical applications that require ECG monitoring prior to/after the MR examination while the patient is still in the MR environment but outside of the MR scanners bore using ECG devices as a patient emergency indicator.

ECG waveform acquisitions, ECG co-registration and ECG monitoring during MRI pose technical challenges and requires safety measures that will not be familiar to users of other conventional ECG technologies. For all those reasons, the basic principles of using ECG in an MRI environment and their implications for clinical MRI and MRI research are provided in this chapter. Key concepts, technical solutions, practical considerations and safety implications for cardiac gated MRI using electrocardiograms are outlined. Unsolved technical problems and unmet clinical needs are also considered carefully, in an attempt to stimulate the community to throw further weight behind the solutions of remaining issues. Driven by the limitations and motivated by the challenges of ECG, the need for novel cardiac gating/triggering technology is discussed. Current trends, such as the trend towards wireless techniques and the move to acoustic cardiac gating techniques, and their

implications for daily routine MR applications are surveyed. Demonstrable progress in gating/triggering technology and methodology is shown to provide further encouragement for the imaging community to tackle solutions of the outstanding issues. A concluding section of the presentation explores future directions fueled by a set of alternative gating/triggering techniques.

2. Clinical needs for ECG in MRI

MRI is not a real time imaging modality. In day-to-day clinical routine MRI data acquisition is commonly propagated over a series of cardiac cycles. Consequently, cardiac activity can degrade image quality, particularly when motion suppression techniques are unavailable, unsuccessful or not utilized. The challenge of synchronization of data acquisition with the cardiac cycle constitutes a practical impediment of MRI so that MRI of the heart, large vessels and other organs experiencing motion related to cardiac activity requires speed and efficiency due to cardiac motion and flow constraints, which dictate the viable window for data acquisition.

The need for speed and efficiency prompted the development of various cardiac motion compensation and cardiac motion synchronization techniques. Cardiac motion has been addressed by synchronization strategies exploiting (i) finger plethysmography (Lanzer et.al. 1984), (ii) cardiac activity related esophageal wall motion (Brau et.al. 2002), (iii) invasive left ventricular blood pressure gating (Pattynama et.al. 1994), (iv) Doppler ultrasound (Rubin et.al. 2000), (v) motion induced changes in the impedance match of RF-coils (Buikman et.al. 1988), (vi) self gating techniques (Buehrer et.al. 2008, Crowe et.al. 2004, Larson et.al. 2005, Larson et.al. 2004, Nijm et.al. 2008), (vii) finger pulse oximetry (POX) triggering/gating techniques and optic acoustic methods (Rengle et.al. 2007) including human and animal studies.

In current clinical MR practice, cardiac motion is commonly dealt with using electrocardiographic (ECG) gating/triggering techniques (Chia et.al. 2000, Fischer et.al. 1999, Lanzer et.al. 1985) to synchronize data acquisition with the cardiac cycle. For this purpose, prospective triggering and retrospective gating regimes have been established as summarized in Figure 1. Both triggering/gating regimes share the principle, that only portions of the data needed to form the final image are acquired per cardiac cycle. This data acquisition approach is called segmentation, with the full MR data set being acquired segment by segment over a series of consecutive R-R intervals.

Prospective triggering is used to position the data acquisition window into a specific cardiac phase as demonstrated in Figure 1. Commonly, prospectively triggered MR data acquisition is conducted during the cardiac rest period at mid-diastole to avoid cardiac motion artifacts as illustrated in Figure 1. For this purpose acquisition windows ranging from 50 ms to 200 ms duration are usually applied. If data acquisition is performed during cardiac phases other than the cardiac rest period image quality can be heavily diminished due to cardiac motion effects. For example, Figure 1 shows images of the right coronary artery (RCA) derived from MR angiography (MRA) using acquisition windows placed around systole. For acquisition windows placed at 265 ms and 432 ms in the cardiac cycle, MRAs of the RCA show severe degradation in image quality due to cardiac and coronary artery motion throughout the course of the acquisitions window.

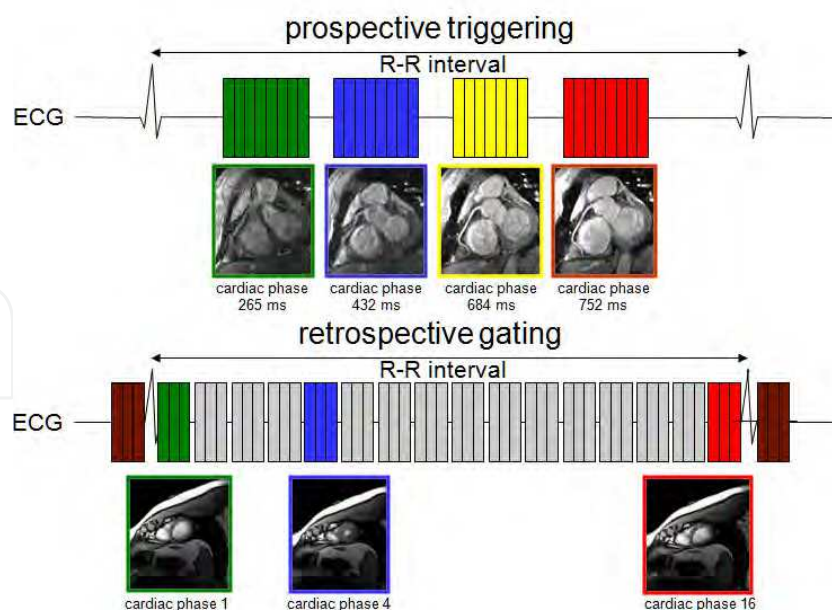


Fig. 1. Basic scheme of prospective triggering and retrospective gating in cardiac MRI using the electrocardiogram.

For retrospective gating data acquisition windows - each covering a specific cardiac phase of limited duration - are spread equidistantly across the entire R-R interval. This approach affords retrospective reconstruction of a series of images of the heart, which form a CINE movie. These movies are used to track myocardial contraction and relaxation for the goal of myocardial (dys)function assessment or cardiac chamber quantification. If the acquisition windows are kept short (20 ms to 50 ms) image quality is free of motion artifacts while long acquisition windows (larger than 50 ms) may hamper image quality due to cardiac motion effects; in particular at systole as illustrated in Figure 2.

To summarize, prospective triggering and retrospective gating regimes require a reliable tracking and monitoring of the cardiac cycle. The quality and stability of the QRS complex detection throughout the exam will dictate the efficiency of scanning and the overall image quality of scans. Mis-detection or mis-registration of the ECG's R-wave can corrupt image quality severely.

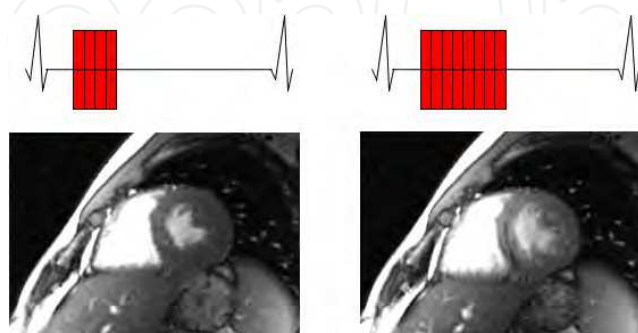


Fig. 2. Short axis views of the heart derived from CINE MRI illustrating the impact of cardiac motion on image quality. Two different durations for the acquisition window were used: (left) short acquisition window (50 ms, marked in red), (right) long acquisition window (200 ms, marked in red).

3. Practical considerations

In current clinical MR practice, MR scanners are equipped with extra hardware for ECG signal detection and processing. The basic setup for ECG monitoring in a clinical MRI environment is shown in Figure 3. This includes (i) ECG electrodes, leads and short high impedance cables, (ii) signal preamplifier and converter box, (iii) optical-fiber or wireless connections used for ECG signal transfer, (iv) physiological monitoring unit for signal processing and trigger generation. The signal flow in Figure 3 is from the left (signal collection using ECG-electrodes), through the middle (signal processing), to the right (input to the MR-systems internal ECG circuitry).

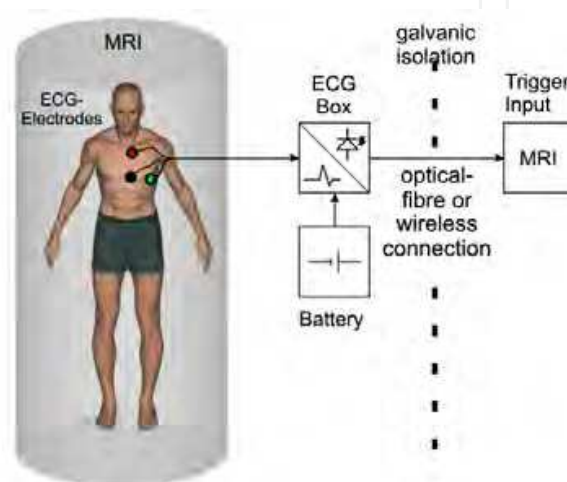


Fig. 3. Basic setup for ECG monitoring in a clinical MRI environment.

Patient preparation such as skin preparation, electrode and lead positioning are of profound importance for any successful ECG monitoring in an MRI environment. Careful skin preparation includes (i) removal of chest hair by shaving, if applicable, (ii) cleaning of the skin with special abrasive skin prepping gel and (iii) the use of a clean gauze pad to thoroughly dry the skin area where the surface electrodes will be positioned. Typical placement of ECG surface electrodes in an MRI environment might differ from ECG electrode positioning commonly used in conventional ECG monitoring. Admittedly, a stronger signal can be achieved from widely spaced electrodes. However, this approach can induce artifacts in the ECG trace in an MRI environment. Consequently, in an MRI environment ECG electrodes are placed relatively close to each other on the left hand side of the upper torso as illustrated in Figure 4. Obtaining a good ECG signal requires the lead alignment with the strongest ECG vector and a good adhesion between the ECG electrode and the patient's skin. It is highly recommended to use electrodes before their expiration date only since old electrodes can be dried out, which will result in bad electrical contact.

The ECG signal transferred into the scanners internal circuitry interfaces is used for gating and triggering of MR acquisitions. For this purpose different parameters can be modified on the scanners user interface to time MR imaging. Those parameters include a trigger delay to place the data acquisition at any phase in the cardiac cycle, the number of cardiac phases to be imaged and a trigger window to allow changes in the heart rate of 10%-20% during the course of segmented MR acquisitions. If changes in the heart rate exceed the duration of the trigger window, arrhythmia rejection will be applied. This means that MR data acquired

during cardiac cycles with a duration shorter or longer than the predefined range will be discarded and re-acquired. Of course, this approach increases the scan time. Hence a very limited number of arrhythmia rejections are accepted for breath-held scans.

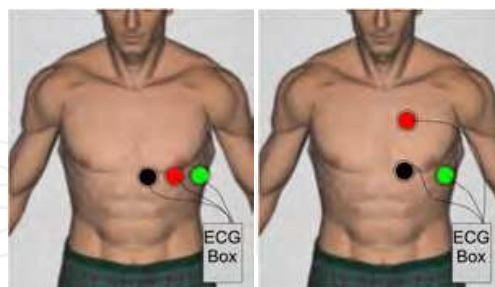


Fig. 4. Typical placement of ECG surface electrodes in an MRI environment. (left) placement in a parallel order which is beneficial for ultra high magnetic fields and (right) the traditional placement of ECG electrodes at field strengths of 1.5 T, which is used by the majority of clinical MR scanner.

4. Safety implications and safety measures

Conventional ECG electrodes are not classified as being MR-safe due to the use of low impedance conductors or ferromagnetic components. ECG, being an inherently electrical measurement with electrically active components (Lanzer et.al. 1985), does carry a risk of surface heating of patients' skin and even of skin burns resulting from induction of high voltages in ECG electrodes or ECG cables due to interactions with RF fields used in MRI (Health 2010, Kugel et.al. 2003, Lange & Nguyen 2006, Shellock & Cruess 2004, Shellock & Kanal 1996). The use of non MR safe ECG hardware has even caused an incident in the MR bore, where high-voltage induction in ECG wiring caused a fire (Kugel et.al. 2003).

Various safety measures and technologies have been implemented on clinical MR scanners to safeguard patients with the ultimate goal of avoiding disasters and injuries due to ECG hardware and its interaction with electromagnetic fields. If electrical ECG leads are used they should not be allowed to form loops which otherwise bear the potential to serve as an RF antenna which might result in burning hazards. Safety measures also involve the use of ECG electrodes being classified as MR-safe. Consequently, user manuals of clinical scanners outline explicitly that MR-safe electrodes which are made available through the MR vendor's accessories catalogue must be used.

Safety measures also recommend the use of high impedance leads instead of conventional low impedance leads. Figure 5 demonstrates how a low impedance wire increases the Rf power deposition inside the human body. Keeping ECG leads as short as possible is essential. In the ideal case ECG leads shorter than the radio-frequency (RF) wave length need to be employed. For this reason the user manuals of clinical MR systems emphasize or even dictate that only ECG cables and ECG equipment provided by the MR vendor must be used. To keep ECG leads short, fiber optic leads or wireless connections are used in modern systems for signal transfer between the battery powered ECG converter box and the MRI system.

The clinical need of ECG monitoring prior/after MRI examinations bears the risk of leading to RF induced skin burns since patients might undergo an MRI scan without removing conventional ECG electrodes commonly used in the telemetry unit. The FDA's MAUDE data

base reports several skin burns in for the period 2005-2010 due to induction of high voltages in ECG hardware due to interaction with RF fields (Health 2010), the main cause being that conventional ECG leads used for patient monitoring were not removed or replaced prior to the MR scan.

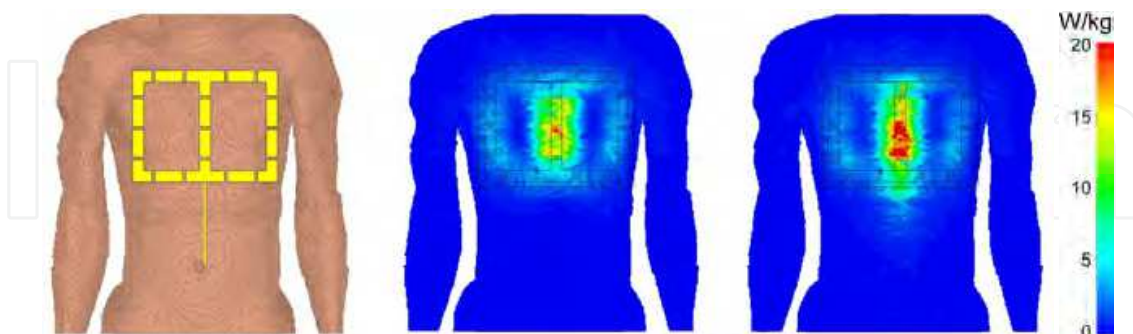


Fig. 5. Signal absorption rate (SAR) simulations which demonstrate the impact of low impedance ECG leads in a human voxel model (left). For this purpose a 4 channel transmit/receive cardiac RF coil was used. The lead positioning mimics the clinical situation where ECG leads are positioned between the coil and the surface of the anterior chest. Point SAR simulations of the cardiac coil at 7T without the lead (middle) and with the lead (right) are shown. RF power deposition is pronounced in the presence of the leads.

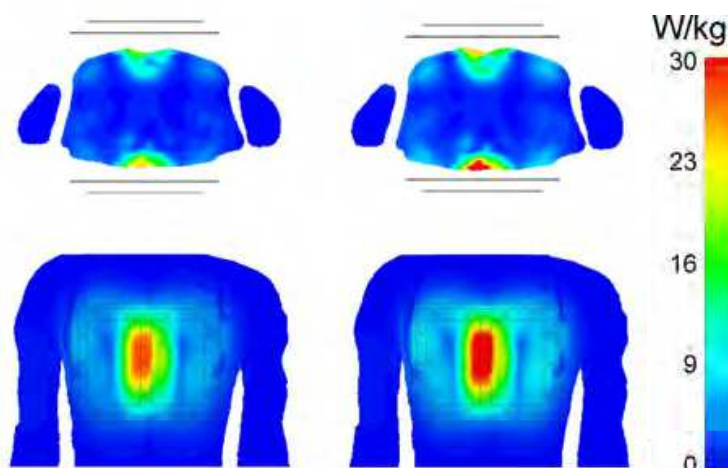


Fig. 6. Axial and coronal views of the upper torso derived from signal absorption rate (SAR_{10g}) simulations. The simulations demonstrate the impact of extra padding for the purpose of keeping RF coils in a safe distance from ECG electrodes. For padding an extra layer with a thickness of 1cm was inserted between the anterior and posterior section of the coil and the anterior and posterior upper chest. For the simulations a 4 channel transmit/receive RF cardiac coil was used together with an accepted power of 30 W without padding (left) and with padding (right). With padding a maximum local SAR_{10g} value of 18.1 W/kg is reached. Without padding the maximum local SAR_{10g} value increased to 21.2 W/kg. This value would exceed the IEC safety guidelines of 20 W/kg.

The manufacturer's user manuals for RF coils advice the use of extra padding for keeping RF coils in a safe distance from ECG electrodes being mounted to the chest. This measure has been implemented to avoid ECG electrodes being positioned in areas of high local

electromagnetic (EM) fields caused by the RF coil's. The influence of extra padding on the SAR distribution can be seen in Figure 6.

5. Interference of ECG with magnetic fields

Electrocardiograms acquired in the MR environment are not a patient emergency condition indicator due to ECG waveform distortions. If brought into a magnetic field ECG being an electrical measurement is corrupted by interference with electromagnetic fields and by magneto-hydrodynamic (MHD) effects (Frauenrath et.al. 2009, Stuber et.al. 2002, Togawa et.al. 1967). MHD potential is induced when a conductive fluid travels through a magnetic field. The interference between the magnetic field and the conductive fluid generates a voltage perpendicular to the magnetic field lines and the direction of the fluid flow (Togawa et.al. 1967). The MHD voltage (V) can be described by:

$$V = \int_0^L \mathbf{u} \times \mathbf{B} \, dL \quad (1)$$

where \mathbf{B} is the magnetic flux density (T), \mathbf{u} is the velocity of the fluid (m/s), and dL is the distance vector between electrodes (Togawa et.al. 1967).

In the clinical setting the MHD effect creates voltages related to blood flow which are superimposed to the ECG potential as surveyed in Figure 7. The MHD effect is pronounced during cardiac phases of systolic aortic flow, which results in a severe distortion of the ECG's S-T segment. The susceptibility to electromagnetic field (EMF) interference manifests itself in ECG waveform distortions already apparent in ECG traces acquired in clinical 1.5 T MR scanners (Becker et.al. 2009). As high and ultrahigh field MR becomes more widespread, the propensity of ECG recordings to MHD effects is further pronounced (Brandts et.al. 2010, Frauenrath et.al. 2009, Snyder et.al. 2009) as demonstrated in Figure 7. Figure 7 shows ECG traces obtained at magnetic field strengths of 1.5 T, 3.0 T and 7.0 T which were acquired simultaneously to prospectively cardiac gated 3D phase contrast MR angiography acquisitions. At 3.0 T severe distortions were detected for cardiac phases around the S-T segment. At 7.0 T the MHD contributions gain amplitudes which are in the order of magnitude of or even larger than the amplitude of the ECG's R-wave.

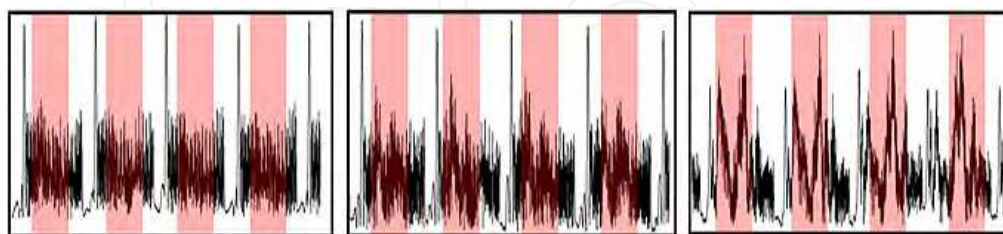


Fig. 7. Unfiltered electrocardiograms (ECG) obtained at magnetic field strengths of 1.5 T (left), 3.0 T (middle) and 7.0 T (right). ECG waveforms were susceptible to T-wave elevation and other waveform distortions shaded in red which increased with field strengths and were pronounced at 7.0 T.

Artifacts in the ECG trace and severe T-wave elevation might be mis-interpreted as R-waves resulting in misdetection of cardiac activity or erroneous cardiac gating together with motion corrupted image quality. These artifacts render MHD effects detrimental for a

reliable synchronization of MRI or registration of MRI data with the cardiac cycle and constitute a practical impediment as outlined in Figure 8. Figure 8 shows mid-ventricular, short axis views of the heart together with whole R-R interval time series of one-dimensional projections along the profile (dotted line) marked in the short axis view (top), trigger detection tickmarks used for synchronization of MR imaging with the cardiac cycle which were obtained from a single subject over 18 cardiac cycles after temporal realignment using cross correlation and reassignment (middle) and ECG signal waveforms obtained from the same single subject over 18 cardiac cycles (bottom). In spite of ECG's severe signal distortion faultless ECG triggering was observed for the example shown on the left hand side of Figure 8. In this example of correct recognition of the onset of cardiac activity, ECG gated 2D CINE MRI was found to be immune to the effects of cardiac motion as demonstrated by the sharp delineation between blood and myocardium throughout the entire cardiac cycle. An example of

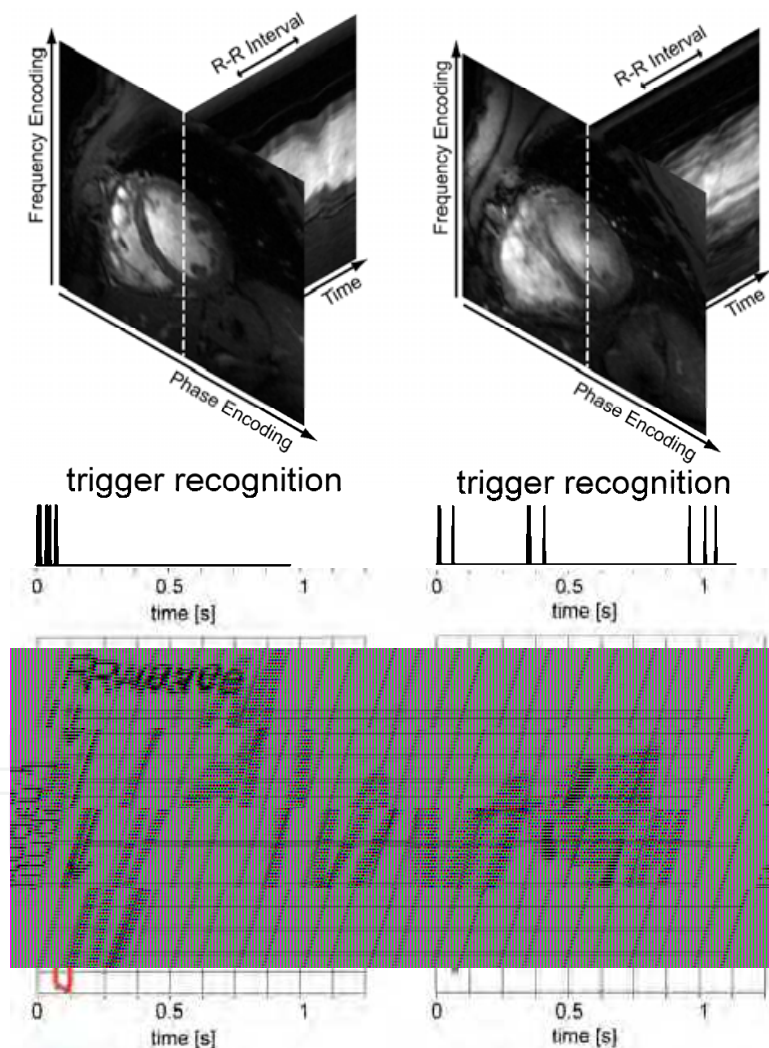


Fig. 8. Top) Mid-ventricular, short axis views of the heart together with whole R-R interval time series of one-dimensional projections along the profile (dotted line) marked in the short axis view. (Middle) Trigger recognition tick marks. Bottom) ECG waveforms obtained from a single subject over 18 cardiac cycles. (Left) Faultless Gating: Clinically acceptable image quality because of the absence of cardiac motion induced blurring; (Right) Erroneous ECG Gating, which diminished the image quality due to cardiac motion induced image blurring.

erroneous ECG trigger detection is shown on the right hand side of Figure 8. Here ECG gated 2D CINE MRI was prone to severe cardiac motion artifacts due to R-wave mis-registration which induced reduction in myocardium/blood contrast and image sharpness. To this end, R-wave mis-registration has been consistently reported for ECG triggered CMR at 7.0 T (Brandts et.al. 2010, Maderwald et.al. 2010). In one report 20% of the healthy subjects needed to be excluded from left ventricular function assessment (Brandts et.al. 2010). In another study 80% of the acquisitions were gated using pulse oximetry due to MHD artifact induced ECG-triggering problems (Maderwald et.al. 2010).

6. Patient monitoring in the fringe field of a MR scanner

Although ECG is known to be non-diagnostic within the bore of any clinical MR system due to magneto-hydrodynamic (MHD) effects, there are an increasing number of clinical indications that require ECG monitoring prior to/after the MR scan or in the MR scanner room using conventional 12 leads ECG devices as a patient emergency indicator (Cheng et.al. 2003, Lubbers et.al. 2011, Paetsch et.al. 2004, Wahl et.al. 2004). For example, in addition to continuous monitoring during stress testing which is commonly used in cardiovascular MRI, ECG monitoring should resume as quickly as possible after post stress MR imaging - ideally while the patient is still on the MRI table or in the fringe magnetic field of the MR scanner as outlined by Jekic et.al. (Jekic et.al. 2010). This monitoring approach requires the ECG signal to stay within the accuracy limits defined by the guidelines of the American Heart Association (AHA) for automated electrocardiography (Bailey et.al. 1990). These guidelines outline that deviation of the real ECG trace due to magneto-hydrodynamic effects from the true, uncompromised waveform taken outside of the MR environment may not exceed 0.025 mV or 5%, whichever is greater. A recent publication reported that this threshold can be achieved in the fringe field of an MRI system for stray magnetic field strengths lower than 70 mT (Jekic et.al. 2010). Also, the clinical need of ECG monitoring prior/after MRI bears the risk of leading to RF induced skin burns since patients might undergo an MRI scan without removing conventional ECG electrodes commonly used in the telemetry unit.

7. ECG alternatives for cardiac gated/triggered MRI

Various approaches have been proposed to cancel, correct for, bypass or extract MHD blood flow potential induced artifacts from the surface electrocardiogram. These efforts include optimization of ECG electrode placement (Dimick et.al. 1987), R-wave detection algorithm based on the vector cardiogram (Fischer et.al. 1999), and sophisticated ECG signal processing (Nijm et.al. 2008).

Realizing the constraints of conventional ECG, a MR-stethoscope has been proposed for the pursuit of robust and safe clinical cardiac gated/triggered MRI (Frauenrath et.al. 2008, Niendorf et.al. 2010). In contrast to ECG-triggering the MR-stethoscope employs acoustic instead of electrical signals. For cardiac gating/triggering, the first heart tone of the phonocardiogram, which marks the onset of the acoustic cardiac cycle, is selected. The acoustic gating device meets the following criteria:

- free of interference with electromagnetic fields
- immunity to magneto-hydrodynamic effects at 1.5 T, 3.0 T and 7.0 T
- compliance with the safety regulations on medical devices defined by the CE and FDA
- support of prospective- and retrospective cardiac gating/triggering regimes

As shown by the block diagram in Figure 9, the acoustic gating device comprises three main components: (i) an acoustic sensor, (ii) a signal processing unit and (iii) a coupler unit to the MRI system (Frauenrath et.al. 2008). Like the chest piece of a common stethoscope, the acoustic sensor, located on the patient's chest, registers the heart sounds. The signal processing unit detects the first heart sound and transforms it into a trigger signal, which mimics the basic waveform of the ECG. The MR-Stethoscope is compatible with common MRI scanners and does not require any hardware or software changes. It should be noted that the R-wave which marks the electrophysiological onset of the cardiac cycle and the 1st heart tone which represents the onset of the acoustic cardiac cycle are separated by a physiological delay of $\Delta t=30$ ms (Rangayyan & Lehner 1987). However, it was found that the delay between ECG and the phonocardiogram is heart rate independent (Frauenrath et.al. 2008).

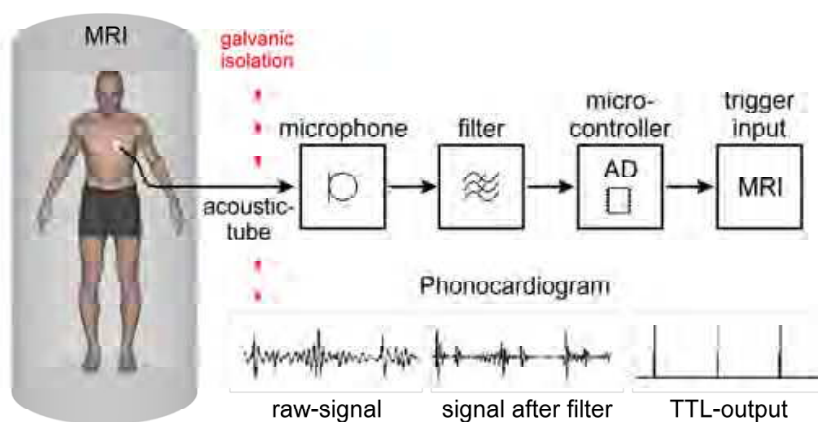


Fig. 9. Block diagram of acoustic cardiac triggering (ACT). ACT is free of interferences from electromagnetic fields and magneto-hydrodynamic effects, and provides a reliable trigger signal free of jitter even in the presence of free breathing.

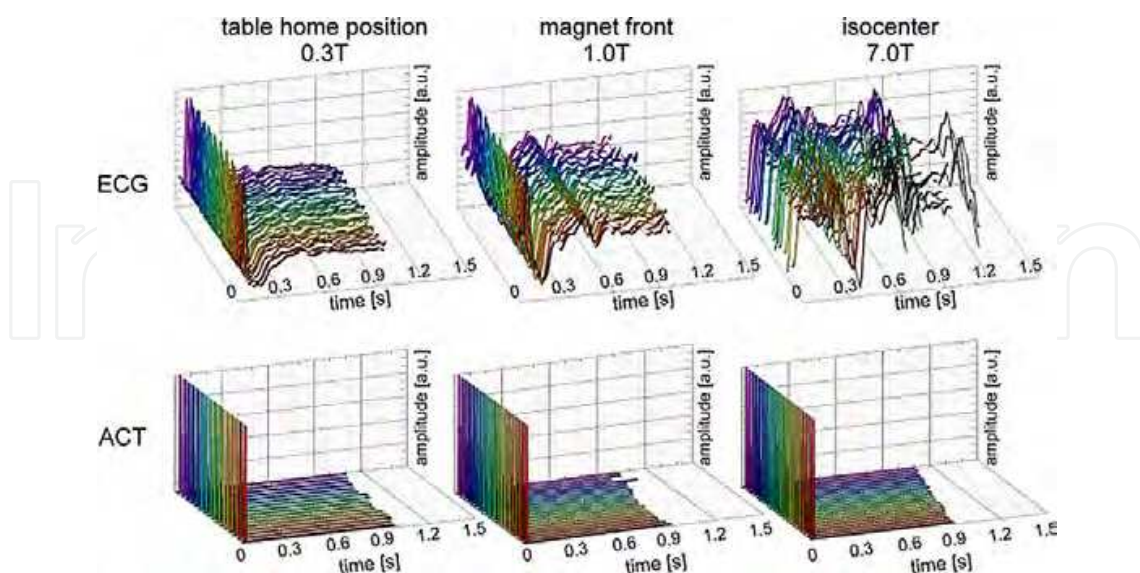


Fig. 10. ECG (top) and acoustic trigger signal (bottom) traces acquired at three different field strengths using the MRI scanners internal physiological signal processing unit. Severe signal distortion occurred in the ECG signal obtained at the magnet's isocenter, whereas the trigger signal derived from ACT remains undistorted

The use of the MR stethoscope substantially reduces the complexity of patient preparation for an MR examination by obviating the need to set up ECG-electrodes and position ECG-leads. Even more, the acoustic triggering (ACT) approach offers suitability for all magnetic field strengths (Frauenrath et.al. 2009, Frauenrath et.al. 2010) as indicated in Figure 10. ACT presents immunity to electromagnetic interference and magneto-hydrodynamic effects as demonstrated in Figure 10 (Frauenrath et.al. 2009, Frauenrath et.al. 2010) which helps to reduce - if not to eliminate - the effect of R-wave mis-registration which is frequently encountered in ECG-triggered acquisitions, in particular at high and ultrahigh magnetic field strengths (Brandts et.al. 2010, Brants et.al. 2010, Maderwald et.al. 2010).

Examples of cardiac images derived from ECG and ACT gated/triggered MR imaging are shown in Figure 11 including retrospective gating and prospective triggering regimes. For retrospective gating Figure 11 shows four chamber views of the heart derived from cardiac gated 2D CINE MRI. ECG gated 2D CINE MRI was prone to severe cardiac motion artifacts if R-wave mis-registration occurred, which resulted in cardiac motion induced blurring. Unlike ECG, ACT gating produced images free of cardiac motion artefacts as illustrated in Figure 11. For prospective triggering examples derived from free breathing coronary artery MR imaging, an application which exhibits pronounced sensitivity to cardiac motion are depicted in Figure 11. For example, the displacement of the right coronary artery (RCA) is in the order of 3 cm to 4 cm throughout the course of cardiac cycle. Mis-triggering due to distortions in the ECG-trace resulted in image blurring embodied by reduced RCA vessel sharpness and diminished RCA vessel delineation. Robust and reliable triggering using ACT revealed excellent image quality for CAI, which is free of motion artifacts.

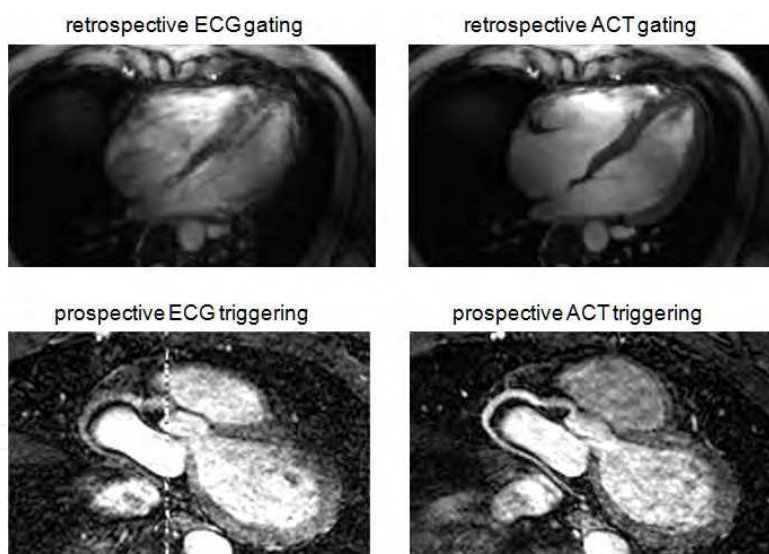


Fig. 11. Top: Four chamber views of the heart derived from ECG (left) and ACT (right) gated 2D CINE MRI at 7.0 T. Unlike ECG which caused mis-triggering ACT gated acquisitions provided a reliable trigger signal together with sharp images. Bottom: Maximum intensity projections (MIP) obtained from free breathing, cardiac gated CAI using ECG triggering (left) and ACT triggering (right) at 1.5 T. Mis-triggering due to distortions in the ECG-trace resulted in image blurring embodied by reduced vessel sharpness and diminished vessel delineation. The DC-offset seen in the centre line of the ECG-gated images is due to RF interferences with the electronics of the ECG-device's A/D converter, which is battery powered and usually positioned on the anterior chest of the volunteer. Robust and reliable triggering using ACT revealed excellent image quality for CAI, which is free of motion artifacts.

The acoustic approach also appears to be an excellent candidate for gating acquisitions in areas located distant from the heart. In clinical practice, areas of interest are usually positioned at the magnet's isocenter. Consequently, the position of the heart together with the position of the ECG electrodes in non-cardiac studies is off-center, closer to the rear or front end bell of the MR scanner gradient coils, which amplifies changes in dB/dt during gradient coil switching which is used for spatial encoding. This geometrical constraint increases the interference between the electrophysiological signals and electro-magnetic fields generated by the gradients, leading to pronounced distortion of the ECG signal. The capability of local acoustic gating can in principal serve to alleviate substantially the fundamental problem of erroneous ECG-gating for off-center positions of the heart. Fetal cardiovascular MRI is another emerging application (Saleem 2008) which suffers from synchronization problems and hence is a driving force for further advancement of the MR-stethoscope towards capturing fetal phonocardiograms at (ultra)high magnetic fields.

8. Future directions

Demonstrable progress in ECG technology and methodology used in the MRI environment is providing encouragement for the imaging community to tackle the solution of the outstanding issues. This includes the refinement and redesign of ECG hardware and devices used in a MR environment but also the broad move towards alternative cardiac gating/triggering approaches. One important development on the hardware horizon is the advent of acoustic triggering techniques using pressure transducers or optical microphones for signal detections. Future development also involve the development of even more sophisticated ECG signal processing algorithms to compensate for MHD contributions to the ECG signal. Even more, contrary to the common notion that considers MHD being adverse concomitants or detrimental artifacts of traditional ECG acquired in a magnetic field environment it is conceptually appealing to explore the merits of MHD effects for the pursuit of cardiac gated MRI. It has been recently proposed that the MHD effect being inherently sensitive to magnetic flux density, flow, orientation of flow with respect to the magnetic field lines and velocity of an electrical charge carrier such as blood in a magnetic field (Togawa et.al. 1967). These characteristics can be put to use as an alternative approach for registration of cardiac activity and for cardiac gating/triggering (Frauenrath et.al. 2011). Early applications include acquisition of MHD waveforms in surface areas close to the heart and the aortic arch but also in peripheral regions including surface areas close to the right common carotid artery, close to the forearm's ulnar artery and close to the lower leg's posterior tibial artery (Frauenrath et.al. 2011).

In any case, the unmet clinical needs and (un)solved problems of cardiovascular MRI are likely to motivate novel approaches used for the assessment of cardiac activity and for the tracking of cardiac contraction and relaxation. One intriguing development on the methodology horizon is the non-contact detection of myocardium's mechanical activity by ultrawideband RF-radar and its interpretation applying electrocardiography (Thiel et.al. 2009, Thiel et.al. 2009). To drive this approach into a clinical application an understanding of how the myocardium's mechanic is rendered by reflected and post processed UWB radar signals is essential (Thiel et.al. 2009, Thiel et.al. 2009). To this end, pioneering research is moved forward to correlate the UWB signal with the ECG through simultaneous acquisition and evaluation of radar signals with signals from a high-resolution electrocardiogram (Thiel et.al. 2009, Thiel et.al. 2009).

9. Conclusion

In short, while today's development of ECG techniques remain in a state of creative flux, productive engagement in this area continues to drive further developments with the ultimate goal of enhancing the capabilities of ECG in a modern high and ultrahigh field MR environment for synchronization of MR data acquisition with the cardiac cycle or for co-registration of functional MR mapping techniques with cardiac activity. Such improvements would benefit an ever growing set of indications for cardiovascular and neurovascular MR applications; in particular those which aim for high spatial resolution which can be easily compromised by physiological motion. If practical challenges can be overcome with appropriate hardware and post-processing design, an optimistically-inclined practitioner might envisage ECG technology tailored for MR which might even open the door to patient monitoring in an MR environment. While this is, for the moment, merely a vision, it continues to motivate new basic and clinical research.

10. Acknowledgment

The authors gratefully acknowledge the enthusiastic researchers at the Berlin Ultrahigh Field Facility (B.U.F.F.), Berlin, Germany, who kindly contributed examples of their pioneering work and other valuable assistance.

11. References


- Assomull RG; Pennell DJ & Prasad SK. (2007) Cardiovascular magnetic resonance in the evaluation of heart failure. *Heart*; 93:985-992.
- Bailey JJ; Berson AS; Garson A, Jr. (1990) Recommendations for standardization and specifications in automated electrocardiography: bandwidth and digital signal processing. A report for health professionals by an ad hoc writing group of the Committee on Electrocardiography and Cardiac Electrophysiology of the Council on Clinical Cardiology, American Heart Association. *Circulation*; 81:730-739.
- Becker M; Frauenrath T; Hezel F. (2009) Comparison of left ventricular function assessment using phonocardiogram- and electrocardiogram-triggered 2D SSFP CINE MR imaging at 1.5 T and 3.0 T. *Eur Radiol*.
- Brandts A; Westenberg JJ; Versluis MJ. (2010) Quantitative assessment of left ventricular function in humans at 7 T. *Magn Reson Med*.
- Brandts A; Westenberg JJ; Versluis MJ. (2010) Quantitative assessment of left ventricular function in humans at 7 T. *Magn Reson Med*; 64:1471-1477.
- Brants A; Versluis M; de Roos A. (2010) Quantitative comparison of left ventricular cardiac volume, mass and function obtained at 7 Tesla with "gold standard" values at 1.5 Tesla. *Proc. Intl. Soc. Mag. Reson. Med.*; 18:1299; Stockholm, SE.
- Brau AC; Wheeler CT; Hedlund LW. (2002) Fiber-optic stethoscope: a cardiac monitoring and gating system for magnetic resonance microscopy. *Magn Reson Med*; 47:314-321.
- Buehrer M; Curcic J; Boesiger P. (2008) Prospective self-gating for simultaneous compensation of cardiac and respiratory motion. *Magn Reson Med*; 60:683-690.
- Buikman D; Helzel T & Roschmann P. (1988) The rf coil as a sensitive motion detector for magnetic resonance imaging. *Magn Reson Imaging*; 6:281-289.

- Cheng CP; Schwandt DF; Topp EL. (2003) Dynamic exercise imaging with an MR-compatible stationary cycle within the general electric open magnet. *Magn Reson Med*; 49:581-585.
- Chia JM; Fischer SE; Wickline SA. (2000) Performance of QRS detection for cardiac magnetic resonance imaging with a novel vectorcardiographic triggering method. *J Magn Reson Imaging*; 12:678-688.
- Crowe ME; Larson AC; Zhang Q. (2004) Automated rectilinear self-gated cardiac cine imaging. *Magn Reson Med*; 52:782-788.
- Dimick RN; Hedlund LW; Herfkens RJ. (1987) Optimizing electrocardiograph electrode placement for cardiac-gated magnetic resonance imaging. *Invest Radiol*; 22:17-22.
- Fischer SE; Wickline SA & Lorenz CH. (1999) Novel real-time R-wave detection algorithm based on the vectorcardiogram for accurate gated magnetic resonance acquisitions. *Magn Reson Med*; 42:361-370.
- Frauenrath T; Niendorf T & Kob M. (2008) Acoustic method for synchronization of Magnetic Resonance Imaging (MRI). *Acta Acustica united with Acustica*:148-155.
- Frauenrath T; Kozerke S; Henzel F. (2009) The MR-stethoscope: safe cardiac gating free of interference with electro-magnetic fields at 1.5 T, 3.0 T and 7.0 T. *Journal of Cardiovascular Magnetic Resonance*; 11:O78.
- Frauenrath T; Hezel F; Heinrichs U. (2009) Feasibility of cardiac gating free of interference with electro-magnetic fields at 1.5 Tesla, 3.0 Tesla and 7.0 Tesla using an MR-stethoscope. *Invest Radiol*; 44:539-547.
- Frauenrath T; Hezel F; Renz W. (2010) Acoustic cardiac triggering: a practical solution for synchronization and gating of cardiovascular magnetic resonance at 7 Tesla. *J Cardiovasc Magn Reson*; 12:67.
- Frauenrath T; Dieringer M; Patel N. (2011) From Artifact to Merit: Cardiac Gated MRI at 7T and 3T Using Magneto-Hydrodynamic Effects for Synchronization. 4611; Montreal.
- Fuchs VR & Sox HC, Jr. (2001) Physicians' views of the relative importance of thirty medical innovations. *Health Aff (Millwood)*; 20:30-42.
- In: U.S. Food and Drug Administration. Center for Devices and Radiological Health. (2010) MAUDE data base reports of adverse events involving medical devices. <http://www.accessdata.fda.gov/scripts/cdrh/cfdocs/cfMAUDE/search.CFM>. accessed November 15, 2010.
- Jekic M; Ding Y; Dzwonczyk R. (2010) Magnetic field threshold for accurate electrocardiography in the MRI environment. *Magn Reson Med*; 64:1586-1591.
- Kelle S; Weiss RG & Stuber M. (2008) Coronary magnetic resonance imaging. *Curr Pharm Des*; 14:1778-1786.
- Kramer CM; Barkhausen J; Flamm SD. (2008) Standardized cardiovascular magnetic resonance imaging (CMR) protocols, society for cardiovascular magnetic resonance: board of trustees task force on standardized protocols. *J Cardiovasc Magn Reson*; 10:35.
- Kugel H; Bremer C; Puschel M. (2003) Hazardous situation in the MR bore: induction in ECG leads causes fire. *Eur Radiol*; 13:690-694.
- Kwong RY & Korklunkta H. (2008) Diagnostic and prognostic value of cardiac magnetic resonance imaging in assessing myocardial viability. *Top Magn Reson Imaging*; 19:15-24.

- Lange S & Nguyen QN. (2006) Cables and electrodes can burn patients during MRI. *Nursing*; 36:18.
- Lanzer P; Botvinick EH; Schiller NB. (1984) Cardiac imaging using gated magnetic resonance. *Radiology*; 150:121-127.
- Lanzer P; Barta C; Botvinick EH. (1985) ECG-synchronized cardiac MR imaging: method and evaluation. *Radiology*; 155:681-686.
- Larson AC; White RD; Laub G. (2004) Self-gated cardiac cine MRI. *Magn Reson Med*; 51:93-102.
- Larson AC; Kellman P; Arai A. (2005) Preliminary investigation of respiratory self-gating for free-breathing segmented cine MRI. *Magn Reson Med*; 53:159-168.
- Lubbers DD; Rijlaarsdam-Hermsen D; Kuijpers D. (2011) Performance of adenosine "stress-only" perfusion MRI in patients without a history of myocardial infarction: a clinical outcome study. *Int J Cardiovasc Imaging*.
- Maderwald S; Nassenstein K; Orzada S. (2010) MR imaging of cardiac wall-motion at 1.5T and 7T: SNR and CNR comparison. *Proc. Intl. Soc. Mag. Reson. Med.*; 18:1299; Stockholm, SE.
- Niendorf T & Sodickson DK. (2006) Parallel imaging in cardiovascular MRI: methods and applications. *NMR Biomed*; 19:325-341.
- Niendorf T; Hardy CJ; Giaquinto RO. (2006) Toward single breath-hold whole-heart coverage coronary MRA using highly accelerated parallel imaging with a 32-channel MR system. *Magn Reson Med*; 56:167-176.
- Niendorf T & Sodickson DK. (2008) Highly accelerated cardiovascular MR imaging using many channel technology: concepts and clinical applications. *Eur Radiol*; 18:87-102.
- Niendorf T; Sodickson DK; Krombach GA. (2010) Toward cardiovascular MRI at 7 T: clinical needs, technical solutions and research promises. *Eur Radiol*; 20:2806-2816.
- Nijm GM; Swiryn S; Larson AC. (2008) Extraction of the magnetohydrodynamic blood flow potential from the surface electrocardiogram in magnetic resonance imaging. *Med Biol Eng Comput*; 46:729-733.
- Nijm GM; Sahakian AV; Swiryn S. (2008) Comparison of self-gated cine MRI retrospective cardiac synchronization algorithms. *J Magn Reson Imaging*; 28:767-772.
- Paetsch I; Jahnke C; Wahl A. (2004) Comparison of dobutamine stress magnetic resonance, adenosine stress magnetic resonance, and adenosine stress magnetic resonance perfusion. *Circulation*; 110:835-842.
- Pattynama PM; van der Velde ET; Steendijk P. (1994) Cardiovascular MR imaging: pressure-gating using the arterial pressure signal from a conventional ferromagnetic micromanometer-tip catheter. *Magn Reson Imaging*; 12:531-534.
- Pennell DJ; Sechtem UP; Higgins CB. (2004) Clinical indications for cardiovascular magnetic resonance (CMR): Consensus Panel report. *Eur Heart J*; 25:1940-1965.
- Purdon PL & Weisskoff RM. (1998) Effect of temporal autocorrelation due to physiological noise and stimulus paradigm on voxel-level false-positive rates in fMRI. *Hum Brain Mapp*; 6:239-249.
- Rangayyan RM & Lehner RJ. (1987) Phonocardiogram signal analysis: a review. *Crit Rev Biomed Eng*; 15:211-236.
- Rengle A; Baboi L; Saint-Jalmes H. (2007) Optical cardiac and respiratory device for synchronized MRI on small animal. *Conf Proc IEEE Eng Med Biol Soc.*:2046-2049.

- Rubin JM; Fowlkes JB; Prince MR. (2000) Doppler US gating of cardiac MR imaging. *Acad Radiol*; 7:1116-1122.
- Saleem SN. (2008) Feasibility of MRI of the fetal heart with balanced steady-state free precession sequence along fetal body and cardiac planes. *AJR Am J Roentgenol*; 191:1208-1215.
- Schwittler J. (2008) Extending the frontiers of cardiac magnetic resonance. *Circulation*; 118:109-112.
- Shellock FG & Kanal E. (1996) Burns associated with the use of monitoring equipment during MR procedures. *J Magn Reson Imaging*; 6:271-272.
- Shellock FG & Crues JV. (2004) MR procedures: biologic effects, safety, and patient care. *Radiology*; 232:635-652.
- Snyder CJ; DelaBarre L; Metzger GJ. (2009) Initial results of cardiac imaging at 7 Tesla. *Magn Reson Med*; 61:517-524.
- Stuber M; Botnar RM; Fischer SE. (2002) Preliminary report on in vivo coronary MRA at 3 Tesla in humans. *Magn Reson Med*; 48:425-429.
- Thiel F; Hein M; Schwarz U. (2009) Combining magnetic resonance imaging and ultrawideband radar: a new concept for multimodal biomedical imaging. *Rev Sci Instrum*; 80:014302.
- Thiel F; Kreisler D & Seifert F. (2009) Non-contact detection of myocardium's mechanical activity by ultrawideband RF-radar and interpretation applying electrocardiography. *Rev Sci Instrum*; 80:114302.
- Togawa T; Okai O & Oshima M. (1967) Observation of blood flow E.M.F. in externally applied strong magnetic field by surface electrodes. *Med Biol Eng*; 5:169-170.
- Wahl A; Paetsch I; Roethemeyer S. (2004) High-dose dobutamine-atropine stress cardiovascular MR imaging after coronary revascularization in patients with wall motion abnormalities at rest. *Radiology*; 233:210-216.

IntechOpen



Advances in Electrocardiograms - Methods and Analysis

Edited by PhD. Richard Millis

ISBN 978-953-307-923-3

Hard cover, 390 pages

Publisher InTech

Published online 25, January, 2012

Published in print edition January, 2012

Electrocardiograms are one of the most widely used methods for evaluating the structure-function relationships of the heart in health and disease. This book is the first of two volumes which reviews recent advancements in electrocardiography. This volume lays the groundwork for understanding the technical aspects of these advancements. The five sections of this volume, Cardiac Anatomy, ECG Technique, ECG Features, Heart Rate Variability and ECG Data Management, provide comprehensive reviews of advancements in the technical and analytical methods for interpreting and evaluating electrocardiograms. This volume is complemented with anatomical diagrams, electrocardiogram recordings, flow diagrams and algorithms which demonstrate the most modern principles of electrocardiography. The chapters which form this volume describe how the technical impediments inherent to instrument-patient interfacing, recording and interpreting variations in electrocardiogram time intervals and morphologies, as well as electrocardiogram data sharing have been effectively overcome. The advent of novel detection, filtering and testing devices are described. Foremost, among these devices are innovative algorithms for automating the evaluation of electrocardiograms.

How to reference

In order to correctly reference this scholarly work, feel free to copy and paste the following:

Thoralf Niendorf, Lukas Winter and Tobias Frauenrath (2012). Electrocardiogram in an MRI Environment: Clinical Needs, Practical Considerations, Safety Implications, Technical Solutions and Future Directions, *Advances in Electrocardiograms - Methods and Analysis*, PhD. Richard Millis (Ed.), ISBN: 978-953-307-923-3, InTech, Available from: <http://www.intechopen.com/books/advances-in-electrocardiograms-methods-and-analysis/electrocardiogram-in-an-mri-environment-clinical-needs-practical-considerations-safety-implications->

INTECH
open science | open minds

InTech Europe

University Campus STeP Ri
Slavka Krautzeka 83/A
51000 Rijeka, Croatia
Phone: +385 (51) 770 447
Fax: +385 (51) 686 166
www.intechopen.com

InTech China

Unit 405, Office Block, Hotel Equatorial Shanghai
No.65, Yan An Road (West), Shanghai, 200040, China
中国上海市延安西路65号上海国际贵都大饭店办公楼405单元
Phone: +86-21-62489820
Fax: +86-21-62489821

© 2012 The Author(s). Licensee IntechOpen. This is an open access article distributed under the terms of the [Creative Commons Attribution 3.0 License](#), which permits unrestricted use, distribution, and reproduction in any medium, provided the original work is properly cited.

IntechOpen

IntechOpen