

We are IntechOpen, the world's leading publisher of Open Access books Built by scientists, for scientists

5,300

Open access books available

129,000

International authors and editors

155M

Downloads

Our authors are among the

154

Countries delivered to

TOP 1%

most cited scientists

12.2%

Contributors from top 500 universities



WEB OF SCIENCE™

Selection of our books indexed in the Book Citation Index
in Web of Science™ Core Collection (BKCI)

Interested in publishing with us?
Contact book.department@intechopen.com

Numbers displayed above are based on latest data collected.
For more information visit www.intechopen.com



Surgical Treatment of Patients with Ischemic Stroke Decompressive Craniectomy

Erion Musabelliu, Yoko Kato, Shuei Imizu, Junpei Oda and Hirotoishi Sano
*Department of Neurosurgery, Fujita Health University, Toyoaka
 Japan*

1. Introduction

A number of patients with ischemic cerebrovascular stroke suffer a progressive deterioration secondary to massive cerebral ischemia, edema, and increased intracranial pressure (ICP). The evolution is often fatal. Stroke is the second - leading cause of death worldwide. Life-threatening, complete middle cerebral artery (MCA) infarction occurs in up to 10% of all stroke patients, and this may be characterized as massive hemispheric or malignant space - occupying supratentorial infarcts. Malignant, space - occupying supratentorial ischemic stroke is characterized by mortality up to 80%, several reports indicated a beneficial effect of hemicraniectomy in this situation, converting the closed, rigid cranial vault into a semi open.

The main cause of death encountered in these patients is severe postischemic brain edema leading to raised intracranial pressure, clinical deterioration, coma and death. The result is dramatic decrease in ICP and a reversal of the clinical and radiological signs of herniation. For these reasons, decompressive craniectomy has been increasingly proposed as a life-saving measure in patients with large, space-occupying hemispheric infarction. Recent successes with intra-venous and intra-arterial thrombolytic therapy have resulted in an increased awareness of stroke as a medical emergency. Thus, increasing numbers of patients are being evaluated in the early hours following the ictal event. In the process of gaining more experience in the early management of patients with acute ischemic stroke, it has become clear that in a number of these patients a progressive and often fatal deterioration secondary to mass effect from the edematous, infarcted tissue occurs. An increasing body of experimental and clinical evidence suggests that some of these patients may benefit from undergoing a decompressive craniectomy. But, the timing and indications for this potential lifesaving procedure are still debated.

The objectives of this chapter are;

- To help better define the selection criteria for performing the surgery in case of supratentorial infarctions,
- To assess the immediate outcome in terms of time conscious recovery and survival
- To assess long term outcome and quality of life, using standard and functional assessment scales

Complications have been reported in the literature when hemicraniectomy has been completed after cerebral infarction. Malignant cerebral ischemia occurs in a significant number of patients who undergo emergency evaluation for ischemic stroke. This patient

population can be identified by early clinical and neuroimaging characteristics. In some of these patients, Decompressive Craniectomy appears to be a life-saving procedure. If craniectomy is performed early, especially in young patients, a satisfactory functional outcome can be achieved in a significant proportion of cases. Clinical experience, however, demonstrates that even in such patients, an acceptable functional outcome can be achieved after surgery if some preservation of speech is present at the time of intervention.

Additional studies will have to be mounted to analyze in more detail these implications. Survival after Decompressive Craniectomy for MCA infarction is better than that reported after medical management alone. Early hemicraniectomy based on radiographic and clinical criteria, but before signs of brain stem herniation, has been proposed as a means of improving outcomes.

2. Historical background

Decompressive craniectomy procedures have been used to relieve increased ICP and cerebral oedema caused by a variety of pathological events. This technique (decompressive craniectomy) first applied in 1905. (10) In 1905, Cushing reported the use of this procedure to relieve the pressure caused by the growth of an intracranial tumour. (1, 39, 66) Since then, surgical decompression has been reported as a treatment option for traumatic head injury, (24, 26, 53, 42) subdural haematoma, (9, 56, 38) oedema resulting from vasospasm secondary to subarachnoid haemorrhage, (17) encephalitis, (39, 63) intracerebral haematoma, (13) cerebral venous and dural sinus thrombosis, (69) cerebellar infarction, (28, 31, 59) and supratentorial cerebral ischemia. (65, 45)

Non randomized and randomized control data published are reviewed and data are analyzed, enrolling result from recent and earlier studies.

In the 1950s and 60s, a number of reports were published in which the authors described cases of massive cerebral ischemia accompanied by acute and severe brain swelling. (1) These cases were often fatal, with the oedema caused by the infarct producing a "pseudotumour" increasing in pressure within the cranial vault. (44) In 1968, Greenwood used surgical intervention in the treatment of such cases, which decreased the mortality rate to below 50% as reported, (24) in his series of 9 patients with acute infarction involving the MCA or ICA, decompressive hemicraniectomy as well as resection of the necrotic parenchyma were performed. Six of these patients survived, although 3 suffered postoperatively from severe disability. In their report in 1971, Kjellberg and Prieto described a bifrontal decompressive craniectomy procedure for the treatment of a massive infarction; however, the patient did not survive. (41) In 1981, Rengachary and co-workers reported the first cases in which straightforward craniectomy were undertaken, without removal of necrotic brain tissue. (57) Since that study, more additional cases of hemicraniectomy and some with bilateral craniectomy have been reported in the treatment of massive cerebral ischemia. (50) Significant retrospective data support the hypothesis that decompressive hemicraniectomy decreases mortality rates due to this disease entity. Three randomized controlled studies shed light on these issues and enhance the quality of evidence revolving around this procedure.

3. "Malignant" cerebral infarction

Ischemic cerebral infarction is associated with a high rate of morbidity and mortality, which are highest when lesions involve the trunk of one or more of the main cerebral vessels. In

fact, occlusion of either the distal Internal Carotid Artery (ICA) or proximal (MCA) trunk has been characterized as a “malignant” stroke in both clinical and animal studies, and these are the reason why we are considering this topic in relation with brain infarction in MCA territory. (15, 27) Of all cases with supratentorial infarctions in which an autopsy is performed, 13% are shown to suffer from severe brain swelling after an infarction involving the entire distribution of the ICA or MCA. (46, 49) Severe cerebral oedema can lead to herniation of cerebral structures through the tentorium or falx, as well as the brainstem structures through the foramen magnum. In fact, transtentorial herniation has been cited as the probable cause of death in many of these cases of malignant stroke. Bounds et al reviewed 100 autopsy cases of patients in whom an infarction involving the ICA distribution had been diagnosed. (5) Thirty-one patients died of tentorial herniation, which was the only neurological cause of death in all the cases reviewed.

The prognosis for patients who suffer a “malignant” cerebrovascular accident (CVA) is poor, with death occurring usually within the first 4 to 5 days. In this subset of patients, a mortality rate of 78% (estimated to be between 50% - 78%) was observed, (27) all deaths were attributed to transtentorial herniation, which occurred within 2 to 7 days (median 4 days). Similarly, in another set of data 81% of patients with malignant CVA died, and all deaths occurred within 5 days and were caused by herniation, (62, 64) given the poor prognosis in these patients, it is of critical importance to recognize imaging or clinical characteristics suggestive of such a progressive and rapid deterioration. In patients who suffer a malignant CVA the clinical course is generally predictable. The clinical course in these patients is uniform, with clinical deterioration developing within the first 2 to 3 days after stroke. Presenting symptoms may include the sudden onset of hemiplegia, homonymous hemianopsia, forced eye and head deviation toward the lesion side, and aphasia. Precipitous coma and papillary dilation usually occur together following the initial symptoms, (7, 12) in the absence of further intervention, death occurs.

To establish objective criteria for aggressive intervention, many investigators have measured intracranial pressure (ICP) once significant clinical deterioration is apparent. In an early study patients in whom ICP values were greater than 15 mm Hg did not survive the malignant infarct. (61) In subsequent studies other authors have shown that a fatal outcome occurred in most cases when the level was greater than 30 mm Hg. (7, 29, 51, 59, 74) In addition to clinical findings, neuroimaging criteria can help to identify those patients at particular risk for a malignant infarction in the early phase of their stroke. In patients with malignant CVA, a large area of parenchymal hypodensity in the MCA territory is often visualized on the admission CT scans (**Figure 1**). (59, 64, 74, 78)

With progressive clinical deterioration, CT-demonstrated signs may also include mass effect, effacement of the basal cisterns, compression of the ventricular system, a shift of midline structures, (78, 74) and herniation of tissue through the falx, foramen magnum, or tentorium. These patients present clinically with progressive deterioration of consciousness within the first 2 days. Thereafter, symptoms of transtentorial herniation occur within 2 to 4 days after onset of stroke. This clinical presentation is accompanied by early CT signs of major infarct during the first 12 hours after stroke, (74) as no model of medical treatment has been proven superior to the others, treatment options may vary, depending on each clinic protocol. The value of conventional therapies in this condition, as in others of raised ICP, consisting of artificial ventilation, osmotherapy, and barbiturate administration, has been a subject of debate.

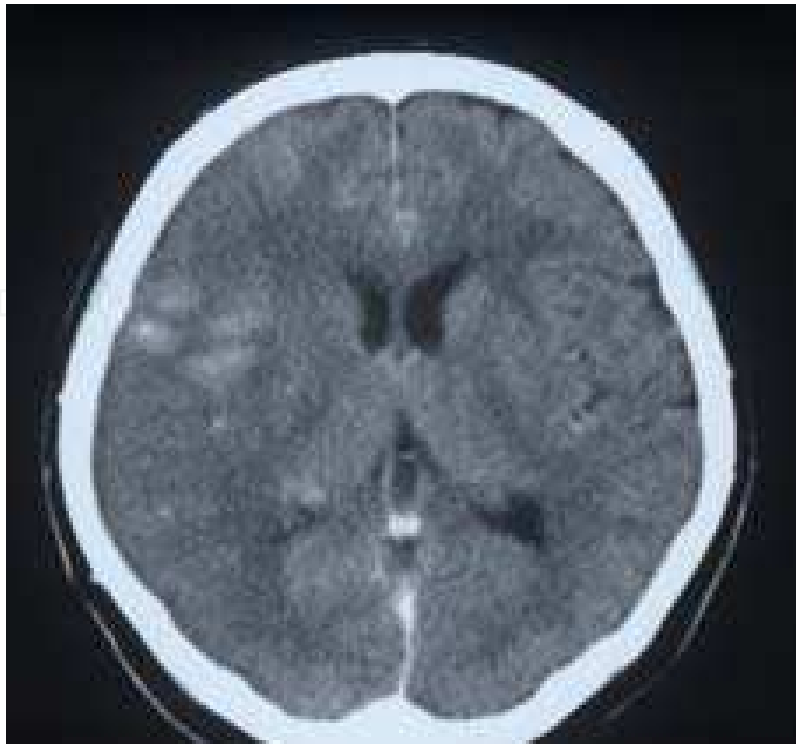

Fig. 1. CT scan demonstrating the R MCA territory infarction

4. Rationale for decompressive craniectomy and experimental studies

Cerebral ischemia results in oedema formation in and around the ischemic area, the larger the area of the infarction, the greater the extent of oedema. In the case of malignant CVA, the entire vascular distribution of the MCA, and possibly the anterior cerebral artery, is compromised. A severe oedematous response ensues throughout a large area. (61) Oedema is responsible for the parenchymal hypodensity that is demonstrated on CT scanning. (37, 56) One of the fundamental pathophysiological processes after cerebrovascular stroke is the development and propagation of an escalating cycle of brain swelling and an increase in ICP. The goals of the clinical management consist of interrupting this cycle by controlling ICP and maintaining cerebral perfusion pressure and cerebral blood flow to avoid brain ischemia. This management strategy has been developed as a result of reported strong correlations between uncontrollable high ICP and high rates of morbidity and mortality. The relationship between high ICP and poor outcome has been demonstrated consistently in both single-centre and multicenter studies and the ability to bring elevated ICP under control has long been considered a requirement for improving outcome of patients with severe head injuries. Progressive brain oedema and the exacerbating effect it has on increasing ICP can cause the area of damaged brain to extend. Within the confined cranial vault, the oedematous tissue places pressure against surrounding normal parenchyma. This is evidenced by the changes seen on CT scanning (**Figure 2**).

Intracranial hypertension results in decreased cerebral perfusion pressure and therefore decreasing blood supply throughout the cerebrum. Because of the increase in mechanical pressure and ICP, other major cerebral vessels may be compressed by the expanding tissue, against dural edges or against the skull. The result is secondary ischemia and a further expansion of the infarcted area. (6)

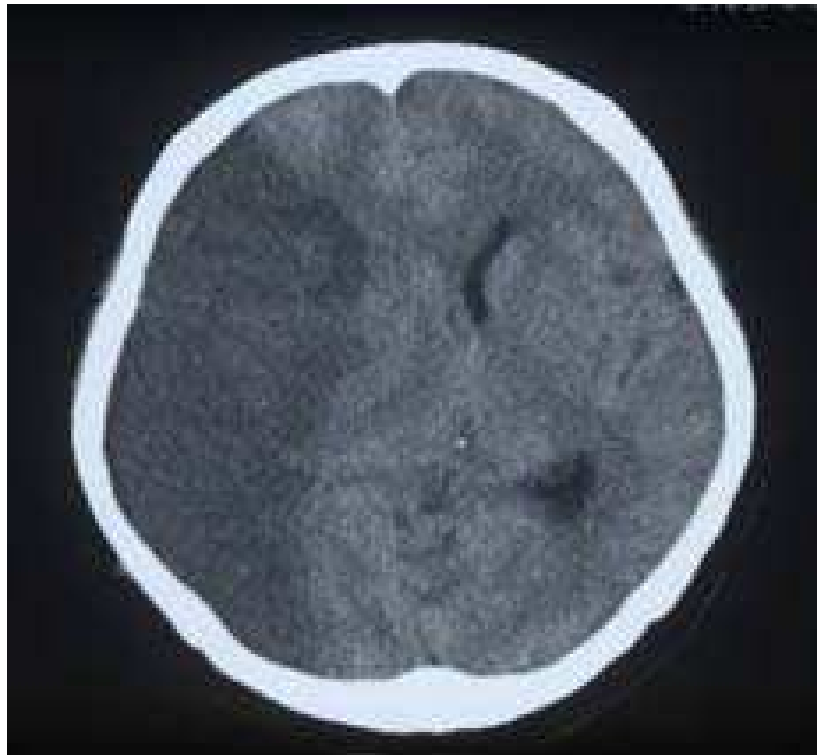

Fig. 2. CT scan on day one, demonstrating evolving R MCA infarction with mass effect and compression of the ventricular system. Clinical examination revealed right midriasis

Proposed as a life-saving procedure, increasing experimental and clinical evidence indicates that an early decompressive craniectomy can limit the extension of the infarcted area. From a mechanical perspective hemicraniectomy provides an immediate opening in the otherwise closed cranial vault. Therefore, compression of normal tissue is prevented or limited. The additional space created allows the tissue to expand through the bone defect, away from midline structures, so that CT-demonstrated changes normally observed when surgery is not performed like midline shift, decreased ventricular size, and herniation are minimized or completely resolved postoperatively. (37, 41, 61) As the cranial vault has essentially been expanded during surgery, there is an immediate decrease of ICP. The initial ICP values of 25 to 60 mm Hg decreased by 15% once the bone flap was removed, and by 70% once the dura was opened, resulting in the normalization of the ICP after surgery. (32) Similar findings were demonstrated when performed a bilateral craniectomy. (78, 80) In 2 patients with ischemic CVA whose initial ICP values were 54.8 mm Hg and 20 mm Hg, respectively, removal of the bone flap caused a decrease in ICP to 35.5 mm Hg and 10 mm Hg, and opening of the dura caused a reduction to 4.4 mm Hg and 3 mm Hg, respectively. In the immediate postoperative period, the ICP values were recorded as 4.4 mm Hg and 10.2 mm Hg. A decrease in ICP allows for an increase in cerebral perfusion pressure, aiding blood flow to the ischemic area, optimizing circulation to the damaged area through collateral vessels. Because hemicraniectomy alone may improve blood flow in the ischemic area, surgical resection of the infarcted tissue should not be conducted in these patients. Although such resection or "strokectomy" has been associated with postoperative improvements in some cases, it is impossible in all the cases to differentiate at surgery between ischemic tissue and necrotic tissue. (34, 57) Being poorly delineated from necrotic tissue, the ischemic area may possibly be damaged or removed upon resection of the infarct.

5. Timing and indications of surgery

Hemicraniectomy has for a long time been used as a last resort to prevent impending death after all medical therapies have been attempted. The surgical procedure certainly preserves life, as evidenced by decreased mortality rates when compared with patients who undergo medical therapy alone. (61) In many of the reported cases, the symptoms of a severe herniation syndrome, fixed, dilated pupils, precipitous coma, cardiorespiratory difficulties and decerebrate posturing, were used to indicate the need for decompressive surgery. (37, 35, 40) Patients suffering malignant CVA receive antioedema medical treatment and hyperventilation or tissue plasminogen activator, (70) before considering a decompressive craniectomy. Usually, an initial reversal of symptoms, such as the degree of pupillary dilation, occurs with aggressive medical treatment. After its initial effectiveness, however, additional medical therapeutic efforts often fail to control or prevent herniation. In the case of massive cerebral ischemia, the effectiveness of such medical therapy is severely limited, at best, as evidenced by the high mortality rates observed in the absence of surgical intervention. In the case of stroke which is typically not treated surgically, physicians may wait too long to intervene surgically. Once the pupils are fixed and a deep coma has indicated an irreversible decline of cerebral function, surgery should not be performed. (57)

Parameter	Time of Surgery	Patient's outcomes. 1, 3, 6 months
Age	Mean ± SD	Survival after one month (in percentage - of enrolled patients)
Sex	Percentage	
Territory of infarction		Barthel Index
MCA	Number	NIHSS score
MCA/ ACA		MRS score
MCA/ PCA		
Hemisphere	Left / Right	
Pathological mechanism (if known)		Functionally independent
Emboli	Number	Mild to moderate disability
Dissection		Severely disabled
Other		
Other related disease/ conditions		
On admission		
Barthel Index Score	Mean ± SD	
SSS score		
GCS		
Time to surgery	Mean	
Imaging findings CT/ MRI		
Signs of herniation before surgery	Percentage	
Mortality rate (after surgery)	Percentage	
Time on NCU	Day	
Time of recovery		

NCU - Neurological Care Unit

ACA - Anterior Cerebral Artery

PCA - Posterior Cerebral Artery

Table 1. Clinical and instrumental criteria used in evaluation of the patient

Evaluation of experimental findings suggests that, early surgical decompressive surgery for the treatment of massive cerebral ischemia may limit the extension of the infarction and reduce morbidity. (14, 21) Craniectomy can decrease the infarct volume and improve neurological outcome in a rat model of MCA occlusion when surgery is completed early (1 hour postictus). (20) Similar results are found when surgery was completed 4 hours postictus. In the 4-hour treatment group, outcome and infarct volume were significantly better as compared with those observed in control animals and animals surgically treated at 12, 24 and 36 hours postictus. Animals treated at these later time periods improved, but no significant differences were reported among these three groups and the control group. (14) When patients who suffer malignant CVA were surgically treated on average 21 hours postictus, there was a greater decrease in mortality rate and length of stay in the intensive care unit as compared with patients who underwent surgery an average 39 hours postictus. There was also a trend of improved Barthel Index (BI) scores demonstrated at follow-up for patients in the earlier surgical group. Several factors need to be considered to optimize both the timing and the indication for decompressive craniectomy (**Table 1**). (26, 30, 32, 48, 71, 72)

6. Predictors of malignant cerebral edema

Severely compressive brain edema is associated with significant mortality and morbidity. From a pathophysiological view, early intervention could minimize secondary ischemia of viable tissue around the infarcted area and possibly prevent herniation. Optimal utility of this procedure would require identifying the population that is most likely to benefit in a way that meets patient's expectations as well as those of their families and caretakers.

By using diffusion weighted MR imaging, a stroke volume greater than 145 cm³ within 14 hours of onset of stroke symptoms has 100% sensitivity and 94% specificity for predicting the progression to malignant edema. (52) Additionally, in patients who suffered a massive MCA territory stroke, stroke volume greater than 50% of the MCA territory were identified, high white blood cell count, additional involvement of the anterior or posterior cerebral artery, systolic blood pressure higher than 180 mm Hg within 12 hours of stroke onset, and a history for the progression toward malignant edema. (36) Patients with an NIHSS score of 20 or greater on admission or who present with nausea or emesis are at high risk for developing malignant cerebral edema. (43) In addition to clinical and radiographic risk factors, serum levels of the astroglial protein S100B have been shown to be predictive of malignant cerebral edema with 94% sensitivity and 83% specificity (for a value of 1.03 mg/L at 24 hours from the ischemic event). (19) This may become a useful monitoring tool at crucial clinical time points at which the development of cerebral edema is believed to be an imminent possibility, once a commercially available bedside kit is available.

7. Time window for surgery

The question of the optimal time window for intervention has not yet been completely elucidated. (4, 26, 30, 32, 48, 71, 72) Although the pooled data from the European trials seem to show benefit from early surgery, only a small number of patients was included in the late group in the HAMLET, (30) and definite conclusions cannot be drawn at this time. Another source of data, did not demonstrate a difference in outcome based on timing. (26) Clear definition of a time window for intervention will be essential to creating treatment guidelines. With that purpose in mind, 2 additional randomized control trials (RCTs), The

North American HeADDFIRST (Hemicraniectomy And Durotomy on Deterioration From Infarction Related Swelling Trial), aimed to evaluate patient outcome after hemicraniectomy within 96 hours from symptom onset, the HeMMI trial (Hemicraniectomy for Malignant Middle cerebral artery Infarcts) in the Philippines is studied patient morbidity and mortality after decompressive surgery within 72 hours from symptom onset.

8. Intracranial pressure monitoring

Intracranial pressure monitoring has been recommended as a guide to surgical timing. (81, 62) A measurement of greater than 25 mm Hg has been used despite attempts at medical therapy as an indicator for surgical intervention. (7, 59) Increased ICP measurements are preceded by the constellation of clinical signs and symptoms constituting the “malignant CVA syndrome;” thus, the usefulness of ICP monitoring in these cases has been questioned. But, brain tissue shifts rather than raised ICP are probably the most likely cause of the initial decrease in consciousness.

9. Neuroimaging studies

Extensive MCA infarction with oedema in greater than 50% of the MCA territory can be identified early after the ictal event on CT scans, and it is observed on the initial CT scan in approximately 69% of the reviewed cases by Hacke et al. (27) Parenchymal hypodensity in greater than 50% of the MCA territory is highly indicative of a progressive clinical course, leading to severe morbidity or death. With current, newer CT scanners, parenchymal hypodensity can be seen and followed soon after symptom onset (**Figure 3**).

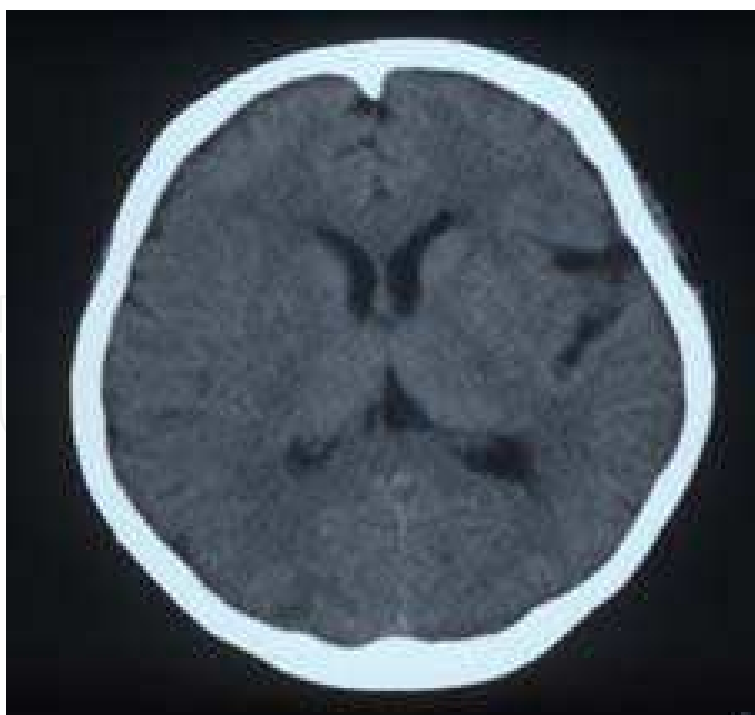

Fig. 3. CT scan demonstrating early CT findings of acute ischemic stroke (within 3 hours from onset) - slight changes, right sulci and Sylvian fissure effacement - effacement of R insular islands and structures of basal ganglia

In another set of data, most of the patients had at least two CT scans, one, within first 4 days after stroke and in some series within the first 12 hours after symptom onset, and the second one with the deterioration of symptoms and or after surgery (**Figures 4 and 5**). (64, 65)

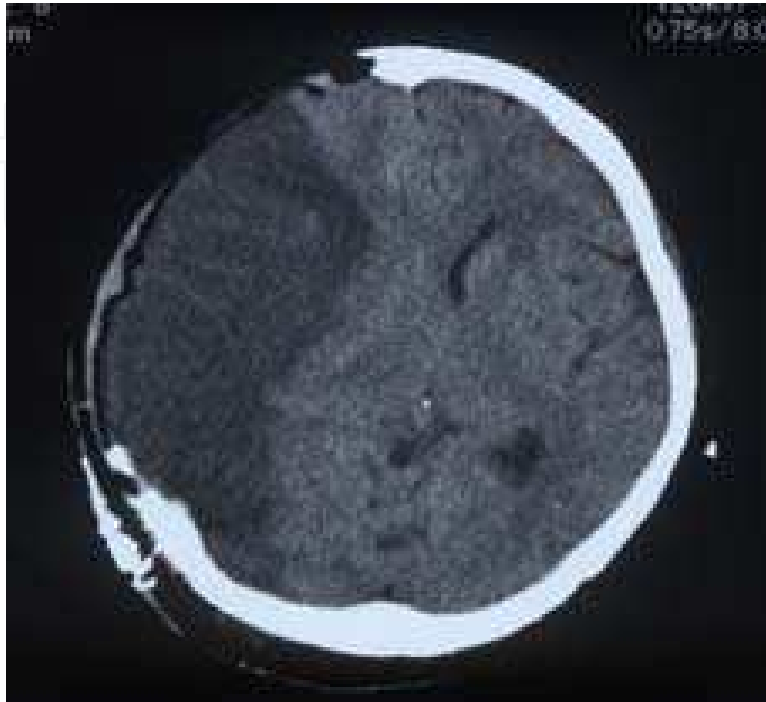


Fig. 4. CT scan, one day after hemicraniectomy (in which large frontoparieto-occipital bone was removed), revealing the presence of midline shift

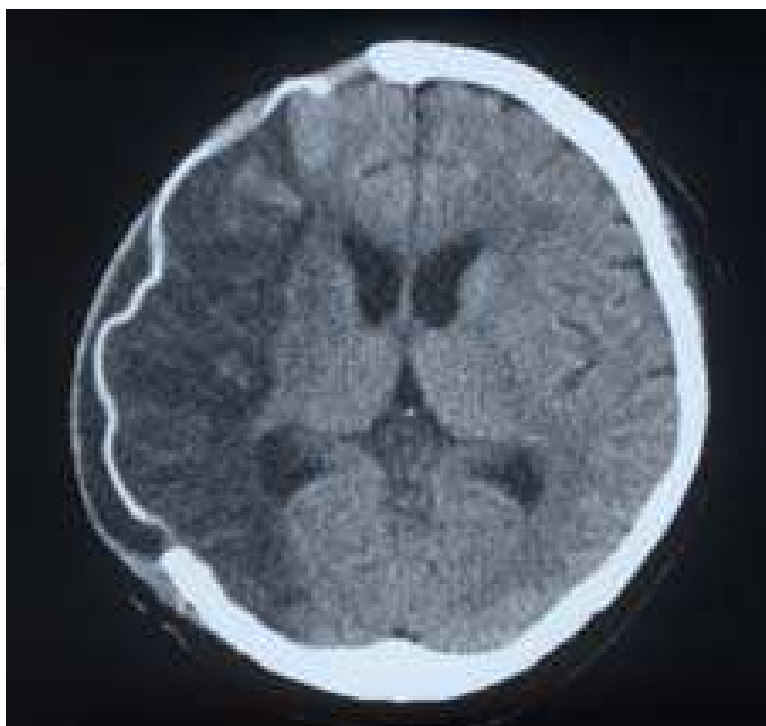


Fig. 5. CT scan, one month posthemicraniectomy, with resolution of previous midline shift

A midline shift of the cerebral structures is another phenomenon of increasing unilateral cerebral oedema that can be identified on CT scanning. The amount of midline shift was significantly different between survivors and nonsurvivors of malignant CVA. (59) In a study conducted to examine only the prognostic value of midline shift, it was suggested that at 32 hours after the occurrence of cerebral infarction, a shift of the third ventricle greater than 4 mm was indicative of a fatal outcome. (23) Regardless of its potential for prognostic significance however, midline shift is not visualized as early on CT scanning as is parenchymal hypodensity (**Figure 1**). Early changes demonstrated on CT scans are also an indicator of the viability of collateral circulation. Cerebral Angiography was performed (**Figure 6**) in patients in whom stroke was demonstrated early with CT scanning. (74)

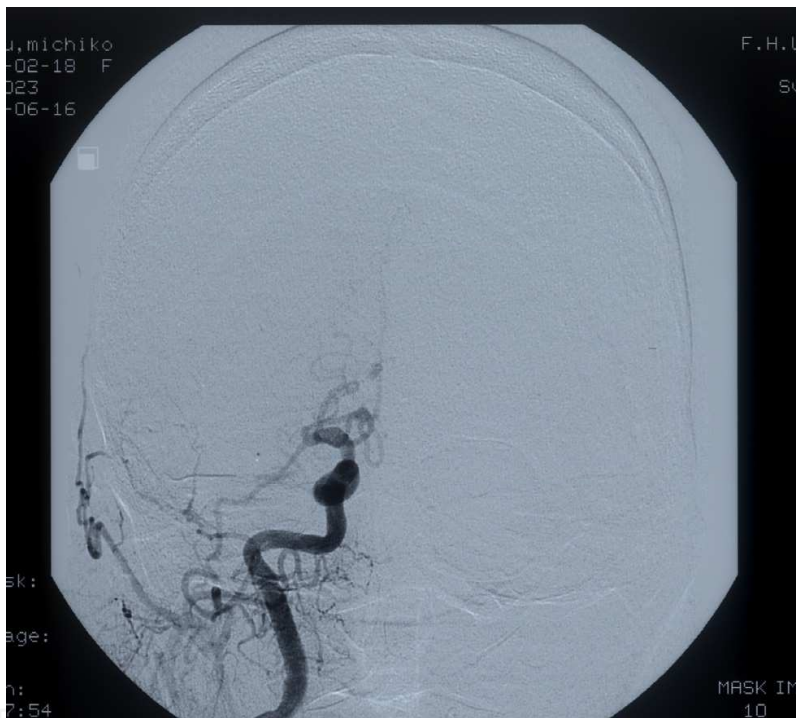

Fig. 6. R ICA AP angiogram reveals absence of R MCA - proximal occlusion

Comparing the angiographic findings with those obtained using CT scanning, the authors observed that parenchymal hypodensity in greater than 50% of the MCA territory was predictive of poor collateral circulation, as evidenced by the angiographic study. (74) These findings are important, because in patients with adequate collateral circulation, decompressive hemicraniectomy may not be necessary.

From neuroradiological studies it has been well recognized that “early visual radiolucency” in the CT examination is a negative outcome predictor. Continued refinements of newer imaging techniques such as diffusion / perfusion magnetic resonance will lead to an earlier identification of those patients more likely to benefit from early decompressive craniectomy. (**Figures 7 and 8**)

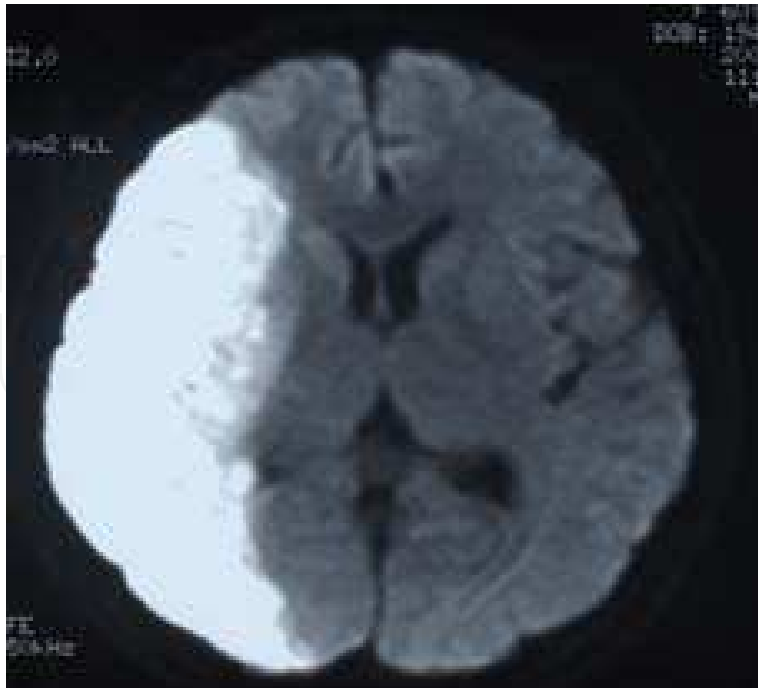


Fig. 7. MRI T2-weight diffusion, revealing R MCA territory infarction with early cytotoxic oedema

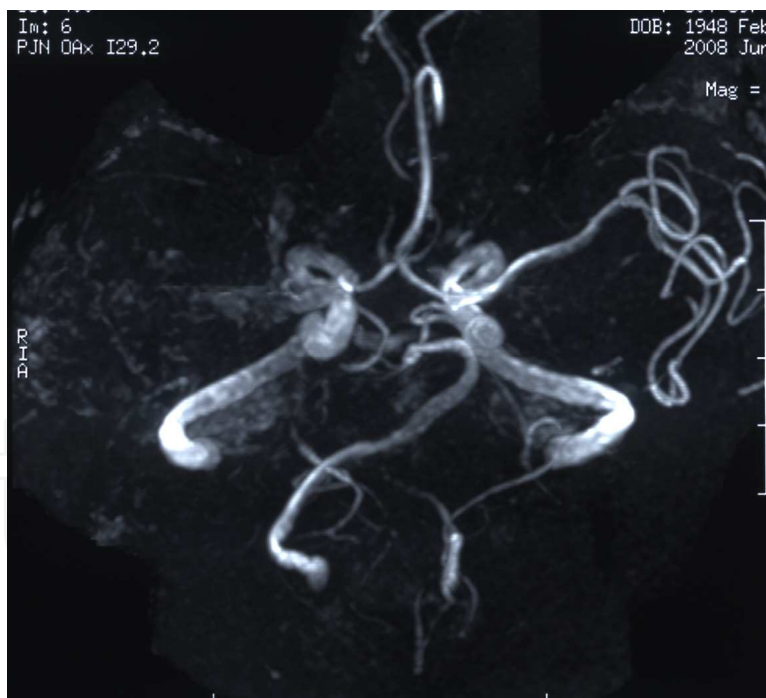


Fig. 8. MR angiography revealing the absence of flow - related enhancement in the R MCA. Confirming persistent proximal occlusion of R MCA.

10. Patient age and surgical age limit

The age of patients undergoing surgical intervention reported in the reviewed series ranged from 11 to 70 years of age. Based on data provided in the literature, it was impossible to

determine if a certain age range of patients benefits more from surgical decompression. Most investigators, however, noted that they are more aggressive in performing hemicraniectomy in young patients in whom CVA has occurred and that the young seemed to benefit more from the procedure. By dividing patients by age in those younger than, and older than 50 years of age, it is found that patients under the age of 50 years made a good functional outcome (Barthel Index scores > 60 [100 = independent, 60-95 minimum assistance, and < 60 = dependent]), but not at all the patients over 50 years of age was this observed at follow-up examinations. (7) In theory and in practice, it would seem that younger patients with ischemic stroke would benefit from early decompressive surgery for the following reasons:

- Their brains are less atrophied, allowing less room for oedematous expansion within the cranial vault. Individuals aged 50 years and younger have been identified as benefiting more from bilateral decompressive craniectomy in cases of subarachnoid haemorrhage because of their unatrophied brains, as compared with those over 50 years of age.
- The ventricular system in younger persons is smaller than in older persons.
- It has been proposed that the oedematous response to ischemia is greater in younger individuals.

Randomized trials to date have focused on patients 60 years of age and younger, thus leaving us with very few data regarding patients older than 60 years of age. The HAMLET displayed conflicting results with previous review series (30) with a trend toward better outcome in the upper age categories (51–61 years). These results raised questions about the existence of an age limit for surgical benefit. The DESTINY RCT will shed more light on the impact of surgery in patients older than 60 years. (33) In patients older than 60 years of age, assessing outcome following decompressive craniectomy of malignant MCA infarction, mortality rate and functional outcome, as measured by Barthel Index (BI) and modified ranking scale (mRS), were significantly worse in patients older than 60 years of age following decompressive craniectomy. (3) Age is an important factor to consider in patient selection for surgery. However, cautious interpretation of the results is required because the outcome scores that were used only measure physical disability, whereas other factors, including psychosocial, financial, and caregiver burden, should be considered in addition to age alone.

11. Dominant hemisphere infarction

As a rule, investigators in the past did not undertake surgery in patients with dominant hemisphere infarctions. The loss of communicative abilities and a plegic dominant upper extremity were judged to be too damaging. Analysis of recent evidence suggests that considering a dominant hemisphere infarction to be a contraindication to surgery may be too harsh a criterion. (60, 65) Functionally, the patients with the dominant hemisphere infarct who underwent hemicraniectomy were not significantly different from those patients who underwent craniectomy after CVA in the nondominant hemisphere. Therefore, surgery can be considered in patients with dominant hemisphere infarction, especially if some residual language function is present at admission.

While the fear of complete aphasia was classically the reason behind the refusal to operate on large dominant hemispheric strokes, data have suggested that nondominant hemispheric

injuries leading to serious depression and neglect can be as disabling as aphasia during the rehabilitation process. (76) Additionally a subset analysis in the DECIMAL trial showed no difference in the mRS scores of survivors with or without aphasia at 1 year; in addition, all surgical survivors agreed with the decisions to undergo surgery when asked retrospectively, including patients still experiencing aphasia. (72) Stroke laterality and its correlation with outcome (29, 30, 33, 34, 71) have also been the subject of subgroup analysis in other trials and controlled and uncontrolled studies have shown no predicative value for outcome related to laterality.

There has been interest in identifying which patients will develop malignant cerebral oedema after massive infarcts, patients at high risk (**Table 2**).

Inclusion criteria	Exclusion criteria
Age 18 - 60 years	Prestroke mRS score ≥ 2
NIHSS score nondominant hemisphere > 18 dominant hemisphere > 20	Prestroke score Barthel Index < 95
Imaging - documented unilateral infraction. MCA at least 2/3 of territory and at least part of basal ganglia.	GCS < 6
± Additional infarctions in ACA or PCA territory. Ipsilaterally.	
Time - onset of symptoms	bilateral - pupils fixed and dilated Other brain related diseases Haemorrhagic transformation of the infarct Life expectancy < 3 years Other related disease/ conditions - affecting outcome. Especially coagulopathy/ systemic bleeding disorders. Pregnancy. Contraindication for anaesthesia

Table 2. Criteria proposed to use for inclusion/ exclusion of patients and clinical outcome.

12. Surgical technique, results and limits

12.1 Operative technique

Hemicraniectomy for supratentorial infarction usually involves aggressive bone removal to alleviate better the symptoms of malignant cerebral oedema. The need for a radical approach, extension of bone removal, was recognized in the event of severe posttraumatic cerebral oedema, this was echoed in the case of massive cerebral ischemia when a few of initial surgically treated patients harboured a bone defect that was too small, not providing adequate space for decompression and resulting in brain herniation through the skull opening. (25, 60) Prolapsed of the oedematous brain through the edges of the craniectomy defect, with possible exacerbation of brain damage is one of the possible limitations of decompressive craniectomy. In the case of cerebral infarction, however, this phenomenon

does not result in significant increased cerebral damage or venous stasis, because most likely the protruding tissue is already necrotic.

In the event of massive cerebral ischemia, the frontal, temporal, and parietal bones overlying the infarcted hemisphere are removed. The dura is incised and reflected. A dural expansion graft of pericranium, lyophilized cadaver dura, homologous temporal fascia, or sintetic material is loosely sutured to the dura edges to prevent cortical adhesions. The dura is fixed to the craniectomy edges to prevent or limit epidural bleeding, and the temporal muscle and skin flap are reapproximated and sutured or stapled into place. The bone flap may be frozen and preserved or instead a fabricated artificial material can be used (e,g titanium), to close the bone defect, cranioplasty is then performed at a later date, when functional recovery has stabilized.

A technical note "In-window" craniotomy and "bridgelike" duraplasty as an alternative to decompressive hemicraniectomy has been lately introduced as an alternative, concluding that decompressive surgery, which uses an in-window craniotomy that gradually opens according to the intracranial pressure, is an alternative solution for deploying autologous material. The procedure has the advantage of obviating the need for a second surgical procedure to close the bone defect, and thus preventing the metabolic cerebral impairment associated with the absence of an overlying skull. (73)

By studying the impact of craniectomy size, shape, and location on parenchymal hemorrhagic and ischemic lesions, postoperative bleeding, and mortality, and interestingly found a 70% rate of hemicraniectomy-associated infarcts and hemorrhage. Bleeding was associated with a small craniectomy size and sharp bone defects. Parenchymal hemorrhage was the only factor that statistically affected mortality rate, with only 55% of patients surviving compared with 80% in the absence of hemorrhage, with a recommendation for craniectomy size in a diameter larger than 12 cm. This conclusion is validated by the fact that some studies suggest that doubling the diameter from 6 cm to 12 cm potentially increases the decompressive volume from 9 to 86 ml. (75, 79) Ideally, hemicraniectomy should be performed in the frontotemporoparietal region and reach the floor of the middle cranial fossa. The midline should be spared to avoid injury to the superior sagittal sinus.

12.2 Results of craniectomy

For more than 50 years, (1, 10, 39, 66) patients have been selected from case reports or series; range age 10 to 76 years, predominantly male patients, with a good outcome for up to 60% of the patients, several studies have shown that decompressive surgery is a possible treatment strategy for increased ICP after severe supratentorial stroke.

Although increasing numbers of studies have reported encouraging results after decompressive craniectomy for ischemic stroke, these studies are mostly limited to case series without a control group, a summery has is shown in a publication. (50) Study shows that mortality is lower in the surgically treated group compared with a higher mortality rate in the control group - medically treated, and with a better outcome in the surgically treated group. (60)

As decompressive craniectomy can be a life-saving procedure in patients who will most likely be left with a significant neurological deficit, the operation has important ethical and psychological implications. Because of their altered level of consciousness, patients cannot directly provide consent and in such cases, informed consent has to be obtained from the

relatives. Psychological disturbances in this patient population were addressed, and mood disturbances were significant in patients who underwent decompressive craniectomy after right-sided hemisphere ischemic stroke, patients suffered severe depressive symptoms, and mild to moderate impairment was demonstrated. (7)

In deciding when surgery is indicated, it is important to know that in general, clinical signs precede critically raised ICP, drowsiness is one of the major clinical symptoms of developing brain oedema (61) thus, ICP monitoring of this condition might be helpful in guiding further therapy. However, elevated ICP is not a common cause of initial neurological deterioration from large hemispheric stroke. (21)

Even under full supportive therapy, the mortality rate is reported high (roughly 80%), and lately the effectiveness of many medical therapies such as chronic hyperventilation, osmotherapeutics, barbiturate therapy, has been challenged. (14, 20, 29, 34, 45) The clinical course of patients with severe supratentorial stroke is highly predictable, therefore, waiting for mesencephalic signs to occur potentially worsens prognosis. It was hypothesized that through decompressive surgery, the vicious circle of extensive oedema, which by elevation of ICP causes ischemia of neighbouring brain tissue and further infarction, may be interrupted. (14) This may then increase cerebral perfusion pressure and optimize retrograde perfusion of leptomeningeal collateral vessels, thus allowing functionally compromised but viable brain to survive. (21)

The timing of surgery, hemisphere infarcted, presence of signs of herniation before surgery, and involvement of other vascular territories may not significantly affect outcome, to identify the patients most likely to benefit from hemicraniectomy, age may be a crucial factor in predicting functional outcome after hemicraniectomy in patients with large MCA territory infarction, as from different review of data. (26, 33, 47, 60)

There are several limits to these reviews.

12.3 What limits?

These were data prior to RCTs but in the absence of randomized controlled data by that time, questions remained regarding optimal patient selection, timing of therapy, and prognosis.

Waiting for signs of herniation may worsen prognosis because of irreversible mesencephalic injury. Early decompressive surgery may further improve outcomes in these patients, considering for surgery nondominant hemisphere or incomplete aphasia before deterioration. For the patients, surgically treated before the occurrence of clinical signs of herniation, within the first 24 hours after stroke onset, hemicraniectomy is an effective therapy for the condition of malignant MCA infarction. Most related complications associated with the operation were epidural haematoma, subdural haematoma, and hygromas. However, whether and when decompressive surgery is indicated in these patients is still a matter of debate but, younger patients may have better functional outcome even if undergoing decompressive craniectomy of the dominant hemisphere. (65)

Given the unresolved questions regarding the role of decompressive craniectomy and appropriate patient selection, the following RCTs were conducted and designed, to investigate the efficiency of decompressive surgery: DECIMAL (Decompressive Craniectomy In MAlignant middle cerebral artery infarcts) (72) DESTINY (DEcompressive Surgery for the Treatment of malignant INfarction of the middle cerebral artery) (34, 71) and HAMLET (Hemicraniectomy After Middle cerebral artery infarction With Life-Threatening Edema Trial). (30) Not all the RCTs demonstrated statistical superiority of hemicraniectomy and failed to meet the primary end point. (71)

13. Surgery-related complications and the quality of life related surgery

Complications have been reported.

The outcomes of patients undergoing decompressive craniectomy may be impacted by the complications of the procedure, reported complications include inadequate decompression, infection, hemorrhage, and the development of contralateral fluid collections, postoperative epidural and subdural haemorrhage as well as hygromas has occurred. Furthermore, delayed sinking flap syndrome may result in headaches, seizure and focal neurological deficits and is typically cured by replacement of the bone flap. Similarly, hydrocephalus may develop in a delayed fashion. (7, 28, 29, 34, 45, 60, 65, 71, 77)

Available data are in agreement on a reduction of the mortality rate, but the reported functional outcome was highly variable. Older age, more severe neurological deficit on admission, and longer duration of intensive care treatment and mechanical ventilation were significantly associated with worse disability (BI < 50). The health-related quality of life (QOL) was considerably impaired in the subscales of mobility, household management, and body care. Decompressive hemicraniectomy improves survival in patients with malignant MCA infarction when compared with earlier reports of conservative treatment alone. Functional outcome and QOL remain markedly impaired, especially among elderly patients and in those with a severe neurological deficit at admission. (18) Early death is a result of transtentorial herniation while delayed death is typically due to the medical complications of prolonged hospitalization including pneumonia and pulmonary emboli. (67) Although the impact on mortality appeared unequivocal in most studies. Surgical age limit has not yet been fully defined very few data exist to support hemicraniectomy for patients older than 60 years. Data analysis, demonstrate significant mortality reduction in the surgically treated patients compared with those receiving medical treatment. Surgical decompression within 48 hours of stroke onset reduces the risk of death and the risk of significant morbidity and showed a statistically significant reduction in severely disabled, bedridden patients (mRS score > 4), effect on severe disability (mRS score 5) and effect on moderate disability (mRS score 4). (72, 34, 30)

Quality of life issues are difficult to put in proper perspective, studies help clarify some facets of this important subject. Future studies will need to focus more rigorously on the long-term quality of life in survivors and the neurological outcome. There exists a difficult balance between increasing survival and poor neurological outcome, which at the other end includes the subjective assessment of outcome and discussion with the patient and the family that should be held early, in the need for surgical decompression, while keeping in mind that RCTs reported a trend of reduced disability among survivors. (72, 34, 30, 55, 68) Data refer that most patients remain in a vegetative state after this intervention, (11) however other data conclude that decompressive hemicraniectomy improves survival in patients with malignant MCA infarction when compared with earlier reports of conservative treatment alone. Functional outcome and QOL remain markedly impaired, especially among elderly patients and in those with a severe neurological deficit at admission. (3, 4, 8, 18, 33)

14. Conclusions

Malignant cerebral ischemia occurs in a significant number of patients who undergo emergency evaluation for ischemic stroke. The mortality rate in these patients is very high. Fatal outcome is usually related to progressive, severe cerebral oedema with brain

herniation and compression of critical brainstem structures. This patient population can be identified by early clinical and neuroimaging characteristics. In some of these patients, decompressive craniectomy appears to be a life-saving procedure. If craniectomy is performed early, especially in young patients, a satisfactory functional outcome can be achieved in a significant proportion of cases. Questions persist regarding the indications for such a procedure in patients with dominant infarctions. Clinical experience, however, demonstrates that even in such patients, an acceptable functional outcome can be achieved after surgery if some preservation of speech is present at the time of intervention.

Best Medical Treatment or Optimal medical management for malignant edema due to stroke has not been standardized. Recommendations for medical management of stroke-related malignant edema included admission to the intensive care unit, osmotherapy with mannitol or glycerol, invasive monitoring of intracranial pressure, blood pressure control, elevation of the head to 30°, and maintenance of normothermia, normoglycemia, and normovolemia. Morbidity and mortality rates are high for this disease entity despite such aggressive measures. (30) Although decompressive craniectomy has been shown to significantly decrease mortality, high morbidity rates among survivors have tempered enthusiasm for this procedure. This reluctance has been most pronounced in elderly patients and those with dominant hemisphere infarcts. The span of the optimal operative time window when surgical decompression is superior to medical management alone is also subject to debate.

(4)

We hope that our findings will add to existing information on decompressive hemicraniectomy and help until further data are available. However, there are some unanswered questions and questions persist regarding the age and the indications for such a procedure in patients with dominant infarctions:

- Which subset of patients will benefit maximally?
- Which patients will survive with an unacceptable degree of functional dependency?
- What is the optimal timing for surgery?

MCA infarction with malignant edema is a devastating disease for which hemicraniectomy can play a positive role.

Acknowledgement: To our patients, to whom we dedicate a very important part of our lives. To our professors who taught us how to treat our patients.

As disclosure, on behalf of the authors, I report no conflict of interest concerning the materials or methods used in our work or the findings specified.

15. References

- [1] Adams JH, Graham DI: Twelve cases of fatal cerebral infarction due to arterial occlusion in the absence of atheromatous stenosis or embolism. *J Neurol Neurosurg Psychiatry* 1957, 30: 479-488
- [2] Akins PT, Guppy KH: Sinking skin flaps, paradoxical herniation, and external brain tamponade: a review of decompressive craniectomy management. *Neurocrit Care* 2008, 9: 269-276
- [3] Arac A, Blanchard V, Lee M, Steinberg GK: Assessment of outcome following decompressive craniectomy for malignant middle cerebral artery infarction in patients older than 60 years of age. *Neurosurg. Focus.* 2009, 26: E3 1-6

- [4] Arnaout OM, Aoun SG, Batjer HH, Bendok BR: Decompressive hemicraniectomy after malignant middle cerebral artery infarction: rationale and controversies. *Neurosurg Focus* 2011, 30: E18 1-5
- [5] Bounds JV, Wiebers DO, Whisnant JP, et al: Mechanism and timing of deaths from cerebral infarction. *Stroke* 1981, 12: 474-477
- [6] Camarata PJ, Heros RC, Latchaw RE: "Brain attack": the rationale for treating stroke as a medical emergency. *Neurosurg* 1994, 34: 144-158
- [7] Carter BS, Ogilvy CS, Candia GJ, et al: One-year outcome after decompressive surgery for nondominant hemispheric infarction. *Neurosurg* 1997, 40: 1168-1176
- [8] Chang V, Hartzfeld P, Langlois M, Mahmood A, Seyfried D: Outcomes of cranial repair after craniectomy. *J Neurosurg*. 2010, 112: 1120-1124
- [9] Cooper PR, Rovit RL, Ransohoff J: Hemicraniectomy in the treatment of acute subdural hematoma: a re-appraisal. *Surg Neurol* 1976, 5: 25-28
- [10] Cushing H. The establishment of cerebral hernia as a decompressive measure for inaccessible brain tumors; with the description of intermuscular methods of making the bone defect in temporal and occipital regions. *Surg Gynecol Obstet* 1905, 1: 297-314
- [11] Danish SF, Barone D, Lega BC, Stein SC: Quality of life after hemicraniectomy for traumatic brain injury in adults. A review of the literature. *Neurosurg Focus* 2009, 26: E2 1-5
- [12] Delashaw JB, Broddaus WC, Kassell NF, et al: Treatment of right hemispheric cerebral infarction by hemicraniectomy. *Stroke* 1990, 21 :874-881
- [13] Dierssen G, Carda R, Coca JM: The influence of large decompressive craniectomy on the outcome of surgical treatment in spontaneous intracranial hematomas. *Acta Neurochir* 1983, 69: 53-60
- [14] Doerfler A, Forsting M, Reith W, Staff C, Heiland S, Scha'bitz WR, von Kummer R, Hacke W, Sartor K: Decompressive craniectomy in a rat model of "malignant" cerebral hemispheric stroke: experimental support for an aggressive therapeutic approach. *J Neurosurg* 1996, 85: 853-859
- [15] Engelhorn T, Doerfler A, Kastrup A, et al: Decompressive craniectomy, reperfusion, or a combination for early treatment of acute "malignant" cerebral hemispheric stroke in rats? Potential mechanisms studied by MRI. *Stroke* 1999, 30: 1456-1463
- [16] Furlan A, Higashida RT, Wechsler L, et al: Intra-arterial prourokinase for acute ischemic stroke. The PROACT II study: a randomized controlled trial. *JAMA* 1999, 282: 2003-2011
- [17] Fisher CM, Ojemann RG: Bilateral decompressive craniectomy for worsening coma in acute subarachnoid hemorrhage. Observations in support of the procedure. *Surg Neurol* 1994, 41: 65-74
- [18] Foerch C, Lang JM, Krause J, Raabe A, Sitzer M, Seifert V, Steinmetz H, Kessler KR: Functional impairment, disability, and quality of life outcome after decompressive hemicraniectomy in malignant middle cerebral artery infarction. *J Neurosurg* 2004, 101: 248-54
- [19] Foerch C, Otto B, Singer OC, Neumann-Haefelin T, Yan B, Berkefeld J, Steinmetz H, Sitzer M: Serum S100B predicts a malignant course of infarction in patients with acute middle cerebral artery occlusion. *Stroke* 2004, 35: 2160-2164


- [20] Forsting M, Reith W, Schaebitz WR, et al: Decompressive craniectomy for cerebral infarction: an experimental study in rats. *Stroke* 1995, 26: 259-264
- [21] Frank JL, Krieger D, Chyatte D: Hemicraniectomy and durotomy upon deterioration from massive hemispheric infarction: a proposed multicenter, prospective, randomized study. *Stroke* 1999, 30: 243
- [22] Gerriets T, Stolz E, Modrau B, et al: Sonographic monitoring of midline shift in hemispheric infarctions. *Neurol* 1999, 52: 45-49
- [23] Gower DJ, Lee KS, McWhorter JM: Role of subtemporal decompression in severe closed head injury. *Neurosurg* 1988, 23: 417-422
- [24] Greenwood J Jr: Acute brain infarctions with high intracranial pressure: surgical indications. *Johns Hopkins Med J* 1968, 122: 254-260
- [25] Guerra WKW, Gaab MR, Dietz H, et al: Surgical decompression for traumatic brain swelling: indications and results. *J Neurosurg* 1999, 90: 187-196
- [26] Gupta R, Connolly ES, Mayer S, Elkind MS: Hemicraniectomy for massive middle cerebral artery territory infarction: a systematic review. *Stroke* 2004, 35: 539-543
- [27] Hacke W, Schwab S, Horn M, Spranger M, De Georgia M, von Kummer R. Malignant middle cerebral artery territory infarction: clinical course and prognostic signs. *Arch Neurol* 1996, 53: 309-315
- [28] Heros RC: Surgical treatment of cerebellar infarction. *Stroke* 1992, 23: 937-938
- [29] Hofmeijer J, Amelink GJ, Algra A, van Gijn J, Macleod MR, Kappelle LJ, van der Worp HB: The HAMLET investigators. Hemicraniectomy after middle cerebral artery infarction with life-threatening edema trial (HAMLET): protocol for a randomised controlled trial of decompressive surgery in space-occupying hemispheric infarction. *Trials* 2006, 7: 29
- [30] Hofmeijer J, Kappelle LJ, Algra A, Amelink GJ, van Gijn J, van der Worp HB: Surgical decompression for space-occupying cerebral infarction (the Hemicraniectomy After Middle Cerebral Artery infarction with Life-threatening Edema Trial [HAMLET]): a multicentre, open, randomised trial. *Lancet Neurol*. 2009 8: 326-333
- [31] Ivamoto HS, Numoto M, Donaghy RMP: Surgical decompression for cerebral and cerebellar infarcts. *Stroke* 1974, 5: 365-370
- [32] Jourdan C, Convert J, Mottolese C, et al: Evaluation of the clinical benefit of decompression hemicraniectomy in intracranial hypertension not controlled by medical treatment. *Neurochirurgie* 1993, 39: 304-310 (Fr)
- [33] Jüttler E, Bösel J, Amiri H, Schiller P, Limprecht R, Hacke W, Unterberg A: DESTINY II: DEcompressive Surgery for the Treatment of malignant INfarction of the middle cerebral arterY II. *Int J Stroke* 2011, 6:79-86
- [34] Jüttler E, Schwab S., Schmiedek P. et al., for the DESTINY Study Group. Decompressive Surgery for the Treatment of Malignant Infarction of the Middle Cerebral Artery (DESTINY) A Randomized, Controlled Trial *Stroke* 2007, 38: 2518-2525.
- [35] Kalia KK, Yonas H: An aggressive approach to massive middle cerebral artery infarction. *Arch Neurol* 1993, 50: 1293-1297
- [36] Kasner SE, Demchuk AM, Berrouschot J, Schmutzhard E, Harms L, Verro P, Chalela JA, Abbur R, McGrade H, Christou I, Krieger DW: Predictors of fatal brain edema in massive hemispheric ischemic stroke. *Stroke* 2001, 32: 2117-2123
- [37] Kastrau F, Wolter M, et al: Recovery from aphasia after hemicraniectomy for infarction of the speech-dominant hemisphere. *Stroke* 2005, 36: 825

- [38] Kilincer C, Simsek O, Hamamcioglu MK, Hicdonmez T, Cobanoglu S: Contralateral subdural effusion after aneurysm surgery and decompressive craniectomy: case report and review of the literature. *Clin Neurol Neurosurg.* 2005, 107: 412-416
- [39] King AB: Massive cerebral infarction producing ventriculographic changes suggesting a brain tumor. *J Neurosurg* 1951, 8: 536-539
- [40] Kirkham FJ, Neville BGR: Successful management of severe intracranial hypertension by surgical decompression. *Dev Med Child Neurol* 1986, 28:506-509
- [41] Kjellberg RN, Prieto A Jr: Bifrontal decompressive craniotomy for massive cerebral edema. *J Neurosurg* 1971, 34: 488-493
- [42] Kondziolka D, Fazl M: Functional recovery after decompressive craniectomy for cerebral infarction. *Neurosurg* 1988, 23: 143-147
- [43] Krieger DW, Demchuk AM, Kasner SE, Jauss M, Hantson L: Early clinical and radiological predictors of fatal brain swelling in ischemic stroke. *Stroke* 1999, 30: 287-292
- [44] Kunze E, Meixensberger J, Janka M, et al: Decompressive craniectomy in patients with uncontrollable intracranial hypertension. *Acta Neurochir Suppl* 1998, 71: 16-18
- [45] Lanzino JD, Lanzino G: Decompressive craniectomy for space-occupying supratentorial infarction: rationale, indications, and outcome. *Neurosurg. Focus* 2000, 8: E3 1-7
- [46] Major ongoing stroke trials. *Stroke* 2006, 37: E18-e26
- [47] Mayer SA: Hemicraniectomy: a second chance on life for patients with space-occupying MCA infarction. *Stroke* 2007, 38: 2410-2412
- [48] Mori K, Nakao Y, Yamamoto T, Maeda M: Early external decompressive craniectomy with duroplasty improves functional recovery in patients with massive hemispheric embolic infarction: timing and indication of decompressive surgery for malignant cerebral infarction. *Surg Neurol.* 2004, 62: 420-430
- [49] Moulin DE, Lo R, Chiang J, Barnett HJM: Prognosis in middle cerebral artery occlusion. *Stroke* 1985, 16: 282-284
- [50] Musabelliu E, Kato Y, Imizu S, Oda J, Hirotooshi S: Decompressive hemicraniectomy for malignant MCA territory infarction. *Pan Arab Journal of Neurosurgery* 2010, 591: 1-9
- [51] Ng LKY, Nimmannitya J: Massive cerebral infarction with severe brain swelling: a clinicopathological study. *Stroke* 1970, 1: 158-163
- [52] Oppenheim C, Samson Y, Manai R, Lalam T, Vandamme X, Crozier S, Srour A, Cornu P, Dormont D, Rancurel G, Marsault C: Prediction of malignant middle cerebral artery infarction by diffusion-weighted imaging. *Stroke* 2000, 31: 2175-2181
- [53] Pillai A, Menon SK, et al: Decompressive hemicraniectomy in malignant middle cerebral artery infarction: an analysis of long-term outcome and factors in patient selection. *J Neurosurg* 2007, 106: 59-65
- [54] Polin RS, Shaffrey ME, Bogaev CA, et al: Decompressive bifrontal craniectomy in the treatment of severe refractory posttraumatic cerebral edema. *Neurosurg* 1997, 41: 84-94
- [55] Puetz V, Campos CR, Eliasziw M, Hill MD, Demchuk AM: Assessing the benefits of hemicraniectomy: what is a favourable outcome? *Lancet Neurol.* 2007, 6: 580-581
- [56] Ransohoff J, Benjamin MV, Gage EL Jr, et al: Hemicraniectomy in the management of acute subdural hematoma. *J Neurosurg* 1971, 34: 70-76

- [57] Rengachary SS, Batnitzky S, Moranz RA, et al: Hemicraniectomy for acute massive cerebral infarction. *Neurosurg* 1981, 8: 321-328
- [58] Rengachary SS: Surgery for acute brain infarction with mass effect. In: Wilkins RH, Rengachary SS (eds): *Neurosurgery*. New York: McGraw-Hill, 1985, Vol 2, pp 1267-1271
- [59] Rieke K, Krieger D, Adams HP, et al: Therapeutic strategies in space-occupying cerebellar infarction based on clinical, neuroradiological and neurophysiological data. *Cerebrovasc Dis* 1993, 3: 45-55.
- [60] Rieke K, Schwab S, Krieger D, et al: Decompressive surgery in space-occupying hemispheric infarction: results of an open prospective trial. *Crit Care Med* 1995, 23: 1576-1578
- [61] Ropper AH, Shafran B: Brain edema after stroke: clinical syndrome and intracranial pressure. *Arch Neurol* 1984, 41: 26-29
- [62] Schwab S, Aschoff A, Spranger, et al: The value of ICP monitoring in acute hemispheric stroke. *Neurol* 1996, 47: 393-398
- [63] Schwab S, Junger E, Spranger M, et al: Craniectomy: an aggressive approach in severe encephalitis. *Neurol* 1997, 48: 412-417
- [64] Schwab S, Rieke K, Aschoff A, et al: Hemicraniectomy in space-occupying hemispheric infarction: useful intervention or desperate activism? *Cerebrovasc Dis* 1996, 6: 325-329
- [65] Schwab S, Steiner T, Aschoff A, et al: Early hemicraniectomy in patients with complete middle cerebral artery infarction. *Stroke* 1998, 29: 1888-1893
- [66] Shaw CM, Alvord EC Jr, Berry RG: Swelling of the brain following ischemic infarction with arterial occlusion. *Arch Neurol* 1959, 1: 161-177
- [67] Silver FL, Norris JW, Lewis AJ, Hachinski VC: Early mortality following stroke: a prospective review. *Stroke* 1984, 15: 492- 496
- [68] Staykov D, Gupta R: Hemicraniectomy in malignant middle cerebral artery infarction. *Stroke* 2011, 42: 513-516
- [69] Stefani R, Latronico N, Cornali C, et al: Emergent decompressive craniectomy in patients with fixed dilated pupils due to cerebral venous and dural sinus thrombosis: report of three cases. *Neurosurg* 1999, 45: 626-630
- [70] The National Institute of Neurological Disorders and Stroke rt-PA Stroke Study Group: Tissue plasminogen activator for acute ischemic stroke. *N Engl J Med* 1995, 333: 1581-1587
- [71] Vahedi K, Hofmeijer J, Juettler E, Vicaut E, George B, Algra A, Amelink GJ, Schmiedek P, Schwab S, Rothwell PM, Boussier MG, van der Worp HB, Hacke W: The DECIMAL, DESTINY, and HAMLET investigators. Early decompressive surgery in malignant middle cerebral artery infarction: pooled analysis of three randomized controlled trials. *Lancet Neurol* 2007, 6: 215-222
- [72] Vahedi K, Vicaut E, Mateo J, Kurtz A, Orabi M, Guichard JP, Boutron C, Couvreur G, Rouanet F, Touzé E, Guillon B, Carpentier A, Yelnik A, George B, Payen D, Boussier MG: Sequential-design, multicenter, randomized, controlled trial of early decompressive craniectomy in malignant middle cerebral artery infarction (DECIMAL Trial). *Stroke* 2007, 38: 2506-2517

- [73] Valença MM, Martins C, da Silca JC: "In-window" craniotomy and "bridgelike" duraplasty: an alternative to decompressive hemicraniectomy: Technical note. *J Neurosurg* 2010, 113: 982-9
- [74] Von Kummer R, Meyding-Lamade U, Forsting M, Rosin L, Rieke K, Sartor K, Hacke W: Sensitivity and prognostic value of early computed tomography in middle cerebral artery trunk occlusion. *Am J Neuroradiol* 1994, 15: 9-15
- [75] Wagner S, Schnippering H, Aschoff A, Koziol JA, Schwab S, Steiner T: Suboptimum hemicraniectomy as a cause of additional cerebral lesions in patients with malignant infarction of the middle cerebral artery. *J Neurosurg.* 2001, 94: 693-696
- [76] Walz B, Zimmermann C, Böttger S, Haberl RL: Prognosis of patients after hemicraniectomy in malignant middle cerebral artery infarction. *J Neurol.* 2002, 249: 1183-1190
- [77] Waziri A, Fusco D, Mayer SA, McKhann GM II, Connolly ES Jr: Postoperative hydrocephalus in patients undergoing decompressive hemicraniectomy for ischemic or hemorrhagic stroke. *Neurosurgery* 2007, 61: 489-494
- [78] Wijdicks EFM, Schievink WI, McGough PF: Dramatic reversal of the uncal syndrome and brain edema from infarction in the middle cerebral artery territory. *Cerebrovasc Dis* 1997, ;7: 349-352
- [79] Wirtz CR, Steiner T, Aschoff A, Schwab S, Schnippering H, Steiner HH, Hacke W, Kunze S: Hemicraniectomy with dural augmentation in medically uncontrollable hemispheric infarction. *Neurosurg. Focus* 1997, 2: E3 1-9
- [80] Yoo DS, Kim DS, Cho KS, et al: Ventricular pressure monitoring during bilateral decompression with dural expansion. *J Neurosurg* 1999, 91: 953-959
- [81] Young PH, Smith KR, Dunn RC: Surgical decompression after cerebral hemispheric stroke: indications and patient selection. *South Med J* 1982, 75: 473-474

IntechOpen



Acute Ischemic Stroke

Edited by Prof. Julio Cesar Garcia Rodriguez

ISBN 978-953-307-983-7

Hard cover, 236 pages

Publisher InTech

Published online 18, January, 2012

Published in print edition January, 2012

Despite significant technological advances in recent years, their impact on our overall health and social, well-being is not always clear to see. Perhaps, one of the best examples of this can be highlighted by the fact that mortality rates as a result of cerebrovascular diseases have hardly changed, if at all. This places cerebrovascular diseases as one of the most prominent causes of both disability and death. In Cuba, for instance, a total of 22,000 cases of cerebrovascular diseases are reported each year in a country where life expectancy should increase to 80 years in the near future. In such a situation, to have a book that includes in a clear and summarized way, a group of topics directly related to the preclinical investigations advances and the therapeutic procedures for the cerebrovascular disease in its acute phase constitutes a useful tool for the wide range of the contributors to this affection's problems solution. In this group is included students, professors, researchers, and health policy makers whose work represents one of the greatest social and human impact challenges of the XXI century basic and clinical neurosciences.

How to reference

In order to correctly reference this scholarly work, feel free to copy and paste the following:

Erion Musabelliu, Yoko Kato, Shuei Imizu, Junpei Oda and Hirotoishi Sano (2012). Surgical Treatment of Patients with Ischemic Stroke Decompressive Craniectomy, *Acute Ischemic Stroke*, Prof. Julio Cesar Garcia Rodriguez (Ed.), ISBN: 978-953-307-983-7, InTech, Available from: <http://www.intechopen.com/books/acute-ischemic-stroke/surgical-treatment-of-patients-with-ischemic-stroke-decompressive-craniectomy>

INTECH
open science | open minds

InTech Europe

University Campus STeP Ri
Slavka Krautzeka 83/A
51000 Rijeka, Croatia
Phone: +385 (51) 770 447
Fax: +385 (51) 686 166
www.intechopen.com

InTech China

Unit 405, Office Block, Hotel Equatorial Shanghai
No.65, Yan An Road (West), Shanghai, 200040, China
中国上海市延安西路65号上海国际贵都大饭店办公楼405单元
Phone: +86-21-62489820
Fax: +86-21-62489821

© 2012 The Author(s). Licensee IntechOpen. This is an open access article distributed under the terms of the [Creative Commons Attribution 3.0 License](#), which permits unrestricted use, distribution, and reproduction in any medium, provided the original work is properly cited.

IntechOpen

IntechOpen