

# We are IntechOpen, the world's leading publisher of Open Access books Built by scientists, for scientists

4,400

Open access books available

117,000

International authors and editors

130M

Downloads

Our authors are among the

154

Countries delivered to

TOP 1%

most cited scientists

12.2%

Contributors from top 500 universities



WEB OF SCIENCE™

Selection of our books indexed in the Book Citation Index  
in Web of Science™ Core Collection (BKCI)

Interested in publishing with us?  
Contact [book.department@intechopen.com](mailto:book.department@intechopen.com)

Numbers displayed above are based on latest data collected.  
For more information visit [www.intechopen.com](http://www.intechopen.com)



# Conjunctival Flora Before and After Application of 5% Povidone-Iodine Solution

Virginia Vanzzini-Zago<sup>1</sup>, Jorge Villar-Kuri<sup>2</sup>,  
Víctor Flores Alvarado<sup>3</sup>, Alcántara Castro Marino<sup>4</sup>  
and Pérez Balbuena Ana Lilia<sup>5</sup>

<sup>1</sup>Assistant to Laboratory of Microbiology

<sup>2</sup>Chief of staff of Surgery Service

<sup>3</sup>Assistant to Laboratory of Microbiology

<sup>4</sup>Assigned to Cornea Service

<sup>5</sup>Asociación para Evitar la Ceguera en México Hospital "Dr. Luis Sánchez Bulnes"  
Mexico

## 1. Introduction

Conjunctival flora is attached with protein links to conjunctival cells. For this reason, the resident flora, *Corynebacteria* and *Staphylococcus epidermidis* are almost always present in normal conjunctives of any age, and depuration mechanism like tears, blinking or even the antibiotic do not remove it [1]. *Staphylococcus epidermidis*, or other coagulasa negative *Staphylococcus*, *Corynebacteria* or *Propionibacterium acnes* resident in normal conjunctiva and eye lids are named as frequent post-surgical endophthalmitis cause [2], pathogen bacteria as *Staphylococcus aureus* and *Streptococcus pneumoniae* are also related to acute and severe endophthalmitis, reason why it is very important to diminish the conjunctival alive bacteria previous to cataract or other ocular surgery and since 1985 Apt had proposed the use of antiseptic solutions like povidone-iodine in ocular surface. [3]. Some years later, Speaker proved in one comparative study the efficiency of antiseptics using this solution with a statistical significance less endophthalmitis as surgical risk in anterior segment ocular surgeries [4].

The use of drops of aqueous 5 % solution of povidone-iodine (polivinil pirrolidonil iodine solution) is mandatory in all ocular surgeries and its efficacy has been proved and published [5] even when not all bacteria species are diminished to 0 CFU.

### 1.1 Problem statement

Prevention of an endophthalmitis event as post surgical complications in cataract or other ocular surgeries is very important for the eye preservation for a good visual acuity and integrity. The purpose of this survey is to determine the efficacy of 2 drops of 5% povidone-iodine aqueous solution applied in conjunctival sacs 1 to 2 minutes before every cataract surgery for to reduce conjunctival alive flora in 100 patients, and to know which bacteria are susceptible or resistant and remain alive in conjunctival sacs despite the antiseptic method.

## 1.2 Application area

In all ocular surgeries and application of intravitreal injections.

## 1.3 Research course

This is a prospective, comparative and linear study in 100 patients that were submitted to cataract surgery.

## 1.4 Method used

In each patient immediately before the surgery was taken one sample (A) without antibiotic medical treatment of conjunctival sacs in the eye that will be submitted to surgery with a cotton swab for quantitative and qualitative determination of aerobic and anaerobic bacteria, measured in count forming unit (CFU), and a second sample (B) 2 minutes after the application of 5% povidone-iodine aqueous solution and wash out with sterile saline solution. All patients were attended in an eye care hospital in México City, Asociación para Evitar la Ceguera en México “Dr. Luis Sánchez Bulnes” IAP.

Collection of each specimen was performed by completely rotating the cotton swab through the lower conjunctival sac from the temporal to nasal conjunctival zone. We took care not to touch the eye lid margin or lashes. Immediately the cultures for aerobic and anaerobic bacteria were made by direct inoculation in 5% blood sheep agar with brain heart agar base, exposed on one swab side, then it was rotated 180 degrees and inoculated on chocolate agar enriched plate media using the other swab side, by this technique bacteria collected in samples A and B have been distributed equally in both solid culture media. After that, the cotton swab tip was put in thioglycolate broth and incubated at 37 centigrade for 7 days.

Blood agar plates were incubated for aerobic, hemolytic and microaerophilic bacteria for 48 hours in a candle jar (5% CO<sub>2</sub>), and chocolate agar plates were incubated for anaerobic bacteria in anaerobic bags for 7 days in 37 Centigrades incubator.

The enriched thioglycolate broth with 1% hemin and 0.001% vitamin K [6], was used for detection of even small amounts of living anaerobic, or microaerobic fastidious bacteria and incubated 7 days at 37C, and subcultured for anaerobic bacteria.

Multiple bacterial species were counted, selected and identified each one in the plates of blood agar and chocolate agar and expressed in CFU [7]. The same technique for the cultures was used for samples B, after two minutes of the action of antiseptic solution, and wash away with sterile saline solution.

We used the sample A taken without any medical treatment as comparative sample, and samples B as problem sample for statistical calculations.

Aerobic and anaerobic bacteria were identified with semi-automated techniques by Crystal® system (BBL Maryland USA) Gram stain, oxidase, catalase and indol reaction

## 2. Status

### *Inclusion criteria:*

1. All patients that will be submitted to cataract surgery in a period of one month attended in Hospital para Evitar la Ceguera en México “Dr. Luis Sánchez Bulnes” IAP in surgeries performed by Anterior Segment Service
2. Patients of any age that were submitted to cataract surgery.

*Exclusion criteria:*

1. Patient that have been used topical antibiotic drops for prophylactic treatment before surgery.

**2.1 Results**

In the conjunctivas of 19 patients, sample A and B were negative for cultures of aerobic and anaerobic bacteria, 81 patients sowed 26 bacterial species.

The total CFU including all aerobic and anaerobic bacterial species isolated in all the samples A before the application of 5% povidone iodine solution was 5,701 and were diminished to 193 CFU including aerobic and anaerobic bacteria, with statistical significance calculated by Fisher method, of  $\alpha = 0.033$  as is shown in Fig 1.

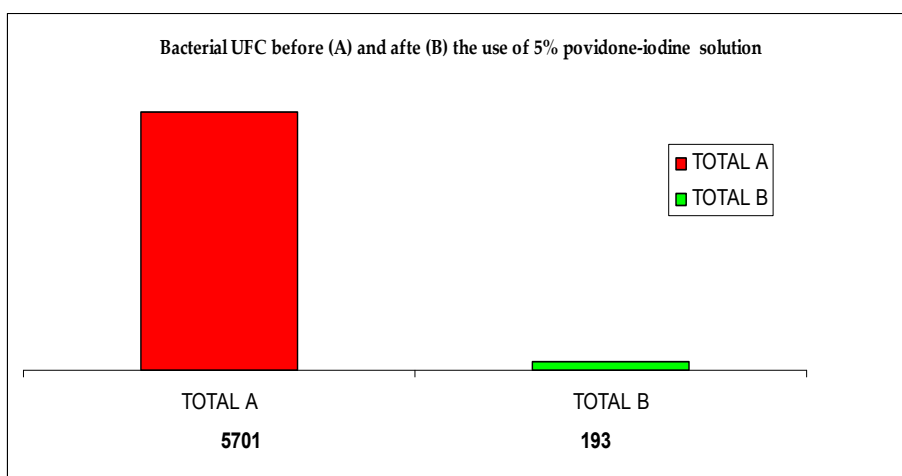


Fig. 1. The CFU of conjunctival sample A taken without antiseptic solution, Sample B after the application of 5% povidone-iodine solution.

Remained some anaerobic and aerobic bacteria as shown in Fig 2 with statistical significance by application of Fisher method with a value of  $\alpha = 0,035$ , for sample A and B.

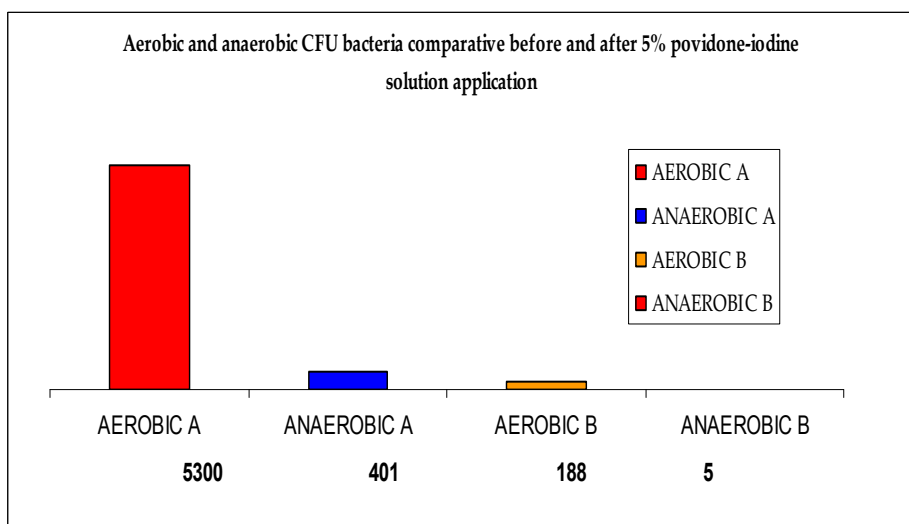


Fig. 2. Aerobic and anaerobic bacteria were diminished by 5% povidone-iodine solution.

Aerobic bacteria in sample A was 5,300 CFU and were diminished to 188 UFC in sample B, and for anaerobic bacteria samples A sowed 401 CFU and were diminished to 5 UFC in sample B, with Fischer statistical method value of  $\alpha = 0.012$ .

*Streptococcus pneumoniae* and *Staphylococcus aureus* were the species more diminished, and in sample B was not found CFU of these two ocular pathogens as is showed in fig 3.

The action of 5% yodopovidone aqueous solution over the conjunctival flora in 100 patients samples mesuring the UFC and the species found was evaluated in Table 1 as shown:

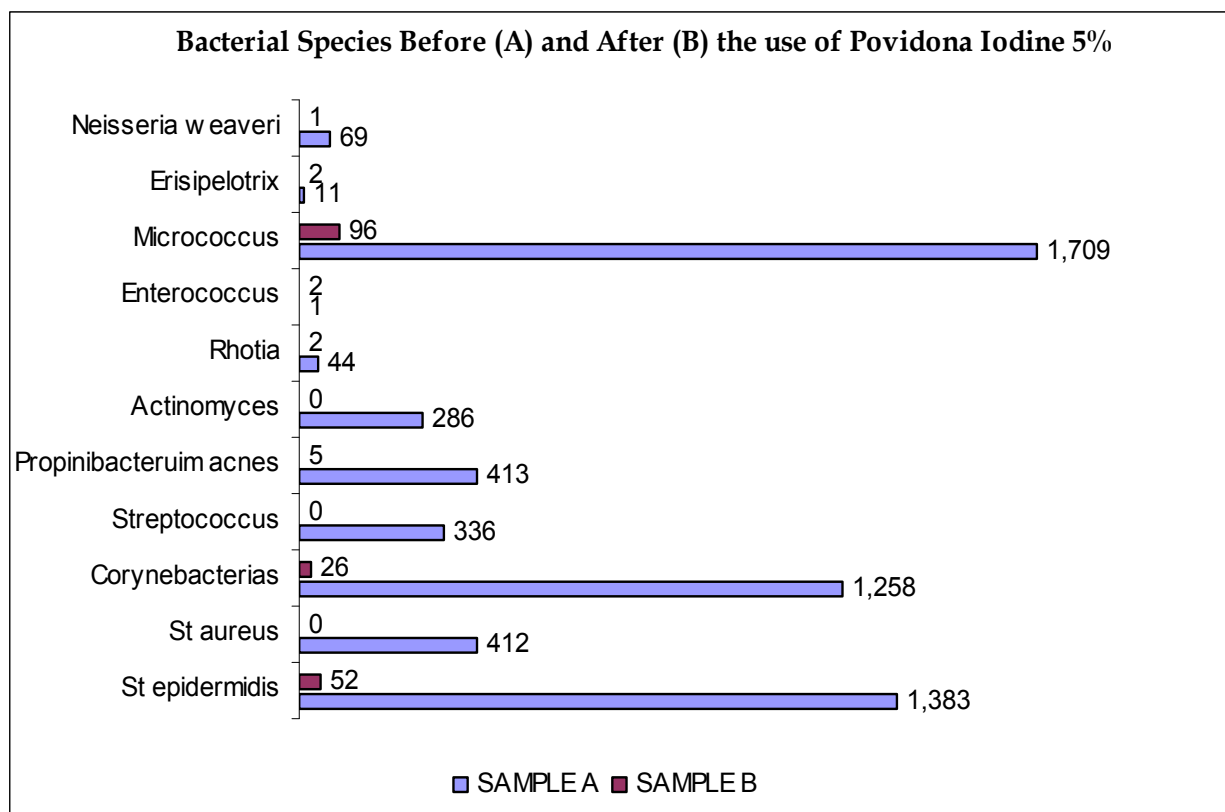


Fig. 3. Some aerobic bacteria like *Staphylococcus epidermidis* and *Micrococcus luteus* are isolated in high quantities in samples A and *Streptococcus pneumoniae*, *Staphylococcus aureus* and *Actinomyces* are diminished to 0 CFU

*Staphylococcus epidermidis*, *Micrococcus luteus*, *Corynebacterium xerosis* and *Propionibacterium acnes* were the bacteria most remained in UFC after antiseptic technique used.

None of the included patients developed post-surgical infectious endophthalmitis or corneal opacity during surgery. The main conjunctival colonization measured by individuals were by *Staphylococcus epidermidis* in 53% of the patients and 18.5% by *Propionibacterium acnes*.

Bacterial genera	specie	Sample A (n=100) Total CFU	Sample B (n=100) Total CFU
<i>Staphylococcus</i>	<i>epidermidis</i>	1383	52
	<i>aureus</i>	487	0
<i>Streptococcus</i>	<i>pneumoniae</i>	335	0
	<i>sanguis</i>	1	0
<i>Micrococcus</i>	<i>spp</i>	79	0
	<i>luteus</i>	1630	96
<i>Corynebacterium</i>	<i>xerosis</i>	627	21
	<i>bovis</i>	116	1
	<i>aquaticum</i>	11	0
	<i>propium</i>	413	0
	<i>Pseudo genitalium</i>	4	1
	<i>renale</i>	4	0
	<i>spp.</i>	75	3
	<i>diphtheriae</i>	6	1
	<i>Pseudo diphtheriae</i>	2	0
	<i>Propionibacterium</i>	<i>acnes</i>	112
<i>Actinomyces</i>	<i>meiyeri</i>	2	0
	<i>odontolyticum</i>	2	0
	<i>pyogenes</i>	286	0
<i>Rothia</i>	<i>dentocariosa</i>	44	2
<i>Erisipelotrix</i>	<i>rusiopathiae</i>	11	2
<i>Bacillus</i>	<i>subtilis</i>	1	0
<i>Enterococcus</i>	<i>faecalis</i>	1	2
<i>Acinetobacter</i>	<i>lwoffii</i>	0	6
<i>Neisseria</i>	<i>elongata</i>	1	0
	<i>weaveri</i>	68	1
<i>Total</i>		5701	193

Table 1. Bacterial CFU in samples A, and bacteria CFU eliminated, diminished or remained in samples B

The number of patients in whom have been diminished conjunctival flora by action of povidone-iodine 5 % solution are presented in Table 2

Genus and specie	n=Pateints before antiseptia	n=Patients after antiseptia	diminished frequency %
<i>Staphylococcus epidermidis</i>	60	32	46.7%
<i>Staphylococcus aureus</i>	8	0	100.0%
<i>Streptococcus pneumoniae</i>	1	0	100.0%
<i>Streptococcus sanguis</i>	1	0	100.0%
<i>Micrococcus spp.</i>	1	0	100.0%
<i>Micrococcus luteus</i>	1	1	0.0%
<i>Enterococcus faecalis</i>	1	2	0.0%
<i>Corynebacterium xerosis</i>	8	1	87.5%
<i>Corynebacterium bovis</i>	4	1	75.0%
<i>Corynebacterium aquaticum</i>	3	0	100.0%
<i>Corynebacterium propinquum</i>	6	0	100.0%
<i>Corynebacterium pseudogenitalium</i>	3	1	66.70%
<i>Corynebacterium renale</i>	1	0	100.0%
<i>Corynebacterium spp.</i>	2	2	0.0%
<i>Corynebacterium diphtheriae</i>	6	1	83.30%
<i>Corynebacterium pseudodiphtheriae</i>	2	0	100.0%
<i>Propionibacterium acnes</i>	27	5	81.50%
<i>Actinomyces meiyeri</i>	1	0	100.0%
<i>Actinomyces odontolyticum</i>	2	0	100.0%
<i>Actinomyces pyogenes</i>	4	0	100.0%
<i>Rothia dentocariosa</i>	4	2	50.0%
<i>Erisipelotrix rhusiopathiae</i>	1	1	0.0%
<i>Bacillus subtilis</i>	1	0	100.0%
<i>Acinetobacter lwoffii</i>	0	1	0.0%
<i>Neisseria elongata</i>	1	0	100.0%
<i>Neisseria weaveri</i>	1	1	0.0%

Table 2. Percentual disimintion of conjunctival colonization, and number of patients with conjunctival colonization.

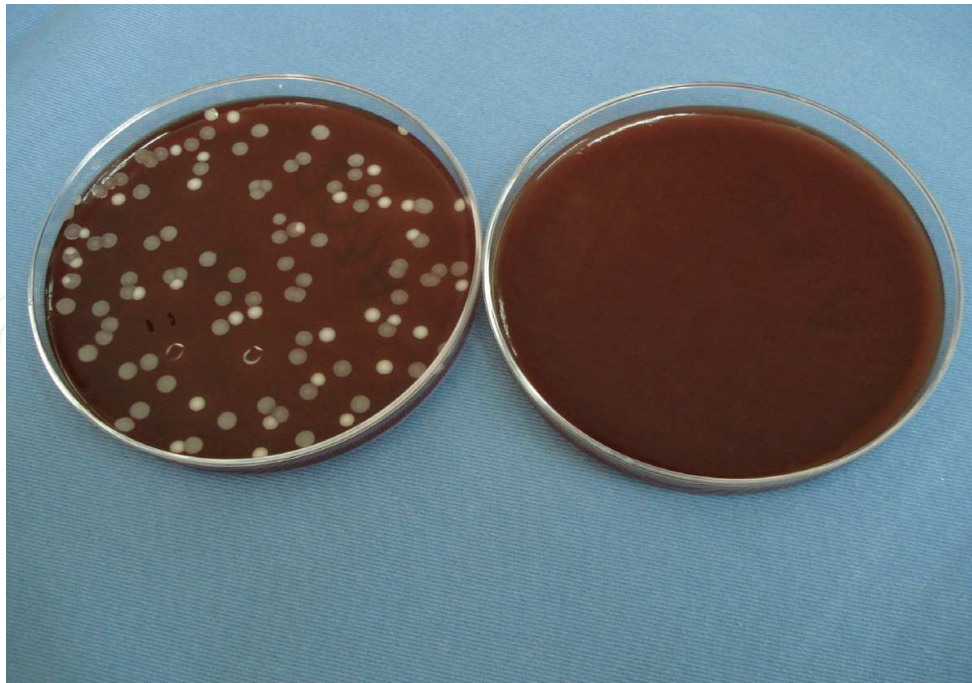


Fig. 4. *Staphylococcus aureus* 120 UFC, *Staphylococcus epidermidis* 104 UFC and *Corynebacterium diptheriae* 1 UFC in samples A in Blood agar. After the antiseptic 5 % povidone-iodine solution technique, *Staphylococcus epidermidis* 2 UFC in sample B

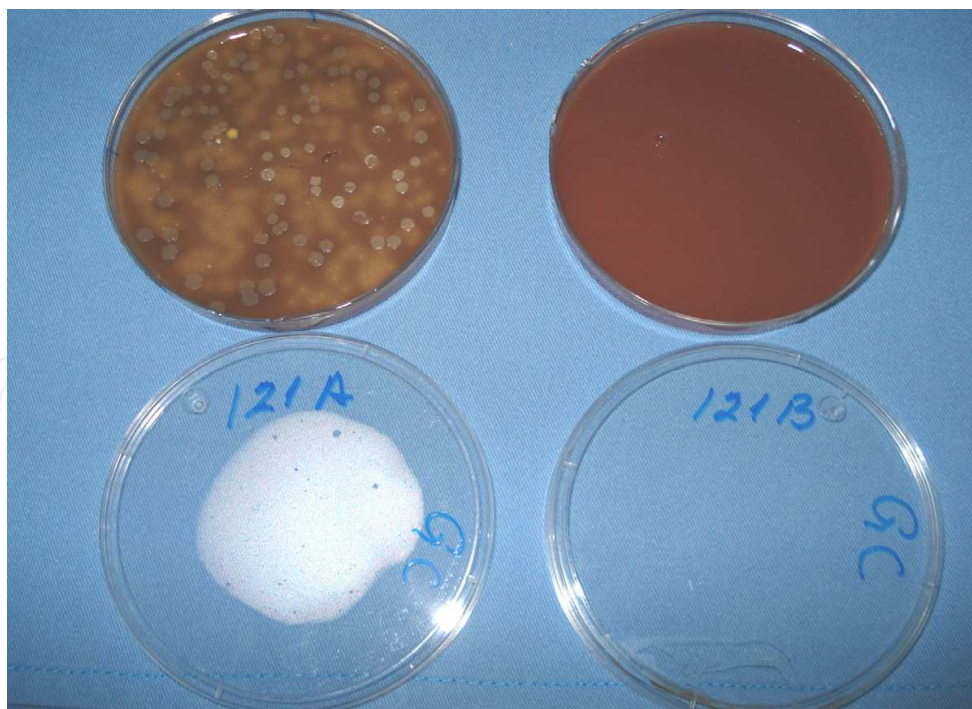


Fig. 5. *Staphylococcus epidermidis* 16 UFC, *Streptococcus pneumoniae* 335 UFC, *Staphylococcus aureus* 74 UFC in samples A in Blood agar and after the antiseptic 5 % povidone-iodine solution technique in sample B *Staphylococcus epidermidis* 1 UFC



### 3. Further research

The contamination of aqueous humor in anterior chamber by periocular flora from conjunctiva, Meibomian and Zies glands, or lids, was demonstrated by Saint-Blancart even with the application of topical antibiotic drops before the surgery [8] and the confirmation that are the same *Staphylococcus epidermidis* from conjunctival flora was made by rPCR methods by pulse fields in gel [2].

In our survey the most numerous bacterial colonization was *Staphylococcus epidermidis* and *Micrococcus luteus* isolated in conjunctiva before the antiseptic solution application and remained some CFU from both species in the patients conjunctivas after the antiseptic application, as it is described by Bausz [9].

We found *Corynebacterium diphtheriae* in normal conjunctivas before the antiseptic application (sample A), with no clinical significance, because they did not have in the bacterial cells DNA the structural Gen of Fago B that make it synthesize its harmful toxin. *Rothia dentocariosa* were found in the sample A in two patients, and remained in one patient after the antiseptic method, this anaerobic bacteria, has been related as corneal pathogen [10] or as post-surgical endophthalmitis cause [11] in our patients did not have clinical significance.

Survival bacterial in presence of universal antiseptic solution as 5% povidone-iodine measured in comparative application methods [12] are indicative of some physical protective mechanism for bacteria as mucus, or tears proteins that capture the iodine molecules and its remained in Henle conjunctival crypts, factors that have not been well studied.

There is no total conjunctiva surface asepsia using topical antibiotic drops alone or iodine compound as demonstrate Inoue. [13]

For this reason there are some antiseptic proposal using topical antibiotics drops in conjunctiva during three days before the anterior segment intraocular surgery [14] reaching an important reduction of bacterial CFU in the conjunctival surface and using 5% povidone iodine solution before the ocular surgeries.

Has been suggested the use of polyhexamethyl-biguanida as preoperative antiseptic for cataract surgery with equal microbicidal efficacy that povidone-iodine [15], this application have not further demonstrative studies. The comparison between povidone -iodine 16 times diluted from 10% concentration and 0.05% solution of chlorexidine gluconate, povidone iodine solution showed superior disinfectant effect. [16]

### 4. Conclusion

This survey demonstrate the effectiveness of 5% povidone-iodine aqueous solution for the eradication of pathogenic bacteria like *Streptococcus pneumoniae*, *Staphylococcus aureus*, *Actinomyces pyogenes*, *A. meiyeri*, and *A. odontolyticus* in conjunctival surface.

The largest population of *Staphylococcus epidermidis* and *Micrococcus luteus* in conjunctival isolated in sample A remained in low quantities in sample B with statistical significance.

There were two patients with colonization after antiseptic technique method used as described, with a different bacterial genus in sample A that in sample B, the colonization was caused by *Acinetobacter lwoffii* and *Enerobacter faecalis*.

With the exception of *Micrococcus luteus* and *Corynebacterium xerosis* others bacterial species were present in conjunctiva after the antiseptic in very low quantities as 1 or 2 colonies.


## 5. References

- [1] M.S. Osato, Normal ocular flora. En Pepose JS, Holland GN, Wilhelmus KR. *Ocular Infection and Immunity* Mosby Co. 2a ed. 1998, pp. 191-199.
- [2] T. L. Bannerman, D. L. Rhoden, S. K. Mc Allister, J. M. Millar, L. A. Wilson. The source of coagulase-negative staphylococci in the Endophthalmitis Vitrectomy Study. A comparison of eyelid and intraocular isolates using pulsed-field gel electrophoresis. *Arch Ophthalmol.* no 115: 357-361. Mar. 1997.
- [3] L. Apt, S. Isenberg, R. Yoshimori, J. H. Paez. Chemical preparation of the eye in ophthalmic surgery. III. Effect of povidone-iodine on the conjunctiva. *Arch Ophthalmol* no 102 pp 728- 729. May 1984.
- [4] M. G. Speaker, J. A. Menikoff. Prophylaxis of endophthalmitis with topical povidone-iodine. *Ophthalmology.* no 98 pp1769-75, Dec. 1991.
- [5] T.A. Ciulla, M. B. Starr, S. Masket. Bacterial endophthalmitis prophylaxis for cataract surgery an evidence-base update. *Ophthalmology*; vol. 1 no. 109 pp 13-24. Jan. 2002.
- [6] D. B. Jones, T. J. Liesegang, M. N. Robinson, Cumitech 13 Laboratory diagnosis of ocular infections. *Amer. Soc. for Microbiology* Washington D.C. pp 1-27. 1981.
- [7] M. H. Kaspar, R. T. Chang, K. Singh, P. R. Eghert, M. S. Blumenkranz, C. N. Ta. Prospective randomized comparison of 2 different methods of 5% povidone-iodine applications for anterior segment intraocular surgery. *Arch Ophthalmol.* Vol. 123 pp 161-165. Feb. 2005.
- [8] P. Saint-Blancart, C. Burucoa, M. Boissonnot, F. Gobert, J. F. Risse. Search of bacterial contamination of the aqueous humor during cataract surgery with and without local antibiotic prophylaxis. *J. Fr Ophthalmol* no 18 vol 11 pp. 650 sup. Nov 1995.
- [9] M. Bausz, E. Fodor, M.D. Resch, K. Kristóf. Bacterial contamination in the anterior chamber after povidone-iodine application and the effect of the lens implantation device. *Cataract Refract Surg* no. 32 vol. 10 pp. 1691 sup.S. Oct. 2006.
- [10] Morley AM, Tuft SJ. *Rothia dentocariosa* isolated from a corneal ulcer. *Cornea* no 25 vol 9 pp 1128-9 Oct 2006.
- [11] M. M. MacKinnon, M. R. Amezaga, J. R. McKinnon. A case of *Rothia dentocariosa* endophthalmitis. *Microbiol Infect Dis* no. 20 vol. 10 pp. 756-7. Oct. 2001.
- [12] H. Miño de Kaspar, R. T. Chang, K. Singh, P. R. Egbert, M. S. Blumenkranz, C. N. Ta. Prospective randomized comparison of 2 different methods of 5% povidone-iodine applications for anterior segment intraocular surgery. *Arch Ophthalmol* no 123 pp. 161-165 Feb. 2005.
- [13] Y. Inoue, M. Usui, Y. Ohashi, H. Shiota, T. Yamazaki. Preoperative disinfection of the conjunctival sac with antibiotic and iodine compounds: A prospective randomized multicenter study. *Jpn J. Ophthalmol* no. 52 vol. 3 pp. 151-61 May-Jun. 2008.
- [14] C. N. Ta, R. C. Lin, G. Singh, H. Miño de Kaspar. Prospective study demonstrating the efficacy of combined preoperative three-day application of antibiotic and povidone-iodine irrigation. *Ann Ophthalmol.* (Skokie) no. 39 vol. 4 pp. 313-7. Dec. 2007.
- [15] Hasmann F, Kramer A, Ohgke H, Strobel H, Müller M, Geerling G. *Ophthalmologie.* No. 101 vol 4:pp 377-83. Apr. 2004.

- [16] Yokohama Y, Makino S, Ibaraki N. Comparison in effectiveness of sterilization between chlorexidine gluconate and povidone iodine. Nippon Ganka Gakkai Zasshi no 12. vol 2. pp. 148-51. Feb. 2008.

IntechOpen

IntechOpen



## **Conjunctivitis - A Complex and Multifaceted Disorder**

Edited by Prof. Zdenek Pelikan

ISBN 978-953-307-750-5

Hard cover, 232 pages

**Publisher** InTech

**Published online** 23, November, 2011

**Published in print edition** November, 2011

This book presents a number of interesting and useful aspects and facets concerning the clinical features, properties and therapeutical management of this condition. Dr. H. Mejía-López et al. present an interesting survey of the world-wide epidemiologic aspects of infectious conjunctivitis. Dr. U. Ubani evaluates conjunctival symptoms/signs participating in the clinical features of this disorder. Dr. A. Robles-Contreras et al. discuss immunologic aspects underlying possibly the conjunctivitis. Dr. Z. Pelikan presents the cytologic and concentration changes of some mediators and cytokines in the tears accompanying the secondary conjunctival response induced by the nasal challenge with allergen. Dr. S. Sahoo et al. summarize the treatment and pharmacologic control of particular clinical forms of conjunctivitis in general practice. Dr. S. Leonardi et al. explain the basic pharmacologic effects of leukotriene antagonists and their use for the treatment of allergic conjunctivitis. Dr. J.A. Capriotti et al. evaluate the therapeutical effects of various anti-adenoviral agents on the acute conjunctivitis caused by adenovirus. Dr. V. Vanzzini-Zago et al. assess the prophylactic use and efficacy of "povidone-iodium solution", prior the ocular surgery. Dr. F. Abazi et al. present the clinical features, diagnostic and therapeutical aspects of "neonatal conjunctivitis". Dr. I.A. Chaudhry et al. review the special sub-form of conjunctivitis, being a part of the "Trachoma". Dr. B. Kwiatkowska and Dr. M. Maślińska describe the clinical, pathophysiologic and immunologic features of conjunctivitis. Dr. S. Naem reviews the conjunctivitis form caused by *Thelazia* nematodes, occurring principally in animals.

### **How to reference**

In order to correctly reference this scholarly work, feel free to copy and paste the following:

Virginia Vanzzini-Zago, Jorge Villar-Kuri, Víctor Flores Alvarado, Alcántara Castro Marino and Pérez Balbuena Ana Lilia (2011). Conjunctival Flora Before and After Application of 5% Povidone-Iodine Solution, *Conjunctivitis - A Complex and Multifaceted Disorder*, Prof. Zdenek Pelikan (Ed.), ISBN: 978-953-307-750-5, InTech, Available from: <http://www.intechopen.com/books/conjunctivitis-a-complex-and-multifaceted-disorder/conjunctival-flora-before-and-after-application-of-5-povidone-iodine-solution>

**INTECH**  
open science | open minds

### **InTech Europe**

University Campus STeP Ri  
Slavka Krautzeka 83/A  
51000 Rijeka, Croatia

### **InTech China**

Unit 405, Office Block, Hotel Equatorial Shanghai  
No.65, Yan An Road (West), Shanghai, 200040, China  
中国上海市延安西路65号上海国际贵都大饭店办公楼405单元

[www.intechopen.com](http://www.intechopen.com)

Phone: +385 (51) 770 447  
Fax: +385 (51) 686 166  
[www.intechopen.com](http://www.intechopen.com)

Phone: +86-21-62489820  
Fax: +86-21-62489821

IntechOpen

IntechOpen

© 2011 The Author(s). Licensee IntechOpen. This is an open access article distributed under the terms of the [Creative Commons Attribution 3.0 License](#), which permits unrestricted use, distribution, and reproduction in any medium, provided the original work is properly cited.

IntechOpen

IntechOpen