

We are IntechOpen, the world's leading publisher of Open Access books Built by scientists, for scientists

6,700

Open access books available

180,000

International authors and editors

195M

Downloads

Our authors are among the

154

Countries delivered to

TOP 1%

most cited scientists

12.2%

Contributors from top 500 universities



WEB OF SCIENCE™

Selection of our books indexed in the Book Citation Index
in Web of Science™ Core Collection (BKCI)

Interested in publishing with us?
Contact book.department@intechopen.com

Numbers displayed above are based on latest data collected.
For more information visit www.intechopen.com



Current Controversies in the Surgical Management of Melanoma

Joyce DP, Prichard RS and Hill ADK
*Beaumont Hospital, Dublin
Ireland*

1. Introduction

The incidence of malignant melanoma has increased exponentially in recent decades (Jemal et al., 2001). Indeed it has been estimated that the incidence worldwide doubles every 10 to 15 years (Cascinelli & Marchesini, 1989). The American Cancer Society projected over 38,000 new cases of melanoma in males and 29,000 in females in 2009 (American Cancer Society, 2009). Currently, melanoma accounts for 3% of cancer diagnoses annually and although this is fewer than the reported incidence of other skin cancers the prognosis is unfortunately significantly worse. Melanoma accounts for 2% of cancer deaths in men and 1% in women (Boring et al., 1994). Survival is directly related to stage at diagnosis. Recent years have seen improvements in overall survival with 87% survival at five years for all patients, and 94% in patients with localized disease (Parker et al., 1996; Kopf, 1988). However, survival for patients with stage IV disease remains low at 25% at 2 years (Balch et al., 2001).

Public awareness of melanoma has increased in parallel with this increasing incidence. The most important risk factor is intermittent high exposure to ultraviolet radiation. However, despite this increasing awareness, the practice of ultraviolet radiation protection behaviour is low. Worryingly, in a 2005 survey in the US up to 14% of adults, primarily women and young adults, reported the use of indoor tanning devices on at least one occasion (American Cancer Society, 2009).

The mainstay of treatment is surgical excision with intention to cure (Prichard et al., 2002). However, the last decade has seen a paradigm shift in the surgical approach to this disease. The management of the primary tumour has become more conservative, with acceptance of narrower excision margins. Similarly, there has been a move away from the routine performance of an elective regional lymph node dissection, towards the utilization of sentinel lymph node biopsies to accurately stage the patient's disease. The purpose of this chapter is to highlight the appropriate surgical management of both the primary tumour and the associated regional lymph node basin. We also aim to distil current controversies in the management of the regional lymph node basin.

2. Diagnosis

Any suspicious naevi or skin lesions should be assessed, using either the ABCDE system or the 7-point checklist shown below.

Seven point checklist:	The ABCDE lesion system:
<i>Major features are:</i>	
Change in size	A Geometrical Asymmetry in 2 axes
Irregular shape	B Irregular Border
Irregular colour	C At least 2 different Colours in lesion
<i>Minor features are:</i>	D Maximum Diameter >6 mm
Largest diameter 7 mm or more	E Elevation of lesion
Inflammation	
Oozing	
Itch/change in sensation	

Table 1. Seven point checklist and ABCDE system for assessment of pigmented lesions (Whited, JD et al. 1998)

2.1 Risk factors

Risk factors for the development of malignant melanoma are varied and include genetic susceptibility, exposure to ultraviolet radiation, and immunologic deficits (Friedman et al., 1991). The most important of these is intermittent ultraviolet exposure. Intermittent unaccustomed sun exposure and sunburn history were found to have considerable roles as risk factors for melanoma. Interestingly, they reported that high occupational exposure was inversely associated to melanoma (Gandini et al., 2005).

Epidemiological studies have identified: blue, green or grey eyes, blonde or red hair, light complexion, freckles, sun sensitivity, and the inability to tan, as risk factors for the development of melanoma (Evans et al., 1988; Gellin et al., 1969). Countries with predominantly fair-skinned populations have shown that increasing proximity to the equator is associated with an increased risk of developing melanoma. Although it is not possible to modify genetic factors, minimizing exposure to ultraviolet radiation, in particular intermittent exposure to high intensity radiation, and the adoption of photoprotective measures, can significantly reduce the risk of development of melanoma (Brozena, 1993; Friedman, 1991). The most commonly practiced sun protection behaviours in a national sample of US adults were the application of sunscreen and shade seeking. The use of protective clothing (hats and long-sleeved shirts) was less frequently practiced (American Cancer Society, 2009)

Other risk factors for the development of melanoma include: a positive family history (Greene et al., 1985) personal history of melanoma or non-melanoma cancer or in-situ skin carcinoma (Evans et al., 1988), large numbers of melanocytic naevi in childhood (Holman & Armstrong, 1984), and xeroderma pigmentosum (Kraemer, 1984).

2.2 Biopsy

Suspicious lesions should undergo a full thickness excisional biopsy (Lees & Briggs, 1991). This should include the full thickness of the lesion with a 1- 3 mm margin of clinically

normal skin and subcutaneous fat. The surgical incision should be planned with definitive treatment in mind. This should include longitudinal orientation in the extremities. In addition, narrow excision margins are recommended, in order to avoid interference with subsequent sentinel lymph node mapping (Royal College of Surgeons Guidelines, 2006).

As shave and punch biopsies make pathological staging of melanoma impossible, their routine use is not recommended (Royal College of Surgeons Guidelines, 2006). Incisional biopsies may also render lesions difficult to assess on histopathological criteria, but they may be acceptable in certain anatomic locations such as the palm or sole, digit, face, ear, subungual areas, or in very large lesions. Incisional biopsies have not been associated with a worse prognosis, in terms of local or regional recurrence rates or mortality (Ledeerman & Sober, 1985; Lees & Briggs, 1991; Austin et al., 1996; Royal College of Surgeons, 2006).

3. Surgical management of the primary tumour

The surgical management of the primary tumour has shifted from extensive surgical resection, which was not only debilitating but also disfiguring, to a more conservative approach. Patients with malignant melanoma should ideally be managed by a multidisciplinary team in a tertiary referral centre. This team should include: a dermatologist, surgeon, medical oncologist, pathologist, radiologist, counsellor, specialist nurse and palliative care specialist (Royal College of Surgeons, 2006).

Excision biopsy of histologically confirmed melanoma should be followed by excision of the melanoma scar with a macroscopic margin of normal skin (Royal College of Surgeons, 2006). Previously, wider excision margins have been used to prevent lymphatic spread to the draining lymph node basin. Numerous studies have, however, failed to show any statistically significant difference between wide excision margins ranging from 3 – 5 cm, and narrower margins of 1 – 2 cm, in terms of local recurrence, mortality and disease-free survival. In addition, wider excision margins are associated with greater morbidity. (Thomas et al., 2004). Excision margins around primary melanoma should not be less than 1 cm. Exception to this rule is made for in-situ melanoma, where confirmed histological excision is adequate (Haigh et al., 2003).

The risk of death from melanoma is dependent on a number of factors, including tumour thickness according to the Breslow classification (Breslow, 1980), the presence of ulceration in the primary tumour, micrometastases to sentinel nodes, tumour site and gender (Balch et al., 2001). As survival is directly dependent on tumour thickness, current guidelines recommend excision margins based on Breslow thickness of the initial excision biopsy (Royal College of Surgeons, 2006). For patients with T1 tumours, a margin of 1 cm is advised. In this group of patients, where melanoma are less than 1 mm thick, rates of local recurrence are not higher when an excision margin of 1 cm is used instead of wider margins (Veronesi et al., 1977). A 1 – 2 cm excision margin is recommended for T2 lesions. Long-term results of a randomised trial have shown that a melanoma greater than 0.8 mm and less than or equal to 2 mm thickness can be treated with excision margins of 2 cm, as safely as those with 5 cm margins. Rates of local recurrence are not higher in patients with the narrower 2 cm margin. Similarly, rates of overall survival and recurrence-free survival are not higher in patients with narrower resection margins (Cohn-Cedarmark et al., 2000). T3 and T4 lesions should have a 20 mm margin. Loco-regional recurrence rates have been shown to be higher in melanoma greater than or equal to 2 mm thickness that is excised with a 1 cm margin, instead of a 3 cm margin. However, overall survival rates are similar in both groups. There

is insufficient data to support the preferred use of either a 2 cm or 3 cm margin, and consequently, it may be reasonable to allow the patient to decide, following an informed discussion of surgical options. The use of the larger 3 cm margin is however recommended in patients with deep tumours (> 4 mm depth), due to the higher risk of loco-regional recurrence (Thomas et al., 2004). In selected cases, however, margin size may be modified to accommodate individual anatomic or cosmetic considerations (Royal College of Surgeons, 2006). Table 2 shows a summary of recommended excision margins based on tumour size.

Margins	
Tis	Histologically clear margins are adequate
T1	1 cm margin recommended
T2	1-2 cm margin recommended
T3&T4	2 - 3 cm margin recommended

Table 2. Recommended excision margins based on tumour size

3.1 In-transit metastasis

In-transit metastases are defined as cutaneous or subcutaneous deposits of melanoma between the site of primary disease and regional lymph nodes (Hayes et al., 2004). Deposits may be localized around the primary tumour, may be widespread throughout the affected limb, or on the head, neck or trunk, depending on the primary site. The number of deposits generally increases over time (Hayes et al., 2004). They are thought to arise from dissemination of melanoma cells via lymphatics to tissues located primarily between the primary tumour and the regional lymph node basin. Other theories include that of drift metastases within tissue fluid of the limb (McCarthy, 2002) or the local implantation of circulating haematogenous melanoma cells (Heenan & Ghaznawie, 1999).

The presence of small in-transit metastatic melanoma presents specific surgical problems. Unlike nodal disease, which can be managed by regional lymph node dissection (with local recurrences being uncommon), in-transit disease is often widespread and may necessitate multiple surgeries as the disease progresses and new deposits become apparent. This may cause a great deal of distress for patients. In its most severe form, in-transit metastasis may become severely disabling and may be refractory to treatment. Treatment is therefore, palliative, even if staging investigations fail to show evidence of distant metastatic disease (Hayes et al., 2004). Recent studies have recommended that treatment should be tailored to the extent of the disease, with treatments associated with significant morbidity being reserved for bulky advanced metastases (Hayes et al., 2004).

In-transit metastases are sharply circumscribed with a clear line demarcating them from normal dermis and epidermis. This line does not contain any in-situ component. Therefore, wide excision margins are not recommended for these lesions, and, therefore, a complete macroscopic excision and primary closure is sufficient. If lesions are grouped closely together, an en bloc excision is acceptable (Hayes et al., 2004).

There are numerous treatments available for management of in-transit metastases that are not amenable to surgical excision. Carbon dioxide laser therapy has been used in the

management of multiple small in-transit metastases that are not suitable for surgical excision. This treatment may be performed under local anaesthetic or if a very large number of lesions are present, general anaesthetic. It is suitable for use as a day-case procedure. If the lesion is small -measuring less than 3 mm- it may be vapourized completely. Larger lesions, however, are first circumscribed with the laser followed by excision of the central core. Haemostasis is achieved with a pressure dressing, following treatment. This procedure is tolerated well by patients, as it is relatively pain free. Wound healing may take up to 6 weeks following treatment. The value of carbon dioxide laser therapy is highest in patients with multiple small lesions, but it is less useful in patients with larger deposits. It has been recommended that this treatment be undertaken before isolated limb perfusion, as the latter is associated with significant morbidity (Hayes et al., 2004).

Isolated limb perfusion (ILP) was first described in the 1960s (Creech & Kremenz, 1966). This process involves the application of a tourniquet to the affected limb, thereby isolating it from the systemic circulation, and administering cytotoxic agents via an extracorporeal bypass circuit. This procedure is performed under general anaesthetic. The first step is to expose and cannulate the artery and vein supplying the affected limb. The chemotherapeutic agent is then perfused over a period of 1 hour. Agents used include melphalan and dacarbazine. TNF- α has been shown to increase response rates, when given with melphalan (Lienard et al., 1992). It is thought to work by targeting neo-vasculature instead of being directly cytotoxic to tumour cells, and is of use in larger deposits (Fraker, 1999). This is then followed by a washout period lasting 30 minutes (Hayes et al., 2004). Advantages of this procedure include the delivery of high doses (up to tenfold higher than the dose tolerated systemically) of chemotherapeutic agents to the affected limb, with a reduction in systemic toxicity (Brielle et al., 1985). Disadvantages of this treatment are numerous: local toxicity may be in the form of mild erythema or even epidermolysis and deep tissue damage (Wieberdink et al., 1982). High pressures may lead to compartment syndrome requiring fasciotomy (Mubarak & Owen, 1977). Hypotension and myelosuppression may result from leakage of perfusate into the systemic circulation (Hayes et al., 2004). One study found that patients with stage III disease, who were treated with BCG and dimethyltriazeno imidazole carboxamide (DTIC), trended towards a delay in recurrence and increased survival, but this was not statistically significant (Can Med Assoc J. 1983). Similarly, the use of interferon alpha for isolated limb perfusion is not supported by strong scientific evidence (RCSI guidelines, 2006).

More recently, the role of isolated limb infusion in the management of in-transit metastasis is being investigated. This technique is minimally invasive, easy to perform and is more economical than isolated limb perfusion (Brady et al, 2006; Mian et al, 2001). The size of the area treated depends on disease severity and ranges from a small section of a limb to the entire limb. The first step in this process is to determine the volume of the limb in order to allow calculation of the appropriate dose of chemotherapeutic agents. A number of techniques have been described for calculation of limb volume. These include the use of programs which take into account serial limb measurements. Other centres use the formula $\pi r^2 h$ to calculate limb volume at measured intervals. The next step is the placement of arterial and venous catheters into the contralateral limb. The catheter tips must lie above the knee or elbow. A hot air blanket is placed over the affected limb with the intention in inducing a temperature of 38-40 degrees Celcius (limb hyperthermia). The patient is anaesthetised and 30ml of papaverine is administered followed by a heparin flush. A tourniquet is then applied. A mixture of dactinomycin and melphalan are circulated for 20

TNM Staging Categories for Cutaneous Melanoma		
Classification	Thickness (mm)	Ulceration Status/Mitoses
Tis	NA	NA
T1	≤ 1.00	a: Without ulceration and mitosis < 1/ mm ² b: With ulceration or mitoses ≥ 1/ mm ²
T2	1.01-2.00	a: Without ulceration b: With ulceration
T3	2.01-4.00	a: Without ulceration b: With ulceration
T4	> 4.00	a: Without ulceration b: With ulceration
N	No. of Metastatic Nodes	Nodal Metastatic Burden
N0	0	NA
N1	1	a: Micrometastasis* b: Macrometastasis†
N2	2-3	a: Micrometastasis* b: Macrometastasis† c: In transit metastases/satellites without metastatic nodes
N3	4+ metastatic nodes, or matted nodes, or in transit metastases/satellites with metastatic nodes	
M	Site	Serum LDH
M0	No distant metastases	NA
M1a	Distant skin, subcutaneous, or nodal metastases	Normal
M1b	Lung metastases	Normal
M1c	All other visceral metastases	Normal
	Any distant metastasis	Elevated
Abbreviations: NA, not applicable; LDH, lactate dehydrogenase. Micrometastases are diagnosed after sentinel lymph node biopsy. †Macrometastases are defined as clinically detectable nodal metastases confirmed pathologically.		

Table 3. TNM staging categories for cutaneous melanoma (Balch et al., 2009)

minutes by withdrawing through the venous circuit and infusion into the arterial circuit. One litre of Hartmann's solution is then infused to remove the chemotherapeutic agents. Following the infusion the tourniquet and catheters are removed, a pressure dressing is applied and the patient's leg is elevated (Al-Hilli et al, 2007).

Isolated limb infusion has a number of advantages over isolated limb perfusion. Firstly, it is associated with a lower rate of complications including erythema, skin loss, compartment syndrome, myopathy, neuropathy and limb loss (1%). In addition, catheters are placed percutaneously making it less invasive with no requirement for a bypass circuit. Operating time is shorter than for isolated limb perfusion (4 hours for isolated limb perfusion versus 1 hour for isolated limb infusion). Complete response rates of 45% and partial response rates of 42% have been reported for isolated limb infusion compared to complete response rates of 40% and partial response rates of 40% for isolated limb perfusion (Brady et al, 2006; Mian et al, 2001).

The presence of in-transit metastases indicates a poor prognosis. The development of in-transit disease is rapidly followed by distant metastases (Hayes et al., 2004). The American Committee on Cancer Staging (AJCC) classify it as stage IIIB or IIIC disease, along with regional lymph node metastases. Five year survival rates in patients with stage III disease ranges from 18% to 60%. However, patients with in-transit metastasis have the worst prognosis, with 5 year survival of approximately 25% (Hayes et al., 2004).

3.2 Reconstruction

The optimal treatment of patients is primary closure, following excision of the primary tumour with adequate margins. Unfortunately, this is not always possible, and the patient may require reconstructive surgery. The type of reconstruction employed depends on the location of the melanoma. Skin grafts are often used, following excision of melanoma on the limbs. Traditionally, these were harvested from the contralateral limb, as melanoma was thought to metastasize primarily via lymphatic routes (Cade, 1961, Roberts et al., 2002). A recent study has shown that there is no difference in rates of donor site recurrence whether the ipsilateral or contralateral limb is used. The authors recommended that to improve patients post-operative recovery, the skin graft be harvested from the same limb as the primary tumour (Schumacher et al., 2010).

The use of skin grafts on the head and neck, however, is not always ideal, and may give rise to significant deformity. Local rotational skin flaps, such as rhomboid flaps, are safe, versatile, and aesthetically pleasing when used in this area (Lent & Aryian, 1994). They may also be of use in very large areas where a skin graft alone would give a poor cosmetic result.

4. Management of the regional lymph node basin

The outcome in patients diagnosed with melanoma is dependent, not only on tumour thickness, but also on the presence of regional or distant metastasis (Lees & Briggs, 1991). In fact, regional lymph node status is thought to be the most powerful prognostic indicator in clinically localized melanoma (Morton et al., 2006). The presence of regional nodal metastasis is associated with a 50% reduction in survival (Royal College of Surgeons, 2006). The rate of nodal metastatic disease is largely dependant upon the initial tumour thickness. T1 melanoma has a favourable outlook, with a 10% risk of occult nodal metastasis. Approximately 25% of patients, with melanoma between 1.5 - 4.0 mm thick, have lymph node metastasis at presentation. 60% of patients with melanoma greater than 4 mm will

show regional lymph node metastasis at diagnosis. These data form the basis for the current guidelines on which patients should be offered a sentinel lymph node biopsy (Royal College of Surgeons, 2006).

Patients diagnosed with stage III disease commonly have clinically negative lymph nodes but are found to have micro-metastatic disease on their sentinel lymph node biopsy. Such patients have a more favourable outcome than patients with clinically involved nodes at presentation (Balch et al., 2009). The major determinants of outcome for stage III disease are: number of metastatic lymph nodes and the presence of either microscopic or macroscopic disease. Five-year survival rates for patients with stage IIIA disease is 67%, and 10-year survival is 60%. Five-year survival rates for patients with stage IIIB disease is estimated at 53%. Stage IIIC disease has a poorer prognosis with 5-year survival of approximately 26% (Balch et al., 2001).

5. The sentinel lymph node biopsy

The sentinel lymph node is defined as any lymph node that receives lymphatic drainage directly from a primary tumor site (Thompson, 2001; Uren et al., 1994). The rationale for undertaking a sentinel lymph node biopsy in melanoma is to firstly to provide prognostic information and secondly to allow node negative patients avoid an unnecessary lymph node dissection. The current indications for sentinel lymph node biopsy include intermediate thickness melanoma, 1 - 4 mm (Morton et al., 2006). However, a study published this year also recommended that patients with thin melanoma, greater than 0.75 mm and or ulceration, should be considered for a sentinel lymph node dissection, although this has as yet not gained widespread acceptance (Yonick et al., 2011).

The use of sentinel lymph node biopsy allows surgeons to appropriately select patients for complete lymph node dissection, instead of undertaking lymph node dissection in all patients. This practice allows assessment of the regional lymph node basin with low rates of morbidity (Gershenwald et al., 1999). By managing occult nodal metastases early, through sentinel lymph node dissection, the patients risk of melanoma-related death is reduced (Faries et al., 2010).

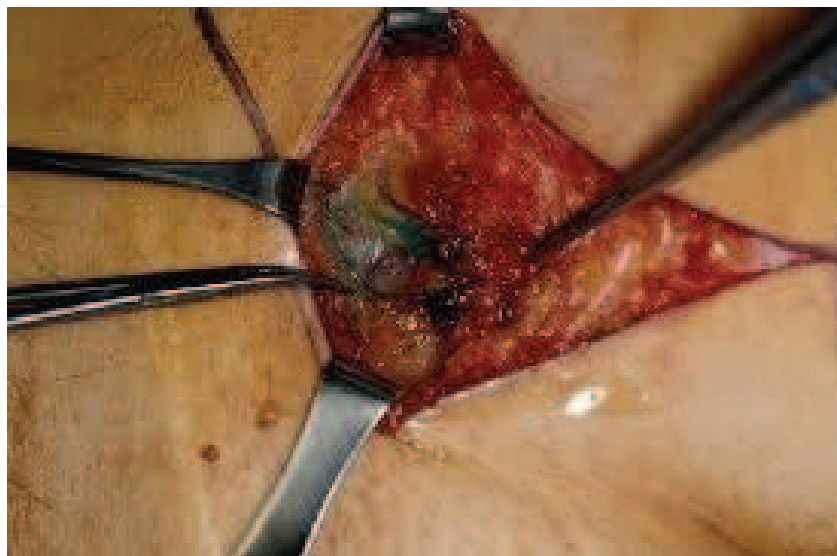


Fig. 1. The sentinel lymph node biopsy

The technical details of sentinel lymph node biopsy can be broken down into a number of steps. First, the patient undergoes preoperative lymphoscintigraphy which identifies the regional nodal basin and estimates the location of the sentinel node. Four intradermal injections of 0.1–0.2 ml of 10 mBq radiocolloid are performed around the melanoma or melanoma scar: the injection should raise a small wheal on the skin. The most commonly used radiotracers are ^{99m}Tc -labeled albumin (Europe), ^{99m}Tc -labeled sulfur colloid and ^{99m}Tc -antimony trisulfide colloid. Scintillation cameras are used to obtain dynamic images. These images allow identification of sentinel nodes within the regional nodal basin. They also allow discrimination of second-tier nodes, which may be falsely interpreted as sentinel nodes on delayed imaging. The surface location of the sentinel node may be marked on the skin preoperatively or, alternatively, a gamma probe can be used to locate the node intra-operatively. Intra-operative lymphatic mapping involves injection of vital blue dye (Isosulfan blue (Lymphazurin), Methylene Blue or Patent Blue V are used). A combination of radiotracers and blue dye has been shown to allow sentinel node identification in 99% of cases. The blue dye is injected intra-dermally (again to produce a wheal) in 2–4 locations at the site of the primary lesion, 10–15 minutes before skin incision. The dye is used to visualize the sentinel node intra-operatively. A gamma probe (covered in a sterile plastic sheath), which detects radiation, may be used to locate the sentinel node. Counts should be obtained over the skin before incision, to confirm the location of the sentinel node. A short skin incision is made, bearing in mind the potential need for complete lymph node dissection. The sentinel nodes are then identified using the blue dye and gamma probe as a guide, and they are removed with minimal dissection. An ex-vivo count should be obtained, by measuring the radioactivity of the sentinel node(s) after removal. A bed count is then also obtained following removal of the sentinel node(s), to ensure that no sentinel nodes remain (Bagaria et al., 2010).



Fig. 2. Gamma probe used to locate sentinel lymph node

Significant controversy surrounds the use of sentinel lymph node biopsy in thin, early melanomas. There are a number of reasons for this. Firstly, patients with a low-risk of nodal metastases are exposed to the toxicity of a potentially unnecessary procedure. Secondly, the routine use of sentinel lymph node biopsy is expensive: global application of sentinel lymph node biopsy in all patients is estimated to cost between \$700,000 and \$1,000,000 for every sentinel node metastasis detected (Agnese et al., 2003).

Can we therefore use the sentinel lymph node technique selectively in patients with thin melanomas? Multiple studies have examined risk factors for poor prognosis in patient with thin melanoma. Age has been shown to be associated with a decreased overall and melanoma-specific survival (Faries et al., 2010). Paradoxically, age is associated with a lower risk of lymph node metastases. This paradox can be explained by decreased lymphatic function with advancing age (Conway et al., 2009). Other risk factors which have been put forward as predictors of lymph node metastasis include: sex, vertical growth phase, Breslow thickness, mitotic rate, Clark level, and tumour-infiltrating lymphocytes (Bedrosian et al., 2000; Bleicher et al., 2003; Cecchi et al., 2007; Gimotty et al., 2004; Kesmodel et al., 2005; Oliveira et al., 2003; Puleo et al., 2005; Vaquerano et al., 2006).

These specific factors remain controversial and several studies have questioned their importance (Stitzenberg et al., 2004; Wong et al., 2006). The use of vertical growth phase as a predictor of metastasis may be problematic as it is not reported in many centres and pathologists may not be experienced at distinguishing it from the radial growth phase. A similar problem is encountered when Clark level is used (Owen et al., 2001). Tumour-infiltrating lymphocytes are measured on a scale that is deemed to be subjective, and therefore may give rise to inter-observer variation. Mitotic rate, however, has been shown to be extremely important in melanoma risk assessment (Gimotty et al., 2005; Paek et al., 2007; Sondak et al., 2004) and is planned to be included in the updated American Joint Committee on Cancer Staging system. Ulceration has been associated with a worse prognosis and a higher rate of nodal metastasis, but this is an uncommon finding in thin lesions (McKinnion et al., 2003). A recent study by Faries et al, examining the rate of nodal recurrence in thin melanoma following wide local excision, only identified Breslow thickness, age, and sex as significant indicators of recurrence. Based on these findings, they developed a scoring system and nomogram for the risk of regional nodal metastasis. It has been recommended that this system may be used to reassure low-risk patients, who are anxious about metastasis, or to convince high-risk patients to proceed with a sentinel lymph node biopsy (Faries et al., 2010).

The role of sentinel lymph node biopsy for patients with thick melanomas (> 4 mm) also remains controversial. This specific group of patients have a high risk of nodal metastasis, with some studies showing rates as high as 60% (Balch et al., 2001; Gershenwald et al., 2000). However, as this group of patients are also at high risk of distant metastatic disease the role of either sentinel lymph node biopsy or regional lymph node clearance remain unclear, in terms of providing an improvement in overall survival. Recent studies, have however proposed an improvement in both disease free and overall survival with the presence of a negative sentinel lymph node (Scoggins et al., 2010). They therefore concluded that sentinel lymph node biopsy and complete lymph node dissection for sentinel node positive patients achieves good regional nodal disease control. Sentinel lymph node biopsy in this group of patients may, therefore important for prognosis as well as having therapeutic implications and should at least be considered in these patients (Scoggins et al., 2010).

6. Elective regional lymph node dissection

Complete lymph node dissection is performed with the intention of halting metastatic spread of melanoma in the early stages of the disease (Callery et al., 1982; Roses et al., 1985). Five-year survival rates in patients with negative complete lymph node dissection stands at 62.5%, compared with 20.3% in patients with positive non-sentinel nodes (Kunte et al.,

2009). Therefore, patients undergoing elective lymph node dissection should have improved survival, when compared with patients who are only treated following the appearance of metastases, a point that has been demonstrated in numerous retrospective studies (Balch et al., 1979, 1988; Callery et al., 1982; Milton et al., 1982; Roses et al., 1985). Before the advent of sentinel lymph node biopsy, a complete lymph node dissection was carried out for all patients with malignant melanoma irrespective of lymph node status. However, a number of randomized prospective trials have failed to show overall survival benefit to elective lymph node dissection, and propose that regional lymph nodal metastases represent markers of systemic disease (Balch et al., 1996; Sim et al., 1978; Veronesi et al., 1977, 1982).

It is unclear if an elective lymph node dissection is the appropriate next step in the management of patients with a positive sentinel lymph node biopsy. Currently, a complete lymph node dissection is carried out for all patients with a positive sentinel lymph node, irrespective of the type of metastases (micro-metastasis or macro-metastasis). The value of a complete lymph node dissection in this group of patients has not been extensively investigated (Garbe et al., 2008) and it must constantly be borne in mind that complete lymph node dissection is associated with significant patient morbidity (Guggenheim et al., 2008).

A significant survival benefit has been noted in patients with a positive sentinel lymph node biopsy, who undergo a complete lymph node dissection, when compared with patients undergoing complete lymph node dissection after nodal metastases become apparent (Kretschmer et al., 2004). In a study conducted by Morton et al. (2006), a 5-year survival rate of 72% was seen in patients with positive sentinel lymph nodes, followed by immediate lymph node dissection, whereas patients undergoing a delayed lymph node dissection had a 5-year survival rate of only 52%. However, further positive non-sentinel lymph nodes are found in a relatively small proportion of patients: previously quoted figures ranged from 17%-24% (Ghaferi et al., 2009; Lee et al., 2004; Rossi et al., 2008; Wright et al., 2010). However, a recent study has shown rates of further positive findings to be as low as 14.8% (Kunte et al., 2011).

Ideally, patients at high risk of non-sentinel nodal metastases could be identified and treated by regional lymph node dissection, and patients with a low risk of non-sentinel nodal metastases could be spared from further intervention (Wright et al., 2008). Recently, researchers have sought to identify factors, which increase a patient's likelihood of non-sentinel node metastases. Increasing Breslow depth has been associated with increased risk of non-sentinel node metastases, while a depth of less than 1 mm has no association with any further positive nodes on completion lymph node dissection (Kunte et al., 2011). Studies have failed to show an association between specific tumour and patient characteristics with an increased rate of non-sentinel nodal metastasis (Rossi et al., 2008). However, a number of histopathologic features have been shown to be associated with positive complete lymph node dissections. These include: nodular melanoma, ulceration, melanoma regression, naevus association, and no special tumour characteristics (Kunte et al., 2011). Using a size/ulceration score, Reeves et al. (2003) showed ulceration to be an independent predictor of non-sentinel node deposits.

Recent studies have examined the association between the size of sentinel lymph node deposits and the rate of positive complete lymph node dissection. Kunte et al. (2011) did not report any patients with micro-metastatic deposits on sentinel lymph node biopsy to have positive findings on complete lymph node dissection (Glumac et al., 2008). Another study showed a 3-year survival rate in patients with 1 mm sentinel lymph node metastasis to be

100%, while 3-year survival in patients with deposits greater than 1 mm was 80% (Van der Ploeg et al., 2009). Ollila et al. (2009), however, found a significantly higher rate of recurrence in patients with sub-micrometastatic disease (ie. sentinel lymph node deposits less than 0.1 mm), compared with node-negative patients. Unfortunately the role of complete lymph node dissection in patients with a positive sentinel lymph node biopsy remains unclear and further study is necessary to identify factors which may be incorporated into a model for assessing risk of identifying high risk patients.

7. Conclusion

The incidence of melanoma is rising steadily in the Western world. Increased awareness of the disease has not impacted on its poor prognosis. Surgery remains the mainstay of treatment for this difficult tumour. Indeed there is little in the way of adjuvant systemic therapy that improves overall survival. Adequate surgical margins with or without local reconstructive techniques can improve local recurrence rates. Utilization of the sentinel node biopsy technique allows accurate staging of disease and determination of prognosis. Positive sentinel lymph nodes should be treated with regional lymph node dissection to reduce loco-regional disease. The impact of this on overall survival has not yet been clearly elucidated. The future lies in the continued expansion of the molecular basis of melanoma and the hope of personalised targeted molecular therapies.

8. References

- Agnese, DM; Abdessalam, SF; Burak, WE Jr; Magro, CM; Pozderac, RV & Walker, MJ. (2003). Cost-effectiveness of sentinel lymph node biopsy in thin melanomas. *Surgery*, Vol.134, No. 4, pp. 542-548.
- Al-Hilli, Z; Khan, W; Hill, A. D. K. (2007). Isolated limb infusion for melanoma. *Surgeon*, Vol. 5, No. 5, pp. 310-2.
- American Cancer Society. (1990). 1989 survey of physicians' attitudes and practices in early cancer detection. *CA*, Vol. 40, pp. 77-101.
- Austin, JR; Byers, RM; Brown, WD; Wolf, P. (1996). Influence of biopsy on the prognosis of cutaneous melanoma of the head and neck. *Head Neck*, Vol. 18, pp. 107-117.
- Bagaria, SP; Faries. MB; Morton. DL. (2010). Sentinel Node Biopsy in Melanoma: Technical Considerations of the Procedure as Performed at the John Wayne Cancer Institute. *J. Surg. Oncol.*, Vol. 101, pp. 669-676.
- Balch, CM; Buzaid, AC; Soong, SJ; Atkins, MB ; Cascinelli, N; Coit, DG. et al. (2001). Final version of the American Joint Committee on Cancer staging system for cutaneous melanoma. *J Clin Oncol*, Vol. 19, pp 3635-3648.
- Balch, CM; Gershenwald, JE; Soong, SJ. et al. (1996). Final Version of 2009 AJCC melanoma staging and classification. *J Clin Oncol*, Vol. 27, No. 36, pp. 6199-206.
- Balch, CM; Soong, S-J; Bartolucci, AA. et al. (1996). Efficacy of an elective regional lymph node dissection of 1 to 4 mm thick melanomas for patients 60 years of age and younger. *Ann Surg*, Vol. 224, pp. 255-66.
- Balch, CM; Soong. SJ; Gershenwald. JE. et al. (2001). Prognostic factors analysis of 17,600 melanoma patients: validation of the American Joint Committee on Cancer melanoma staging system. *J Clin Oncol*, Vol. 19, pp. 3622-34.

- Balch, CM; Soong, SJ; Murad, TM; Ingalls, AL; Maddox, WA. (1979). A multifactorial analysis of melanoma. II. Prognostic factors in patients with stage I (localized) melanoma. *Surgery*, Vol.86, pp. 343-51.
- Balch, CM. (1988). The role of elective lymph node dissection in melanoma: rationale, results, and controversies. *J Clin Oncol*, Vol. 6, pp. 163-72.
- Bedrosian, I; Faries, MB; Guerry, DT. IV. et al. (2000). Incidence of sentinel node metastasis in patients with thin primary melanoma (<1 mm) with vertical growth phase. *Ann Surg Oncol.*, Vol. 7, No. 4, pp.262-267.
- Bleicher, RJ; Essner, R; Foshag, LJ; Wanek, LA; Morton, DL. (2003). Role of sentinel lymphadenectomy in thin invasive cutaneous melanomas. *J Clin Oncol*, Vol. 21, No. 7, pp. 1326-1331.
- Boring, CC; Squires, TS; Tong, T; Montgomery, S. (1994). Cancer Statistics 1994. *CA Cancer J Clin*, Vol. 44, No. 7.
- Brady, MS; Brown, K; Patel, A; Fisher, C; Marx, A. (2006). Phase II trial of isolated limb infusion with melphalan and dactinomycin for regional melanoma and soft tissue sarcoma of the extremity. *Ann Surg Onc*, Vol. 13, No. 8, pp. 1123-9.
- Breslow, A. (1980). Prognosis in cutaneous melanoma: tumor thickness as a guide to treatment. *Pathol Annu*, Vol. 15, pp. 1-22.
- Briele, HA; Djuric, M; Jung, DT; Mortell, T; Patel, MK; Das Gupta, TK. (1985). Pharmacokinetics of melphalan in clinical isolation perfusion of the extremities. *Cancer Res*, Vol. 45, pp. 1885-1889.
- Brozena, SJ; Fenske, NA; Perez, IR. (1993). Epidemiology of malignant melanoma, worldwide incidence, and etiologic factors. *Semin Surg Oncol*, Vol. 9, pp. 165-7.
- Cade, S. (1961). Malignant melanoma. *Ann R Coll Surg Engl*, Vol. 28, pp. 331-366.
- Callery, C; Cochran, AJ; Roe, DJ. et al. (1982). Factors prognostic for survival in patients with malignant melanoma spread to regional lymph nodes. *Ann Surg*, Vol. 196, pp. 69-75.
- Cascinelli, N; Marchesini. R. (1989). Increasing incidence of cutaneous melanoma, ultraviolet radiation and the clinician. *Photochem Photobiol*, Vol. 50, pp. 497-505.
- Cecchi, R; Buralli, L; Innocenti, S; De Gaudio, C. (2007). Sentinel lymph node biopsy in patients with thin melanomas. *J Dermatol*, Vol. 34, No. 8, pp. 512-515.
- Clinical Guidelines Committee. (2006). Management of Cutaneous Melanoma Clinical Guidelines. *Dublin: Royal College of Surgeons in Ireland*.
- Cohn-Cedarmark, G ; Rutqvist, LE ; Anderson, R. et al. (2000). Long-term results of a randomised study by the Swedish Melanoma Study Group on 2-cm versus 5-cm resection margins for patients with cutaneous melanoma with a tumour thickness of 0.8-2.0 mm. *Cancer*, Vol. 89, pp. 1495-1501.
- Conway, WC; Faries, MB; Terando, AM. et al. (2009). Age-related lymphatic dysfunction in malignant melanoma patients. *Ann Surg Oncol*, Vol. 16, pp. 1548-1552.
- Creech, O; Krentz, E. (1966). Techniques of regional perfusion. *Surgery*, Vol. 60, pp. 938-947.
- Evans, RD; Kopf, AW; Lew, RA .et al. (1988). Risk factors for the development of malignant melanoma: I. Review of case-control studies. *J Dermatol Surg Oncol*, Vol. 14, pp. 393-408.

- Faries, MB; Wanek, LA; Elashoff, D; Wright, BE; Morton, DL. Predictors of Occult Nodal Metastasis in Patients With Thin Melanoma. (2010). *Arch Surg*, Vol. 145, No.2, pp. 137-142.
- Fraker, DL. (1999). Hyperthermic regional perfusion for melanoma and sarcoma of the limbs. *Curr Probl Surg*, Vol. 36, pp. 841-907.
- Friedman, RJ; Rigel, DS; Silverman, MK; Kopf, AW; Vossaert, KA . (1991). Malignant melanoma in the 1990s: the continued importance of early detection and the role of physician examination and self-examination of the skin. *CA Cancer J Clin*, Vol. 41, pp. 201-6.
- Gandini, S; Sera, F; Cattaruzza, MS; Pasquini, P; Picconi, O; Boyle, P; Melchi, CF. Meta-analysis of risk factors for cutaneous melanoma : II. Sun exposure. *Eur J Cancer*, Vol. 41, pp. 45-60.
- Garbe, C; Hauschild, A; Volkenandt, M; Schadendorf, D; Stolz, W; Reinhold, U. et al. (2008). Evidence and interdisciplinary consensusbased German guidelines: surgical treatment and radiotherapy of melanoma. *Melanoma Res*, Vol. 18, pp. 61-7.
- Gellin, GA; Kopf, AW; Garfinkel, L. (1969). Malignant melanoma: A controlled study of possibly associated factors. *Arch Derm*, Vol. 99, pp. 43-48.
- Gershenwald, JE; Mansfield, PF; Lee, JE; Ross, MI. (2000). Role of lymphatic mapping and sentinel lymph node biopsy in patients with thick (≥ 4 mm) primary melanoma. *Ann Surg Oncol*, Vol. 7, No. 2, pp. 160-165.
- Gershenwald, JE; Thompson, W; Mansfield, PF. et al. (1999). Multi-institutional melanoma lymphatic mapping experience: the prognostic value of sentinel lymph node status in 612 stage I or II melanoma patients. *J Clin Oncol*. Vol. 17, No. 3, pp. 976-983.
- Ghaferi, AA; Wong, SL; Johnson, TM; Lowe, L; Chang, AE; Cimmino, VM. et al. (2009). Prognostic significance of a positive nonsentinel lymph node in cutaneous melanoma. *Ann Surg Oncol*, Vol. 16, pp. 2978-84.
- Gimotty, PA; Guerry, D; Ming, ME. et al. (2004). Thin primary cutaneous malignant melanoma: a prognostic tree for 10-year metastasis is more accurate than American Joint Committee on Cancer staging. *J Clin Oncol*, Vol. 22, No. 18, pp. 3668-3676.
- Gimotty, PA; Van Belle, P; Elder, DE. et al. (2005). Biologic and prognostic significance of dermal Ki67 expression, mitoses, and tumorigenicity in thin invasive cutaneous melanoma. *J Clin Oncol*, Vol. 23, No. 31, pp. 8048-8056.
- Glumac, N; Hocevar, M; Zadnik, V; Snoj, M. (2008). Sentinel lymph node micrometastasis may predict non-sentinel involvement in cutaneous melanoma patients. *J Surg Oncol*, Vol. 98, pp. 46-8.
- Greene, MH; Clark, WH; Tucker, MA. et al. (1985). High risk of malignant melanoma in melanoma-prone families with dysplastic naevi. *Ann Intern Med*, Vol. 102, pp. 458-465.
- Guggenheim, MM; Hug, U; Jung, FJ; Rousson, V; Aust, MC; Calcagni, M; Künzi, W; Giovanoli, P. (2008). Morbidity and recurrence after completion lymph node dissection following sentinel lymph node biopsy in cutaneous malignant melanoma. *Ann Surg*, Vol. 247, pp. 687-93.
- Haigh, PI; DiFronzo, LA; McCready, DR. (2003). Optimal excision margins for primary cutaneous melanoma: a systematic review and meta-analysis. *Can J Surg*, Vol. 46, pp. 419-426.


- Hayes, AJ; Clarke, MA; Harries, M; Thomas, JM. (2004). Management of in-transit metastases from cutaneous malignant melanoma. *Br J Surg*, Vol. 91, pp. 673-682.
- Heenan, PJ; Ghaznawie, M. (1999). The pathogenesis of local recurrence of melanoma at the primary excision site. *Br J Plast Surg*, Vol.52, pp. 209-213.
- Holman, CD; Armstrong, BK. (1984). Cutaneous melanoma and indicators of total accumulated exposure to the sun: An analysis separating histogenetic types. *J Natl Cancer Inst*, Vol. 73, pp. 75-82.
- Jemal, A; Devesa, SS; Hartge, P; Tucker, MA. (2001). Recent trends in cutaneous melanoma incidence among whites in the United States. *J Natl Cancer Inst*, Vol. 93, No. 9, pp. 678-683.
- Kesmodel, SB; Karakousis, GC; Botbyl, JD. et al. (2005). Mitotic rate as a predictor of sentinel lymph node positivity in patients with thin melanomas. *Ann Surg Oncol*, Vol. 12, No. 6, pp. 449-458.
- Kopf, AW. (1988). Prevention and early detection of skin cancer/melanoma. *Cancer*, Vol. 62, No. 8, pp. 1791-1795.
- Kraemer KH: Xeroderma Pigmentosum, in Dermis DJ, McGuire J (eds). (1984). *Clinical Dermatology*, vol 4, Philadelphia, Harper & Row Publishers, unit 19-7.
- Kretschmer, L; Hilgers, R; Mohrle, M; Balda, BR; Breuninger, H; Konz ,B. et al. (2004). Patients with lymphatic metastasis of cutaneous malignant melanoma benefit from sentinel lymphonodectomy and early excision of their nodal disease. *Eur J Cancer*, Vol. 40, pp. 212-8.
- Kunte, C; Geimer, T; Baumert, J; Konz, B; Volkenandt, M; Flaig, M; Ruzicka, T; Berking, C; Schmid-Wendtner, MH. (2011). Analysis of predictive factors for the outcome of complete lymph node dissection in melanoma patients with metastatic sentinel lymph nodes. *J Am Acad Dermatol.*, Vol. 64, No. 4, pp. 655-62.
- Lederman, JS; Sober, AJ. (1985). Does biopsy type influence survival in clinical stage I cutaneous melanoma? *J Am Acad Dermatol*, Vol. 13, pp. 983-987.
- Lee, JH; Essner, R; Torisu-Itakura, H; Wanek, L; Wang, H; Morton, DL. (2004). Factors predictive of tumor-positive nonsentinel lymph nodes after tumor-positive sentinel lymph node dissection for melanoma. *J Clin Oncol*, Vol. 22, pp. 3677-84.
- Lees, VC; Briggs, JC. (1991). Effect of initial biopsy procedure on prognosis in Stage 1 invasive cutaneous malignant melanoma: review of 1086 patients. *Br J Surg*, Vol. 78, pp. 1108-1110.
- Lent, WM ; Ariyan, S. (1994). Flap reconstruction following wide local excision for primary malignant melanoma of the head and neck region. *Ann Plast Surg*, Vol. 33, No. 1, pp. 23-7.
- Lienard, D; Ewalenko, P; Delmotte, JJ; Renard, N; Lejeune, FJ. (1992). High-dose recombinant tumor necrosis factor alpha in combination with interferon gamma and melphalan in isolation perfusion of the limbs for melanoma and sarcoma. *J Clin Oncol*, Vol. 10, pp: 52-60.
- Malignant tumors (melanomas and related lesions). In: Elder DE, Murphy GF. Melanocytic tumors of the skin. Atlas of tumor pathology. 3rd series. Fascicle 2. Washington, D.C.: Armed Forces Institute of Pathology, pp. 103-205.
- McCarthy, WH. (2002). Melanoma: Margins for error – another view. *Aust NZ J Surg*, Vol. 72, pp. 304-306.

- McKinnon, JG; Yu, XQ; McCarthy, WH; Thompson, JF. (2003). Prognosis for patients with thin cutaneous melanoma: long-term survival data from New South Wales Central Cancer Registry and the Sydney Melanoma Unit. *Cancer*, Vol. 98, No.6 , pp. 1223-1231.
- Mian, R; Henderson, M; Speakman, D; Finkelde, D; Ainslie, J; McKenzie, A. (2001). Isolated limb infusion for melanoma: a simple alternative to isolated limb perfusion. *Can J Surg*, Vol. 44, No. 3, pp. 189-92
- Milton, GW; Shaw, HM; McCarthy, WH. et al. (1982). Prophylactic lymph node dissection in clinical stage I cutaneous malignant melanoma: results of surgical treatment in 1319 patients. *Br J Surg*, Vol. 69, pp. 108-11.
- Morton ,DL; Thompson , JF; Cochran, AJ; Mozzillo, N; Elashoff, R; Essner, R. et al. (2006). Sentinel-node biopsy or nodal observation in melanoma. *N Engl J Med*, Vol. 355, pp. 1307-17.
- Mubarak, SJ; Owen, CA. (1977). Double-incision fasciotomy of the leg for decompression in compartment syndromes. *J Bone Joint Surg (US)*, Vol. 59A, pp. 184-187.
- No authors listed. (1983). Randomized controlled trial of adjuvant chemoimmunotherapy with DTIC and BCG after complete excision of primary melanoma with a poor prognosis or melanoma metastases. *Can Med Assoc J.*, Vol. 128, No. 8, pp. 929-33.
- Oliveira Filho, RS; Ferreira, LM; Bias, LJ; Enokihara, MM; Paiva, GR; Wagner ,J. (2003). Vertical growth phase and positive sentinel node in thin melanoma. *Braz J Med Biol Res*, Vol. 36, No. 3, pp. 347-350.
- Ollila ,DW; Ashburn, JH; Amos, KD; Yeh, JJ; Frank, JS; Deal, AM. et al. (2009). Metastatic melanoma cells in the sentinel node cannot be ignored. *J Am Coll Surg*, Vol. 208, pp. 924-9.
- Owen, SA; Sanders, LL; Edwards, LJ; Seigler, HF; Tyler, DS; Grichnik, JM. (2001). Identification of higher risk thin melanomas should be based on Breslow depth not Clark level IV. *Cancer*, Vol. 91, No.5, pp. 983-991.
- Paek, SC; Griffith, KA; Johnson, TM. et al. (2007). The impact of factors beyond Breslow depth on predicting sentinel lymph node positivity in melanoma. *Cancer*, Vol. 109, No. 1, pp. 100-108.
- Parker, SL; Tong, T; Bolden, S; Wingo, PA. (1996). Cancer statistics, 1996. *CA Cancer J Clin*, Vol. 47, pp. 5-27.
- Prichard, RS; Hill, ADK; Skehan, SJ; O'Higgins, NJ. (2002). Positron emission tomography for staging and management of malignant melanoma. *Br J Surg*, Vol. 89, pp. 389-396.
- Puleo, CA; Messina, JL; Riker ,AI. et al. (2005). Sentinel node biopsy for thin melanomas: which patients should be considered? *Cancer Control*, Vol. 12, No. 4, pp. 230-235.
- Reeves, ME; Delgado, R; Busam, KJ; Brady, MS; Coit, DG. (2003). Prediction of nonsentinel lymph node status in melanoma. *Ann Surg Oncol*, 2003, Vol. 10, pp. 27-31.
- Roberts, DL; Anstey, AV; Barlow, RJ. et al. (2002). U.K. guidelines for the management of cutaneous melanoma. *Br J Dermatol*, Vol. 146, pp. 7-17.
- Roses, DF; Provet , JA; Harris, MN; Gumport, SL; Dubin, N. (1985). Prognosis of patients with pathologic stage II cutaneous malignant melanoma. *Ann Surg*, Vol. 201, pp. 103-7.
- Rossi, CR; De Salvo, GL; Bonandini, E; Mocellin, S; Foletto, M; Pasquali, S. et al. (2008). Factors predictive of nonsentinel lymph node involvement and clinical outcome in

- melanoma patients with metastatic sentinel lymph node. *Ann Surg Oncol*, Vol. 15, pp. 1202-10.
- Schumacher, HH; Chia, HL. et al. (2010). Ipsilateral Skin Grafts for Lower Limb Melanoma Reconstruction Are Safe. *Plastic and Reconstructive Surgery*, Vol. 125, No. 2, pp. 89e-91e.
- Scoggins, CR; Bowen, AL; Martin, RC; Edwards, MJ; Reintgen, DS; Ross, MI; Urist, MM; Stromberg, AJ; Hagendoorn, L; McMasters, K. (2010). Prognostic Information From Sentinel Lymph Node Biopsy in Patients With Thick Melanoma. *Arch Surg*, Vol. 145, No. 7, pp. 622-627.
- Sim, FH; Taylor, WF; Ivins, JC; Pritchard, DJ; Soule, EH. (1978). A prospective randomized study of the efficacy of routine elective lymphadenectomy in management of malignant melanoma: preliminary results. *Cancer*, Vol. 41, pp. 948-56.
- Sondak, VK; Taylor, JM; Sabel, MS. et al. (2004). Mitotic rate and younger age are predictors of sentinel lymph node positivity: lessons learned from the generation of a probabilistic model. *Ann Surg Oncol*, Vol. 11, No. 3, pp. 247-258.
- Stitzenberg, KB; Groben, PA; Stern, SL. et al. (2004). Indications for lymphatic mapping and sentinel lymphadenectomy in patients with thin melanoma (Breslow-thickness ≤ 1.0 mm). *Ann Surg Oncol*, Vol. 11, No. 10, pp. 900-906.
- The American Cancer Society. (2010). What are the key statistics about Melanoma?, In : *The American Cancer Society*, 20.03.10, Available from <http://www.cancer.org/Cancer/SkinCancer-Melanoma/DetailedGuide/melanoma-skin-cancer-key-statistics>
- Thomas, JM ; Newton-Bishop, J ; A'Hern, R. et al. (2004). Excision margins in high-risk malignant melanoma. *New Engl J Med*, Vol. 350, pp. 757-766.
- Thompson, JF. (2001). The Sydney Melanoma Unit experience of sentinel lymphadenectomy for melanoma. *Ann Surg Oncol*, Vol. 8, pp. 445-475.
- Uren, RF; Howman-Giles, R; Thompson, JF. et al. (1994). Lymphoscintigraphy to identify sentinel lymph nodes in patients with melanoma. *Melanoma Res*, Vol. 4, pp. 395-9.
- Van der Ploeg, IM; Kroon, BB; Antonini, N; Valdes Olmos, RA; Nieweg, OE. (2009). Is completion lymph node dissection needed in case of minimal melanoma metastasis in the sentinel node? *Ann Surg*, Vol. 249, pp. 1003-7.
- Vaquerano, J; Kraybill, WG; Driscoll, DL; Cheney, R; Kane, JM III. (2006). American Joint Committee on Cancer clinical stage as a selection criterion for sentinel lymph node biopsy in thin melanoma. *Ann Surg Oncol*, Vol. 13, No. 2, pp. 198-204.
- Veronesi, U; Adamus, J; Bandiera, DC. et al. (1977). Inefficacy of immediate node dissection in stage I melanoma of the limbs. *New Engl J Med*, Vol. 297, pp. 627-630.
- Veronesi, U; Adamus, J; Bandiera, DC. et al. (1982). Delayed regional lymph node dissection in stage I melanoma of the skin of the lower extremities. *Cancer*, Vol. 49, pp. 2420-30.
- Whited, JD; Grichnik, JM. (1998) The rational clinical examination. Does the patient have a mole of a melanoma? *JAMA*, Vol. 279, pp. 696-701.
- Wieberdink, J; Benckhuysen, C; Braat, RP; van Slooten, EA; Olthuis, GA. (1982). Dosimetry in isolation perfusion of the limbs by assessment of perfused tissue volume and grading of toxic tissue reactions. *Eur J Cancer Clin Oncol*, Vol. 18, pp. 905-910.
- Wong, SL; Brady, MS; Busam, KJ; Coit, DG. (2006). Results of sentinel lymph node biopsy in patients with thin melanoma. *Ann Surg Oncol*, Vol. 13, No. 3, pp. 302-309.

- Wright, BE; Scheri, RP; Ye, X. et al. (2008). Importance of sentinel lymph node biopsy in patients with thin melanoma. *Arch Surg*, Vol. 143, No. 9, pp. 892-900.
- Wright, EH; Stanley, PR; Roy, A. (2010). Evaluation of sentinel lymph nodes positive for melanoma for features predictive of nonsentinel nodal disease and patient prognosis: a 49 patient series. *J Plast Reconstr Aesthet Surg*, Vol. 68, pp. 500-2.
- Yonick, DV; Ballo, RM; Kahn, E; Dahiya, M; Yao, K; Godellas, C; Shoup, M; Aranha, GV. (2011). Predictors of positive sentinel lymph node in thin melanoma. *Am J Surg*, Vol. 201, No. 3, pp. 324-8.

IntechOpen



Current Management of Malignant Melanoma

Edited by Dr. Ming Yu Cao

ISBN 978-953-307-264-7

Hard cover, 274 pages

Publisher InTech

Published online 22, September, 2011

Published in print edition September, 2011

Management of melanoma is challenging, especially for the late stage of the disease. Development of new therapies and optimizing current treatments are being pursued in attempt to further improve the survival rate. The book provides up-to-date knowledge and experience in early diagnosis, prevention and treatment of melanoma as well as current ongoing clinical studies on melanoma. The book also provides the most recent perspectives of research on the molecular basis of melanoma, such as melanoma associated genes and a possible link between stress and melanoma.

How to reference

In order to correctly reference this scholarly work, feel free to copy and paste the following:

Joyce DP, Prichard RS and Hill ADK (2011). Current Controversies in the Surgical Management of Melanoma, Current Management of Malignant Melanoma, Dr. Ming Yu Cao (Ed.), ISBN: 978-953-307-264-7, InTech, Available from: <http://www.intechopen.com/books/current-management-of-malignant-melanoma/current-controversies-in-the-surgical-management-of-melanoma>

INTECH
open science | open minds

InTech Europe

University Campus STeP Ri
Slavka Krautzeka 83/A
51000 Rijeka, Croatia
Phone: +385 (51) 770 447
Fax: +385 (51) 686 166
www.intechopen.com

InTech China

Unit 405, Office Block, Hotel Equatorial Shanghai
No.65, Yan An Road (West), Shanghai, 200040, China
中国上海市延安西路65号上海国际贵都大饭店办公楼405单元
Phone: +86-21-62489820
Fax: +86-21-62489821

© 2011 The Author(s). Licensee IntechOpen. This chapter is distributed under the terms of the [Creative Commons Attribution-NonCommercial-ShareAlike-3.0 License](#), which permits use, distribution and reproduction for non-commercial purposes, provided the original is properly cited and derivative works building on this content are distributed under the same license.

IntechOpen

IntechOpen