

We are IntechOpen, the world's leading publisher of Open Access books Built by scientists, for scientists

3,500

Open access books available

108,000

International authors and editors

1.7 M

Downloads

Our authors are among the

151

Countries delivered to

TOP 1%

most cited scientists

12.2%

Contributors from top 500 universities



WEB OF SCIENCE™

Selection of our books indexed in the Book Citation Index
in Web of Science™ Core Collection (BKCI)

Interested in publishing with us?
Contact book.department@intechopen.com

Numbers displayed above are based on latest data collected.
For more information visit www.intechopen.com



Image Fusion for Computer-Assisted Tumor Surgery (CATS)

KC Wong, SM Kumta, LF Tse, EWK Ng¹ and KS Lee¹
Orthopaedic Oncology,

*¹CAOS team, Department of Orthopaedics and Traumatology, Prince of Wales Hospital,
the Chinese University of Hong Kong,
Hong Kong
China*

1. Introduction

Tumor surgeons integrate preoperative two-dimensional images and mentally formulate three-dimensional surgical plans of resection and reconstruction. The surgical procedure aims to remove tumors with clear surgical margins, while critical anatomical structures not infiltrated by tumor can be preserved. This will be particularly difficult in complex areas such as pelvis, sacrum, or when joint-saving intercalated resection is contemplated, or when custom-made prosthesis is used for reconstruction. Incorporating computer technology to aid in this surgical planning and executing the intended resection may improve precision and consequently clinical results in musculoskeletal tumor surgery.

Although primarily developed for neurosurgical applications, computer-assisted intraoperative navigation has gained acceptance and has been used effectively in orthopaedic trauma, spinal procedures and joint replacement surgery (Anderson KC et al., 2005; Gebhard F et al., 2004; Grutzner PA et al., 2004; Laine T et al., 2000; Wixson RL et al., 2005). An extended application of computer navigation assisted resection in pelvic and sacral tumors was first described in 2004 (Hüfner T et al., 2004; Krettek C et al., 2004). Computer-assisted navigation system could facilitate tumors resection and also reconstruction with custom prostheses (Cho HS et al., 2008; Cho HS et al., 2009; Kim JH et al., 2010; Reijnders K et al., 2007; Wong KC et al., 2007; Wong KC et al., 2007; Wong KC et al., 2008), joint sparing limb salvage surgery (Cho HS et al., 2009; Wong KC et al., 2007; Wong KC et al., 2008). The technique of fusing computed tomography (CT) and magnetic resonance images (MRI) was reported. The fusion image, when combined with surgical navigation, helps surgeons reproduce a preoperative plan reliably and may offer substantial clinical benefits in musculoskeletal tumor surgery (Wong KC et al., 2008). The current study represents the continuation of previous publications (Wong KC et al., 2007; Wong KC et al., 2008), which were preliminary reports of the techniques. The number of cases has increased from 13 to 22, and the average follow-up of all patients increased from 9.5 months to 32.5 months. This article is to provide more patients with longer follow-up to better assess the advantages and potential pitfalls of using the technique in musculoskeletal oncology.

Surgeons had not yet incorporated this computer technology into their routine musculoskeletal bone tumors operation. We therefore investigate the results of image fusion

for Computer-Assisted Tumor Surgery (CATS) in musculoskeletal oncology with the help of a navigation system.

2. Methods

We studied 21 patients with 22 musculoskeletal tumors who underwent CATS from March 2006 to July 2009. (Table 1) A commercially available CT-based spine navigation system (Stryker Navigation, Freiburg, Germany; CT spine, version 1.6) was used. Indications for the technique included anticipated difficulties in achieving an accurate tumor resection in affected bone with complex anatomy (pelvis, sacrum) or the need for precision in making a satisfactory resection plane to accommodate a custom tumor prosthesis. Of the 21 patients, 10 were males, 11 were females, and the mean age was 32 years at the time of surgery (range, 6 - 80 years). Five tumors were located in the pelvis, seven sacrum, eight femur, and two tibia. The primary diagnosis was primary bone tumors in 16 (4 benign, 16 sarcoma) and metastatic tumors in two. The minimum follow-up was 14 months (average, 32.5 months; range, 14 - 49 months). No patient was excluded or lost follow-up in this series.

Preoperative CT and MRI examination of each patient were performed. Axial CT slices of 0.0625mm or 1.25mm thickness and various sequences of MR images in Digital Imaging and Communications in Medicine (DICOM) format were obtained. The imported image data sets were then reformatted into axial, coronal and sagittal views in the navigation system. CT and MR images for 22 cases were fused using the navigation software (Fig.1). Navigation system (Stryker Navigation, Freiberg, Germany, CT spine, version 1.6) was used for first eight patients while (Stryker Navigation; iNtellect Cranial, version 1.1) for the rest. PET images were also incorporated into the CT-MR fused images for two patients who had local recurrence following previous surgery and radiotherapy. The process of fusing multimodal image datasets had been described (Wong KC et al., 2008). A three-dimensional (3-D) bone model was created by adjusting the contrast level of the CT images. Tumor extent was defined and its volume was extracted from MR images. As different image datasets shared identical spatial coordinates after image fusion, segmented MR tumor volume was integrated into the CT reconstructed 3-D bone model. A 3-D bone tumor model was generated. All the reconstructed two-dimensional (2-D) and 3-D images were used for preoperative surgical planning. The plane of tumor resection was defined and marked using multiple virtual screws sited along the margin of the planned resection. We also integrated the computer-aided design (CAD) data of custom-made prostheses provided by the manufacturer (Stanmore Implants Worldwide Ltd, Middlesex, United Kingdom) in the final navigation resection planning for eight cases (Fig.1).

Preoperative tumor resection and prosthetic reconstruction was virtually simulated in two patients in the later part of the study by using a commercially CAD software, MIMICS® (Materialise's Interactive Medical Image Control System, Materialise, Ann Arbor, MI) that converts DICOM data into a proprietary format. The surgical plan of tumor resection and CAD prosthesis reconstruction in MIMICS format were back converted to CT data sets in DICOM format. Both original CT data sets and virtual surgical planning CT data sets were fused in the navigation software. The data sets of the fused images were then imported back into a CT-based navigation system (Stryker Navigation, Freiberg, Germany; CT spine, version 1.6) for resection planning. The navigation system was toggled to display the CT data sets with virtual surgical plans. Virtual markers (pedicle screws in CT spine navigation software) were then placed along the plane and orientation of planned tumor resection.

Case	1	2	3	4
Age (yrs)	46	42	24	53
Sex	F	F	F	F
Diagnosis	Parosteal osteosarcoma	Metastatic uterine carcinoma	Undifferentiated bone sarcoma	Schwannoma
Location	Left proximal tibia (posterior aspect)	Left ischial tuberosity	Right proximal femur	Right S2 nerve root
Surgery	Joint-saving resection	Local resection	Local resection after neoadjuvant chemotherapy	Marginal excision via posterior approach
Bone reconstruction	Vascularized fibular graft	No	Modular tumor prosthesis	No
Preoperative fusion image datasets	CT angiogram and MRI	CT and MRI	CT and MRI	CT and MRI
Navigation Planning time* (hours)	3	1.5	2.5	1.5
Registration error (mm)	0.44	0.37	0.36	0.38
Navigation time (minutes)	40	13	18	15
Function (MSTS score ⁺)	28	--	29	--
Followup (months)	49	49	48	44
Complications and Outcome	--	--	--	--

8	7	6	5
54	6	80	14
M	M	F	M
Giant cell tumor	Conventional osteosarcoma	Chordoma	Conventional osteosarcoma
Sacrum (from S1 to S4)	Right distal femur	Sacrum (below and including S2)	Right femur (from subtrochanteric region to distal physis)
Intralesional curettage	Joint saving resection after neoadjuvant chemotherapy	Resection	Joint-saving resection after neoadjuvant chemotherapy
No	Custom extendable tumor prosthesis	No	Custom tumor prosthesis
CT angiogram and MRI	CT and MRI	CT and MRI	+ CT and MRI
2.2	2.5	2.2	3.8
0.45	0.41	0.61	0.50
25	20	35	30
--	26	--	30
37	38	42	43
Local recurrence 26 months post surgery and stabilized with bisphosphonates	Died of distant metastases 5 months post surgery	superficial wound infection	--

9	8	11
M	M	M
Conventional osteosarcoma	Recurrent chordoma	Conventional osteosarcoma
Left distal femur	Left pelvic metastases	Sacrum (from S1 to S5)
Joint saving resection after neoadjuvant chemotherapy	Resection (PII)	Total sacrectomy
Custom extendable tumor prosthesis	Custom pelvic prosthesis	No
CT and MRI	CT angiogram, MRI and PET	CT and MRI
1.2	1.8	1.1
0.35	0.46	0.59
15	15	15
30	23	--
36	35	35
--	Developed soft tissue local recurrence 1 year after surgery	Postoperative wound infection Died of distant metastases 6 months after surgery

12	13	14
54	17	21
F	M	F
Recurrent chondrosarcoma	Recurrent malignant nerve sheath tumor	Low grade chondrosarcoma
Sacrum (from S1 to S5)	Left sciatic nerve and involving ilium and sacrum	Left proximal femur
Total sacrectomy	Left hemipelvectomy (PIV resection)	Joint saving resection
No	No	Custom tumor prosthesis
CT angiogram and MRI	CT angiogram, MRI and PET	CT and MRI
1.2	1.8	2
0.68	0.44	0.42
25	30	50
--	--	28
35	33	32
Died of distant metastases 1 year after surgery	Developed soft tissue local recurrence 5 months after surgery and died of distant metastases 11 months post surgery	--

15	16	F	Conventional osteosarcoma	Right ischium and acetabulum	PII + PIII resection	Custom pelvic prosthesis	CT and MRI	1.5	0.31	30	30	30	--
16	24	M	Parosteal osteosarcoma	Left distal femur	Joint saving resection	Custom tumor prosthesis	CT and MRI	3	0.34	60	28	26	--
17	41	F	Hemangioendothelioma	Right ilium	Resection	No	CT and MRI	1	0.59	45	--	24	--
18	55	M	Sacral chordoma	S1 and below	Total sacrectomy	Posterior instrumentation	CT and MRI	1	0.5	30	--	18	Local recurrence and distal metastases 12 months post surgery

19	42	M	Sacral chordoma	S3 and S4	Partial sacrectomy	No	CT, MRI and PET	1.5	0.49	45	--	17	--
20	6	M	Conventional osteosarcoma	Right distal femur	Joint saving resection after neoadjuvant chemotherapy	Custom extendable tumor prosthesis	CT and MRI	2	0.8	25	30	16	--
21	16	F	Low grade chondrosarcoma	Left proximal humerus	Joint saving resection	Bone graft	CT and MRI	1	0.54mm	25	30	15	--
22	18	F	Chondromyxoid fibroma	Right proximal tibia	Multi-planar resection	Bone graft	CT and MRI	1.5	0.4	45	28	14	--

Table 1. Demographic data for 22 cases in 21 patients. *Navigation planning time included time required for performing image fusion, creating 3-D bone tumor models and planning of intended resection; +MSTS = Musculoskeletal Tumor Society score. The score was obtained at the end of study period. For those patients who died during the study period, we took the maximum score that the patients could achieve following their operations

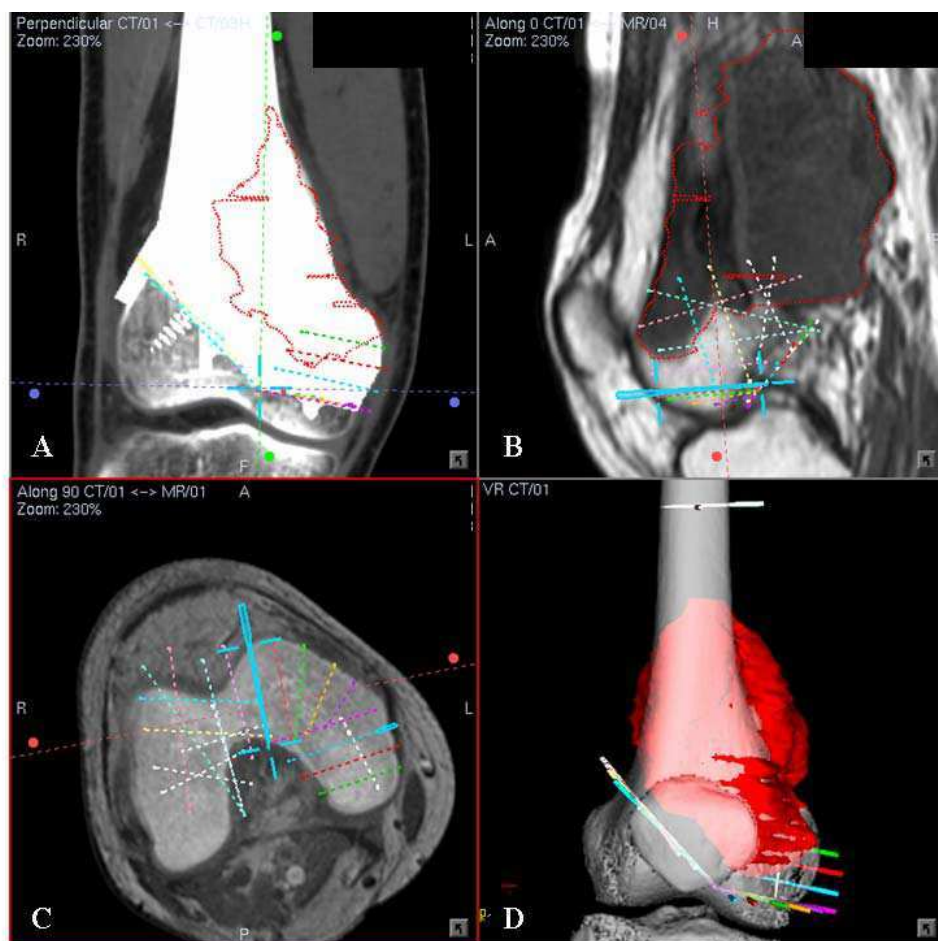


Fig. 1. (A) A coronal section of the CT images with incorporation of CAD prosthesis for Patient 16 with right distal femur parosteal osteosarcoma is shown. Conversion of CAD data of custom prosthesis to DICOM format was made possible using CAD software (MIMICS® - Materialise's Interactive Medical Image Control System). This allowed direct use of CAD data for navigation planning of tumor resection. The central cross represented the virtual marker (pedicle screw in the CT spine navigation software) that marked one of the locations of intended bone resection. (B) A sagittal section of the MR images showed the extent of the tumor. (C) A axial section of CT / MR image fusion at the intended resection of distal femur is shown. (D) A 3-D bone tumor model reconstructed from CT and MR image data sets is shown. The tumor volume was red in color. By analyzing the 2-D CT / MR fused images and 3-D model, a joint-saving resection with multiplanar osteotomies were planned at distal femur and intended bone resections were marked with virtual screws. The more precise the bone resection was, the greater number of virtual screws was needed to define the plane of resection

At the actual surgery, a dynamic reference tracker was attached to the bone in which the tumor was located. An image-to-patient registration to match precisely the operative anatomy and preoperative virtual CT images was performed by paired points and surface points matching. The navigation software calculated the registration errors which indicated any mismatch between preoperative CT images and the patient's anatomy (Fig.2). We next calibrated the navigation probe and operative instruments (drill, bone burr or diathermy)

mounted with navigation trackers to the navigation system. This allowed the real-time tracking the spatial location of the tip of these instruments in relation to the patient's anatomy on the virtual preoperative images (Fig.3). The anatomic locations of virtual pedicle screws were identified and intended resection level and plane was marked using navigated tools. An oscillating saw or osteotome was used to make the osteotomy and the tumor was removed en-bloc. Skeletal defects were reconstructed using custom-made pelvic prostheses in two cases, custom-made joint-saving intercalated prostheses in six, modular proximal femur prosthesis in one, and a vascularized fibular graft in one. No reconstruction was required for twelve cases. Postoperative CT images for Patients 10, 14 and 15 were obtained and the achieved positions of custom prostheses were merged with their preoperative navigation plans. The workflow for the technique of CATS was summarized in Figure 4.

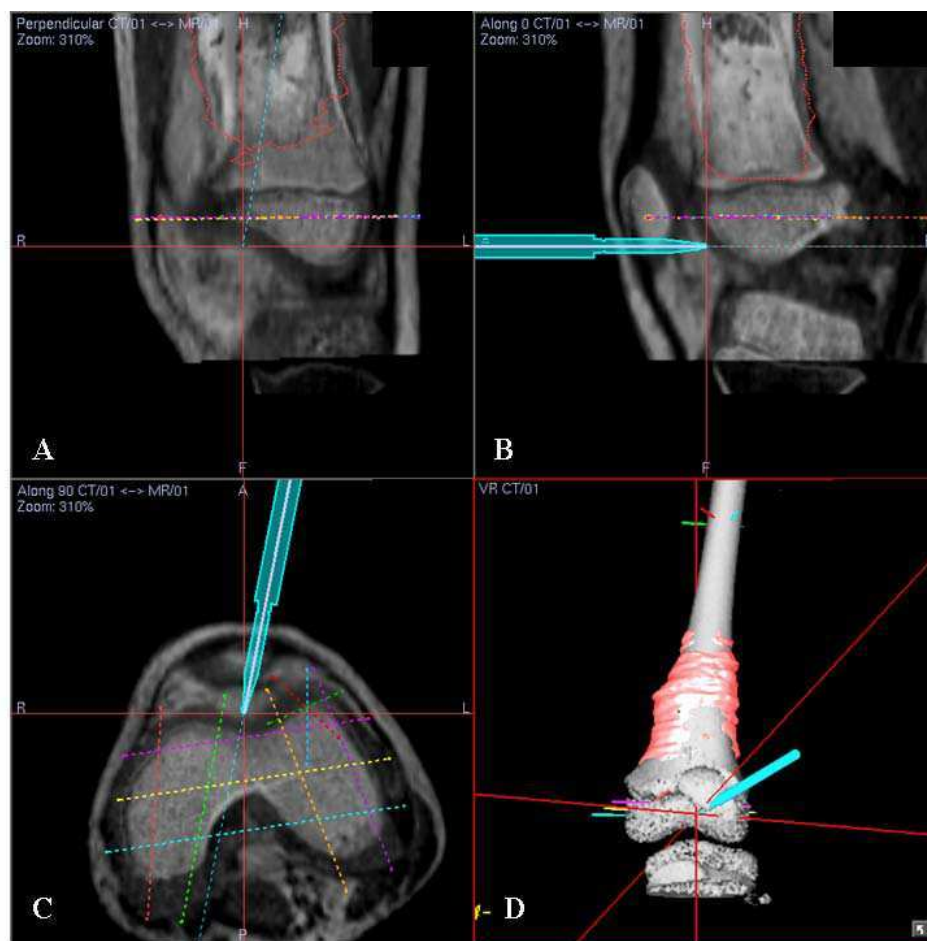


Fig. 2. (A) Coronal, (B) sagittal, (C) axial sections of CT/MR fused images and (D) 3-D bone tumor model for Patient 9 with left distal femur osteosarcoma are shown. After performing image-to-patient registration using paired points and surface matching at the surgery, we assessed the real-time matching between operative anatomy and the virtual images by running the registration probe on bone surface or by checking some anatomic landmarks. The registration was judged to be accurate and acceptable for subsequent navigation procedure as the tip of navigation probe matched well with the cartilage surface of distal femur

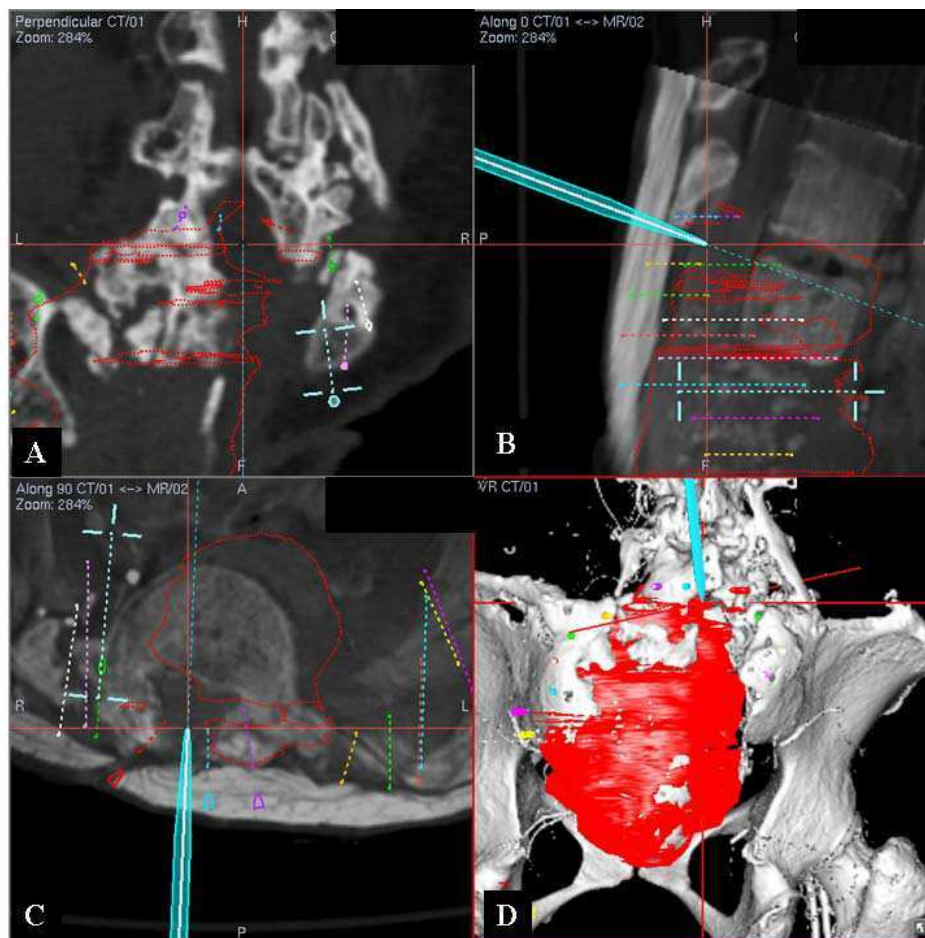


Fig. 3. (A) Coronal section of CT image, (B) sagittal and (C) axial sections of CT/MR fused images, and (D) 3-D bone tumor model for Patient 12 with recurrent mesenchymal chondrosarcoma of sacrum are shown. The patient had two previous operations and posterolateral fusion between lower lumbar spines and iliac crest. The tip of navigation probe was pointing at the location where previous laminectomy was performed at L5 level. Intraoperative navigation helped surgeons to identify with confidence the structures and intended bone resections in patients with distorted anatomy from their tumors or previous operations

We determined the results of CT-MR image fusion for CATS with the help of a navigation system by evaluating the: (1) additional information not seen on conventional images that was obtained for preoperative surgical planning; (2) the accuracy as registration error obtained intraoperatively that was defined as the average deviation between the same point in the preoperatively acquired navigation image and the actual patient's anatomy; (3) the accuracy of executing surgical plan as determined by comparing the cross sections at the resection plane and their preoperative navigation planning, assessing the fit of the custom prostheses to the remaining bone at the surgery, and assessing the histology of resection margins in all malignant tumor specimens. We did not validate the resections for Patients 4, 8 who had intralesional or marginal excision of their benign tumors and Patients 11, 12, 13, 18 and 19 as their resection planes were irregular or curved; (4) time required for navigation planning; (5) time required for operative set-up and execution of the navigation

procedures; (6) complications and local tumor recurrence; (7) functional outcome was assessed using the Musculoskeletal Tumor Society (MSTS) score in patients with limb salvage surgery (Enneking WF et al., 1993).

Computer Assisted Tumor Surgery (CATS) workflow

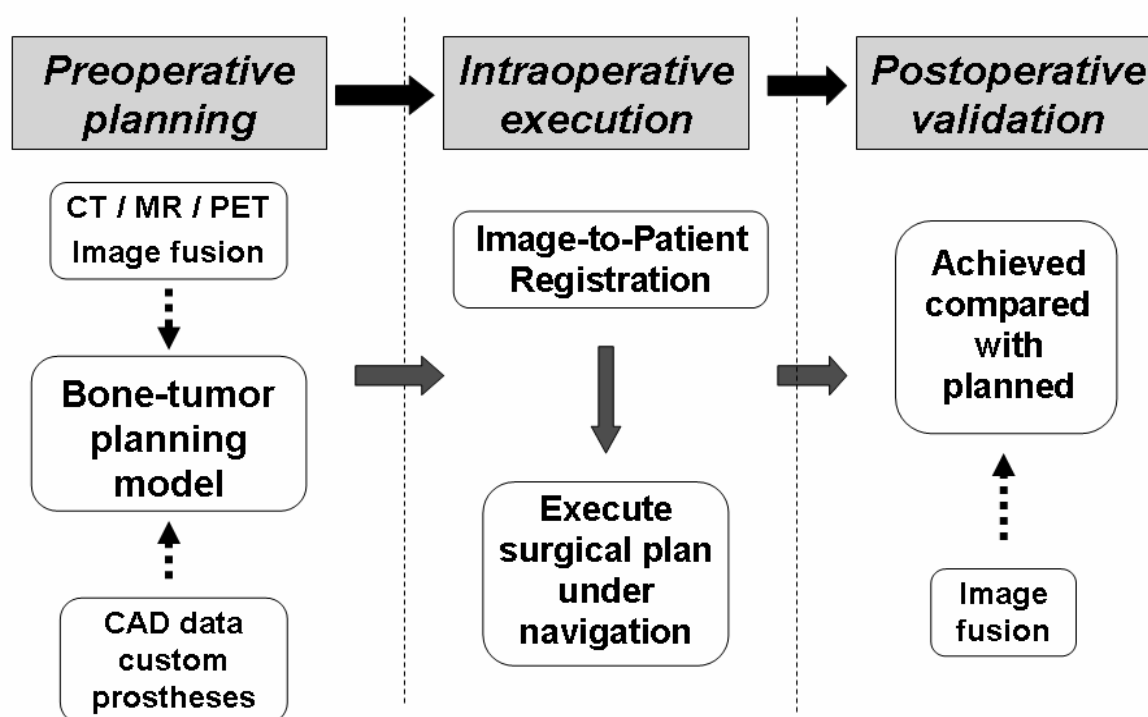


Fig. 4. The workflow of Computer-Assisted Tumor Surgery (CATS) used in the study is shown

3. Result

All tumor resections could be carried out as planned under navigation guidance. Navigation software enabled surgeons to examine all fused image datasets (CT / MRI / PET scan) together in two spatial and three spatial dimensions. It allowed easier understanding of the exact anatomical tumor location and relationship with surrounding structures. Intraoperatively, image guidance with the help of fusion images, provided precise visual orientation, easy identification of tumor extent, neural structures and intended resection planes in all cases. The bone resection could be precisely planned and executed in terms of exact level and orientation, according to the pre-defined tumor volume and data of custom prosthesis. For Patient 14 and 16, incorporation of data of CAD custom prostheses in the resection planning enabled multi-planar osteotomies and precise fit of CAD custom prostheses (Fig.5,6).

The resection achieved was as planned in 15 cases that were validated either by comparing the dimensions at the resection plane of resected specimens with that in the surgical

navigation planning or merging postoperative with preoperative CT images (Fig.7). Histological examination of all resected specimens in patients with malignant tumors showed a clear tumor margin.

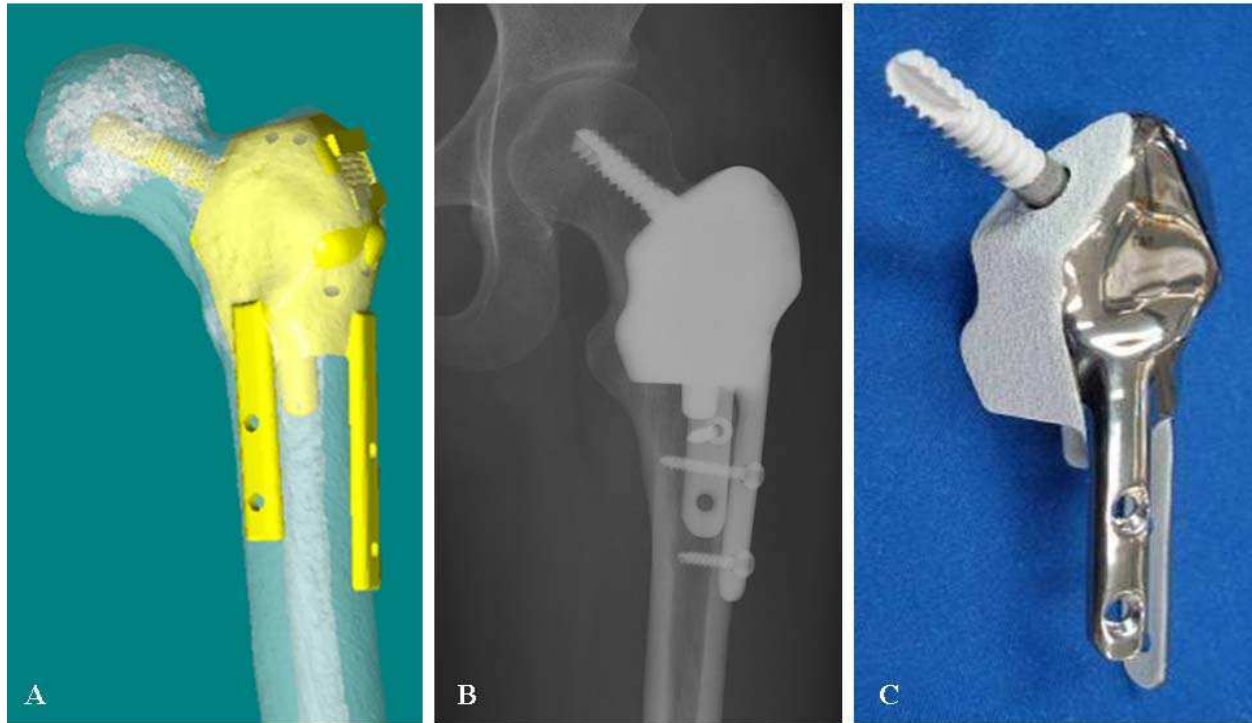


Fig. 5. (A) A joint-saving, CAD custom prosthesis in Patient 14 with low grade chondrosarcoma of left proximal femur is shown. (B) An antero-posterior view of plain radiograph of hip at postoperative one year is shown. The computer navigation technique allowed precise surgical planning, tumor resection and an accurate fit of a CAD custom prosthesis. (C) A specially designed custom prosthesis is shown. Additional extracortical plates and screw at femoral head offered excellent fixation and stability for the reconstruction. Hydroxyapatite that could facilitate osseointegration was coated at the surface of all bone-implant junctions of the prosthesis

We found the technique was particularly useful in pelvic, sacral tumors, joint-saving intercalated tumor resection and fitting of CAD custom-made prostheses.

The mean time for preoperative navigation planning was 1.85 hours (1 to 3.8). The mean time for intraoperative navigation procedures was 29.6 minutes (13 to 60). The time increased with case complexity but lessened with practice. The mean registration error was 0.47mm (0.31 to 0.8). The virtual preoperative images matched well with the patients' operative anatomy. A postoperative superficial wound infection developed in Patient 6 with sacral chordoma that resolved with antibiotic whereas a wound infection in Patient 11 with sacral osteosarcoma required surgical debridement and antibiotic. After a mean follow-up of 32.5 months (14 to 49), five patients died of distant metastases. Three out of four patients with local recurrence had tumors at sacral region. Three of them were soft tissue tumor

recurrence. The mean functional MSTS score in patients with limb salvage surgery was 28.3 (23 to 30). All patients (except one) with limb sparing surgery and prosthetic reconstruction could walk without aids.

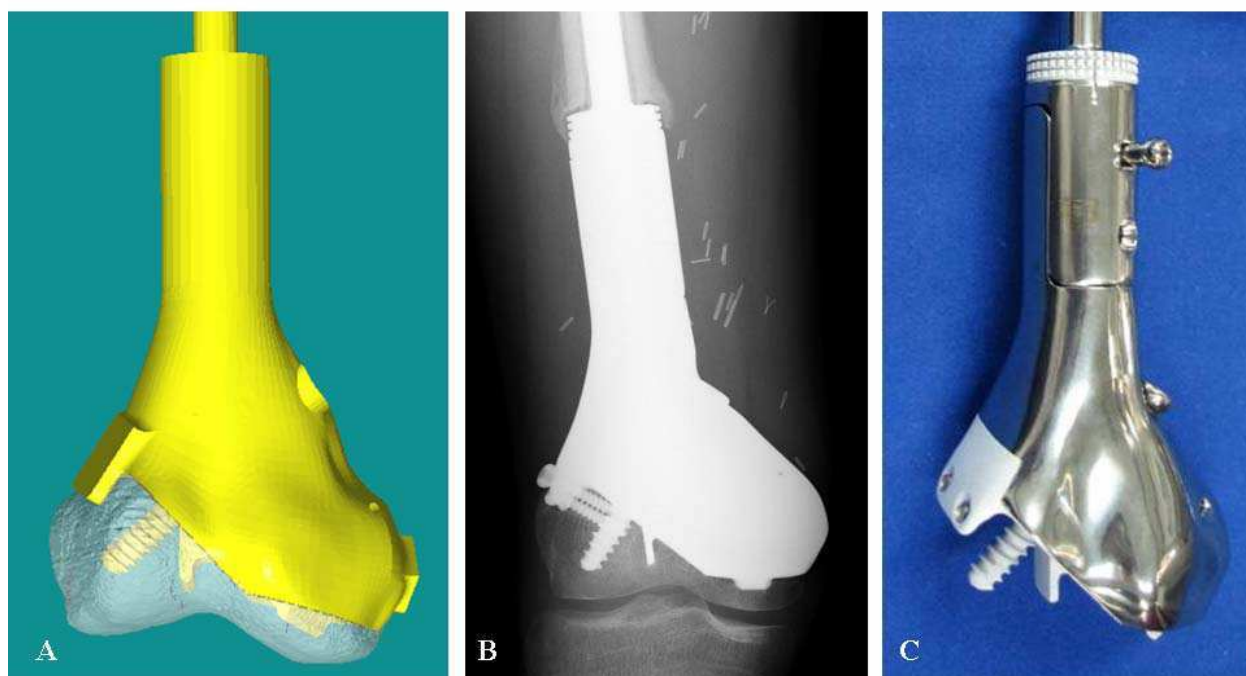


Fig. 6. (A) A joint-saving, CAD custom prosthesis in Patient 16 with right distal femur parosteal osteosarcoma is shown. With navigation planning, multiplanar osteotomies at distal femur was possible to allow joint-saving intercalated resection. The intended resection preserved soft tissue attachment (femur condylar insertion of cruciate ligaments and lateral collateral ligaments insertion) to the distal remaining bone. It allowed sufficient blood supply to the small bone segment. (B) An antero-posterior view of plain radiograph at postoperative one year is shown. Bone formation was present at the bone-implant junctions. The distal bone segment was viable without evidence of osteonecrosis. (C) A specially designed custom prosthesis is shown

4. Discussion

CT and MRI are complementary preoperative imaging investigations for planning complex musculoskeletal bone tumors resection and reconstruction. Conventionally, tumor surgeons analyze 2-D imaging information, mentally integrate and formulate a 3-D surgical plan. Difficulties are anticipated with increase in case complexity and distorted surgical anatomy. Although computer-assisted surgery has been widely used in cranial biopsies and tumor resection, only small case series with early experience are recently reported in the field of musculoskeletal tumor surgery. By including more patients with longer follow-up period in

the study, we investigated the results of image fusion for CATS in musculoskeletal oncology with the help of a navigation system.

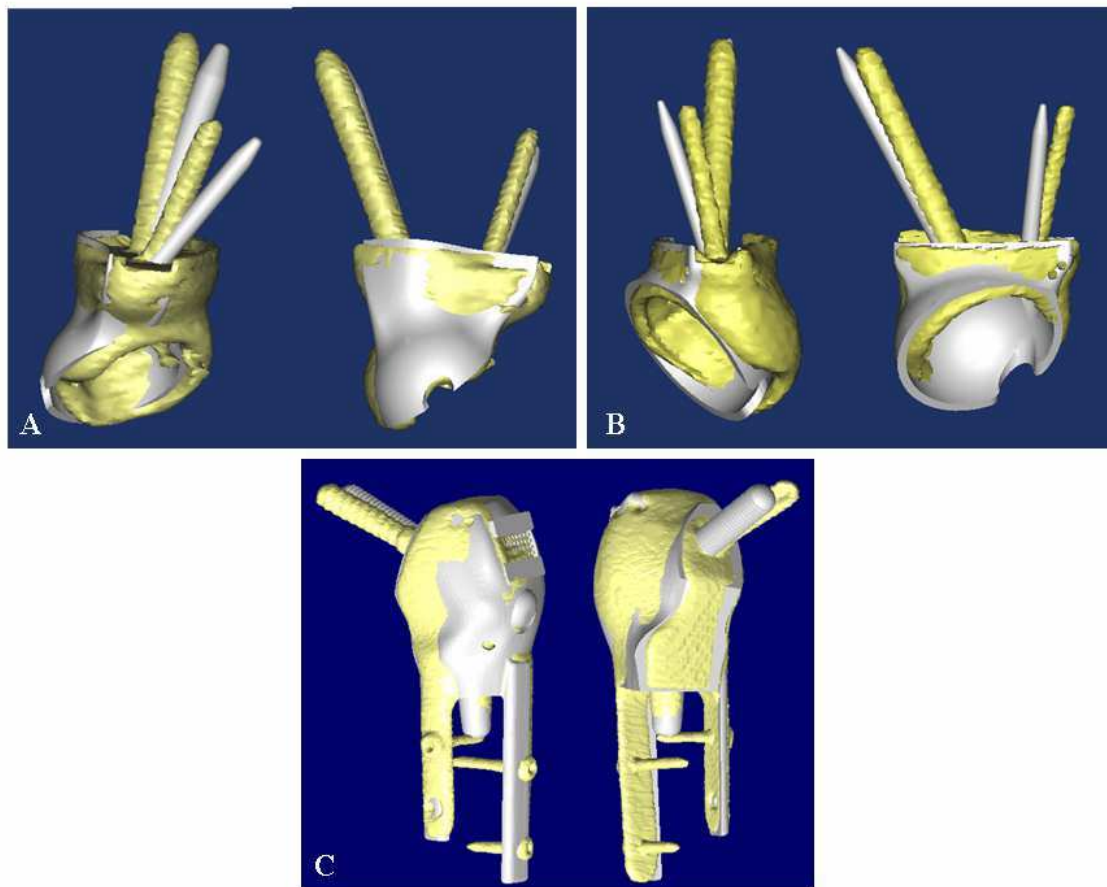


Fig. 7. Postoperative CT images were merged with preoperative planning for (A) Patient 10, (B) Patient 15 and (C) Patient 14. The achieved position (yellow colour) of a custom prosthesis could be compared to that of planned (silver color). The comparable position between the achieved and planned suggested that CATS might improve the surgical accuracy of tumor resection and reconstruction with CAD custom prosthesis

MRI based navigation has been described if fiducial markers for registration are implanted prior to MRI scanning (Kim JH et al., 2010). However, an additional operation for inserting markers is necessary. The operation is also difficult via a small wound access under local anaesthesia, in particularly if the involved bone is deep and covered by thick soft tissue. Our results showed that accurate image-to-patient registration of error < 1mm was feasible and reproducible in CT-based navigation. It was adopted for computer-assisted bone tumor surgery. Fusing multimodal images (CT / MR) could provide additional information besides bone information from CT images.

A study had investigated the surgical accuracy of an experienced surgeon in performing a pelvic tumor resection with 1-cm surgical margin (Cartiaux O et al., 2008). Authors reported that the surgeon could achieve 1-cm surgical margin (± 5 mm) in a probability of only 52%. The difficult pelvic anatomy and its complex geometry might contribute to the inaccuracy. Our results showed that image fusion and CATS technique allowed better surgical planning,

improved intraoperative visualization and determination of intended resection. In this study, the registration error of $< 1\text{mm}$ and the achieved resection comparable to planned resection suggested that surgeons should have a higher chance of reproducing their surgical plans and enhancing the accuracy of bone tumors surgery. This detailed and interactive image analysis is particularly helpful in difficult pelvic, sacral, or joint-saving bone tumor resections.

Currently assessing resection margins intraoperatively is possible by means of frozen section. If it is positive, they can be regarded as a guide to additional resection. When it is negative, they add no information about the distance from the tumor. Our results suggested that we could validate the clear margin and quantify the distance from the tumor boundaries by means of images navigation guidance following tumor resection at the surgery.

Reports have described the use of computer navigation in joint-saving tumor resection (Cho HS et al., 2009; Wong KC et al., 2007; Wong KC et al., 2008). We also found that the CATS technique enabled us to perform accurate joint-saving tumor resection and precise fit of CAD custom prostheses for Patient 5, 7, 9, 14, 16, 20 which would not have been possible without an accurate guide to the plane of intended resection. In Patients 14, 16, intended resection was not restricted to an osteotomy along a single plane and multiplanar osteotomies were possible around bone tumors. It could maximally preserve the adjacent normal tissue for subsequent bony reconstruction but yet achieve adequate surgical margin. The technique therefore might facilitate an accurate fit of a CAD custom prosthesis to a skeletal defect with complex geometry. We believe that the technique with similar workflow is feasible for various types of allograft reconstruction in musculoskeletal tumor surgery (Muscolo DL et al., 2006). It has great potential for allograft selection in bone bank by CT-CT image fusion; transepiphyseal resection intercalary allograft reconstruction; or hemicondylar allograft reconstruction, etc.

Although CAD/CAM software allows surgeons to perform virtual surgical simulation with the preoperative image data sets, it still relies on surgeons' experience to implement the exact surgical planning at the time of surgery. The difficulty increases with complexity of cases. Commercially available surgical navigation systems only accept medical imaging data in DICOM format and do not offer complex surgical simulation on these data. On the other hand, CAD/CAM software can import medical imaging data in DICOM format for virtual manipulation. However, the surgical simulation in its proprietary format of the software is incompatible for direct use in surgical navigation system. We find that image fusion of both the original CT data sets and virtual surgical plan data sets (CAD format is back converted to DICOM format by MIMICS software) can enhance the capacity of surgical navigation in executing virtual surgical plans. For surgical planning of musculoskeletal tumors, image fusion of virtual CT data sets with custom prosthesis and original CT data sets allow accurate planning of resection planes and thus precise fitting of custom tumor prosthesis to the residual bone segment after tumor resection. Therefore, image fusion may enable surgeons to precisely execute complex virtual surgical simulation with any CT-based surgical navigation system at the time of actual surgery.

Four patients developed local recurrence and three of them were located at sacral region in this study. The higher chance of recurrence in these patients might be explained by the fact that the nature of the tumor itself; they all had large soft tissue extraosseous tumor extension and two of them were operated as recurrent cases. Although CATS could help visualize and

plan the surgery, navigation by itself could only assist and guide the final bone resection at the surgery. Surgeons still adopted conventional technique in soft tissue.

During navigation surgery, surgeons have to look at virtual preoperative images on the screen and cannot simultaneously look at the operative site and screen, which can be a source of surgical errors. Other potential sources of navigation errors may include displacement of patient's dynamic reference tracker, changes of the operative anatomy in relation to the preoperative image data, incorrect calibration of navigation tools, surgeons' perception inaccuracies or hand tremor, etc. Therefore, surgeons should have full understanding of the principles and possible errors of the computer technology, so to avoid misinterpretation of navigation information for their operations. Procedural and surgical skill training is necessary for optimal and correct use of the technique.

Limitations of this study include patients with heterogeneous diagnosis, the lack of control subjects to make a comparative assessment of clinical results. The potential benefits of the CATS technique in improving surgical accuracy may not imply good clinical results in terms of better patients' survival and reduced local recurrence. The small study size, nonrandomized and the early results may not allow us to confirm the value of using this technique, which requires additional financial investment and effort when compared to conventional technique. Without well conducted clinical trials with larger sample size, the utility of the CATS technique may not be realized.

6. Conclusion

Our study suggests Computer-Assisted Tumor Surgery (CATS) with image fusion offers advanced preoperative 3-D surgical planning and supports surgeons with precise intraoperative visualization and identification of intended resection for pelvic, sacral tumors. It enables surgeons to reliably perform joint sparing intercalated tumor resection and accurately fit CAD custom-made prostheses for the resulting skeletal defect. Long-term clinical studies and basic studies of navigation errors are necessary to confirm its value in musculoskeletal tumor surgery.

7. Reference

- Anderson KC, Buehler KC, Markel DC. (2005). Computer assisted navigation in total knee arthroplasty: comparison with conventional methods. *J Arthroplasty* 2005 Oct; 20 (7 Suppl 3): 132-8.
- Cartiaux O, Docquier PL, Paul L, Francq BG, Cornu OH, Delloye C, Raucet B, Dehez B, Banse X. (2008). Surgical inaccuracy of tumor resection and reconstruction within the pelvis: an experimental study. *Acta Orthop.* 2008 Oct; 79(5):695-702.
- Cho HS, Kang HG, Kim HS, Han I. (2008). Computer-assisted sacral tumor resection. A case report. *J Bone Joint Surg Am.* 2008 Jul; 90(7):1561-6.
- Cho HS, Oh JH, Han I, Kim HS. (2009). Joint-preserving limb salvage surgery under navigation guidance. *J Surg Oncol.* 2009 Sep 1; 100(3):227-32.
- Docquier PL, Paul L, Cartiaux O, Banse X. Registration accuracy in computer-assisted pelvic surgery. (2009). *Comput Aided Surg.* 2009 Jun 9:1-8. [Epub ahead of print]
- Eggers G, Mühling J, Marmulla R. (2006). Image-to-patient registration techniques in head surgery. *Int J Oral Maxillofac Surg.* 2006 Dec;35(12):1081-95.

- Enneking WF, Dunham W, Gebhardt MC, Malawer M, Pritchard D. (1993). A system for functional evaluation of reconstructive procedures after surgical treatment of tumors of the musculoskeletal system. *Clin Orthop* 1993; 286: 241-6.
- Fehlberg S, Eulenstein S, Lange T, Andreou D, Tunn PU. (2009). Computer-assisted pelvic tumor resection: fields of application, limits, and perspectives. *Recent Results Cancer Res.* 2009; 179: 169-82. Review.
- Gebhardt F, Weidner A, Liener UC, Stockle U, Arand M. (2004). Navigation at the spine. *Injury.* 2004 Jun; 35 Suppl 1:S-A35-45. Review.
- Grunert P, Darabi K, Espinosa J, Filippi R. (2003). Computer-aided navigation in neurosurgery. *Neurosurg Rev.* 2003 May; 26(2):73-99; discussion 100-1.
- Grutzner PA, Suhm N. (2004). Computer aided long bone fracture treatment. *Injury.* 2004 Jun; 35 Suppl 1:S-A57-64.
- Hüfner T, Kfuri M Jr, Galanski M, Bastian L, Loss M, Pohlemann T, Krettek C. (2004). New indications for computer-assisted surgery: tumor resection in the pelvis. *Clin Orthop Relat Res.* 2004 Sep;(426):219-25.
- Kim JH, Kang HG, Kim HS. (2010). MRI-guided navigation surgery with temporary implantable bone markers in limb salvage for sarcoma. *Clin Orthop Relat Res.* 2010 Aug; 468(8):2211-7. Epub 2010 Jan 7.
- Krettek C, Geerling J, Bastian L, Citak M, Rücker F, Kendoff D, Hüfner T. (2004). Computer aided tumor resection in the pelvis. *Injury.* 2004 Jun; 35 Suppl 1:S-A79-83.
- Laine T, Lund T, Ylikoski M, Lohikoshi J, Schlenzja D. (2000). Accuracy of pedicle screw insertion with and without computer assistance: A randomized controlled clinical study in 100 consecutive patients. *European Spine J* 2000; 9(3): 235-40.
- Muscolo DL, Ayerza MA, Aponte-Tinao LA. (2006). Massive allograft use in orthopedic oncology. *Orthop Clin North Am.* 2006 Jan; 37(1):65-74. Review.
- Reijnders K, Coppes MH, van Hulzen AL, Gravendeel JP, van Ginkel RJ, Hoekstra HJ. (2007). Image guided surgery: new technology for surgery of soft tissue and bone sarcomas. *Eur J Surg Oncol.* 2007 Apr;33(3):390-8. Epub 2006 Nov 29.
- Wixson RL, MacDonald MA. Total hip arthroplasty through a minimal posterior approach using imageless computer-assisted hip navigation. (2005). *J Arthroplasty* 2005 Oct; 20 (7 Supp 3): 51-6.
- Wong KC, Kumta SM, Chiu KH, Cheung KW, Leung KS, Unwin P, Wong MC. (2007). Computer assisted pelvic tumor resection and reconstruction with a custom-made prosthesis using an innovative adaptation and its validation. *Comput Aided Surg.* 2007 Jul; 12(4):225-32.
- Wong KC, Kumta SM, Chiu KH, Antonio GE, Unwin P, Leung KS. (2007). Precision tumour resection and reconstruction using image-guided computer navigation. *J Bone Joint Surg Br.* 2007 Jul; 89(7):943-7.
- Wong KC, Kumta SM, Antonio GE, Tse LF. (2008). Image fusion for computer-assisted bone tumor surgery. *Clin Orthop Relat Res.* 2008 Oct; 466(10):2533-41. Epub 2008 Jul 22.




Image Fusion

Edited by Osamu Ukimura

ISBN 978-953-307-679-9

Hard cover, 428 pages

Publisher InTech

Published online 12, January, 2011

Published in print edition January, 2011

Image fusion technology has successfully contributed to various fields such as medical diagnosis and navigation, surveillance systems, remote sensing, digital cameras, military applications, computer vision, etc. Image fusion aims to generate a fused single image which contains more precise reliable visualization of the objects than any source image of them. This book presents various recent advances in research and development in the field of image fusion. It has been created through the diligence and creativity of some of the most accomplished experts in various fields.

How to reference

In order to correctly reference this scholarly work, feel free to copy and paste the following:

K.C. Wong, S.M. Kumta, L.F. Tse, E.W.K. Ng and K.S. Lee (2011). Image Fusion for Computer Assisted Tumor Surgery (CATS), Image Fusion, Osamu Ukimura (Ed.), ISBN: 978-953-307-679-9, InTech, Available from: <http://www.intechopen.com/books/image-fusion/image-fusion-for-computer-assisted-tumor-surgery-cats->

INTECH
open science | open minds

InTech Europe

University Campus STeP Ri
Slavka Krautzeka 83/A
51000 Rijeka, Croatia
Phone: +385 (51) 770 447
Fax: +385 (51) 686 166
www.intechopen.com

InTech China

Unit 405, Office Block, Hotel Equatorial Shanghai
No.65, Yan An Road (West), Shanghai, 200040, China
中国上海市延安西路65号上海国际贵都大饭店办公楼405单元
Phone: +86-21-62489820
Fax: +86-21-62489821